

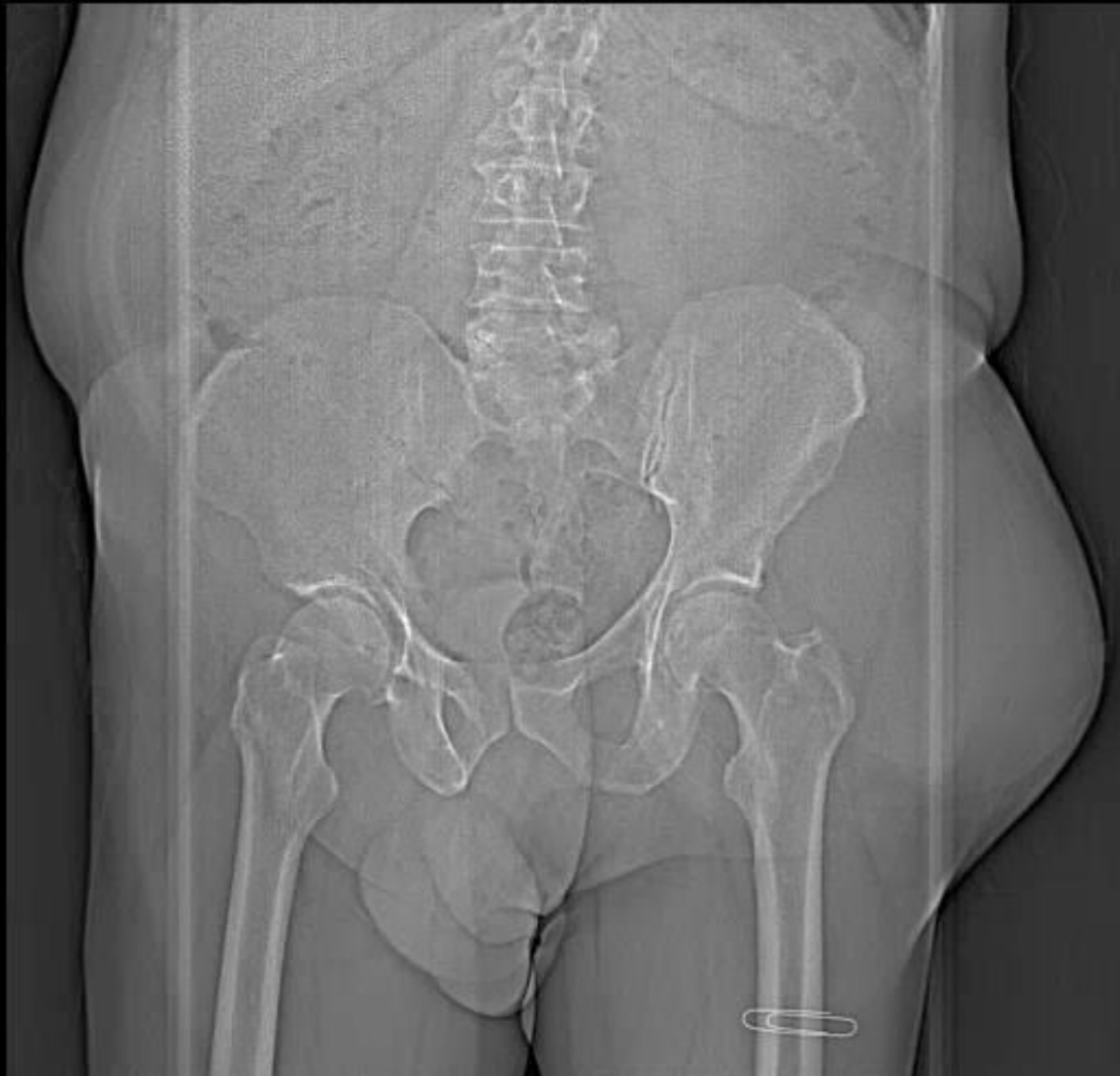# Best Cases of the AIRP

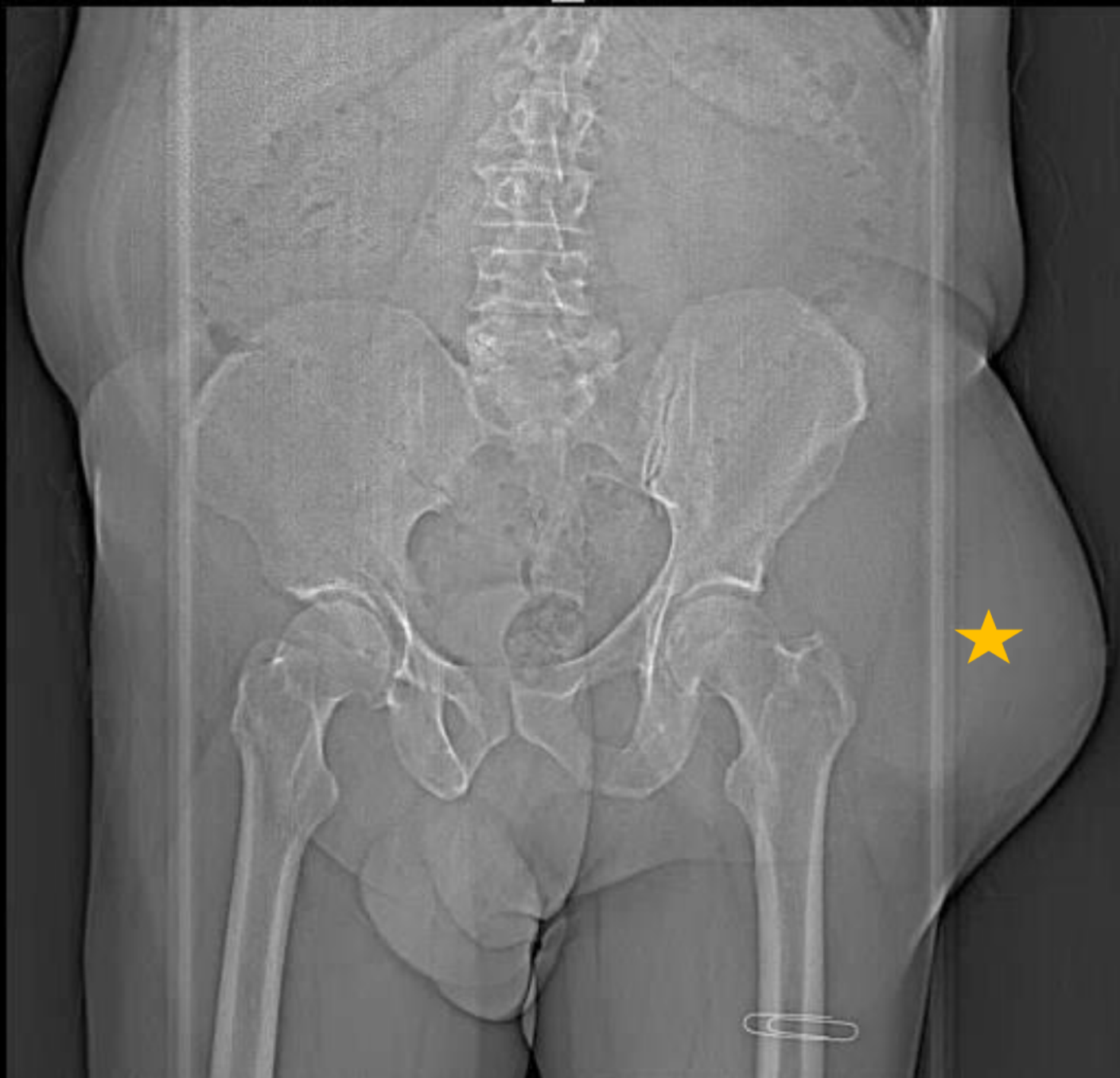
February-March, 2016

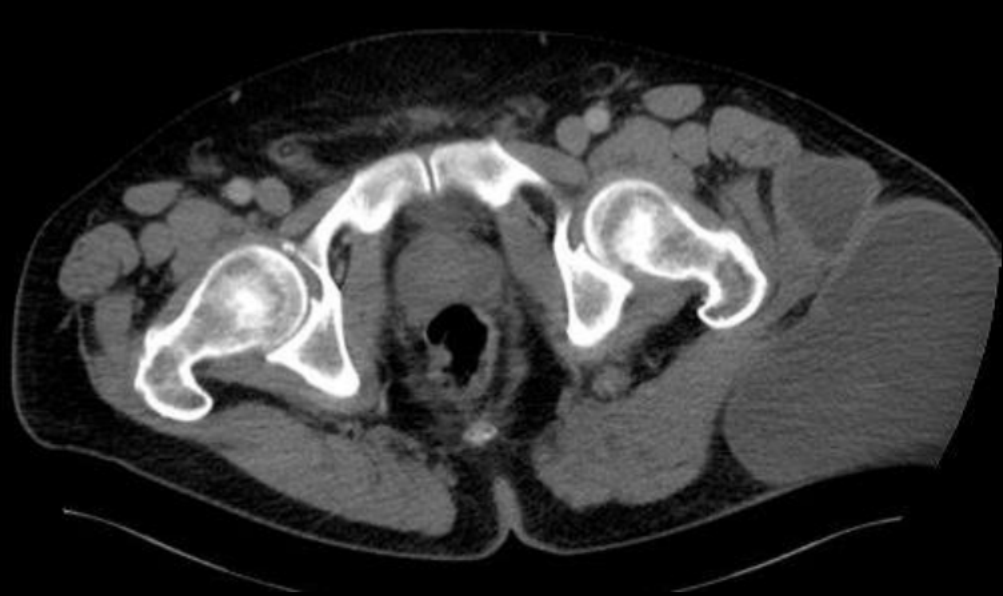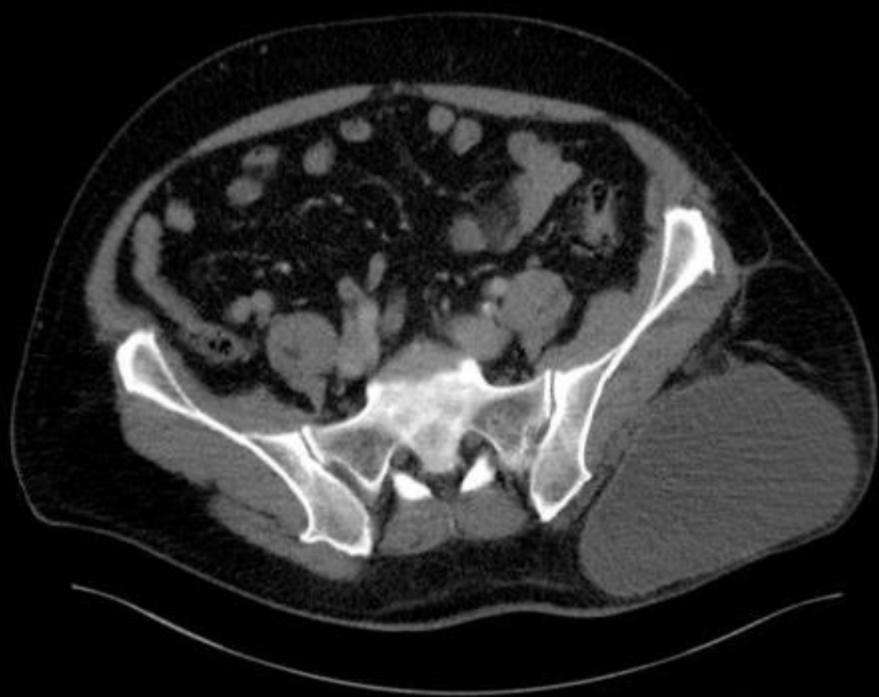


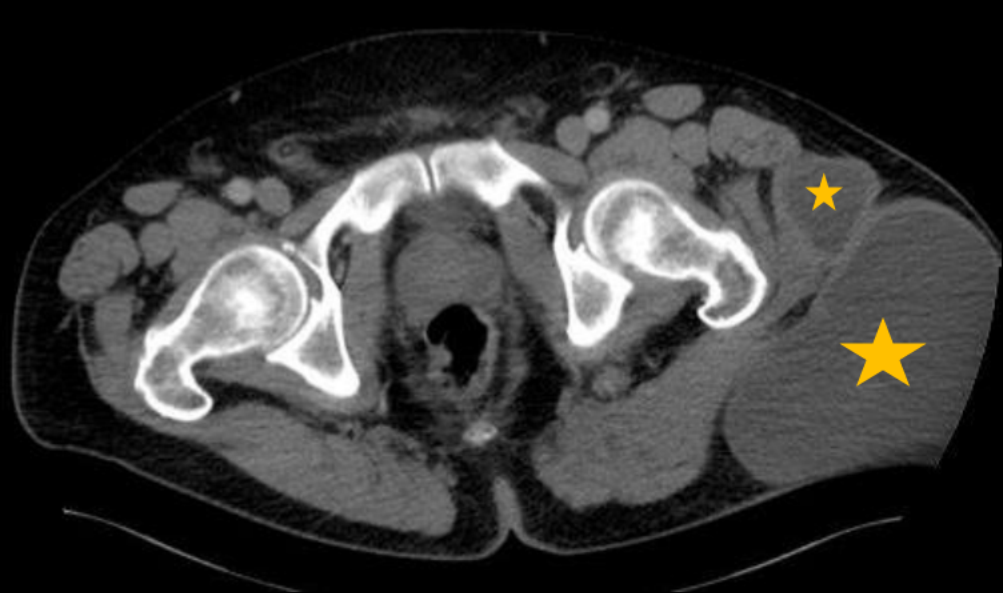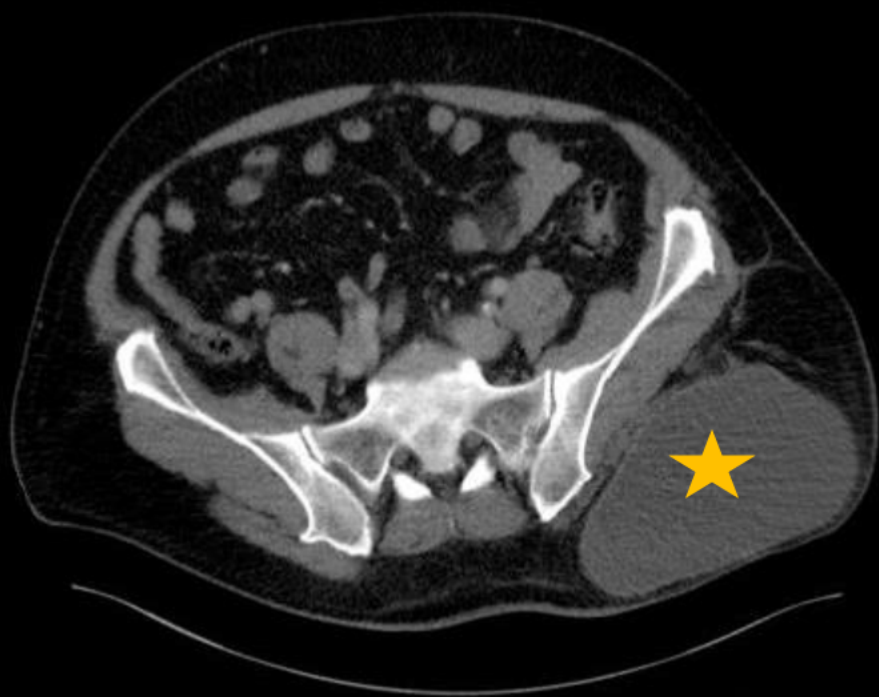


67-year-old male with enlarging left gluteal mass. Left buttock injury in MVA 25 years ago. Left buttock injury in a fall more recently

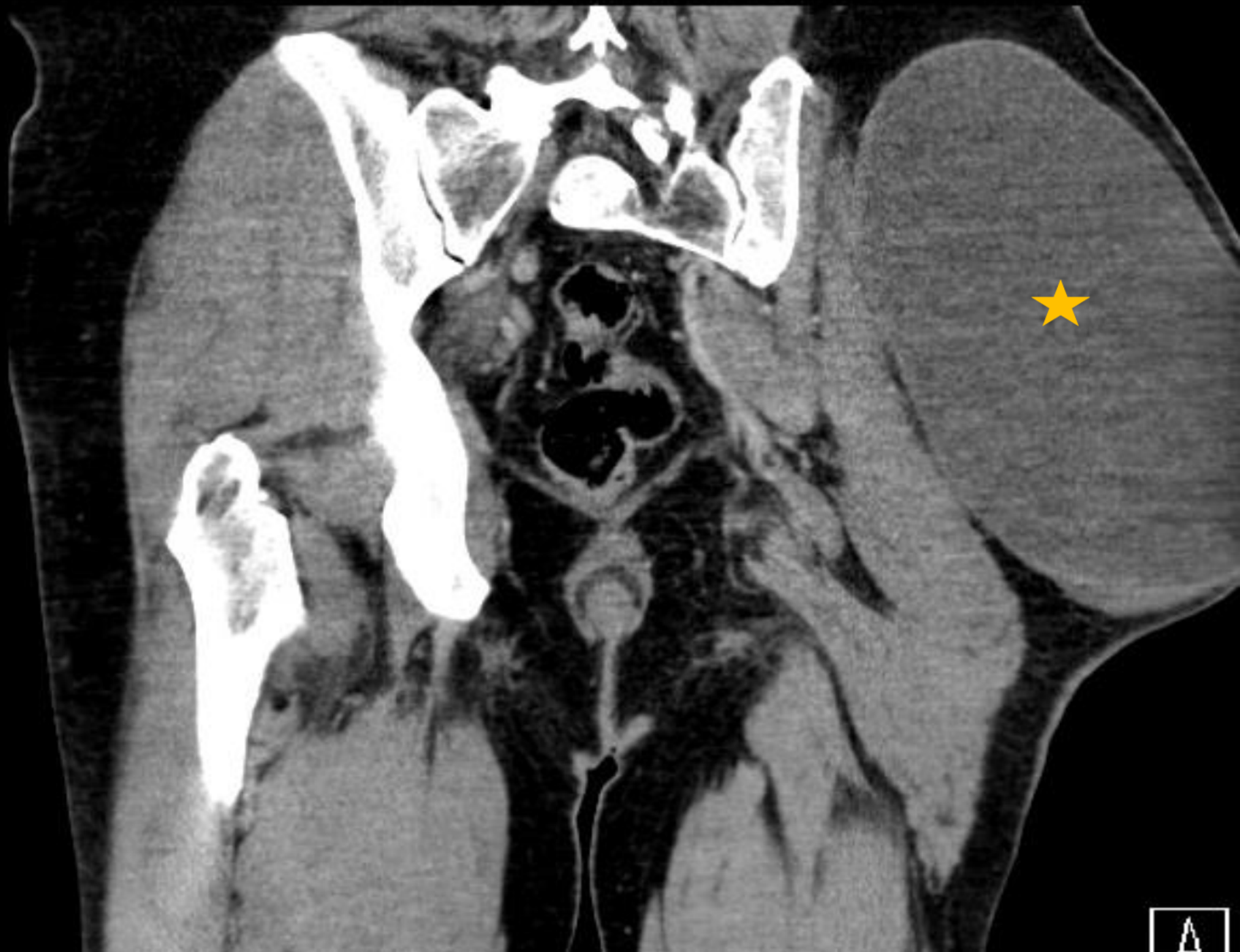


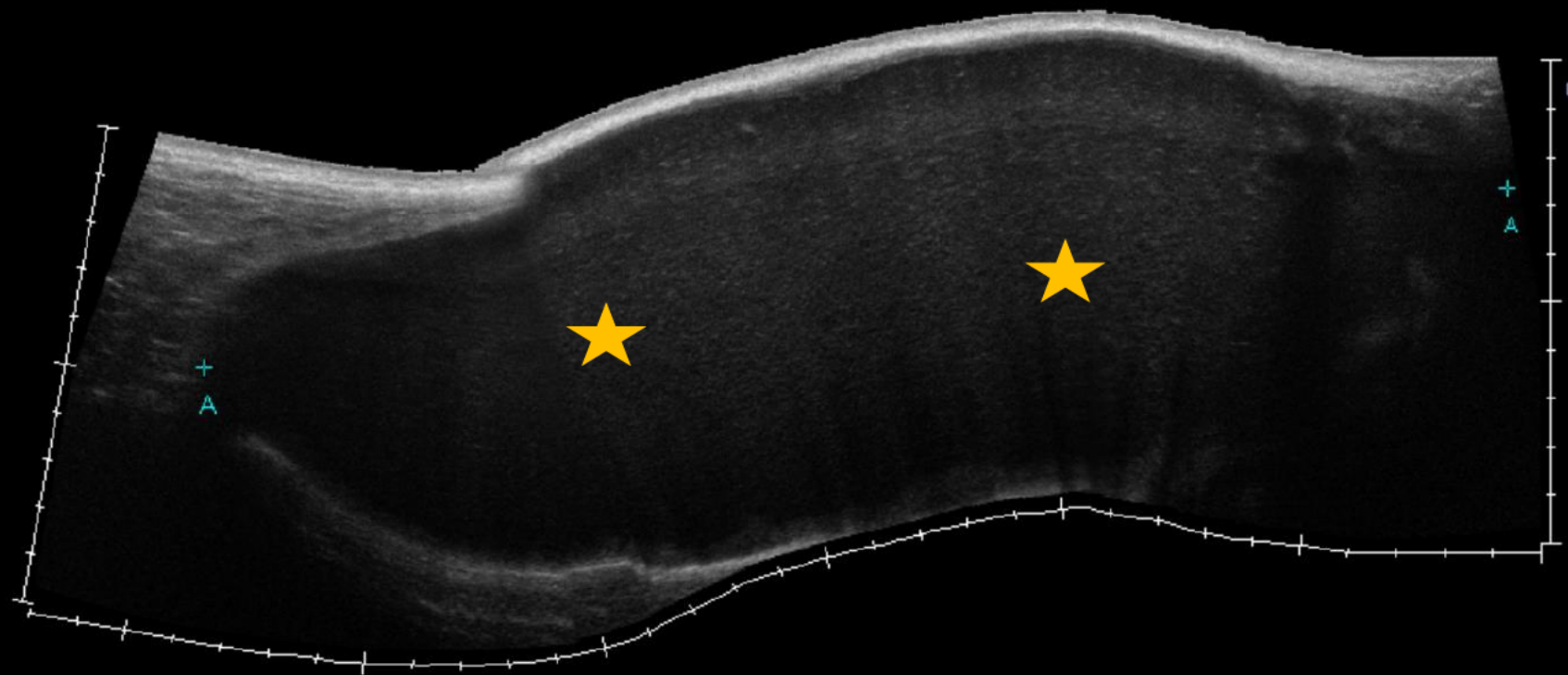











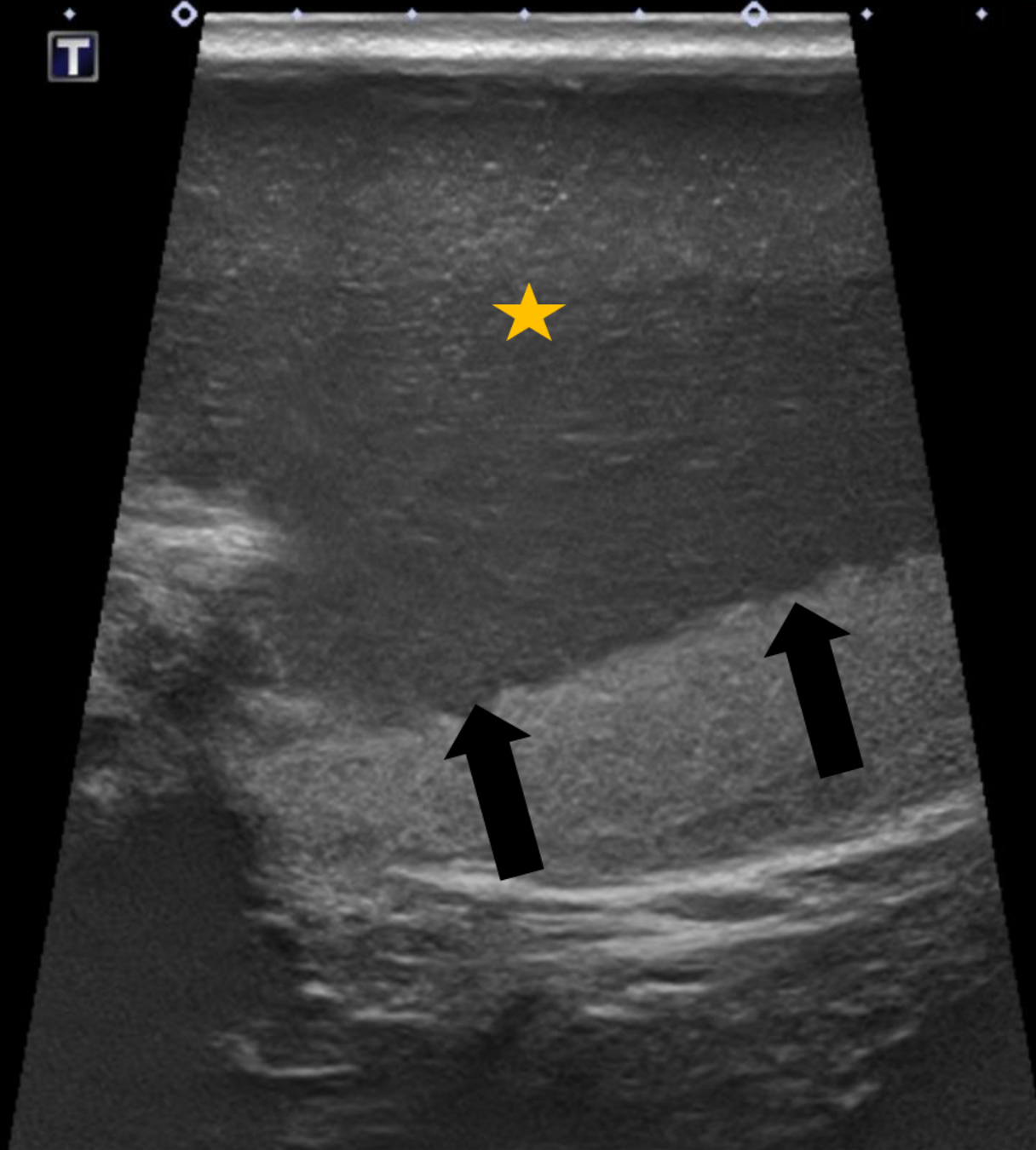
12L5  
diffT9.0  
16 fps  
Qscan  
G:100  
DR:70



T

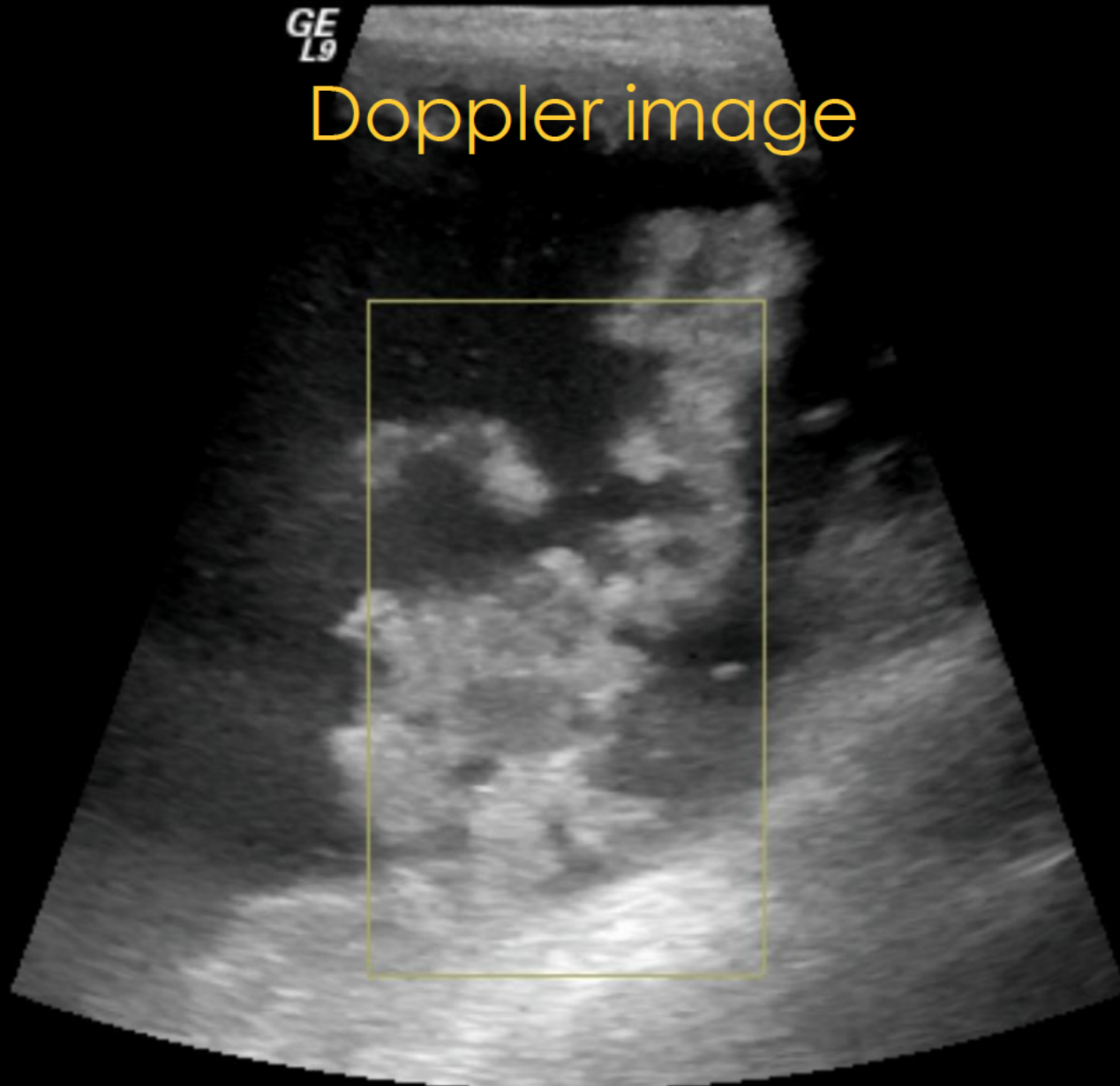


T

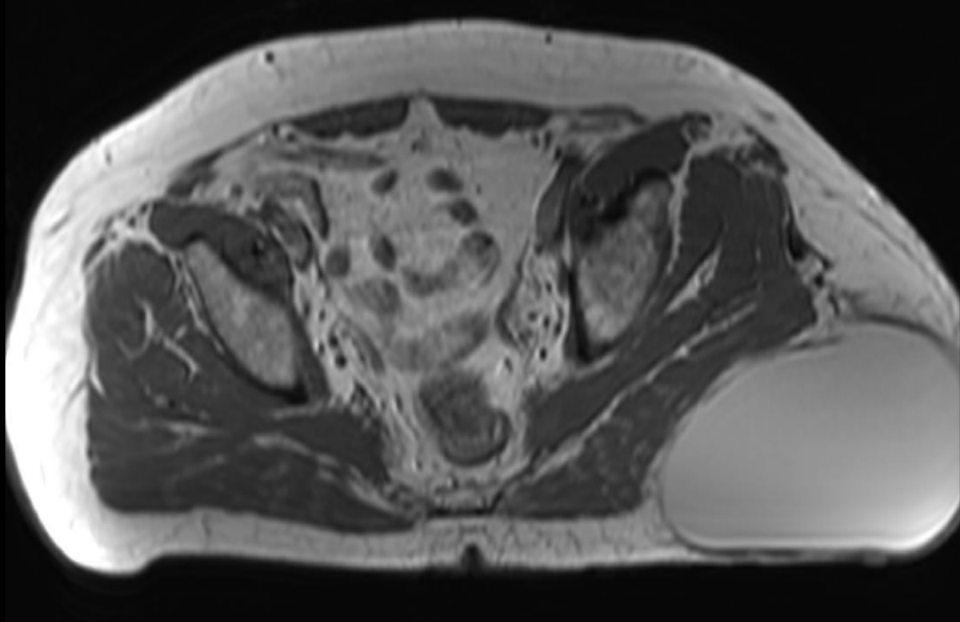


GE  
L9

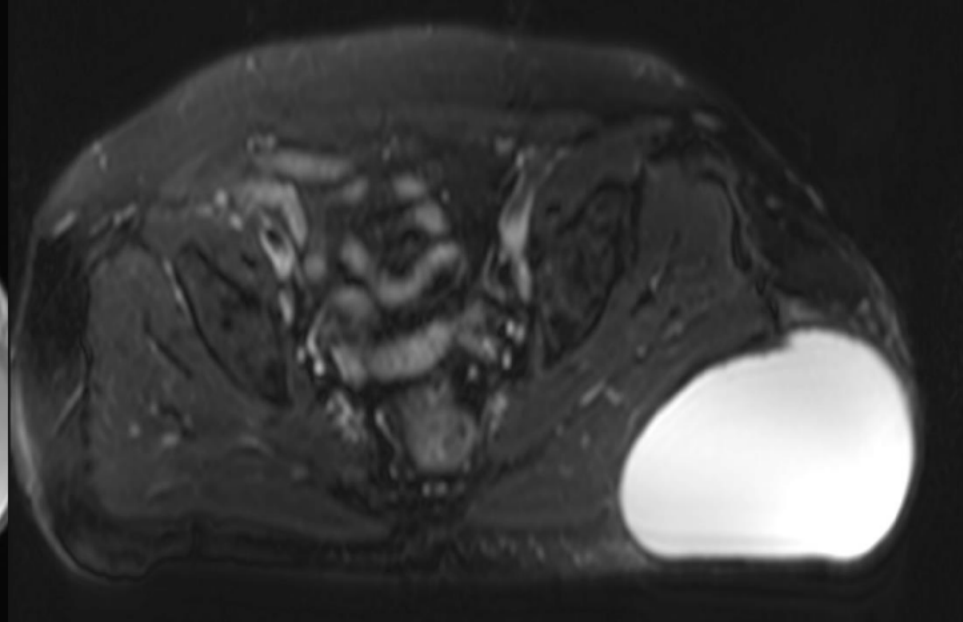
Doppler image



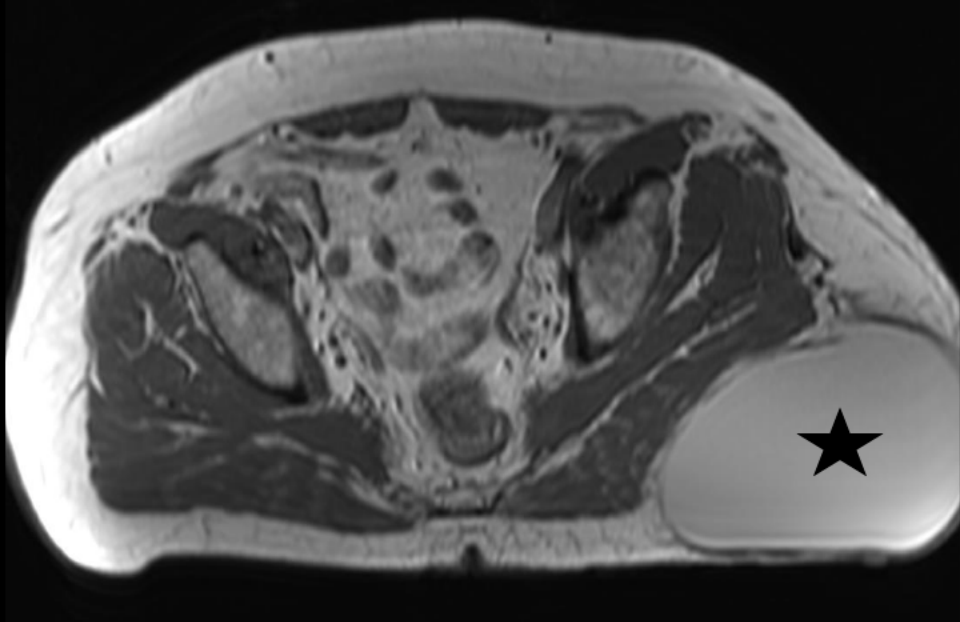
LAT LEFT BUTTOCK



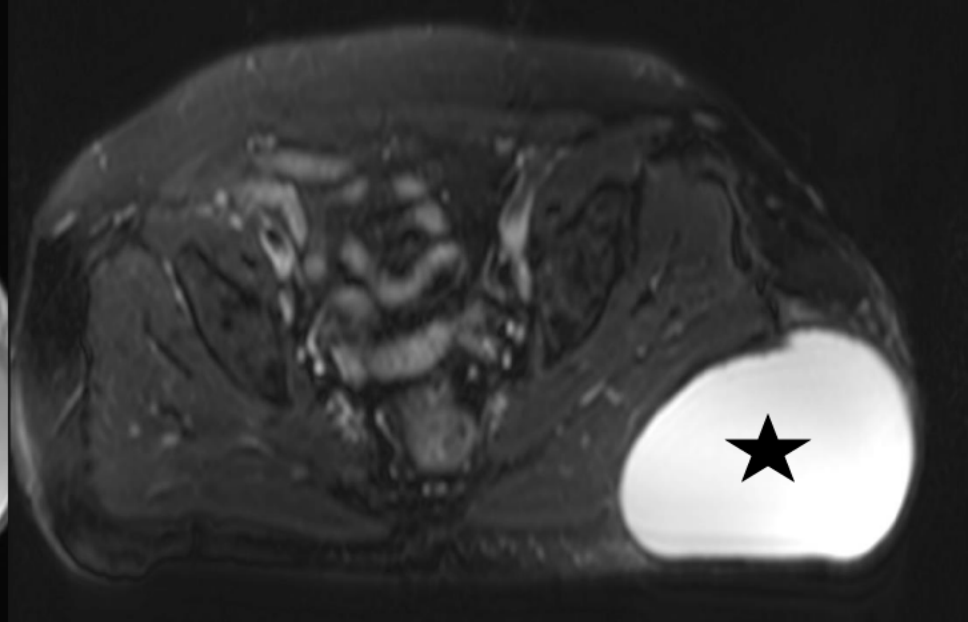
T1 non FS



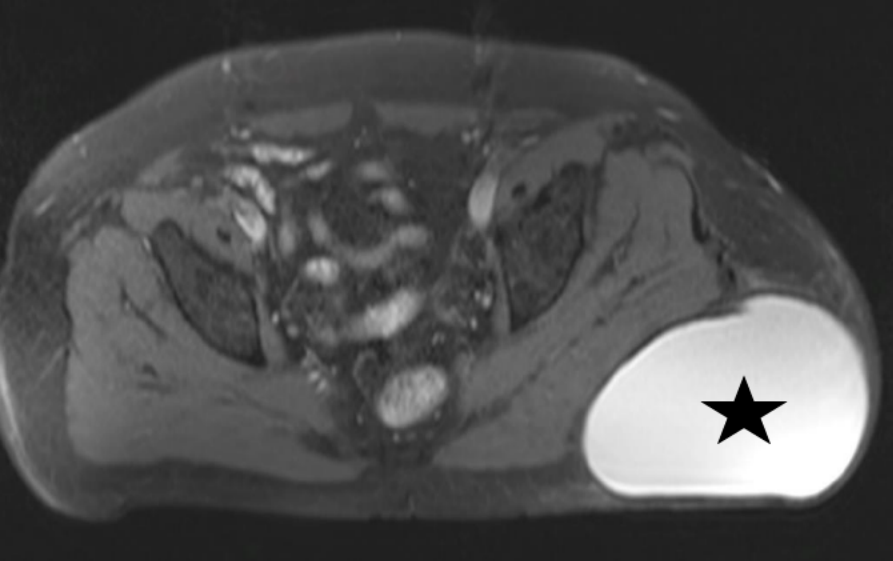
T2 FS images



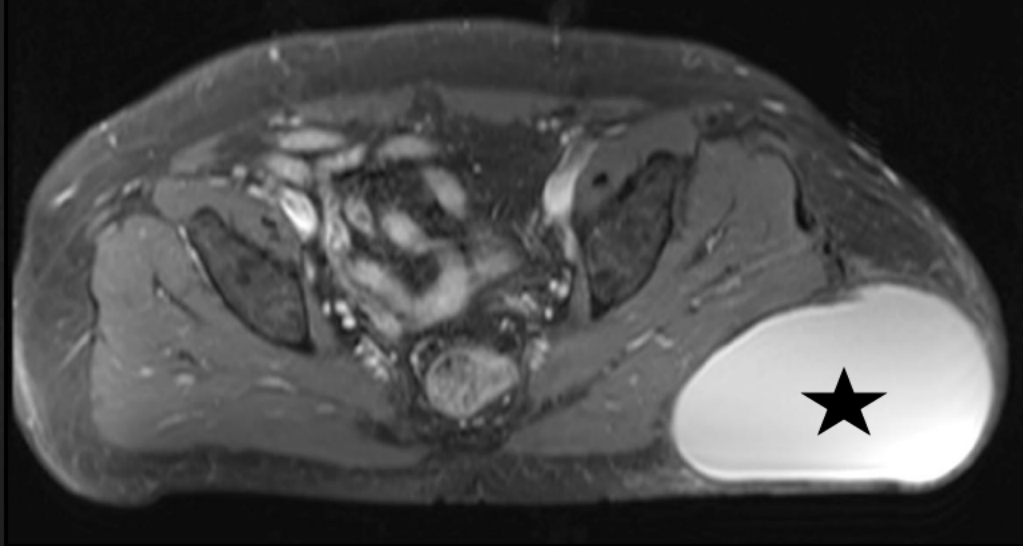
T1 non FS



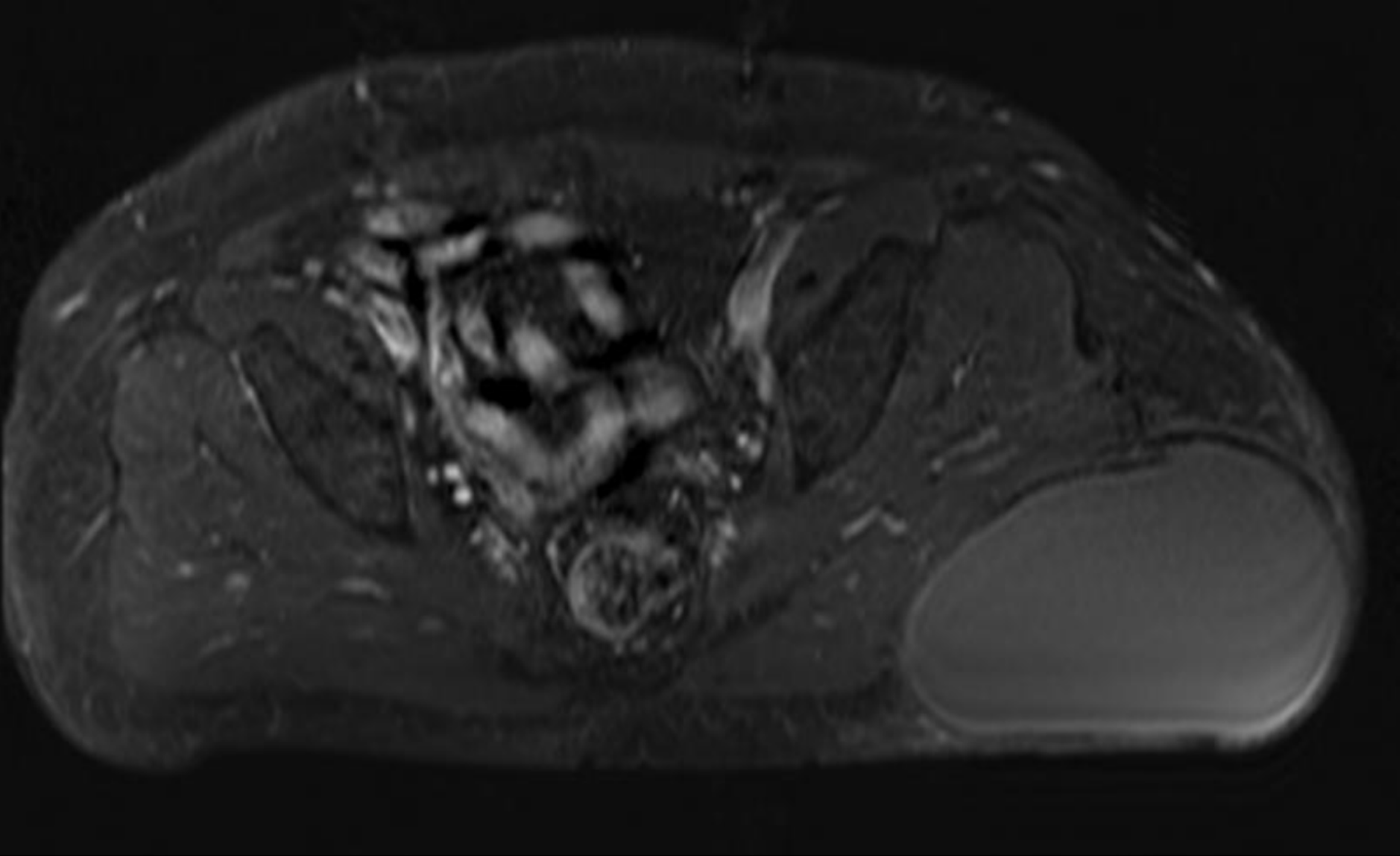
T2 FS images



T1 FS Pre

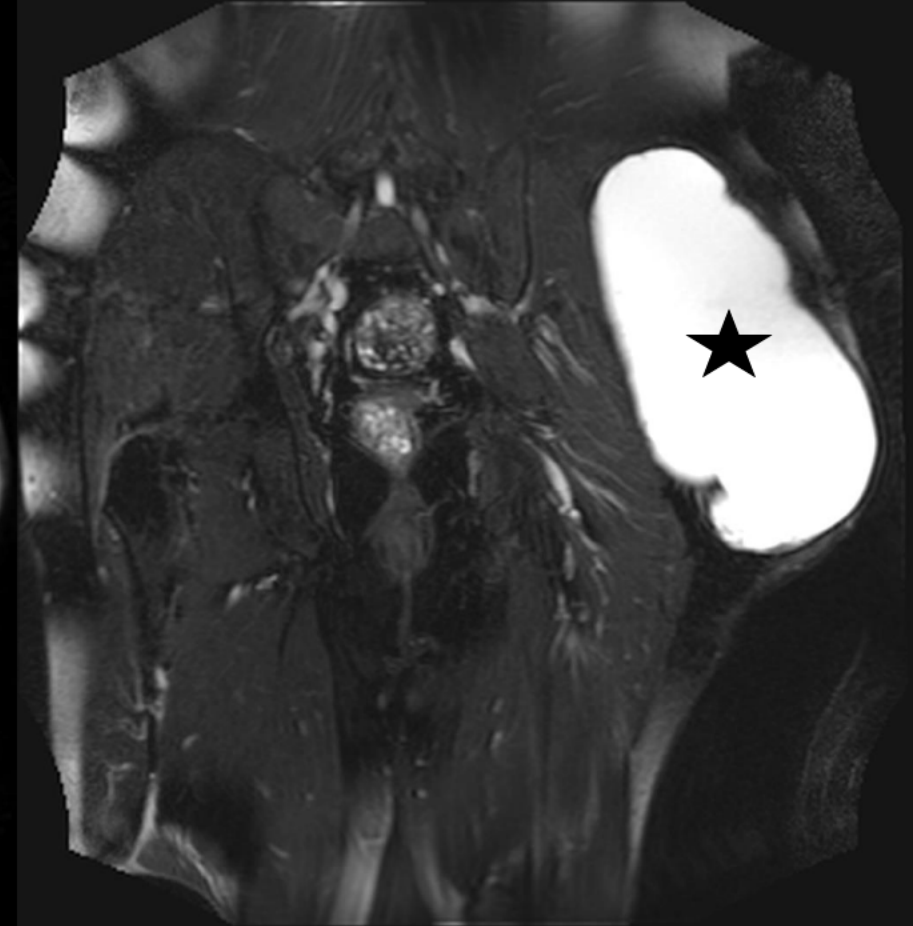
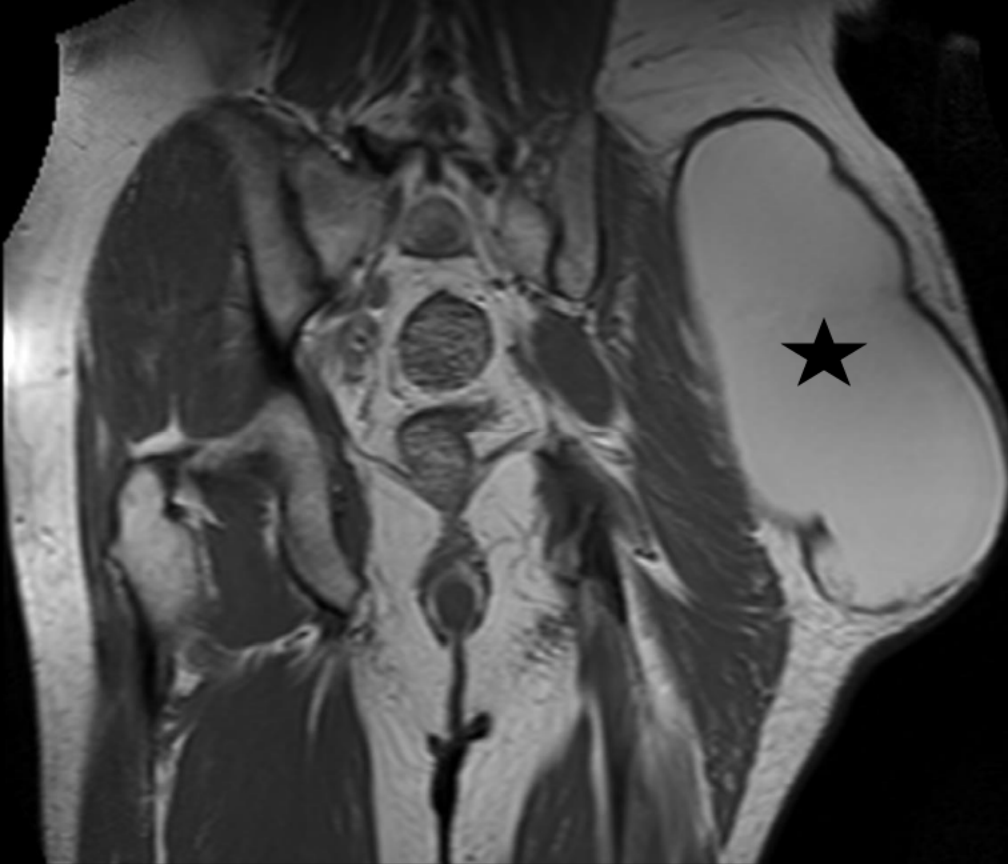


T1 FS Post



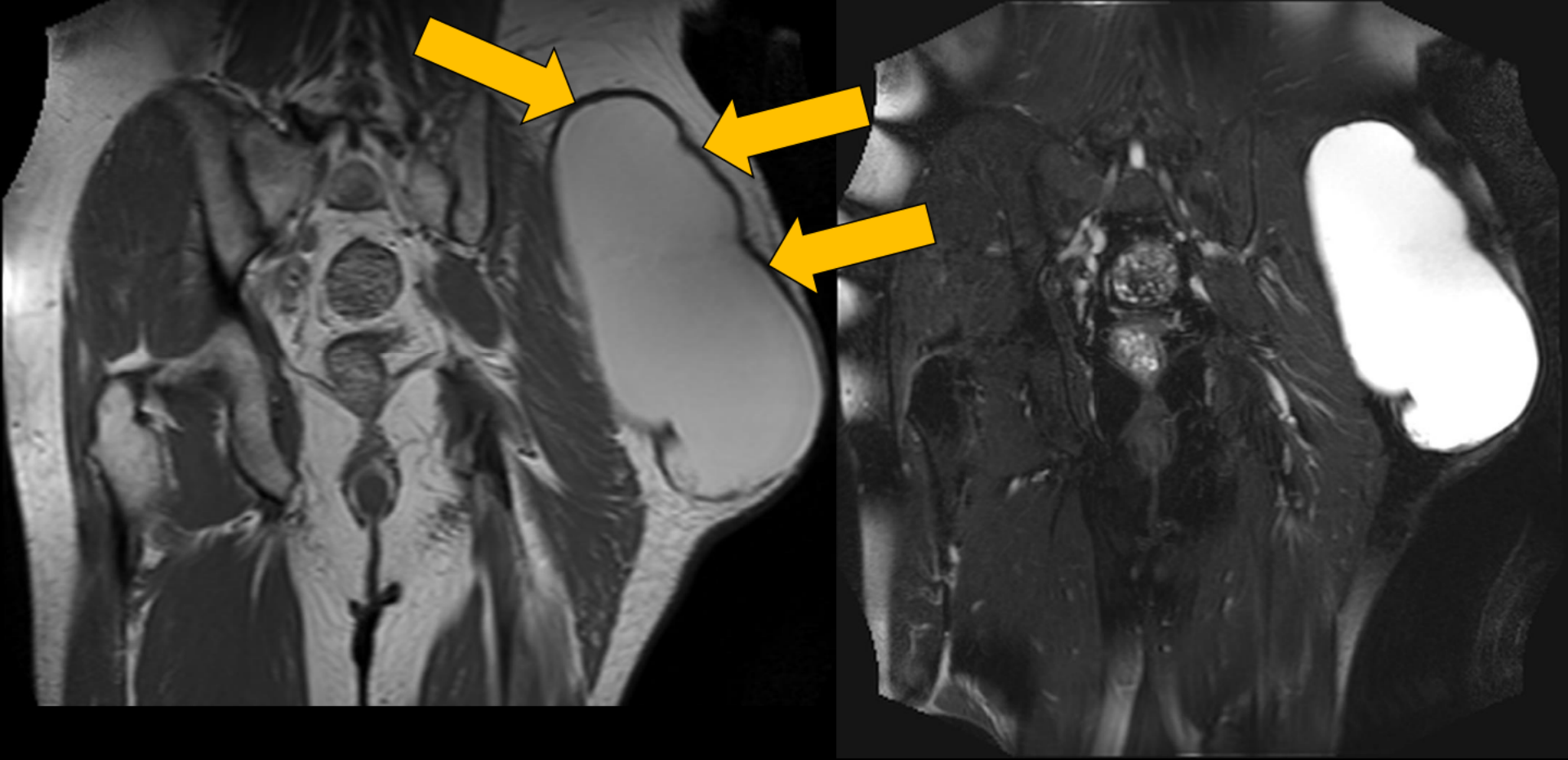
T1 FS subtraction image



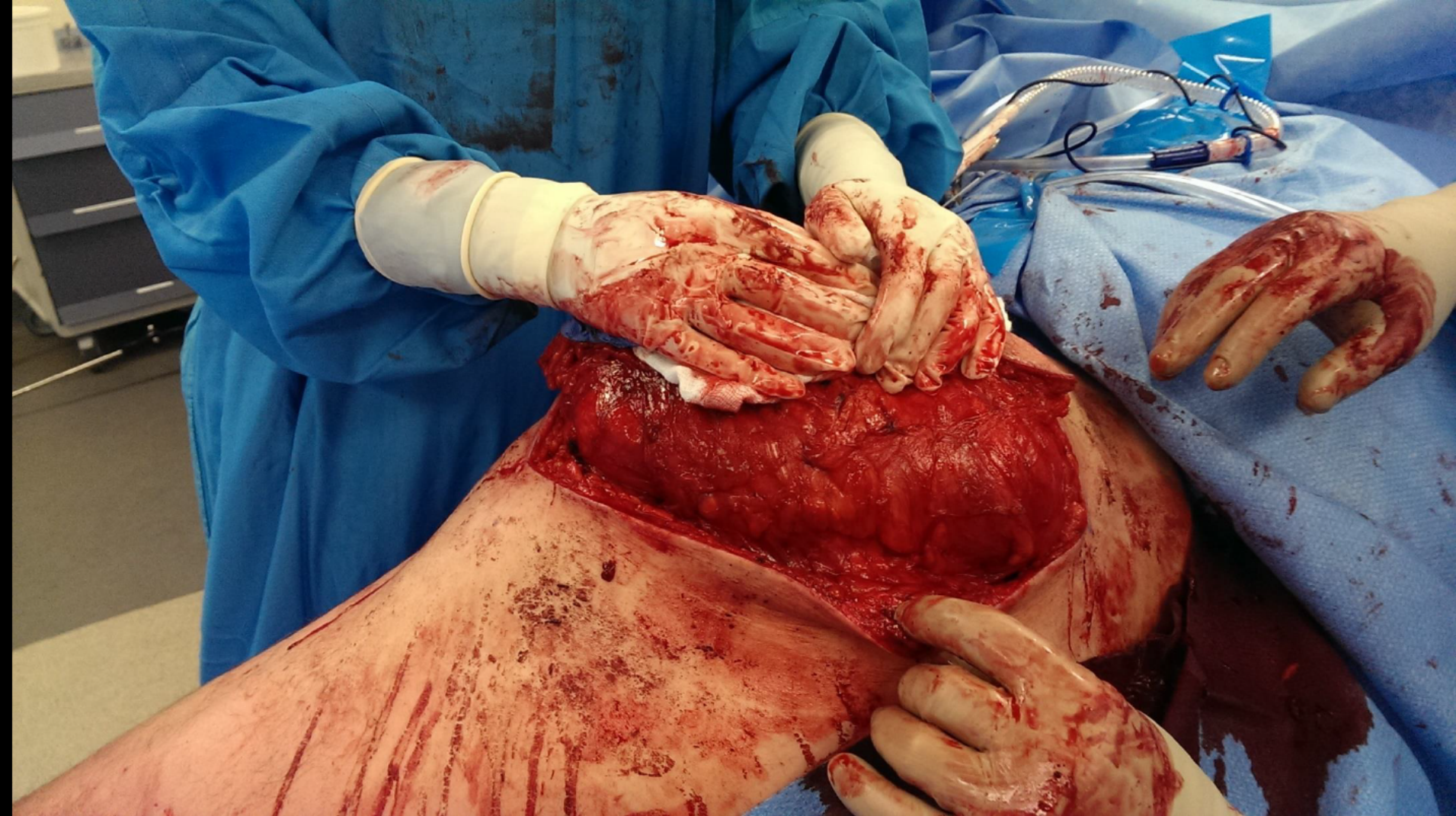

Coronal T1 and T2 FS



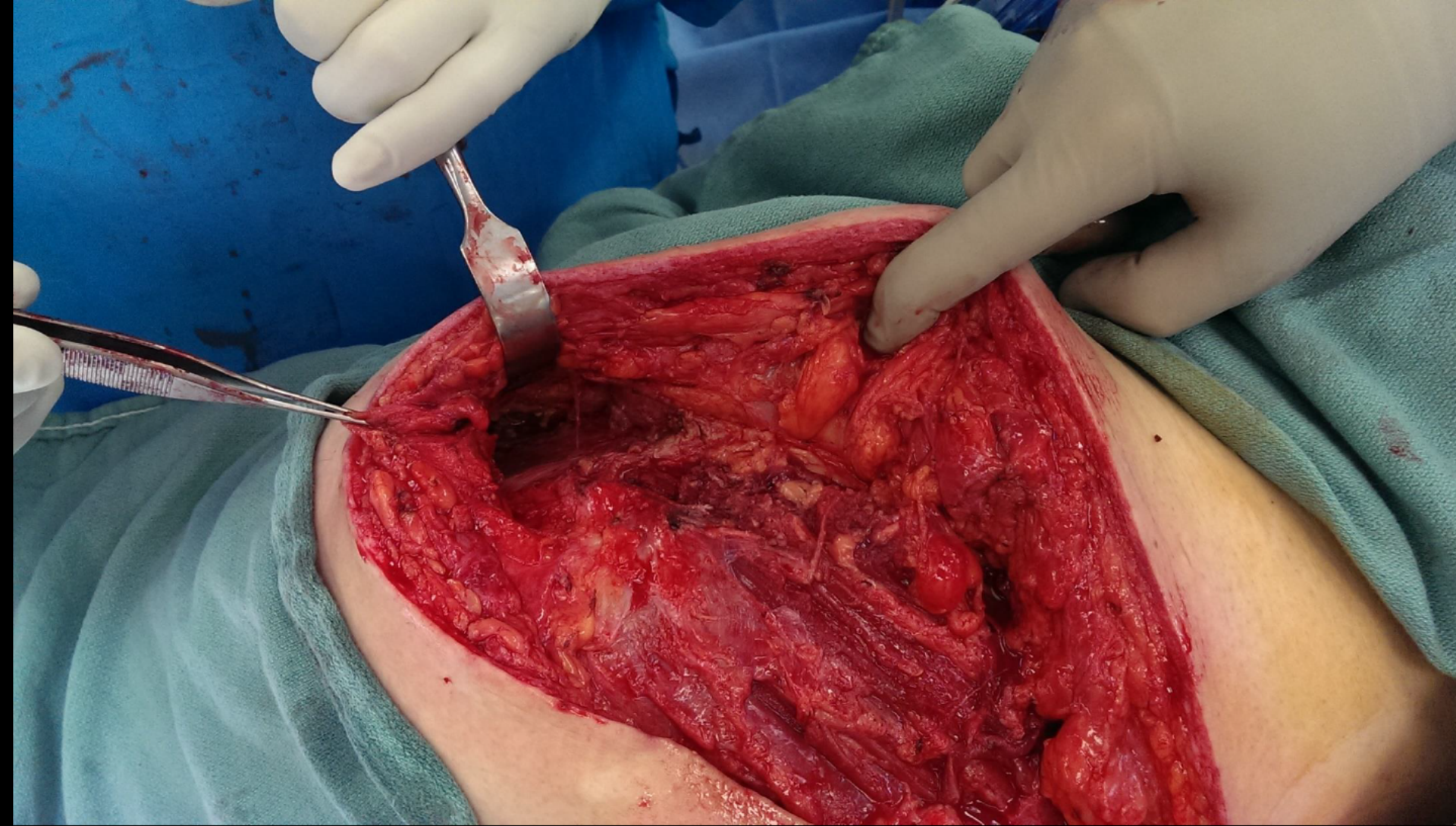


Coronal T1 and T2 FS



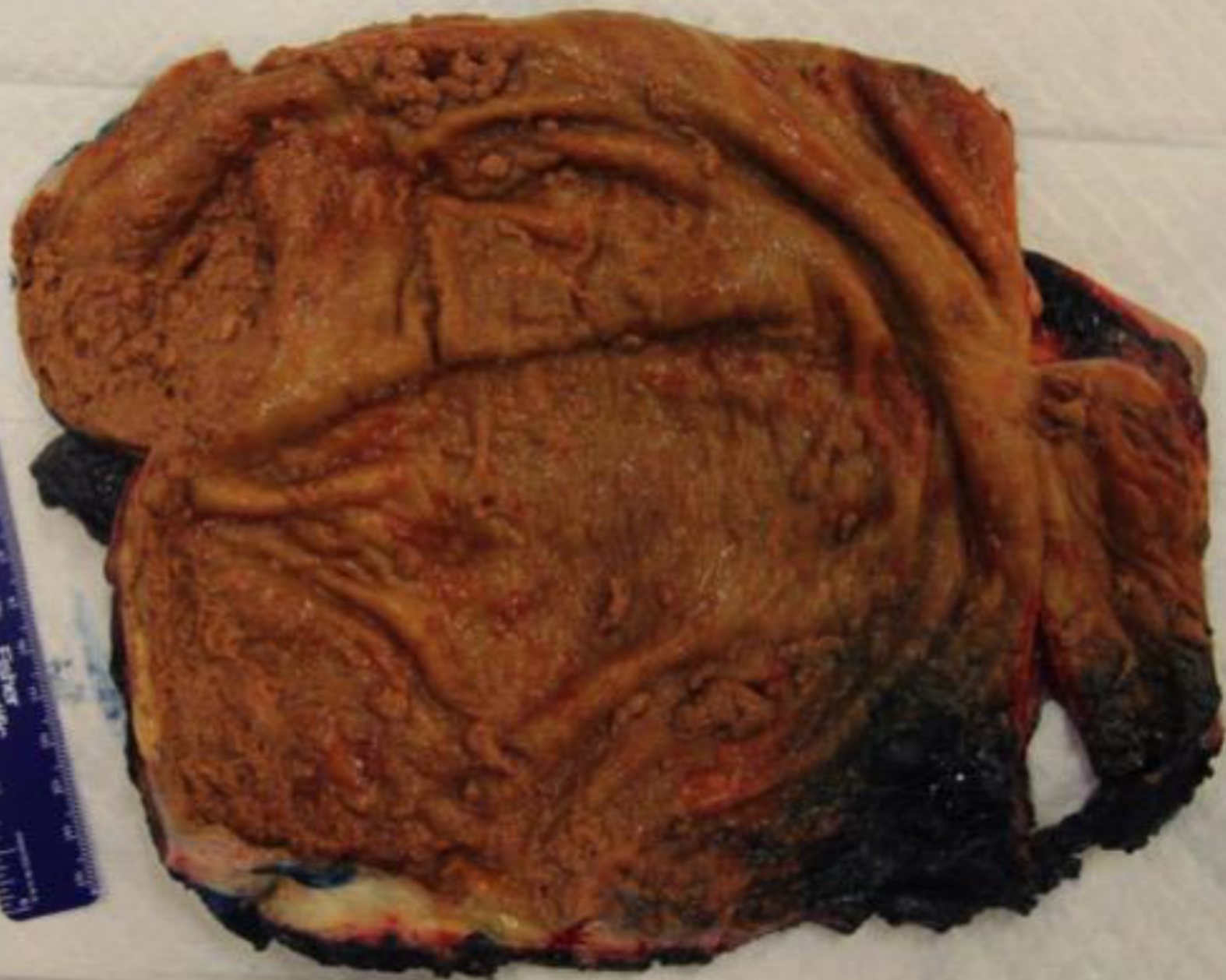Intraoperative picture

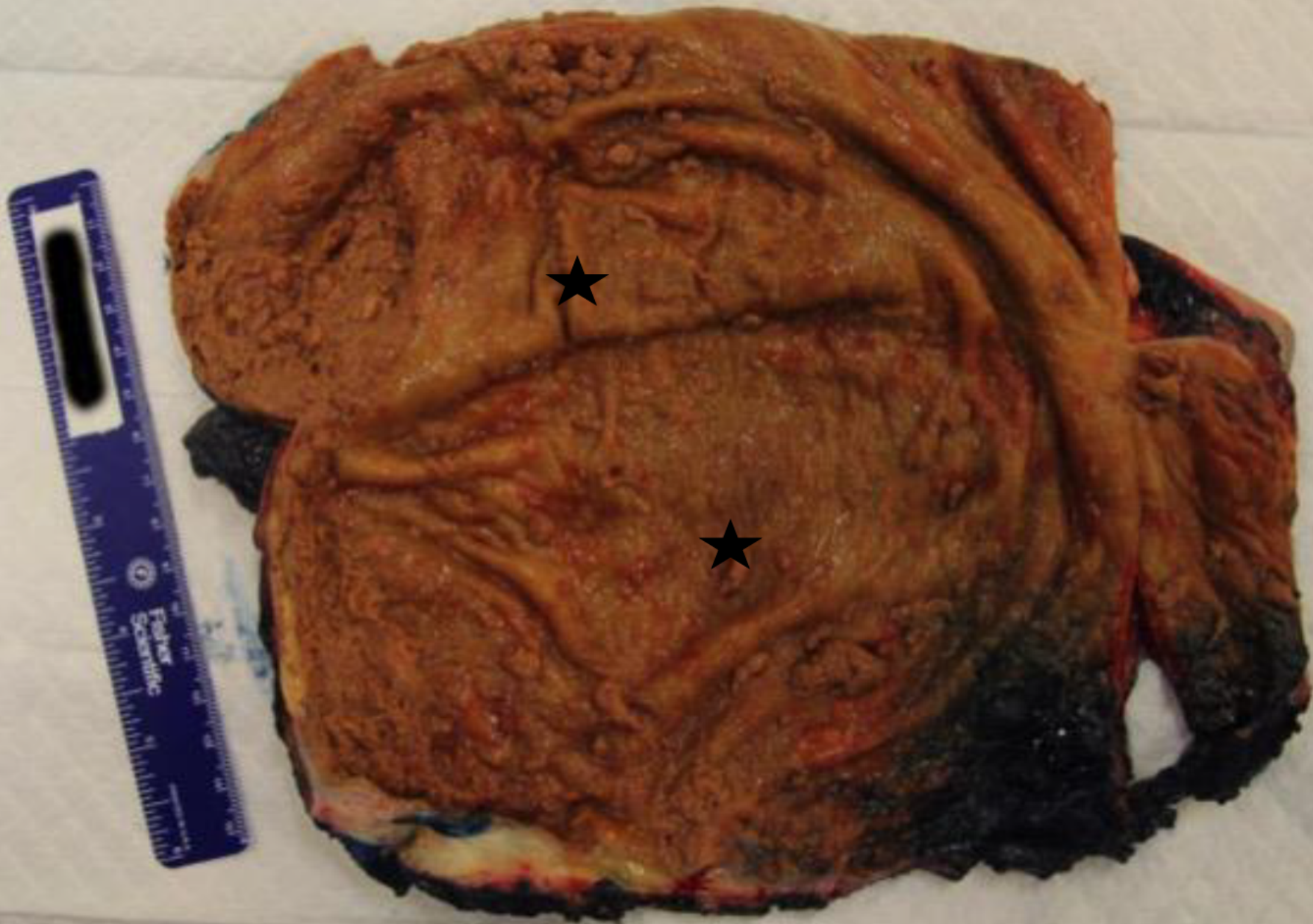



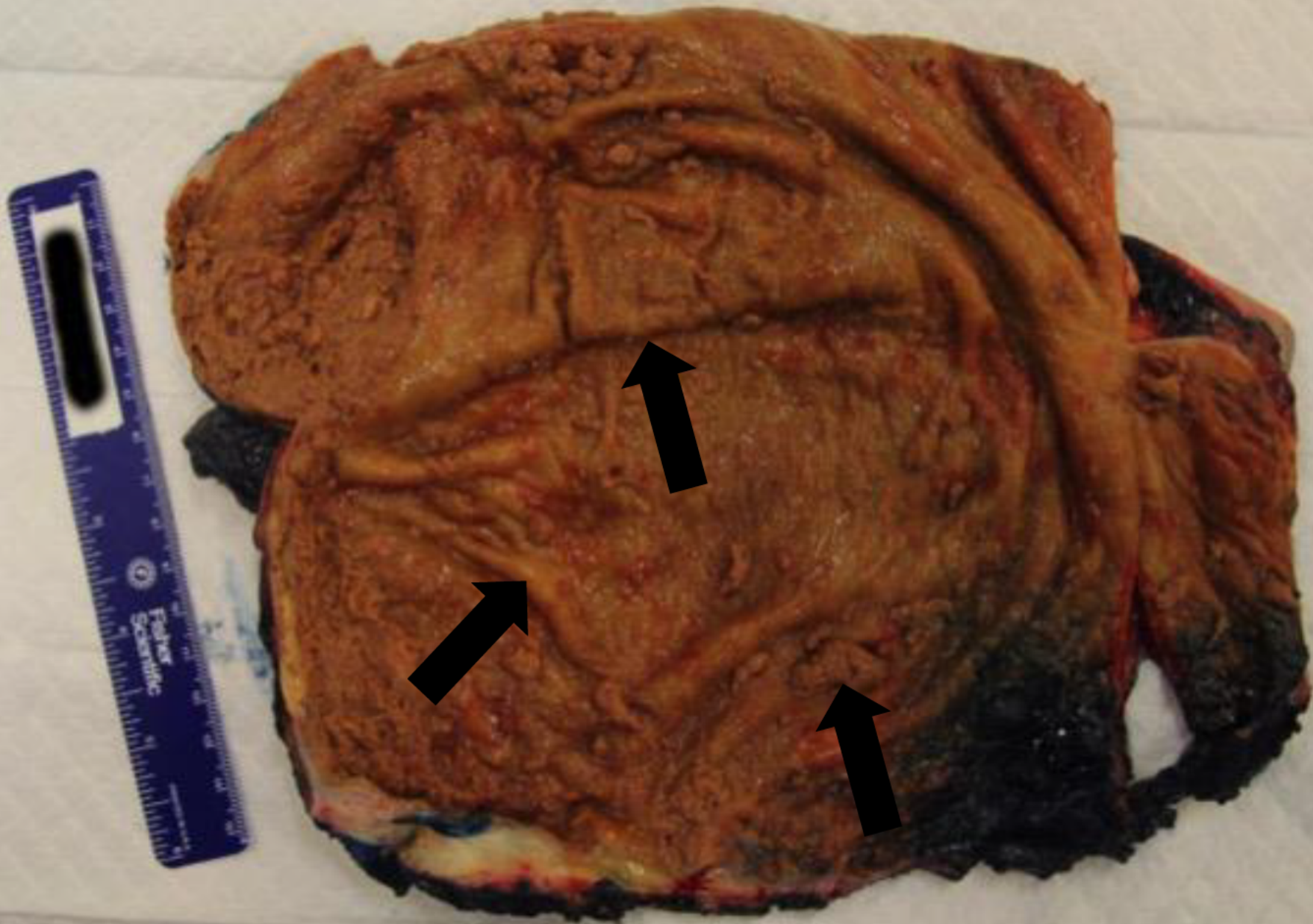
Intraoperative picture

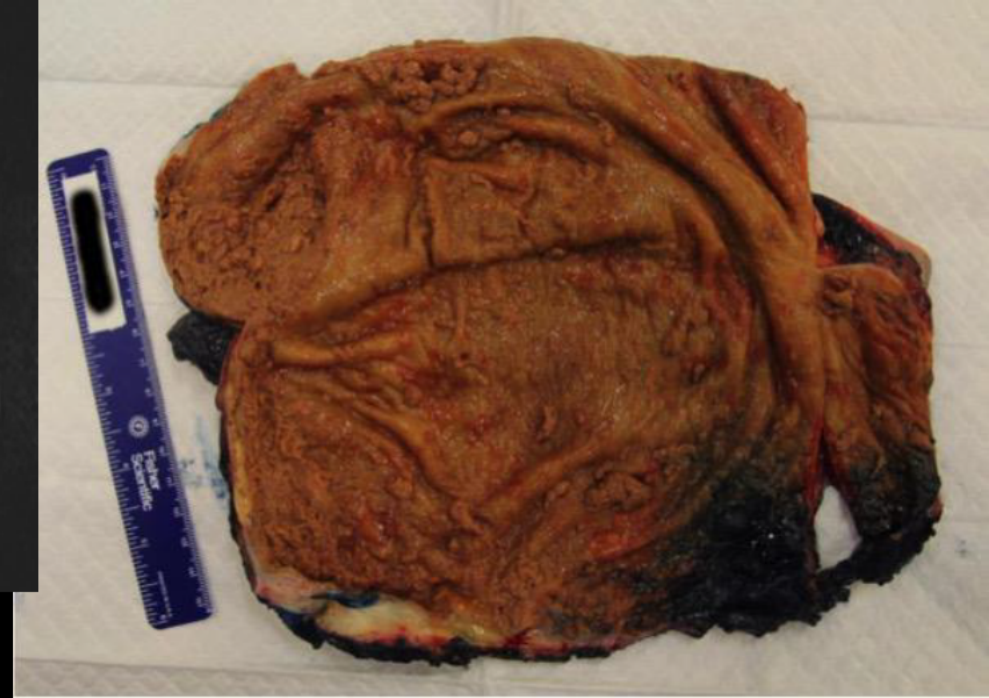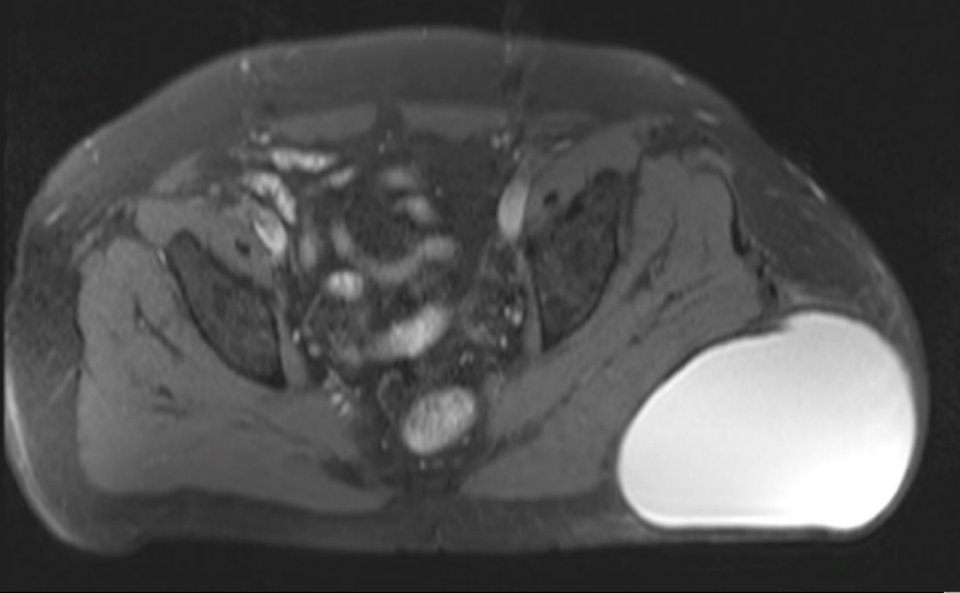






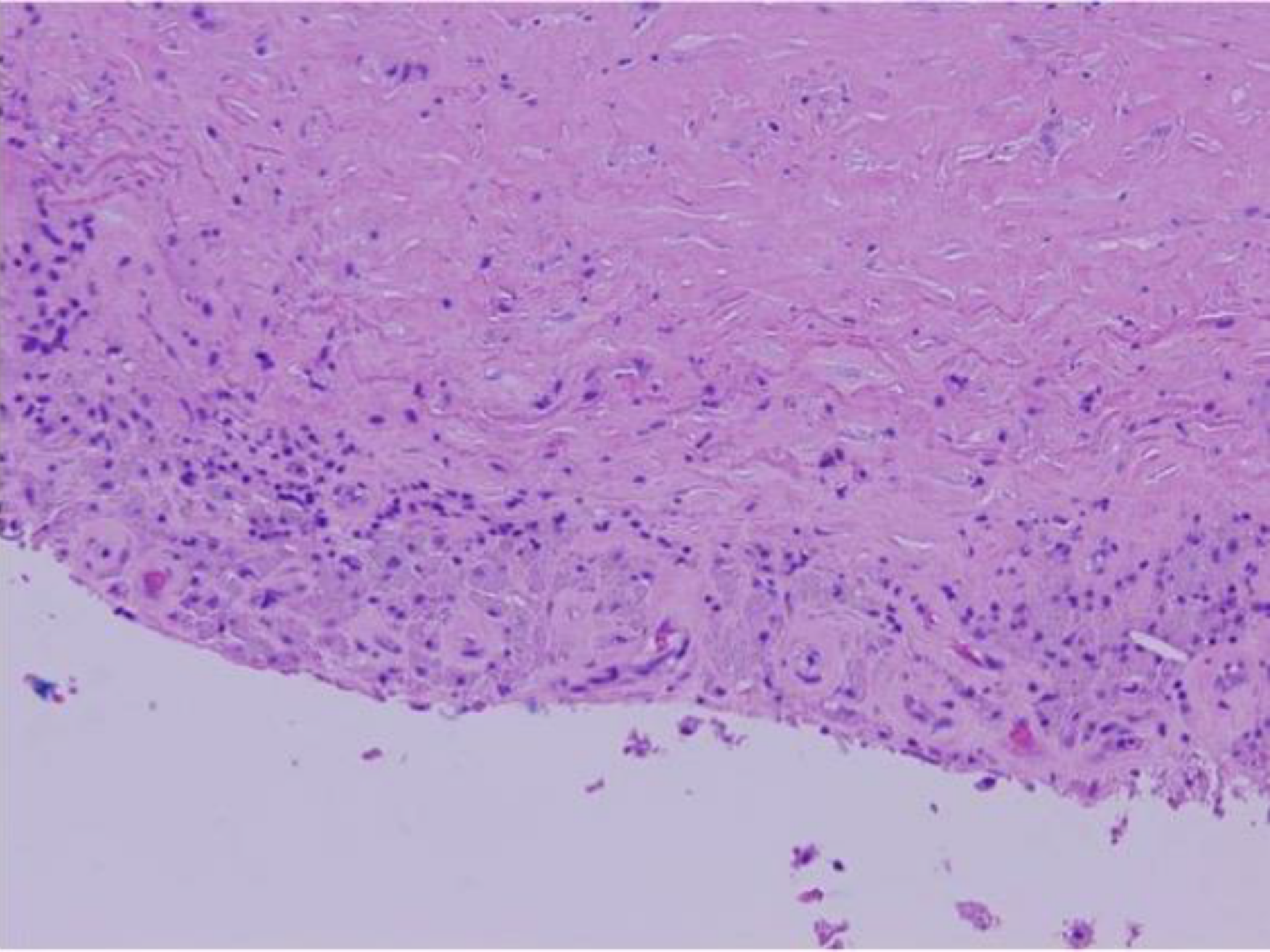




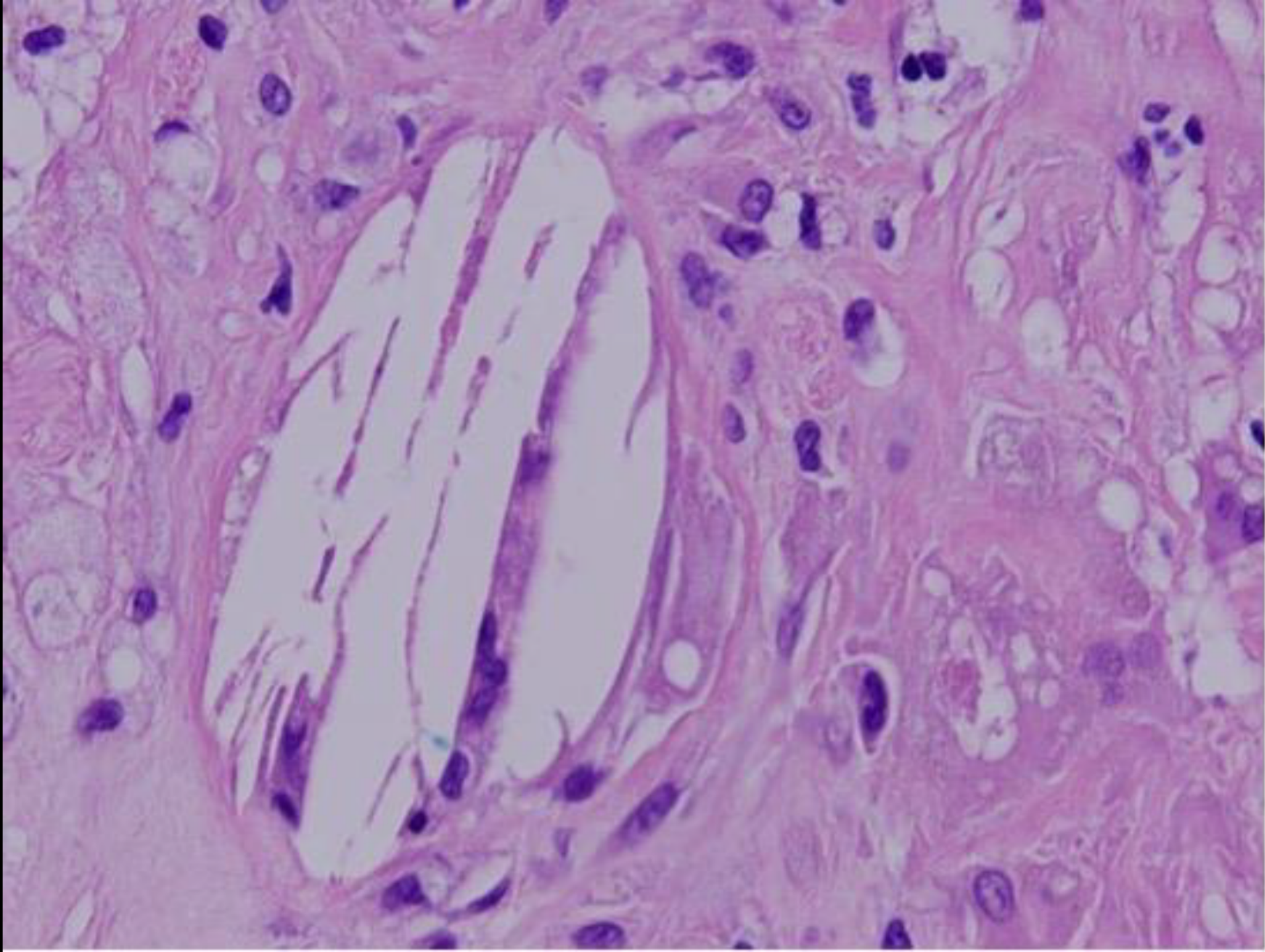


T1 FS and matched gross photograph





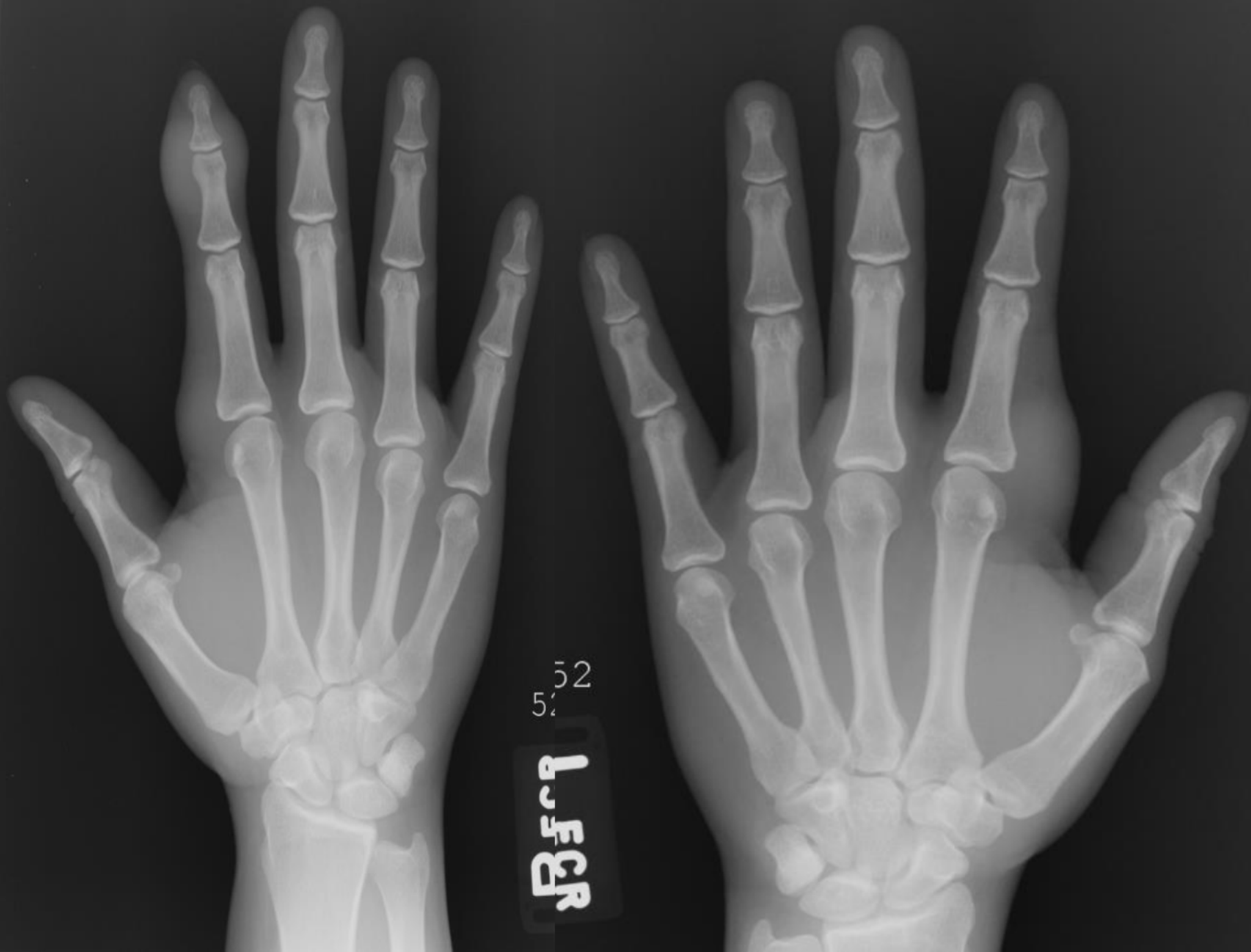



# Morel-Lavallee lesion

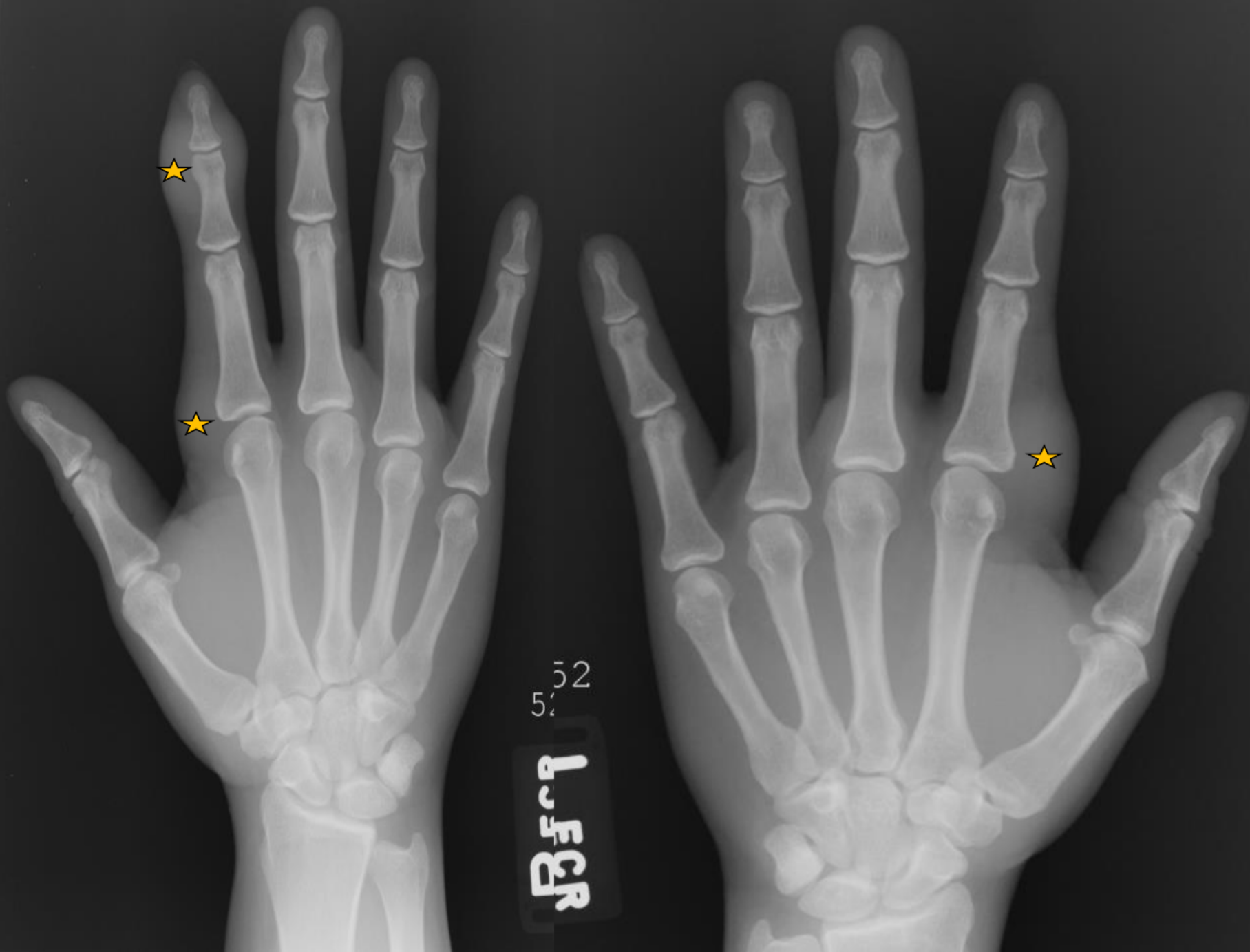
Dr. Kristopher McLean  
McMaster University  
Hamilton, Ontario  
Canada

34-year-old female with worsening  
bilateral hand numbness and tingling,  
and bilateral throbbing ankle and  
heel pain over several years



52  
52

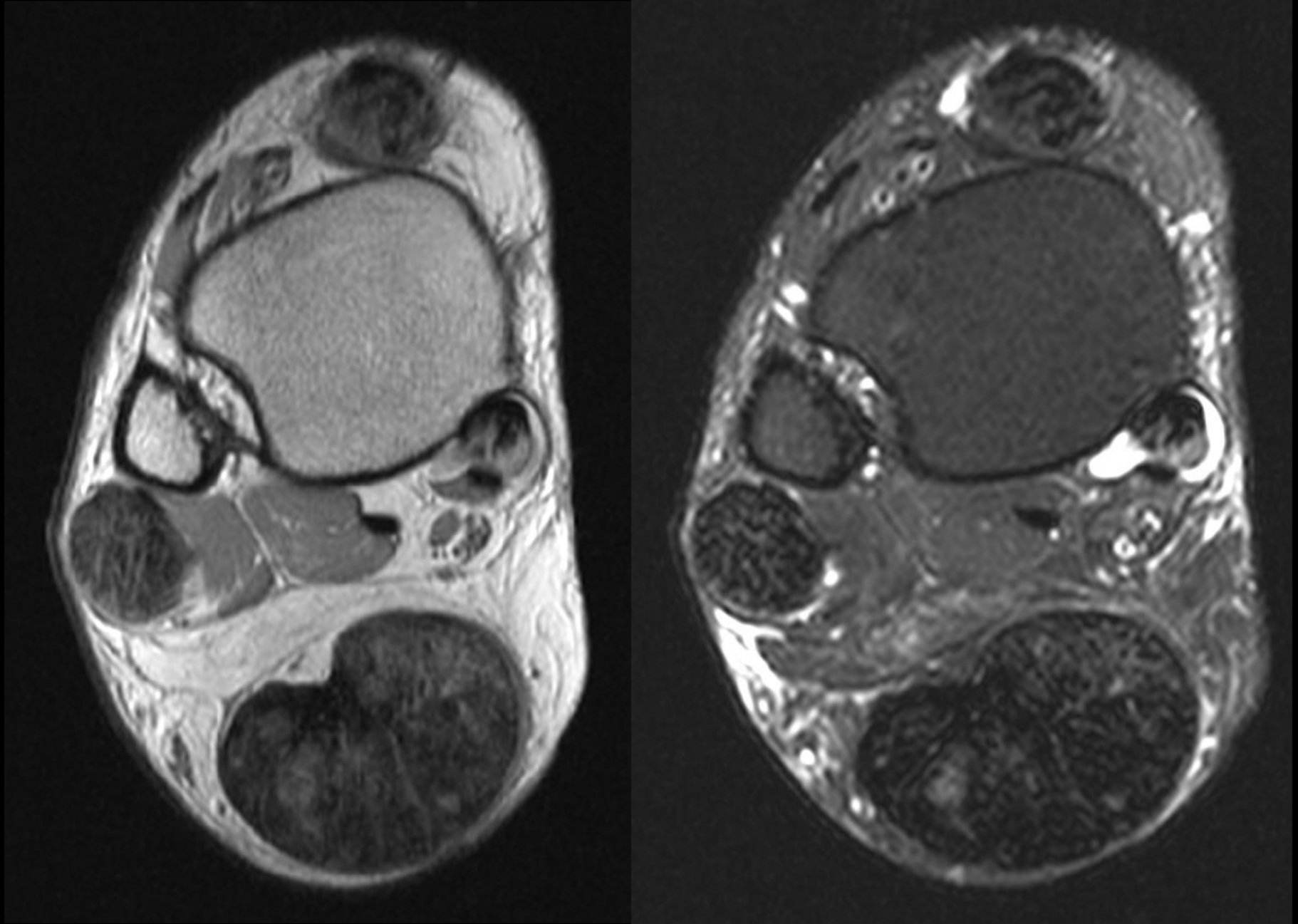
L-5CR



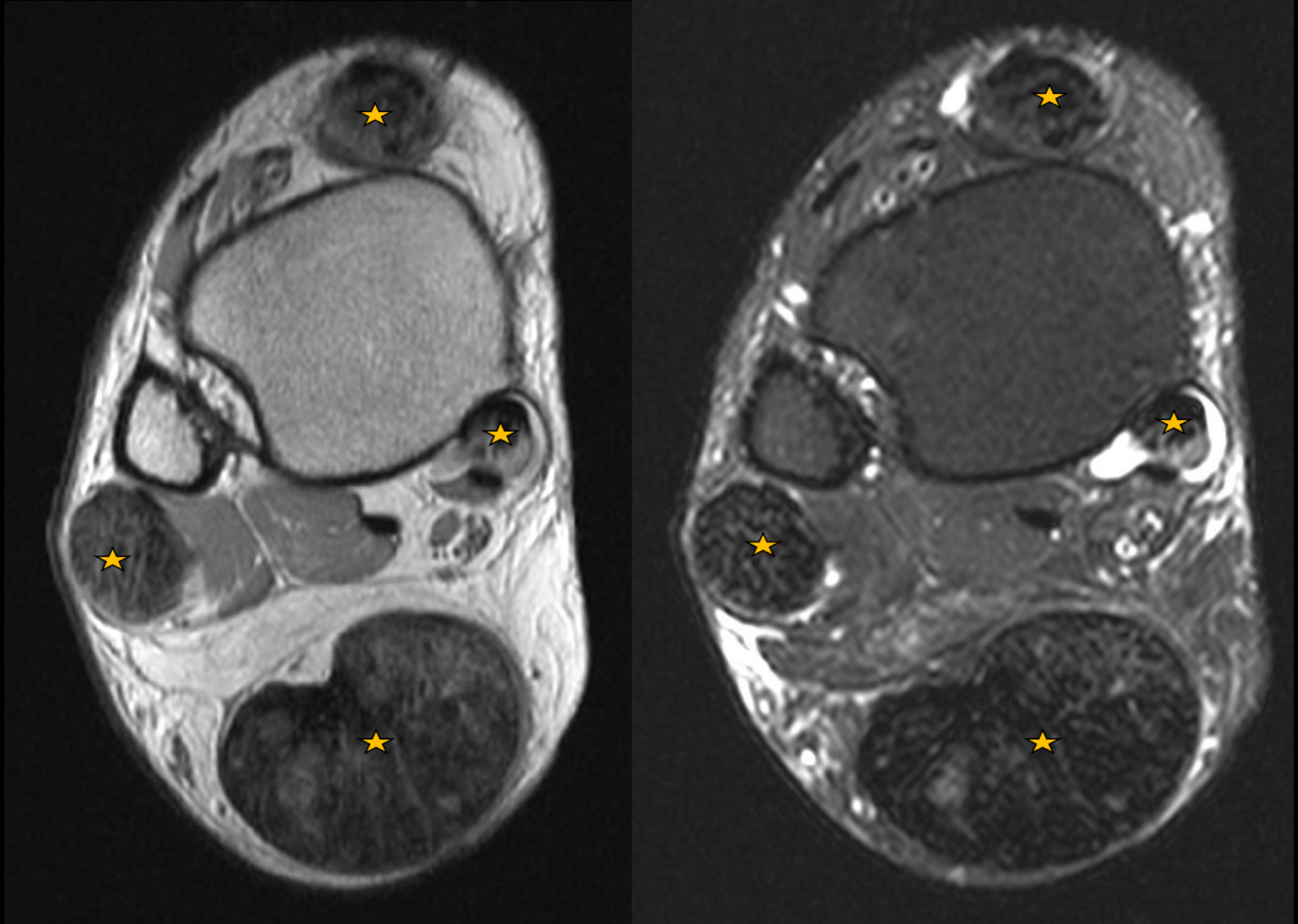
52  
52

1.5 CR

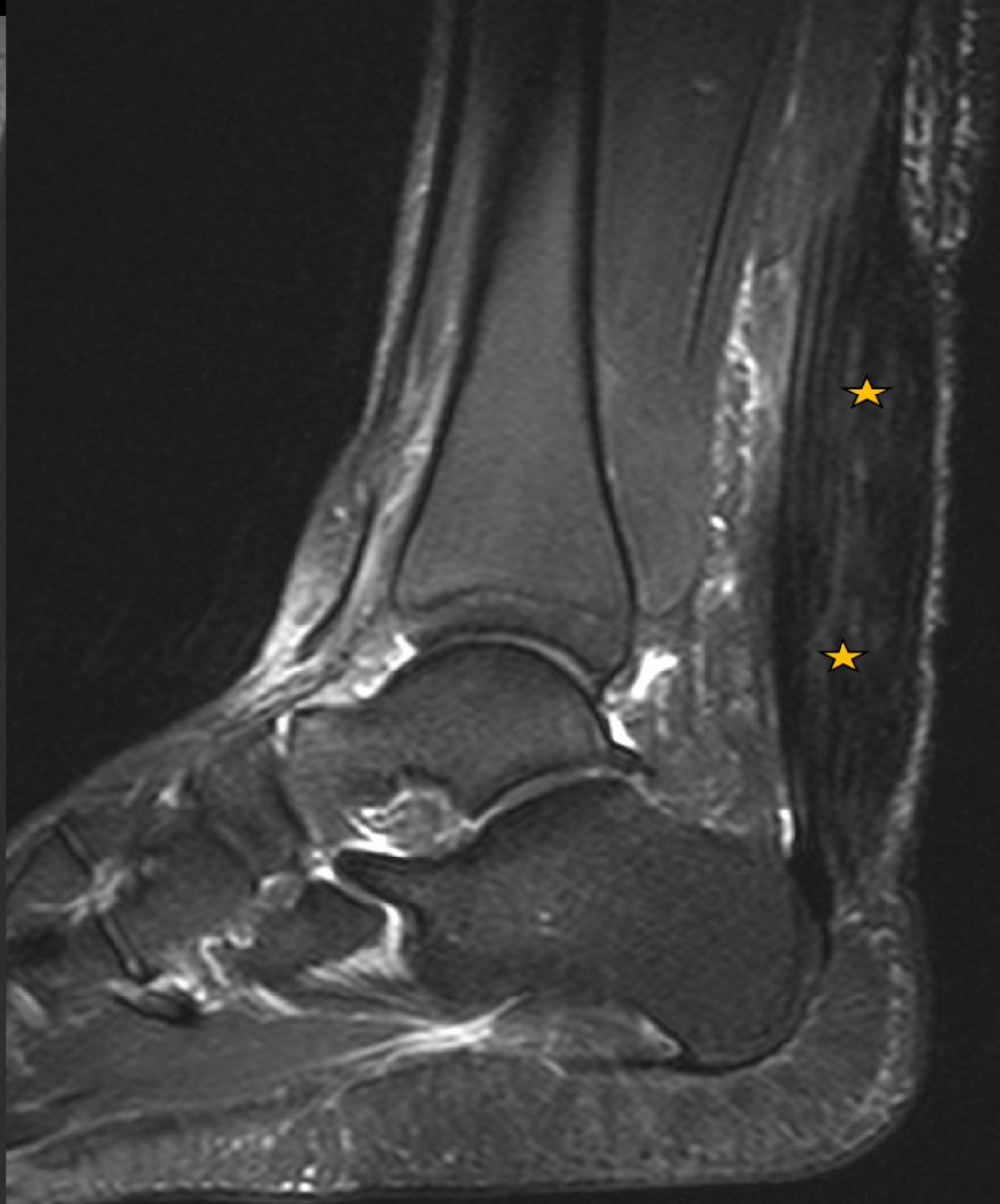
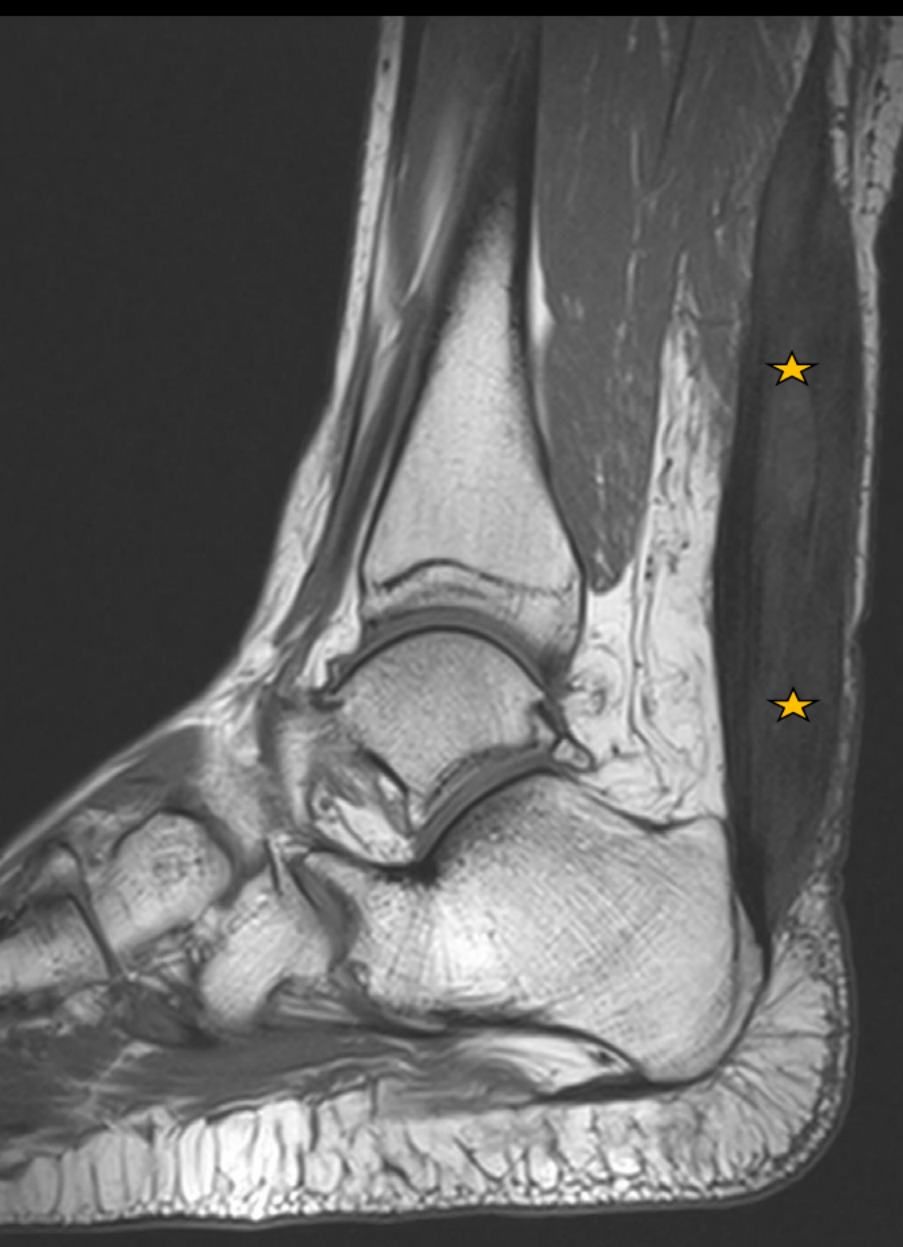




Ankle axial PD non FS and Axial T2 FS

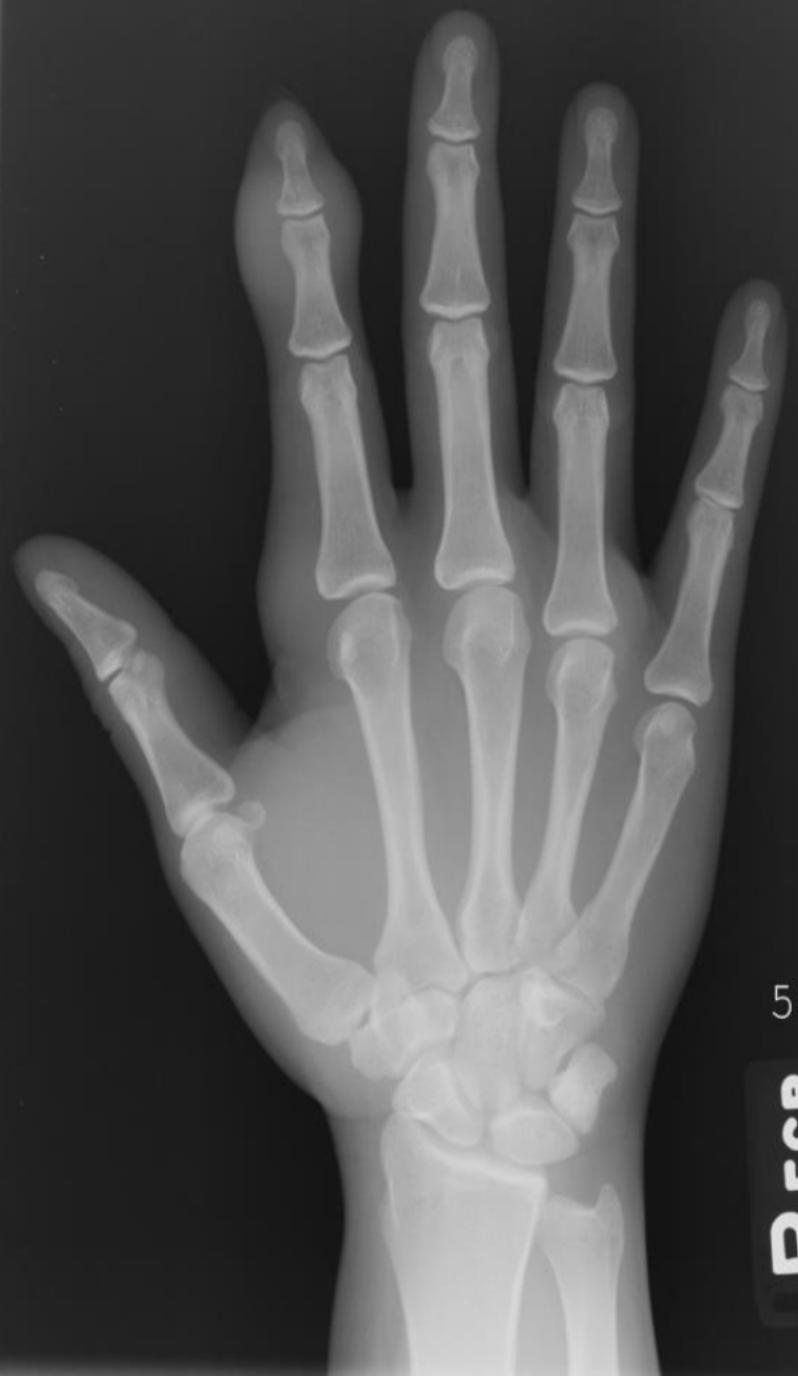

Ankle axial PD non FS and Axial T2 FS



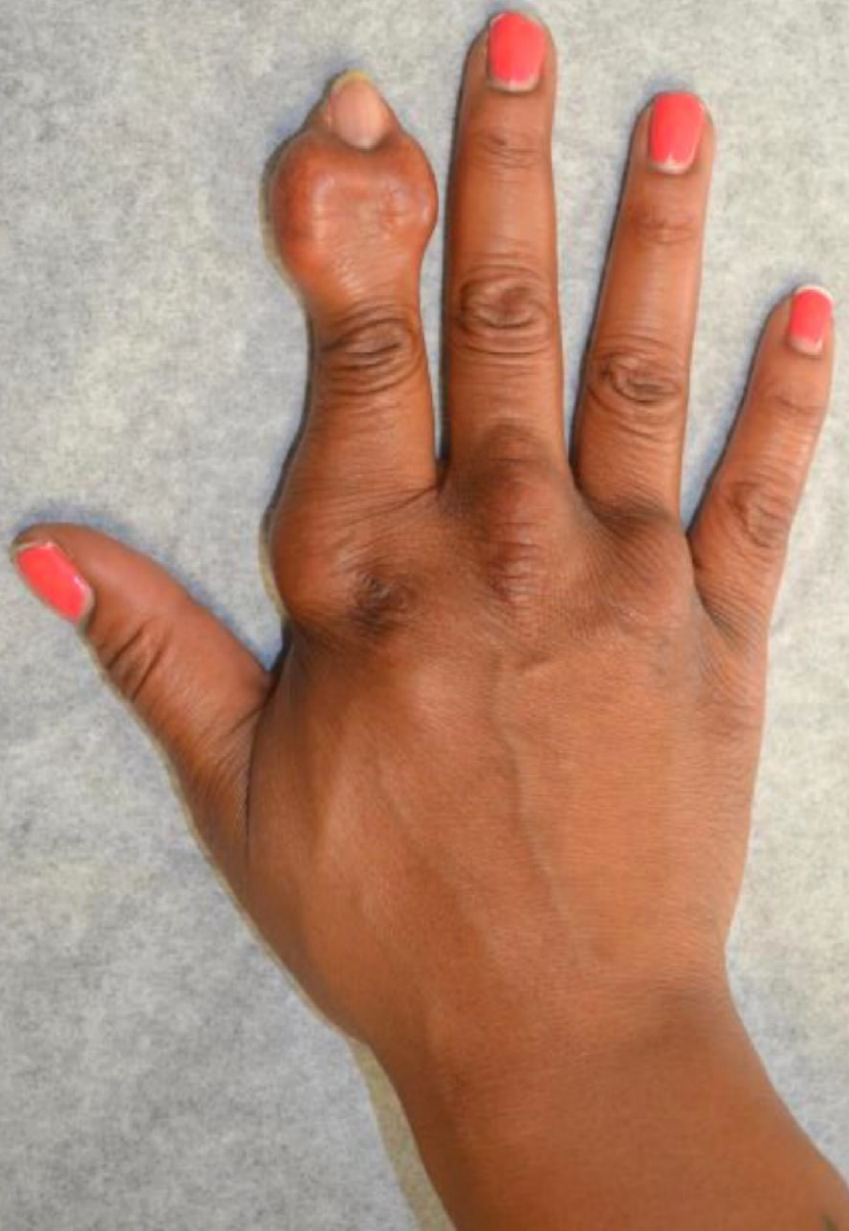Sagittal T1 non FS and T2 FS





52

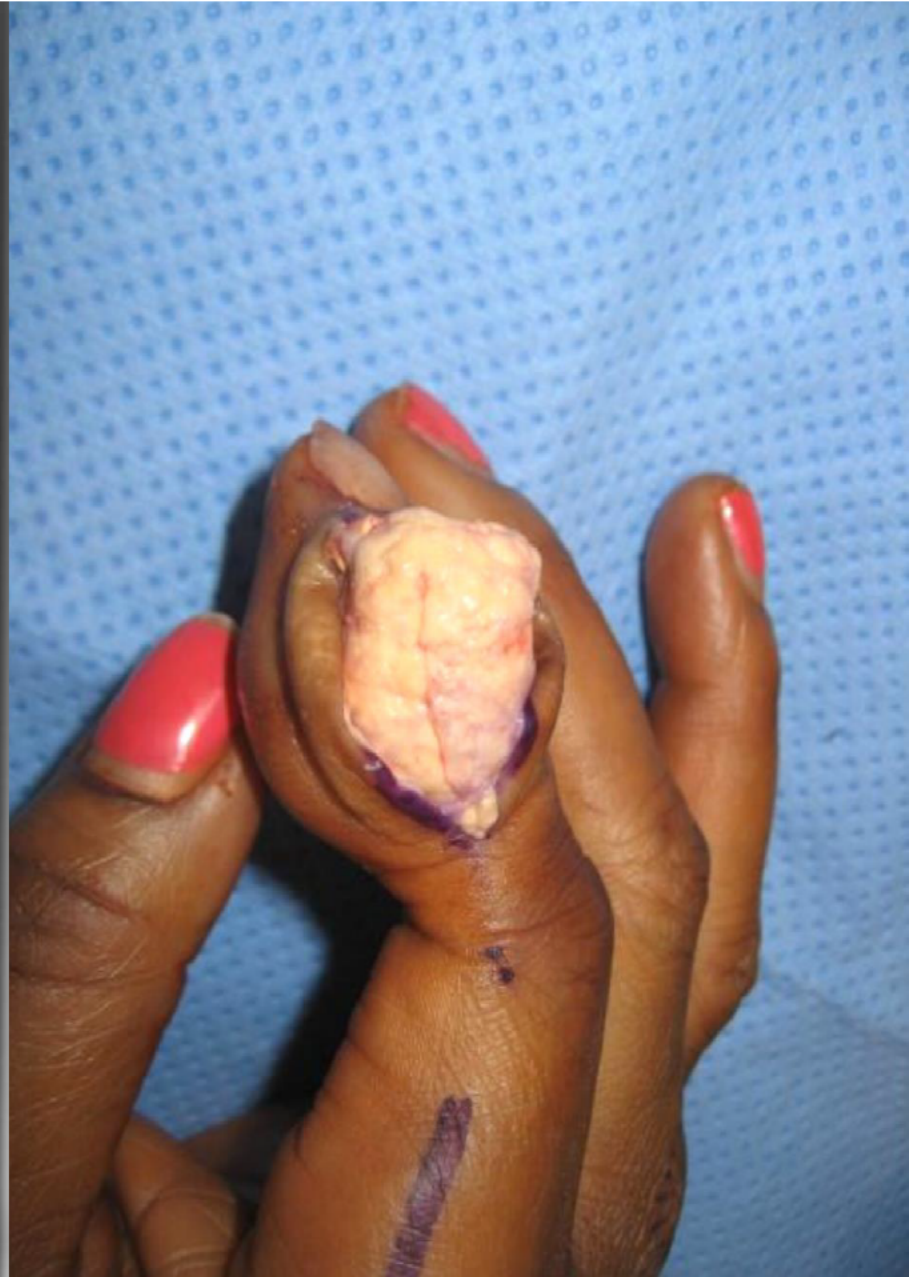**RECR**



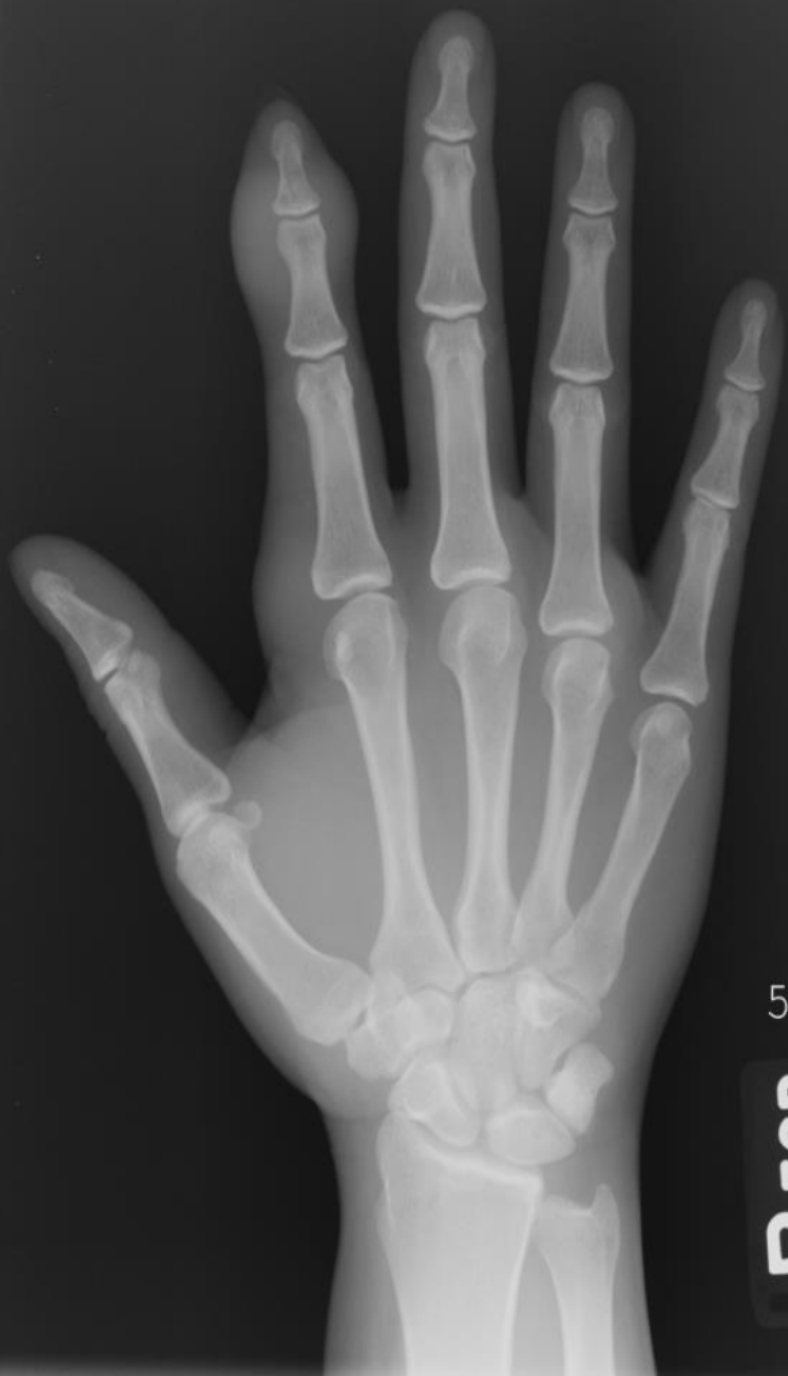

52

RECR

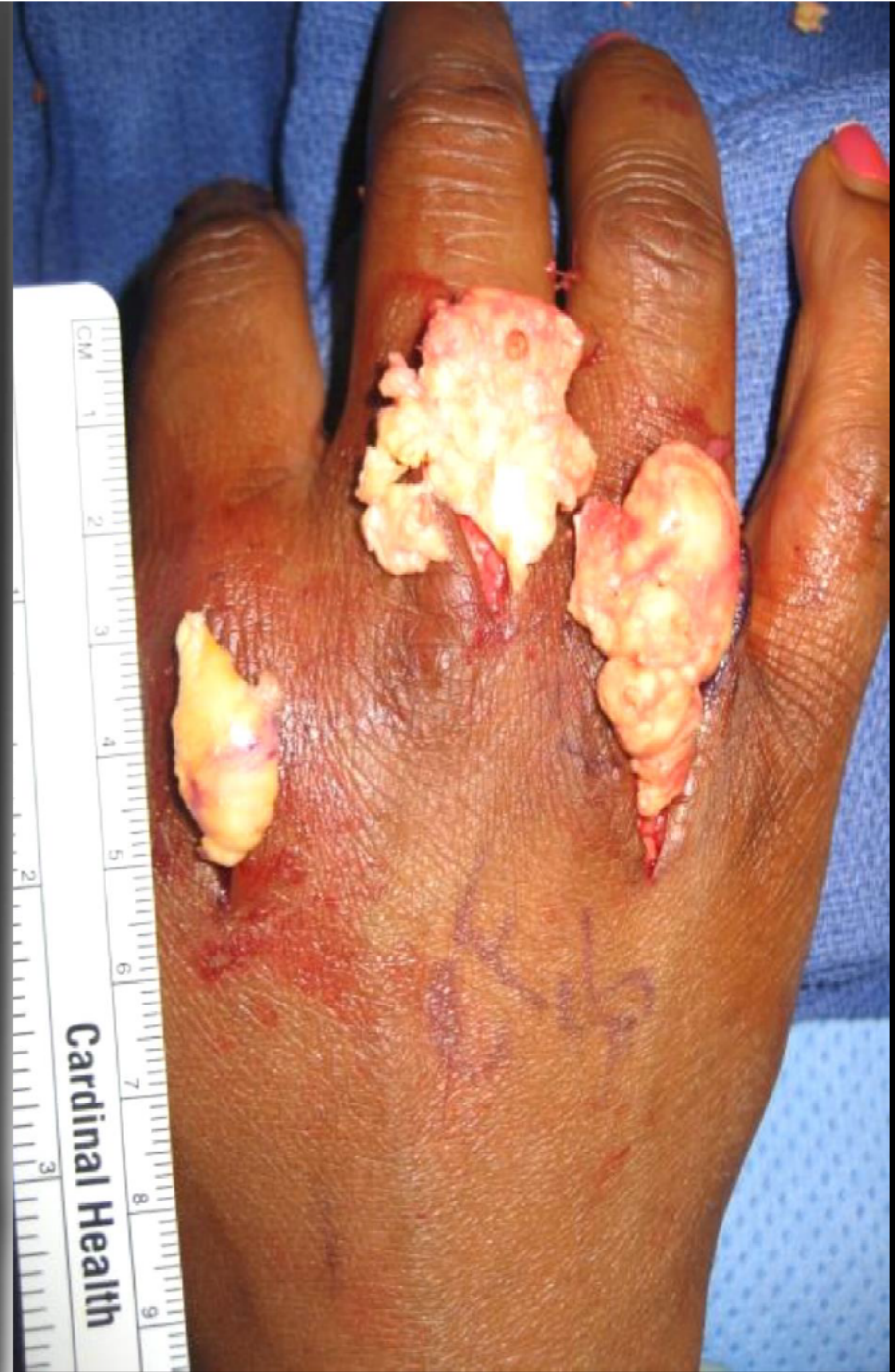


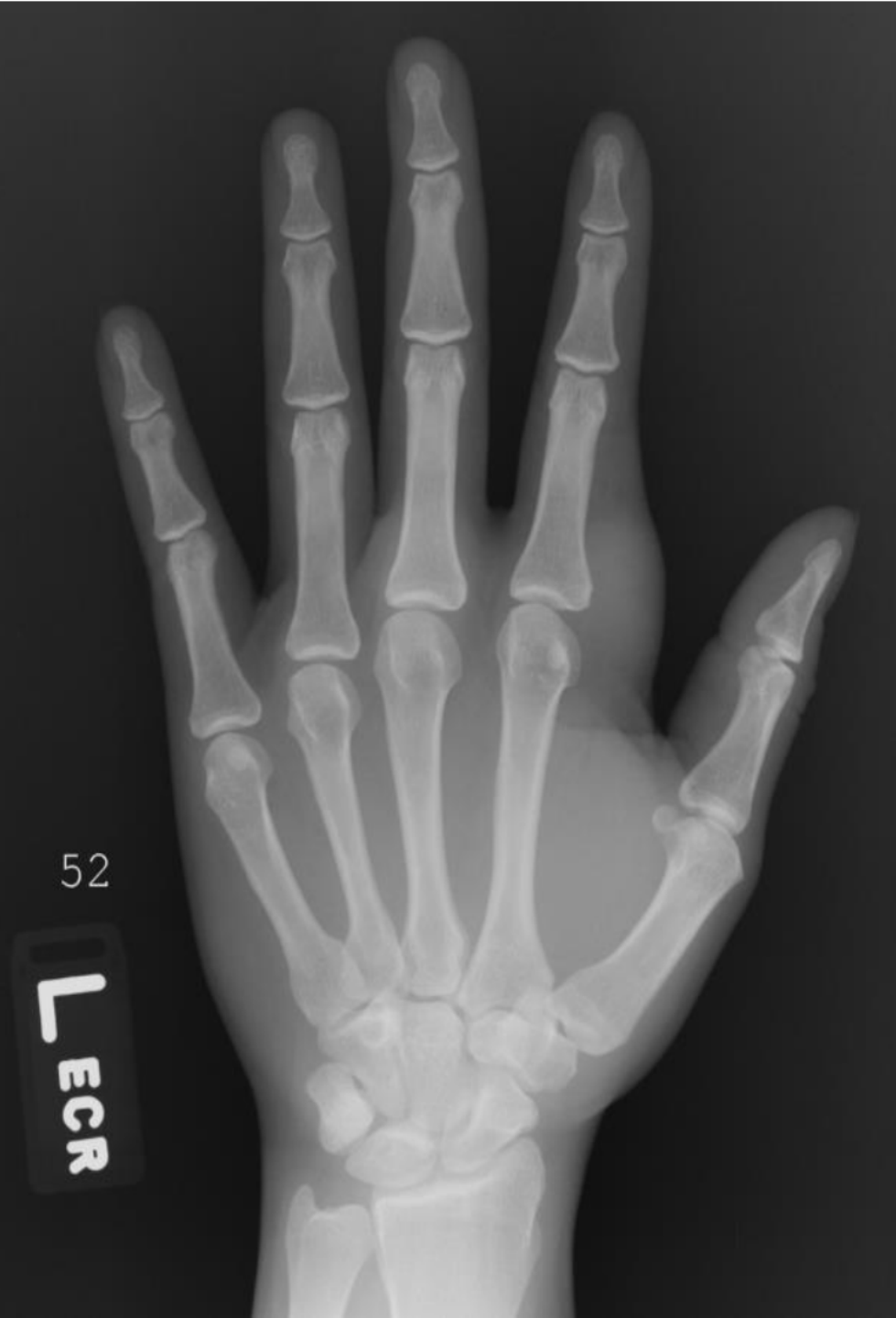


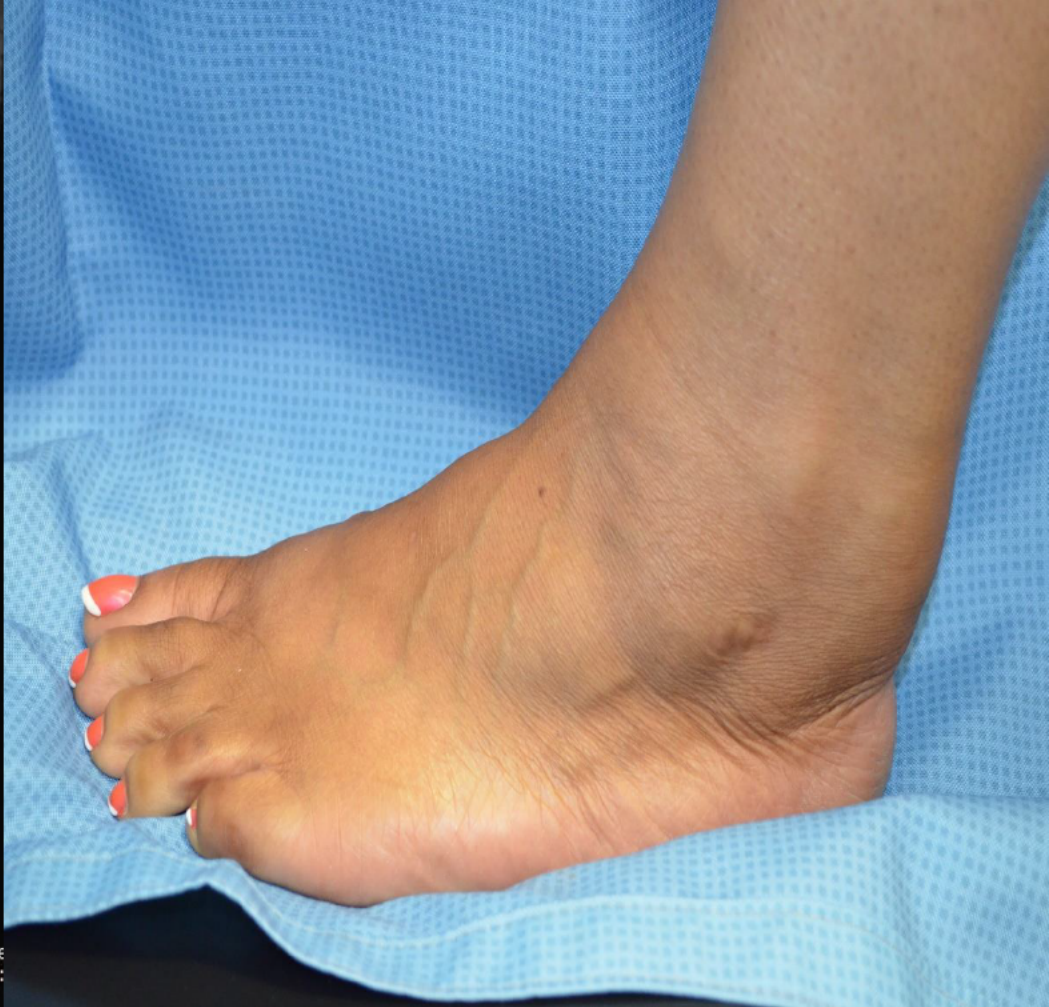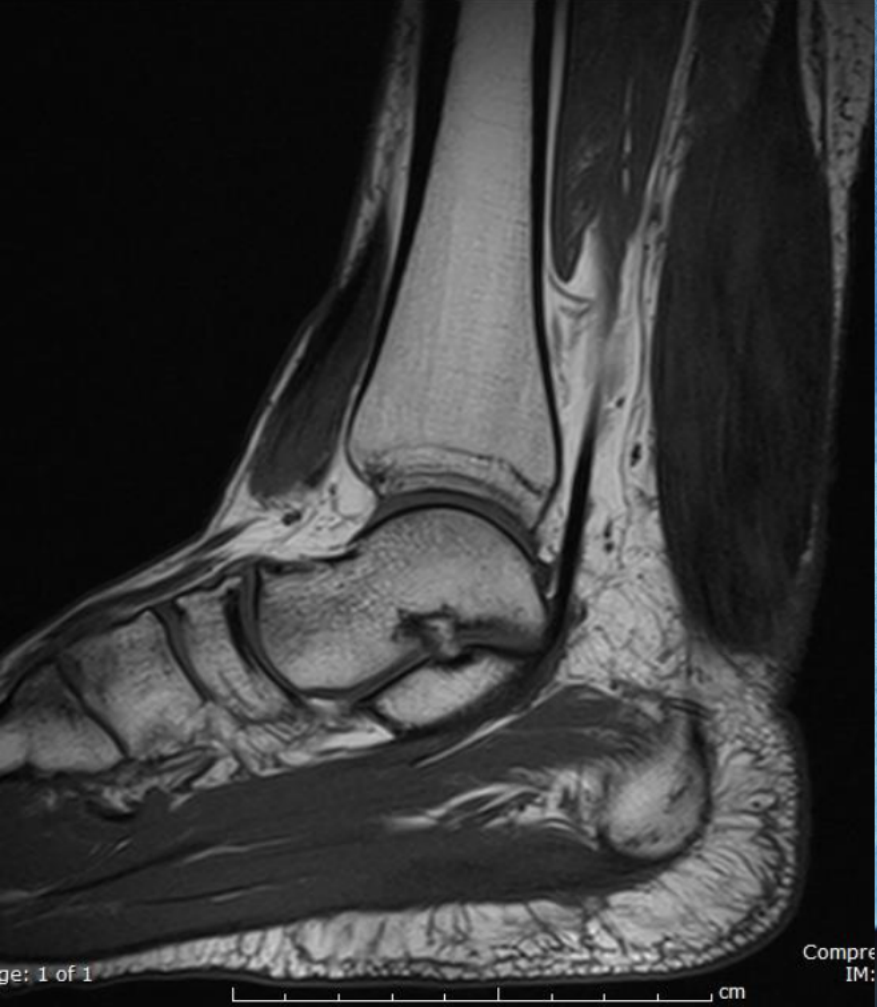52

RECR

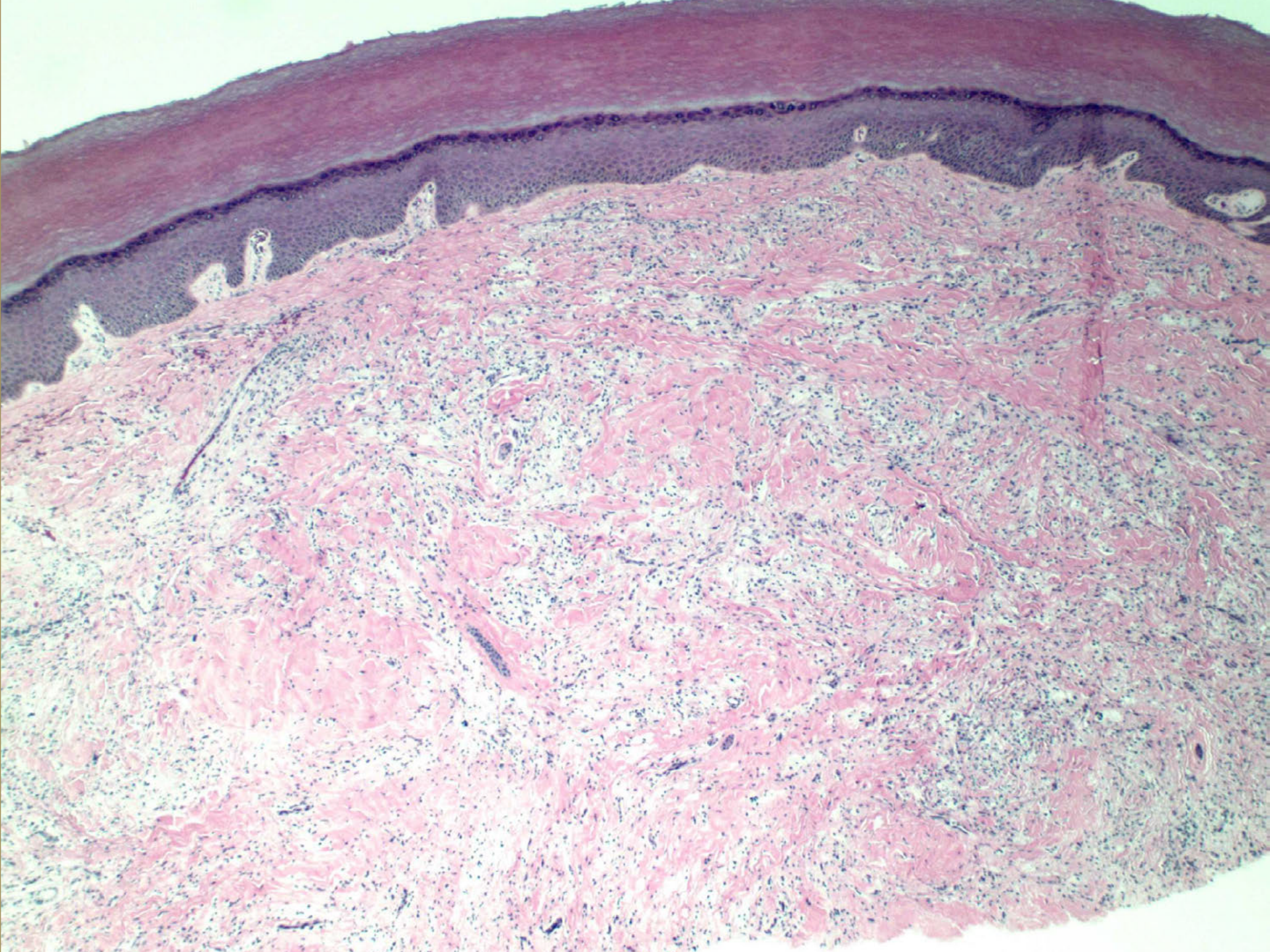




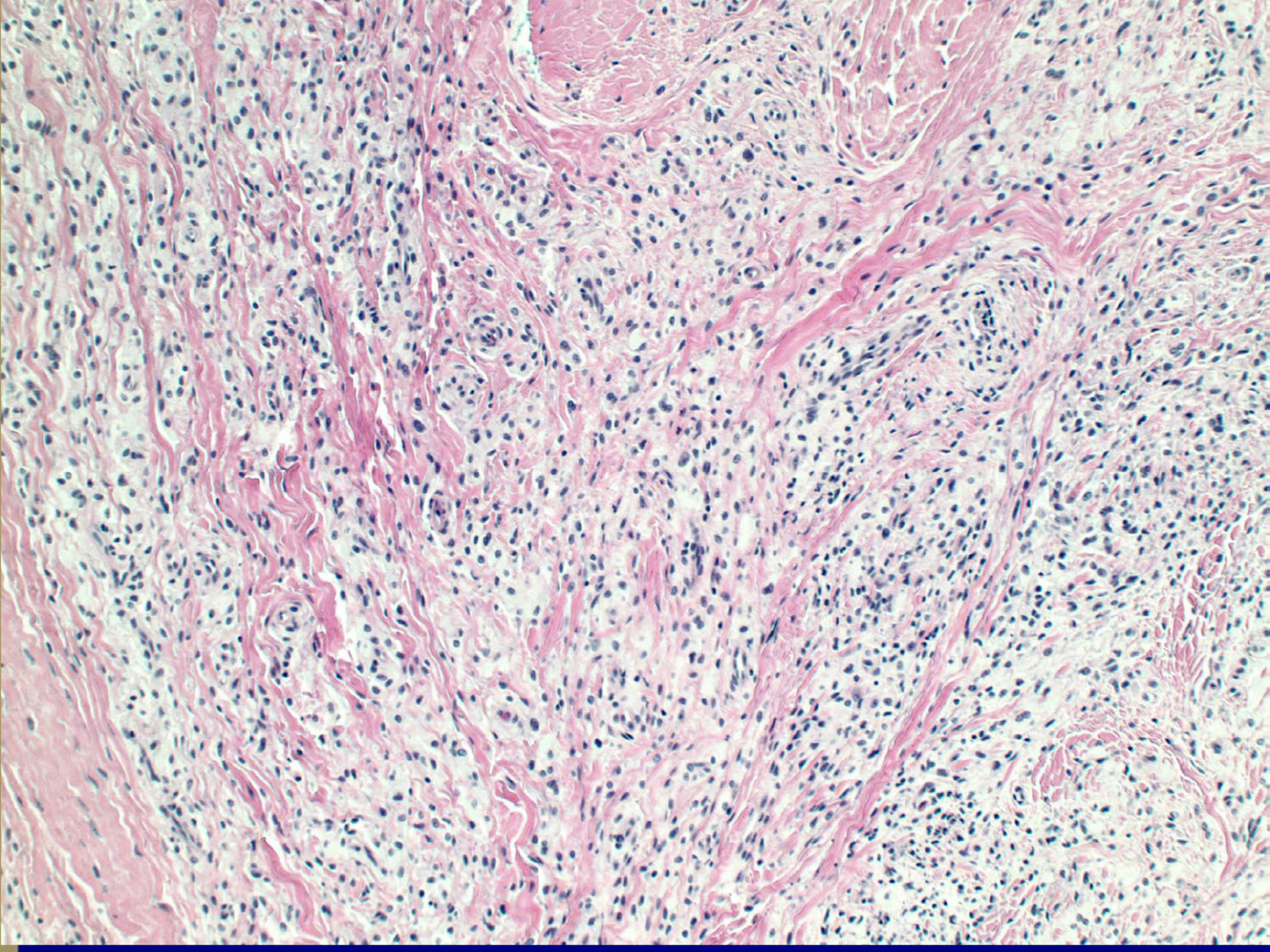




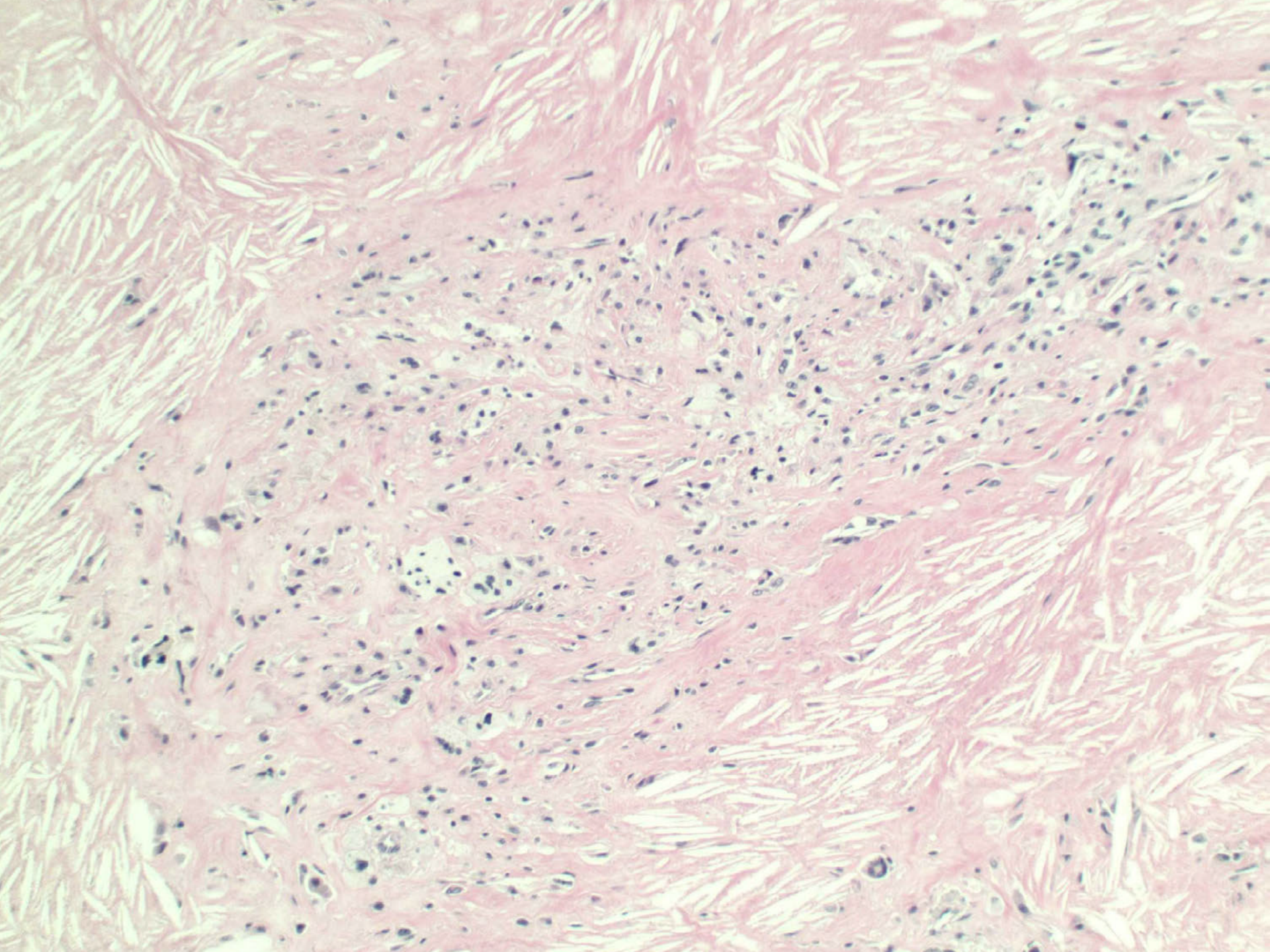




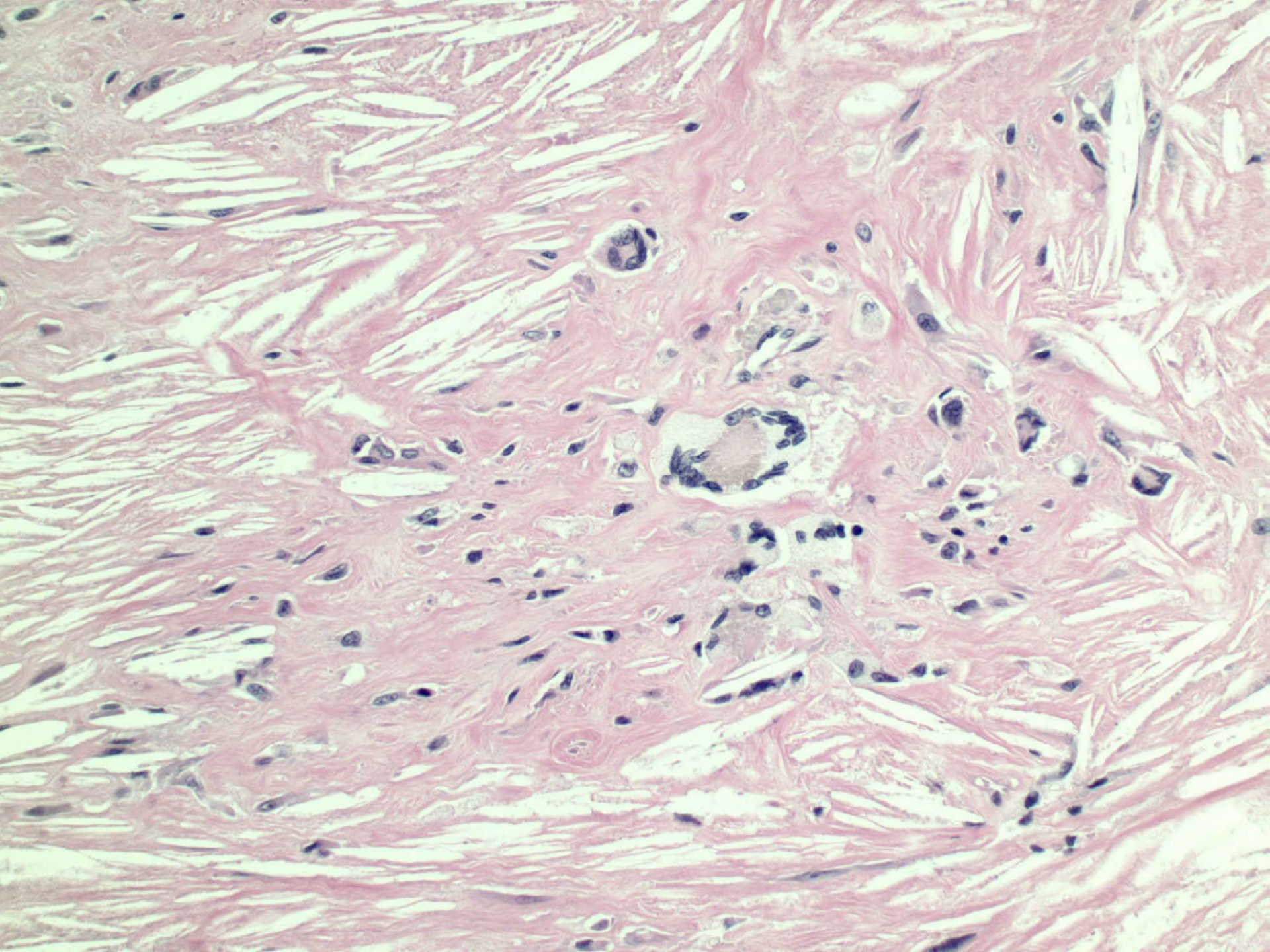










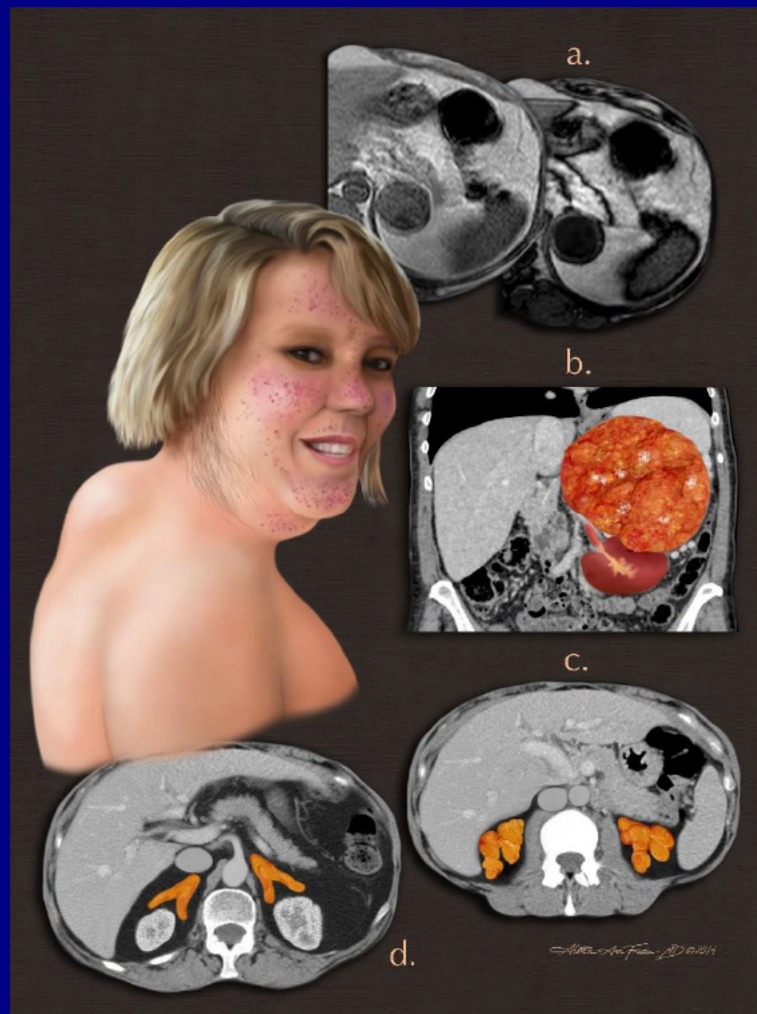

# Xanthomatosis

Dr. Devrim Ersahin  
Yale New Haven Hospital  
New Haven, Connecticut

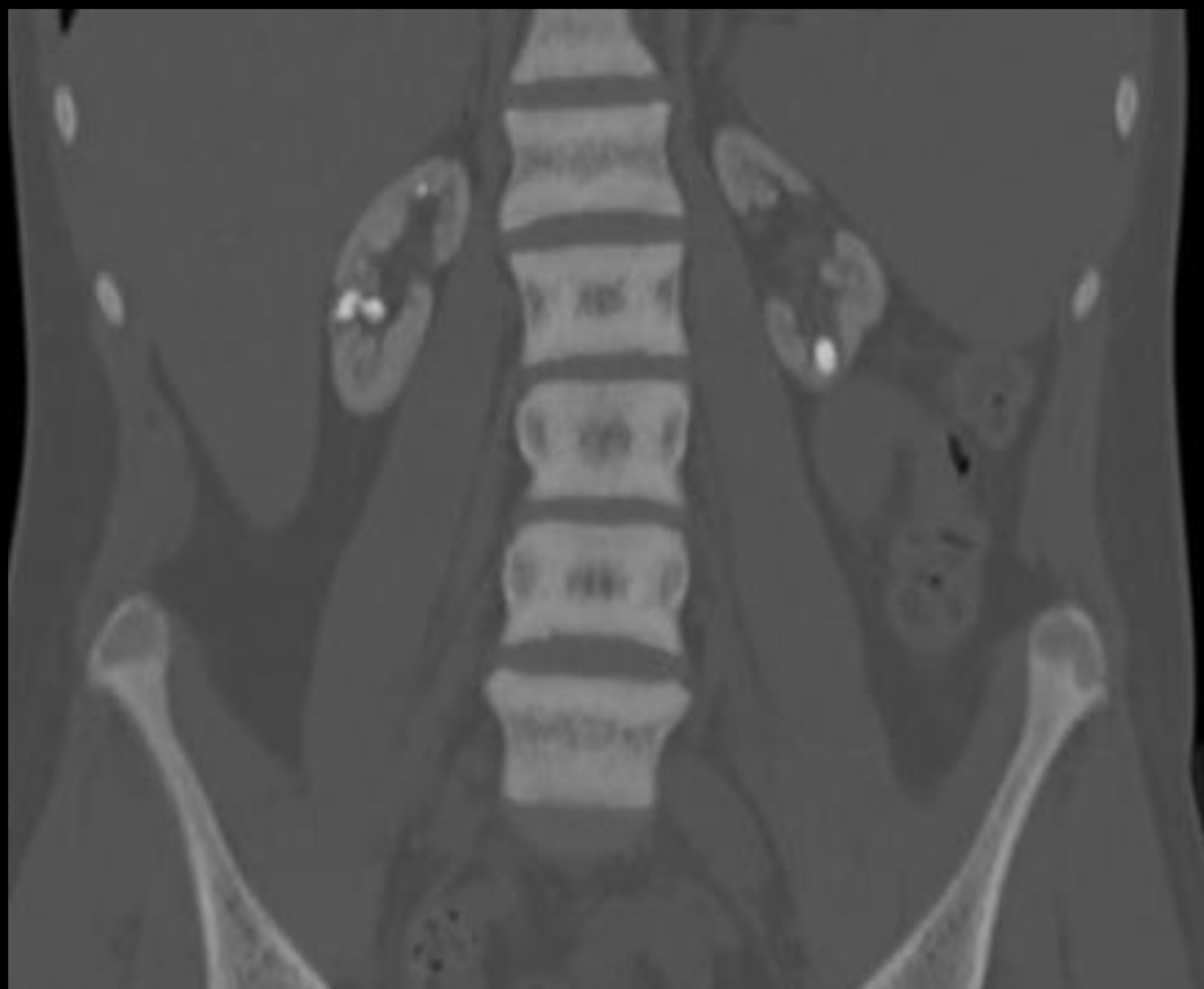


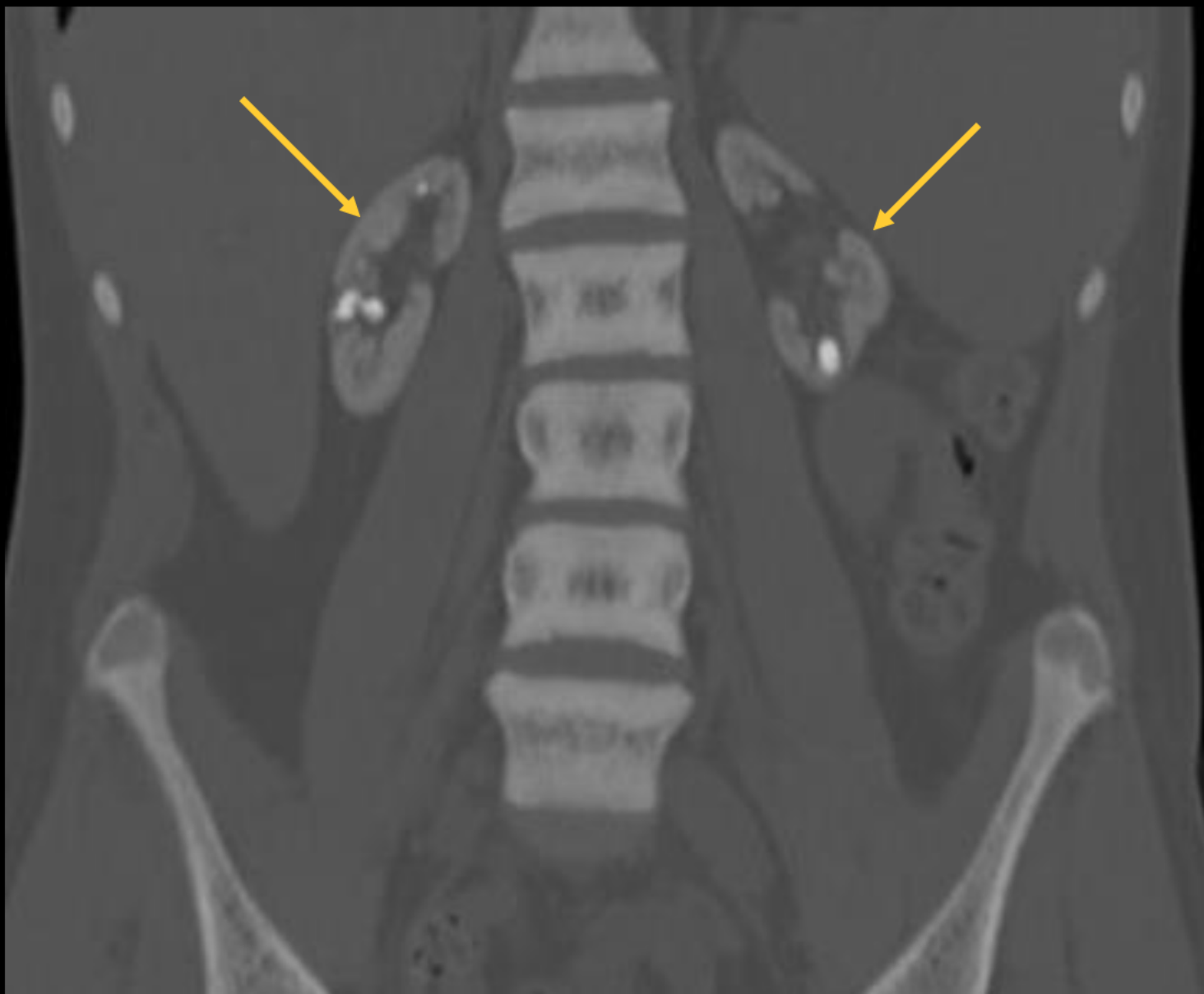
# Genitourinary Best Case



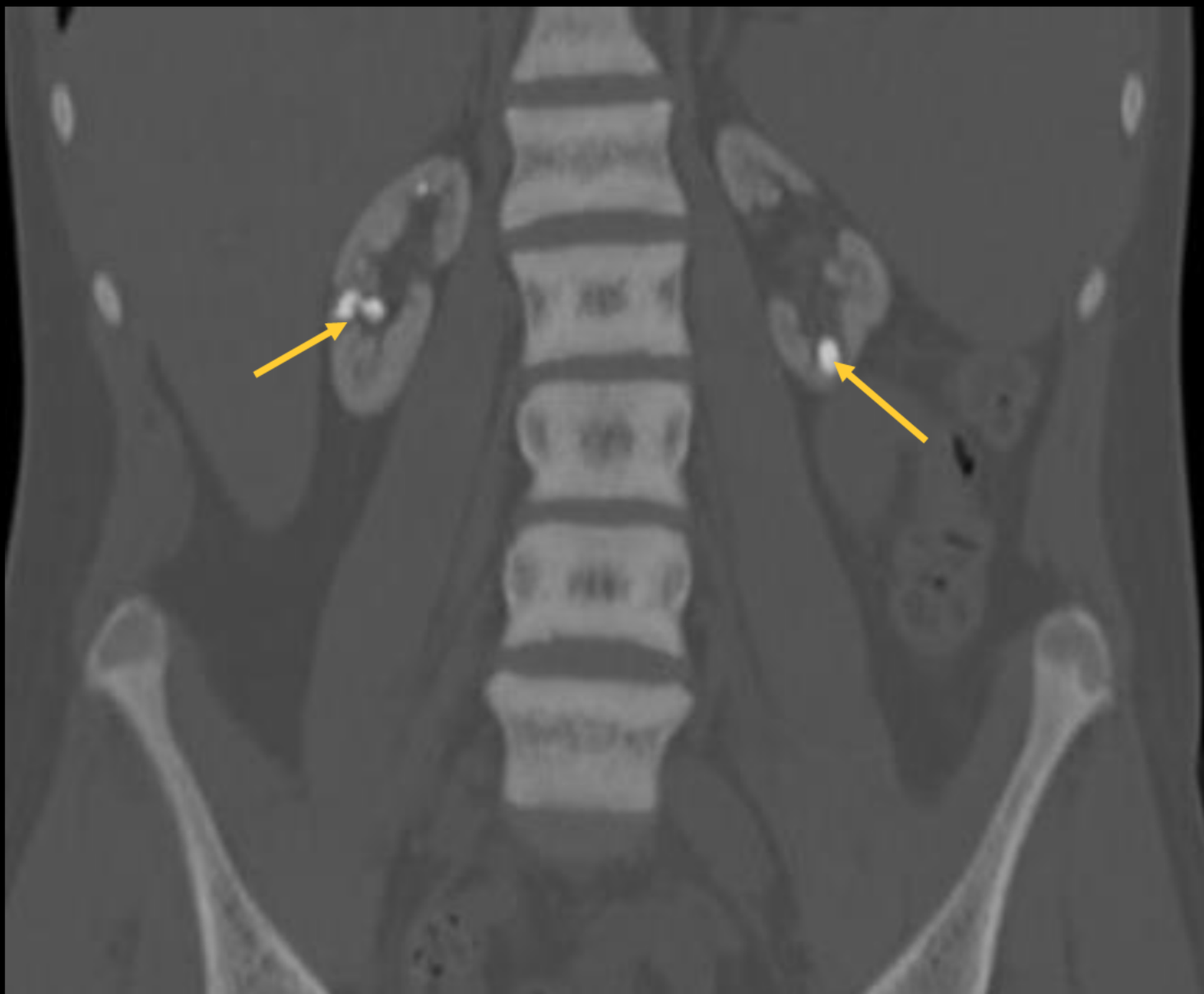
# Clinical Information

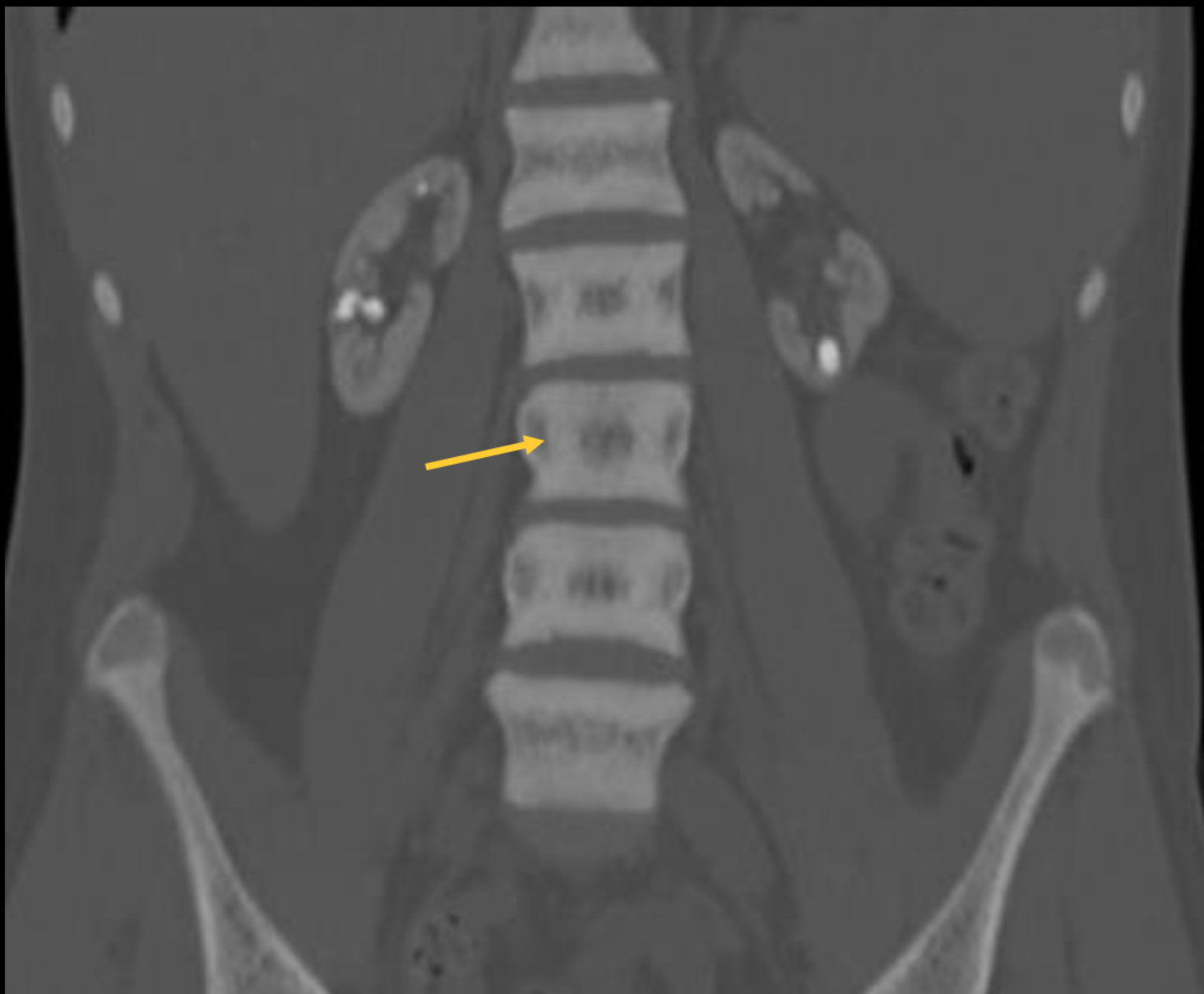**Withheld.....**

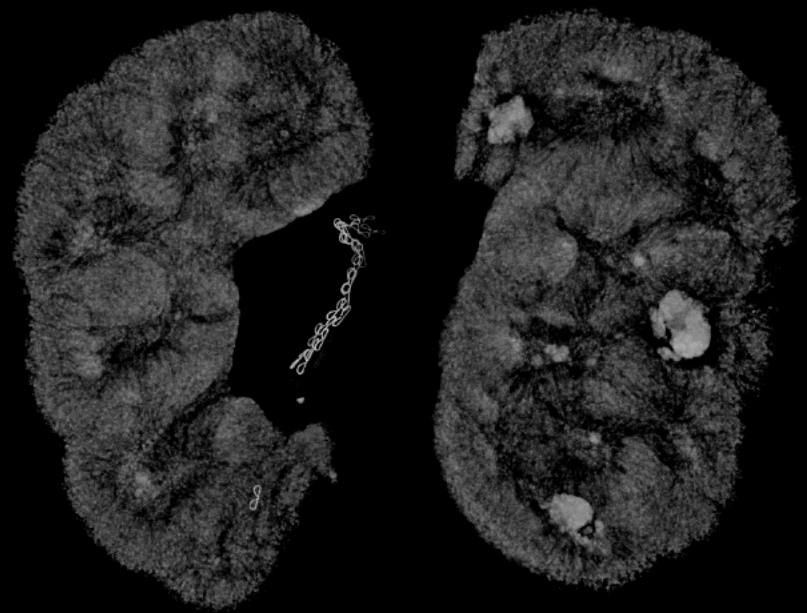
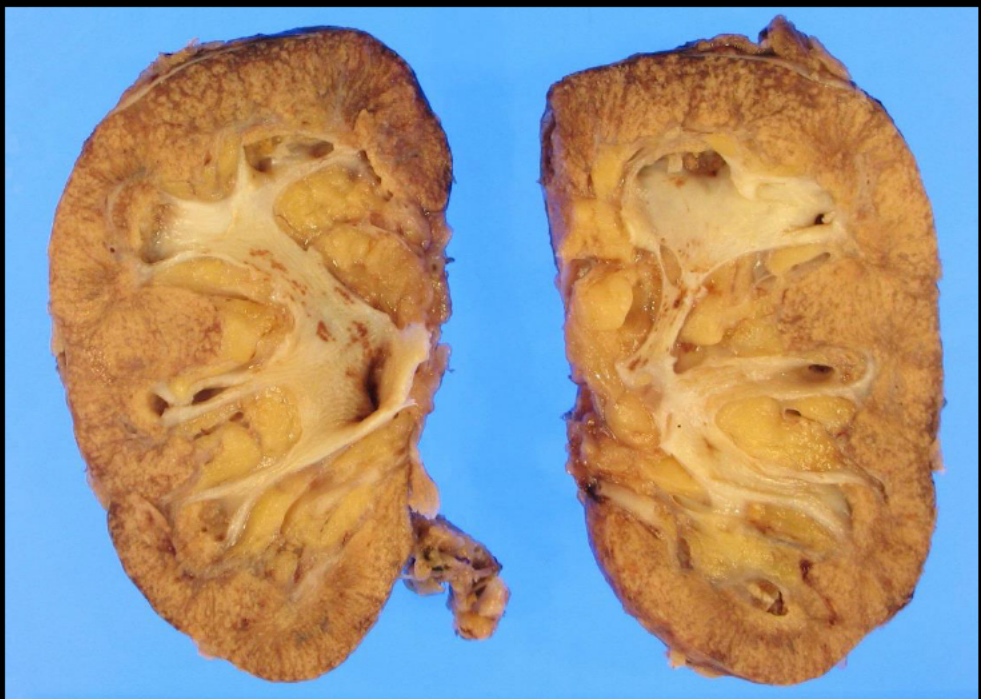


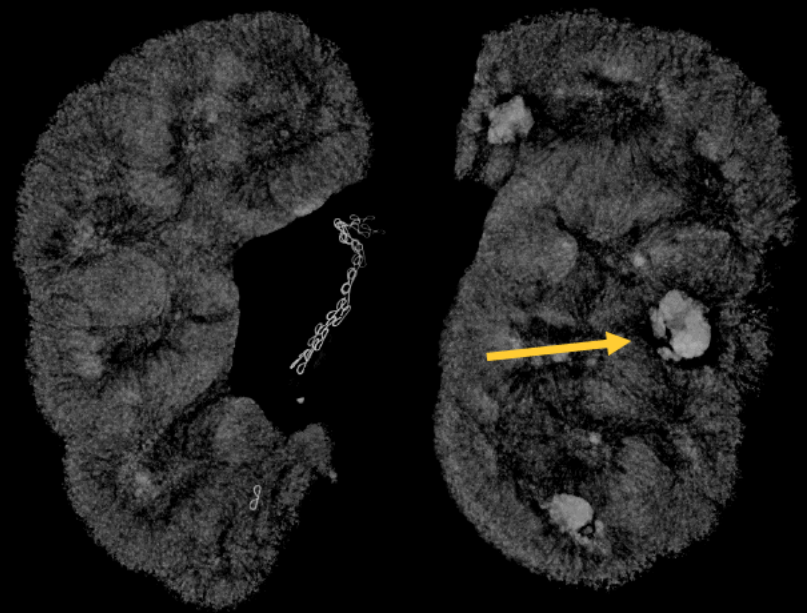
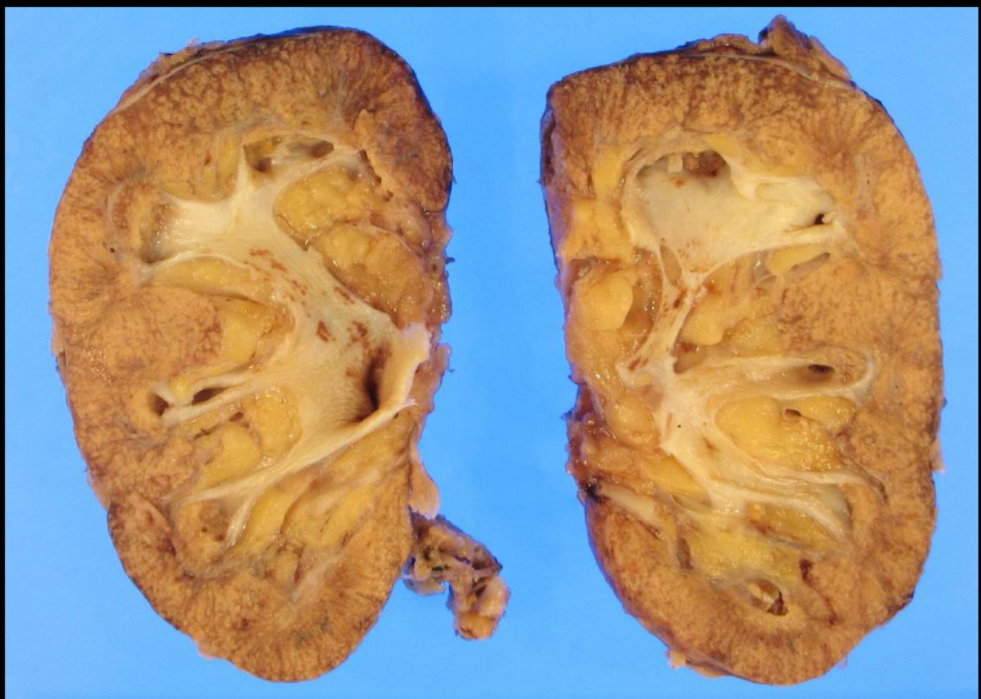




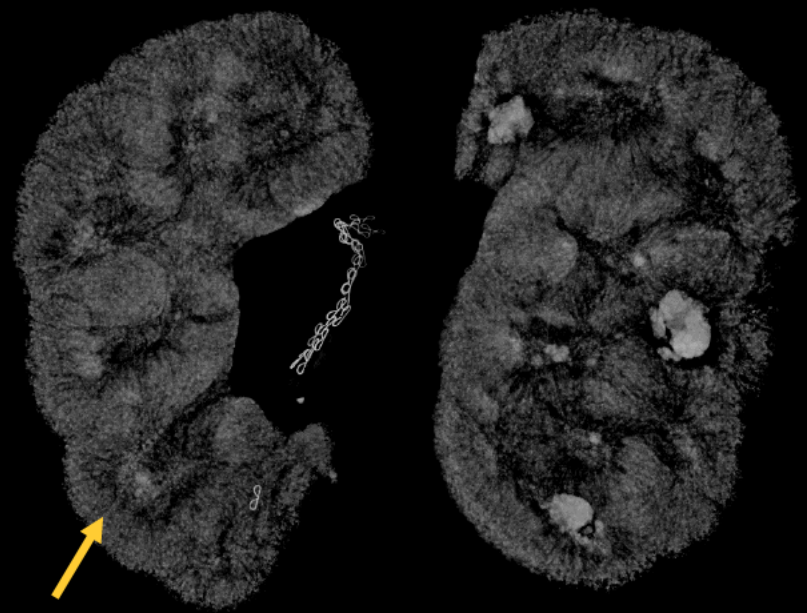
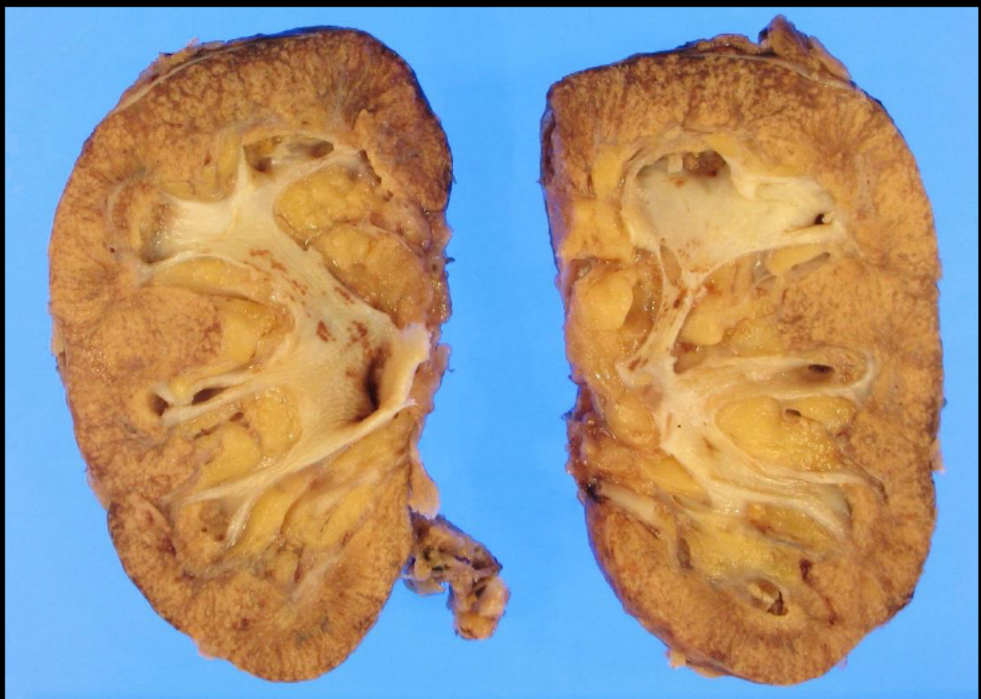




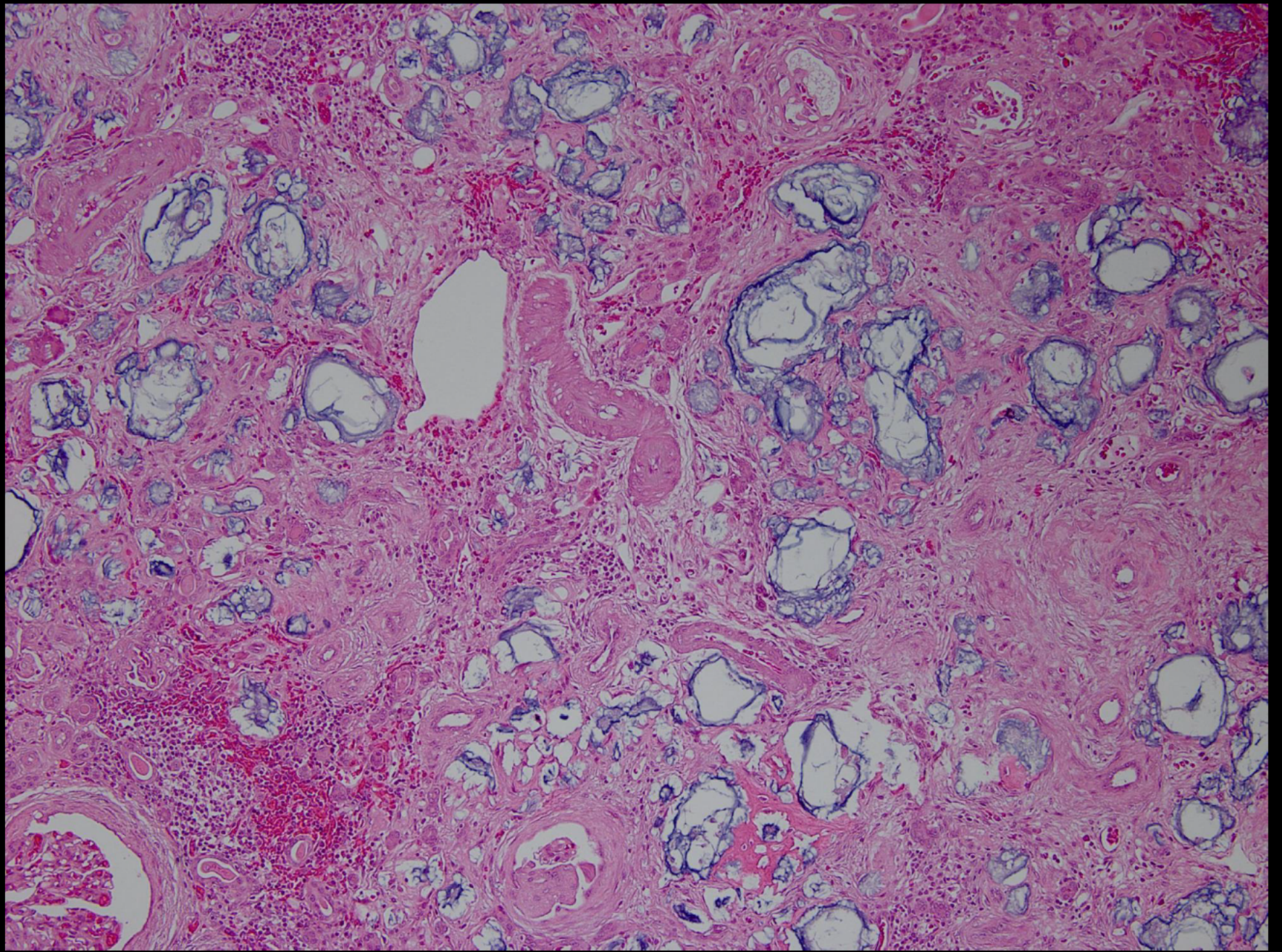




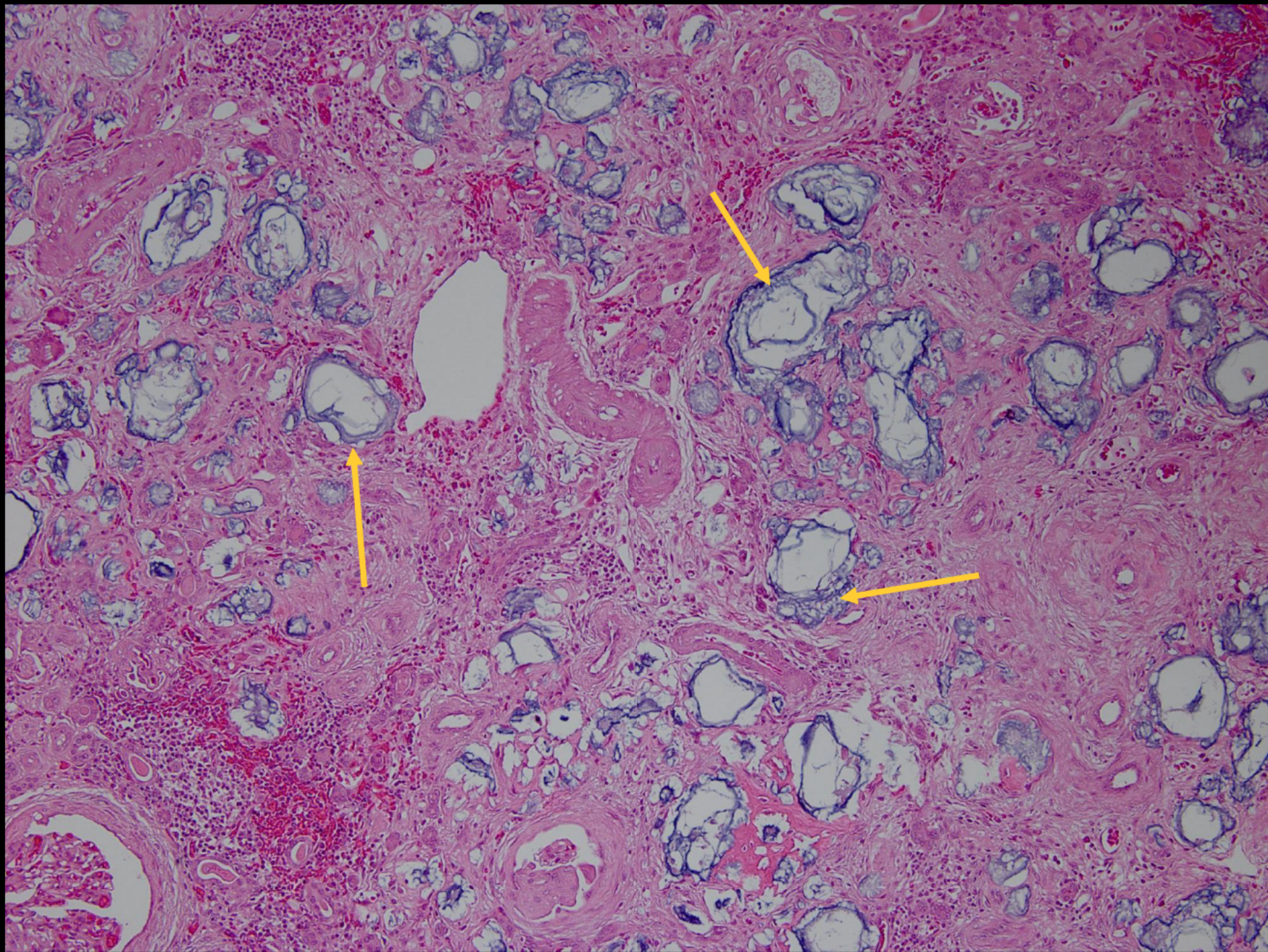




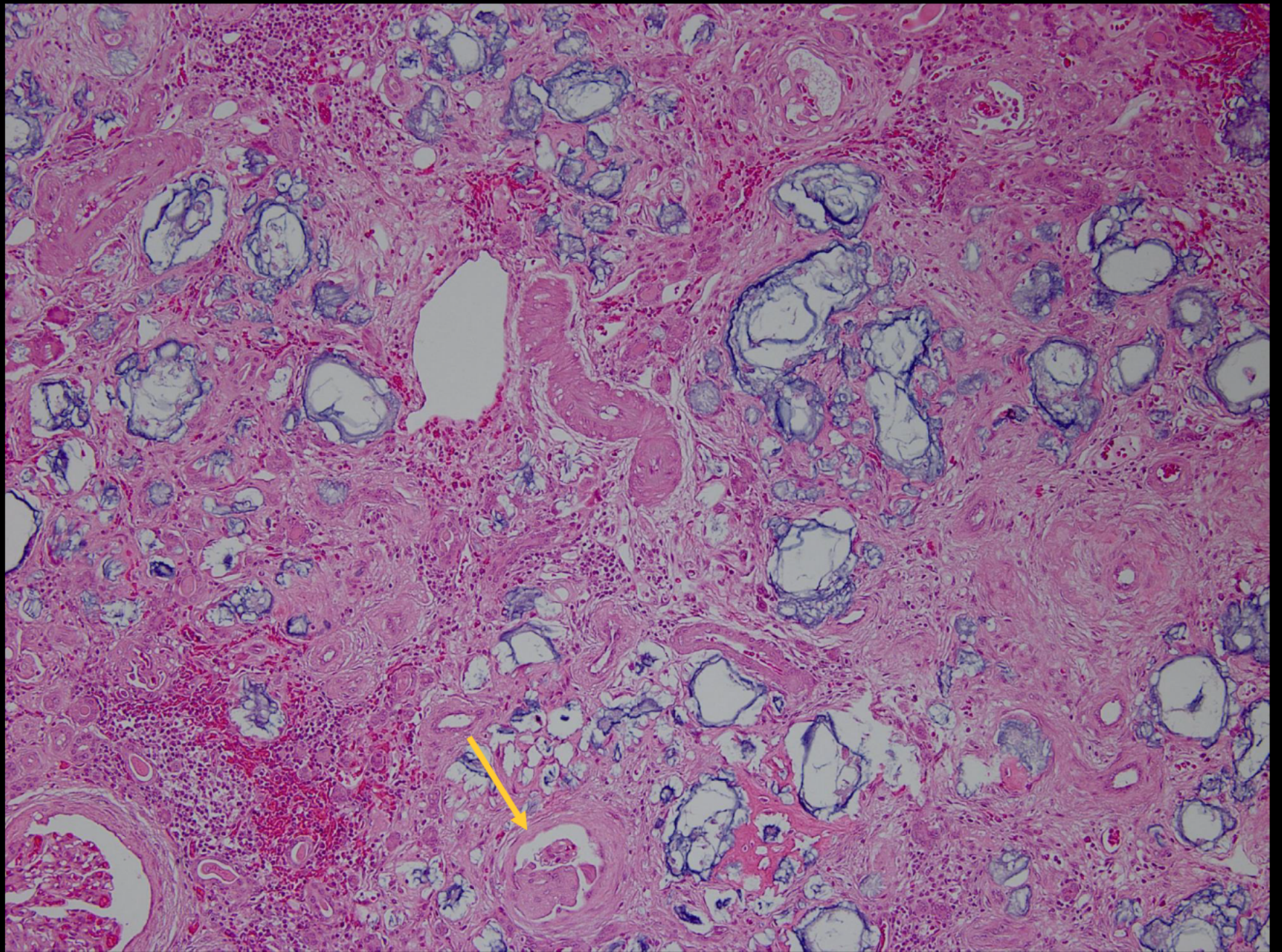




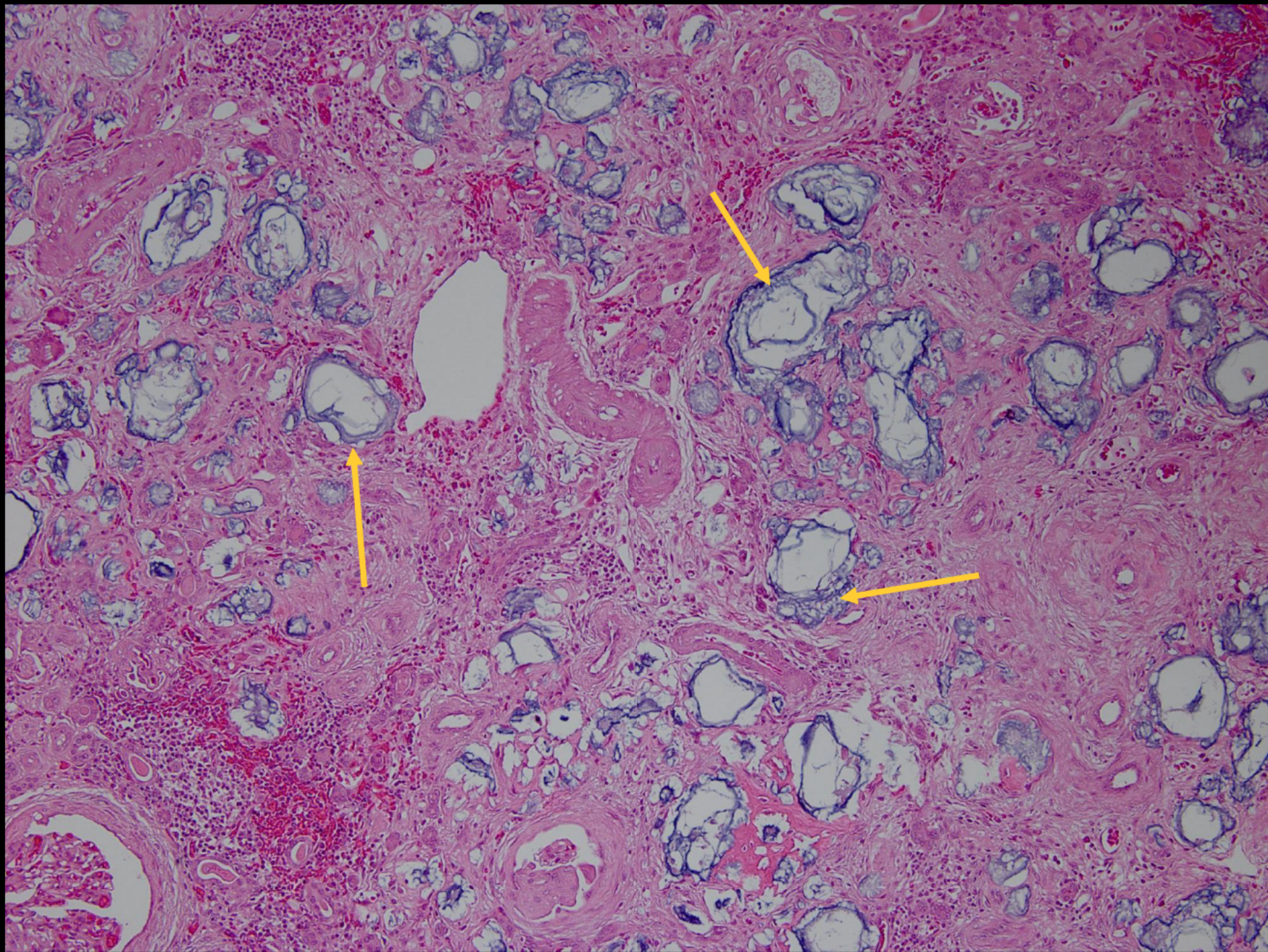














# Primary Hyperoxaluria Type 1

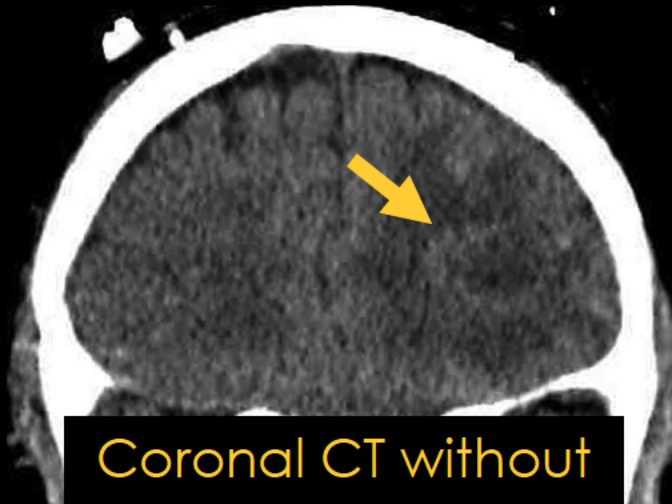
**Matthew Quirk, MD**  
**UCLA Medical Center**  
**Los Angeles, CA**



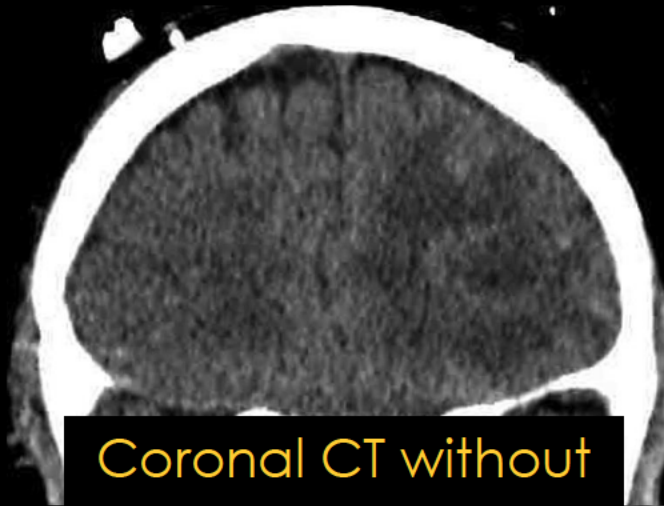


# History

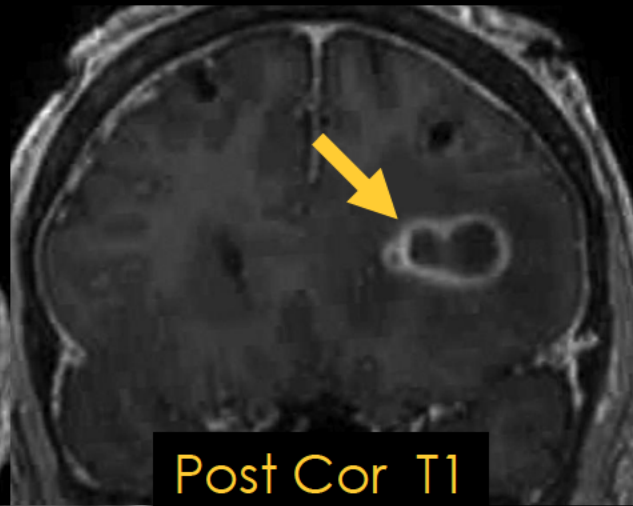
**57-year-old male transferred from outside facility by sister with progressive confusion and 1-day history of fever. Physical exam shows non-reactive pupils, no brainstem reflexes and no motor activity**



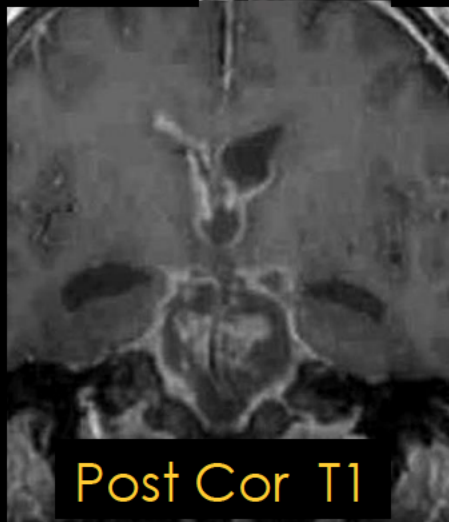Coronal CT without



Coronal CT without

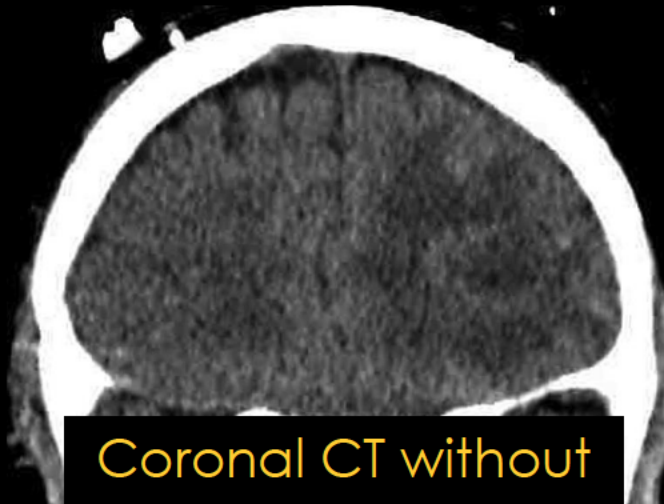


Post Cor T1

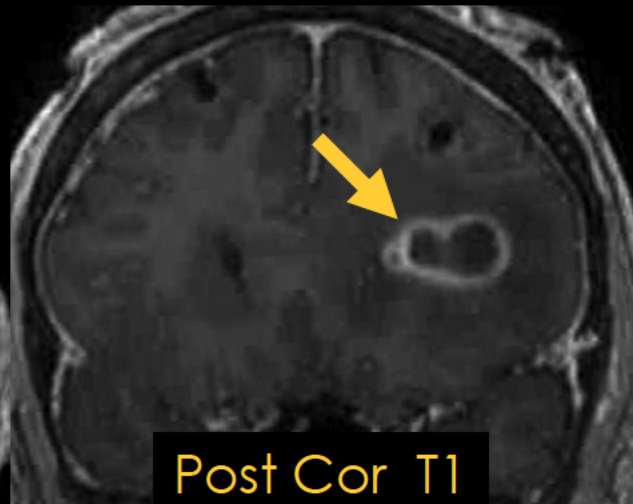


Post Cor T1

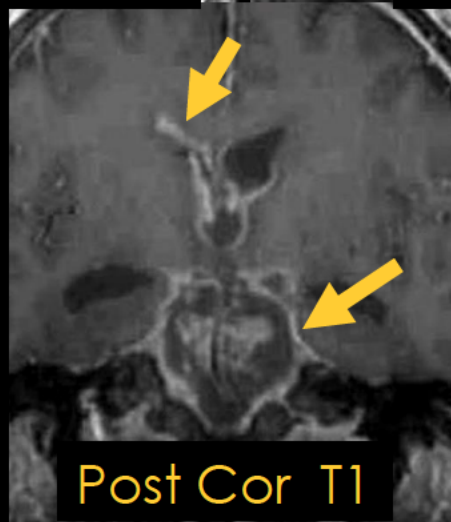




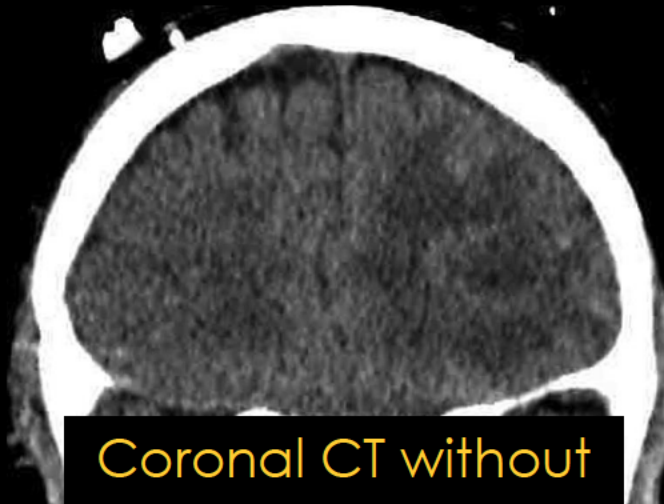
Coronal CT without



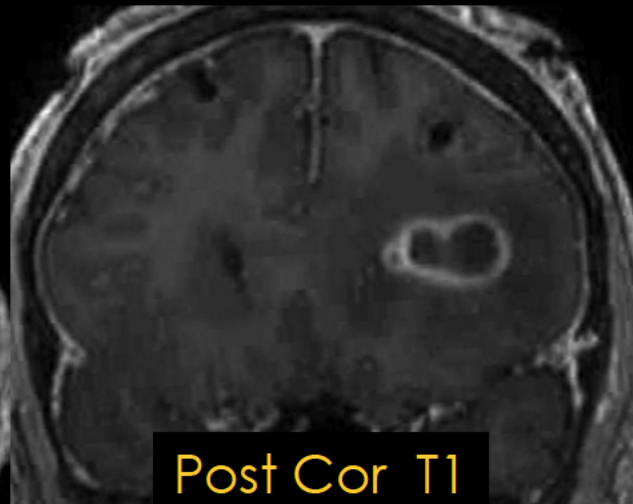
Post Cor T1



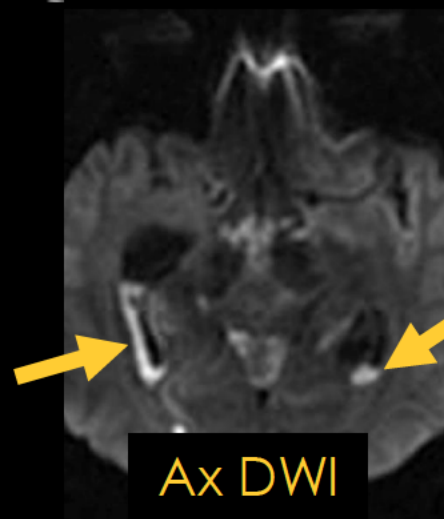
Post Cor T1



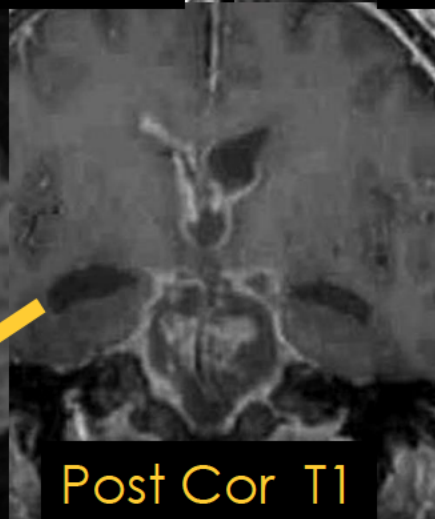Coronal CT without



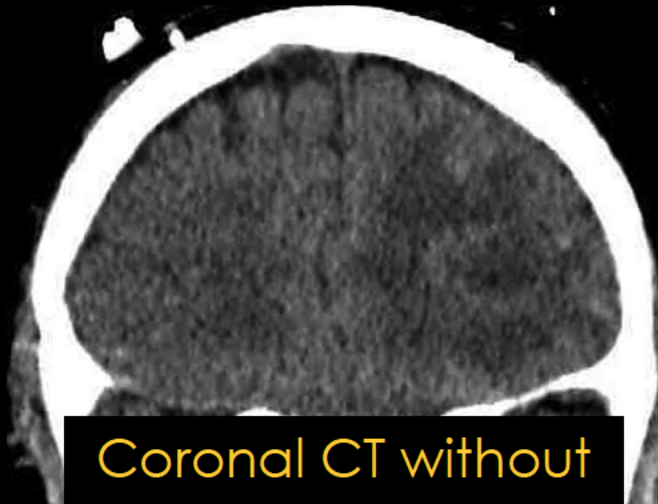Post Cor T1



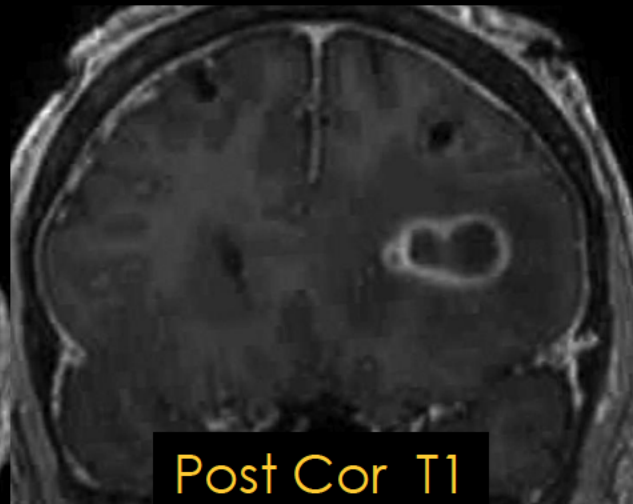
Ax DWI



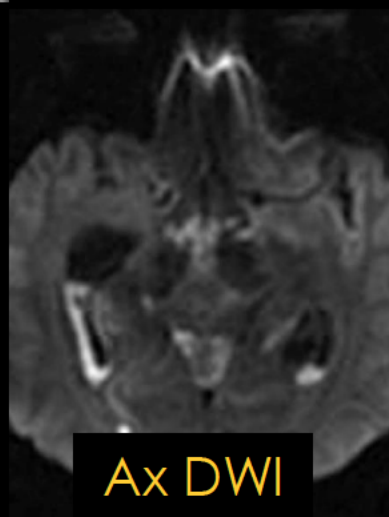
Post Cor T1



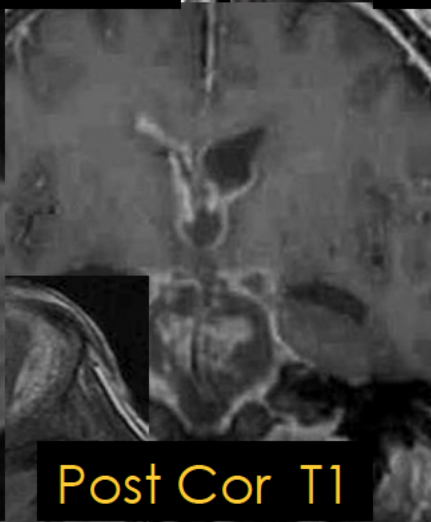
Coronal CT without



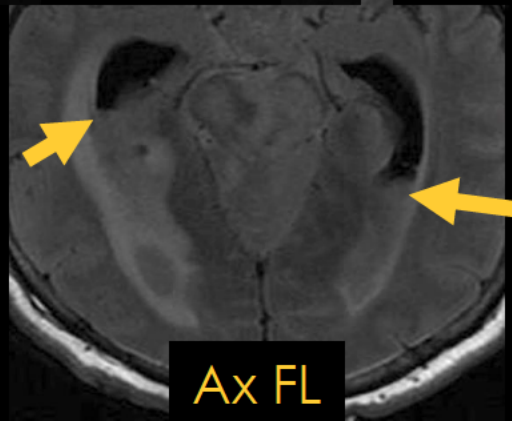
Post Cor T1



Ax DWI

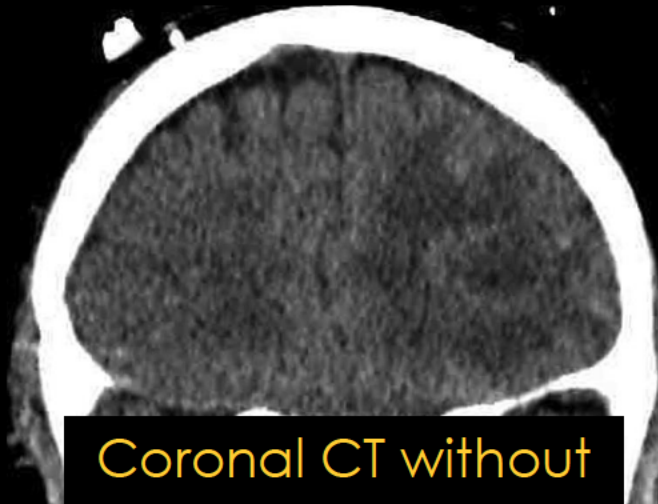


Post Cor T1

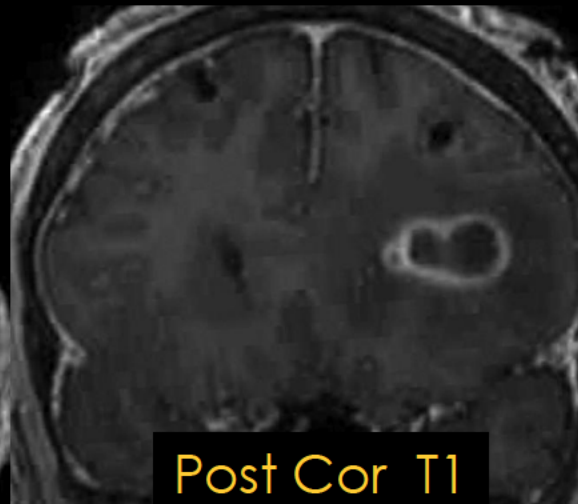


Ax FL

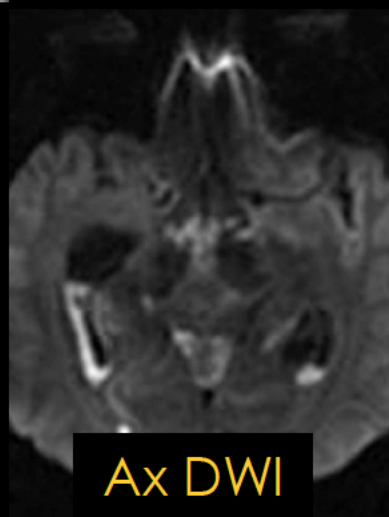
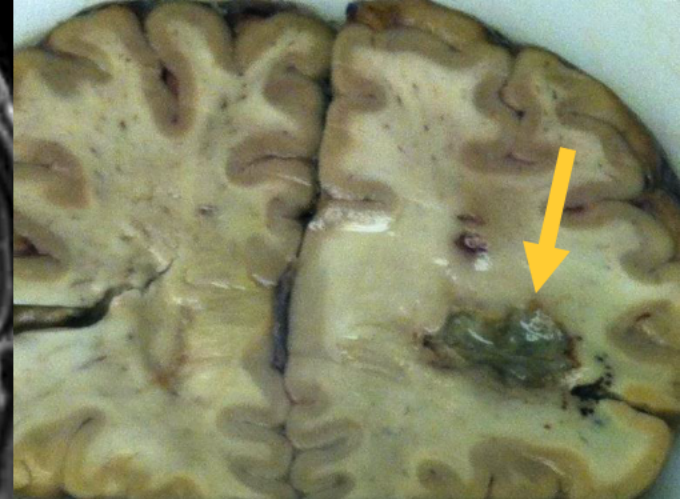



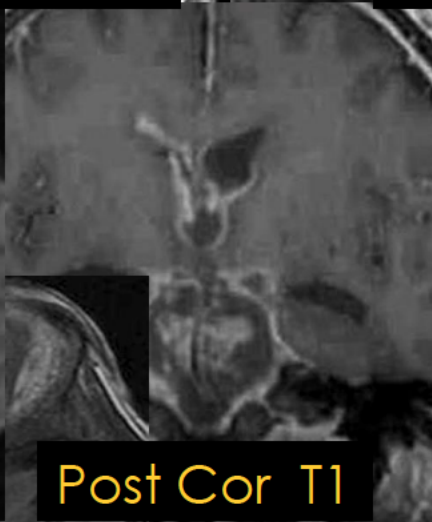
Coronal CT without



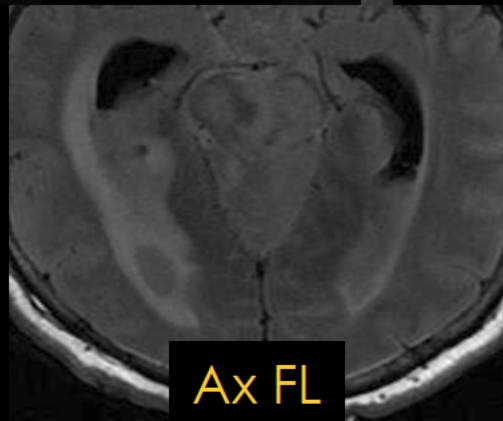
Post Cor T1



Ax DWI



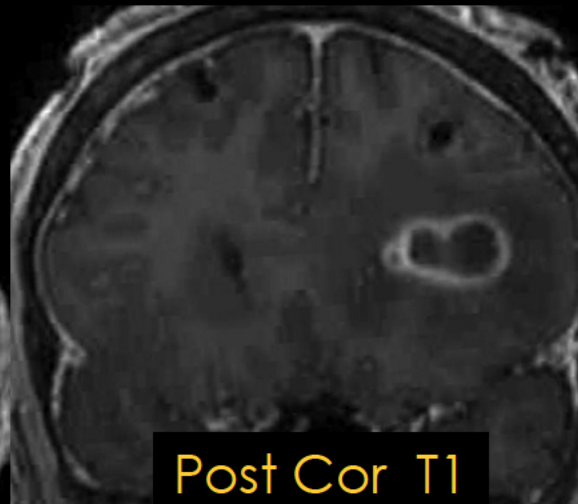
Post Cor T1



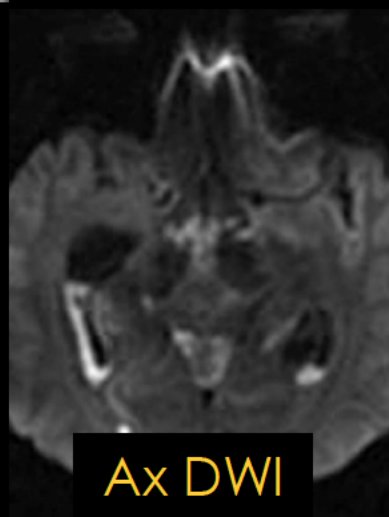
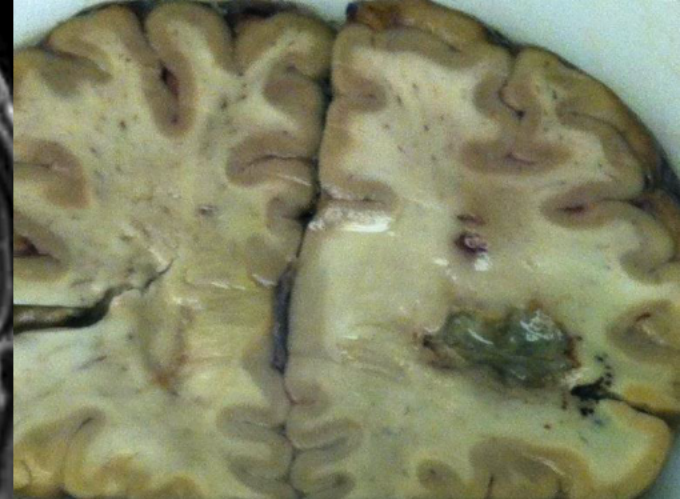Ax FL



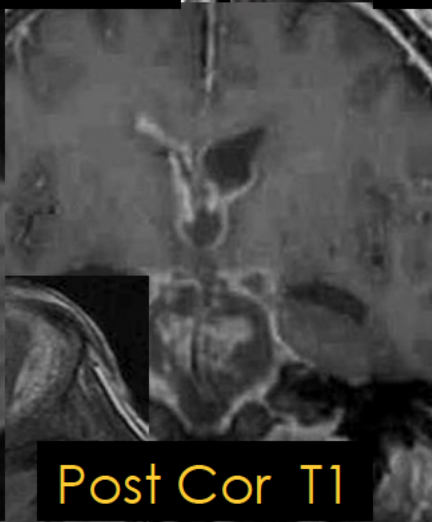
Coronal CT without



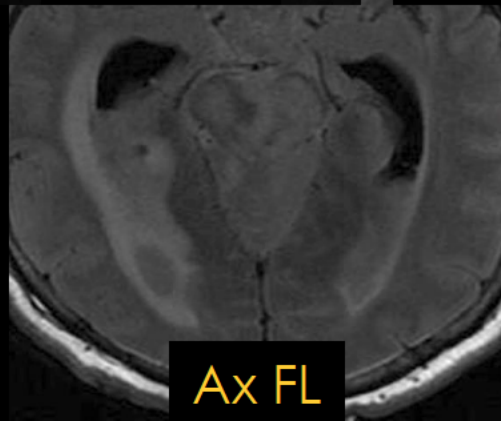
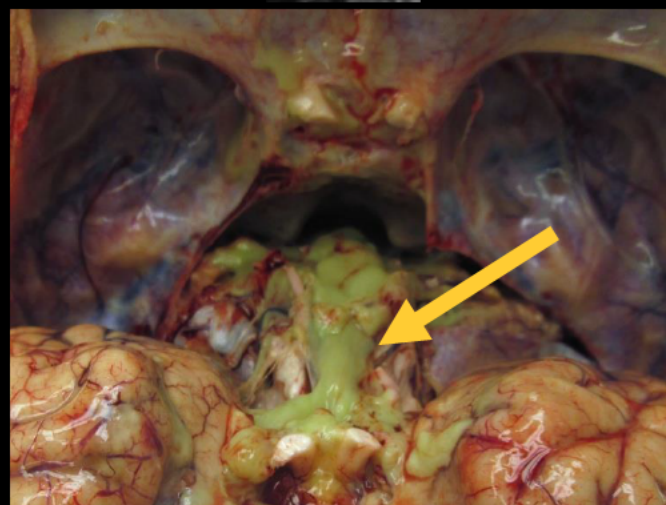
Post Cor T1



Ax DWI

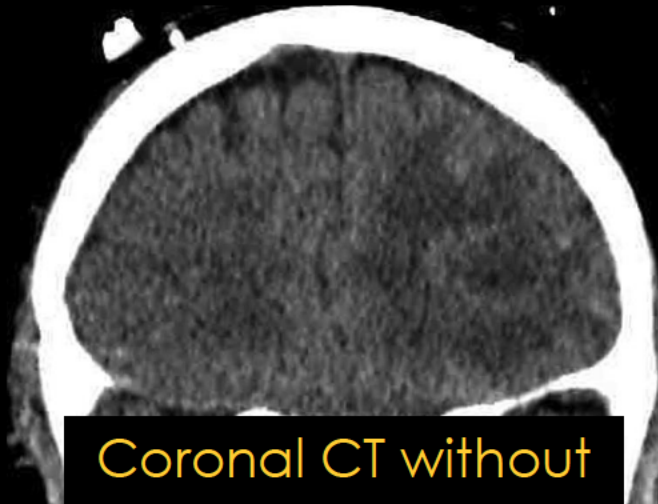


Post Cor T1

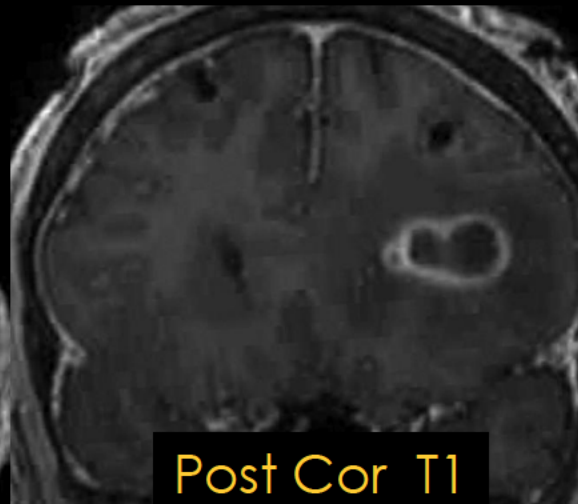


Ax FL

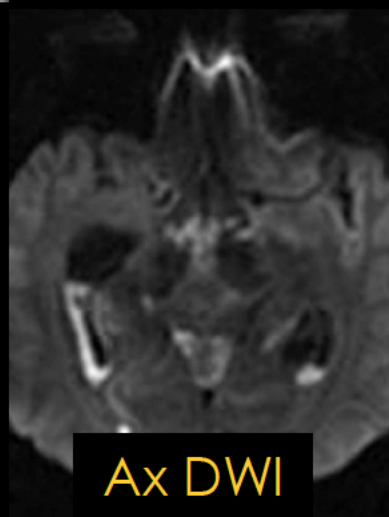




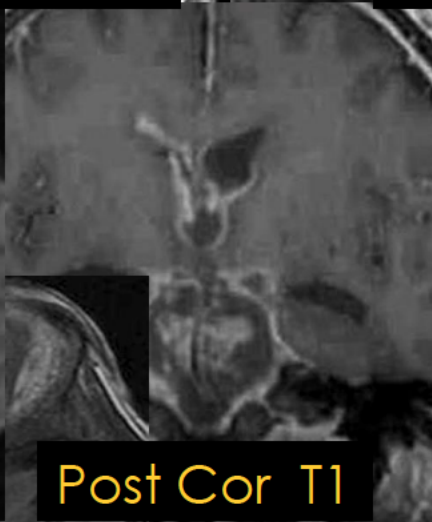
Coronal CT without



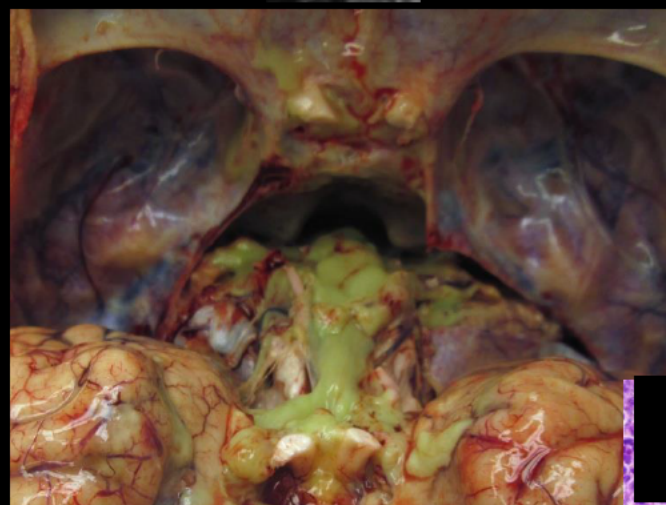
Post Cor T1



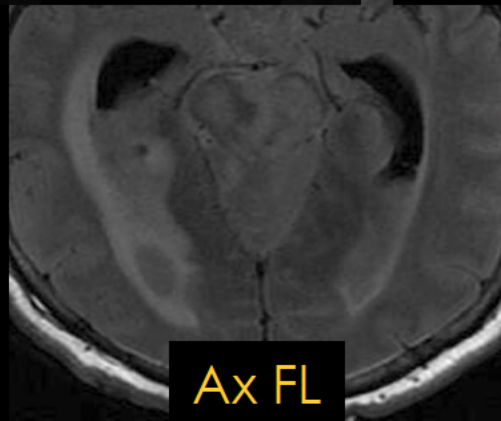
Ax DWI



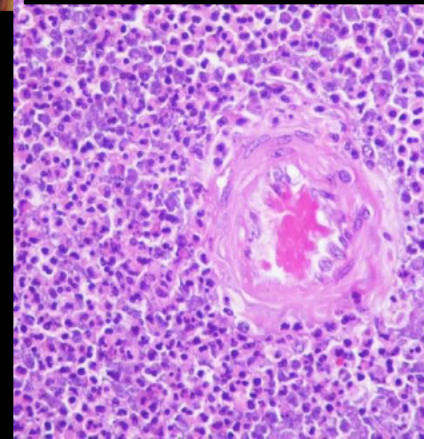
Post Cor T1



Perivascular  
inflammatory cells



Ax FL

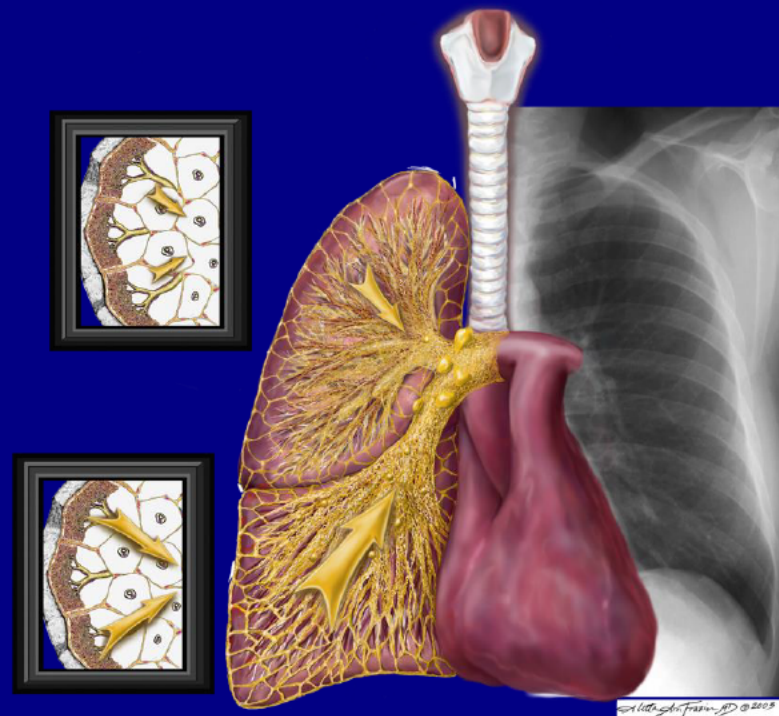




# **Diffuse Meningitis, Abscess, and Ventriculitis (with intraventricular rupture and fluid-debris level)**

**Abdelkader Mahammed, M.D.**  
**University of Toledo**  
**Toledo, Ohio**

# Pulmonary and Mediastinal Best Case

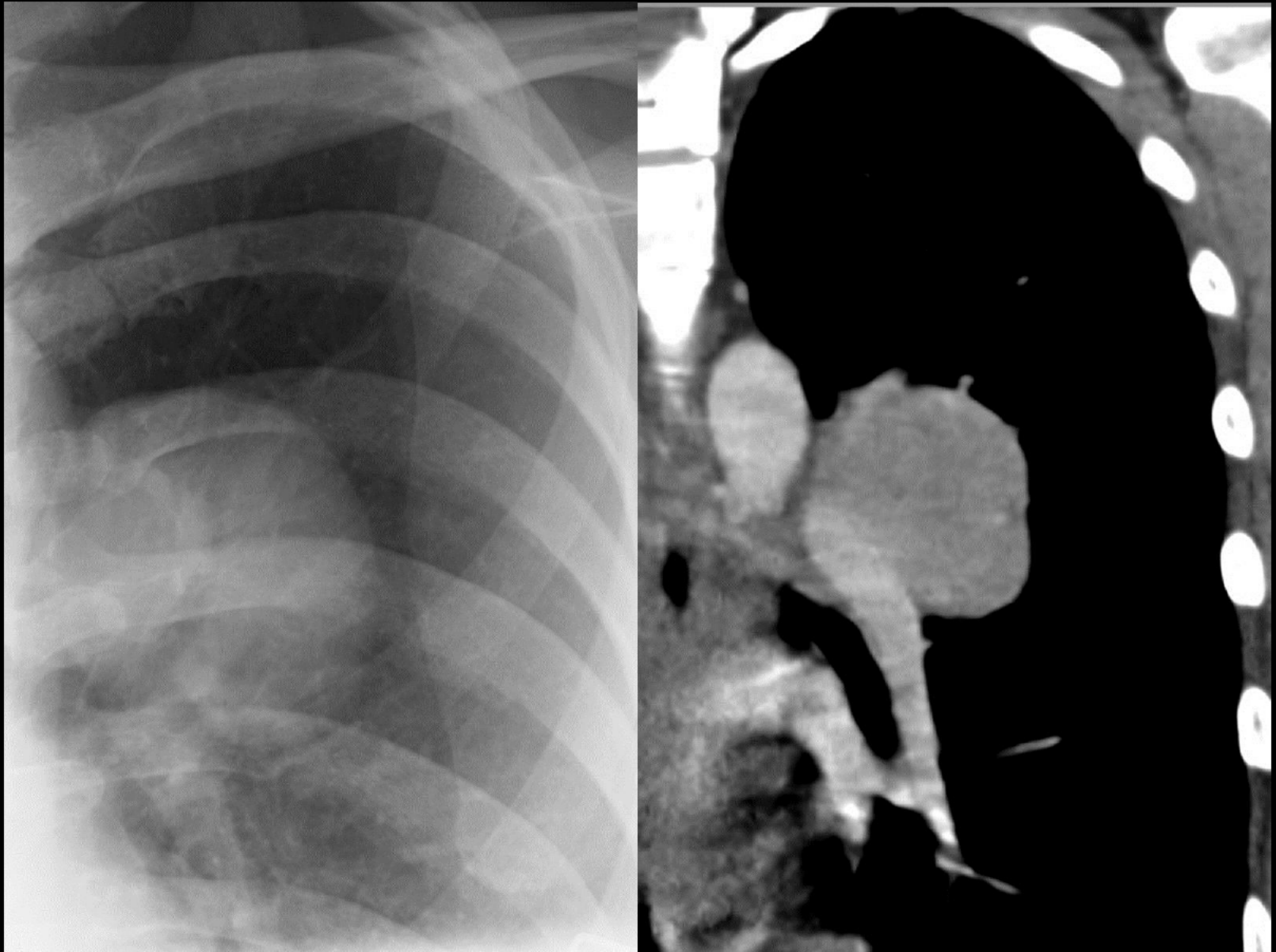


## History

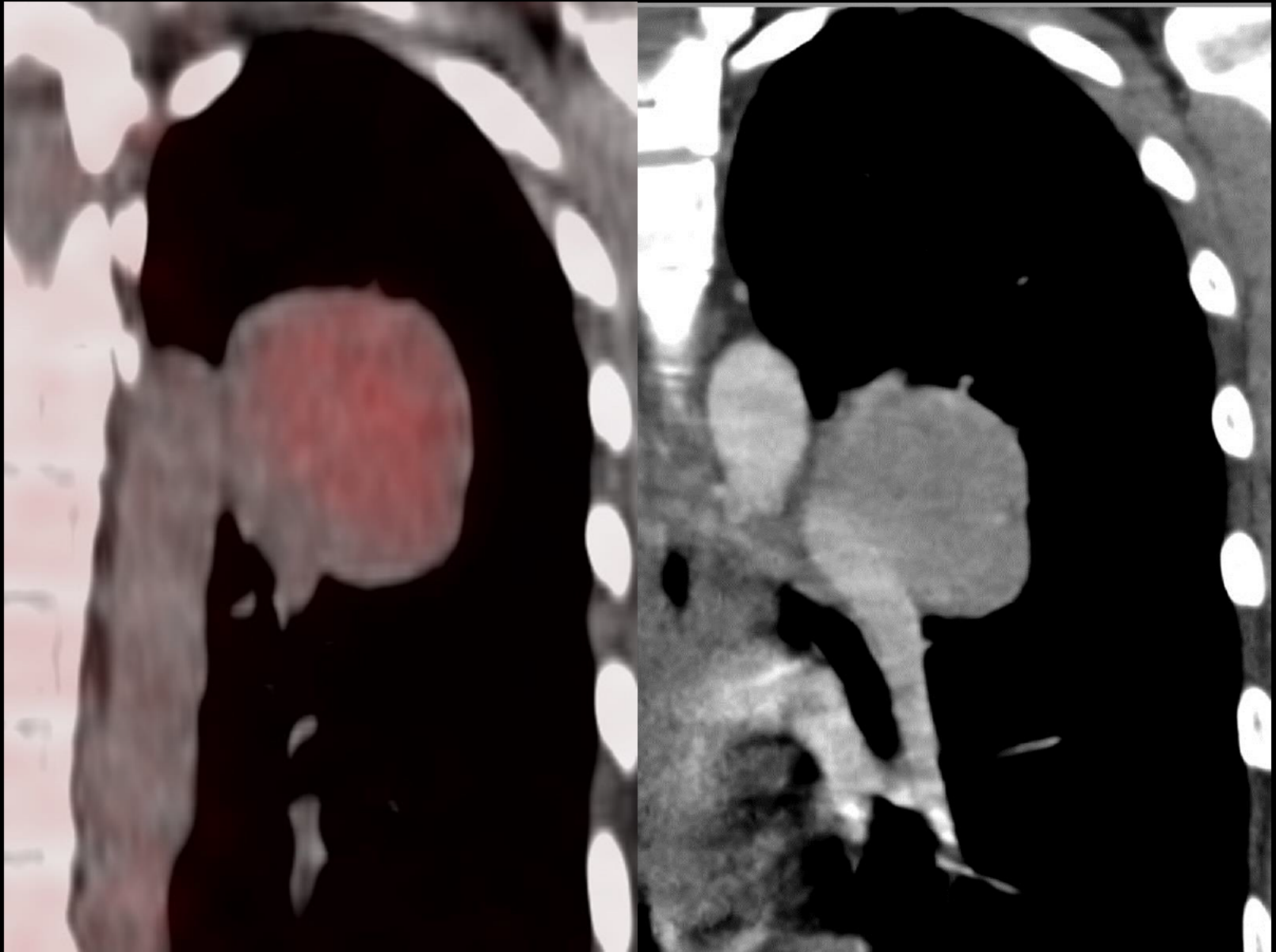
**30 year old female with left shoulder pain  
found to have a left hilar mass on a  
shoulder study**



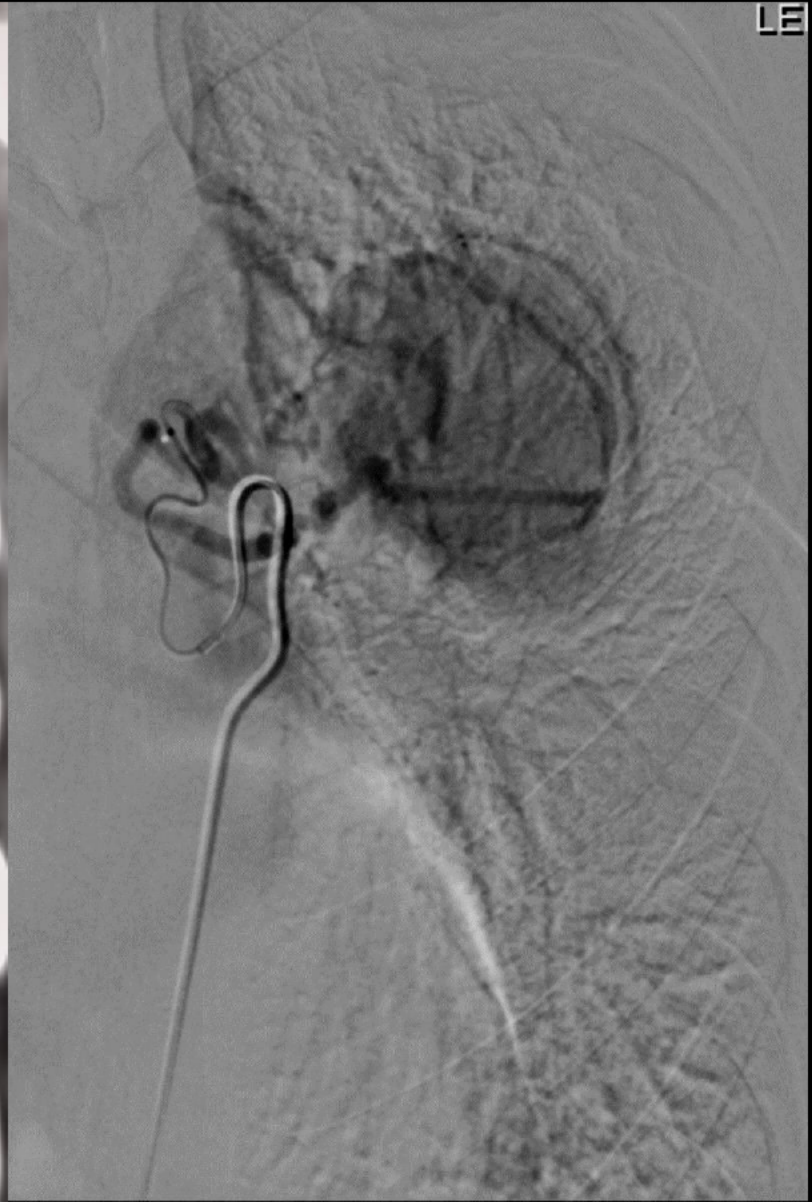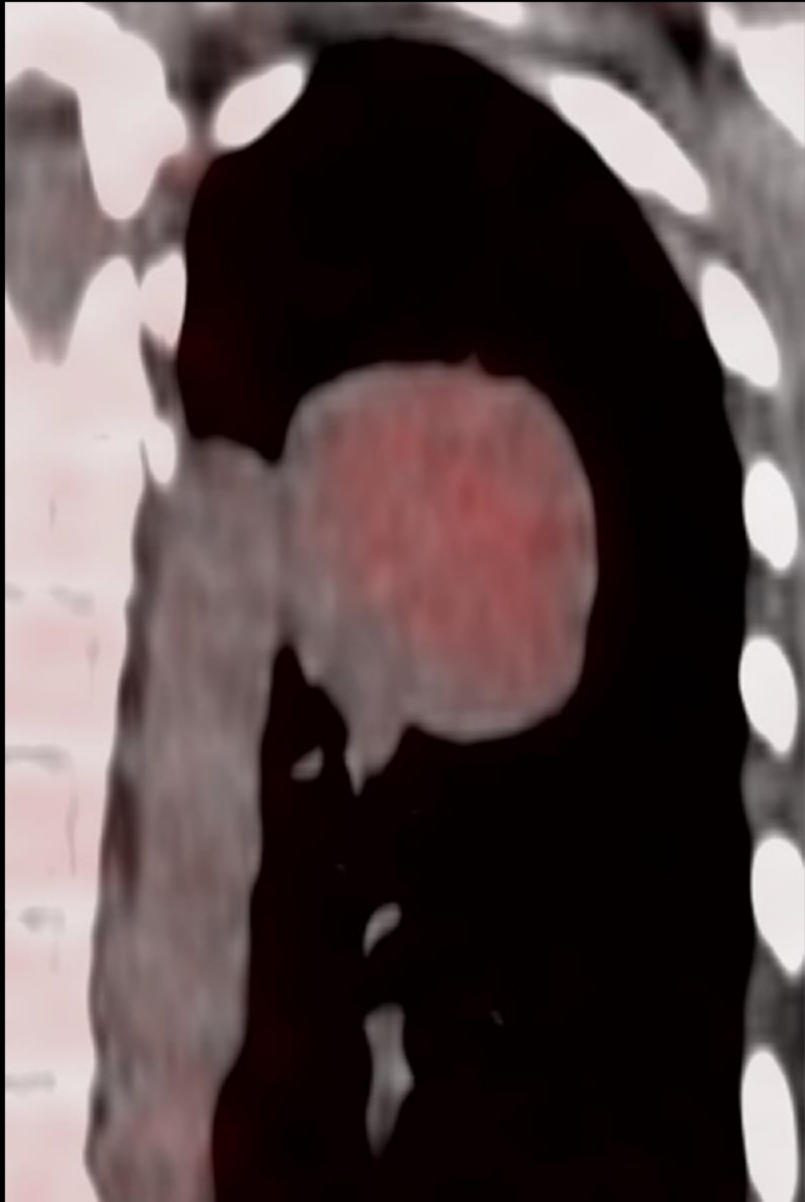
## Plain film/CT



# PET/CT

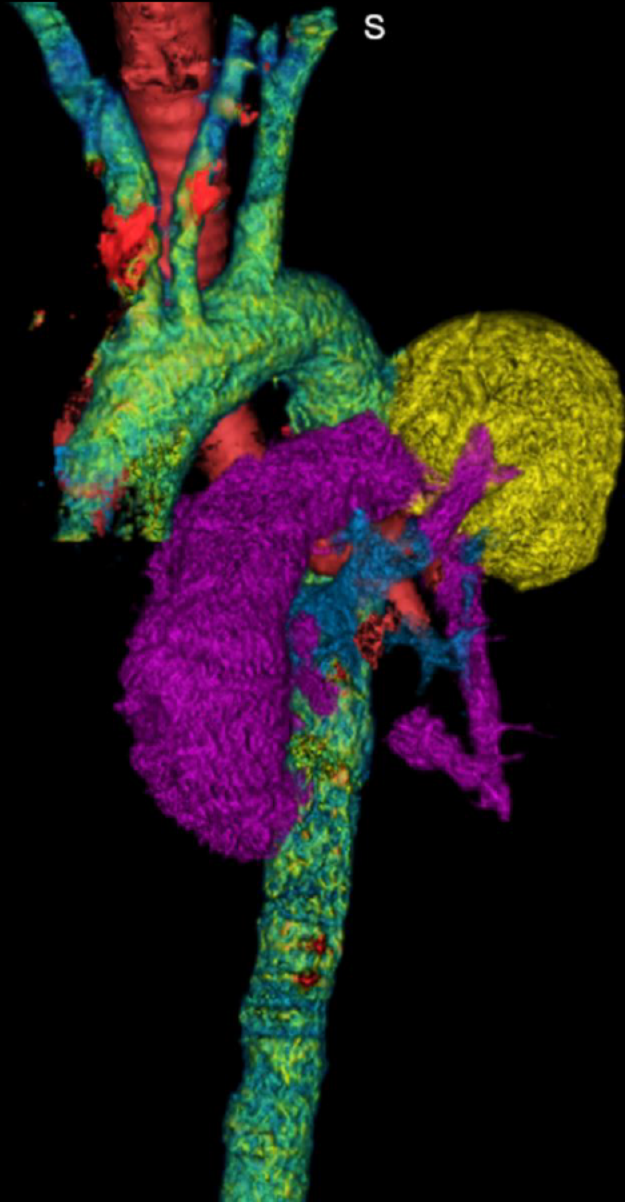
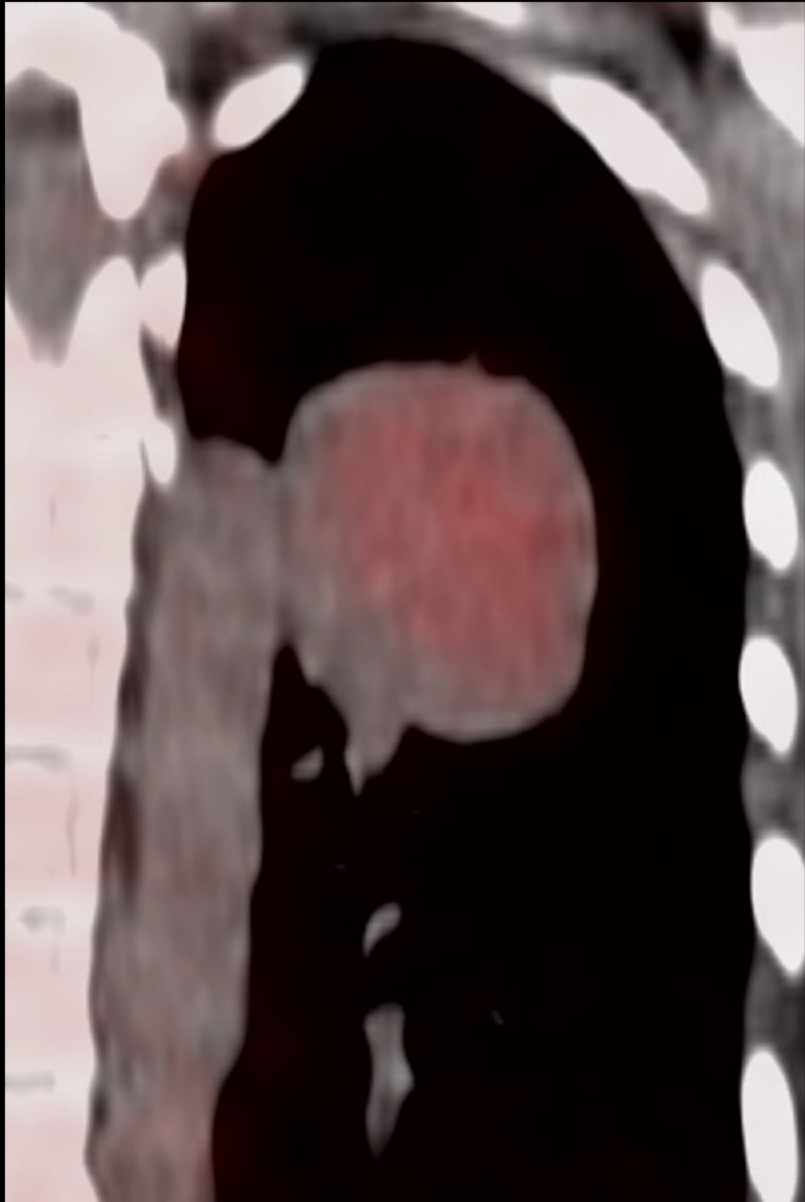


# Bronchial artery supply

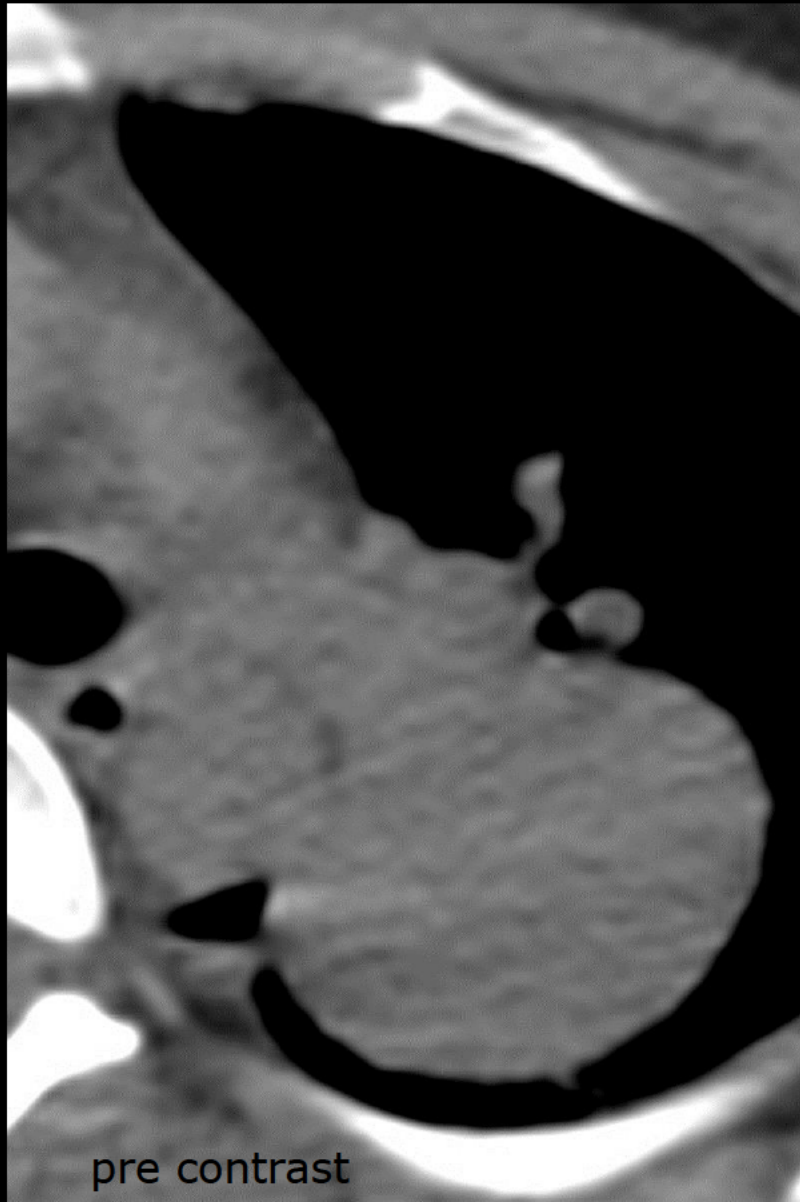




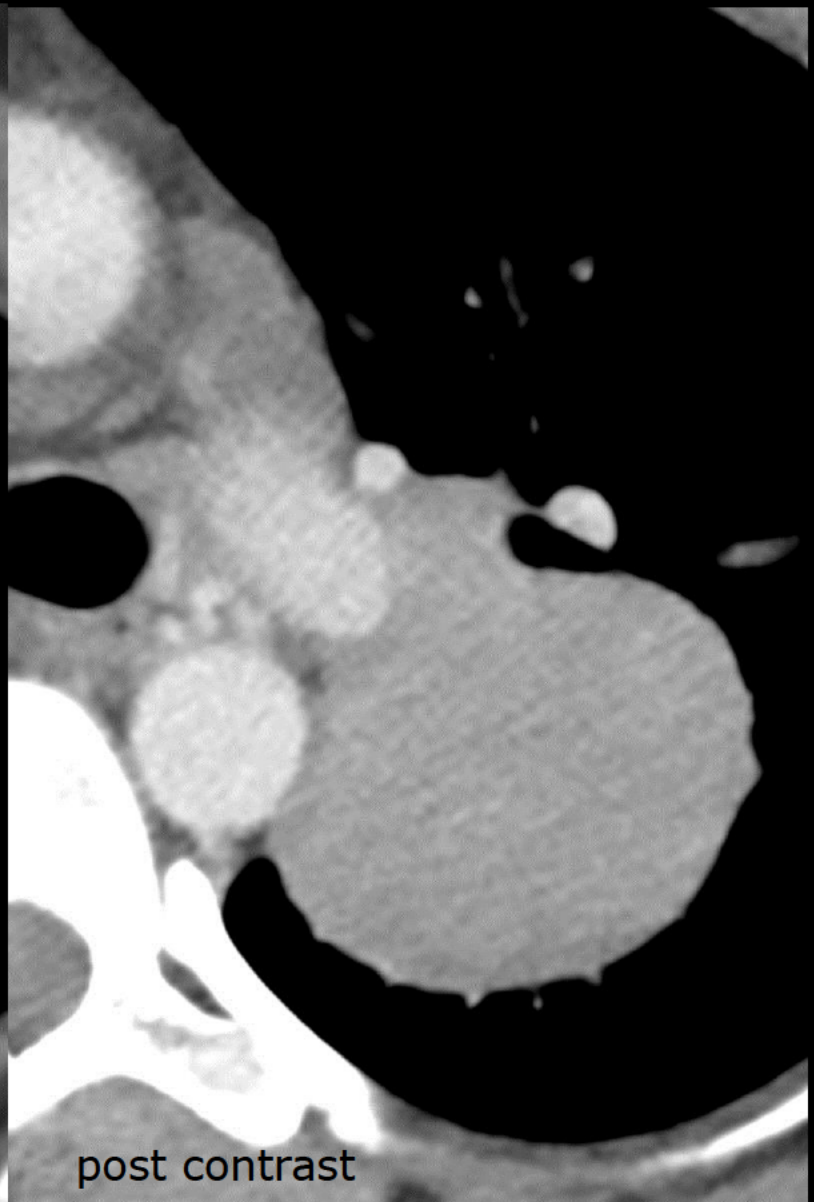
# 3D reconstruction



CT

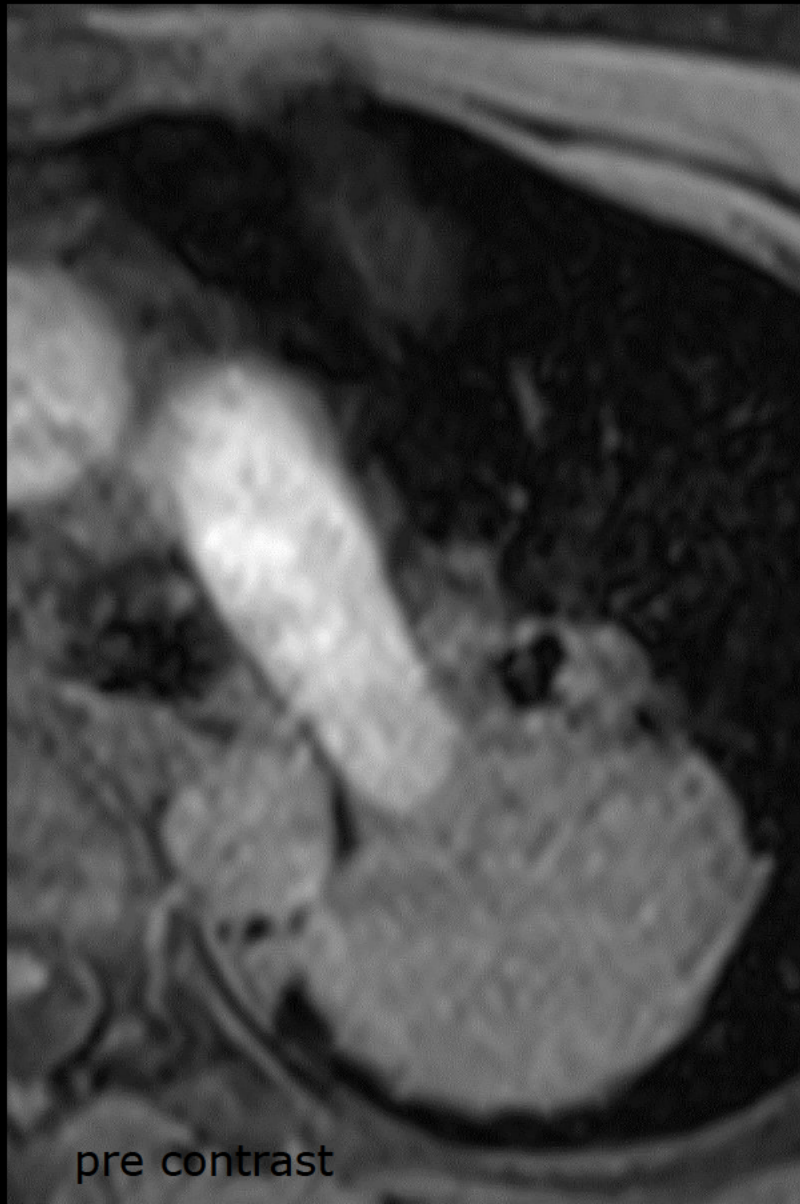

pre contrast

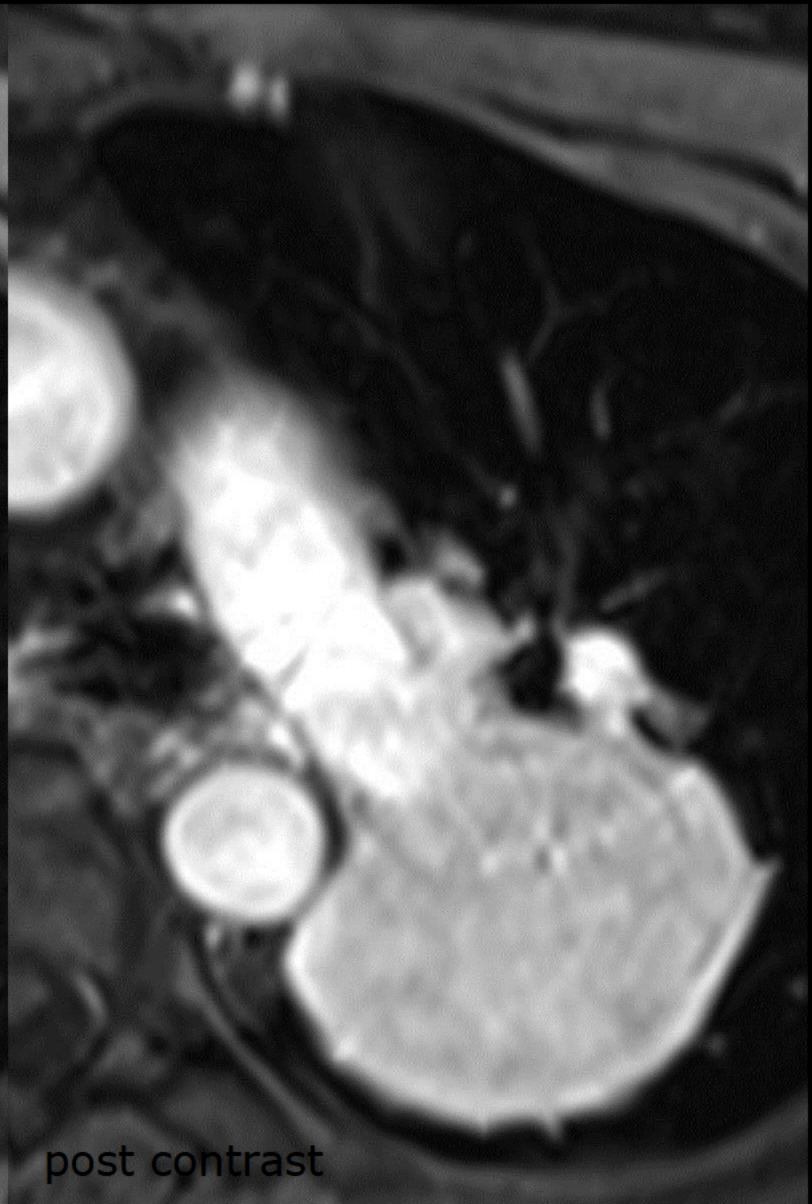


post contrast

# MR



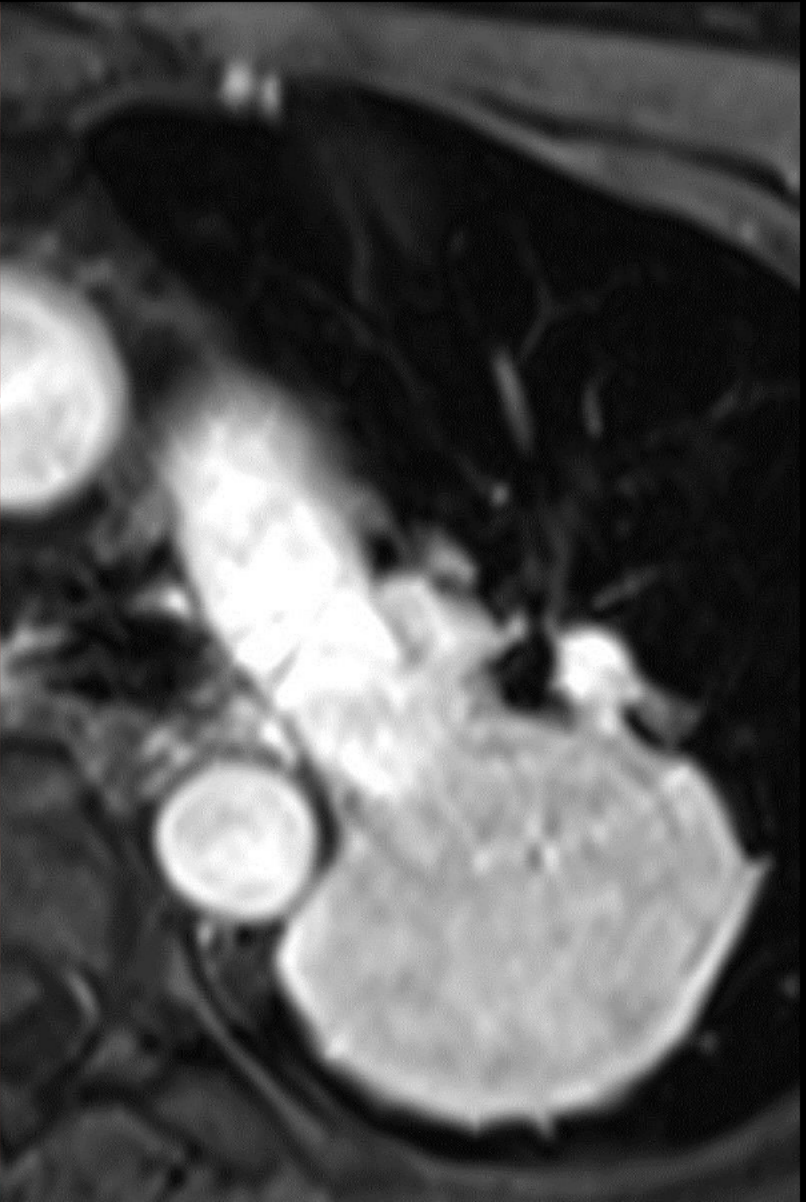
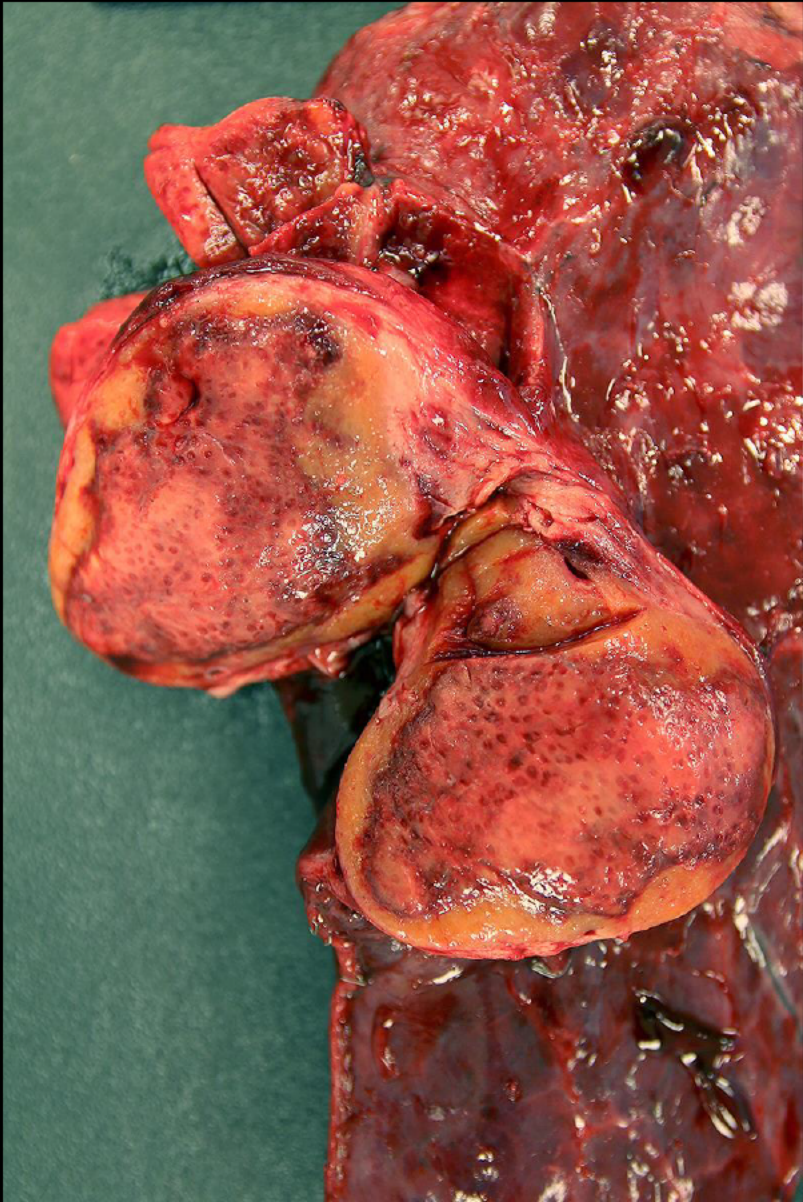
pre contrast



post contrast

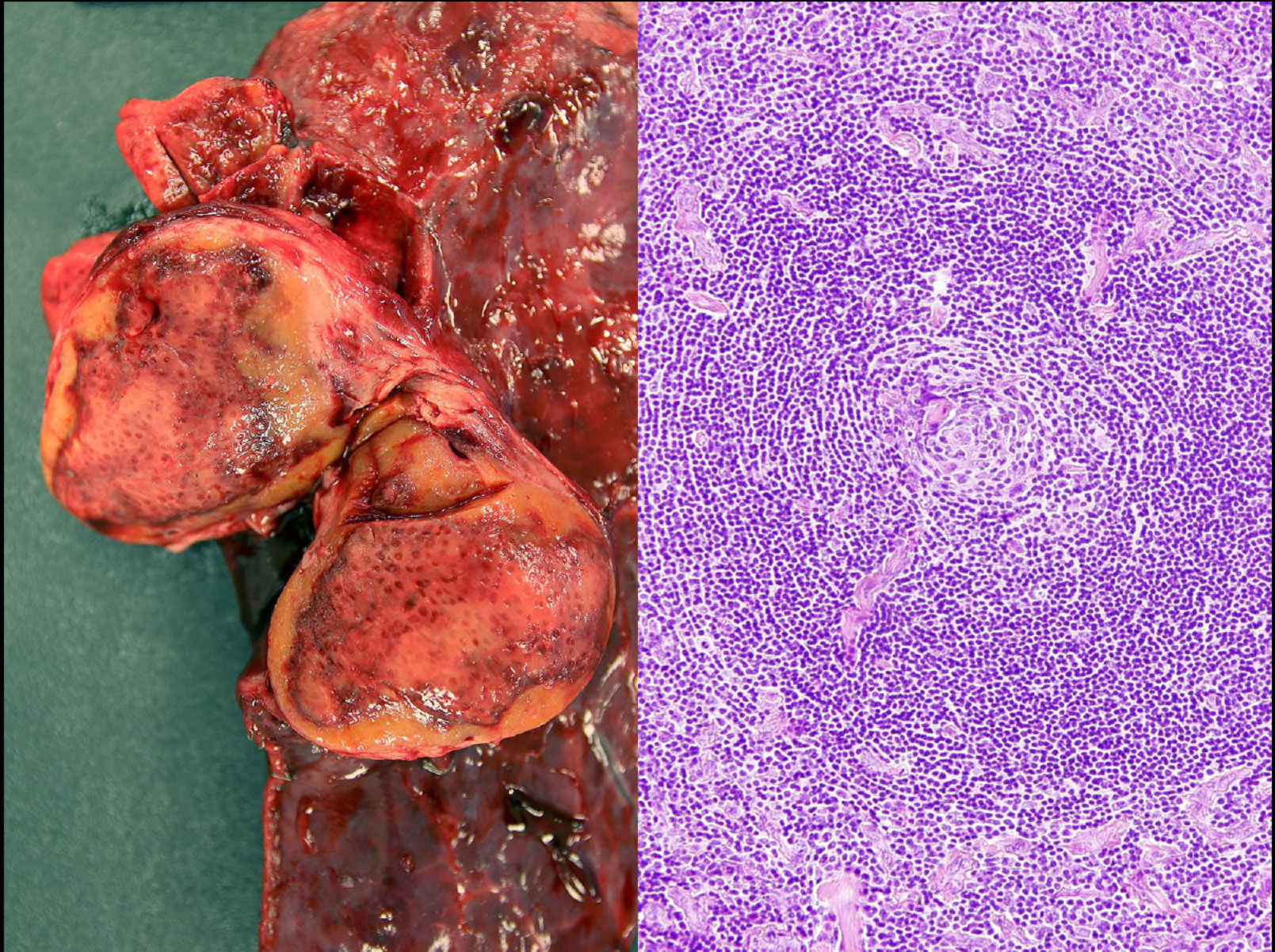


# Gross





# Typical histology

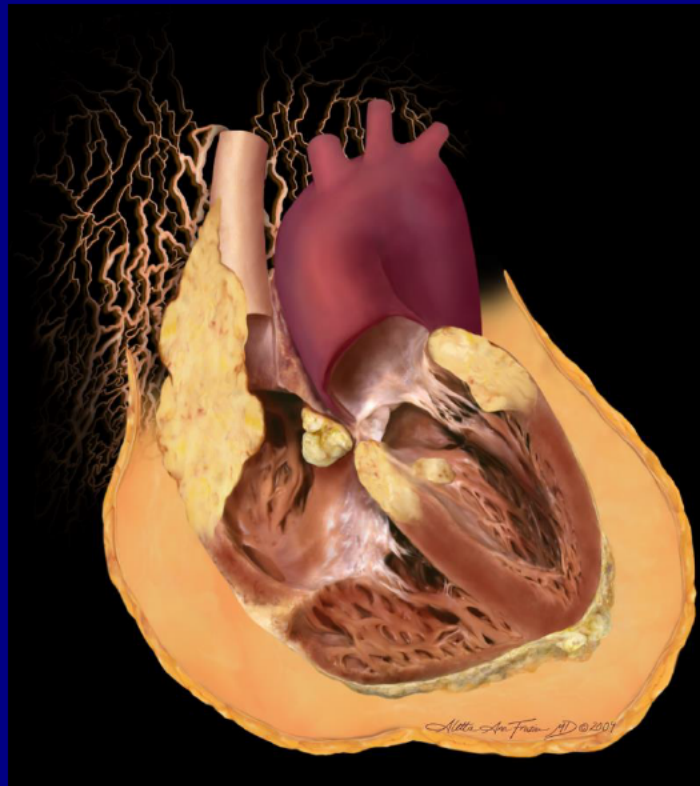

# Castleman's Disease

**Gregory Bonci, MD**  
**Brigham & Women's Hospital**  
**Boston, MA**



# Cardiovascular Best Case



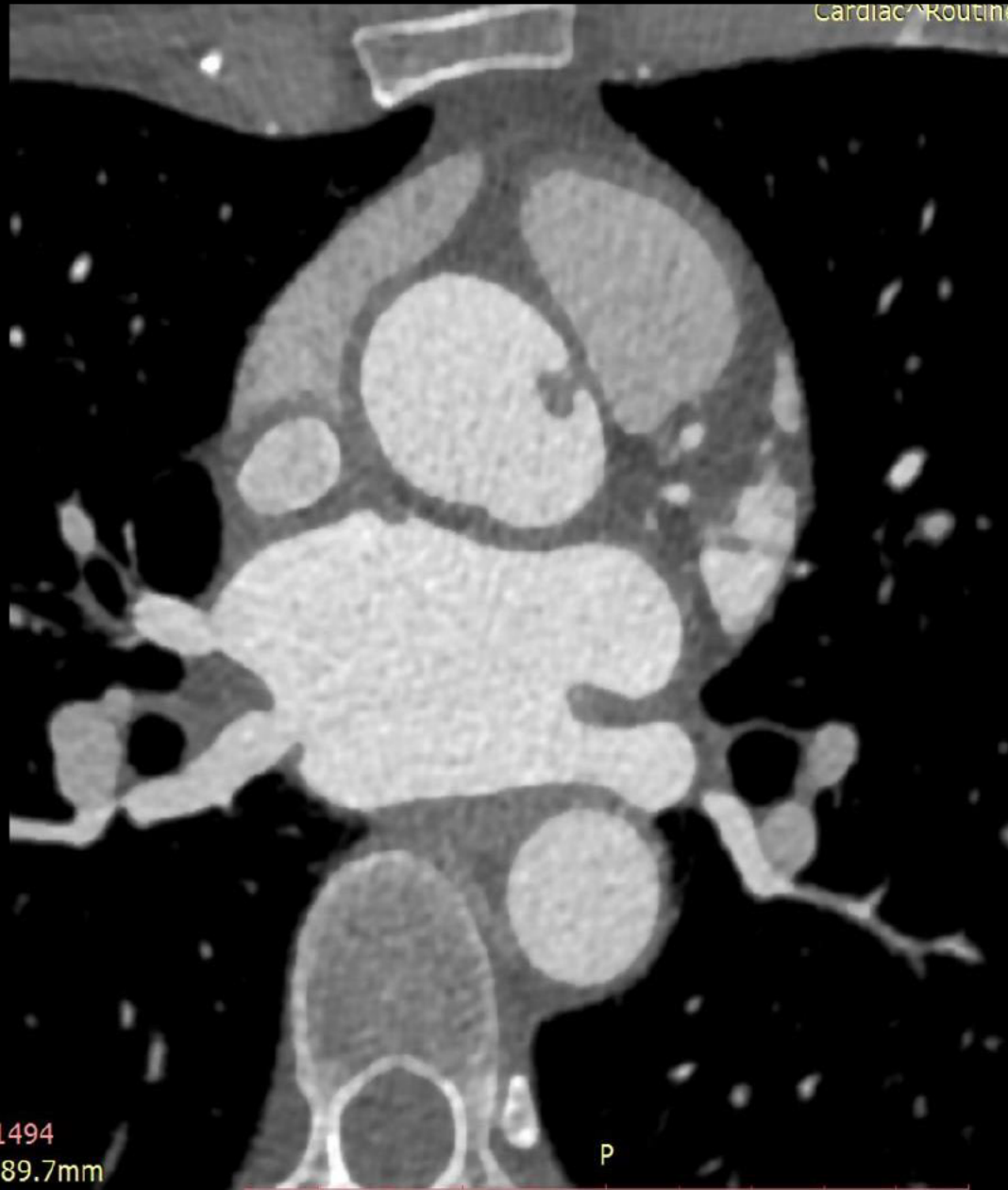
## Clinical Information

**48 year old female presents to ER with a  
pre-syncopal episode**

Cardiac Routine

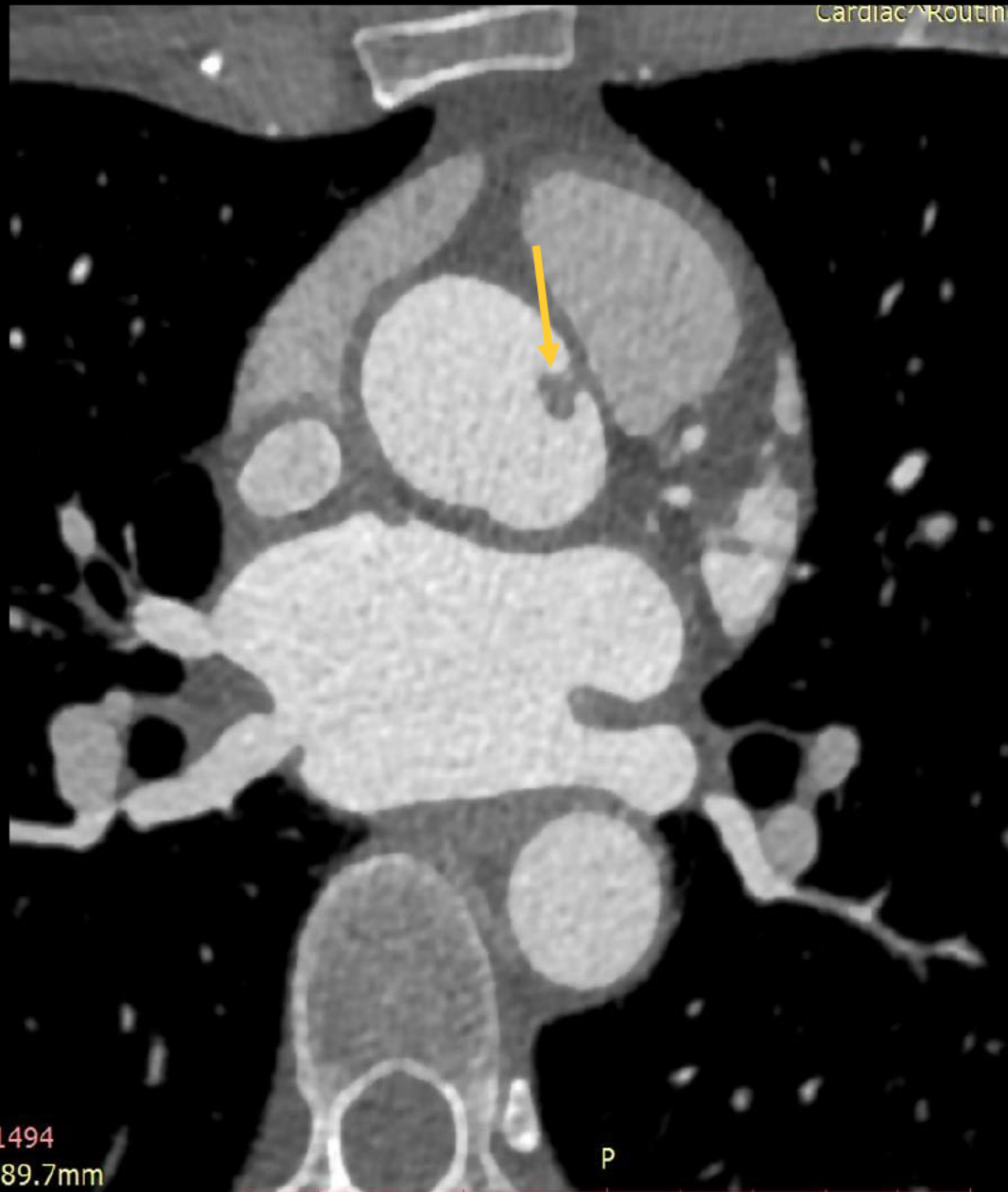
W: 1494  
.: -189.7mm

P



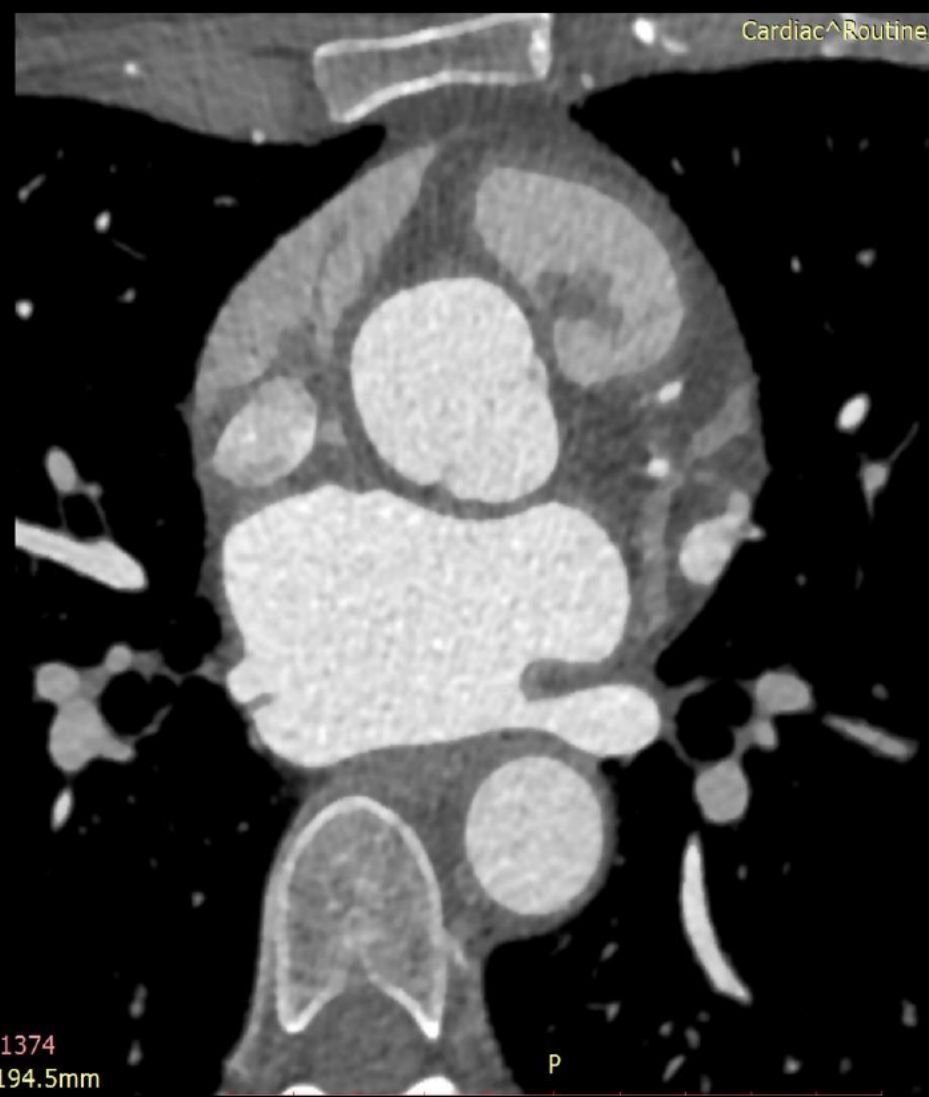
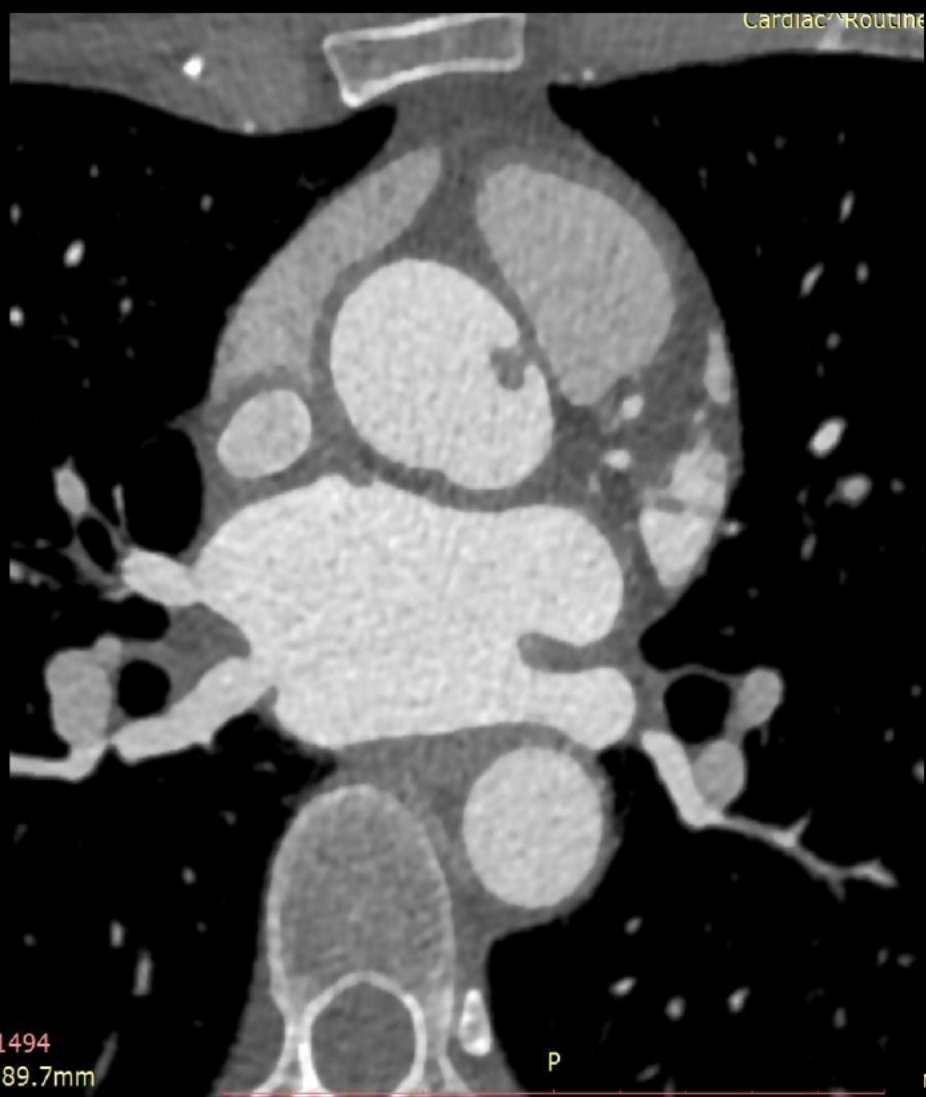


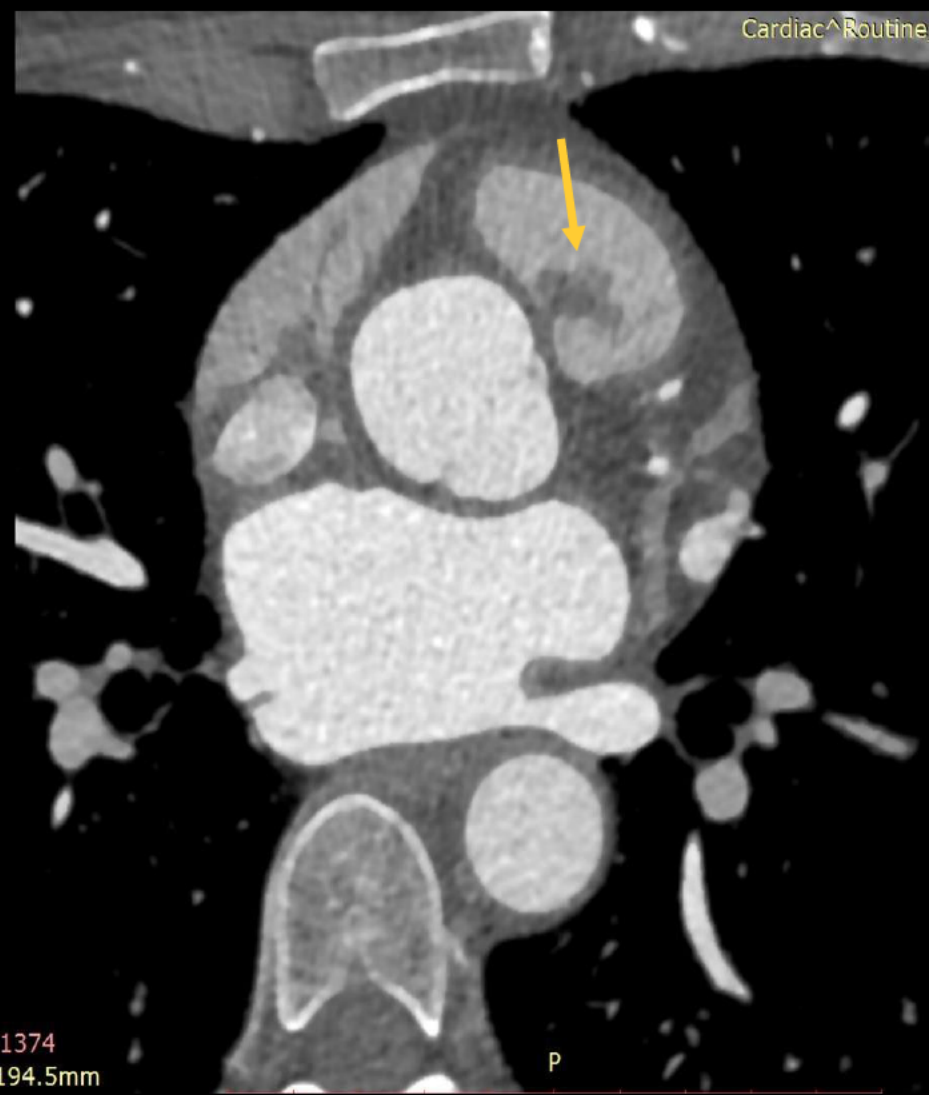
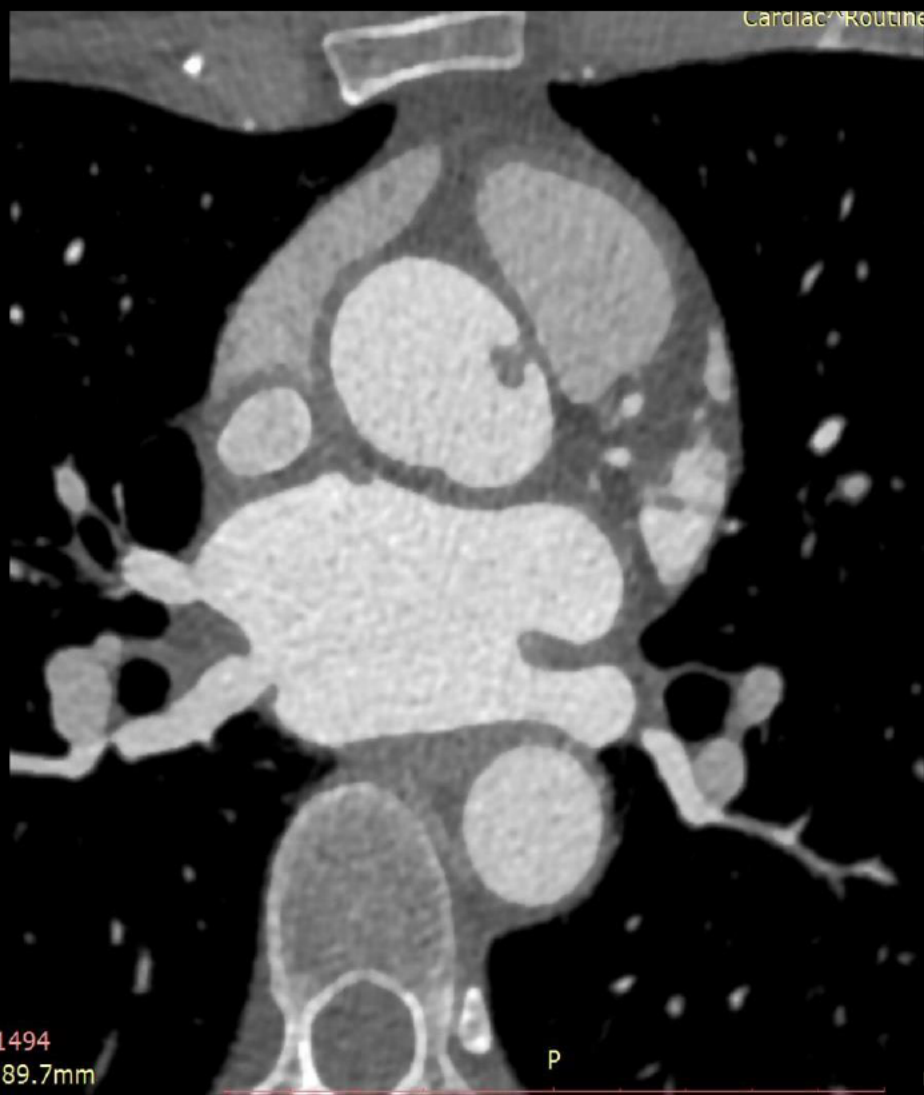
Cardiac Routine



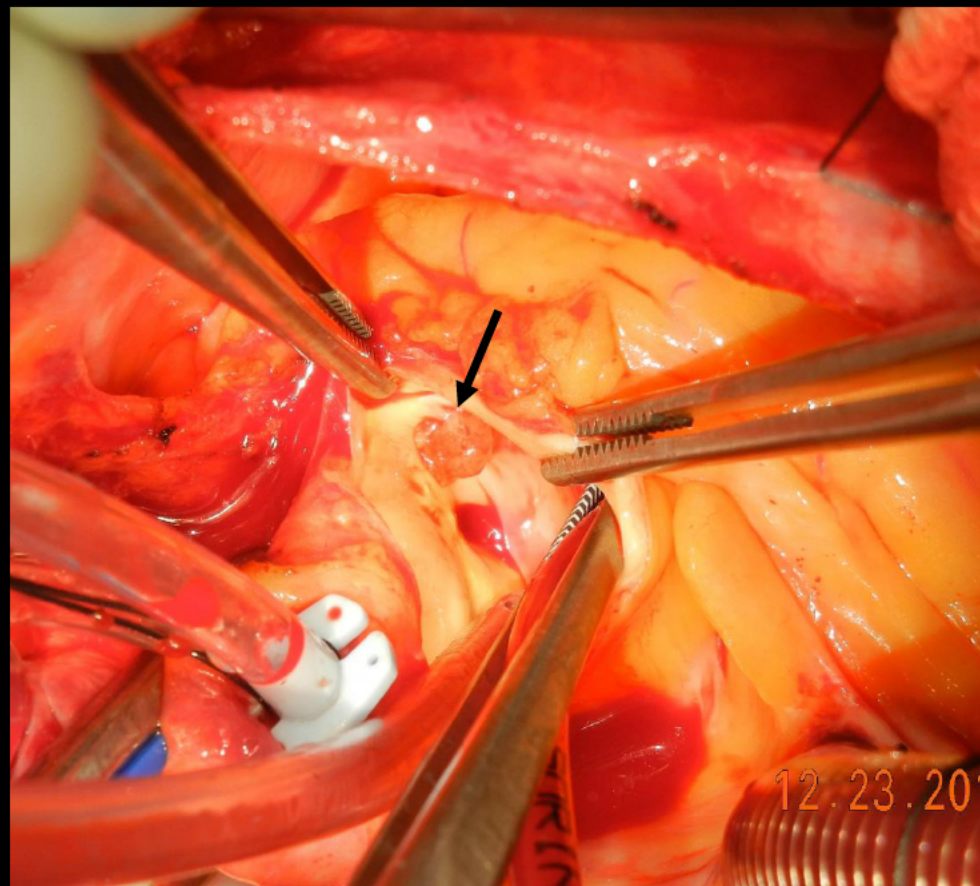
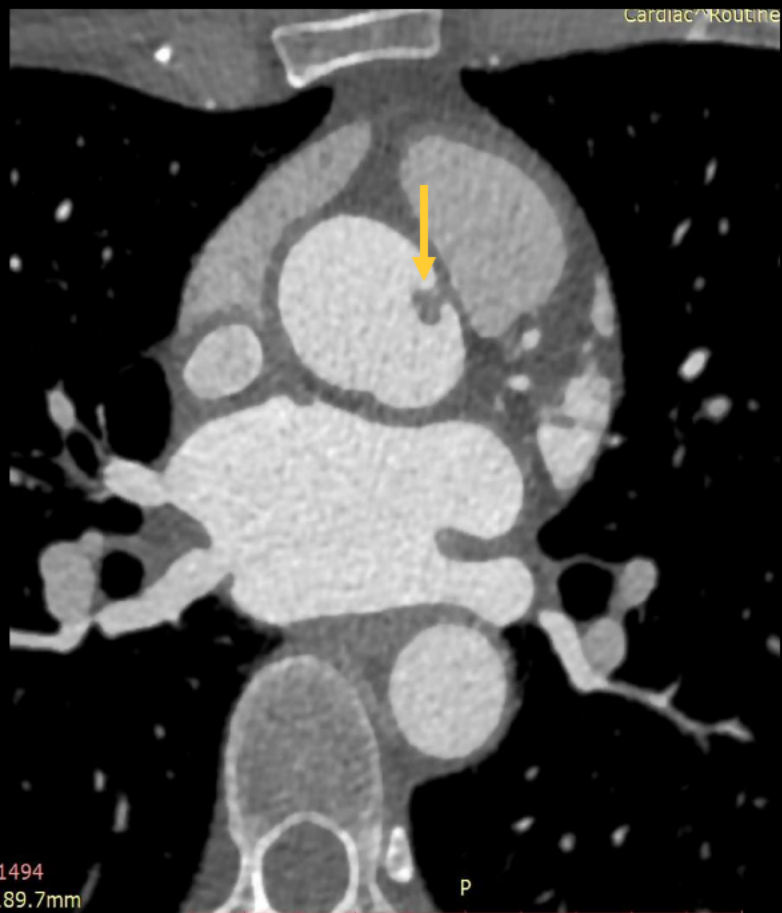W: 1494  
.: -189.7mm

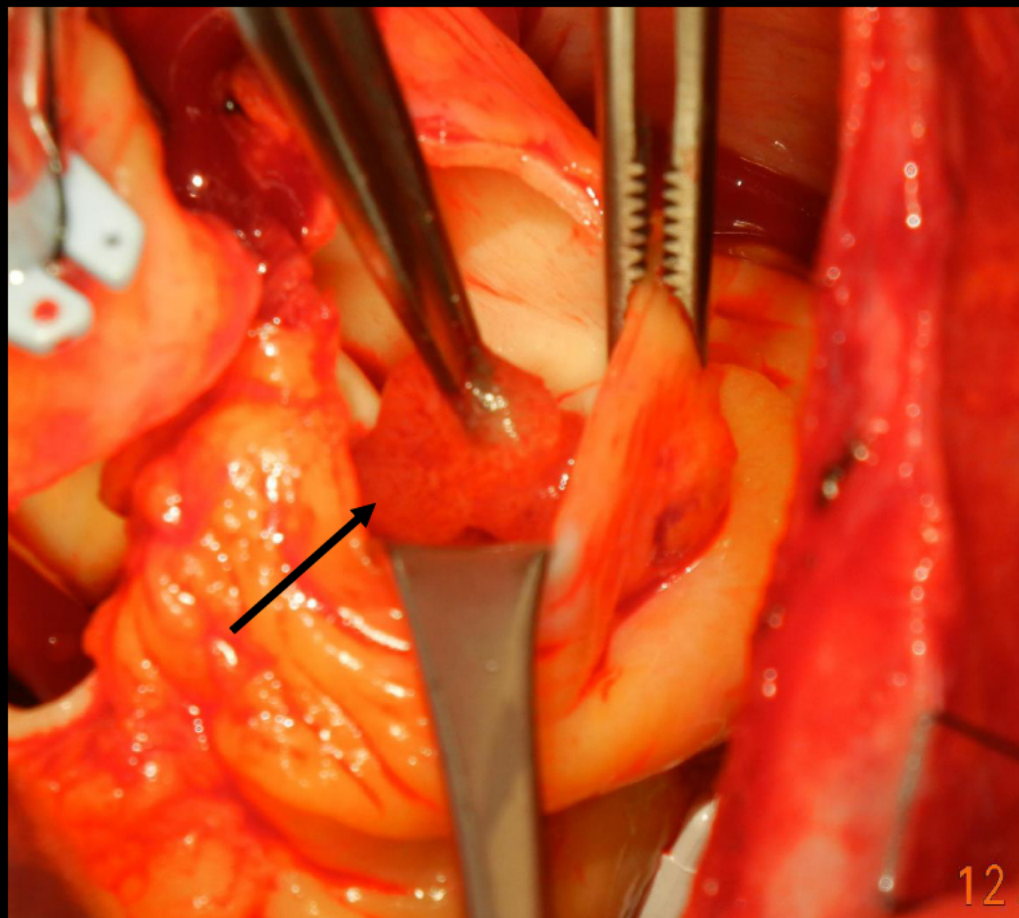
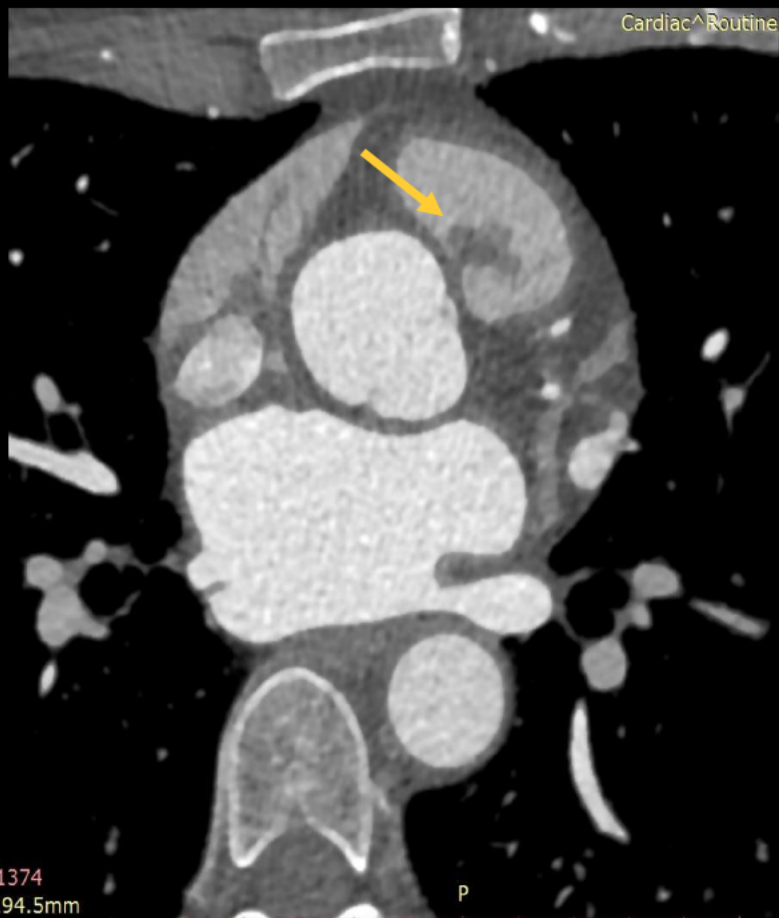P

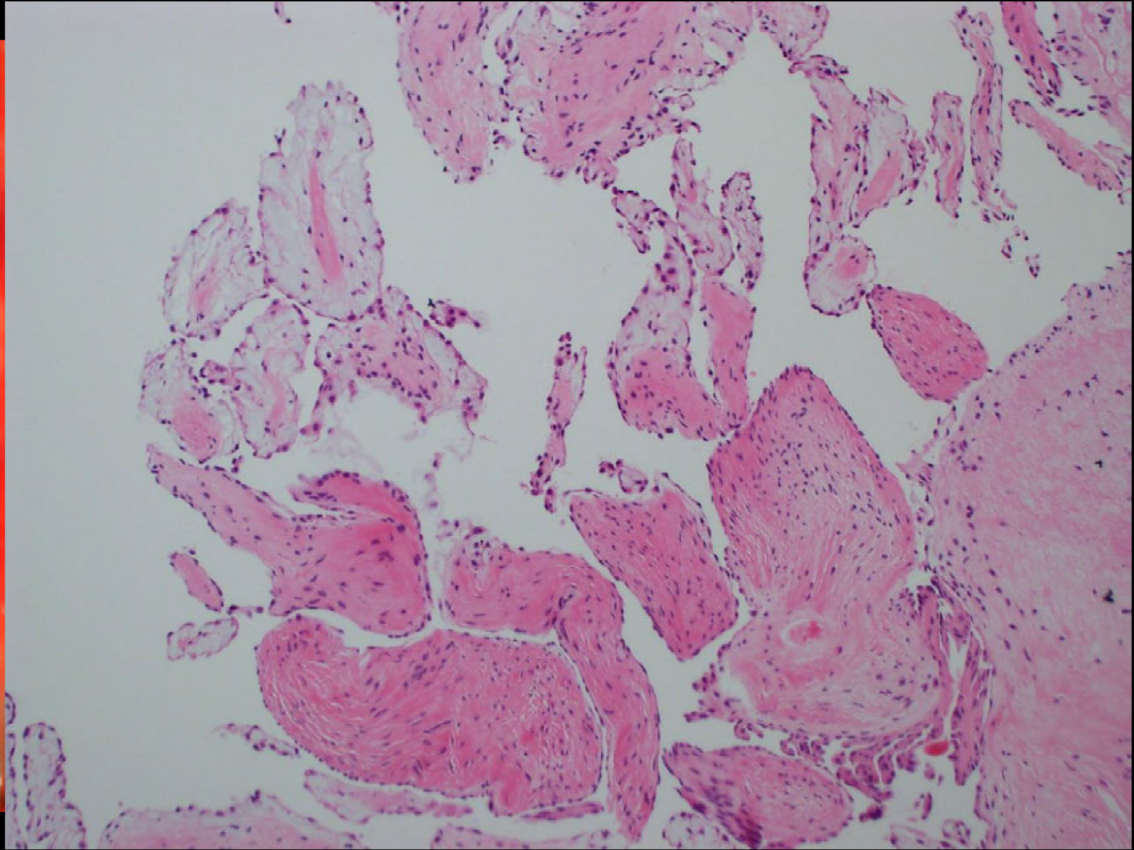
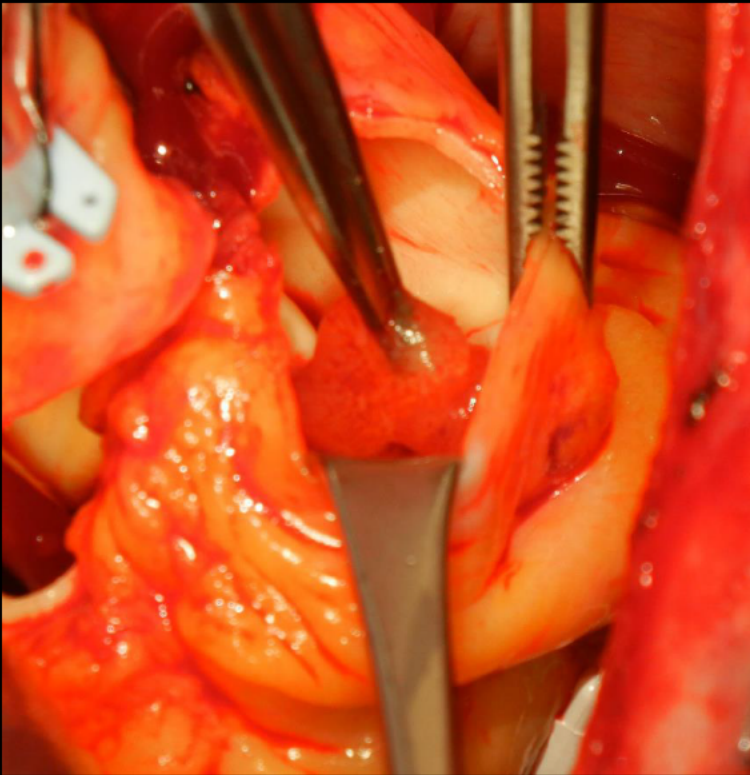




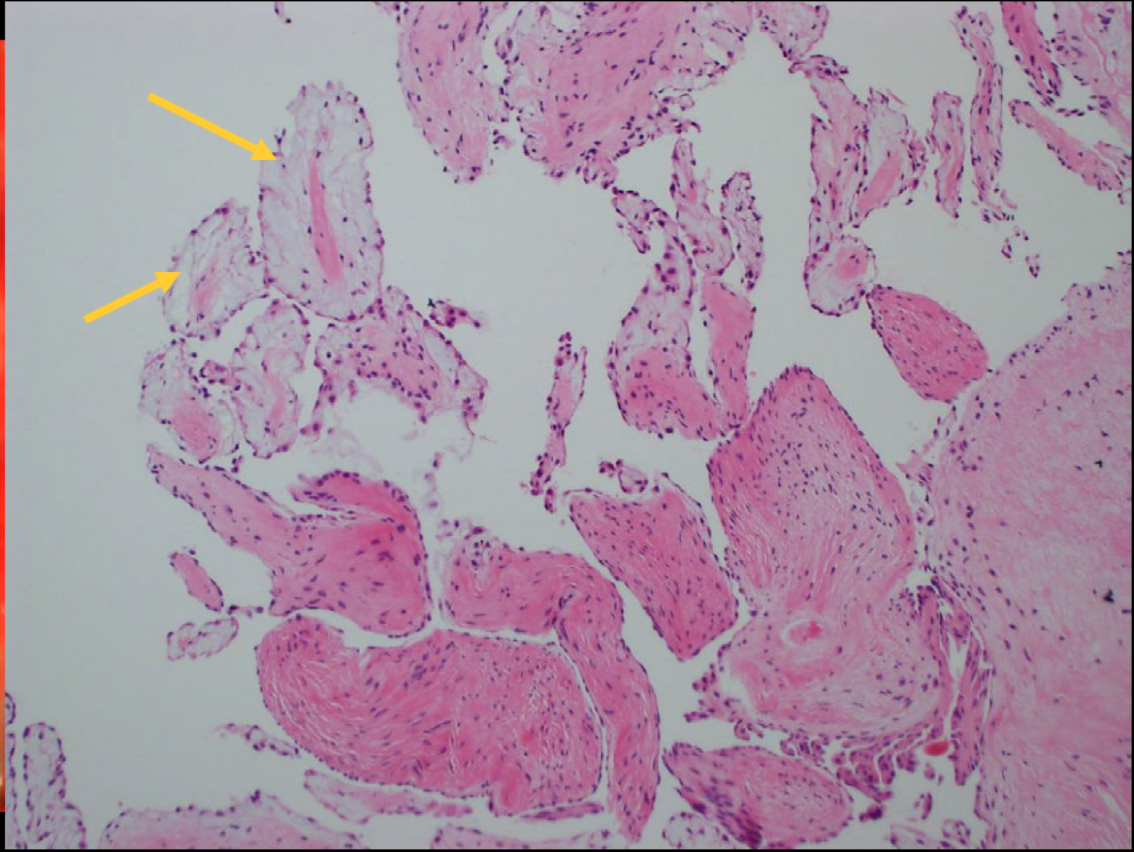
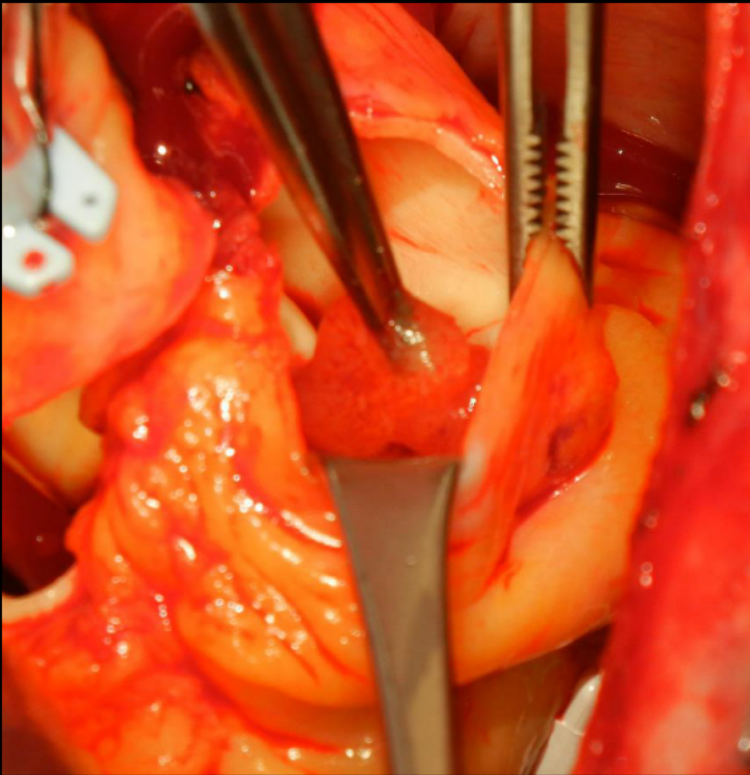


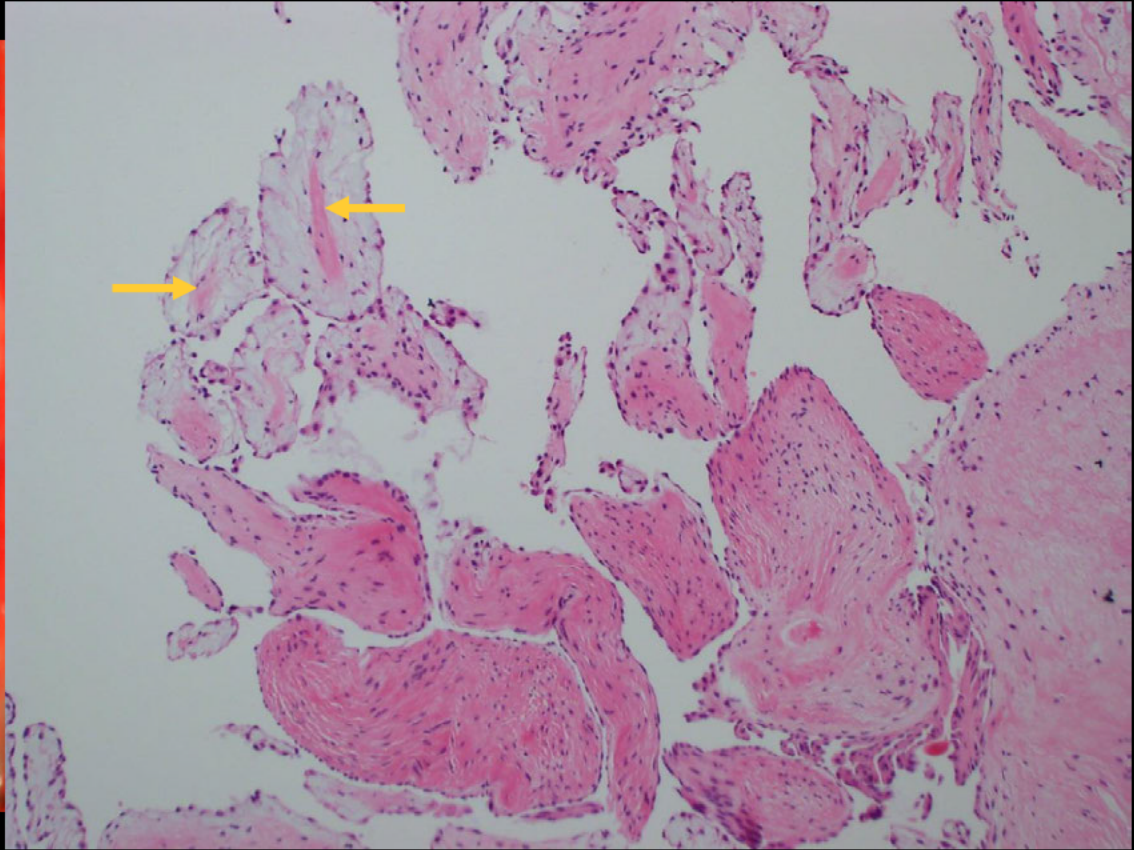
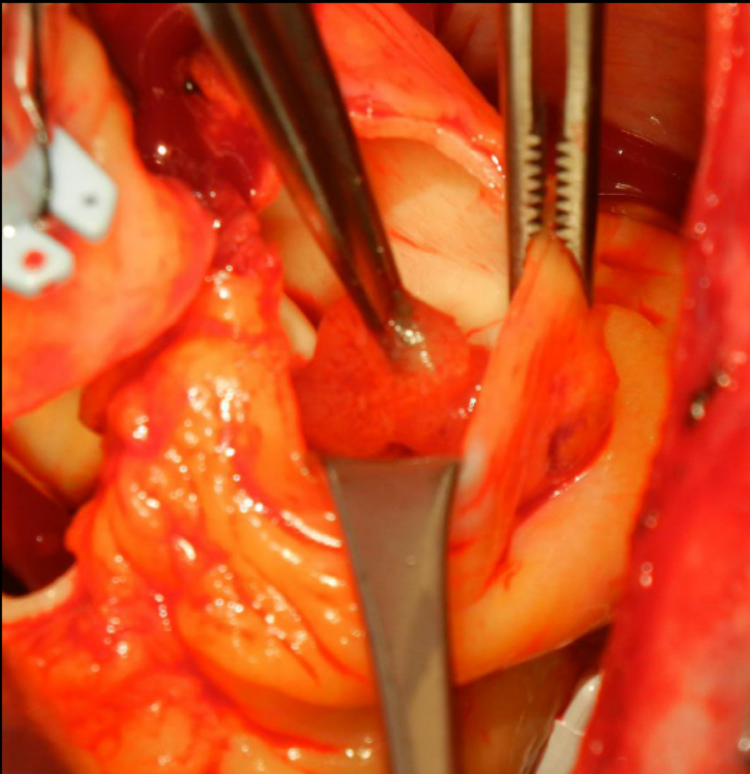










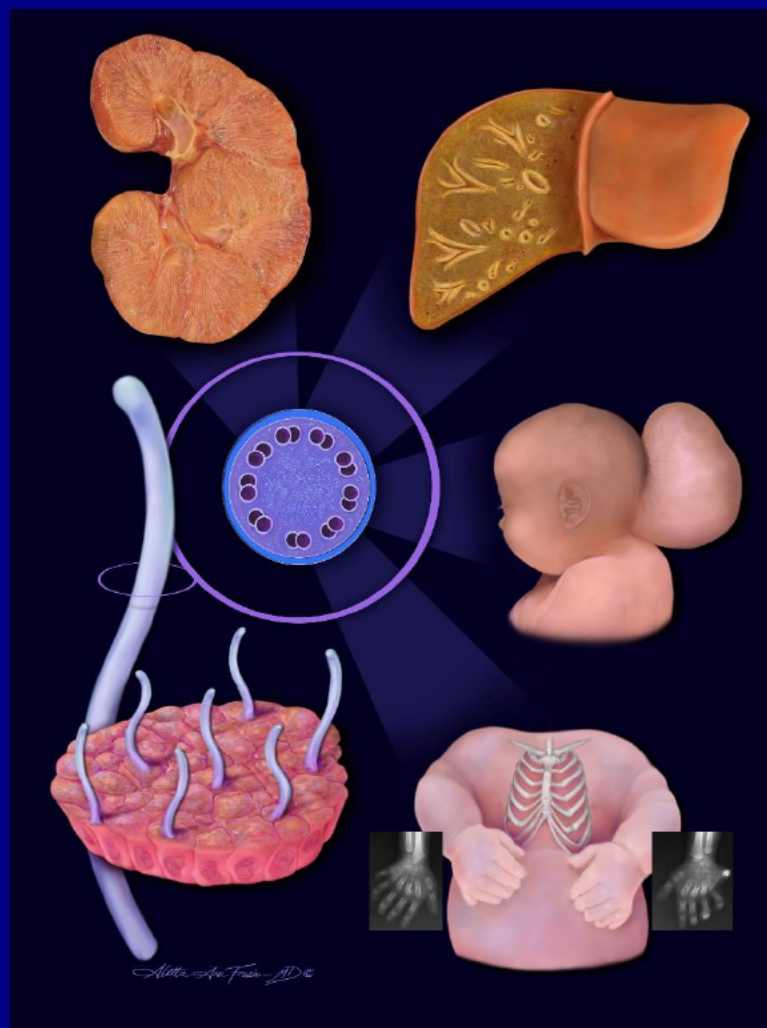


# Papillary Fibroelastomas

**Yanki Tumer, MD**  
**Northwestern University**  
**Chicago, Illinois**

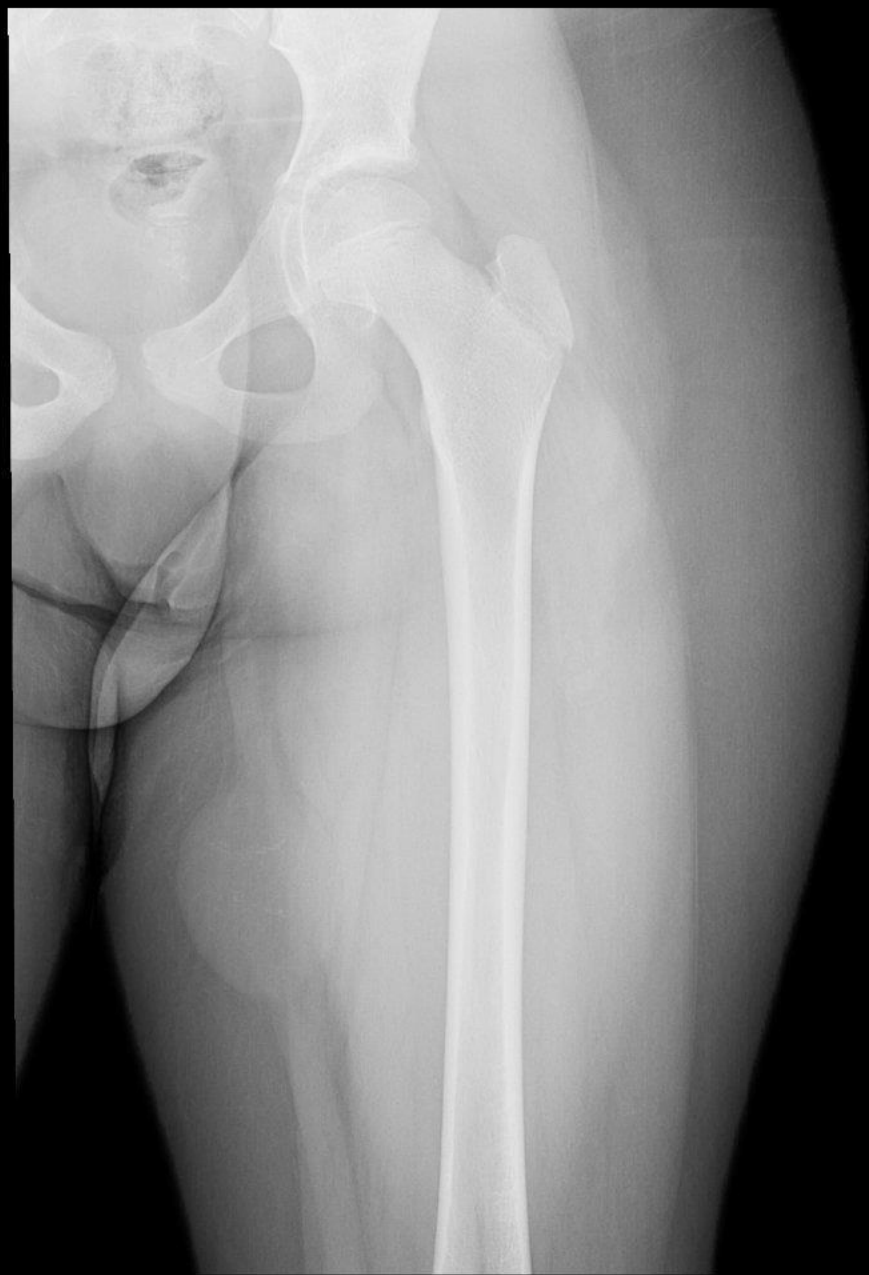

# Pediatric Best Case

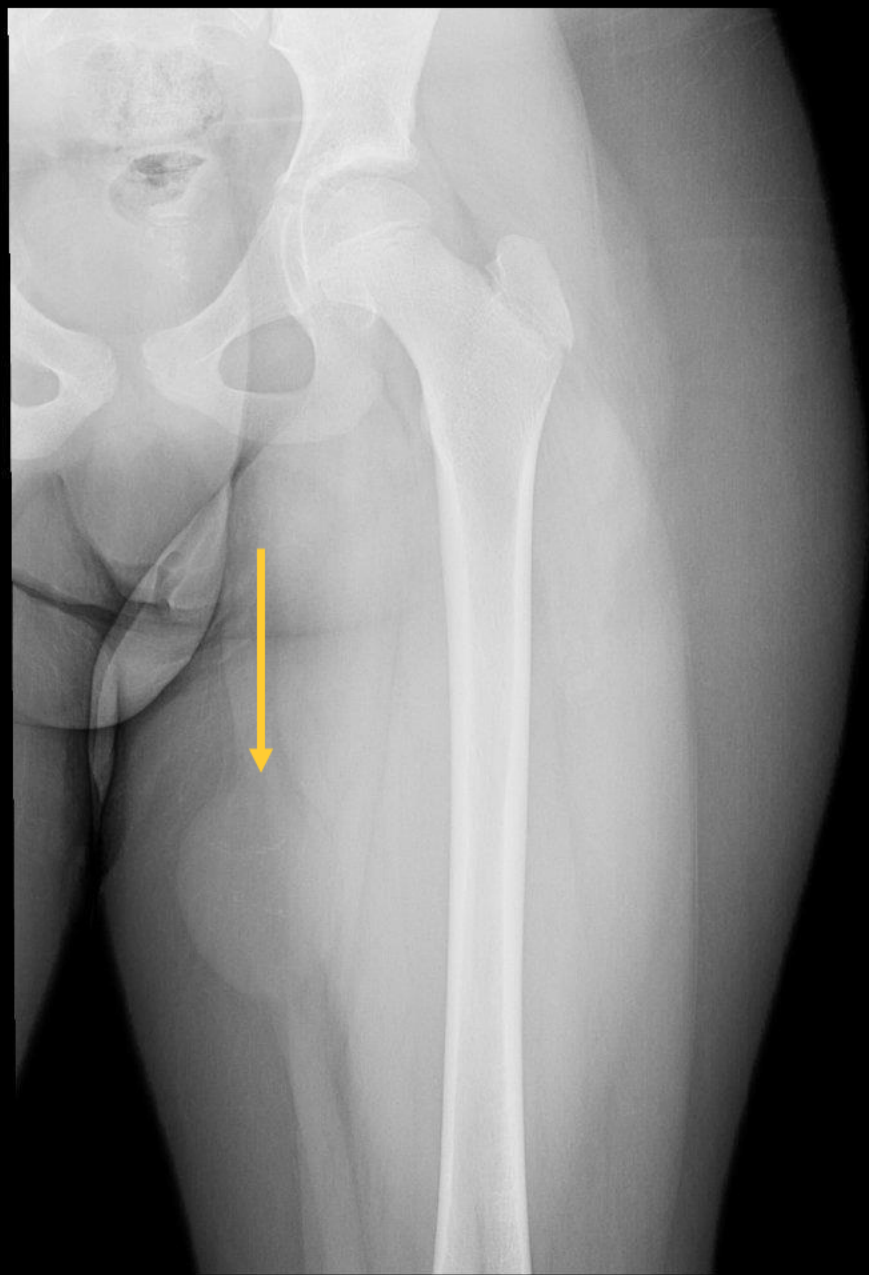


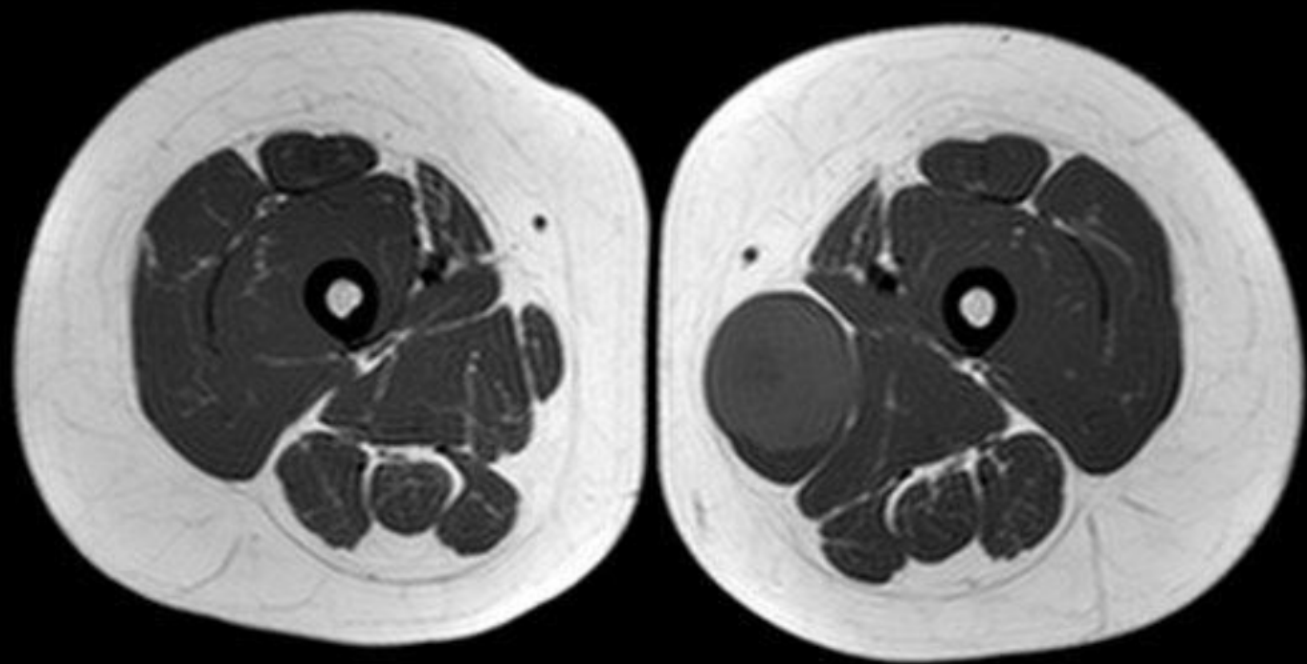
# Clinical Information

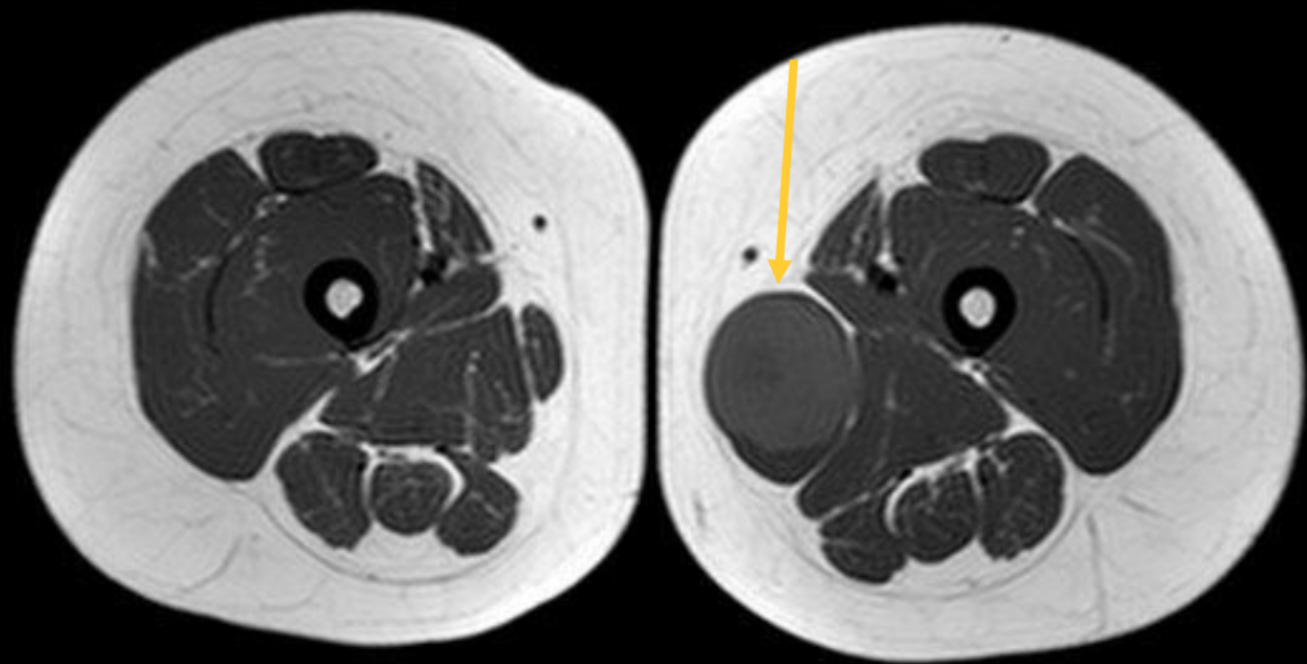
**9-year-old female who presented with a painless soft-tissue mass of left medial proximal thigh noticed suddenly by the patient herself 2 weeks prior**



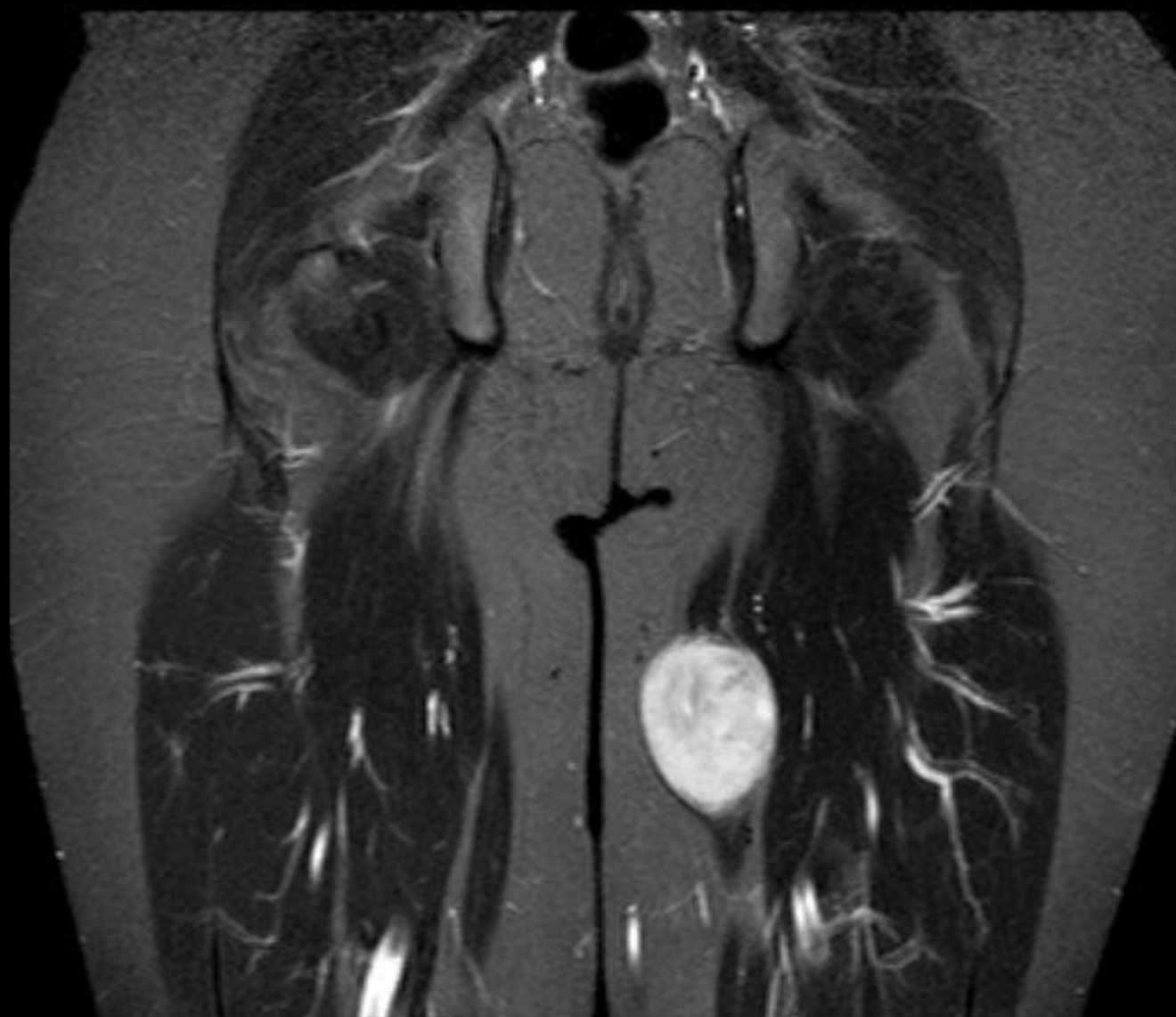


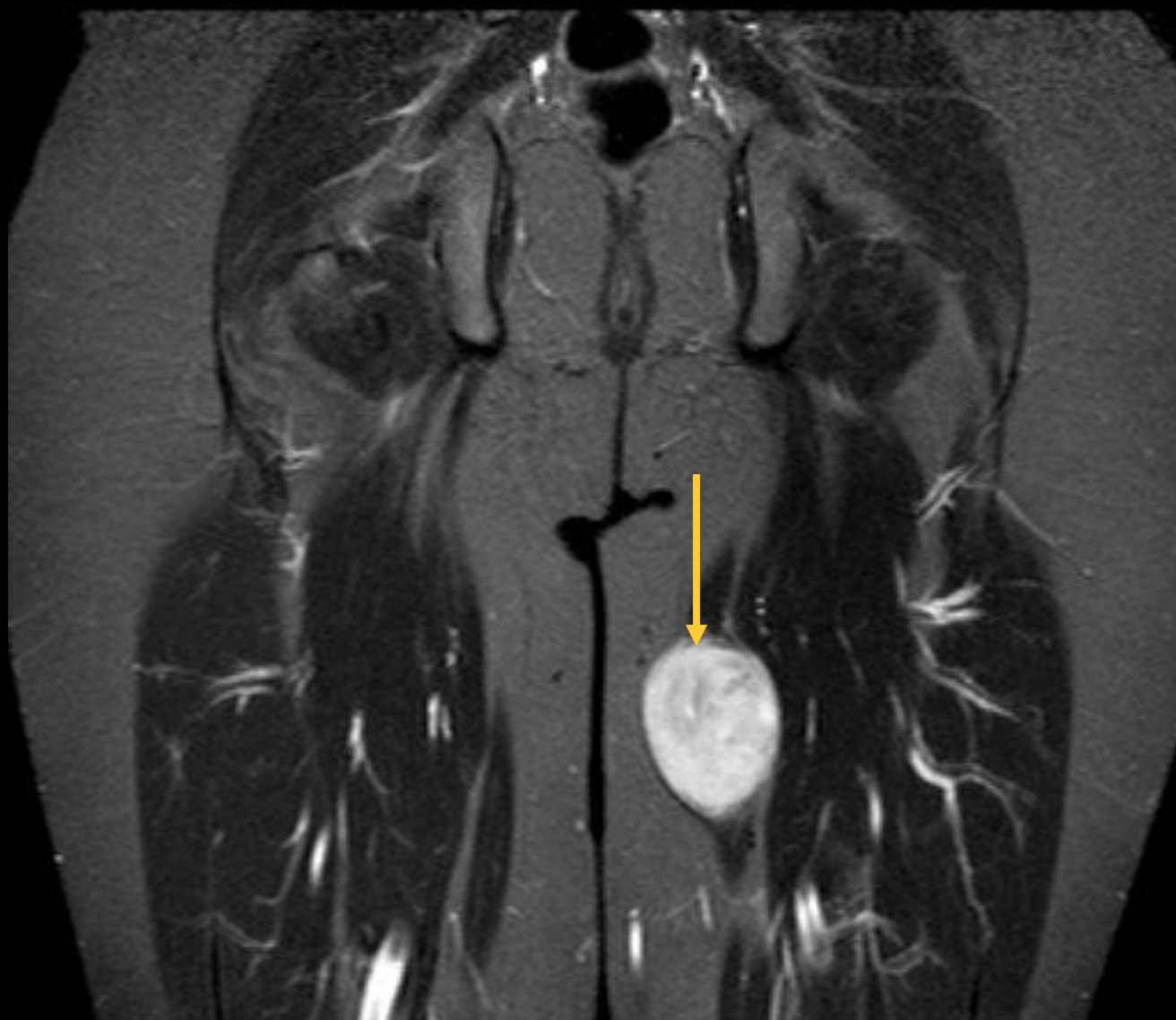
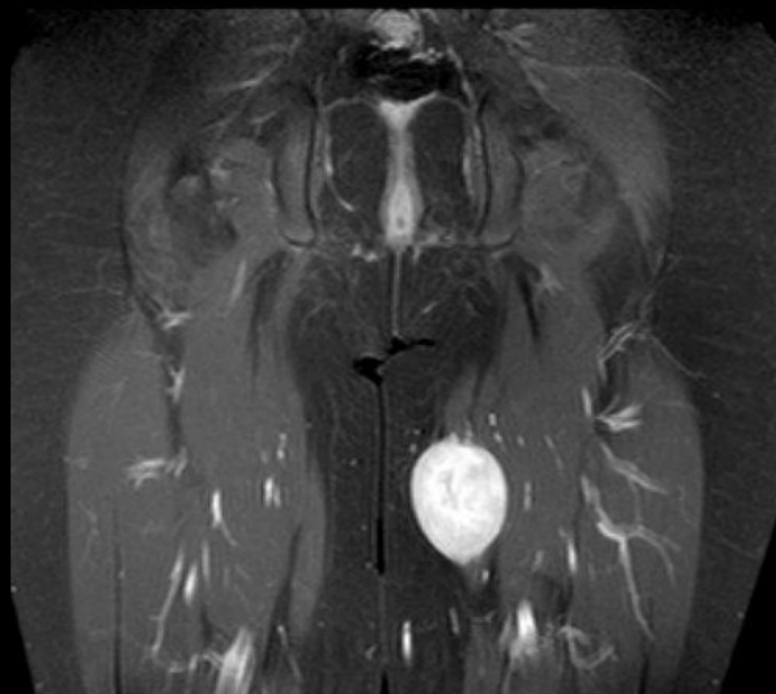


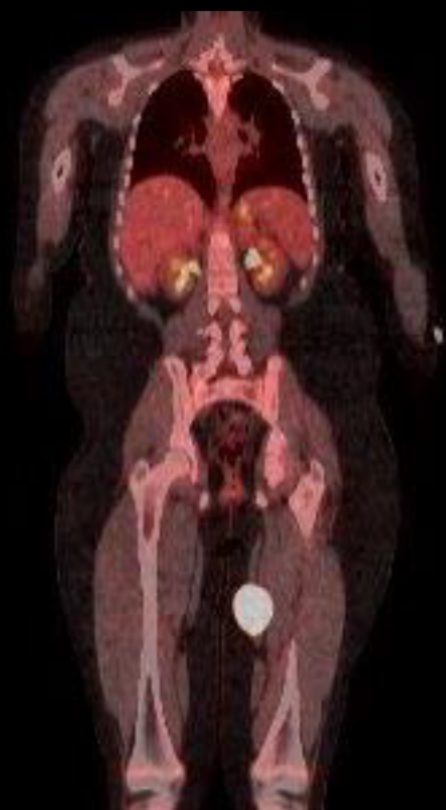

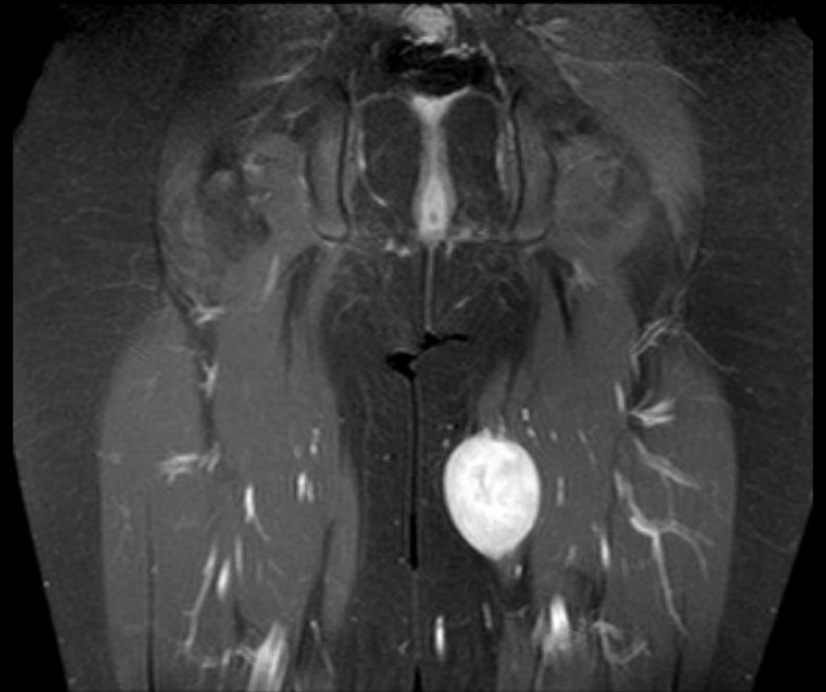
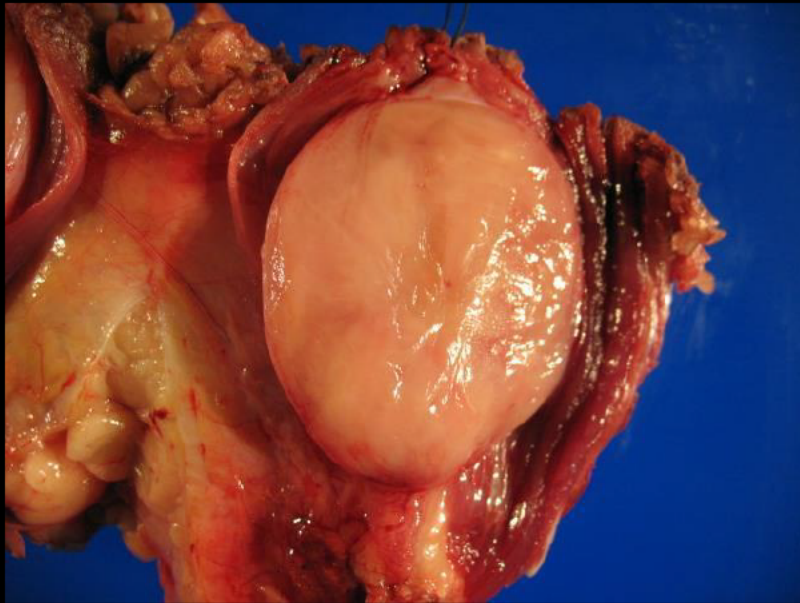








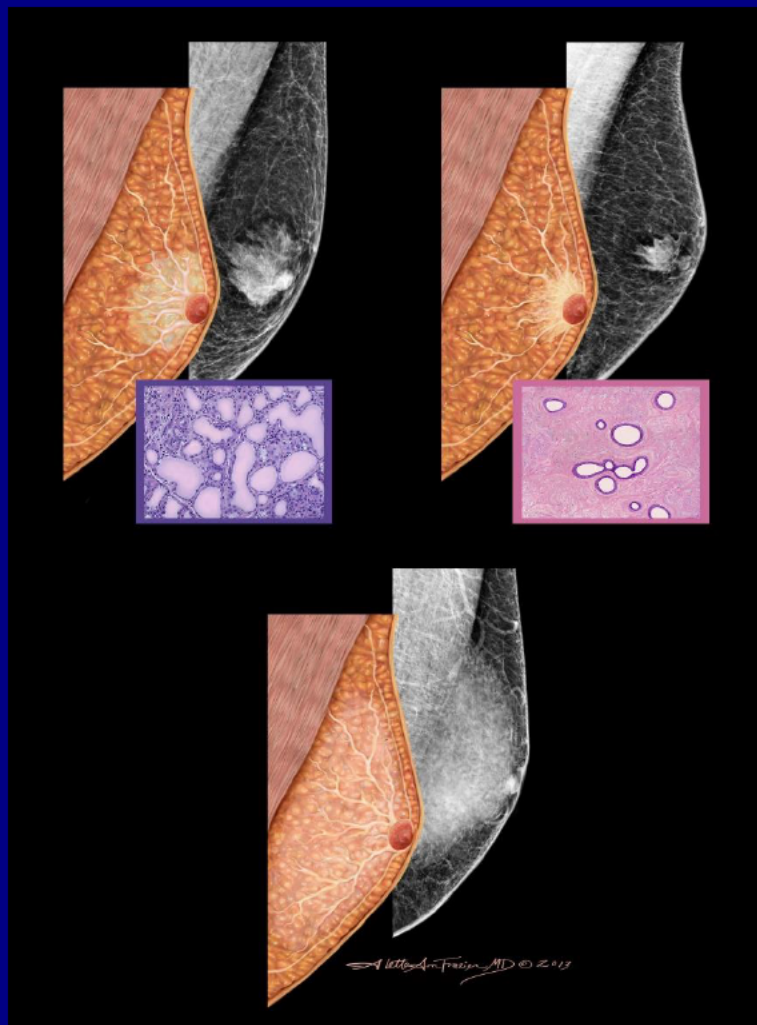




# Inflammatory Myofibroblastic Tumor

**Mujtaba Mohammed, MD**  
**SUNY Upstate**  
**Syracuse, New York**

# Breast Best Case

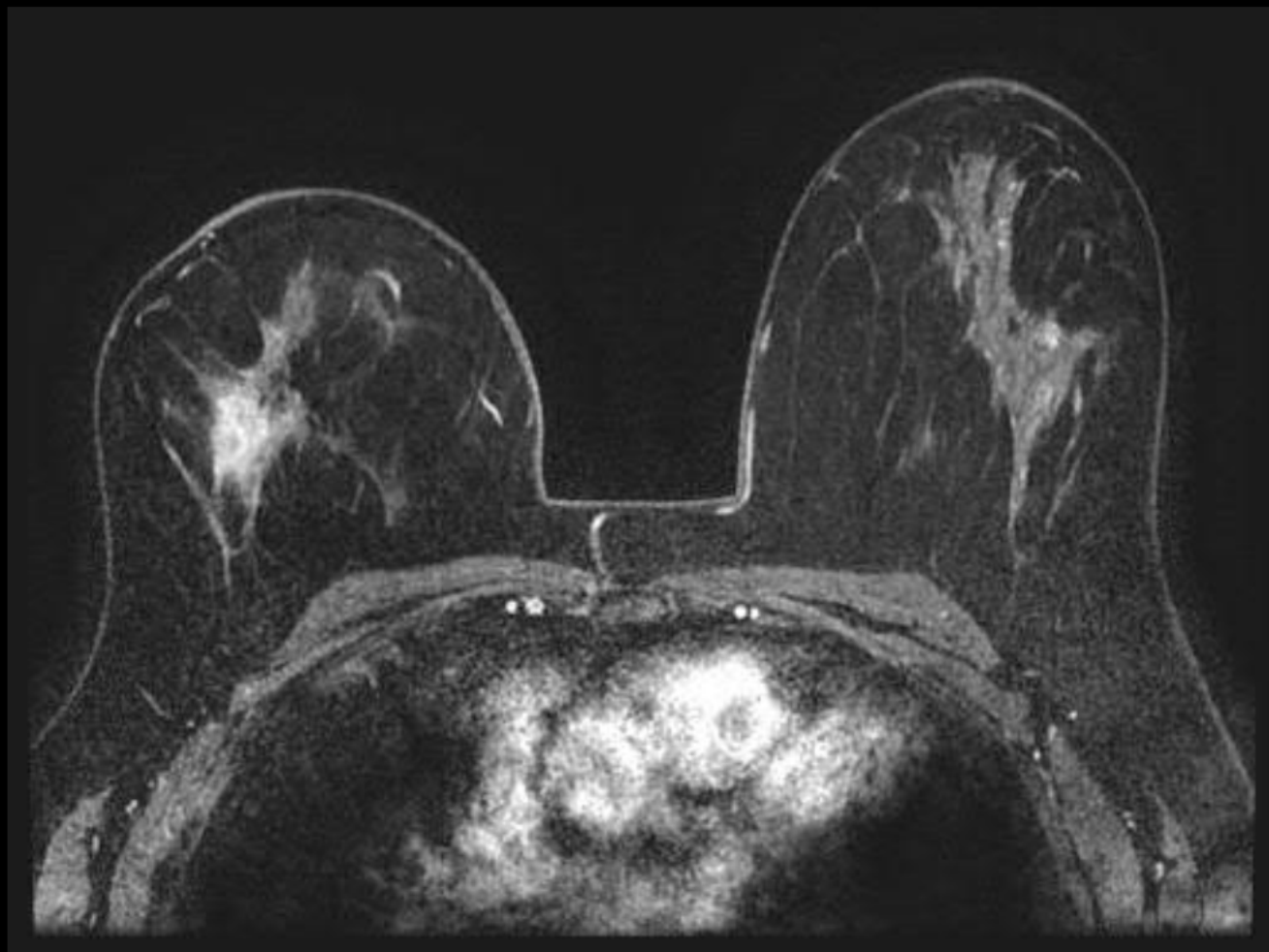




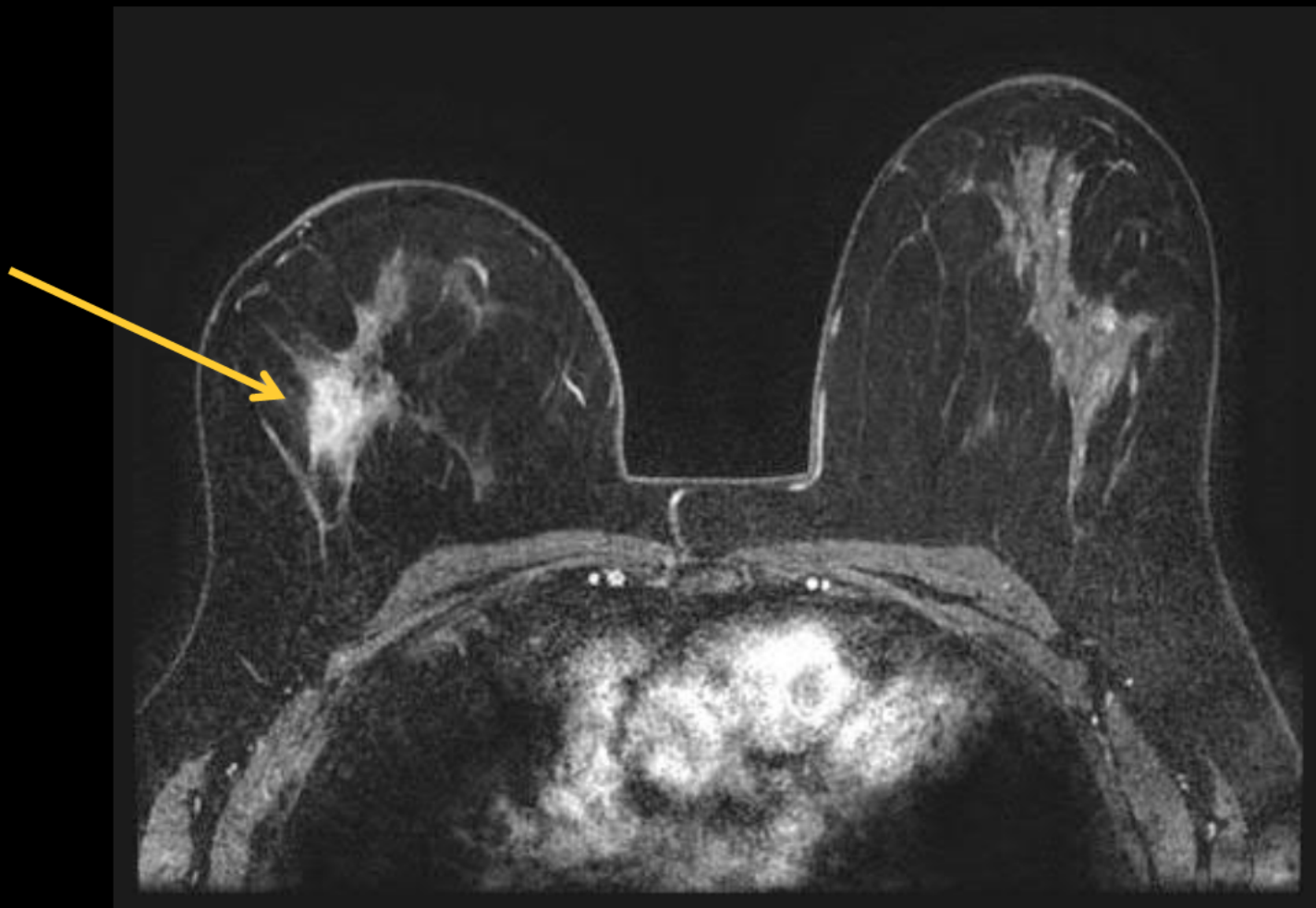## Clinical Information

**40 yo female with palpable lump in the right breast.  
Prior right lumpectomy for invasive ductal  
carcinoma 10 years ago treated with  
chemotherapy and radiation therapy.**

# Breast MRI

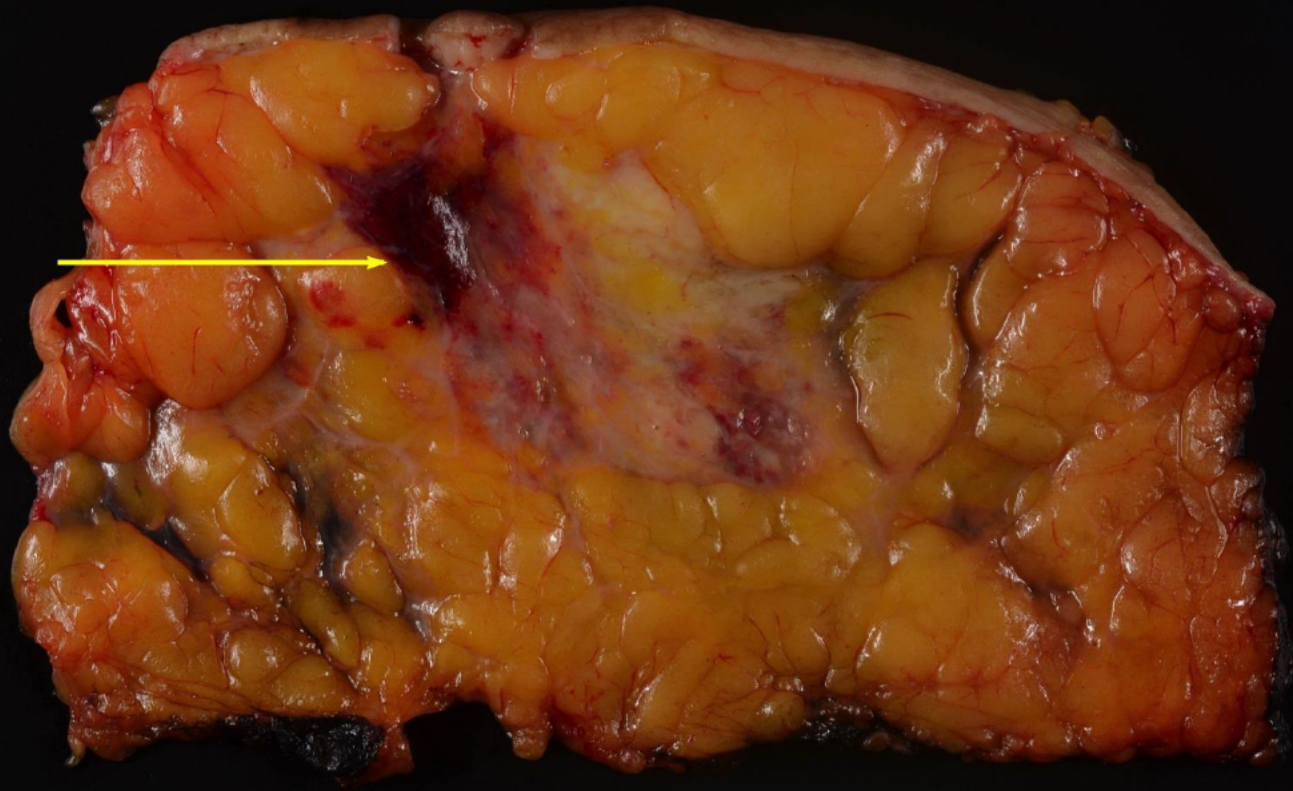


# Breast MRI

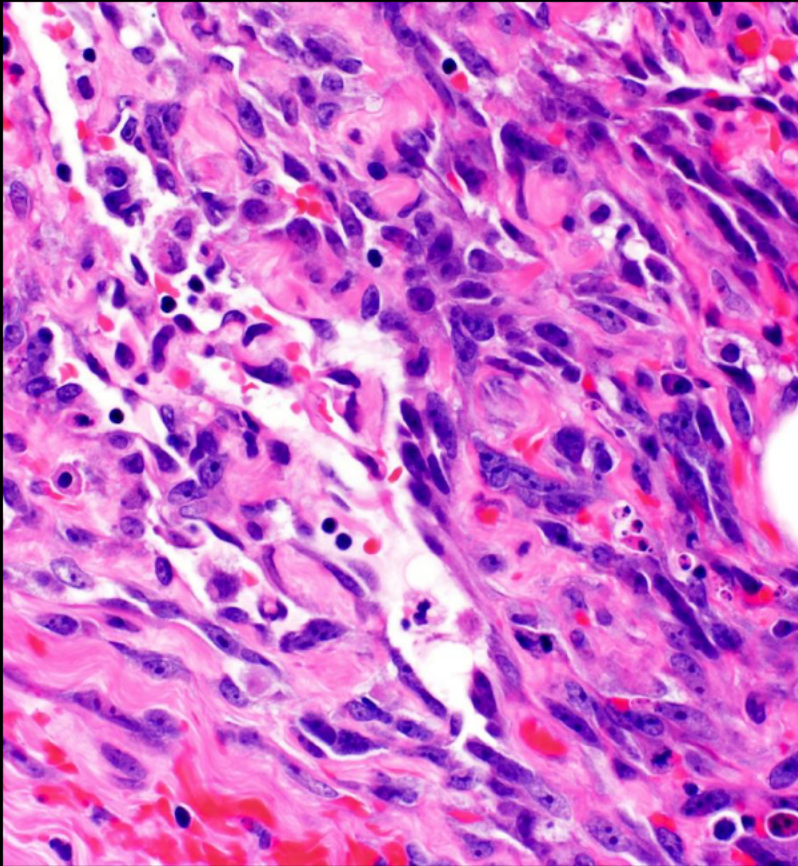




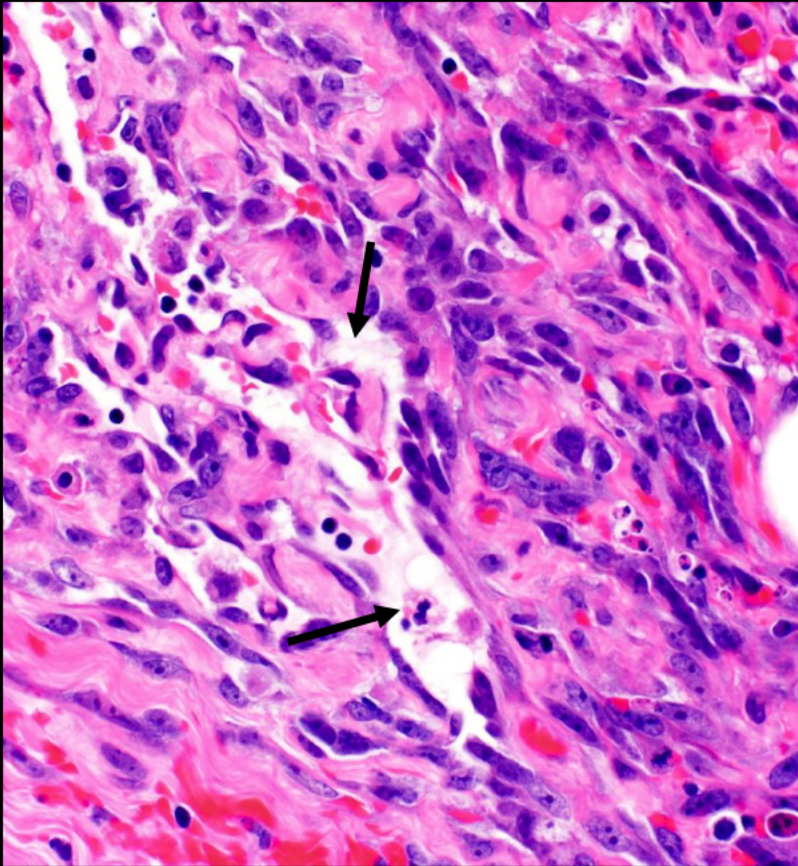
# Gross



# Histology

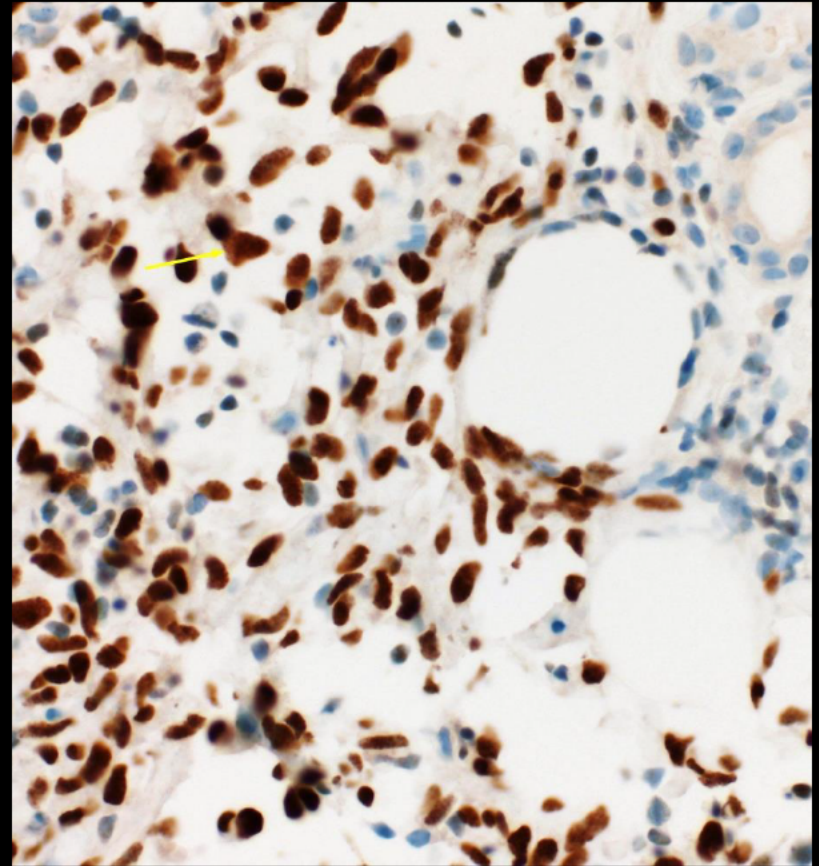
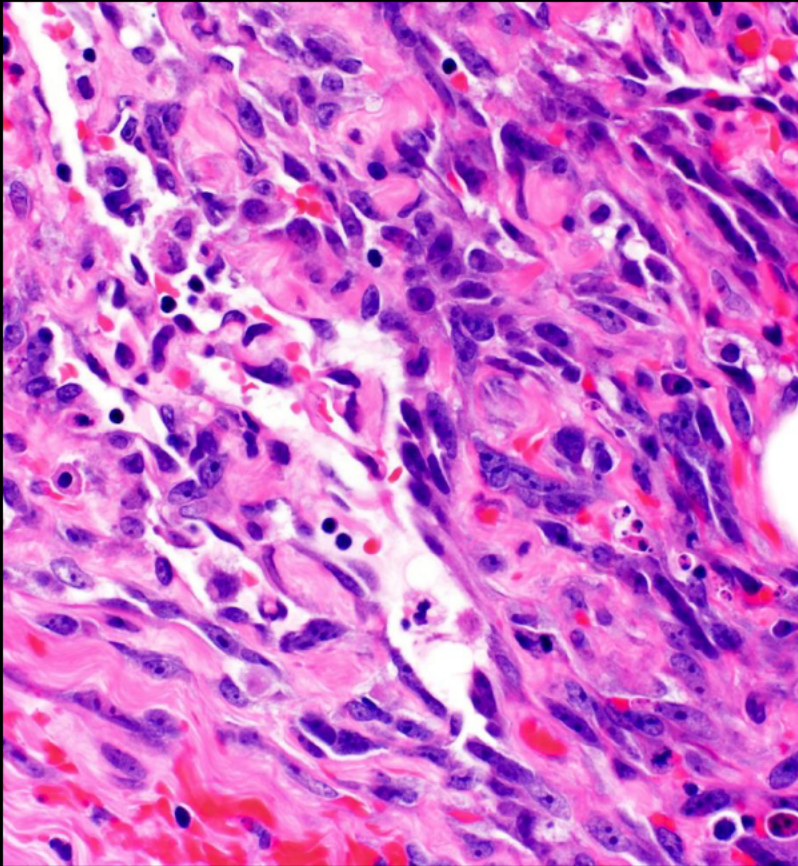


# Histology





# Histology



# Angiosarcoma

**Chris Gu, MD**  
**Mayo Medical Center**  
**Rochester, MI**

**Many thanks to all of you for  
submitting such great cases!**

**From the staff of the  
American Institute for Radiologic Pathology**