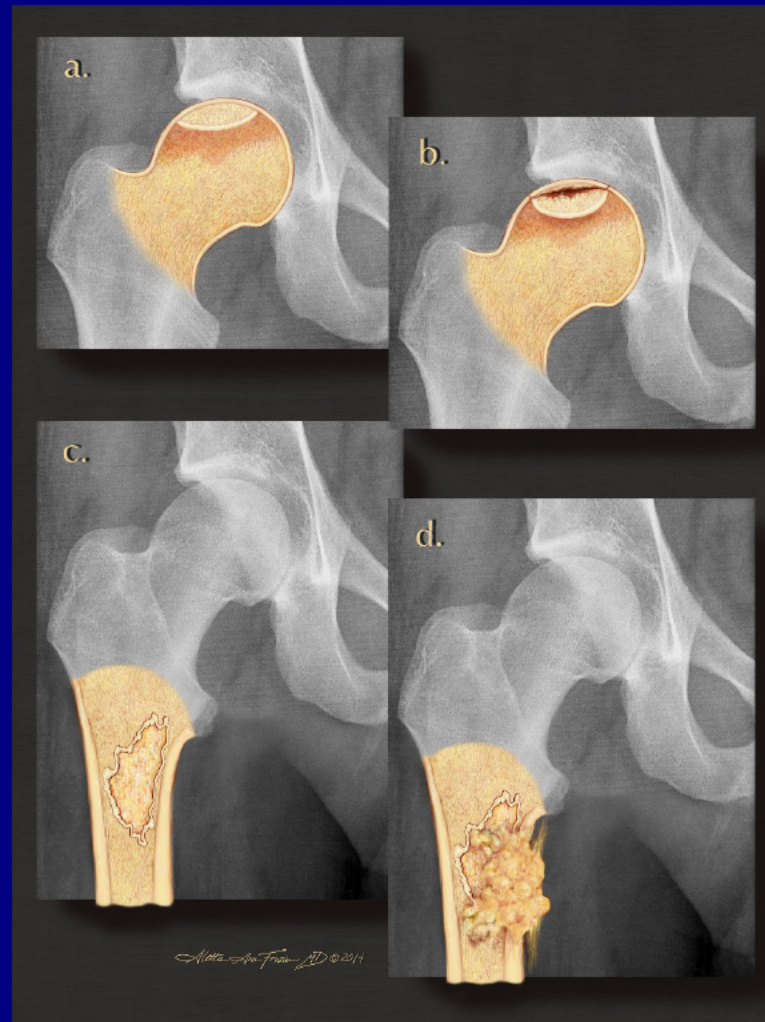


Best Cases of the AIRP

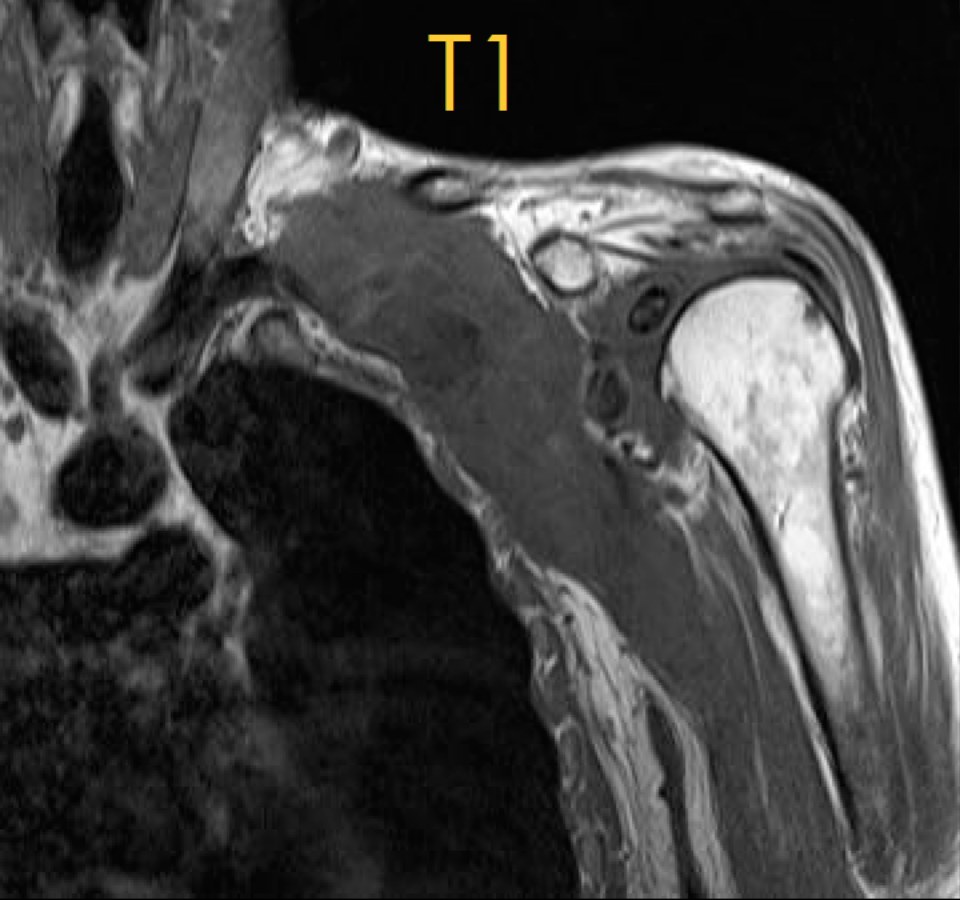Feb-March, 2017

Musculoskeletal Best Case

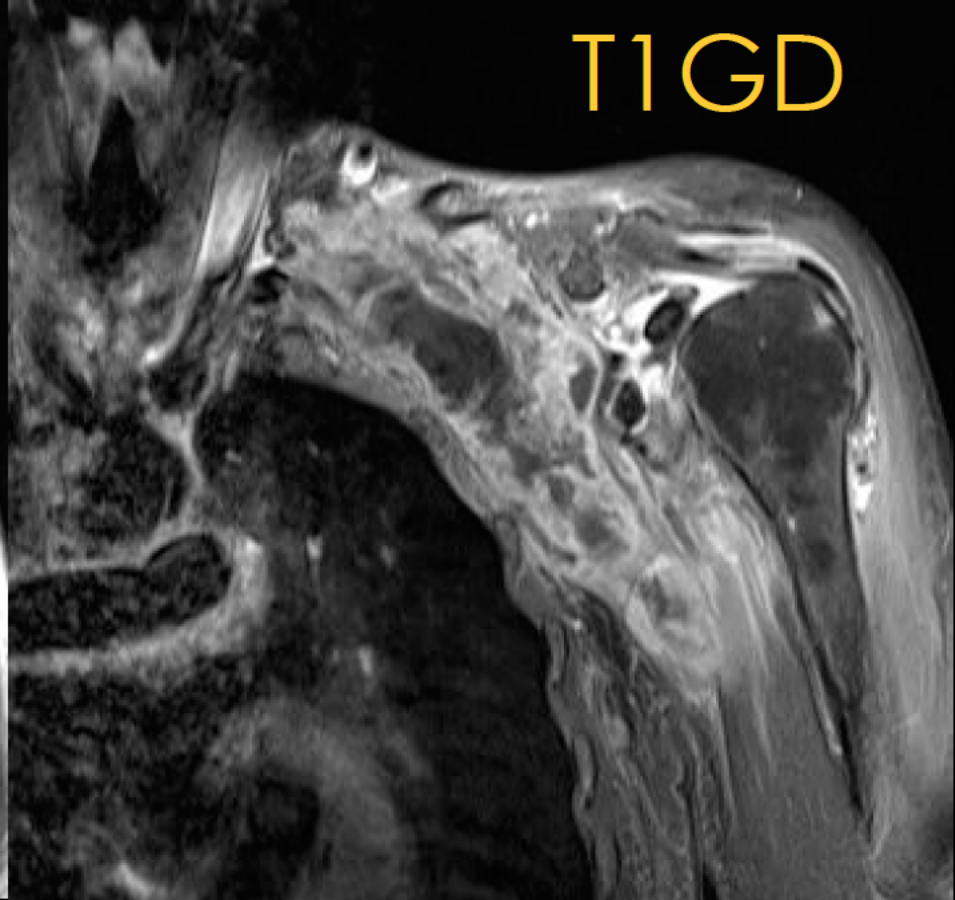


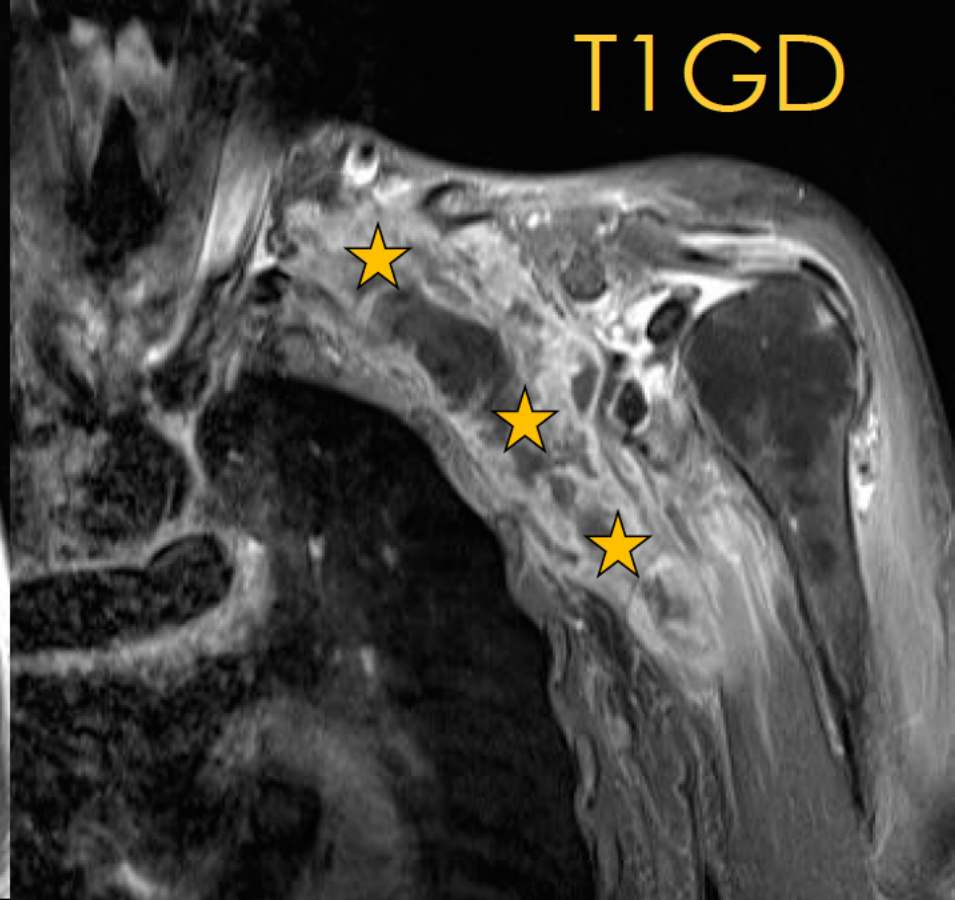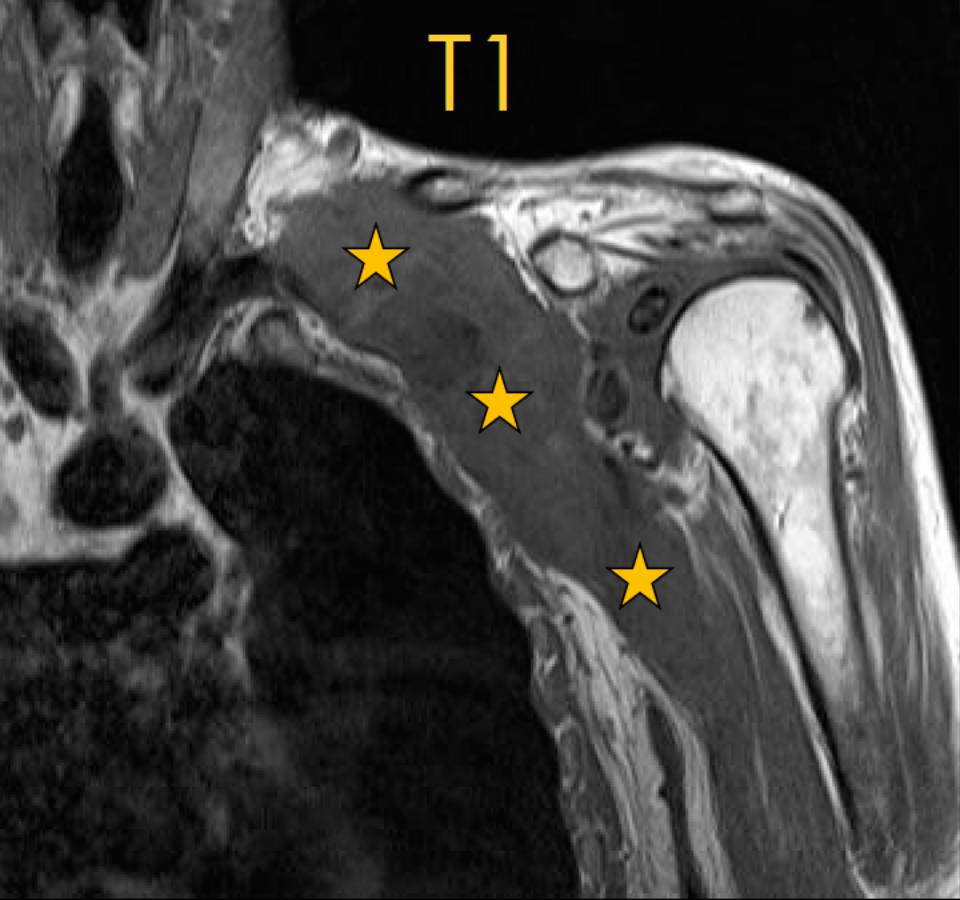70 year-old man with history of
lymphoma treated with
chemotherapy and radiation
with paresthesia of the left arm
for one month

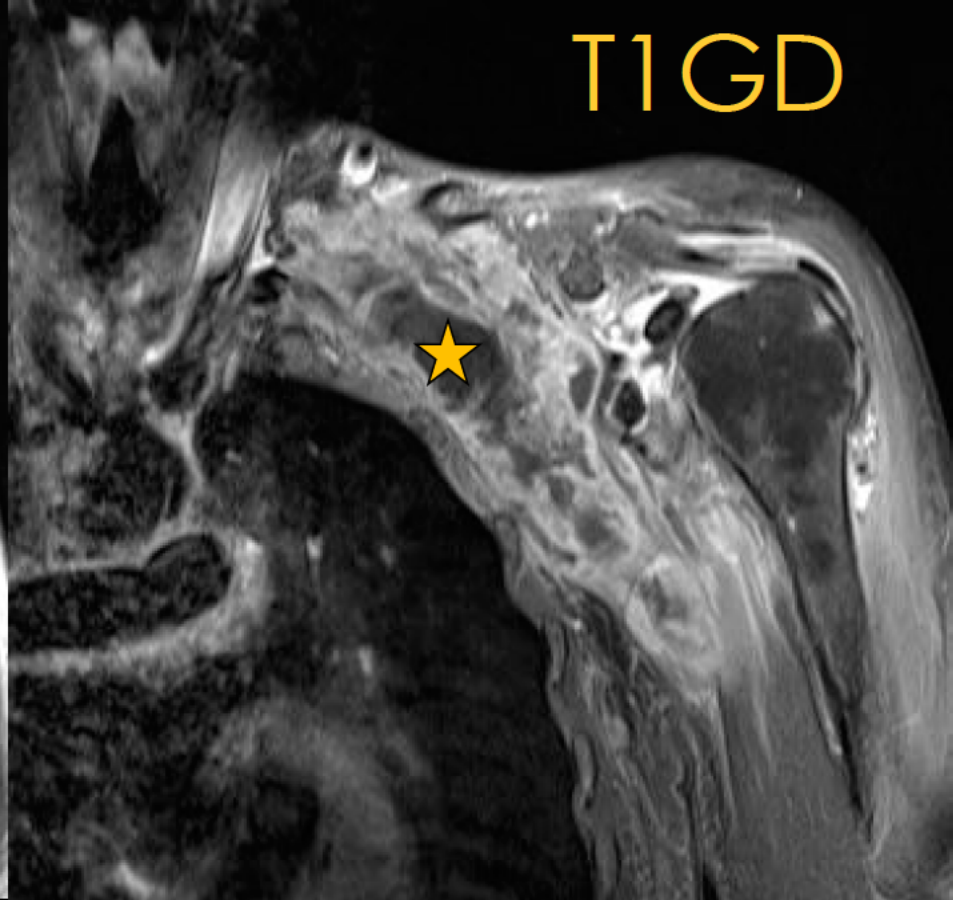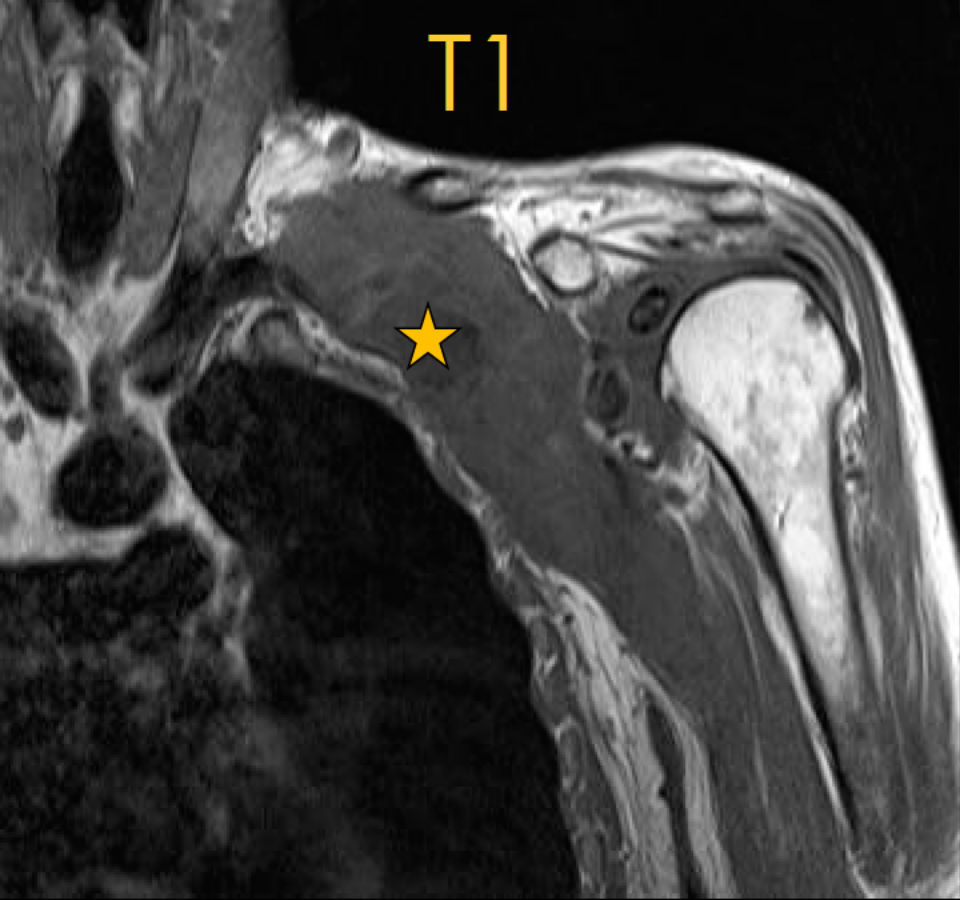T1

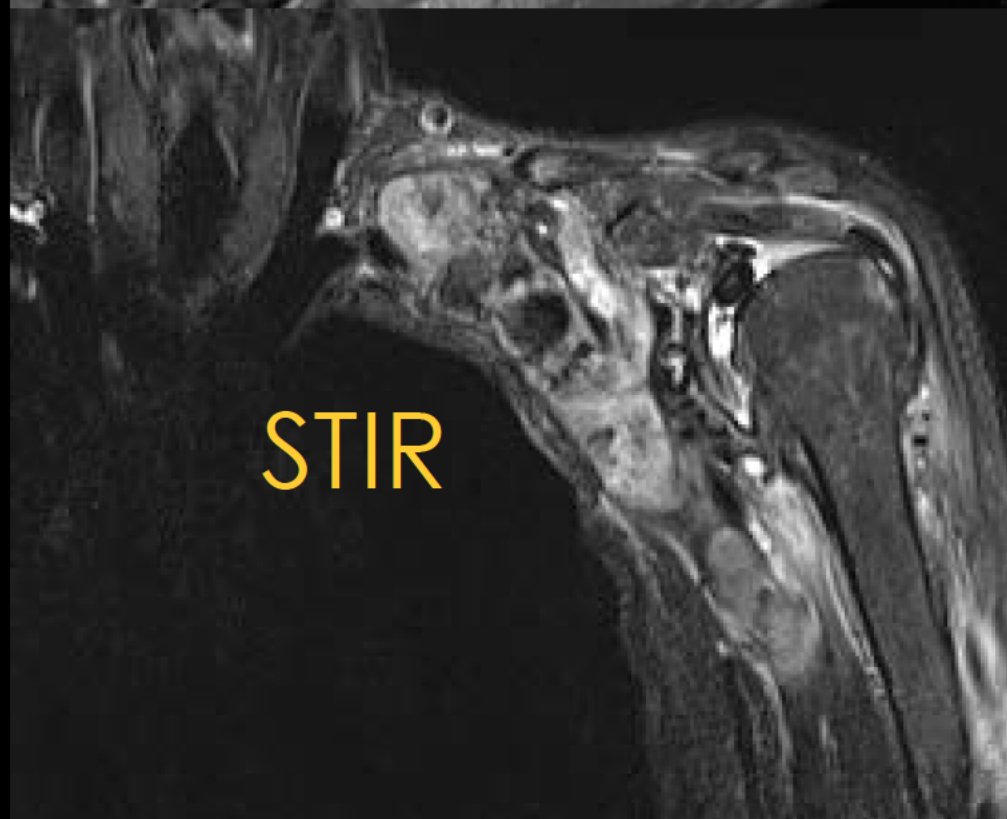
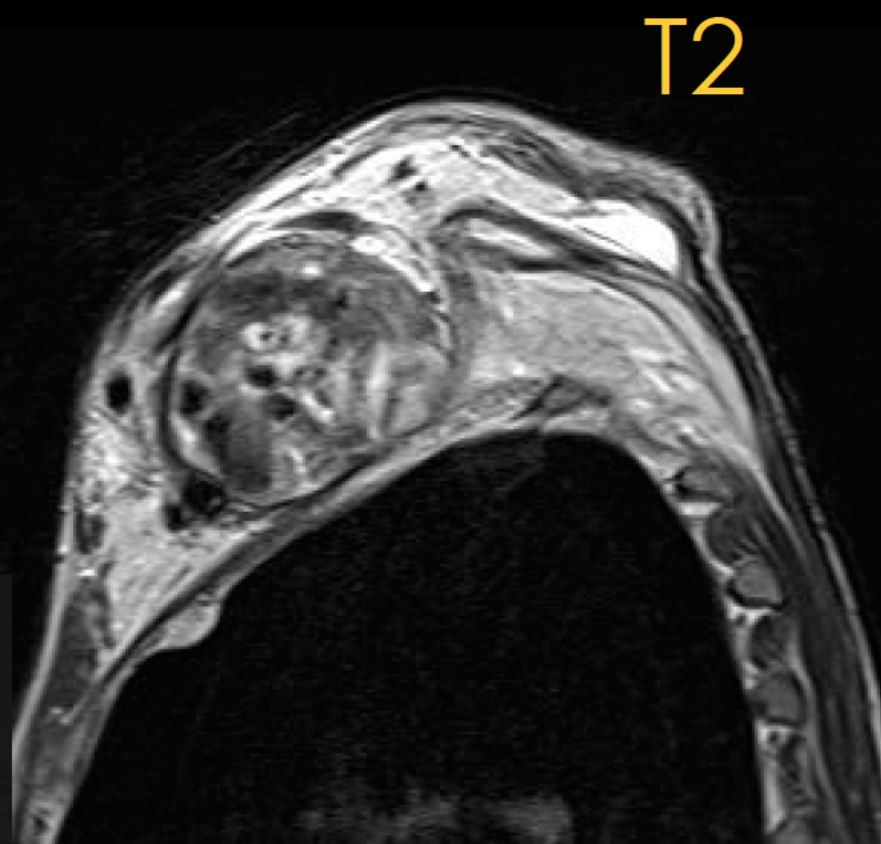
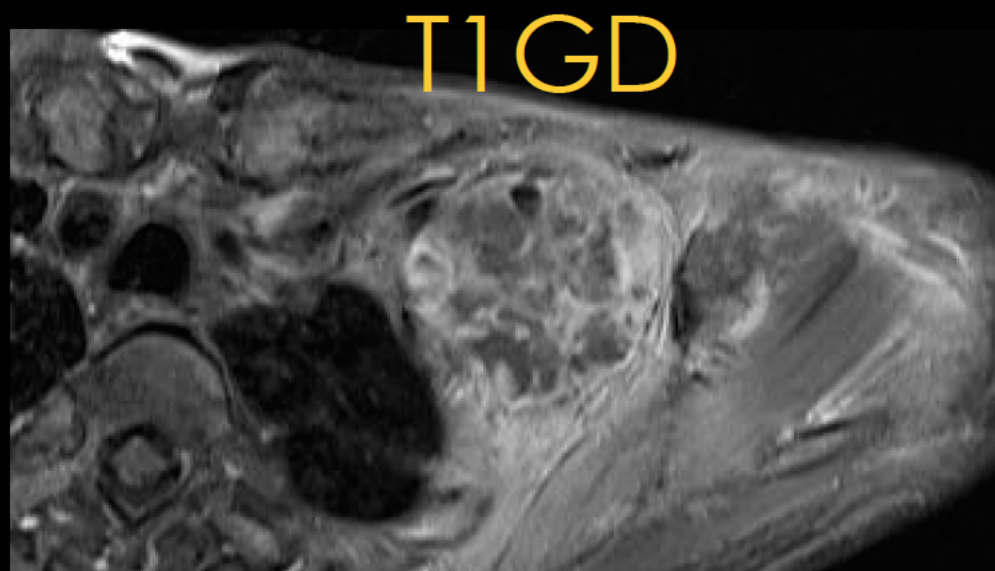


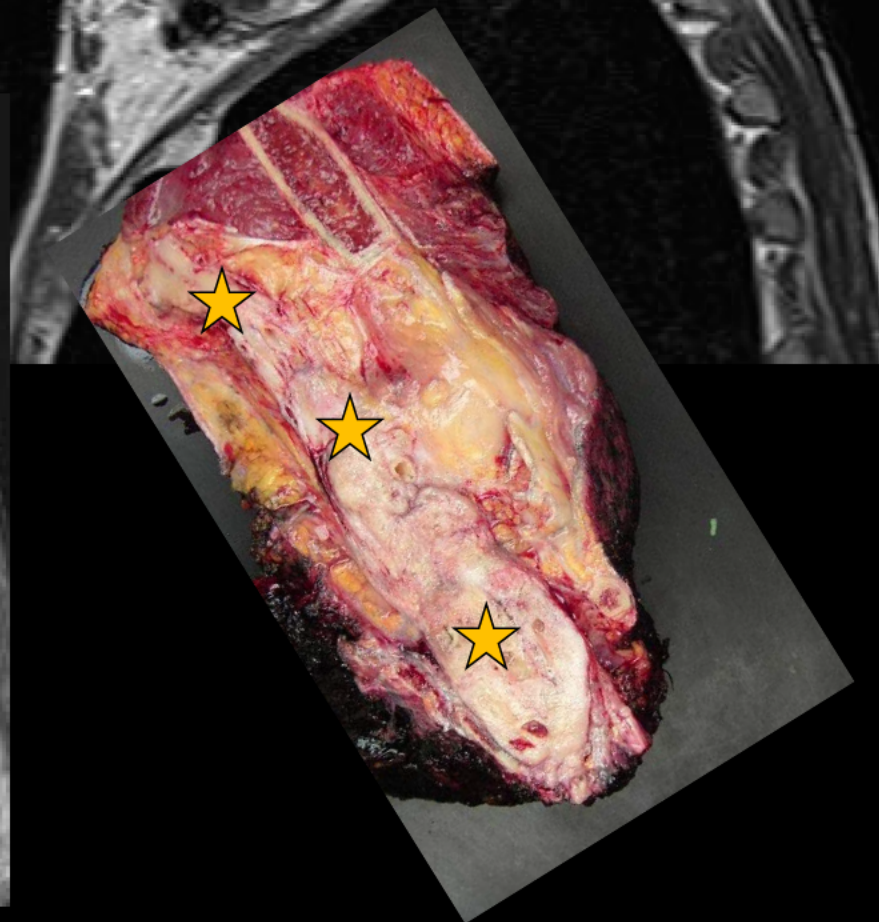
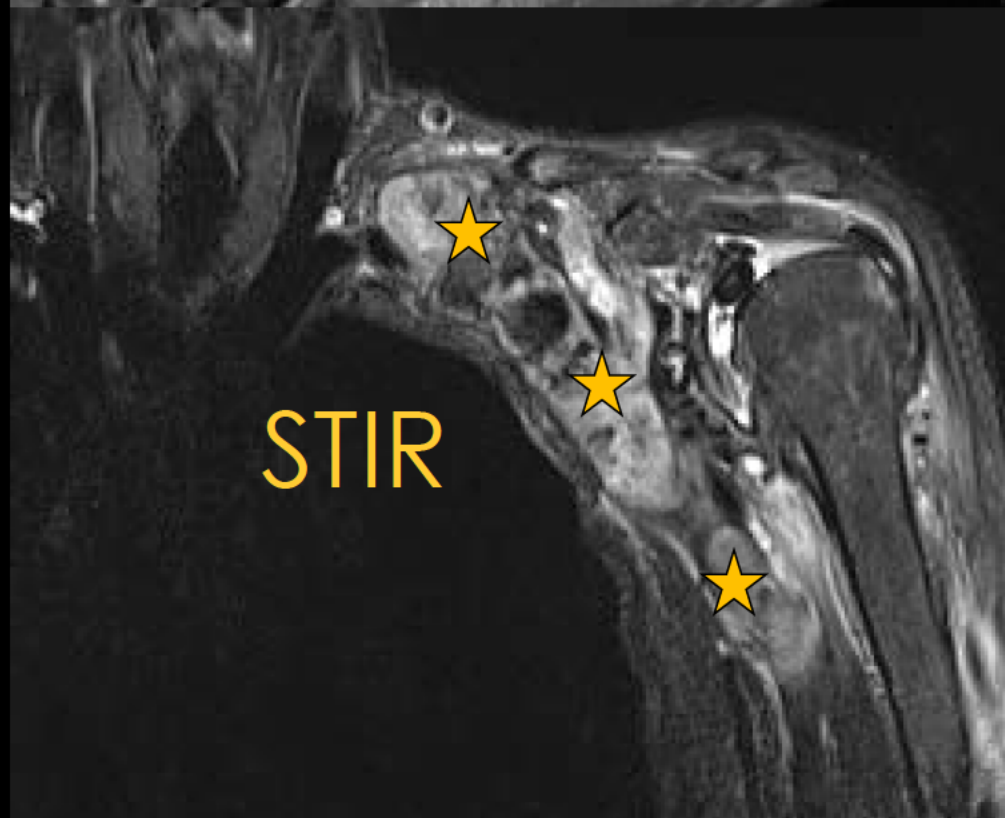
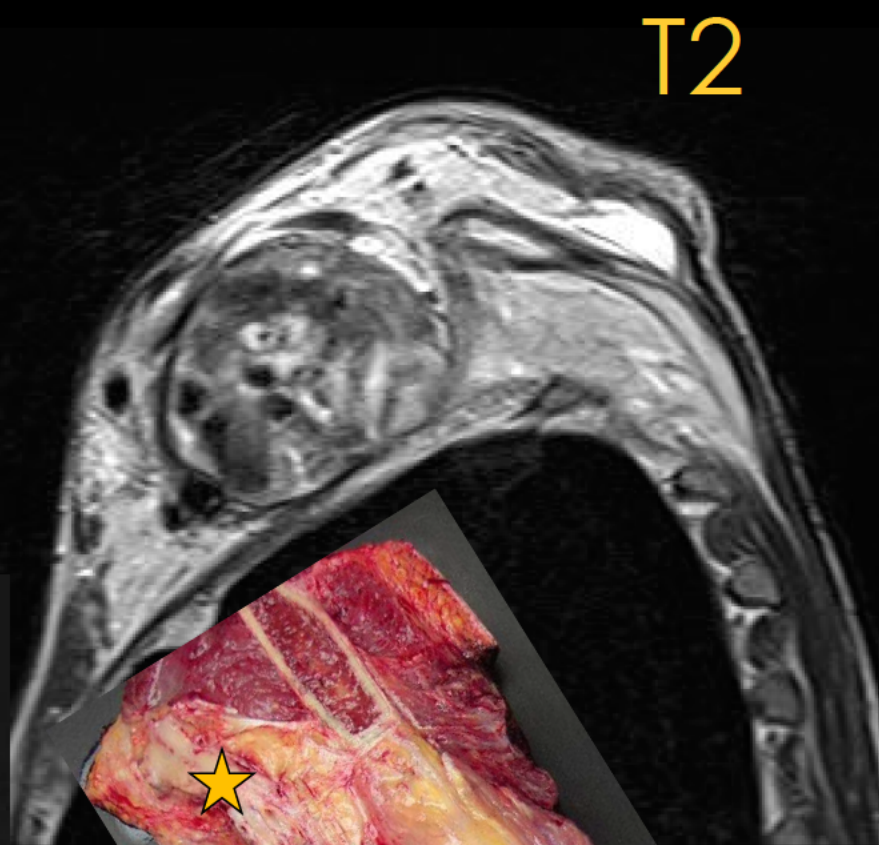
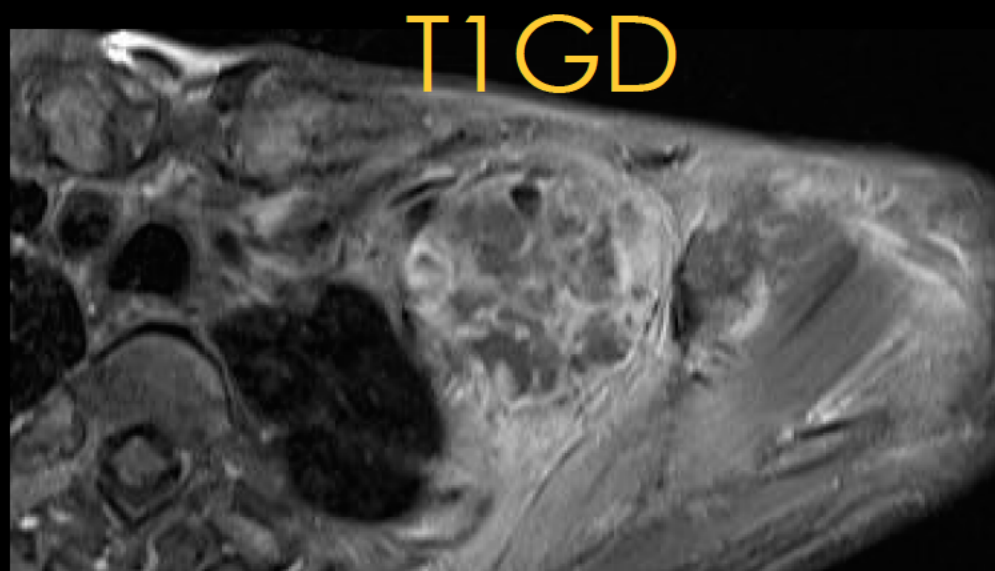
T1GD



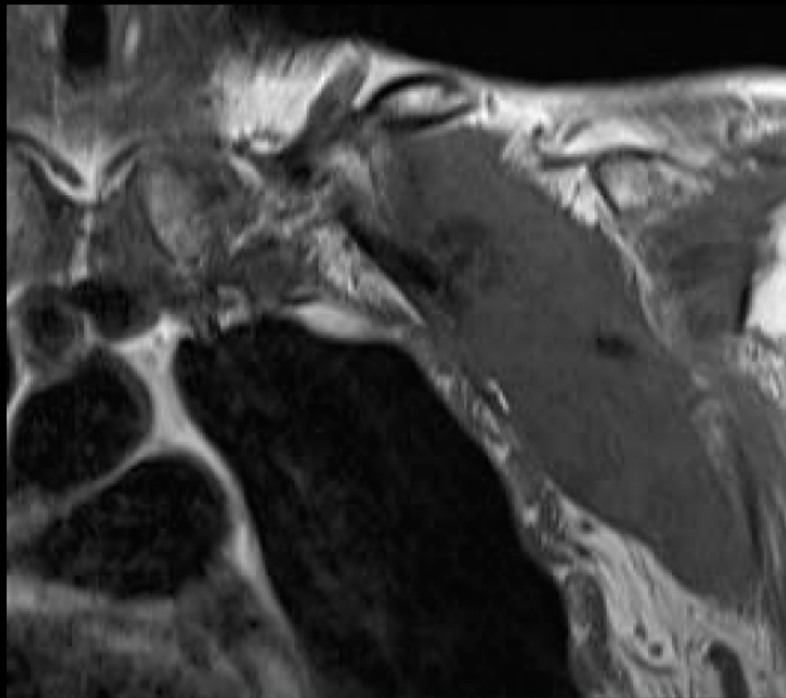




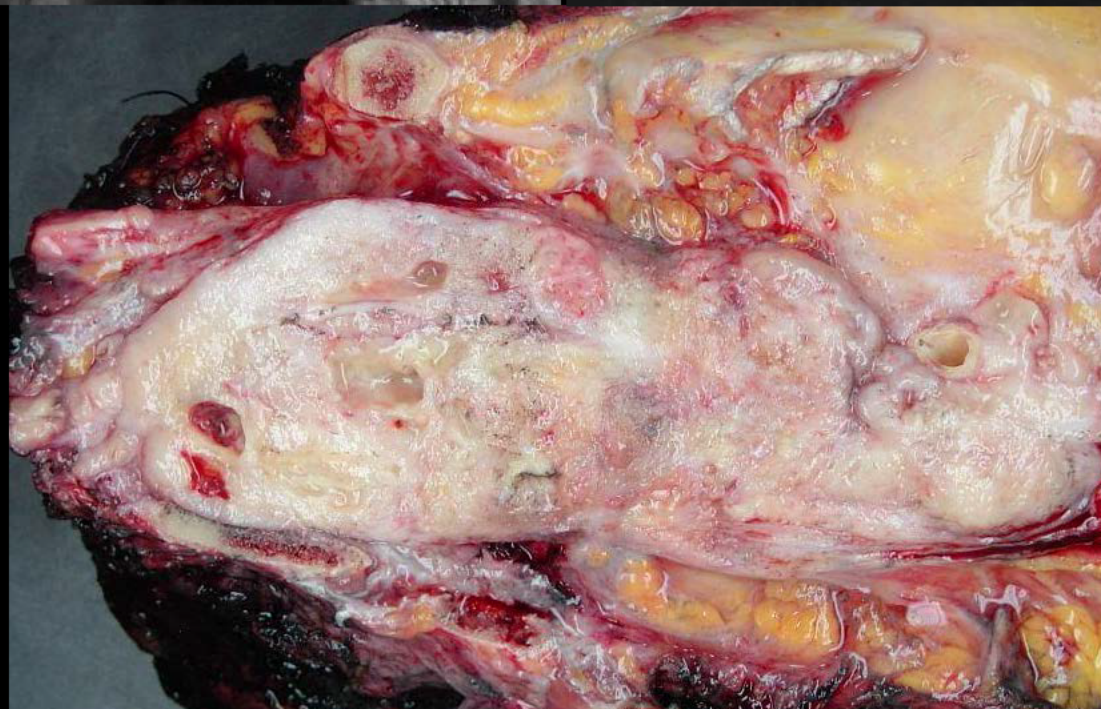
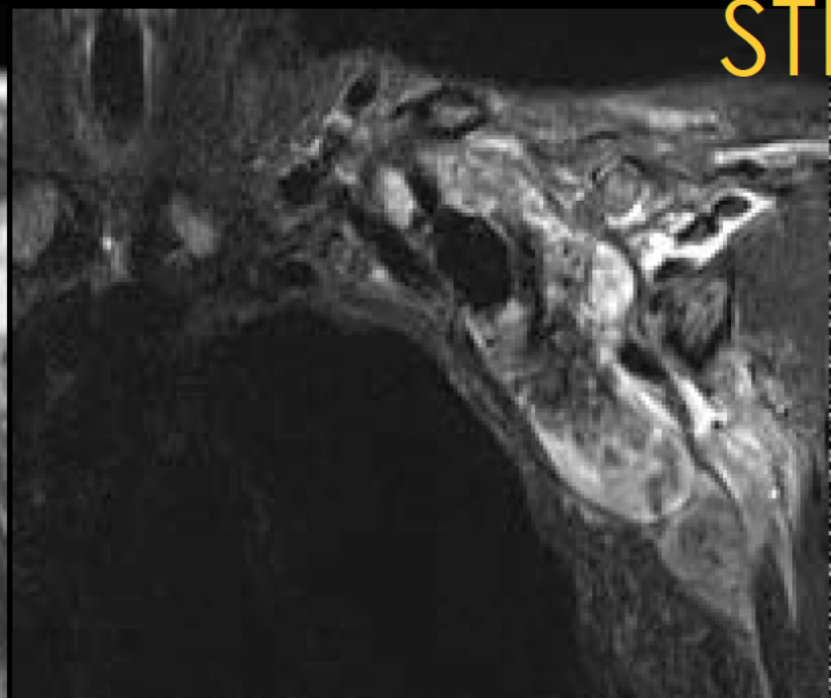




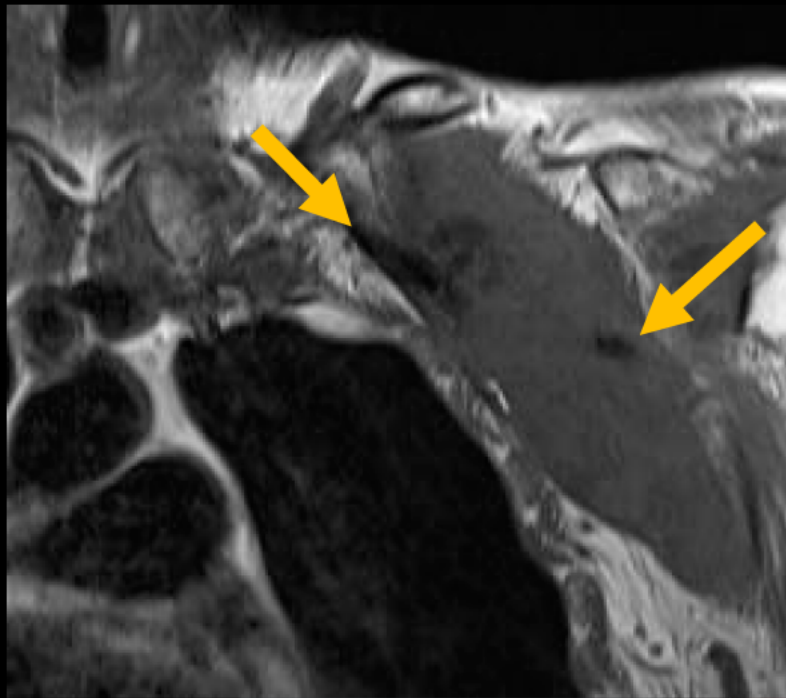
T1



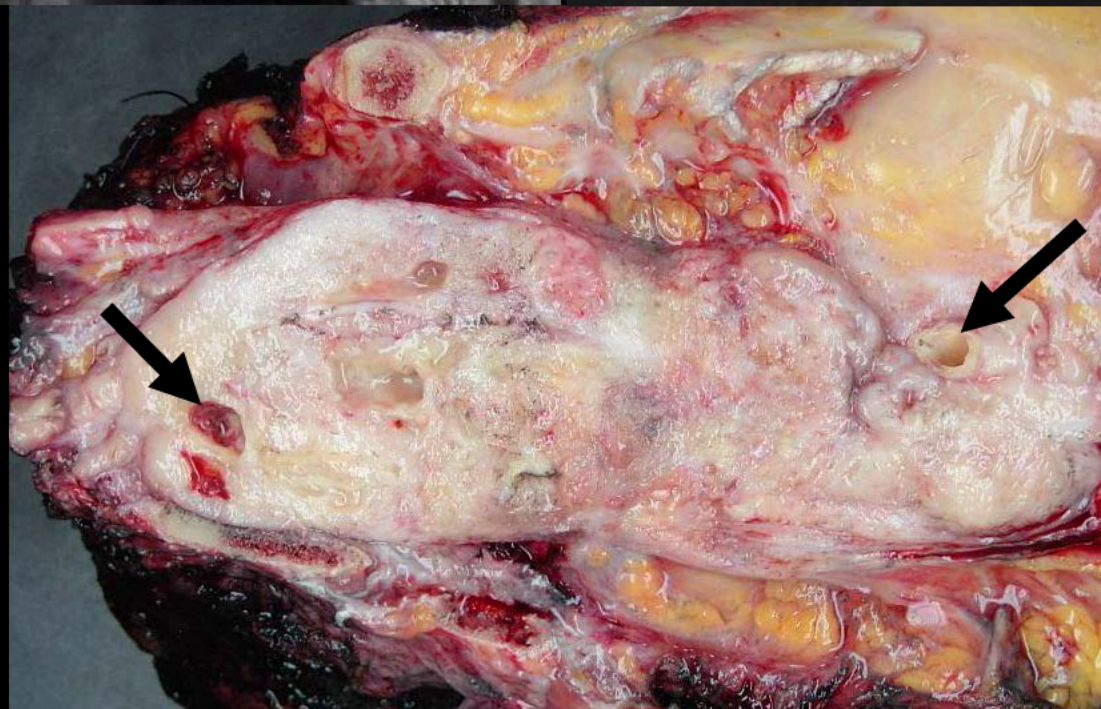
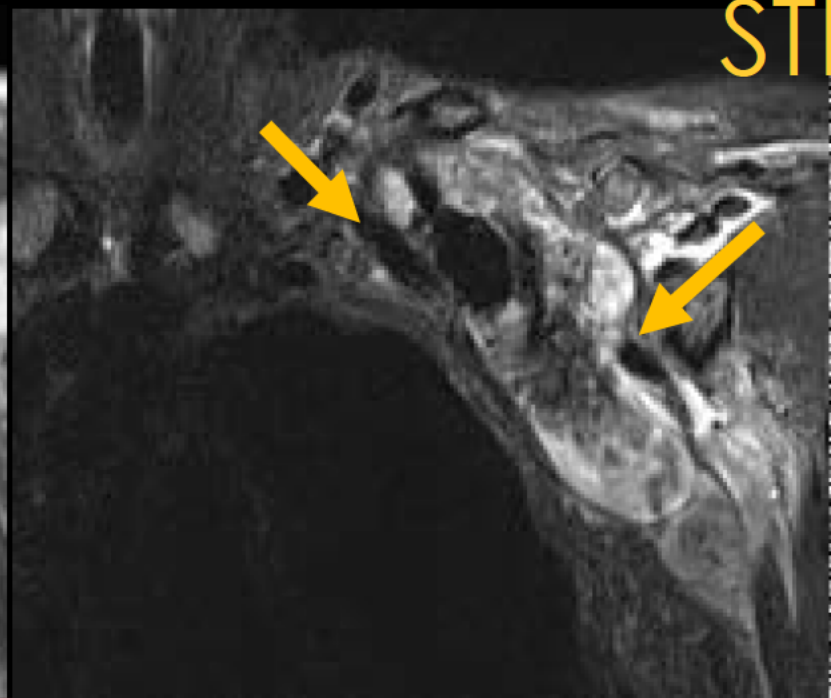
STIR



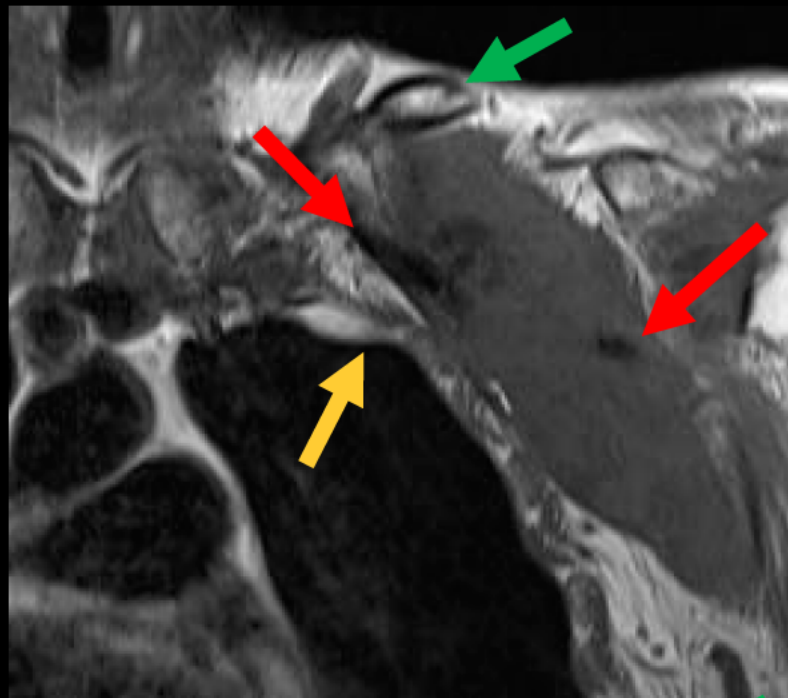T1



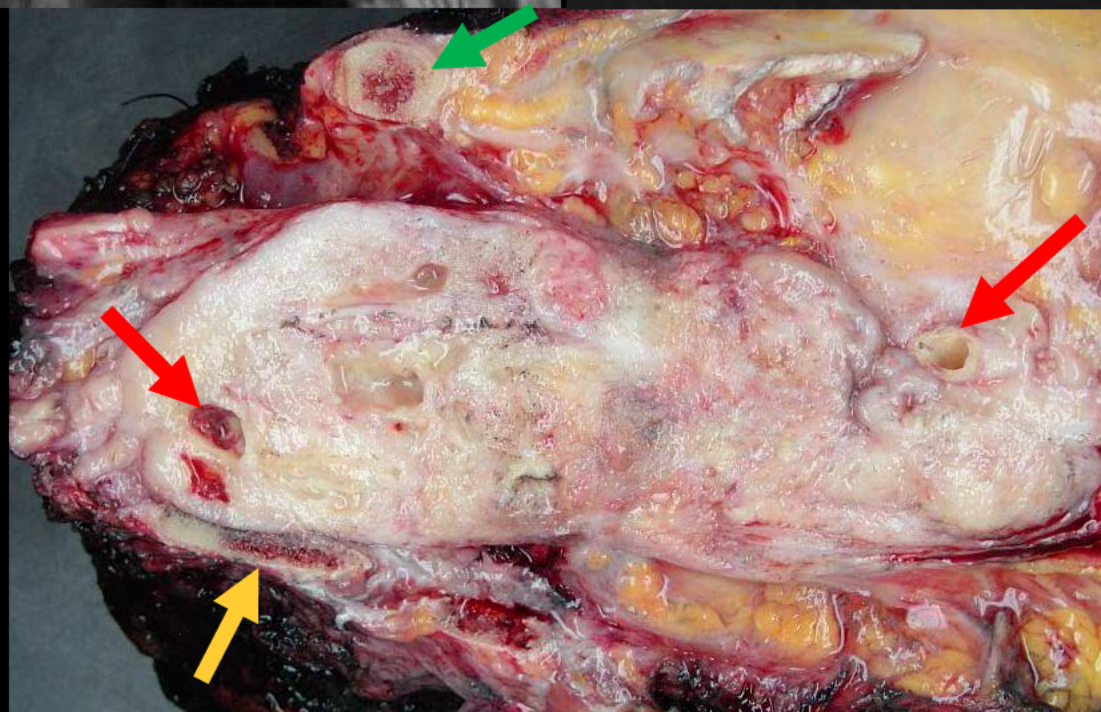
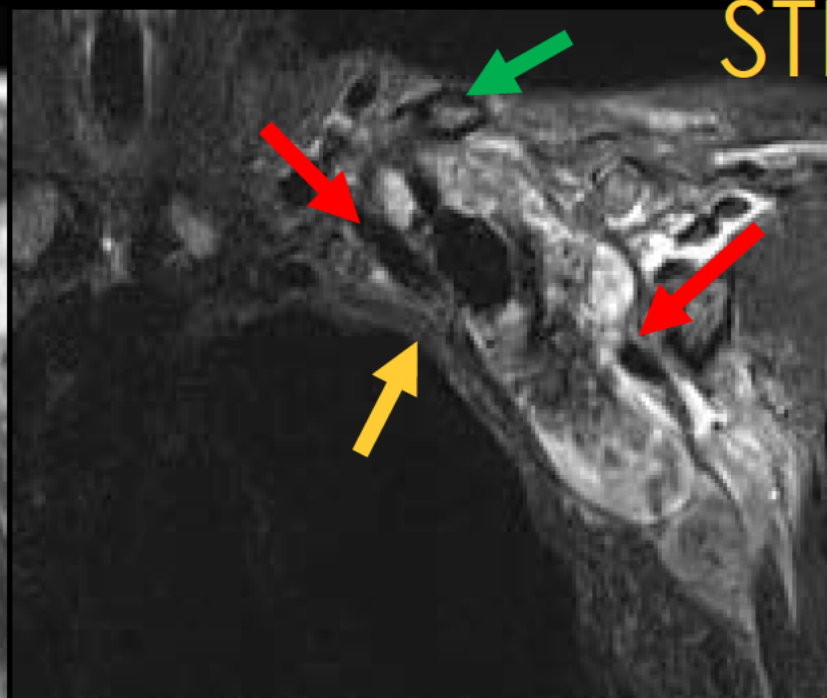
STIR



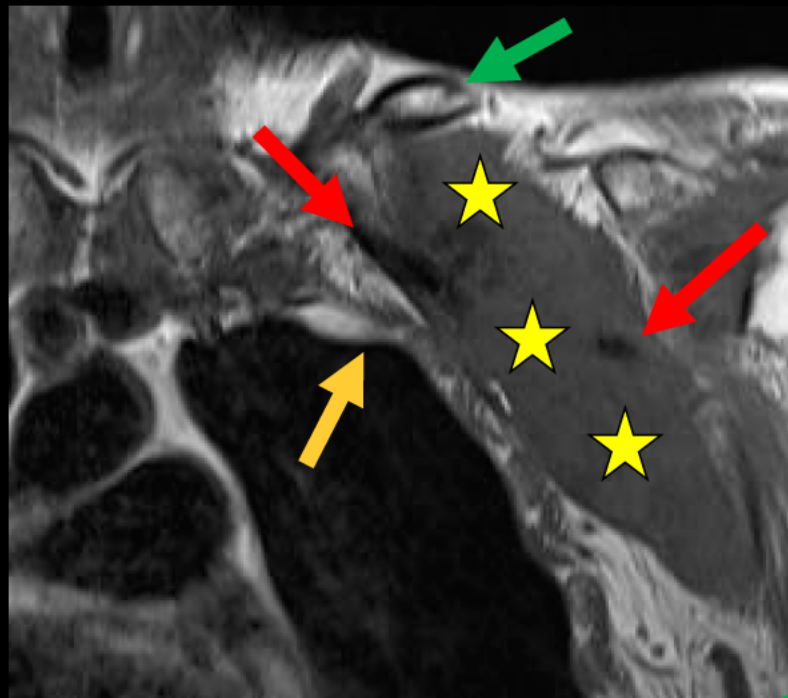T1



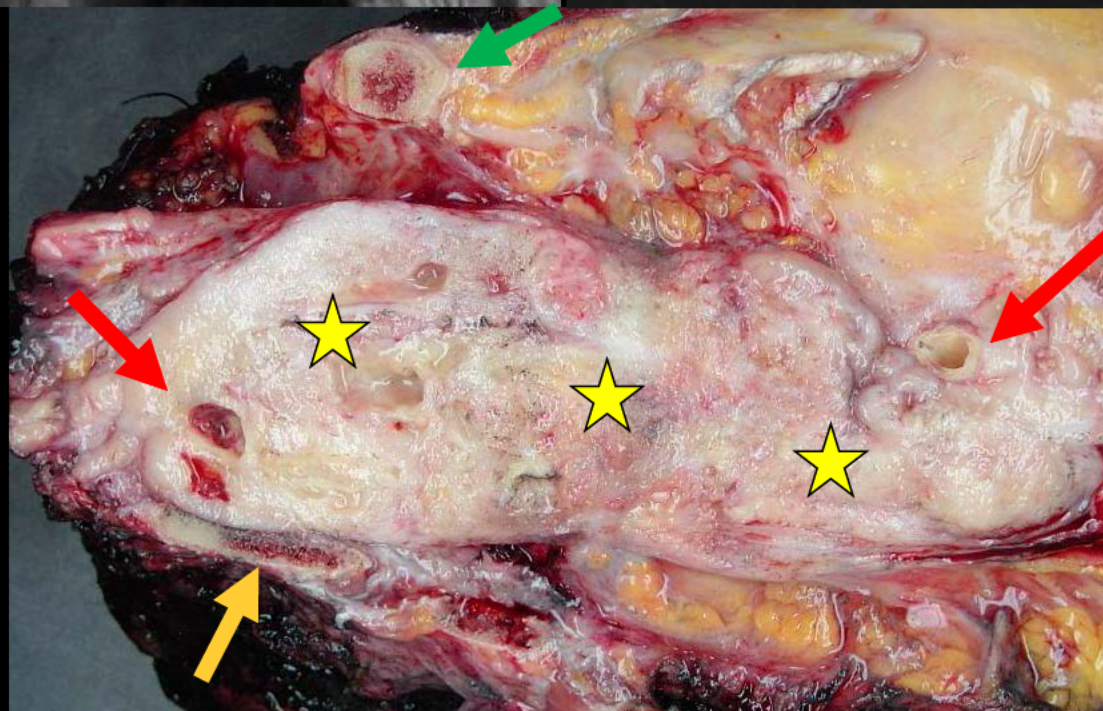
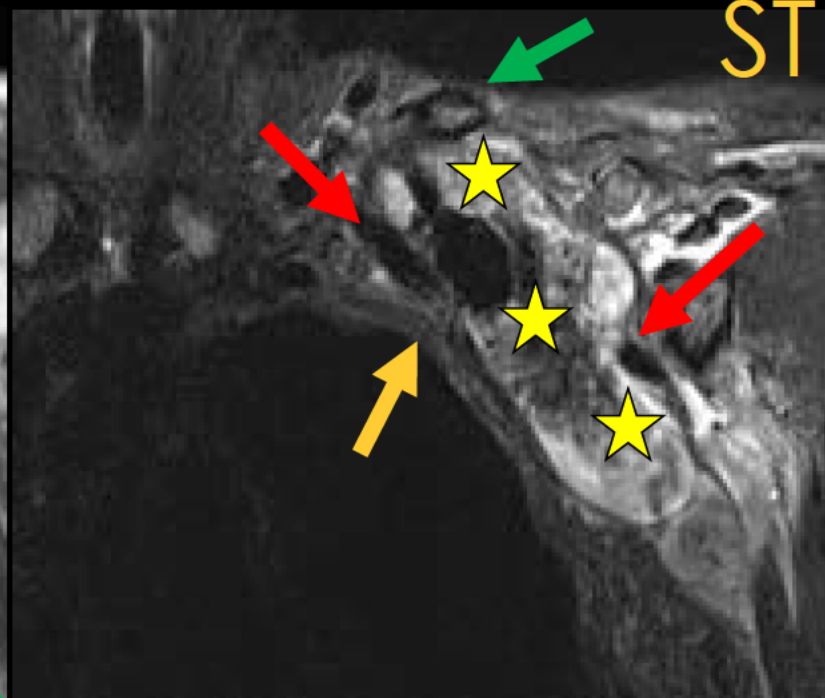
STIR

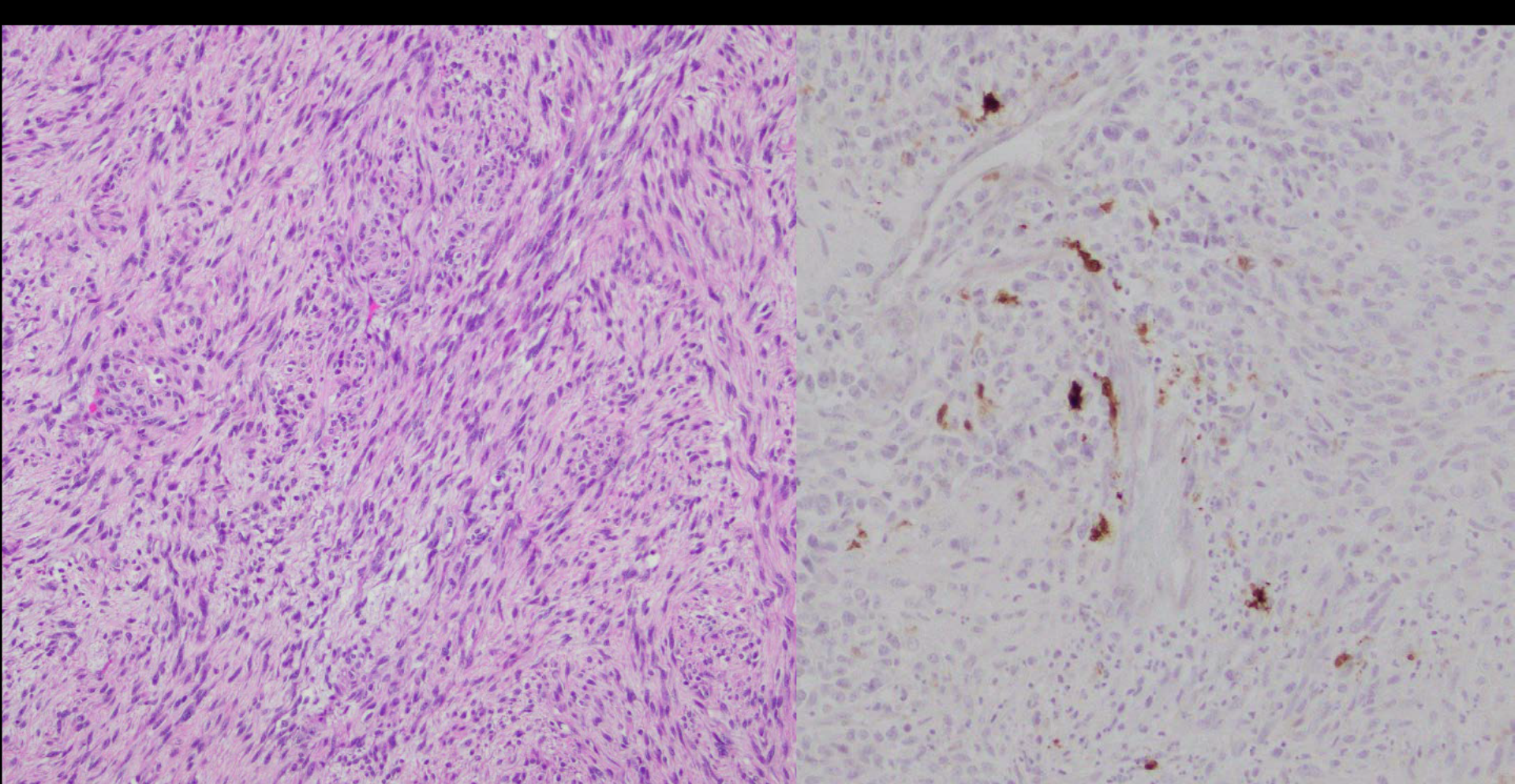


T1

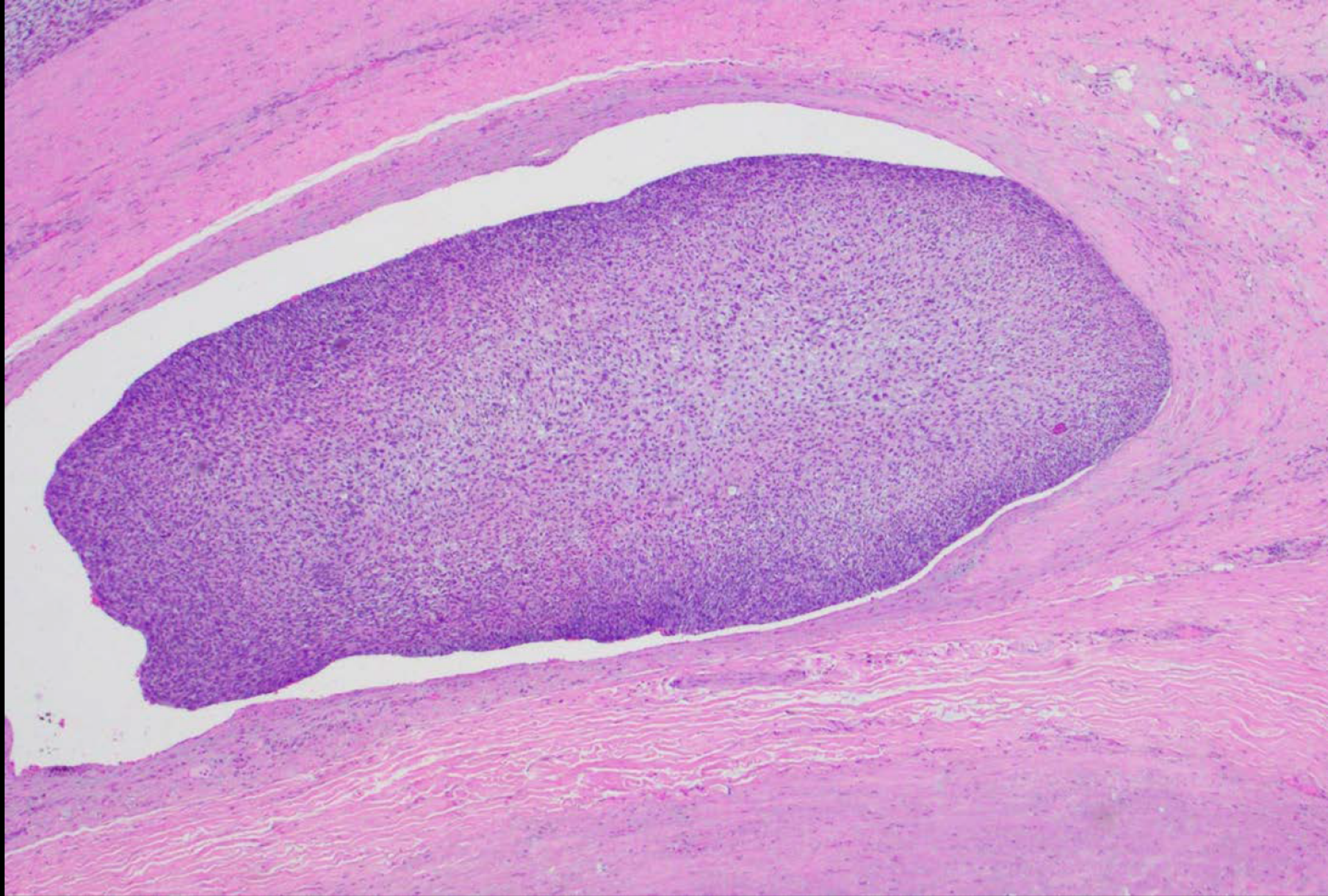


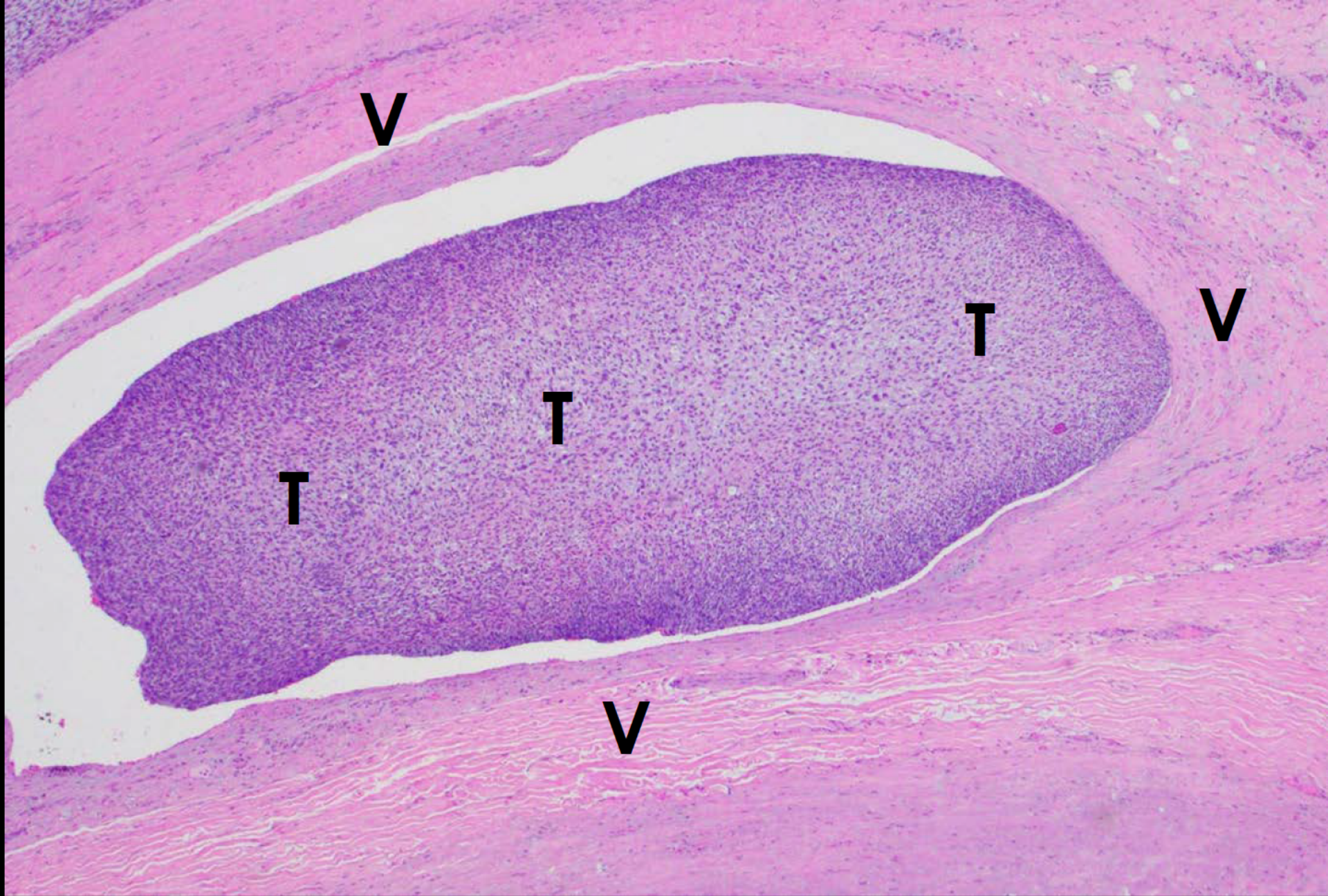
STIR





S 100



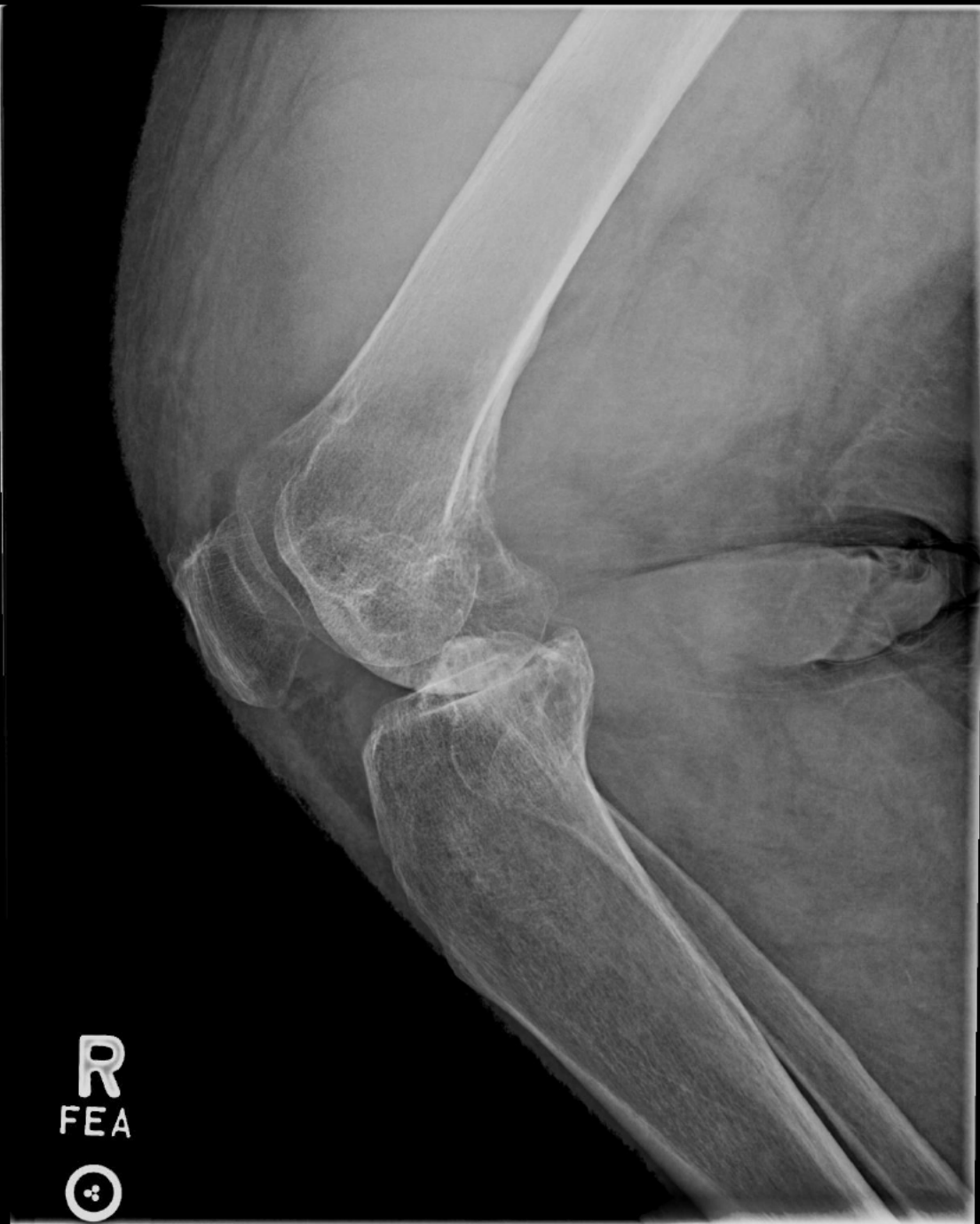

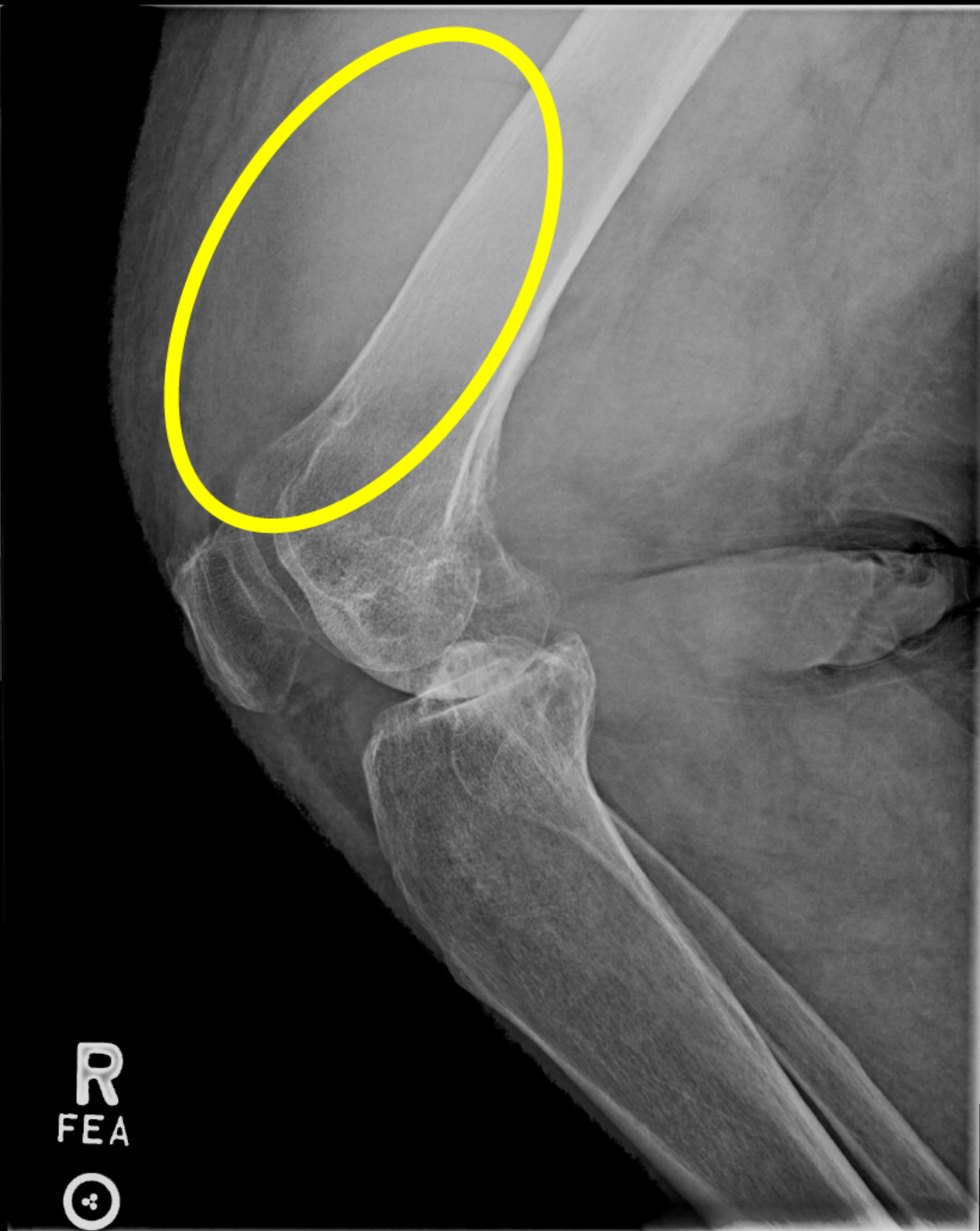
Radiation Induced Malignant Peripheral Nerve Sheath Tumor

Anderson Kevin Toporowicz, MD
Maisonnette-Rosemont
Université de Montréal
Montreal, Quebec

Honorable mention

76 year old woman with right
knee slowly growing mass for
one year and pain

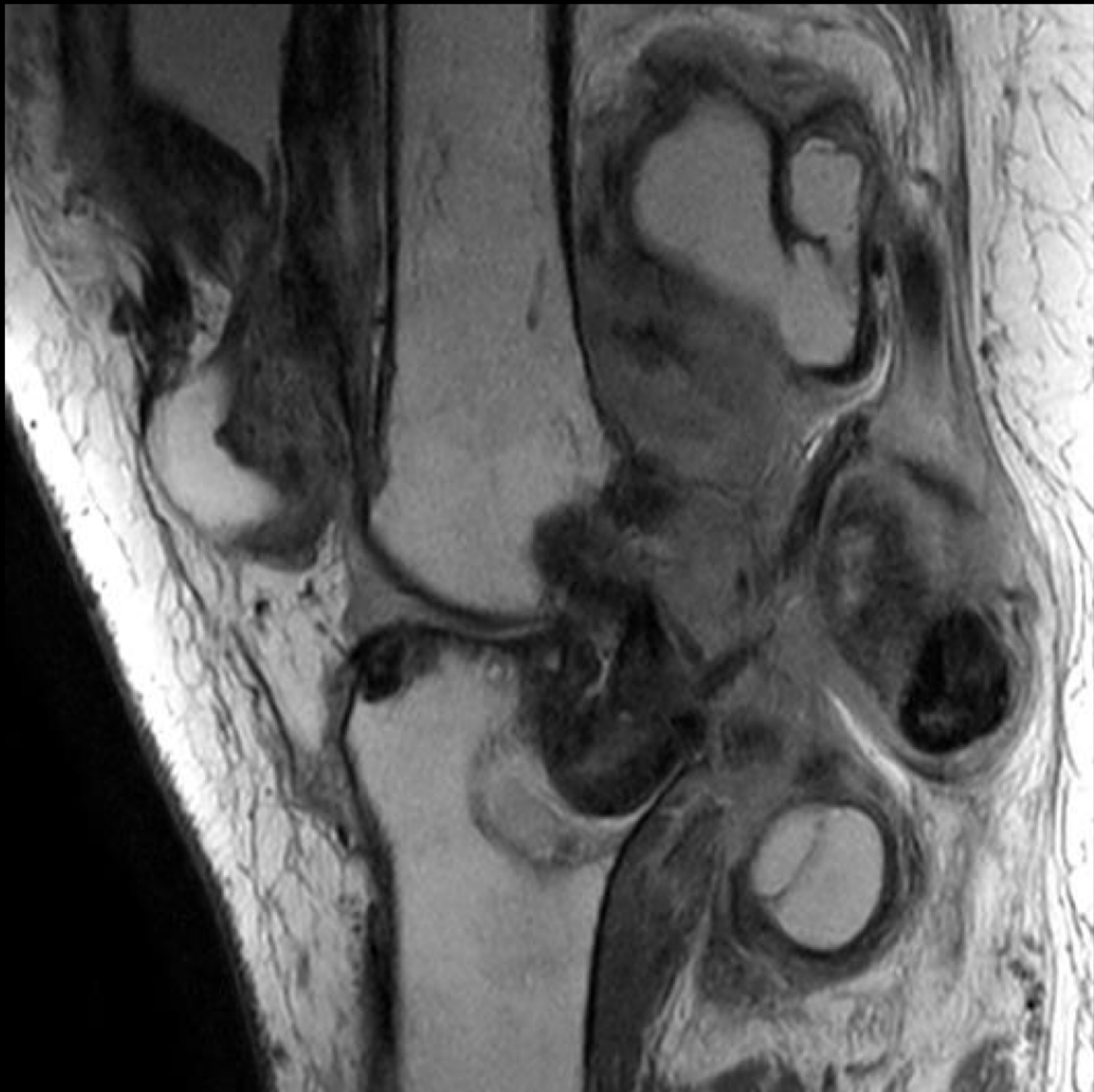



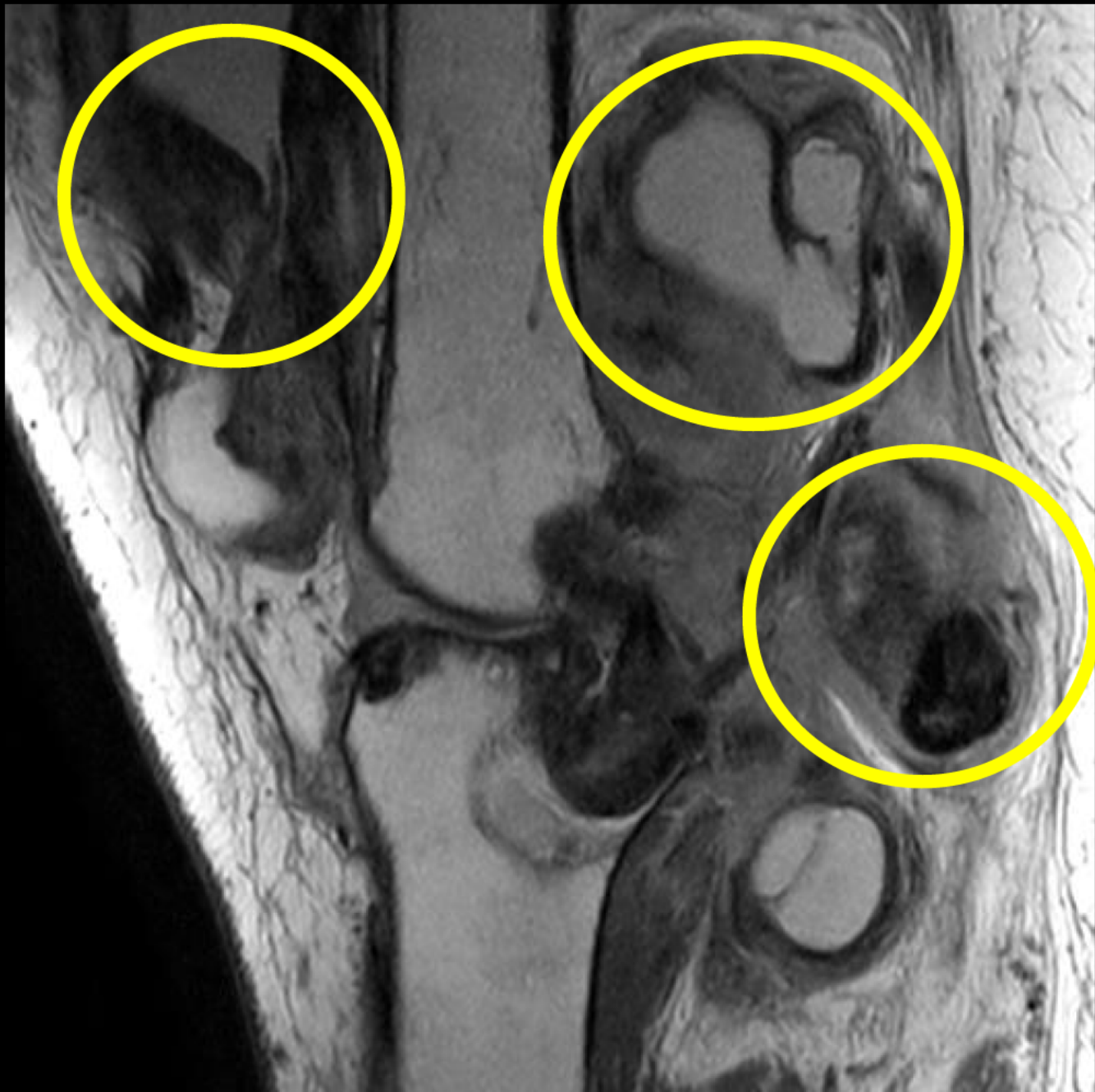
R
FEA



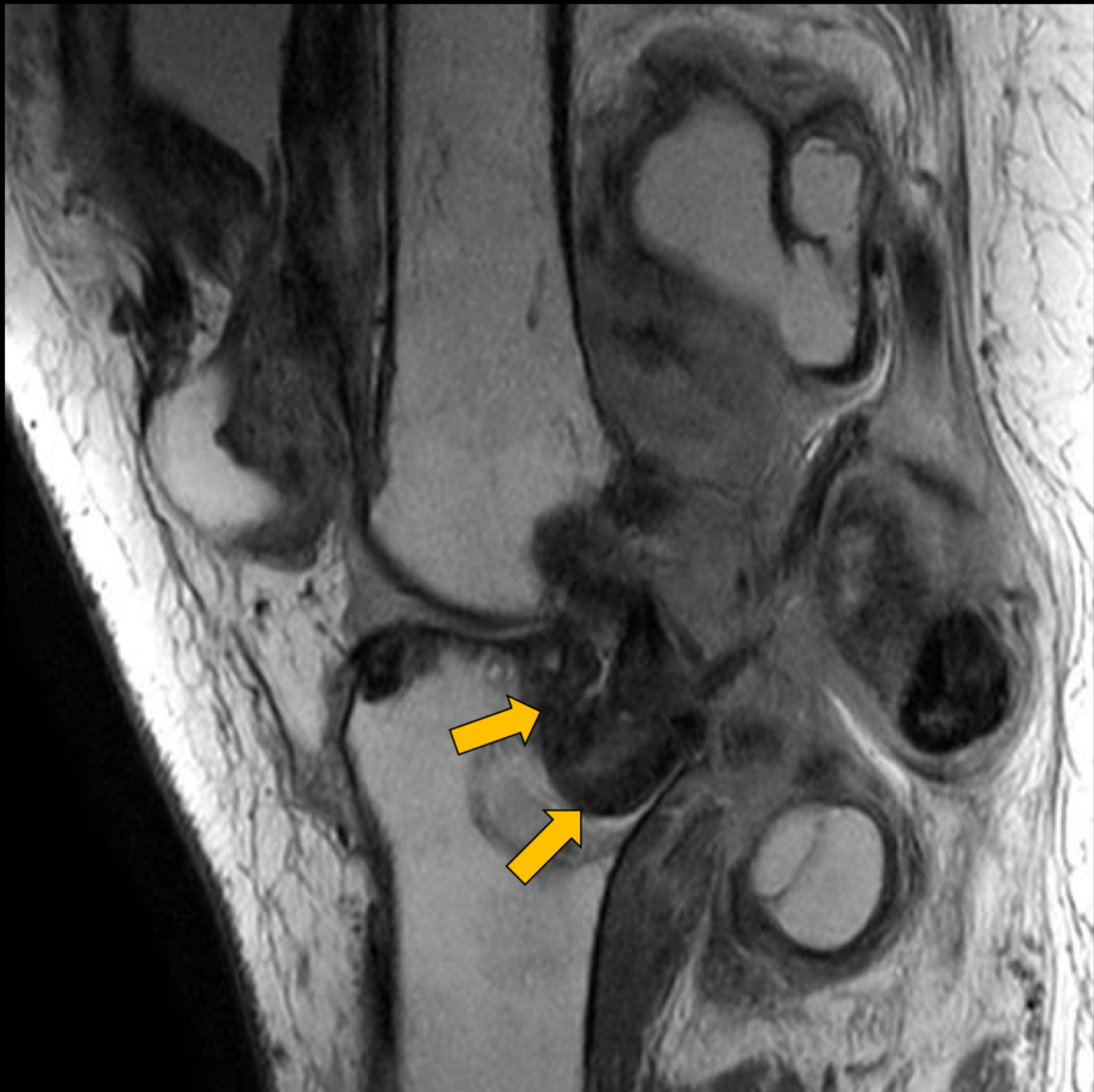
PD

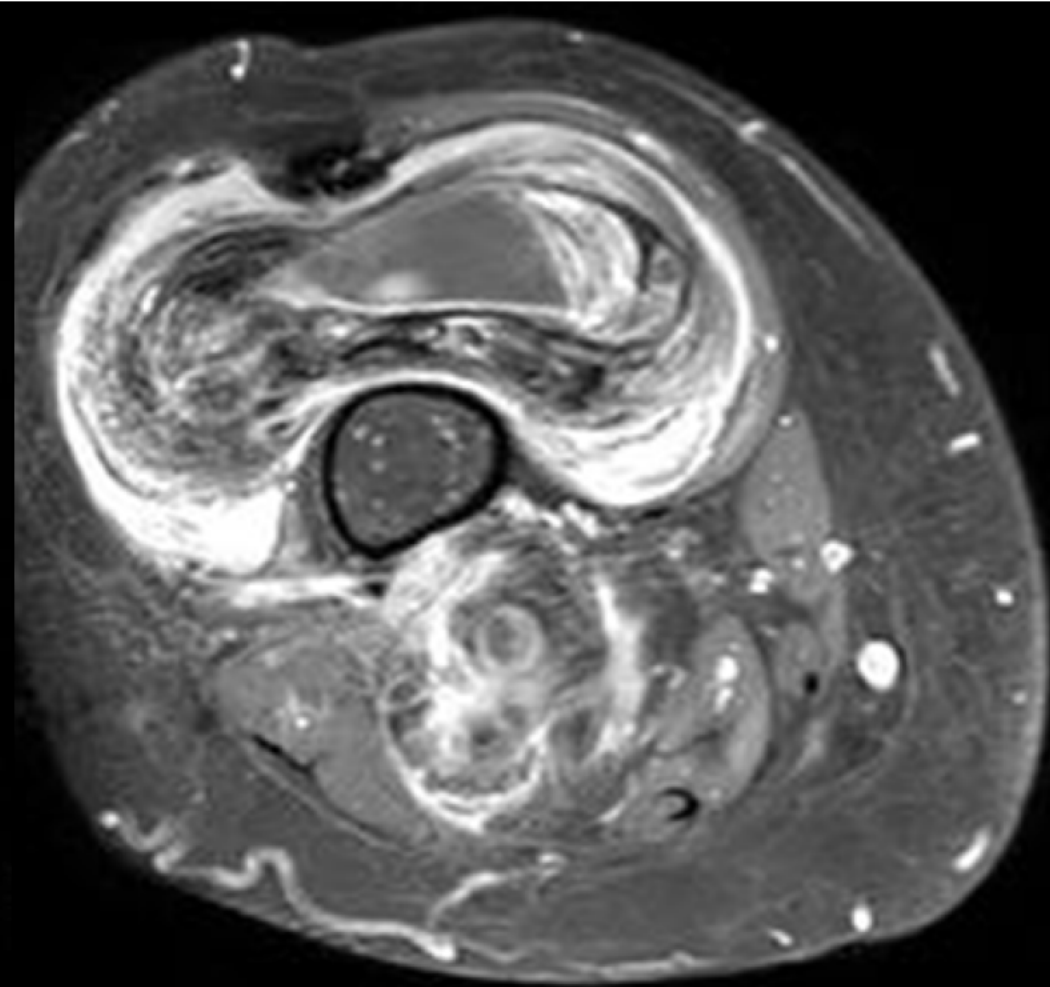
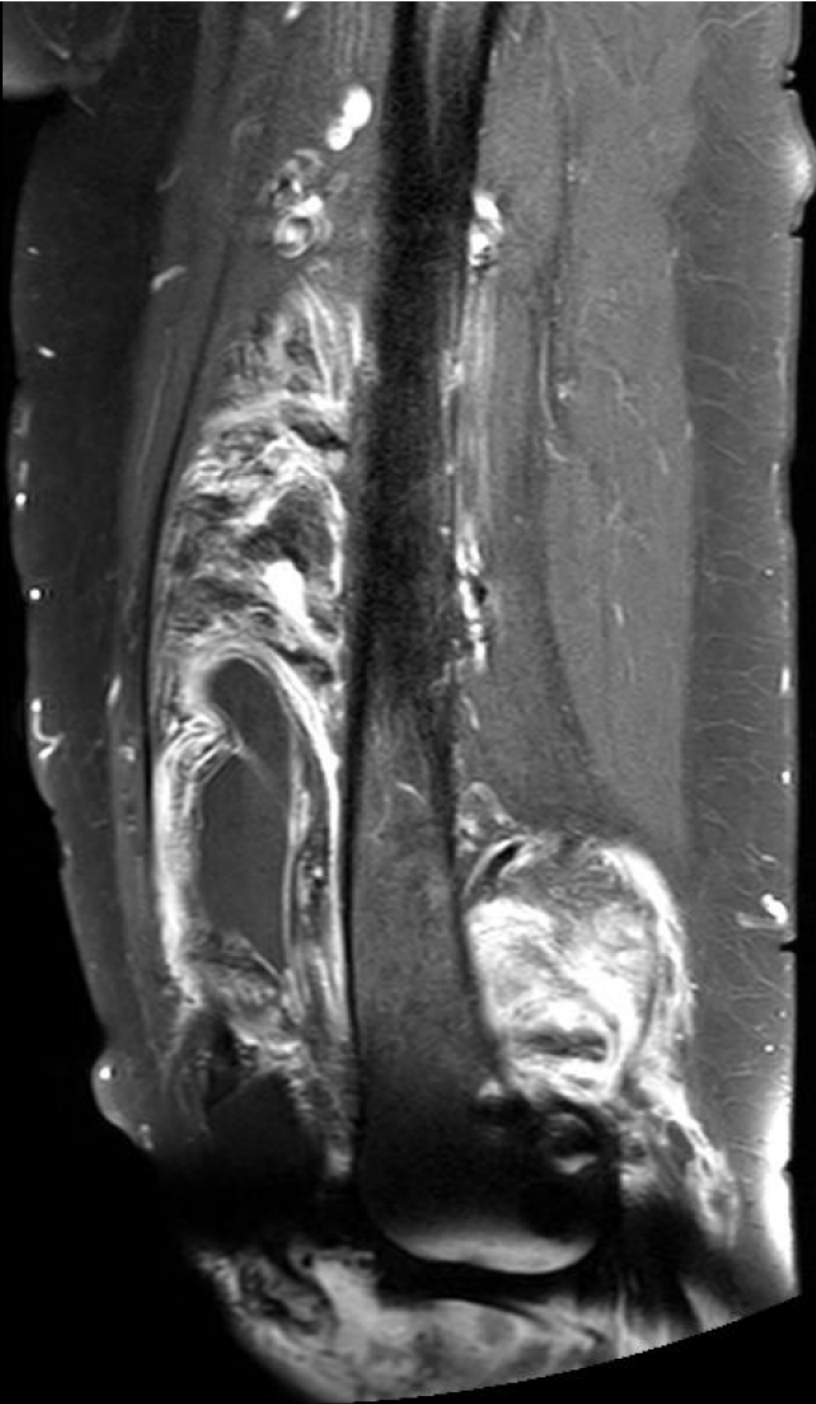


PD



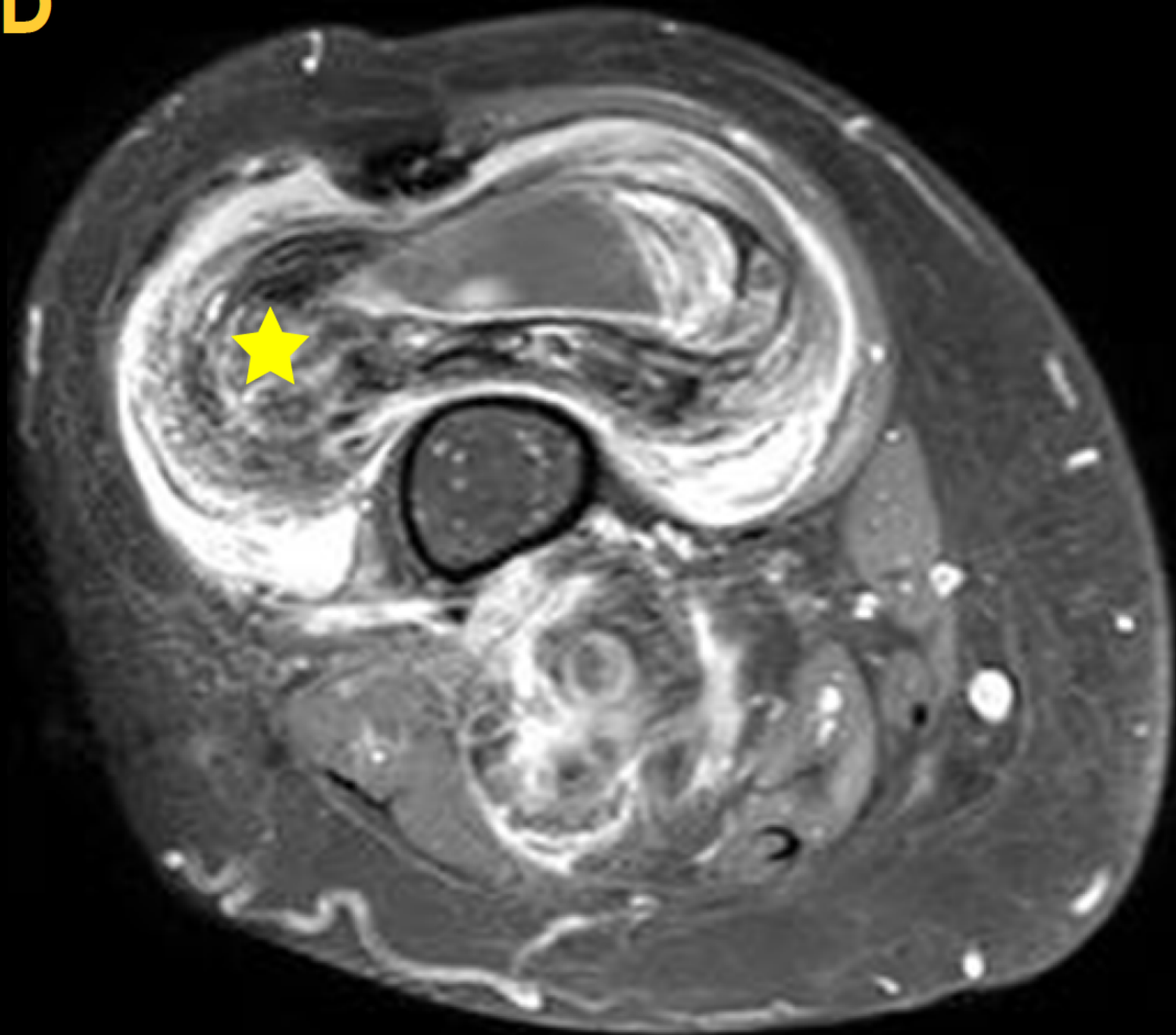
PD



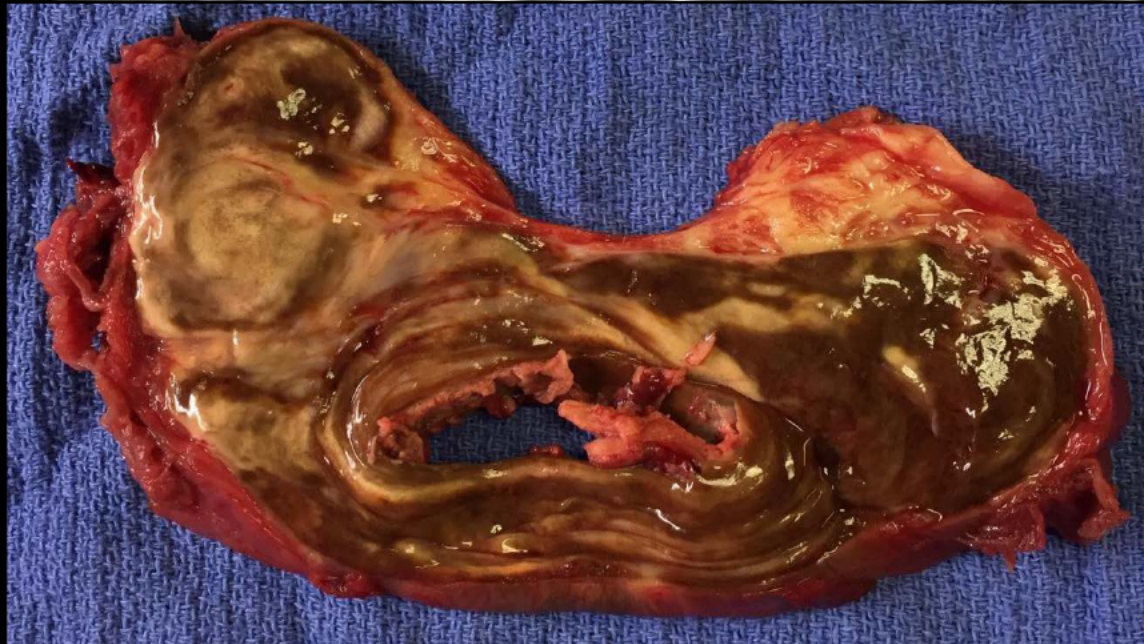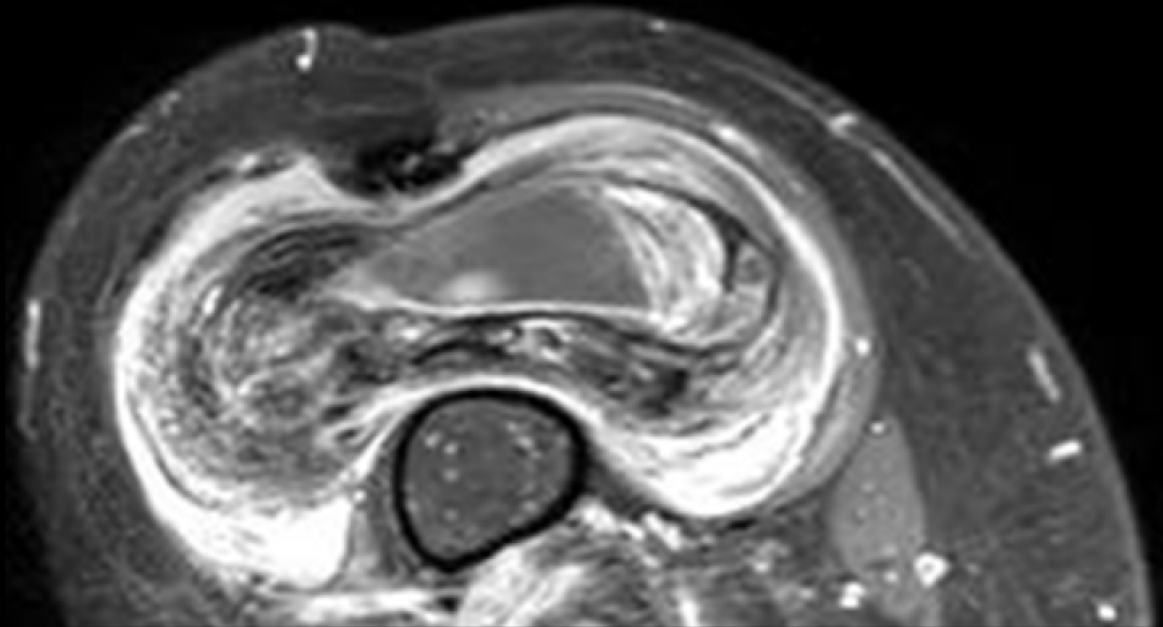


T1 GD

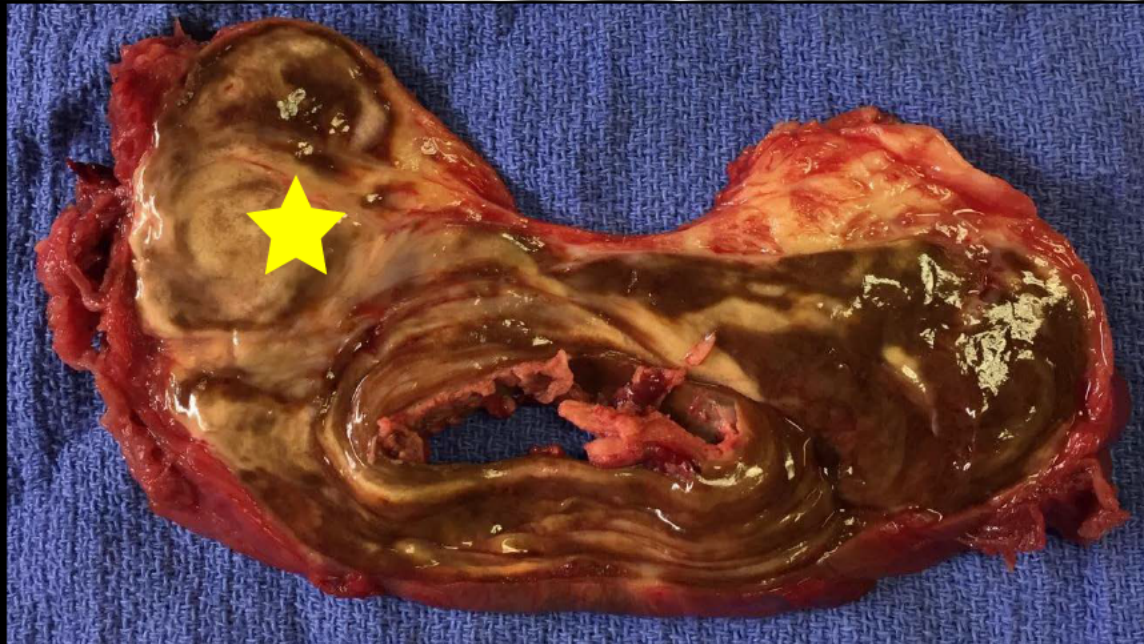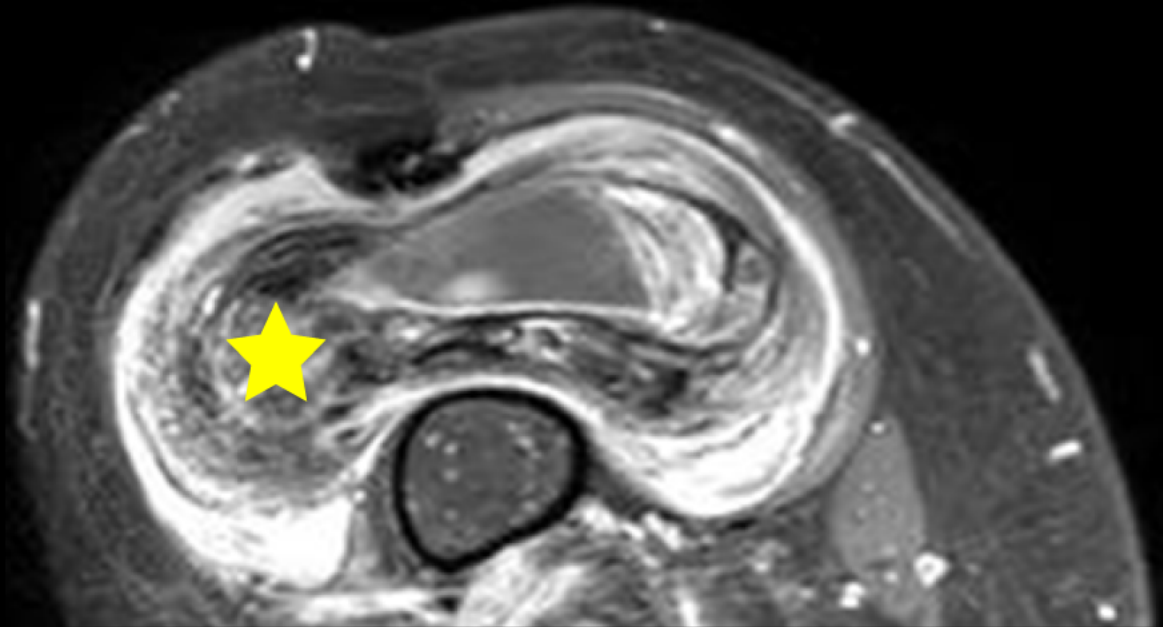
T1 GD

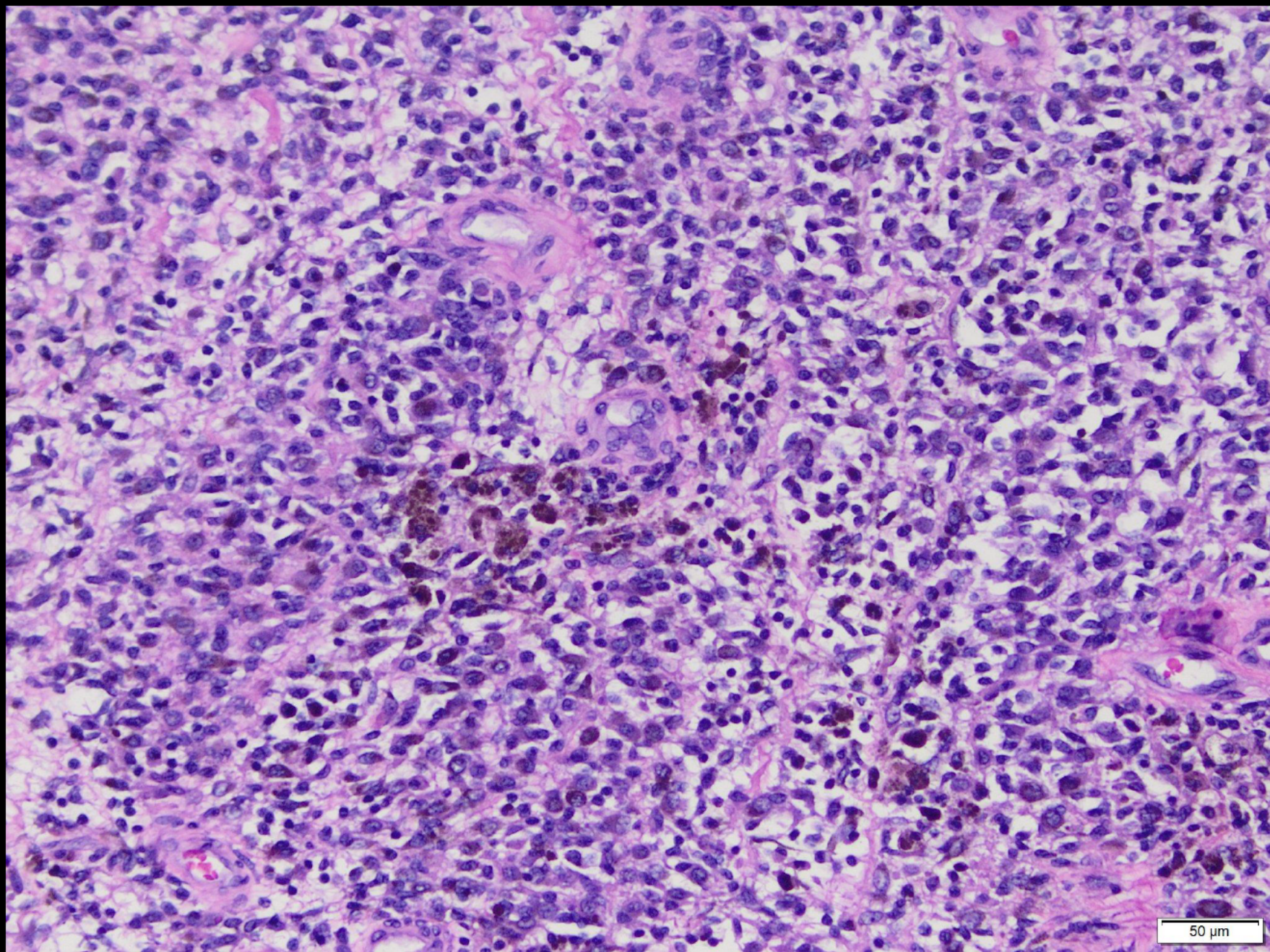


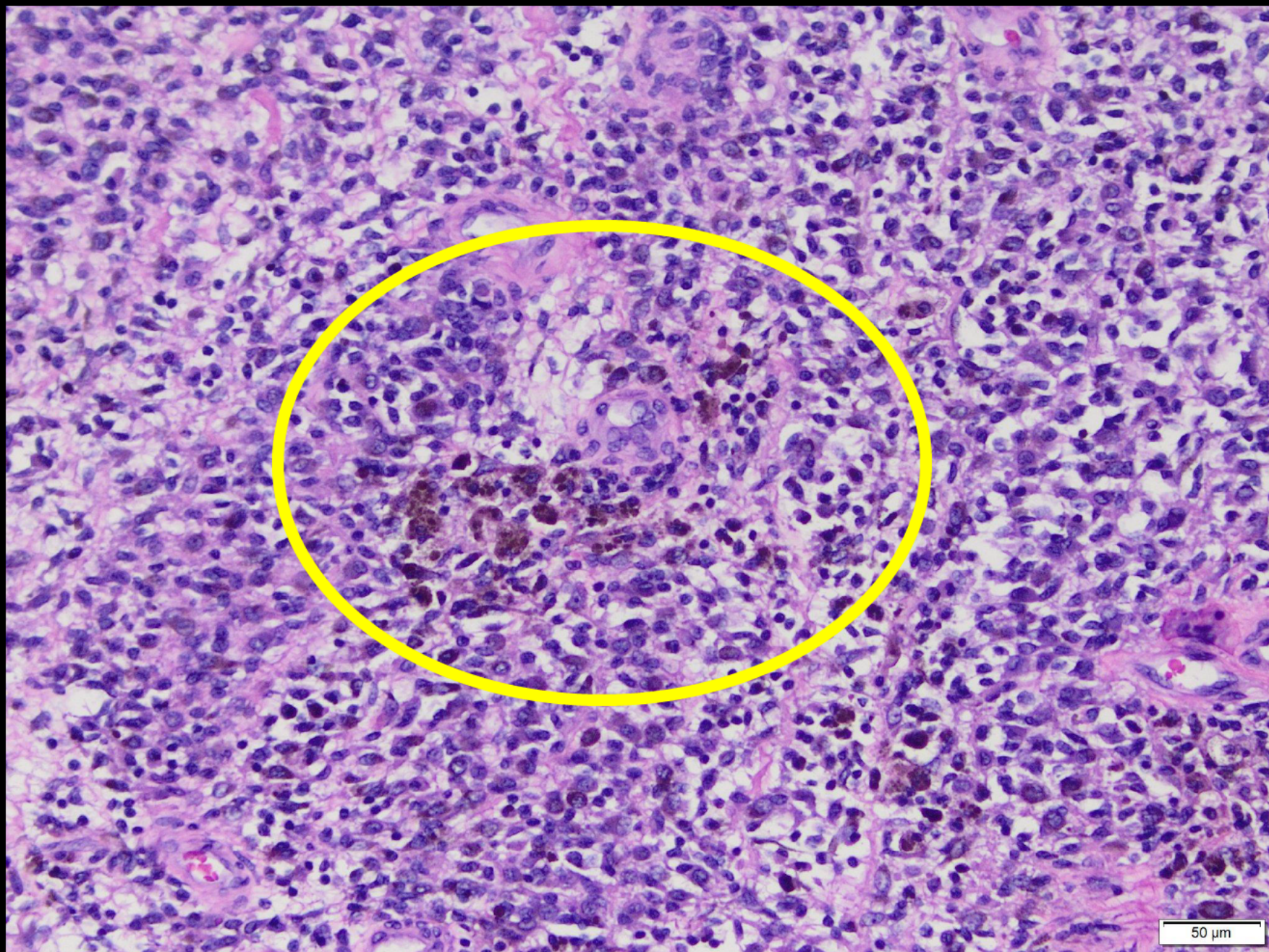
T1 GD



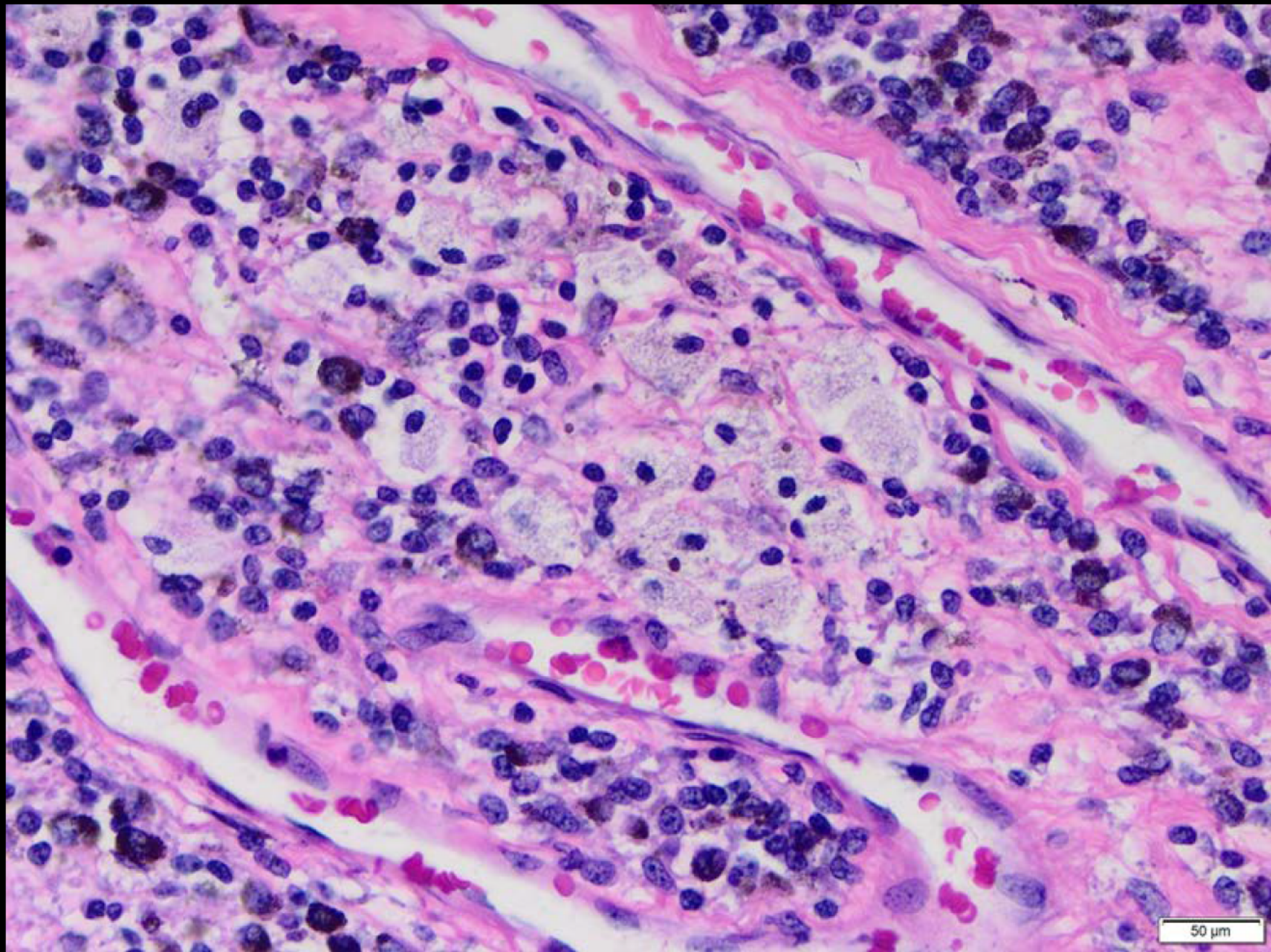
T1 GD

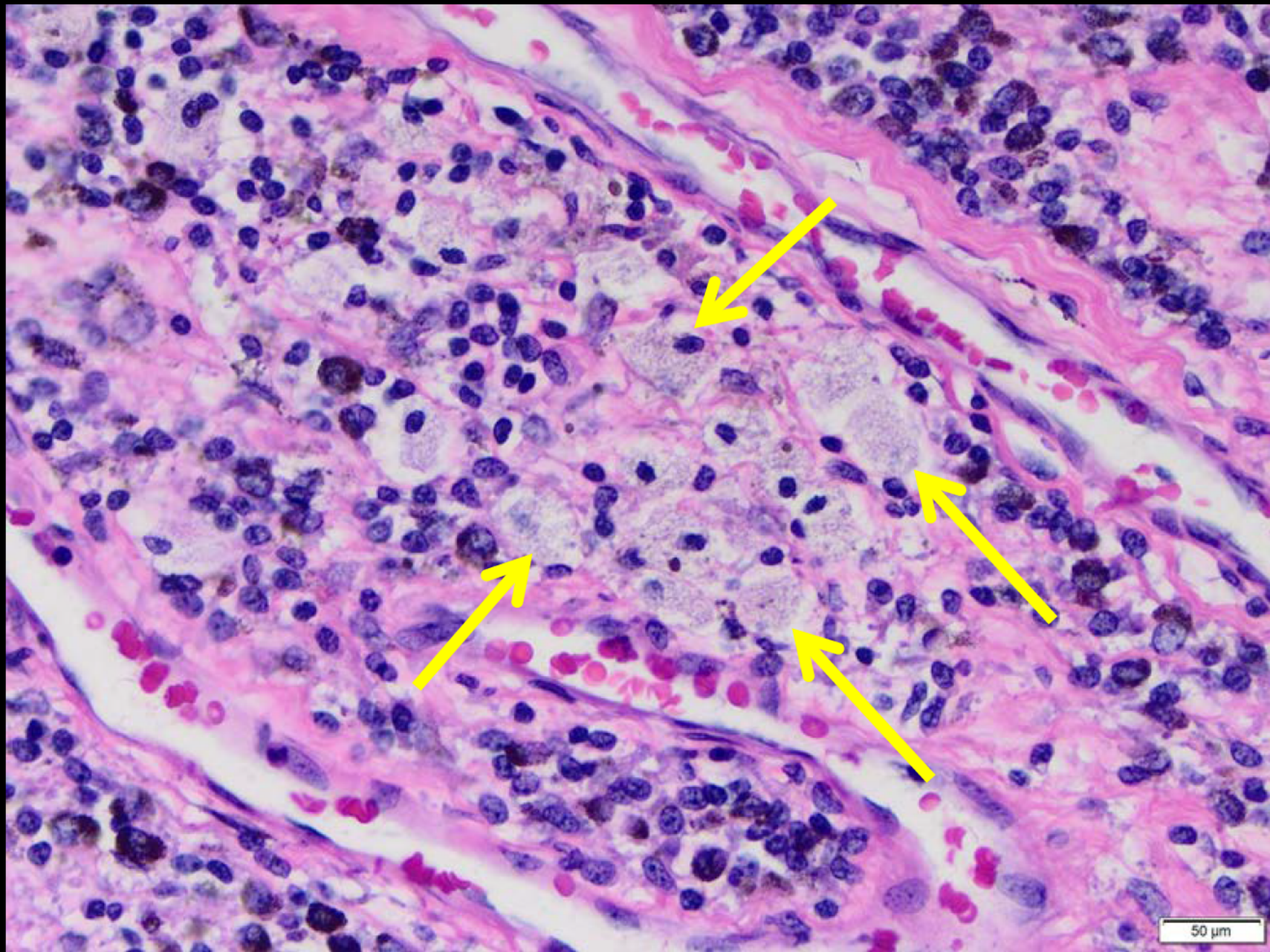


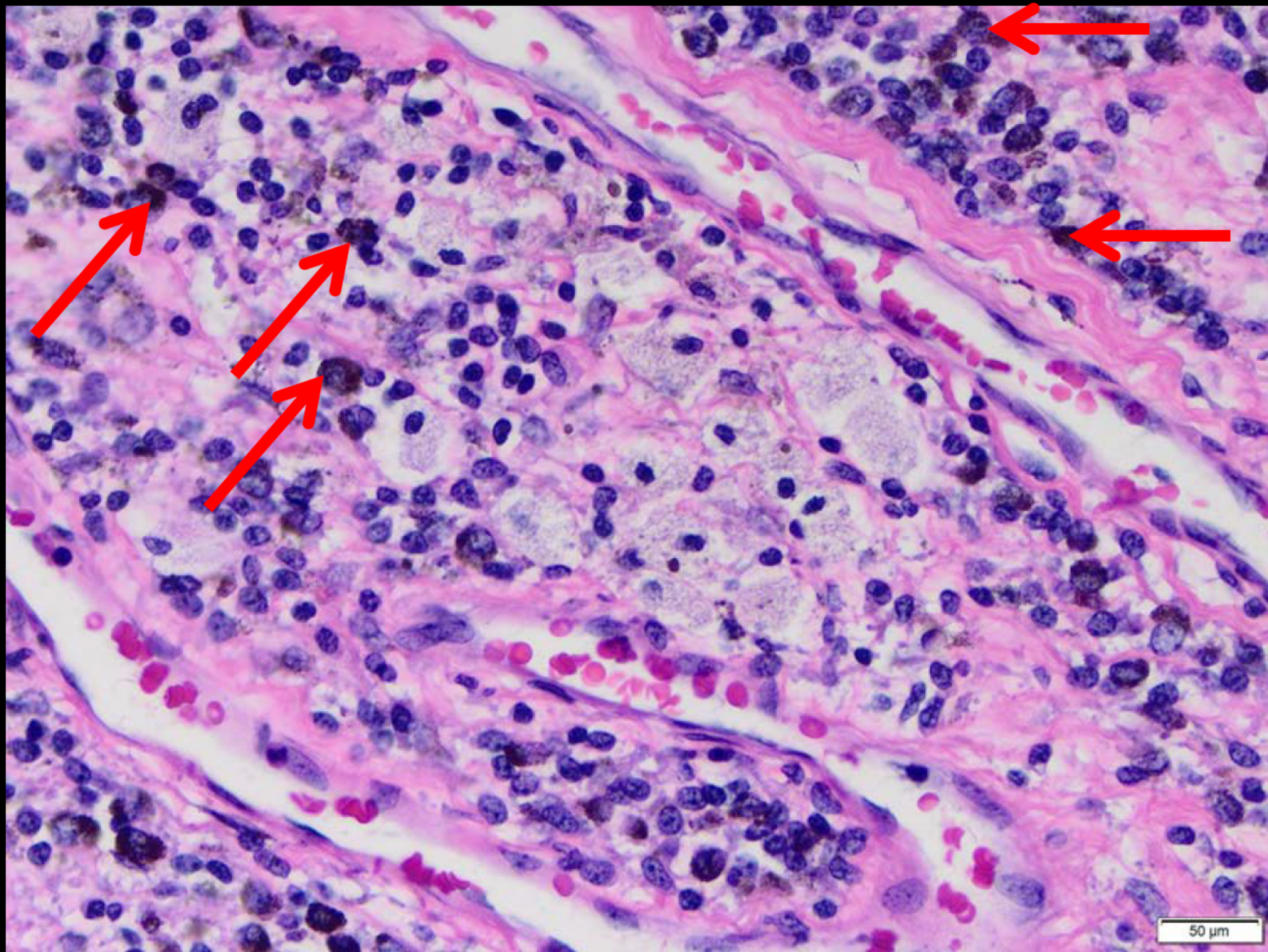




50 μ m



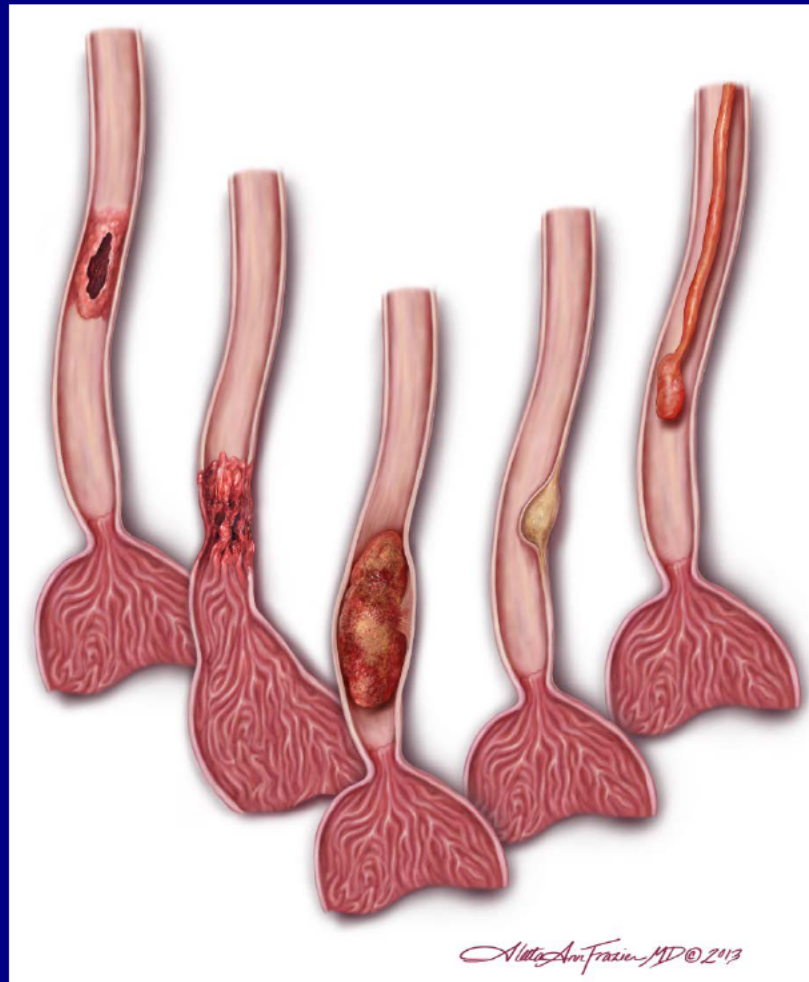



Pigmented Villonodular Synovitis

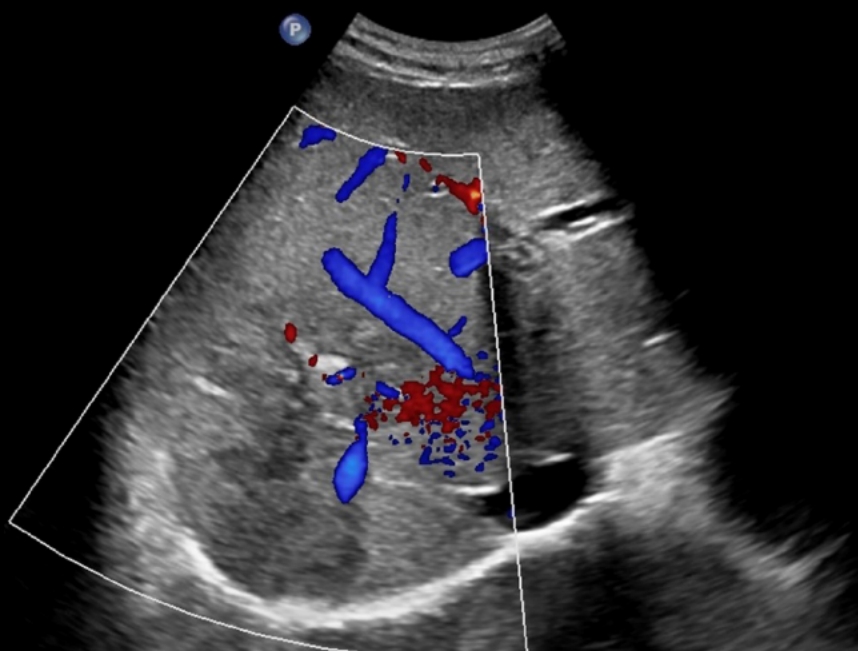
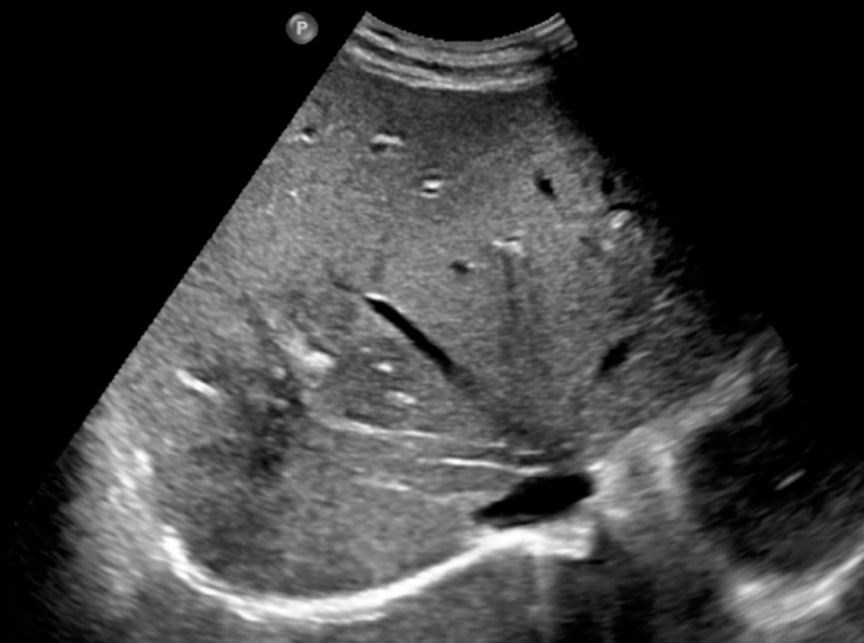
Dr. Haowei Zhang
University of Mississippi Medical Center
Jackson, Mississippi

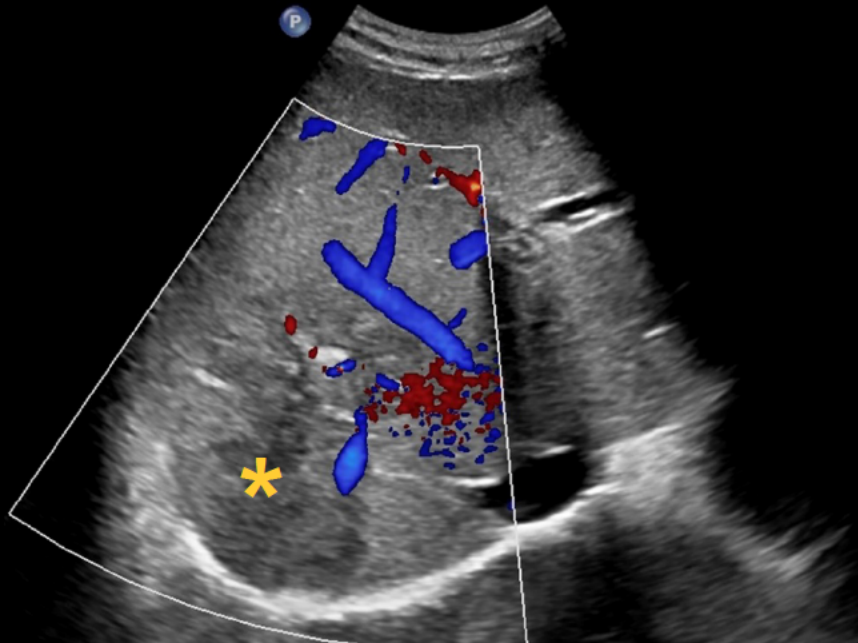
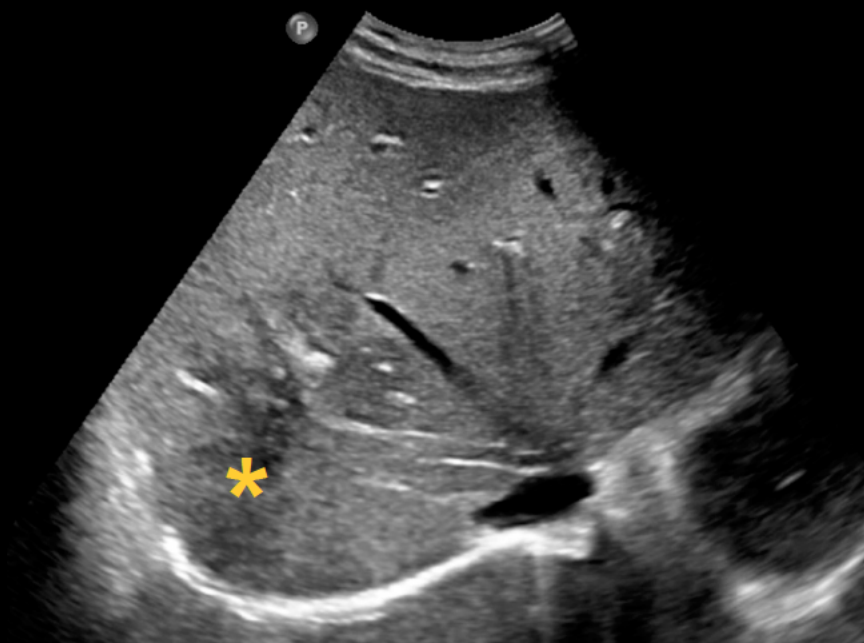Gastrointestinal Best Case

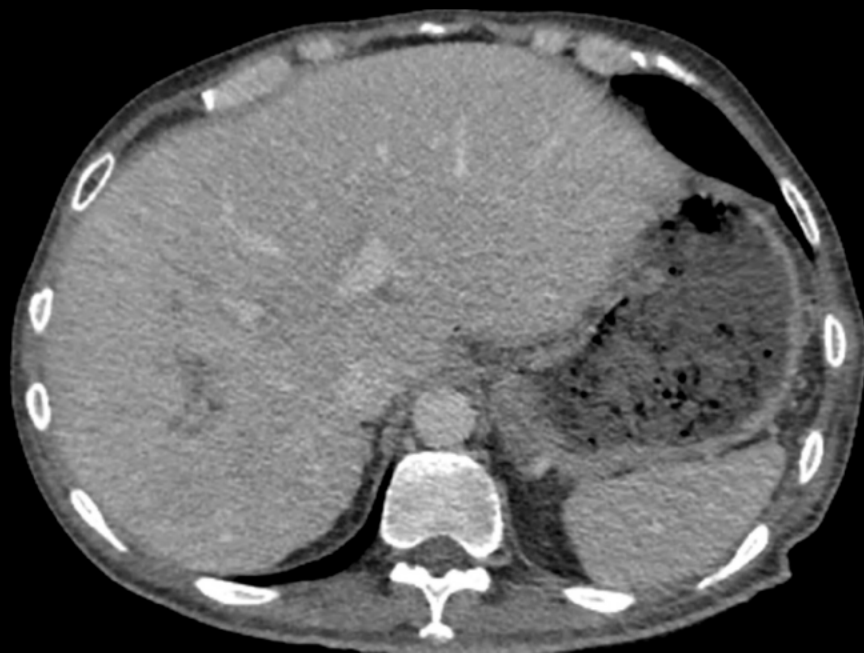
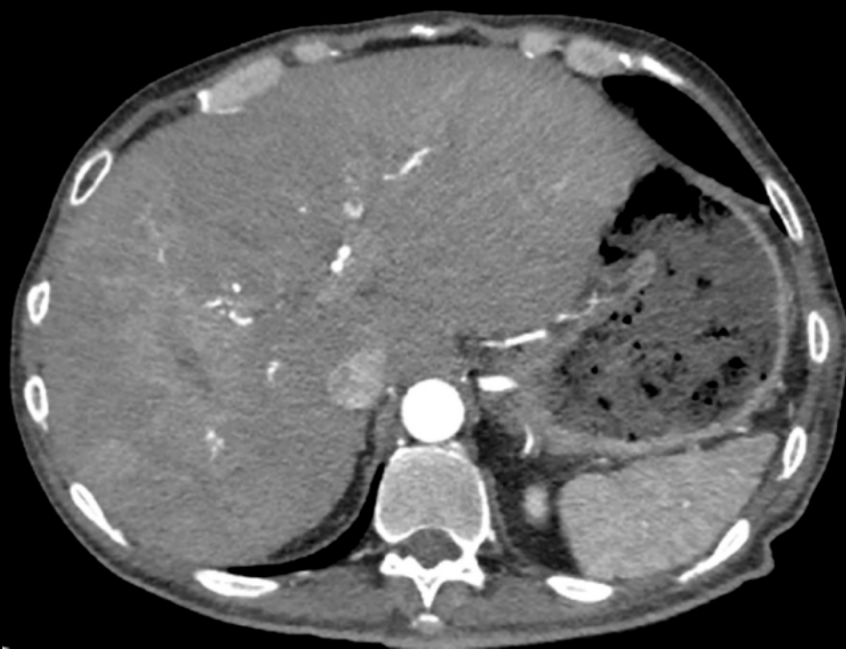
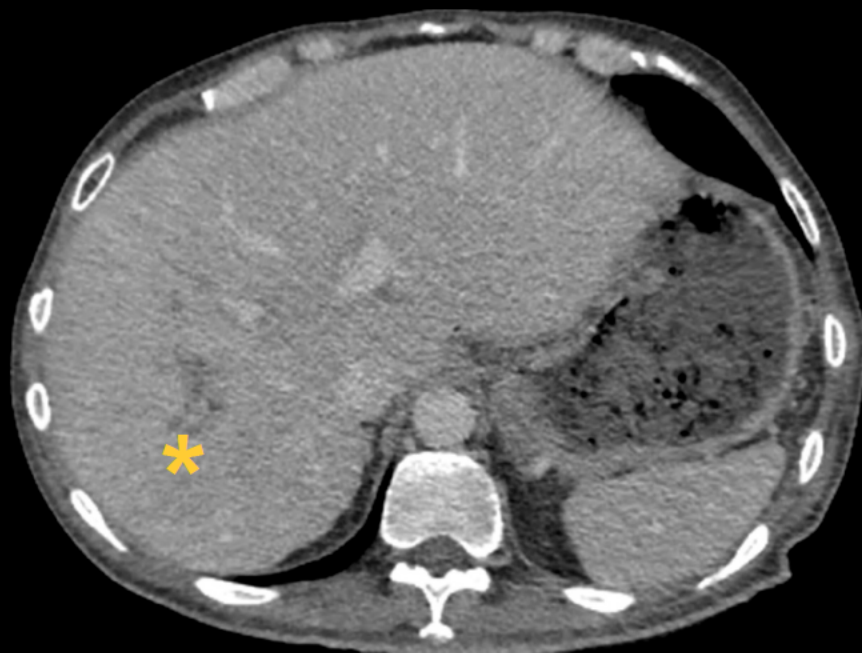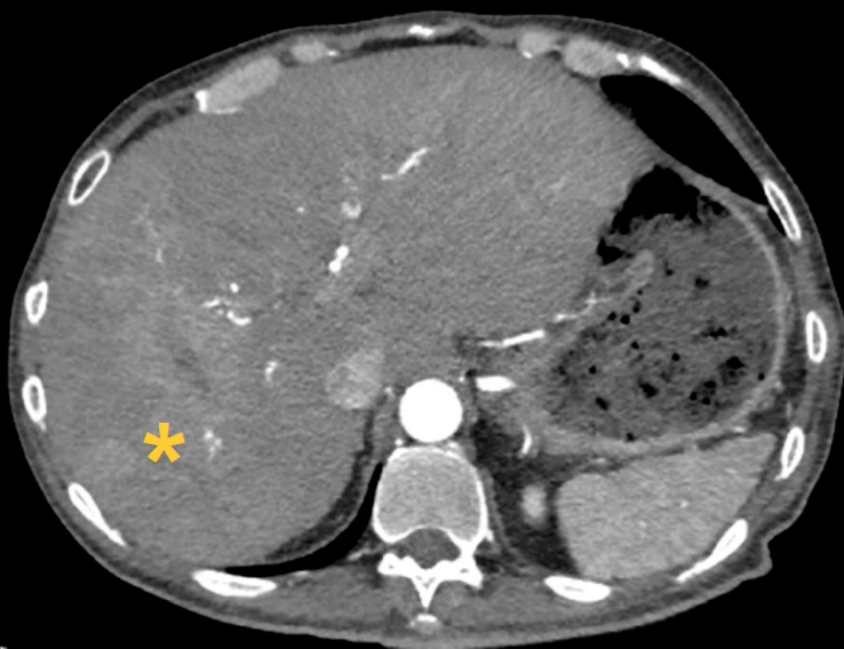
Clinical information

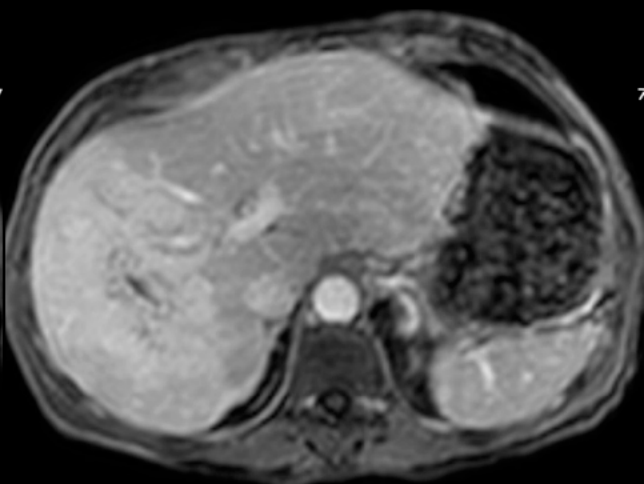
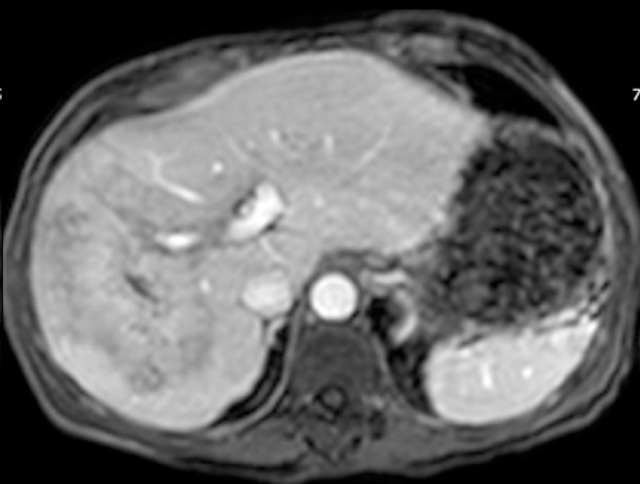
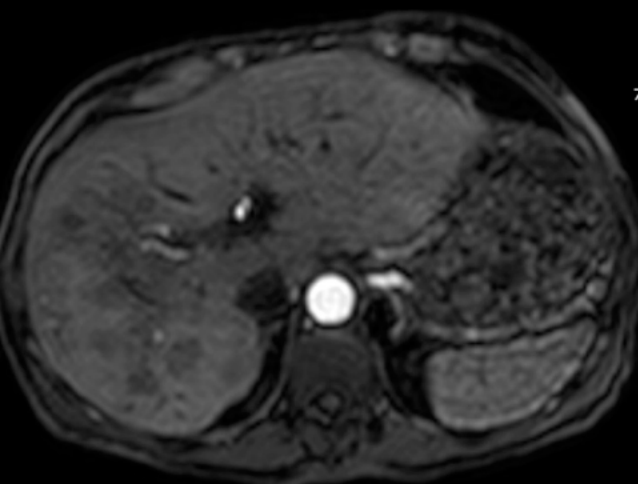
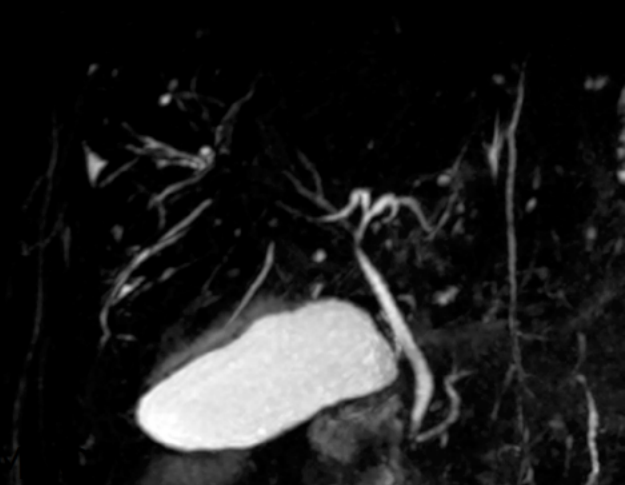
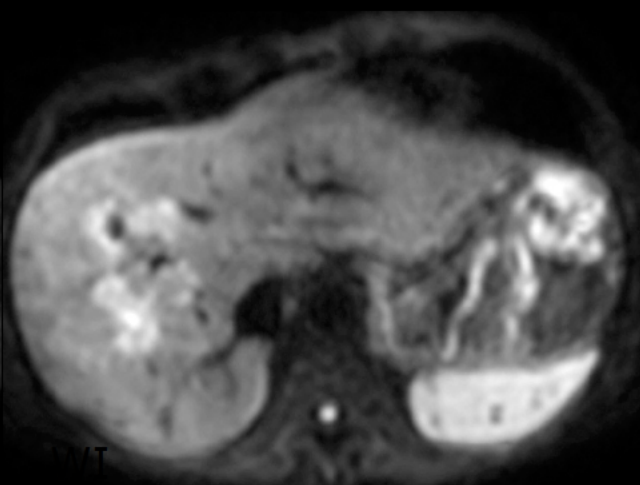
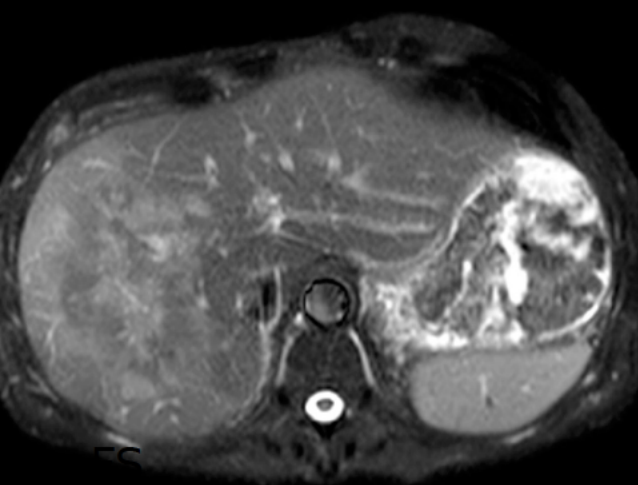
46 year old man with polyuria, polydipsia,
and polyphagia found to have
hyperglycemia and elevated LFTs.

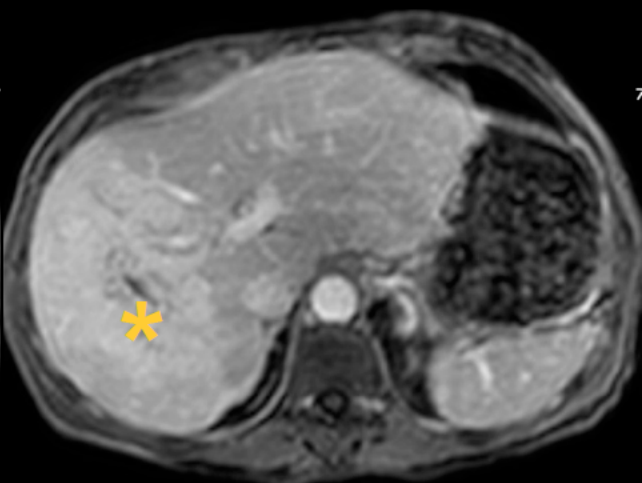
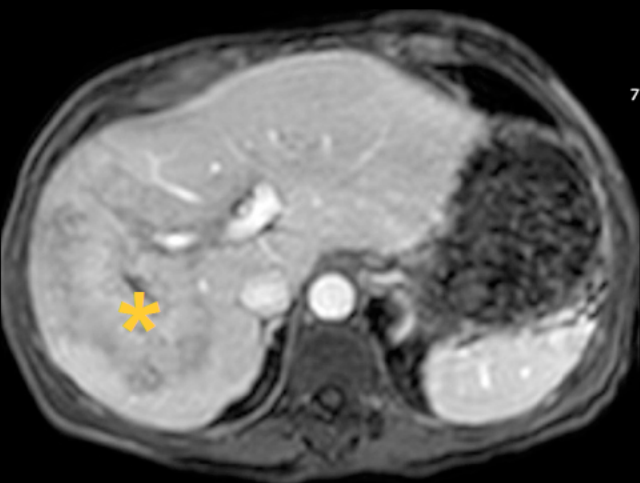
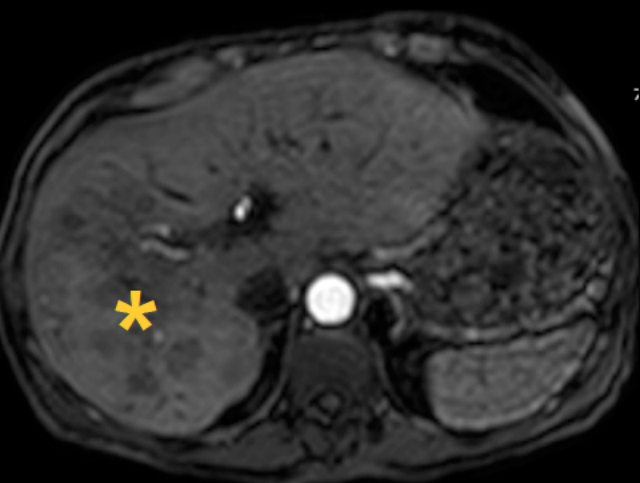
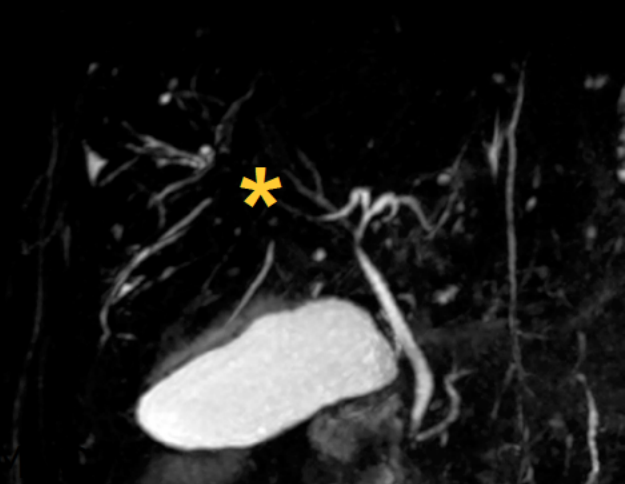
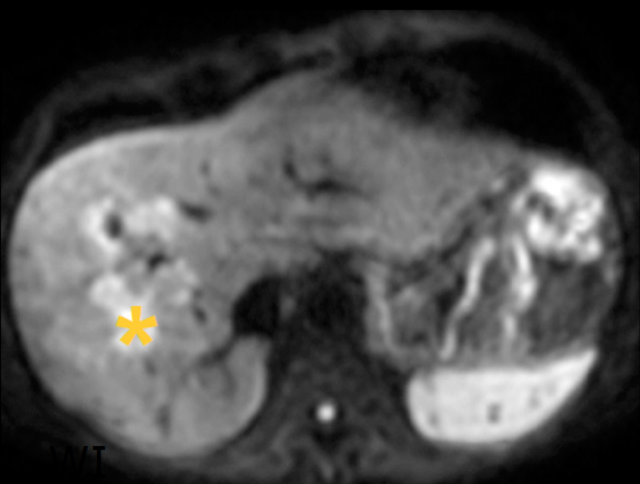
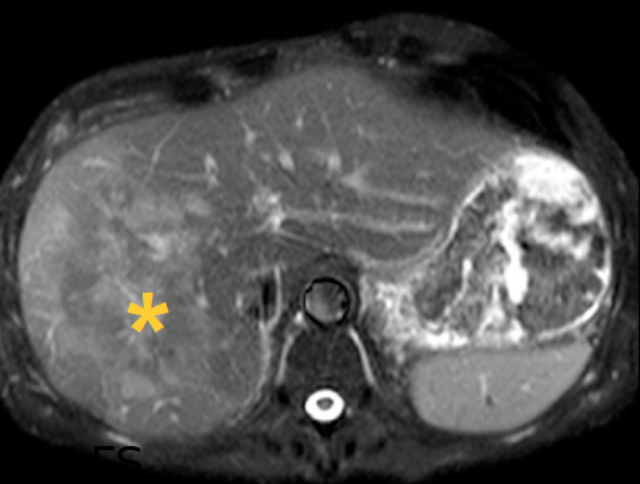


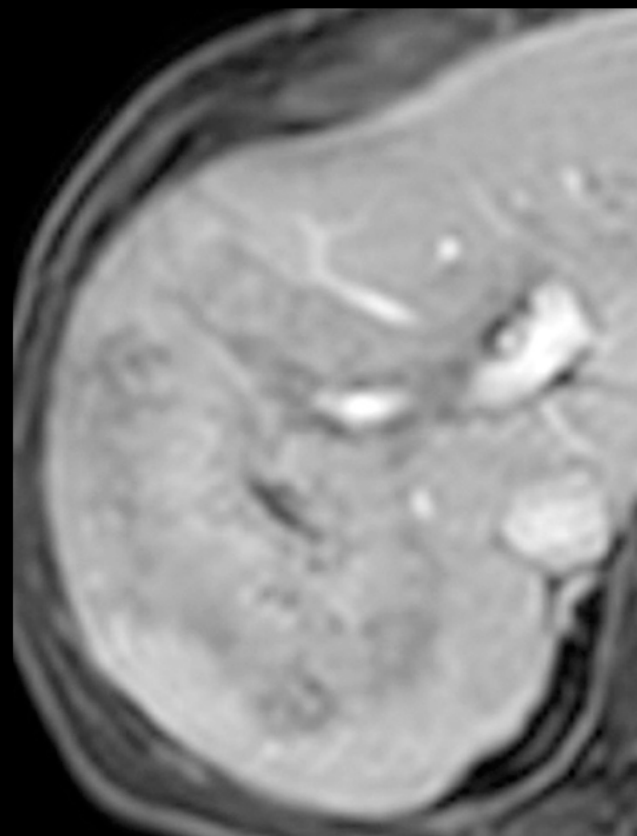
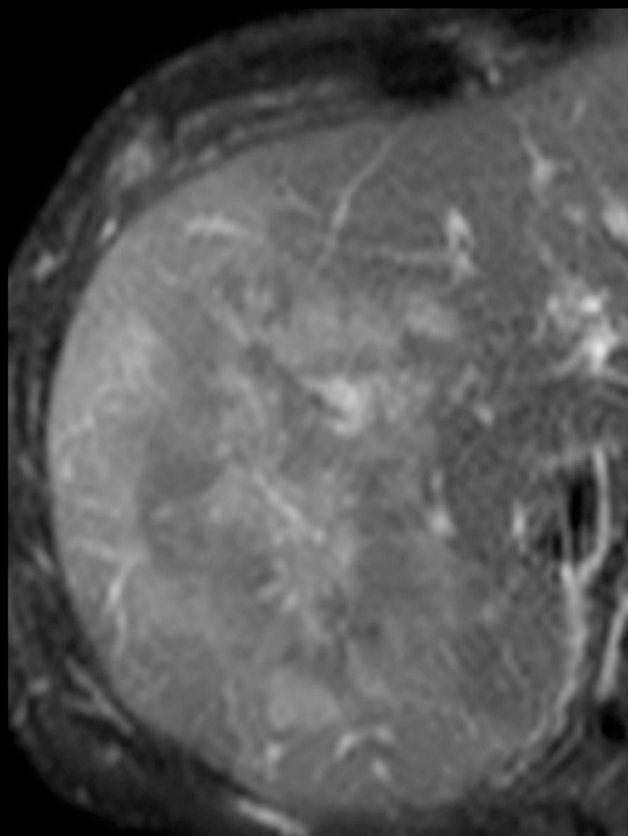
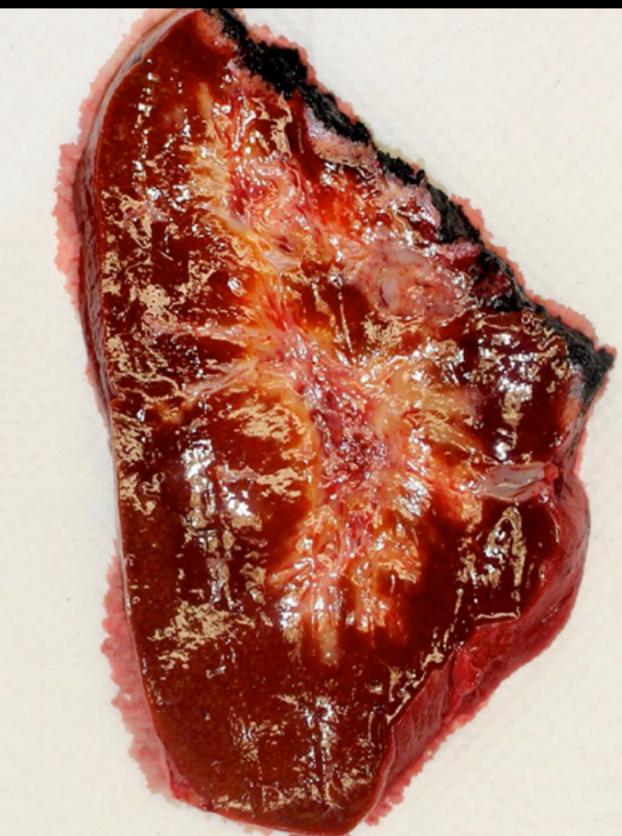


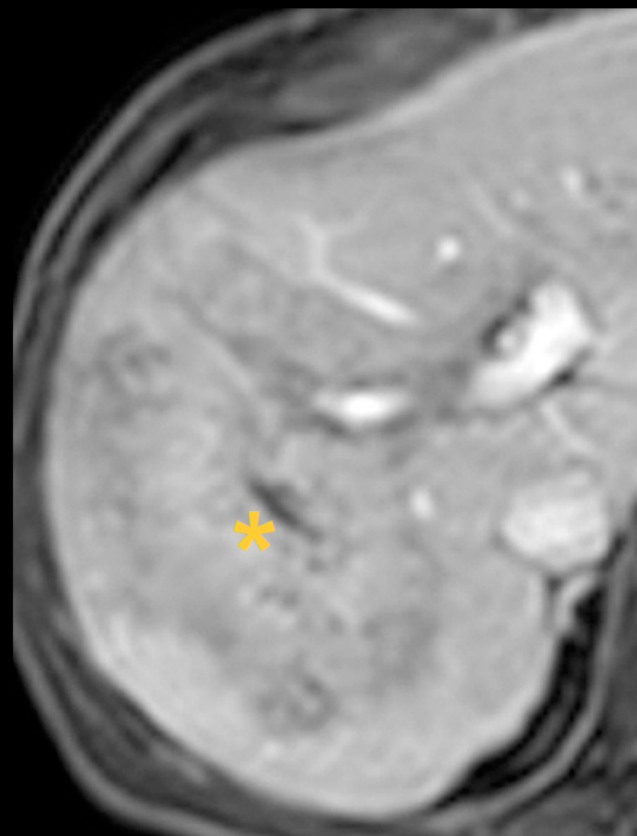
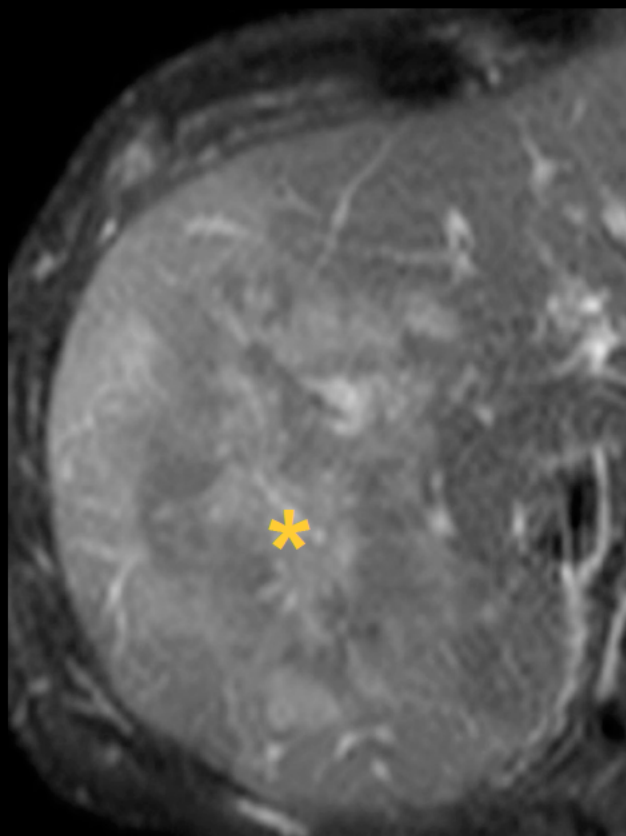
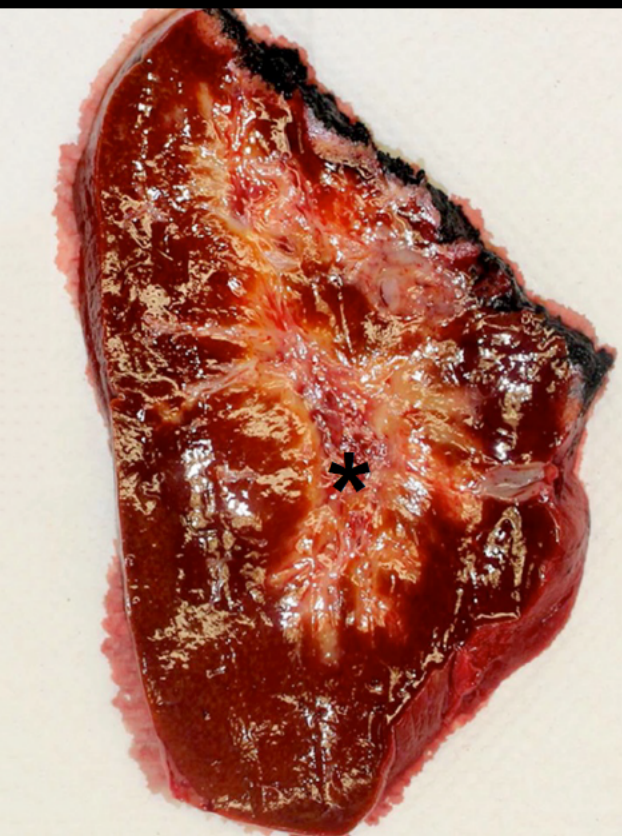


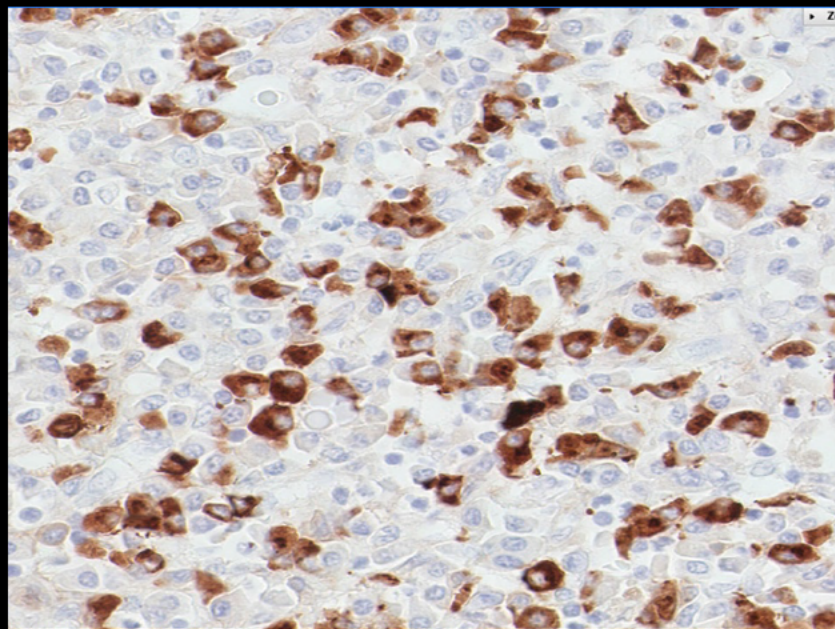
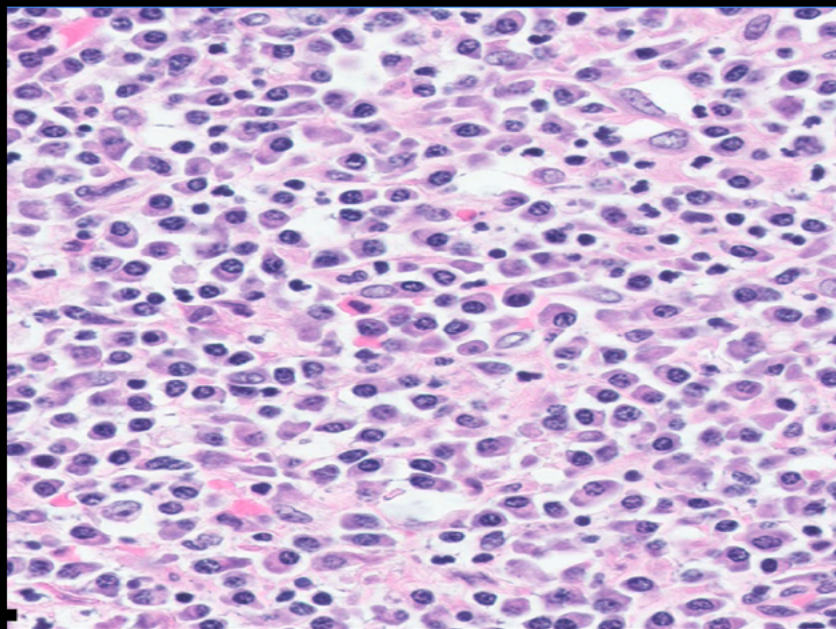
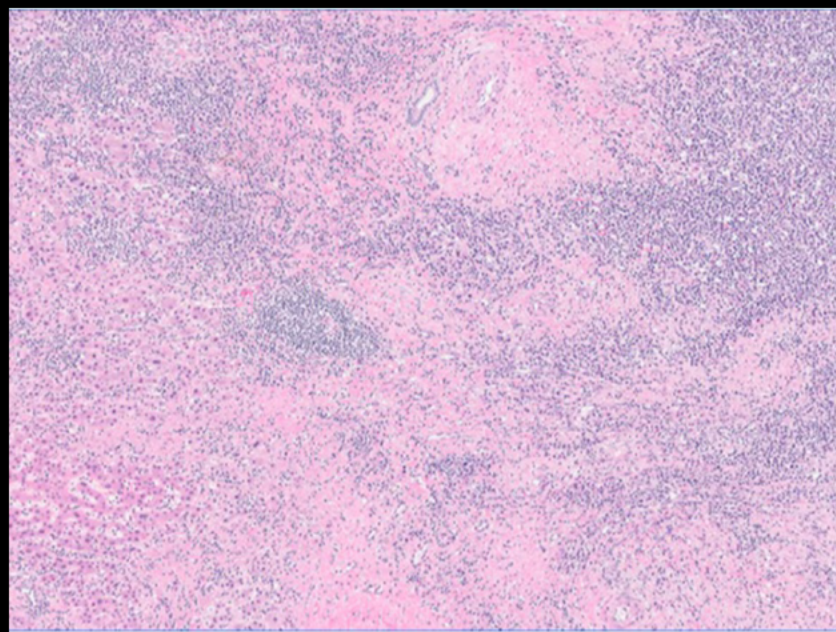


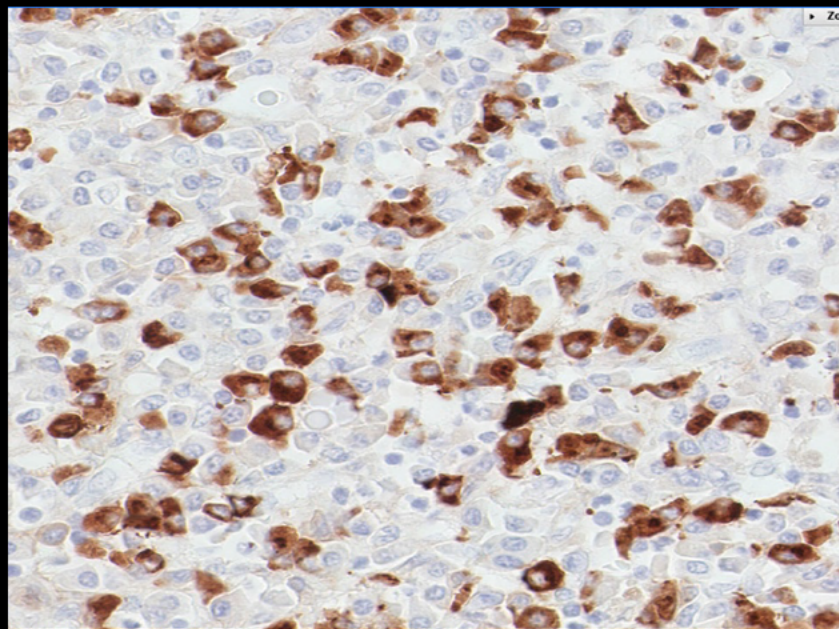
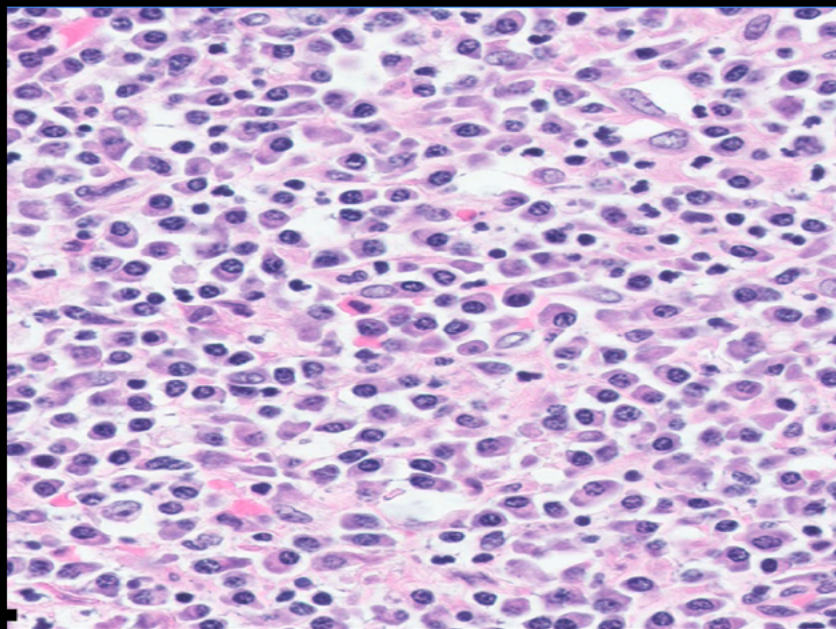
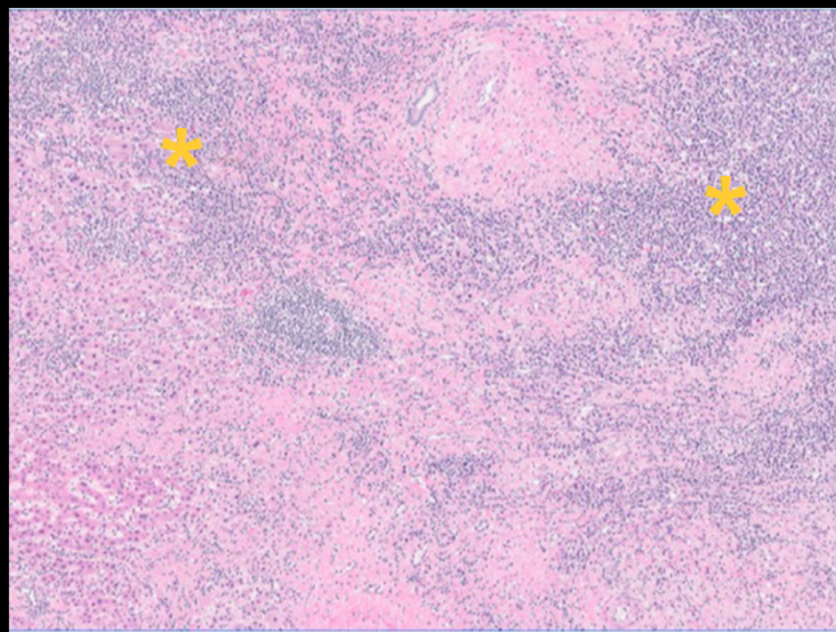








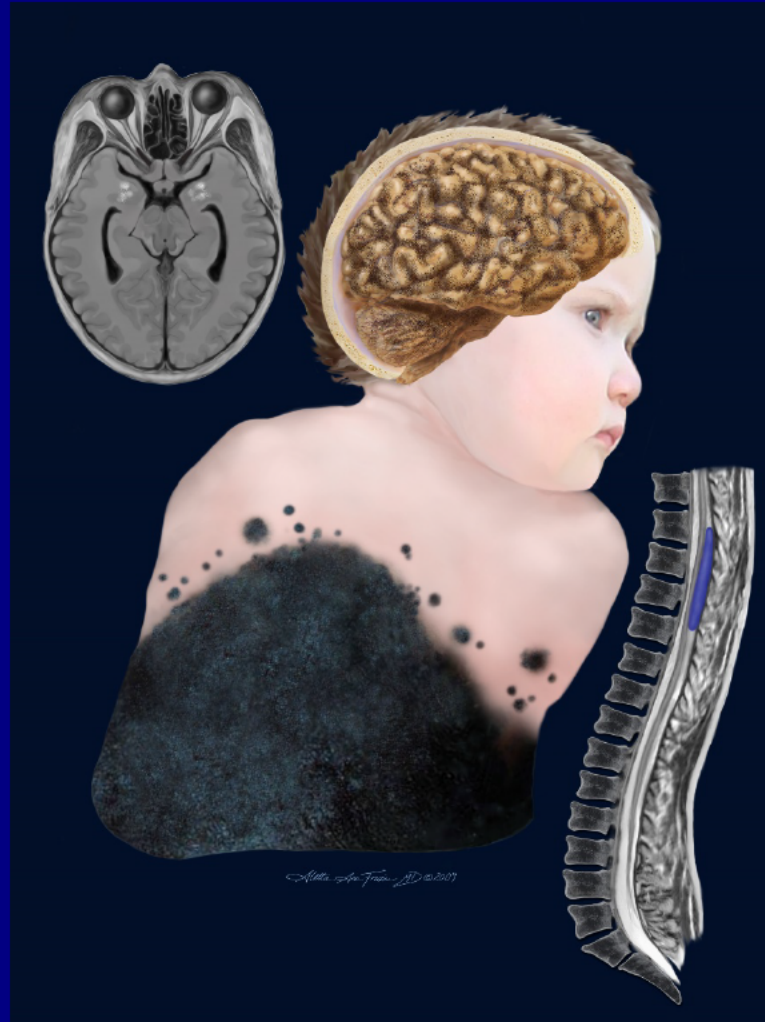



Inflammatory Pseudotumor IgG4-related disease

Jeffrey Gnerre, MD
Westchester Medical Center
Valhalla, New York

Neuroradiology Best Case



A Special Thank You

An unprecedented number (19 of 47) of submitted cases were finalists as a Neuroradiology Best Case. As the quality of these cases was so extraordinary, Dr. Koeller would like to recognize the contributing residents listed below. To all of you that added to the Neuroradiology archives...Thank you!

Omar Ashour

Joelle Brisson

Adam Bryant

Gregory Bryant

Joshua Finkle

Will Guest

Kathryn Henault

Jennifer Joyce

Cody Larson

Chia-Ying Lin

Therese Lincke

Pedro Lourenco

Keshav Menon

Kritdipha Ningunha

Martin Oberschmied

Krishna Patel

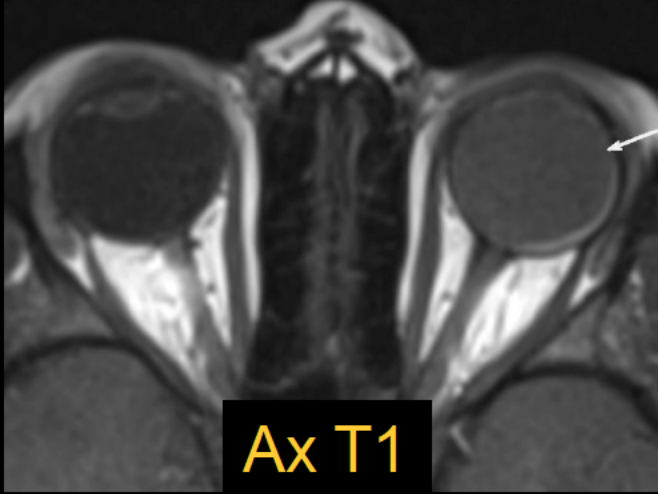
Rodrigo Sanchez

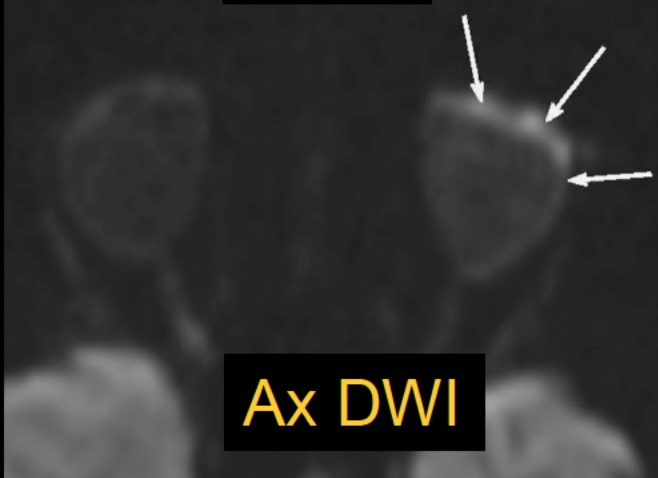
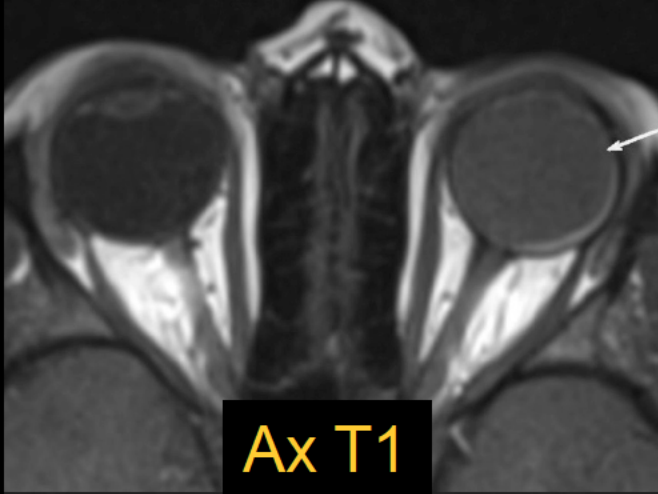
Ravi Sheth

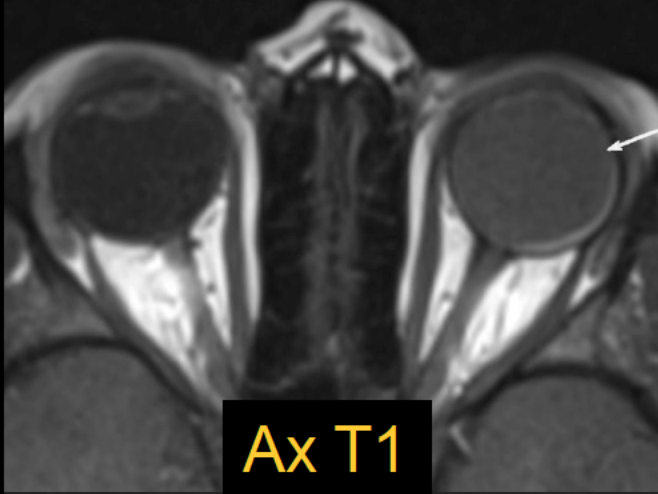
David Wen

Clinical Information

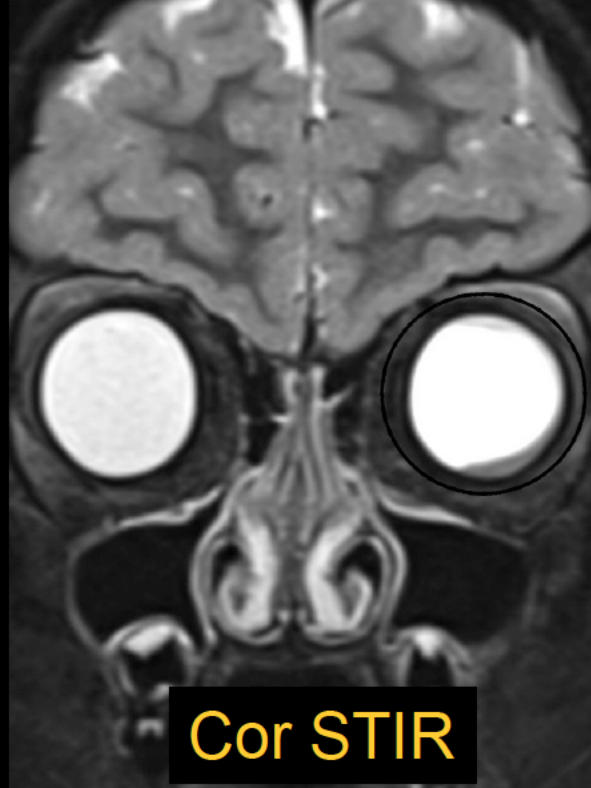
7-year-old female with 3 months of
left eye drifting and blurred vision.
Known DICER1 mutation



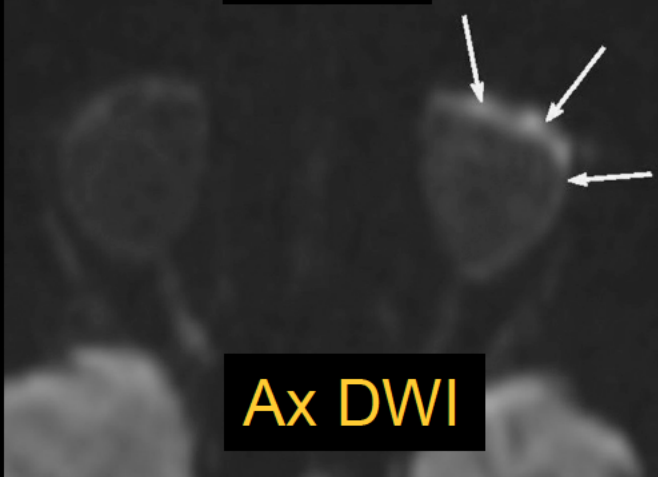




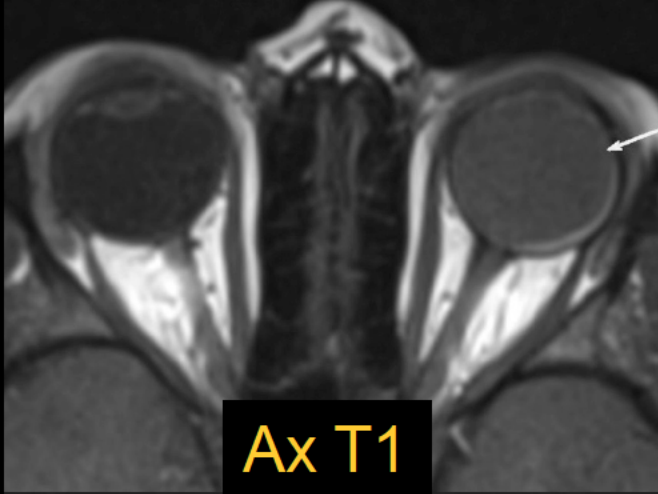
Ax T1



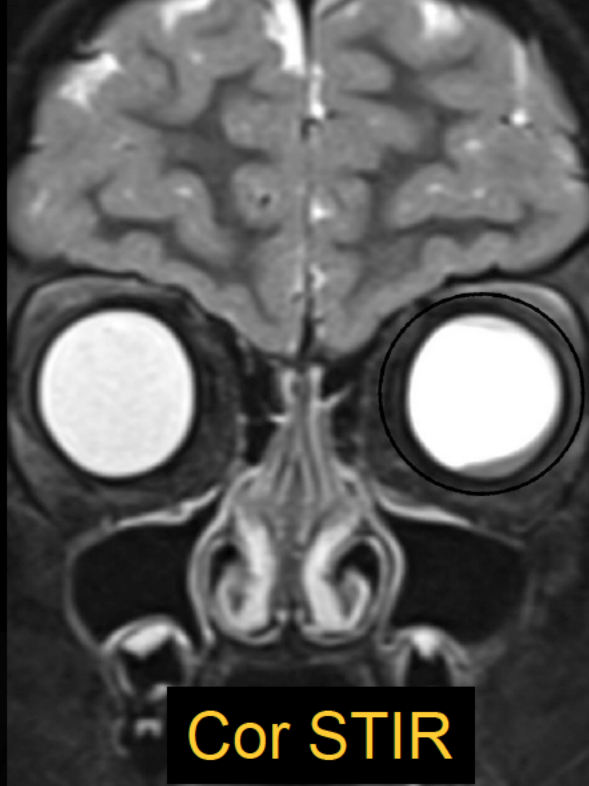
Cor STIR



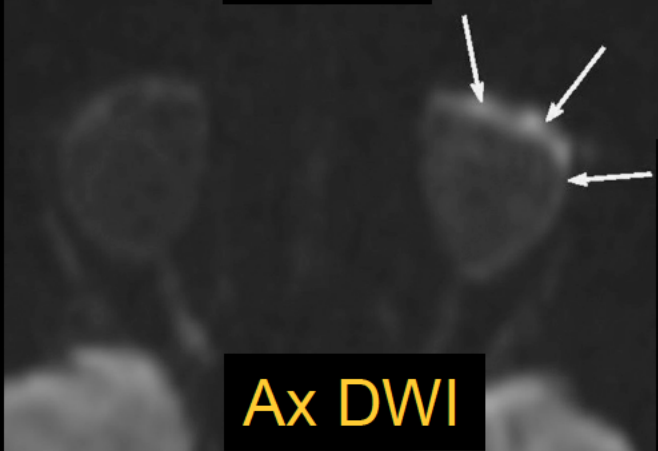
Ax DWI



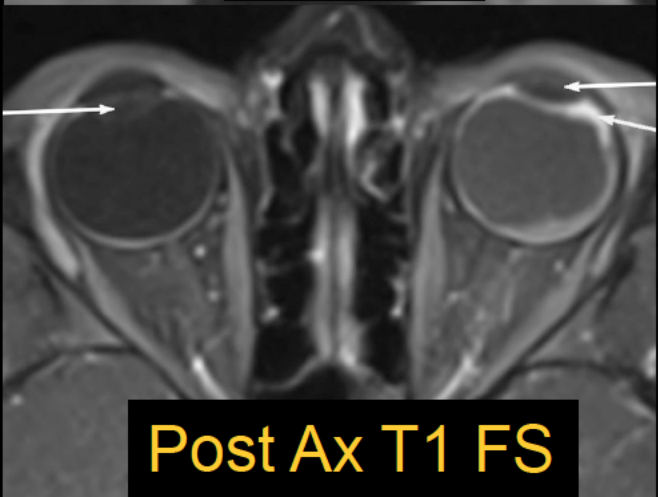
Ax T1



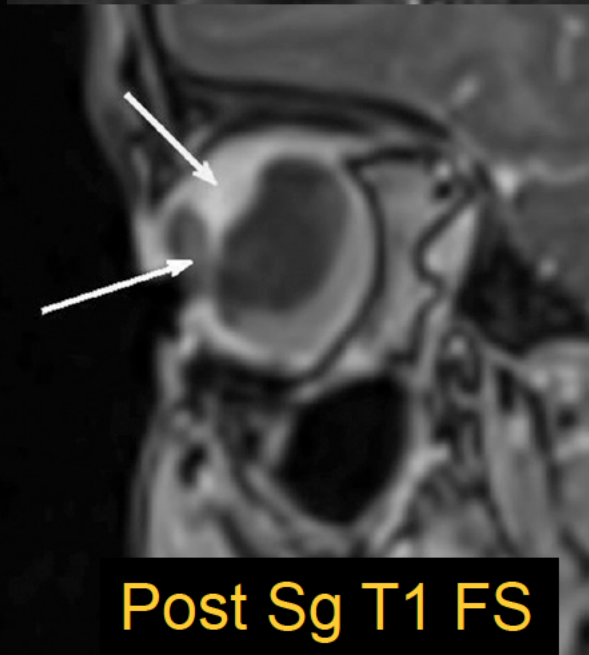
Cor STIR



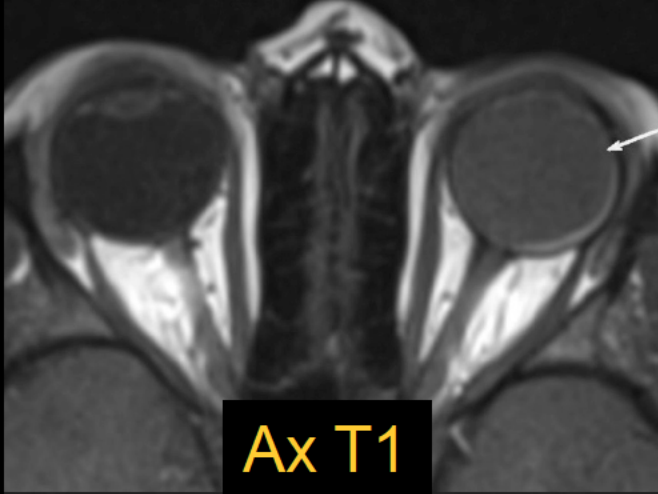
Ax DWI



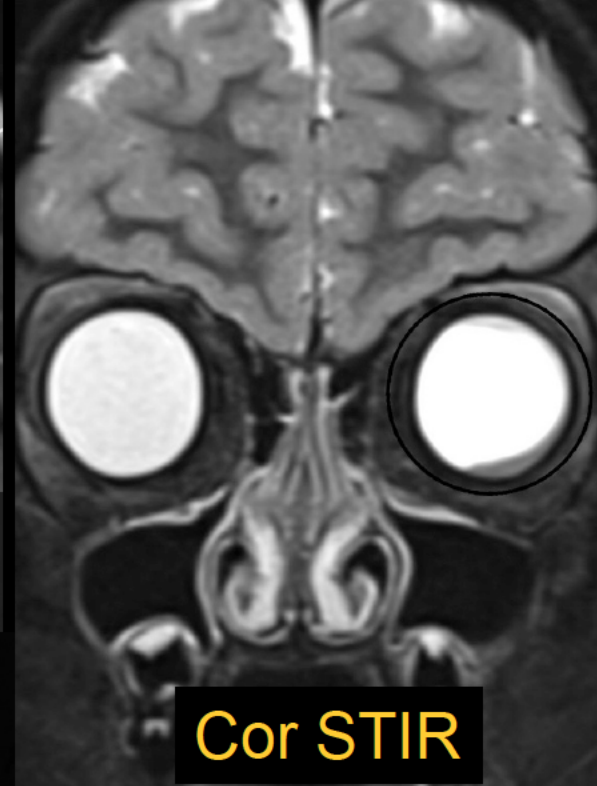
Post Ax T1 FS



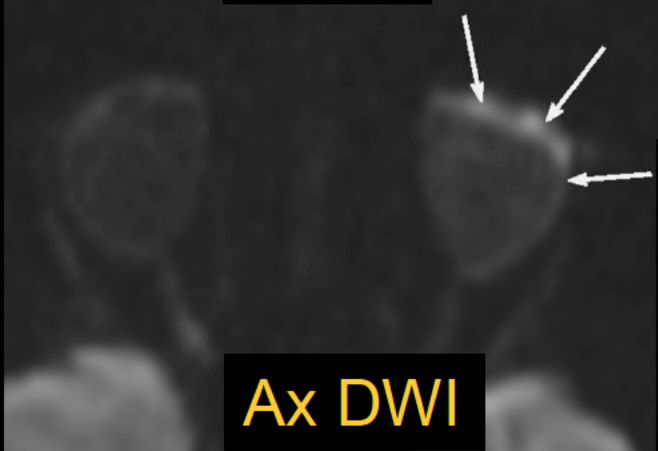
Post Sg T1 FS



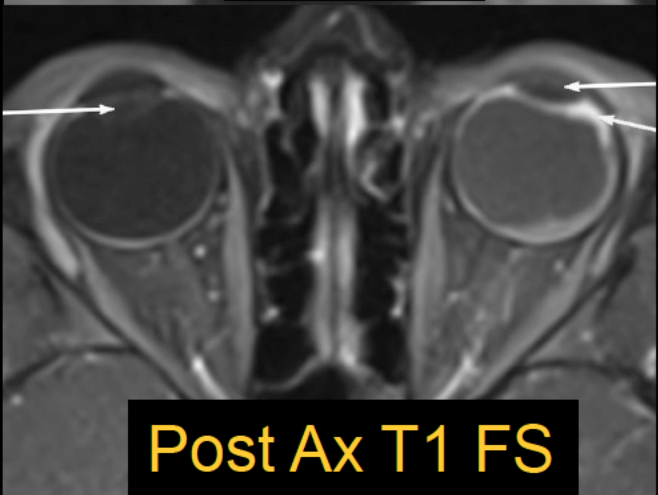
Ax T1



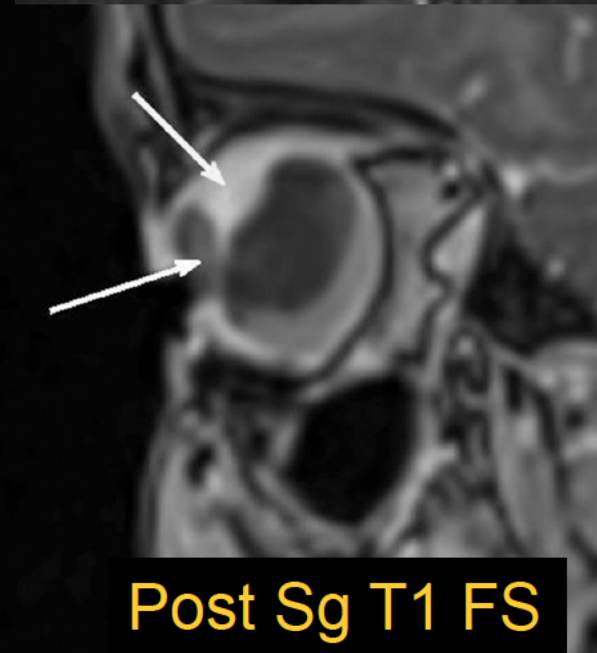
Cor STIR



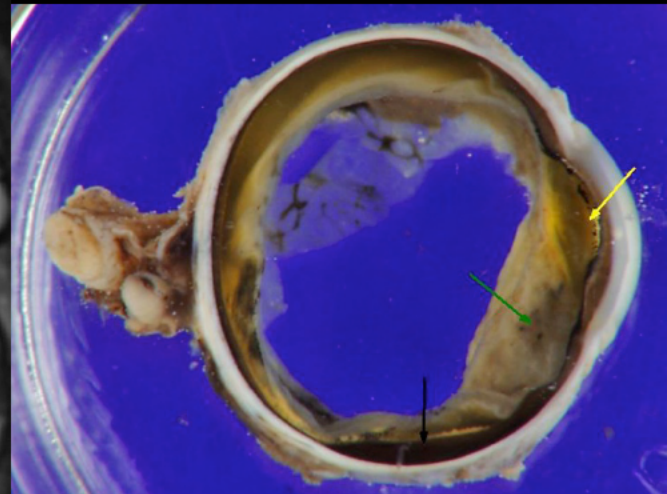
Ax DWI

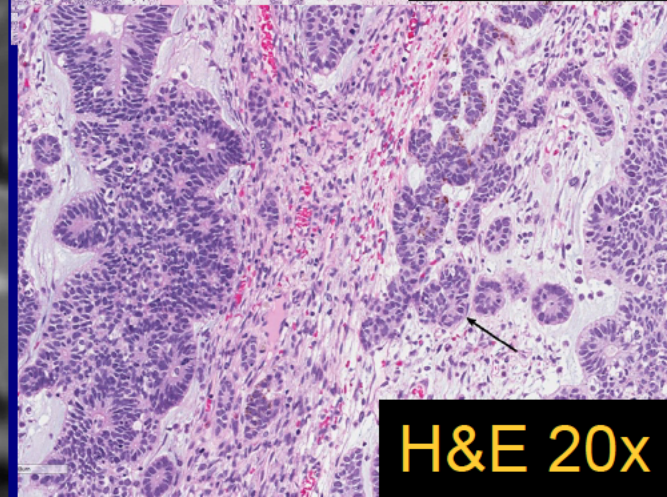
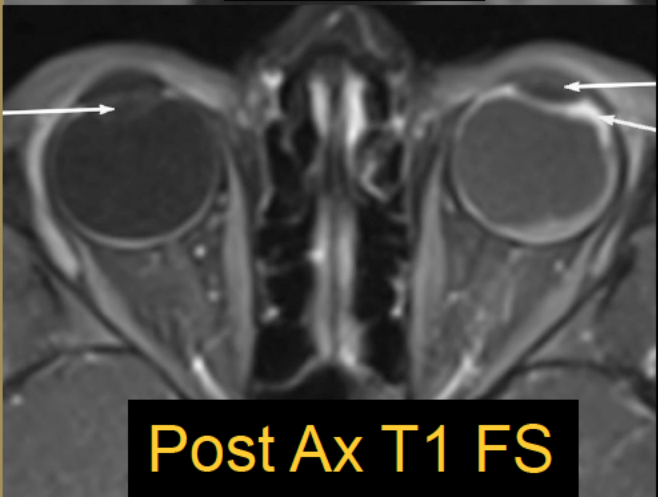
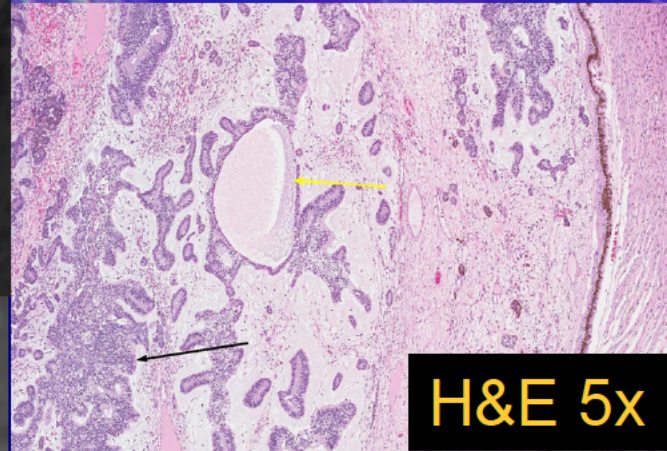
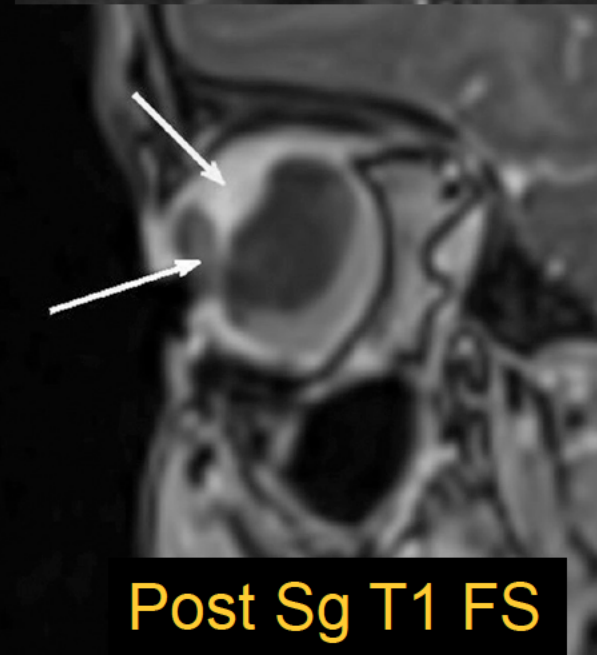
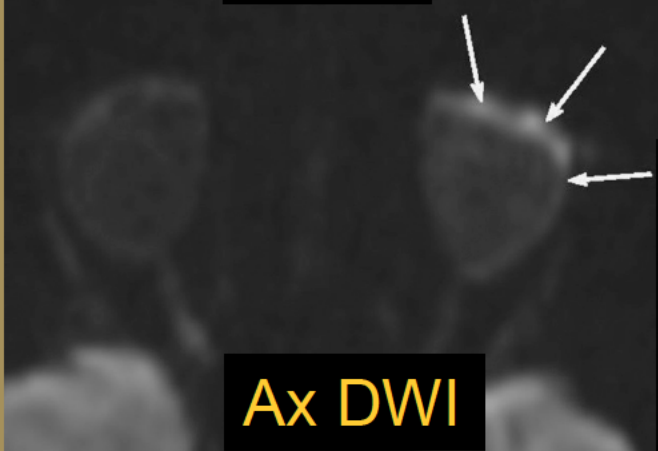
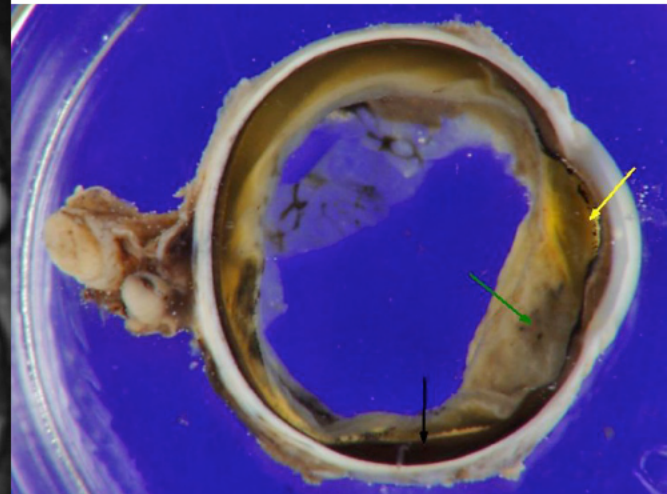
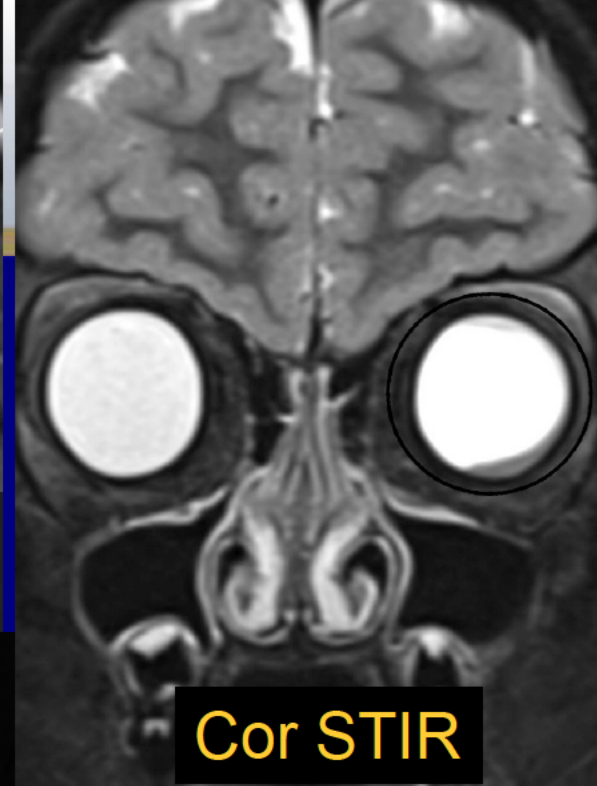
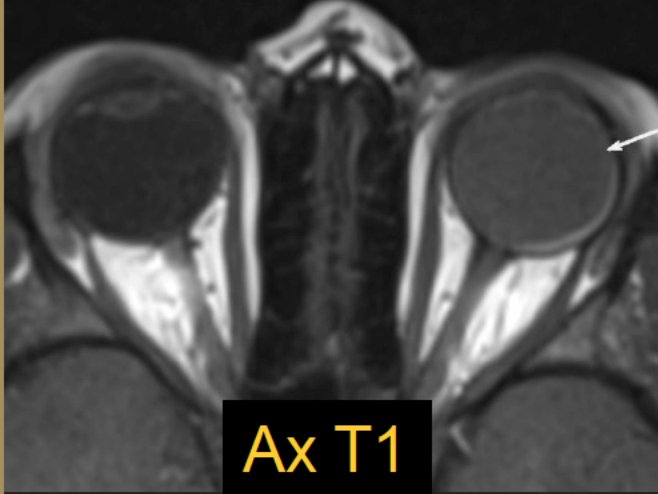


Post Ax T1 FS



Post Sg T1 FS





Intraocular Medulloepithelioma

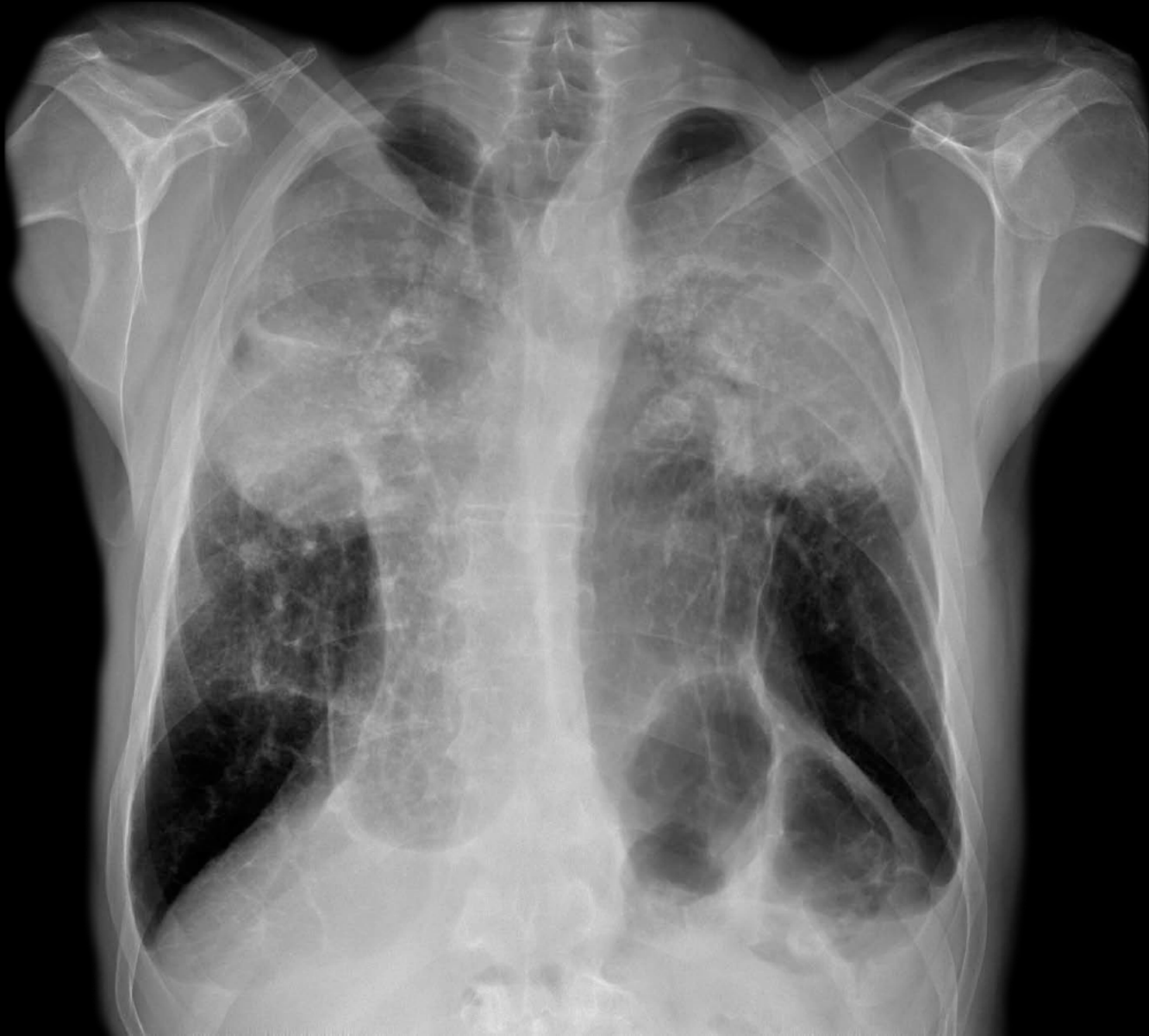Omar Ashour, M.D.
Nationwide Children's Hospital
The Ohio State University
Columbus, Ohio



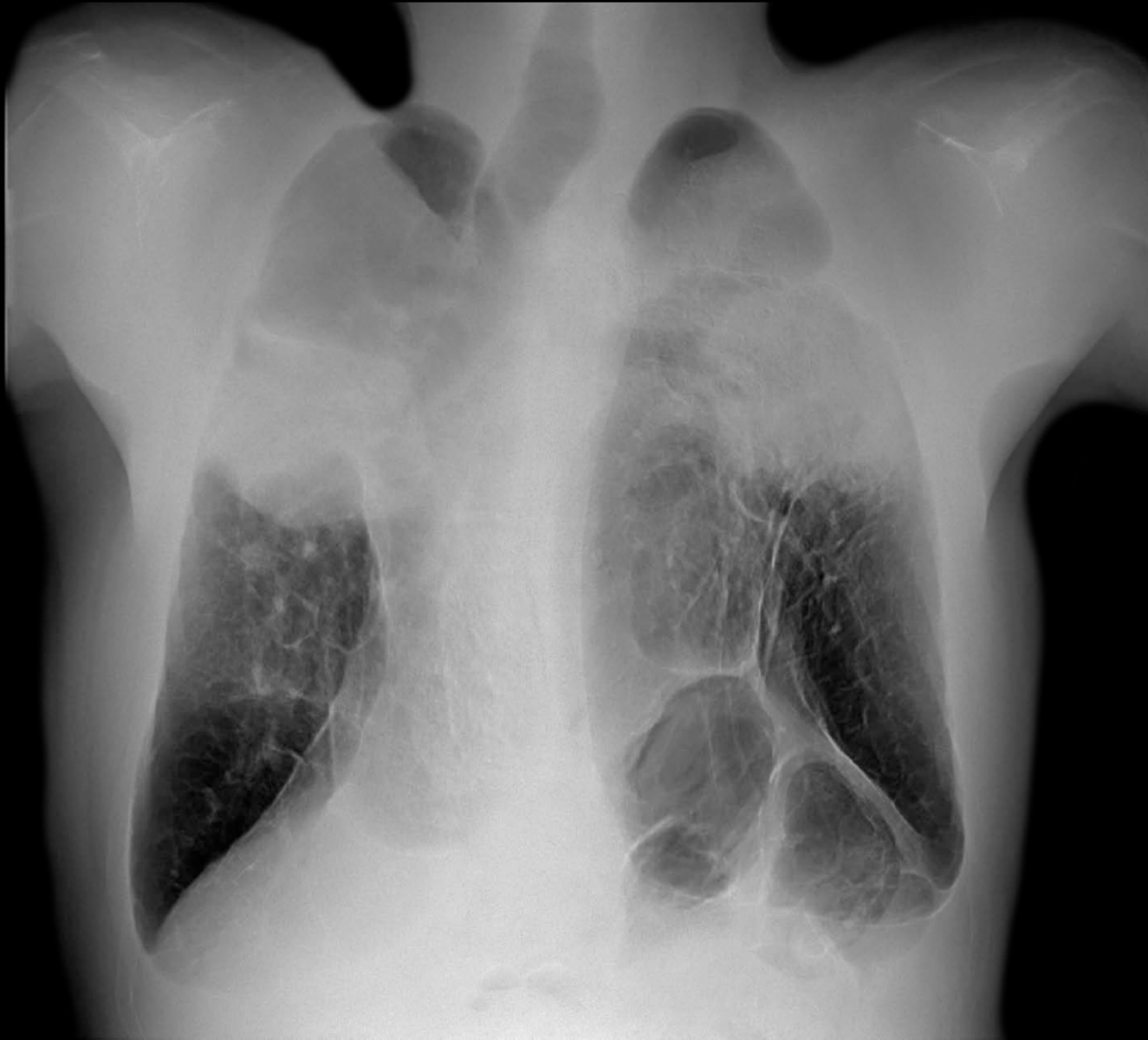Clinical Information

59 year old non-smoker male who presents with chronic dyspnea. The patient worked in a coal mine for 23 years

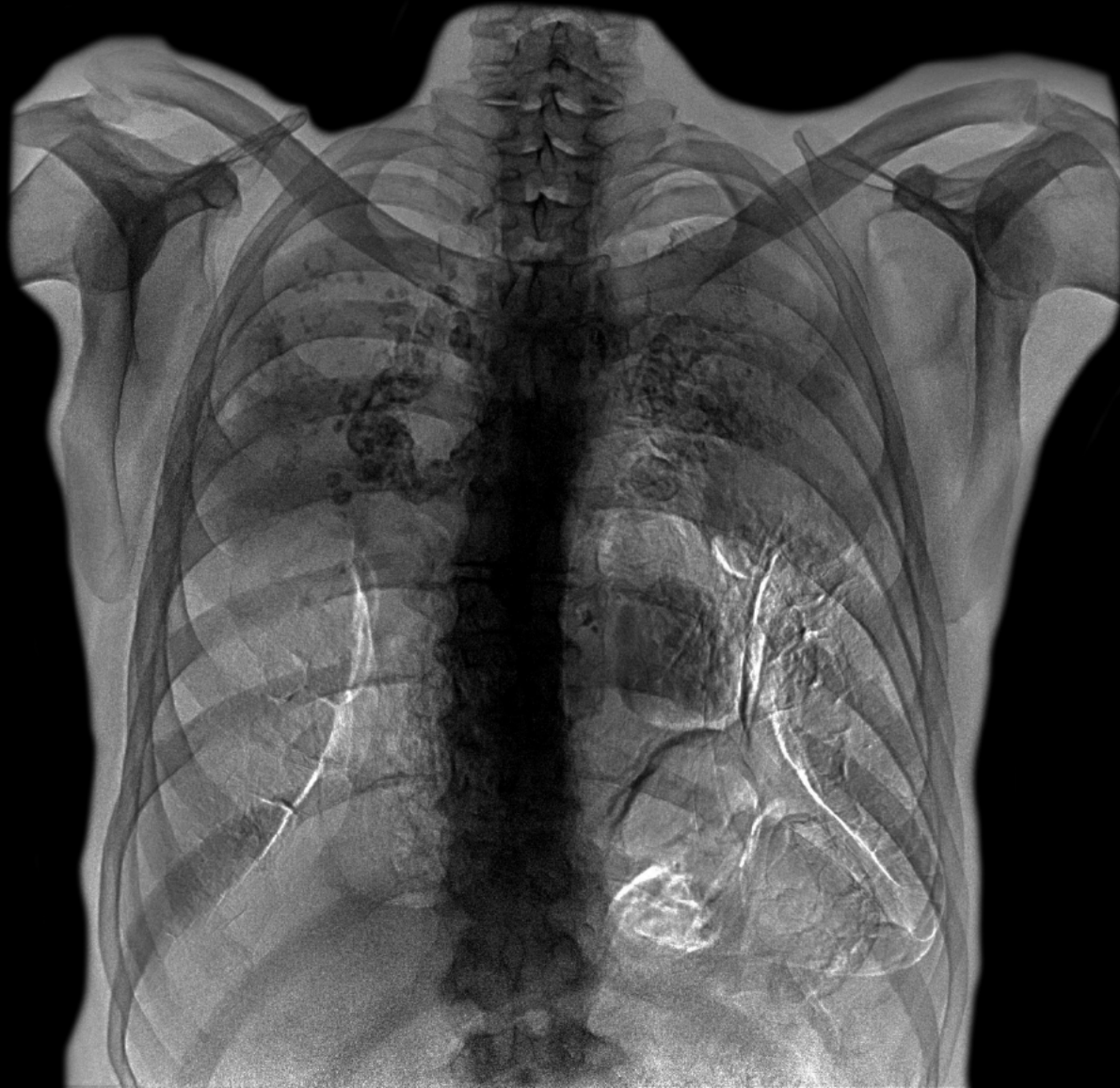PA: bilateral upper lobe masses



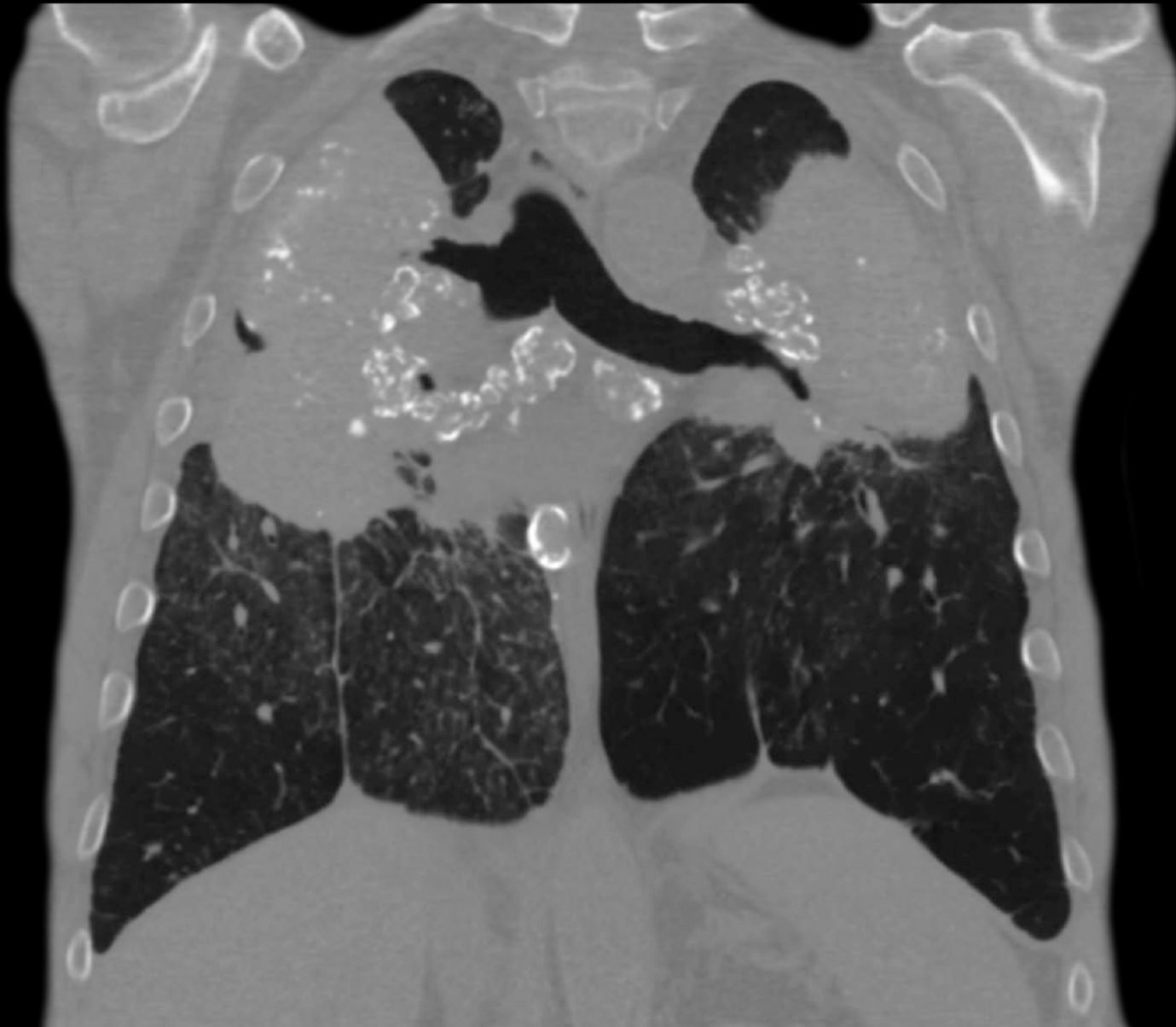Subtraction: bilateral upper lobe masses



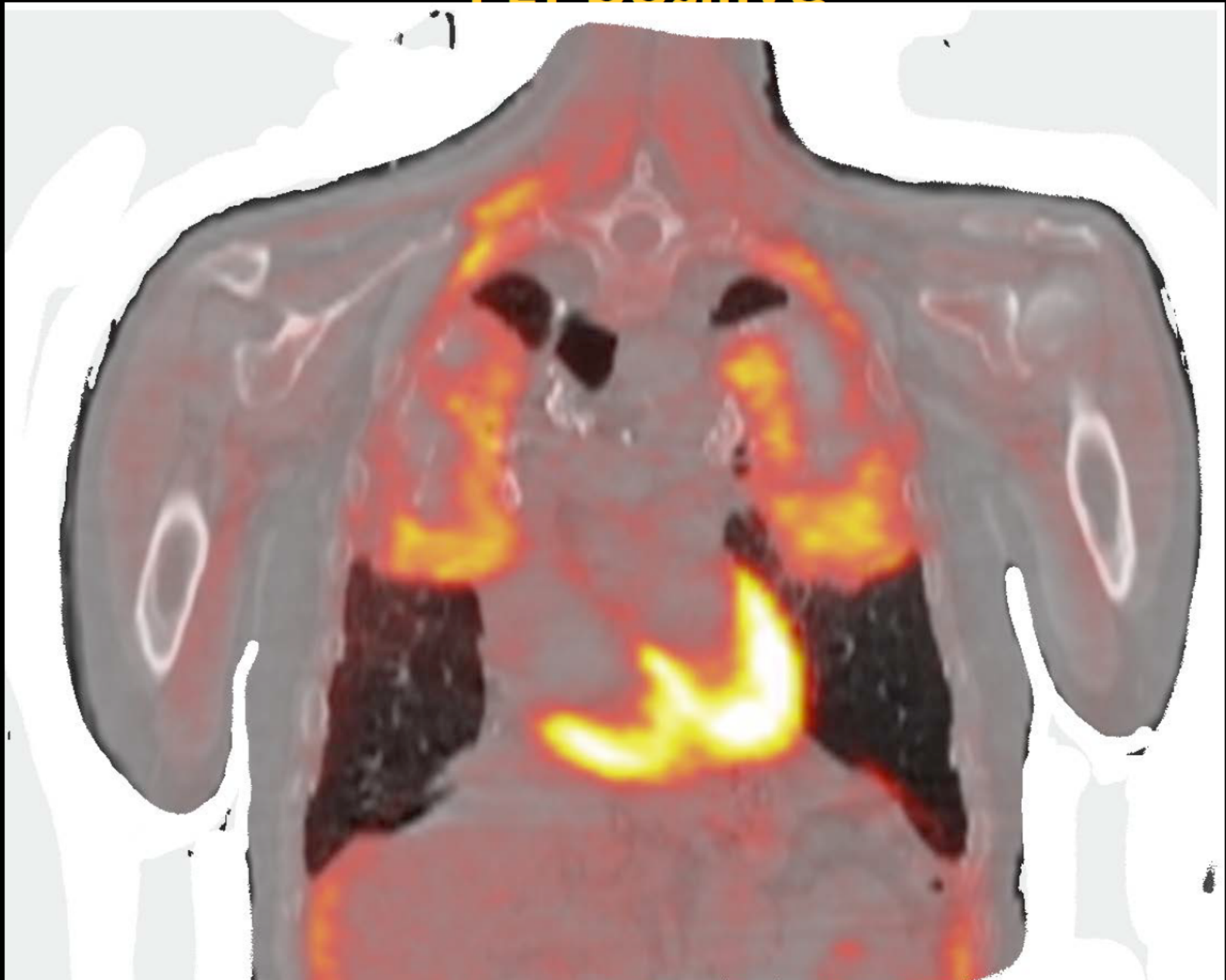
Dual energy: “eggshell calcifications”



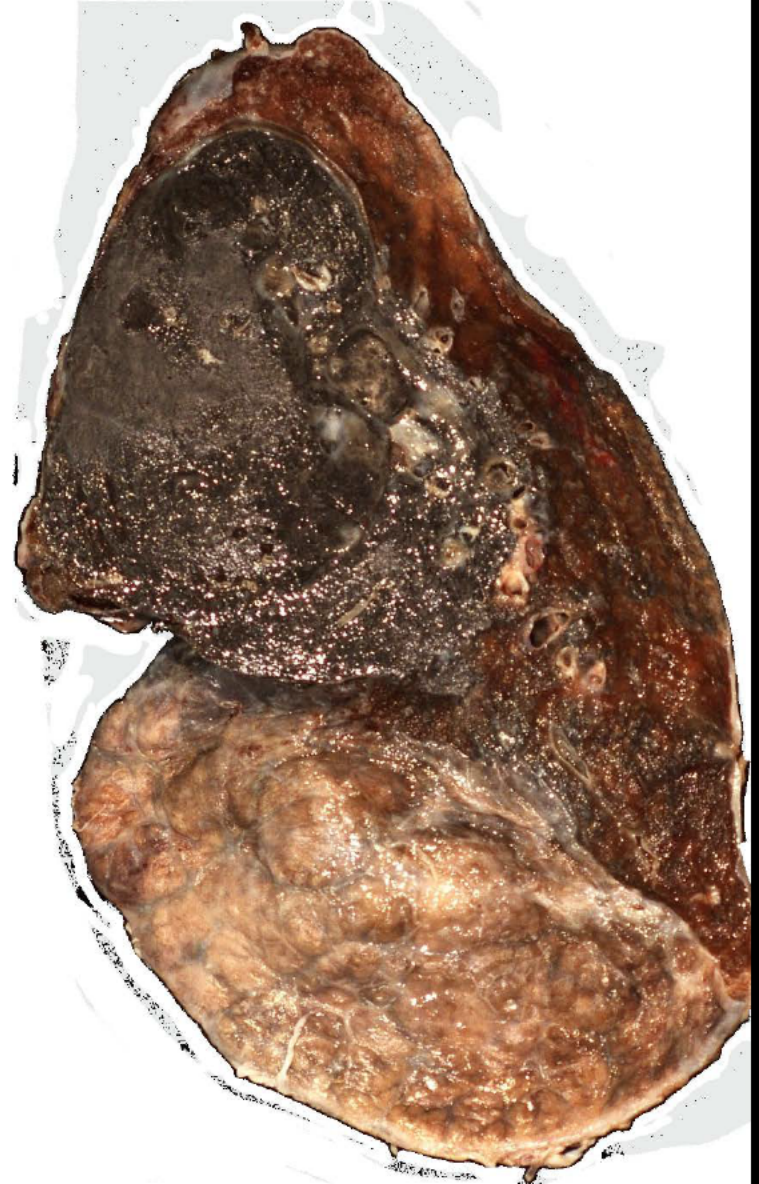
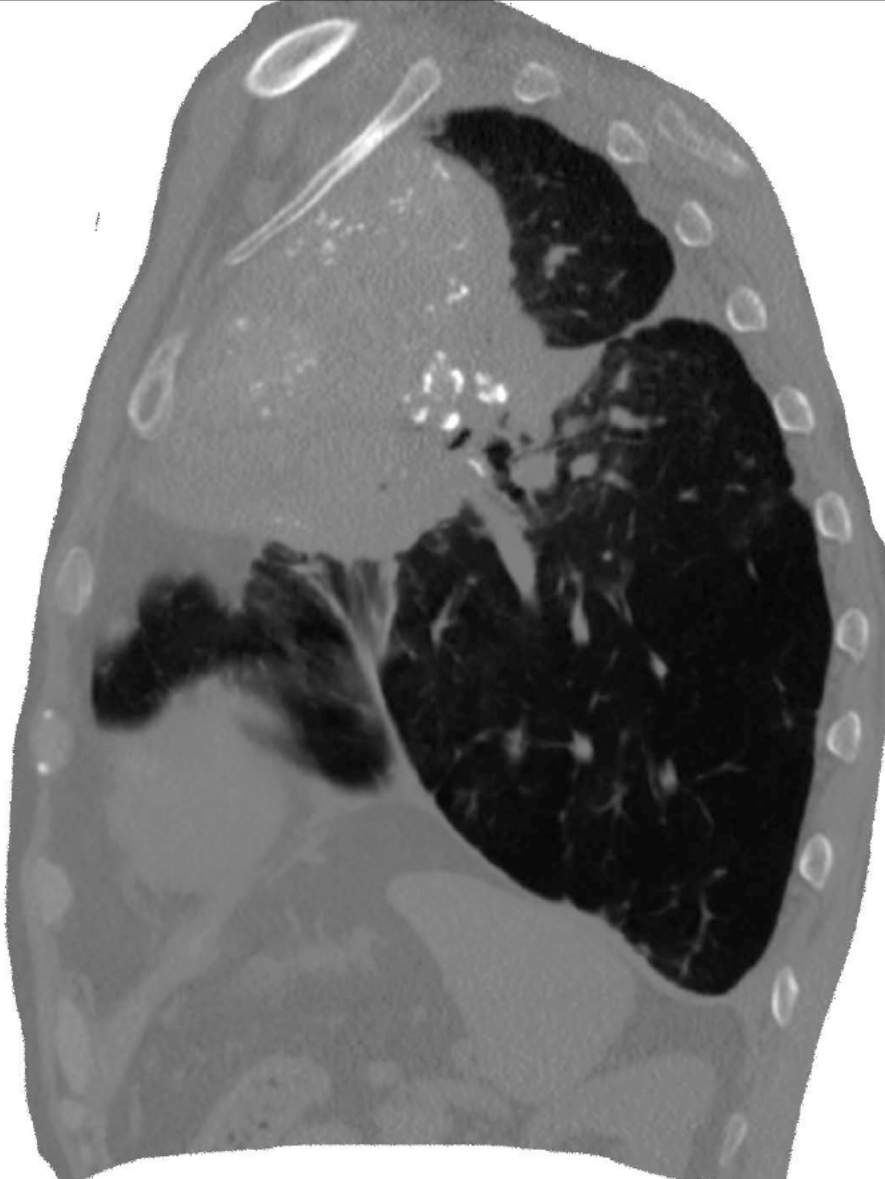
CT: masses and calcified lymph nodes



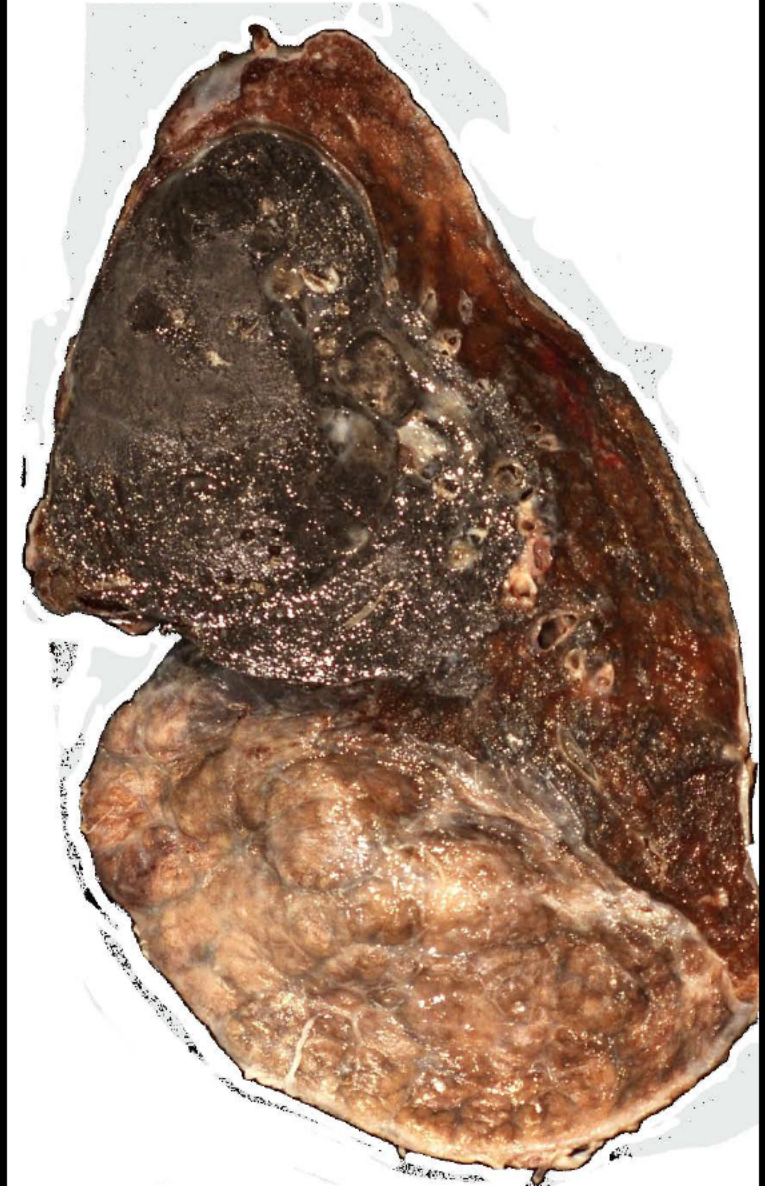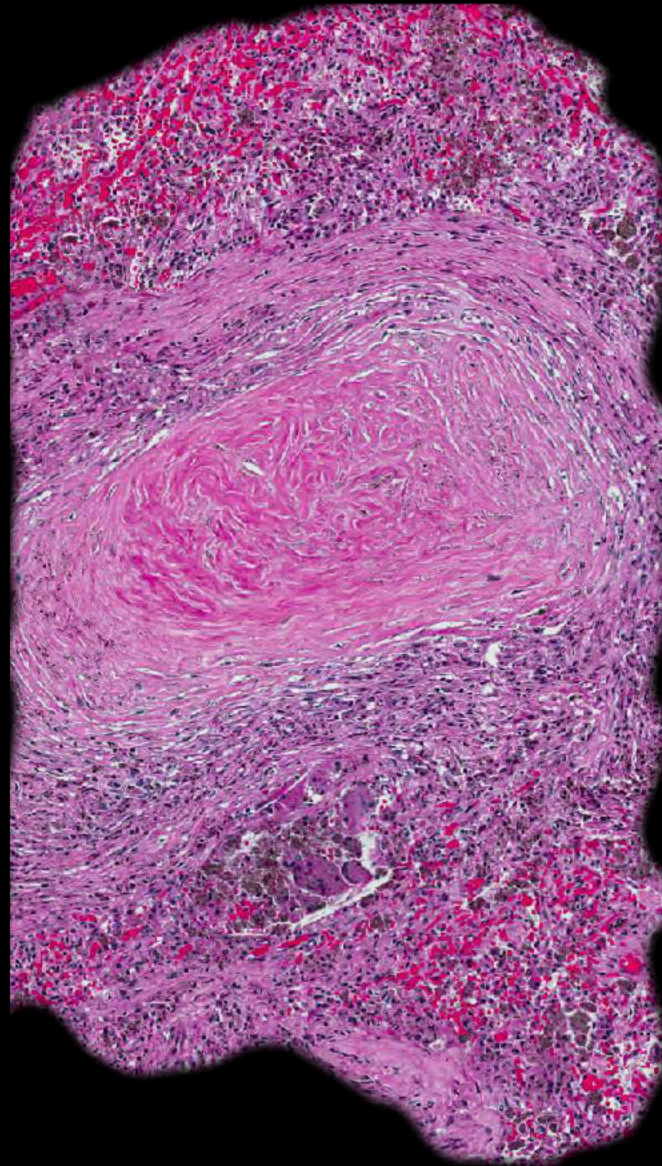
PET positive



Sagittal: progressive massive fibrosis



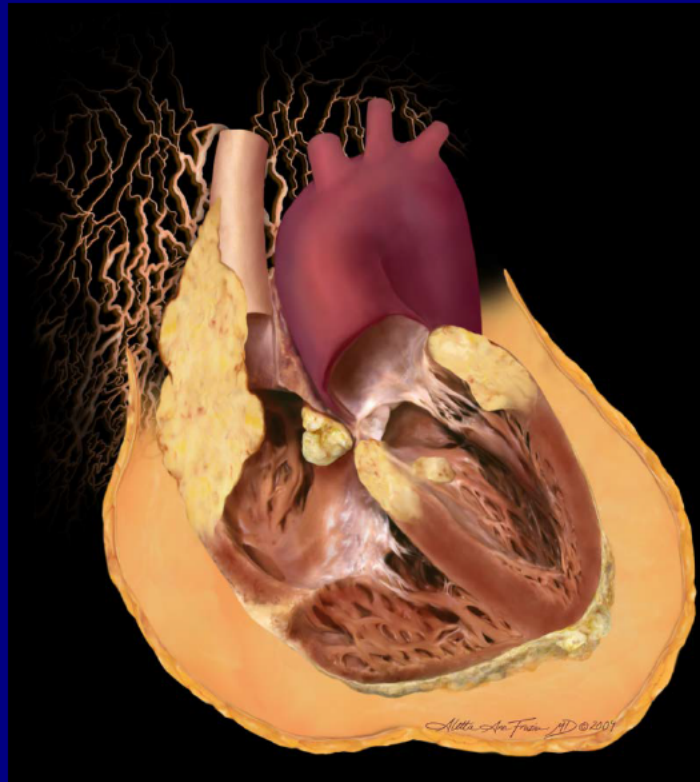Silicotic nodule and PMF



Progressive Massive Fibrosis (mixed dust pneumoconiosis)

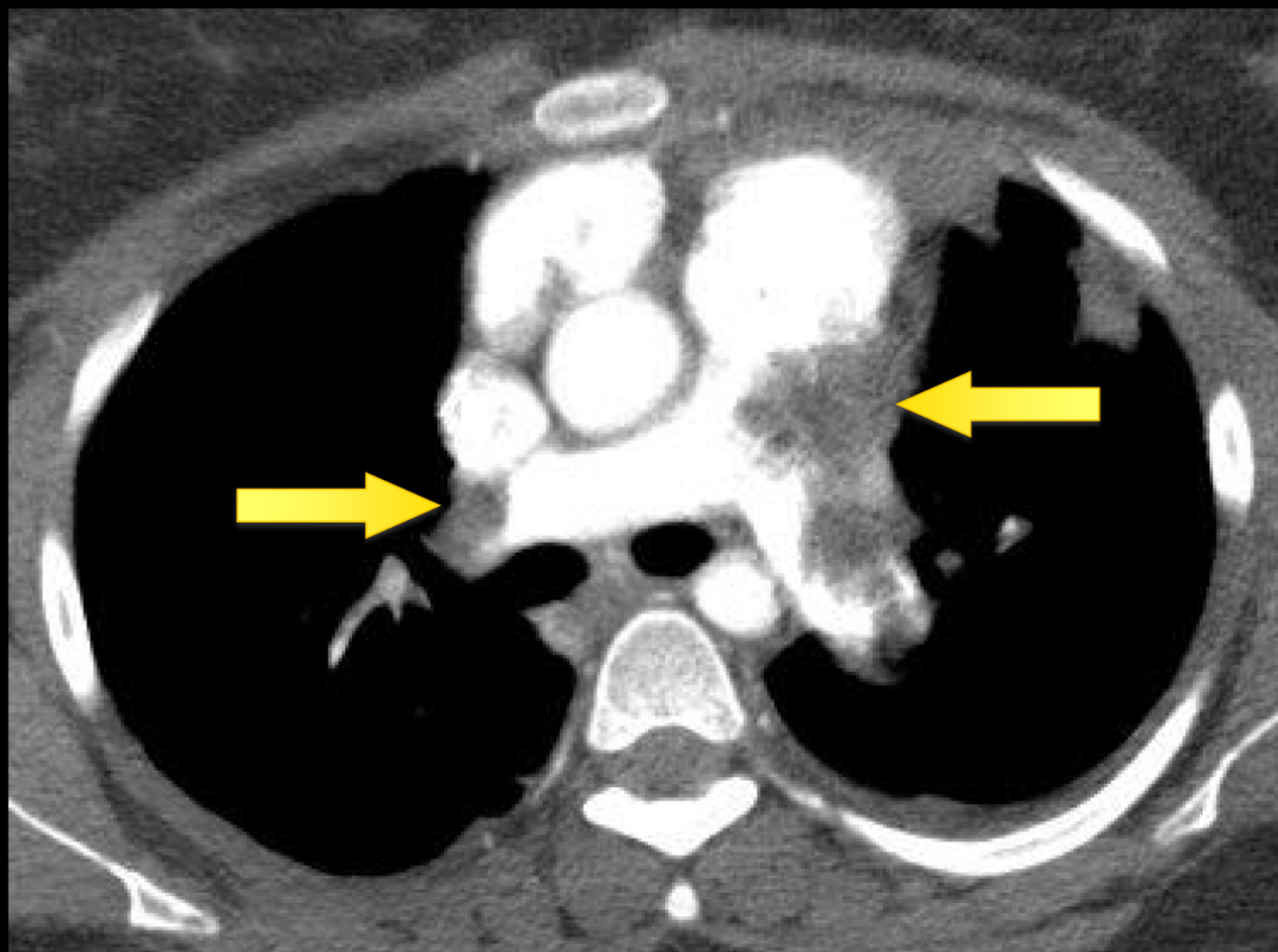
Matthew Kulzer, MD
University of Pittsburgh Medical Center
Pittsburgh, PA

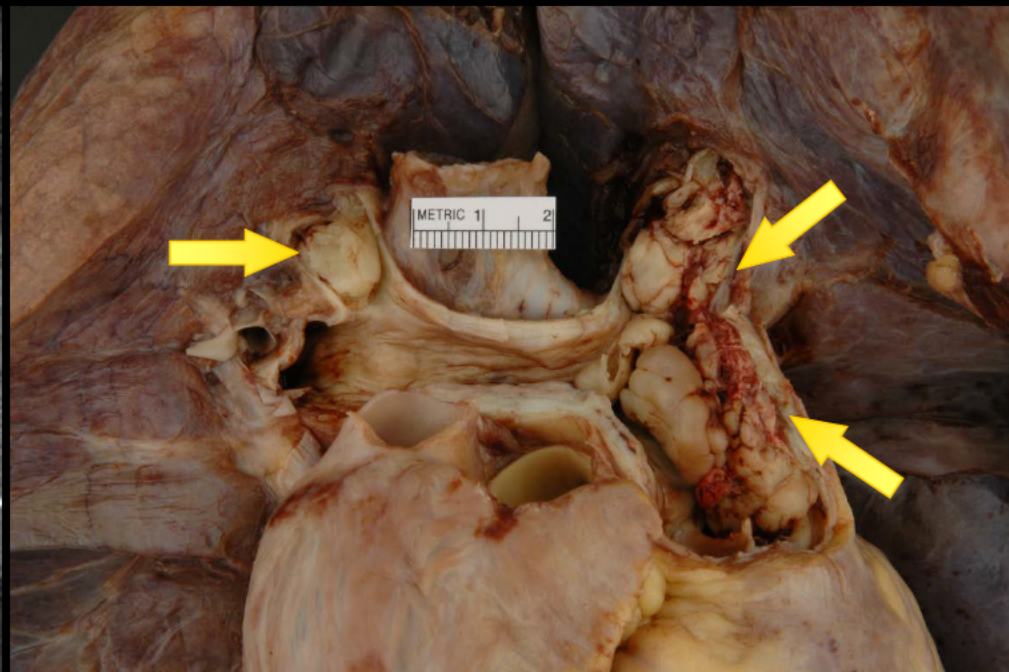
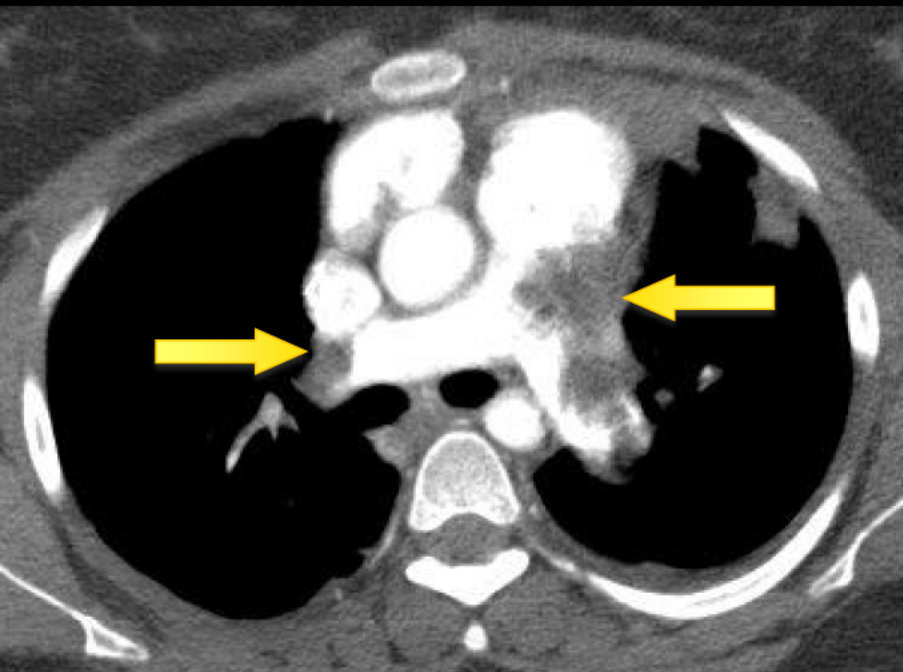
Cardiovascular Best Case

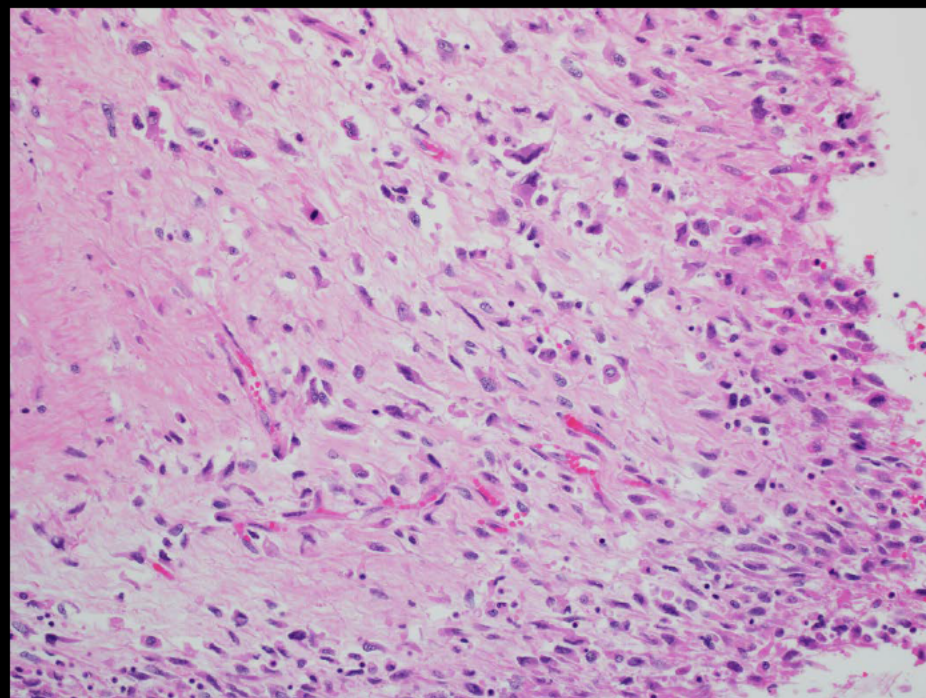
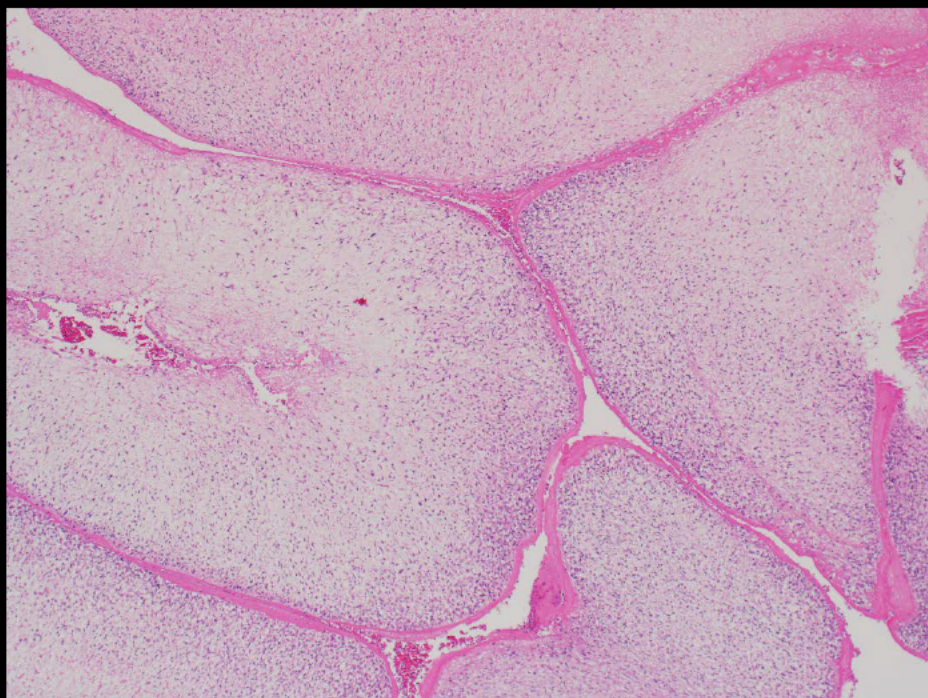


Clinical Information

24 year old female was treated over the last three months for a pulmonary embolism diagnosed at an outside hospital. She has experienced increasing dyspnea and recently hemoptysis and a syncopal episode







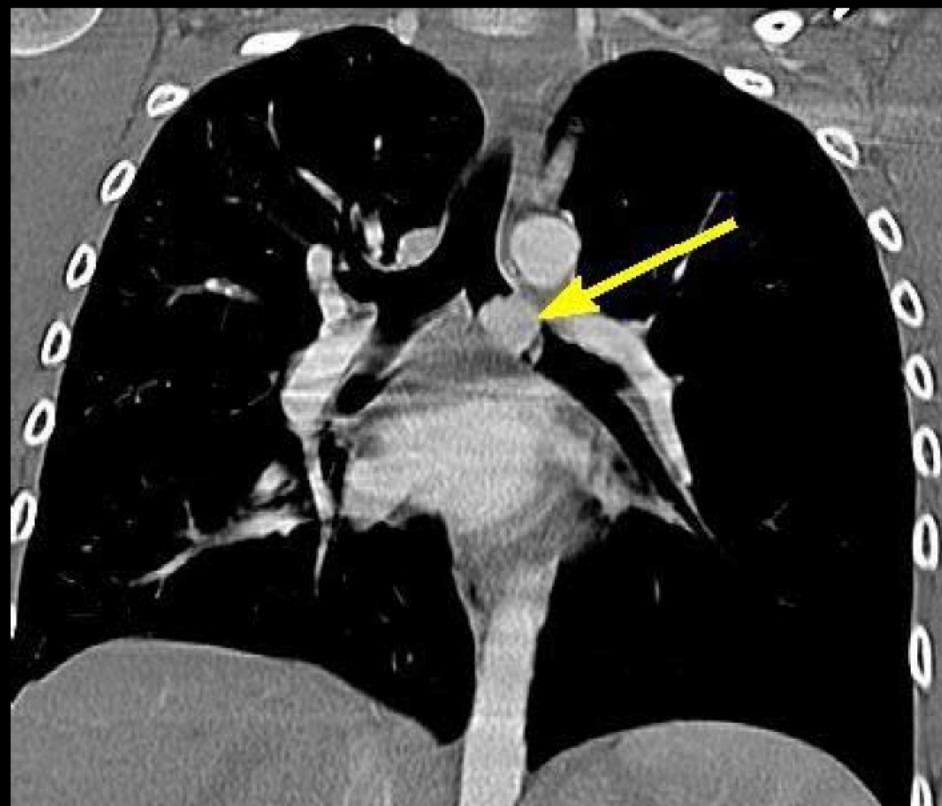
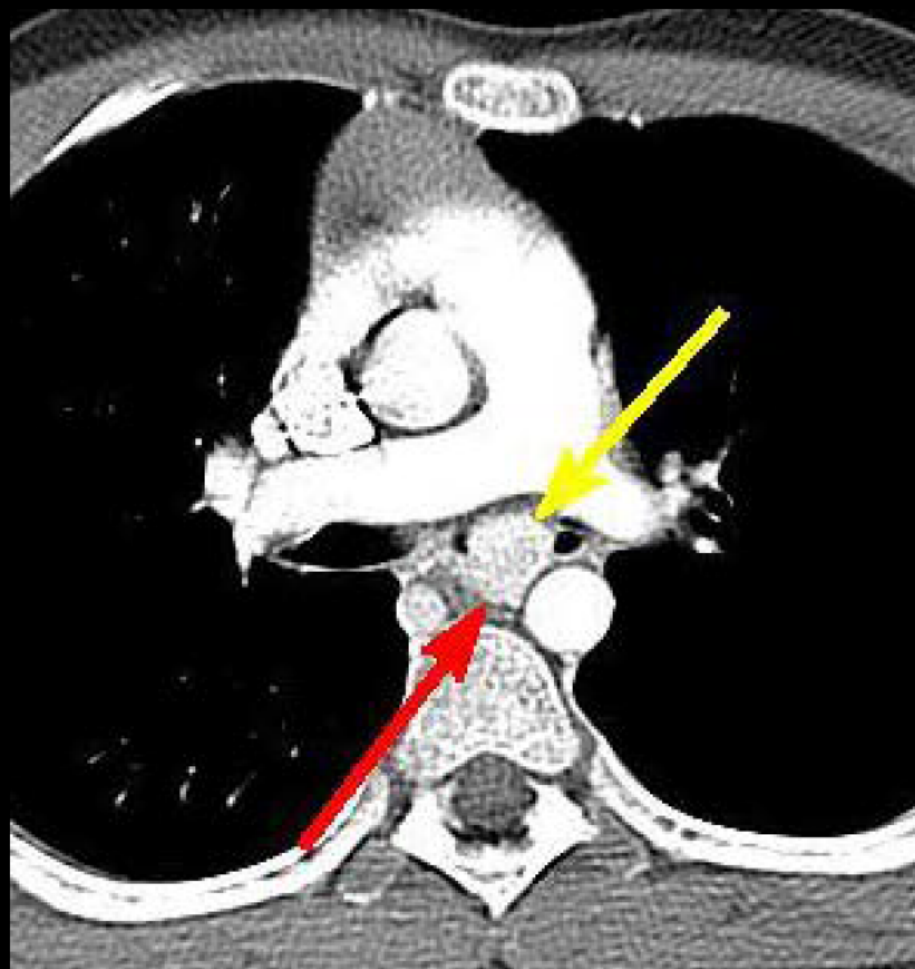
Pulmonary Artery Intimal Sarcoma

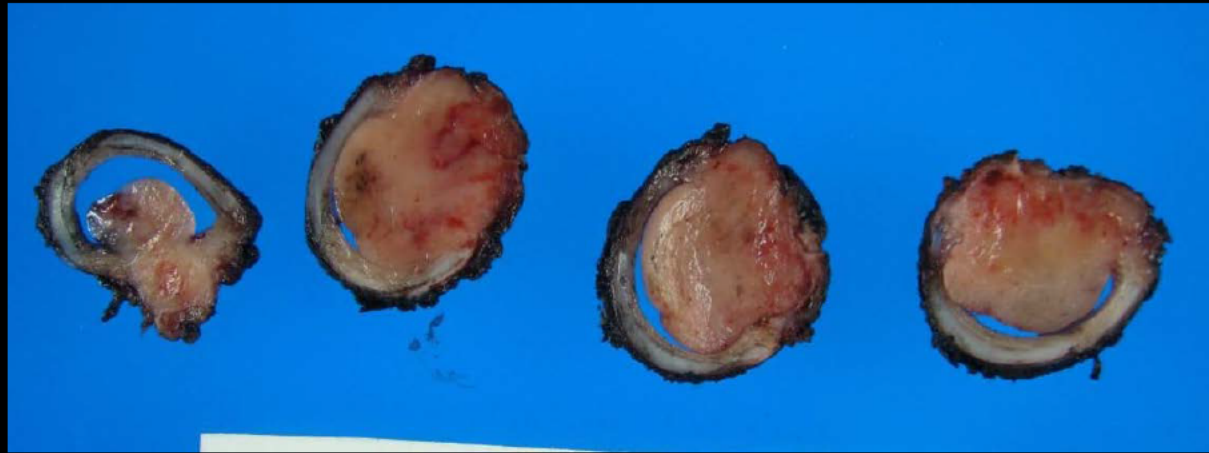
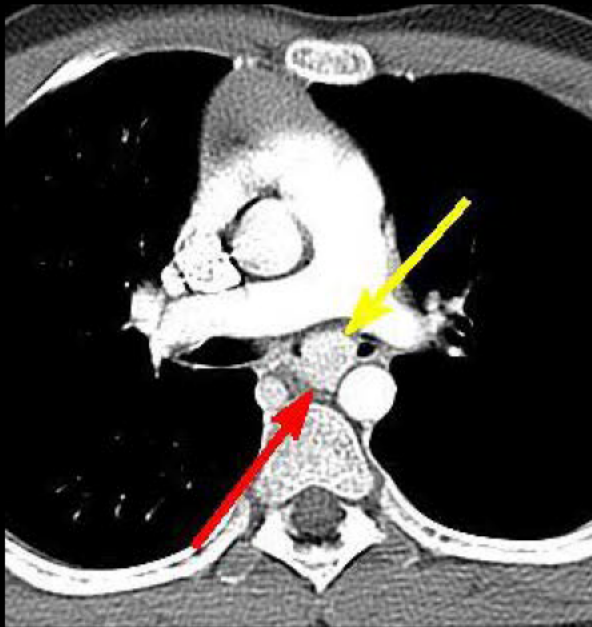
**Dr. Daniel Adamo
Mayo Clinic
Rochester, MN**

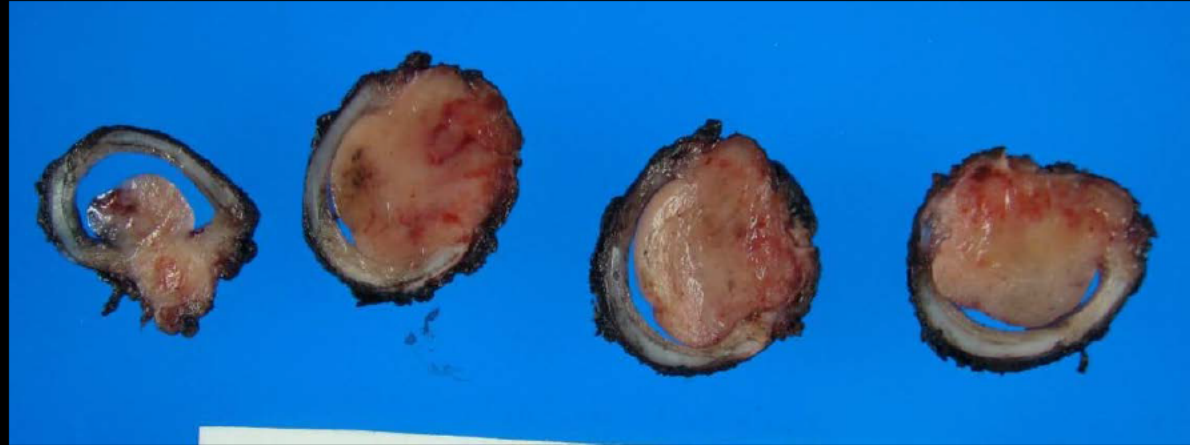
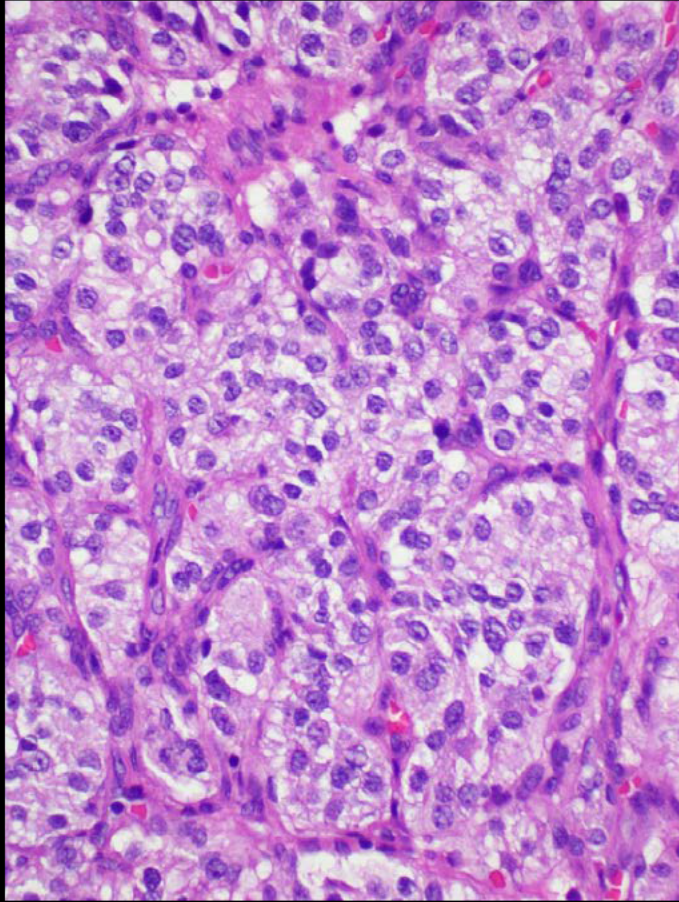


Clinical Information

10 year-old male patient presents with
near syncope and small volume
hemoptysis.



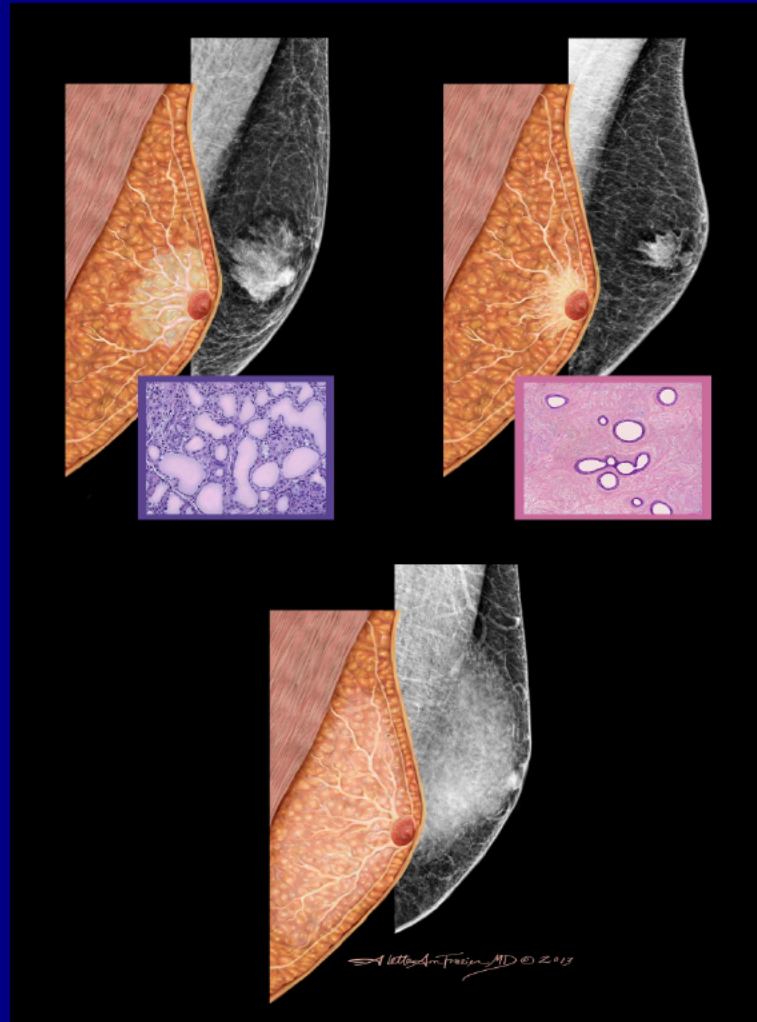




Bronchial Paraganglioma

Anthony Onofrio
Baylor University Medical Center
Dallas, TX

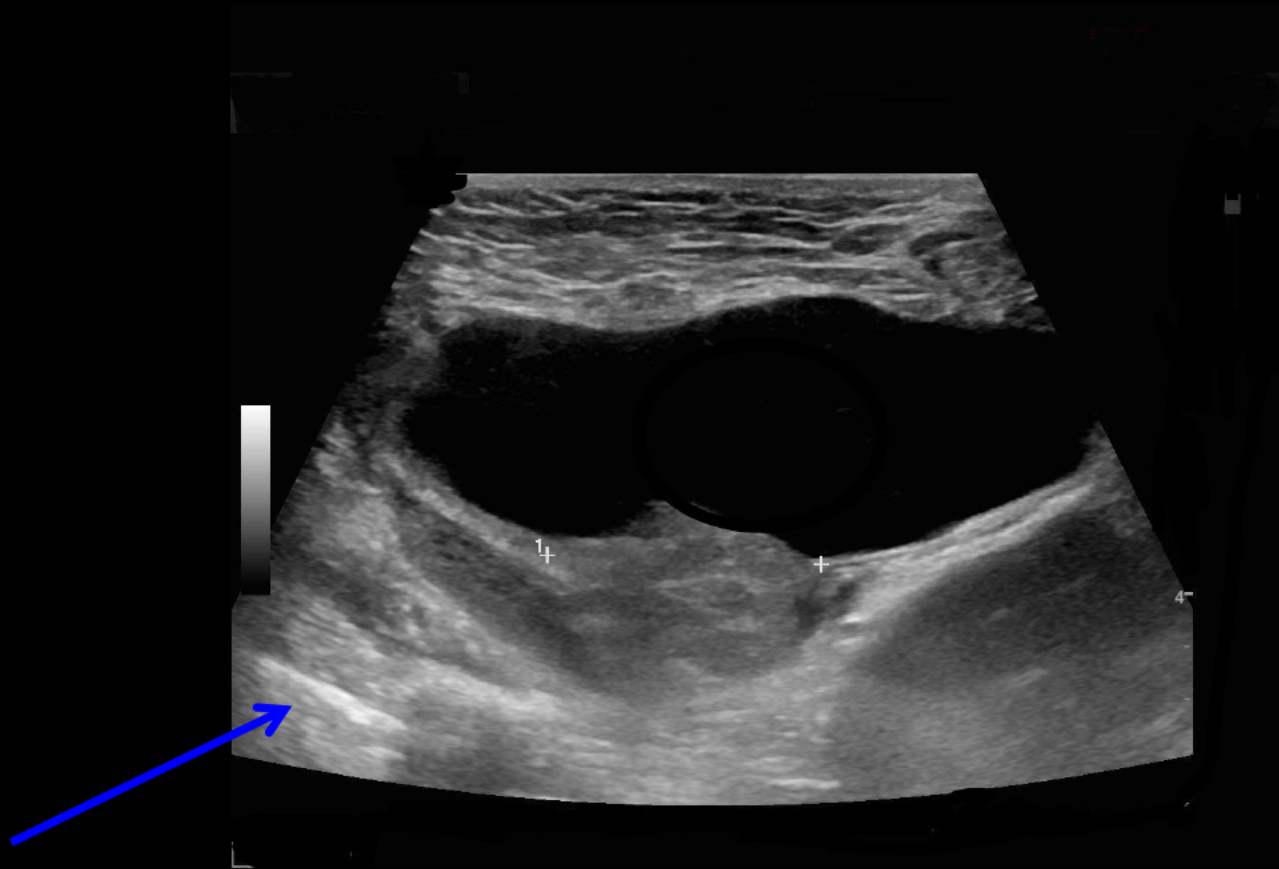
Breast Best Case



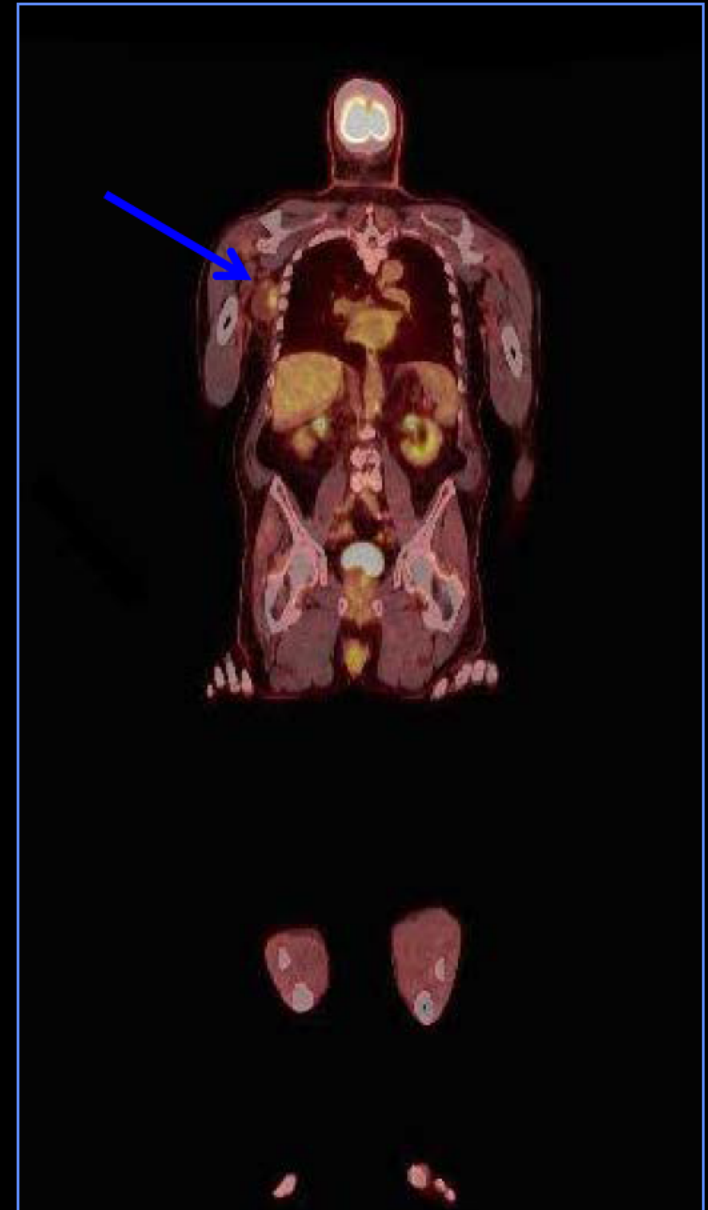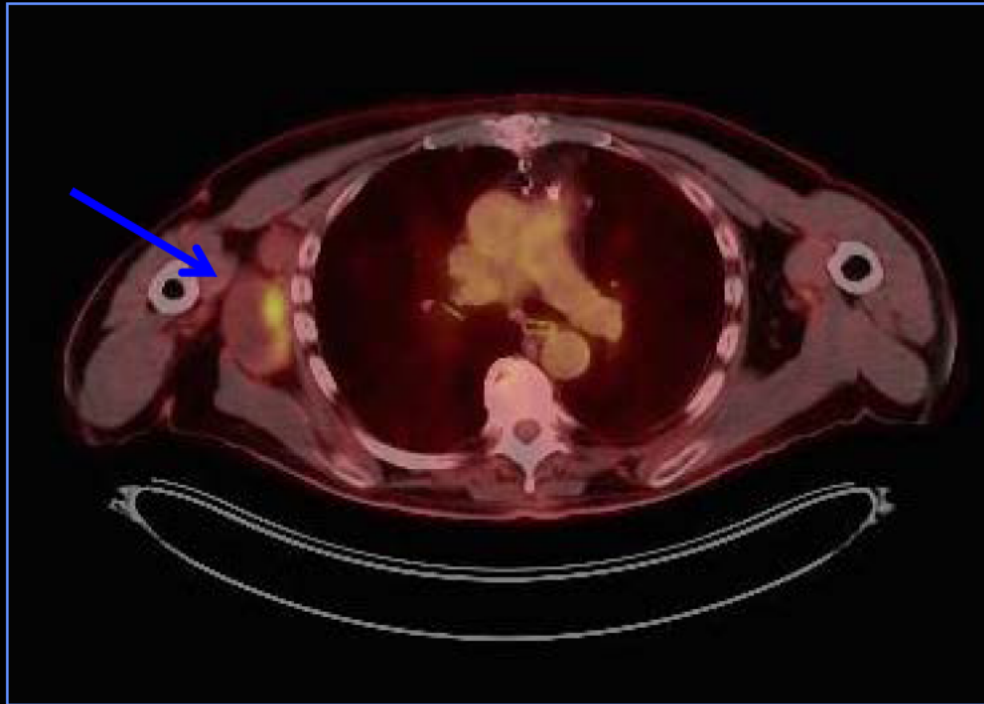
Clinical Information

81 yo male with fullness in the
right axilla


US Right Axilla



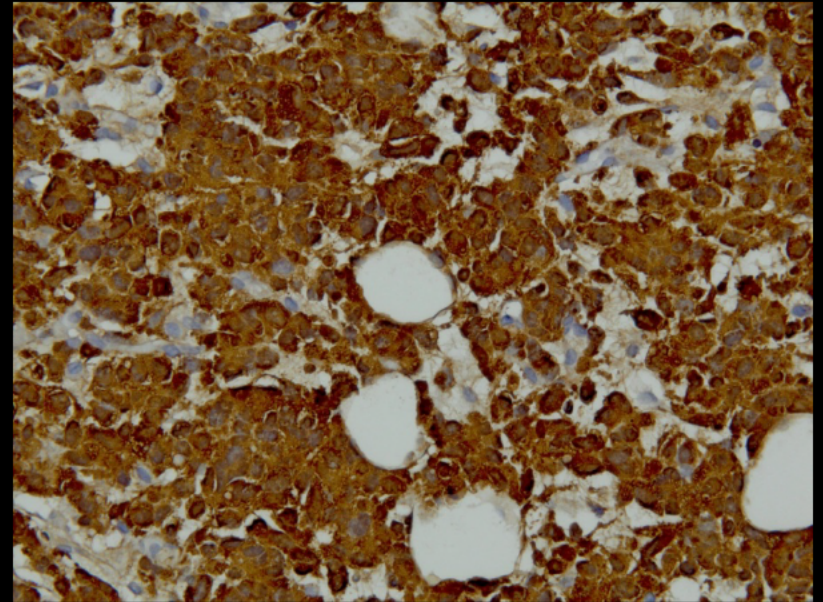
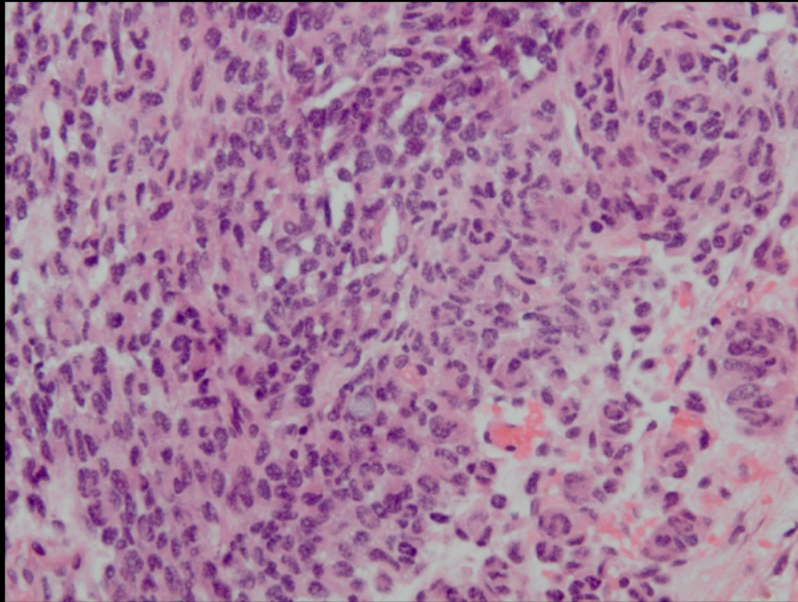
FDG-PET



Core Needle Biopsy Performed



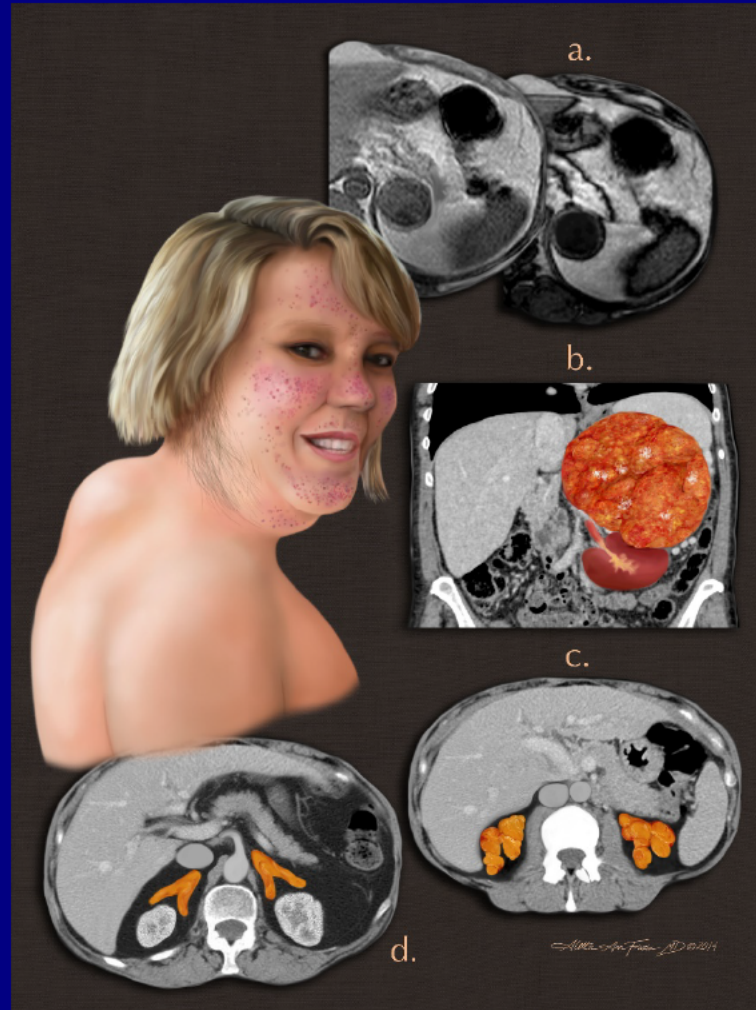
Histology



Metastatic Melanoma to Axillary Lymph Node

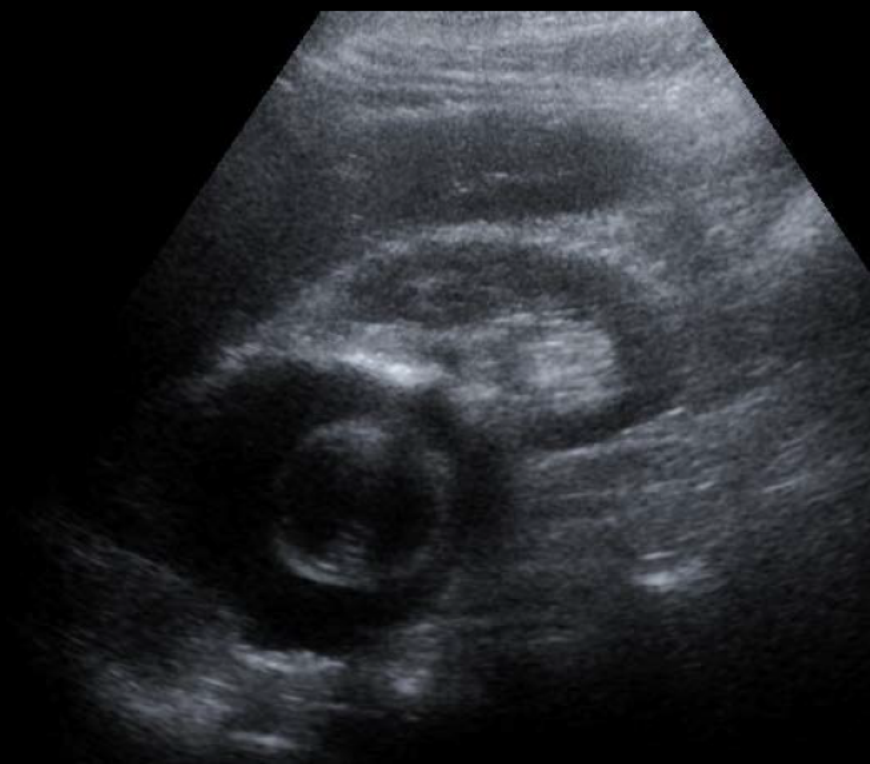Eralda Mema
New York Presbyterian Hospital
New York, New York

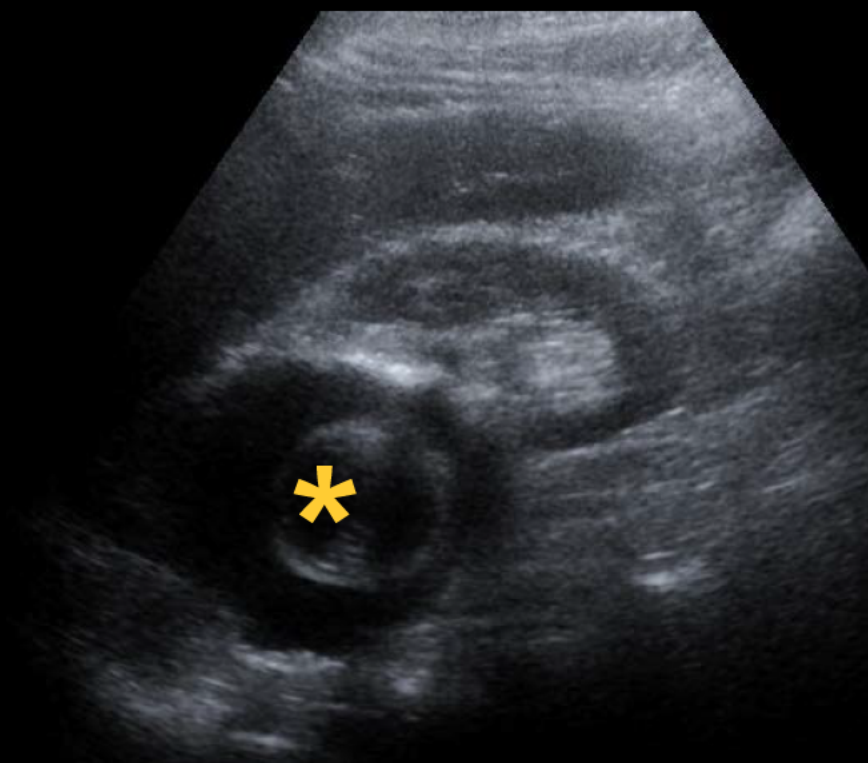
Genitourinary Best Case

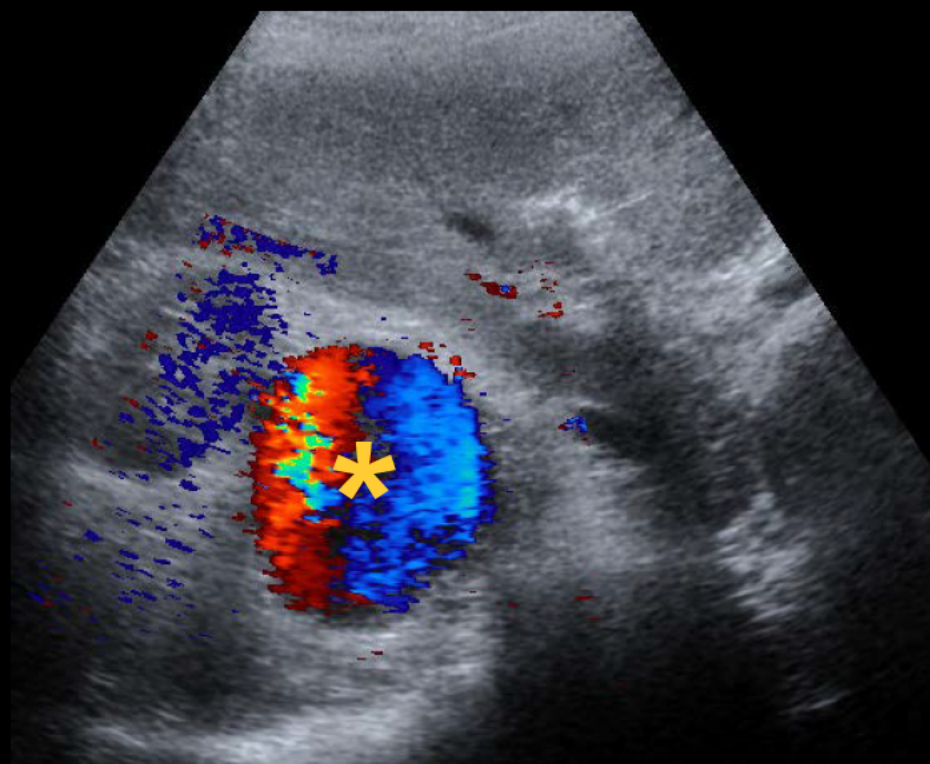
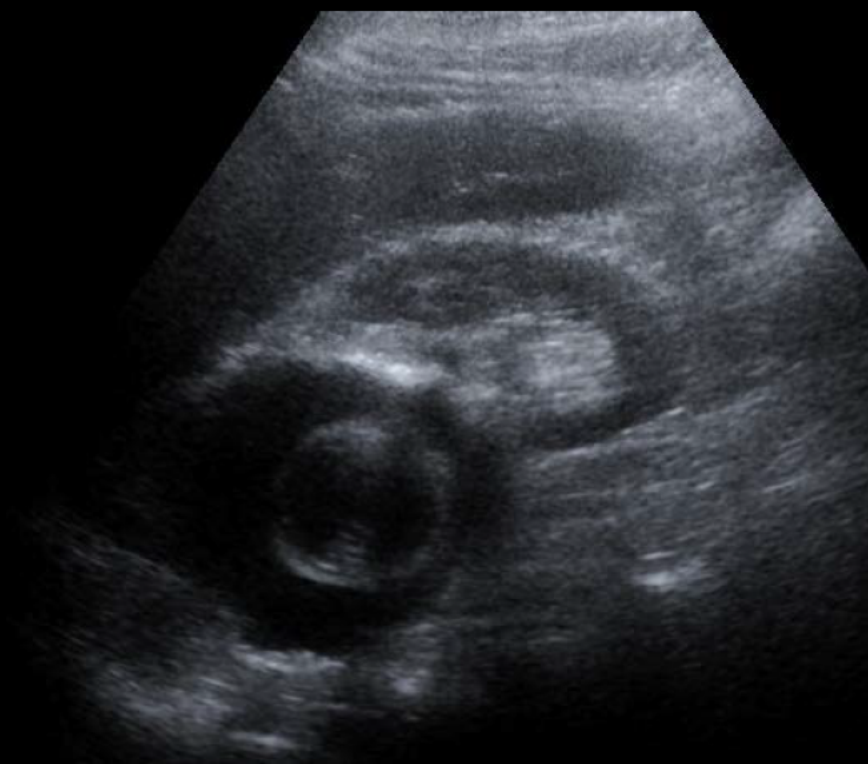

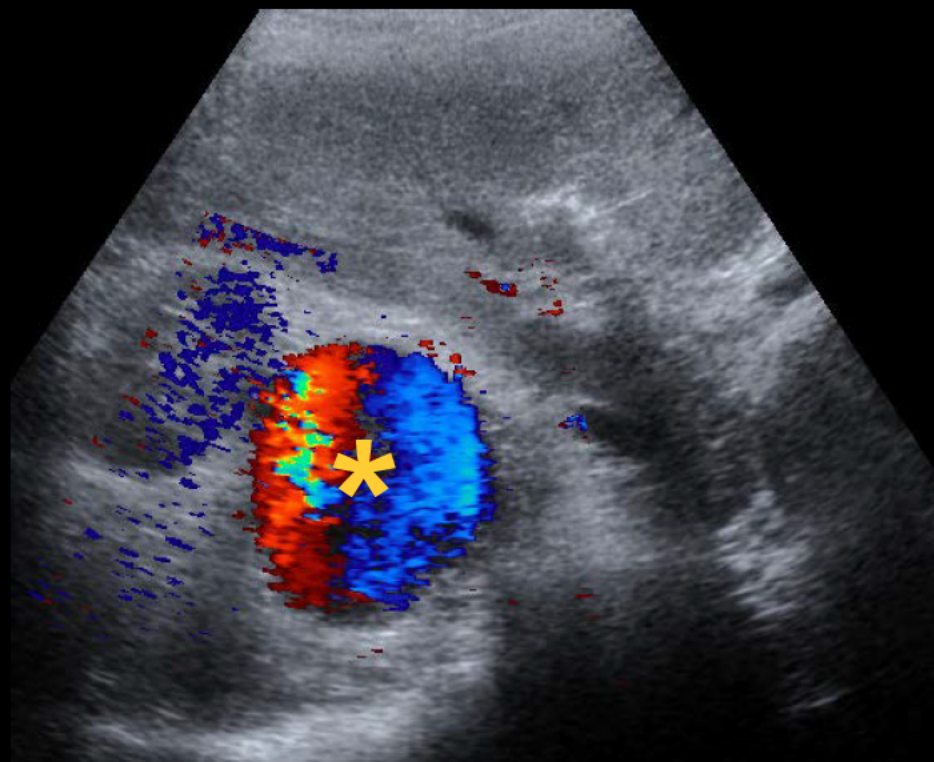
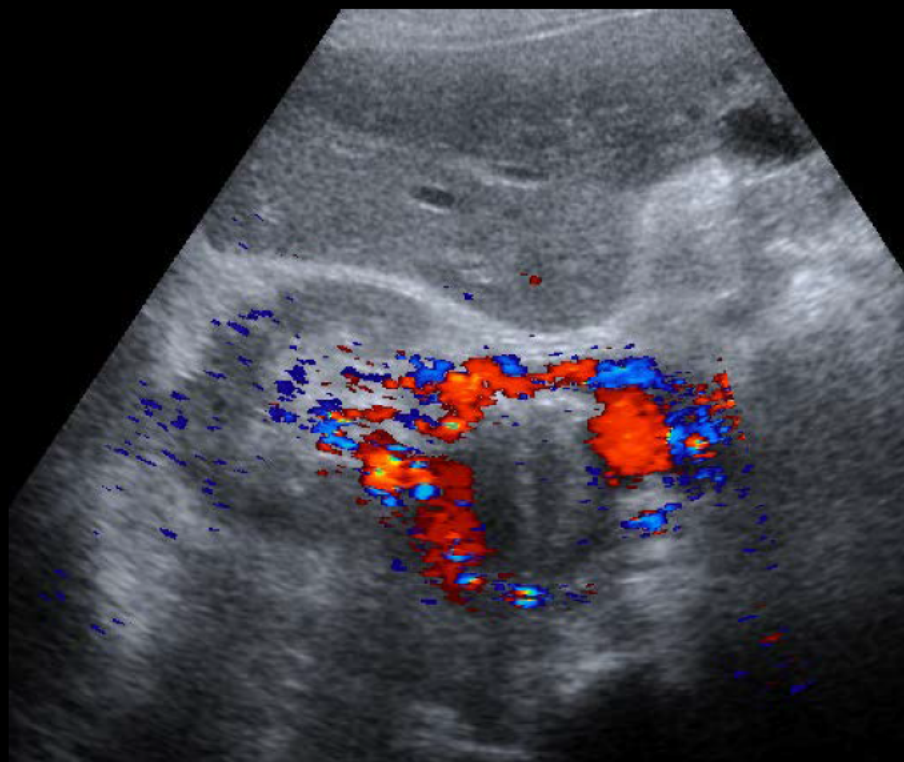
Clinical Information

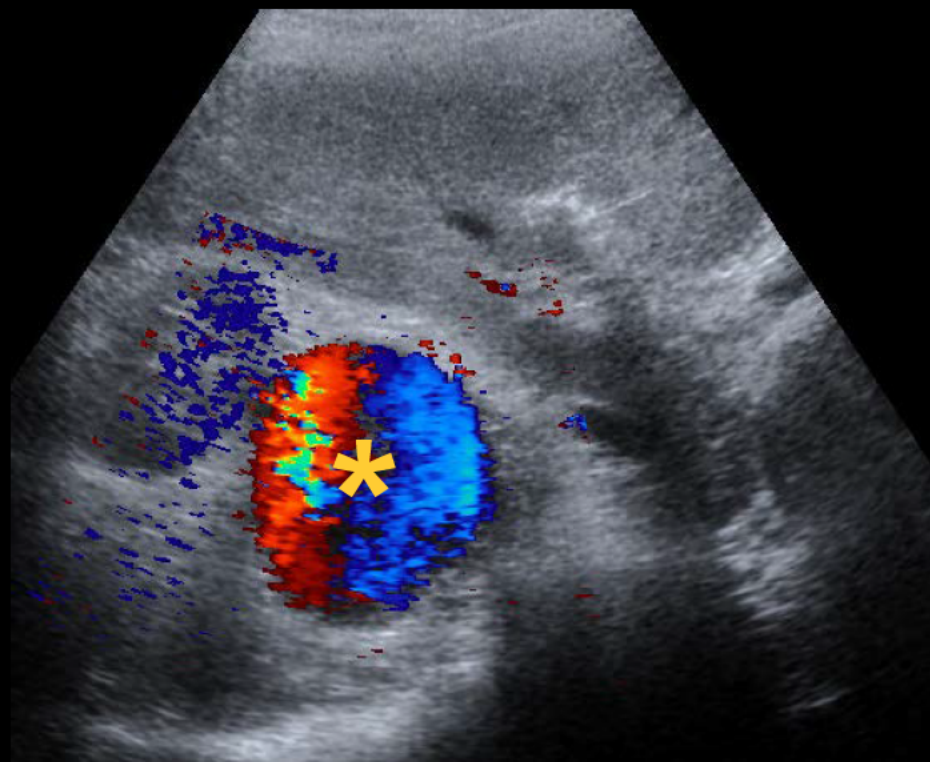
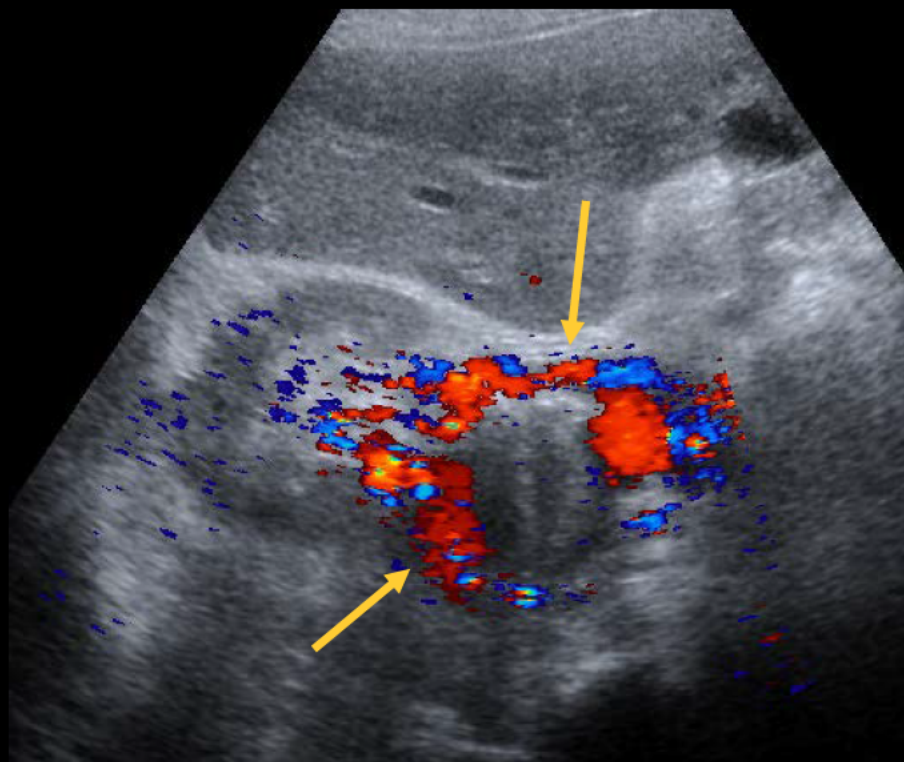
68 year old male with past medical history of COPD and non-ischemic cardiomyopathy who was admitted with a COPD exacerbation. He underwent a renal ultrasound for decreased urine output and a lesion was identified.

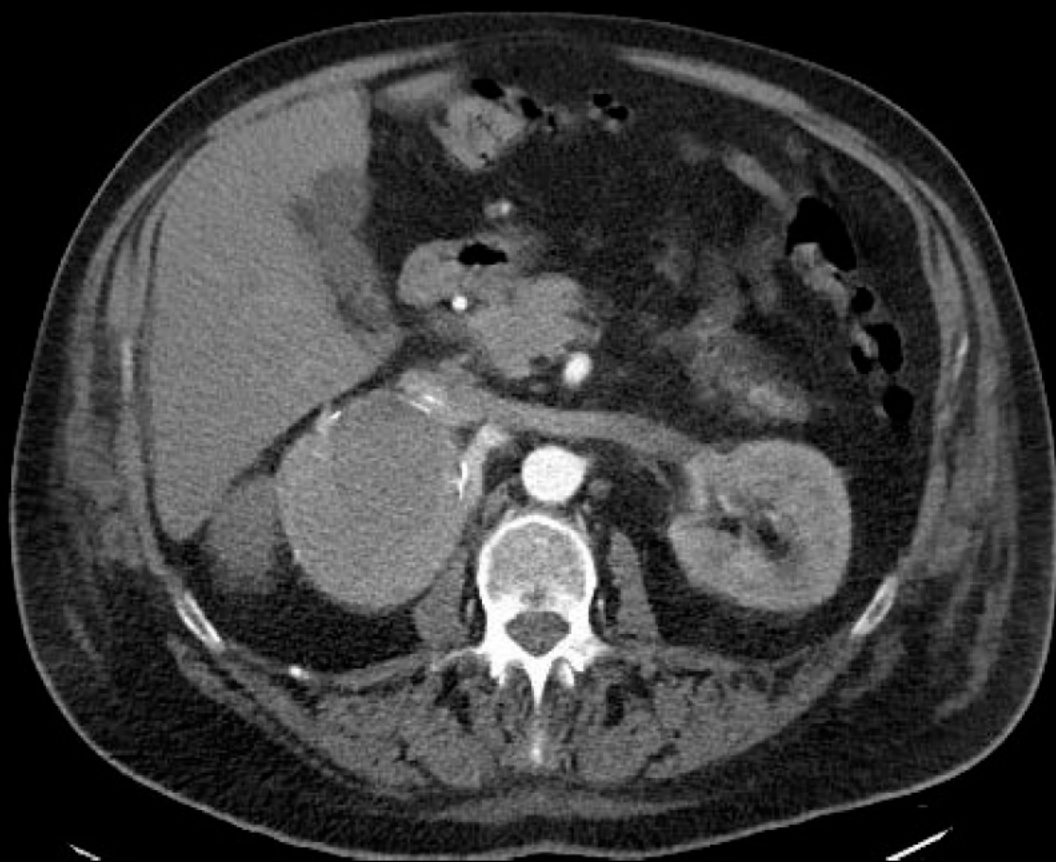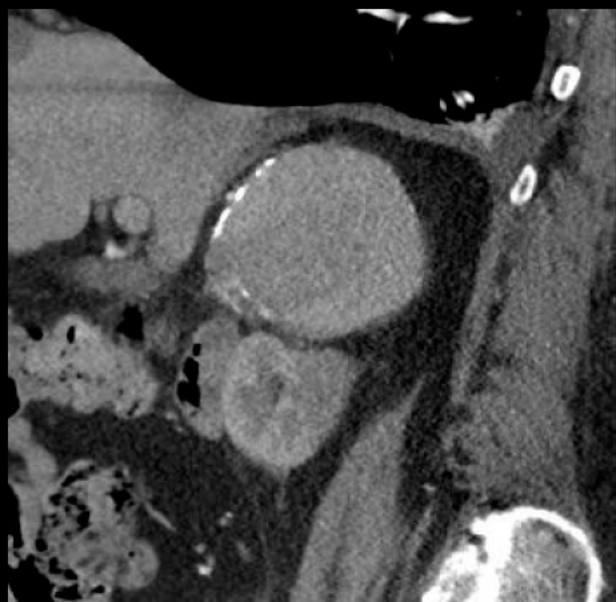

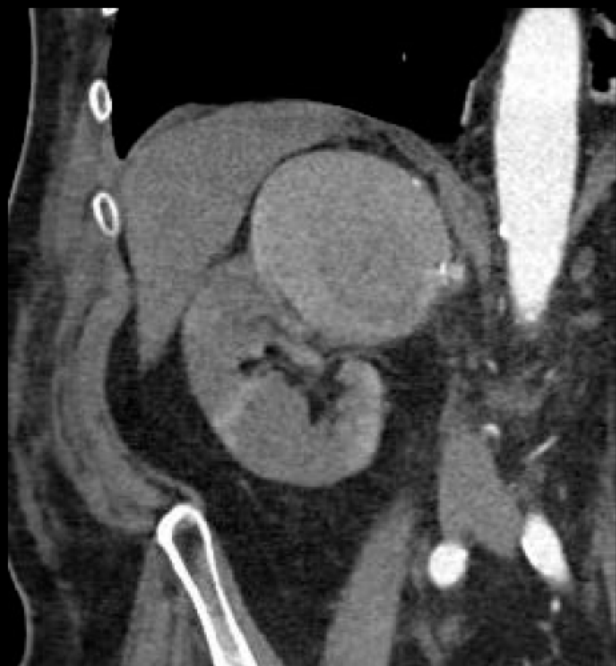
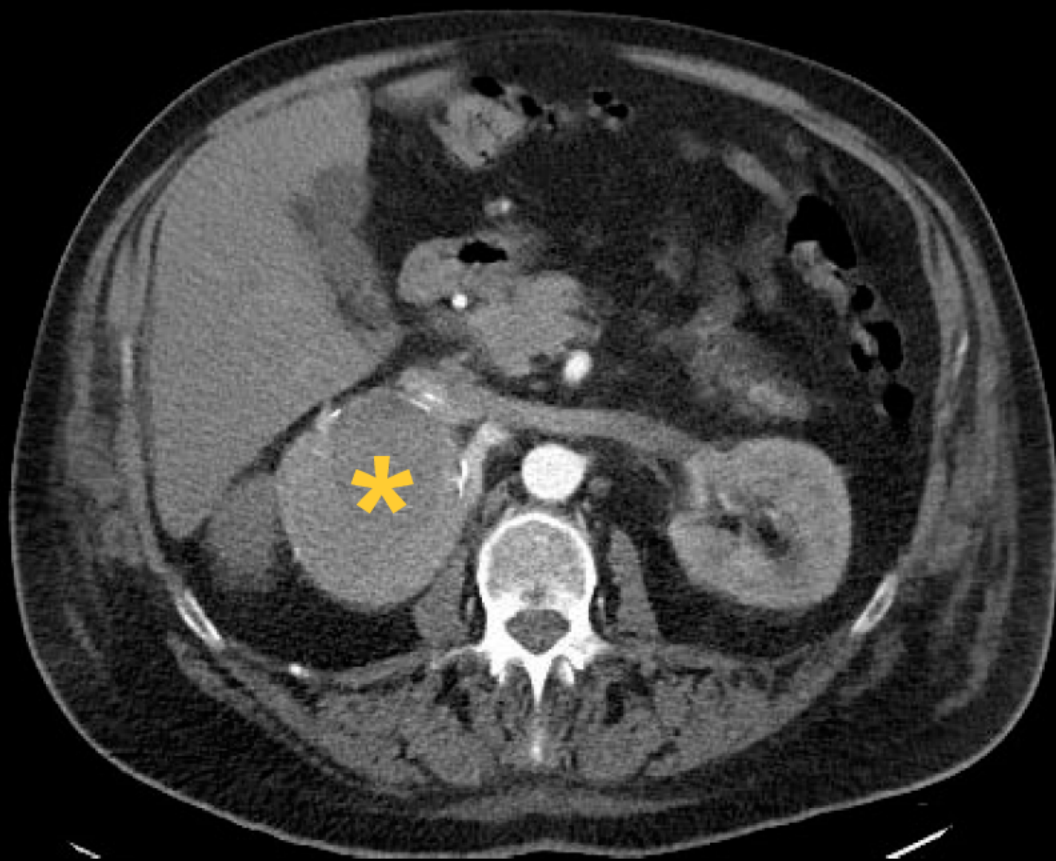
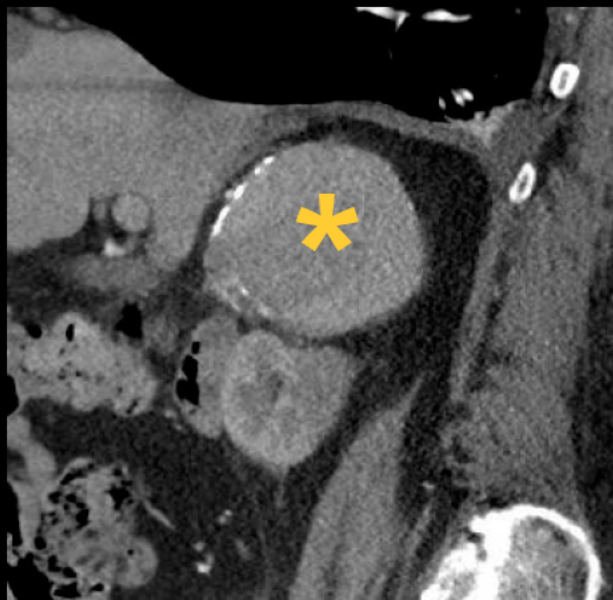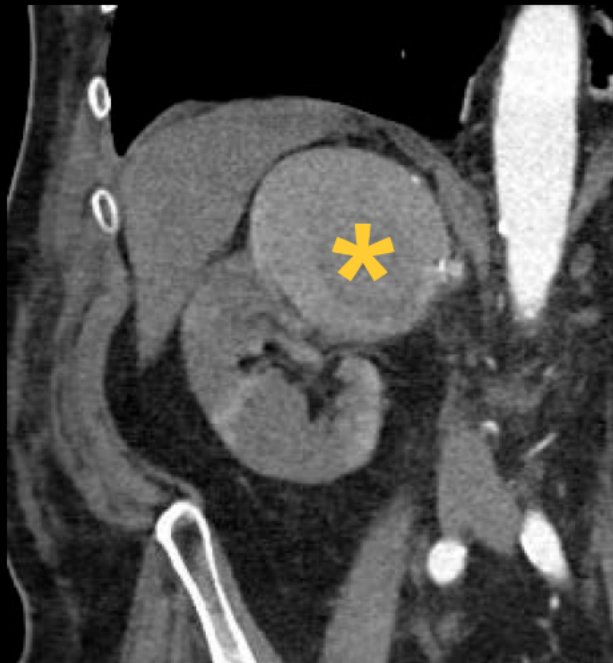


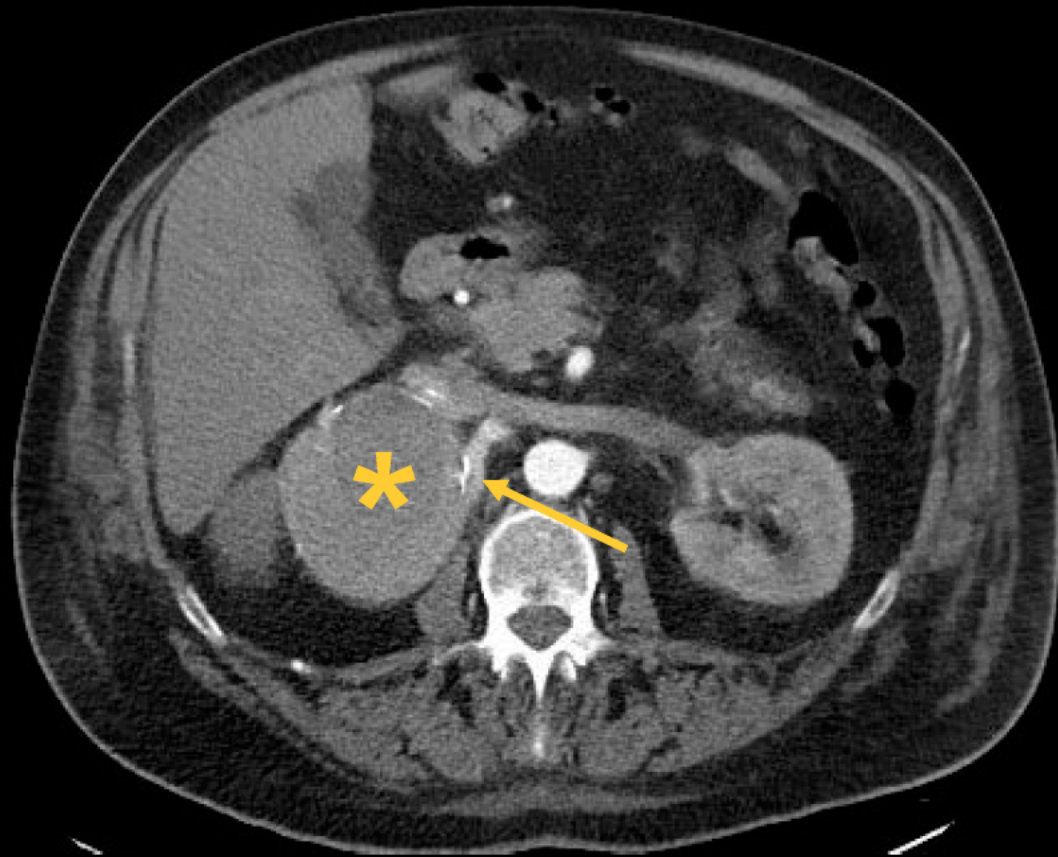
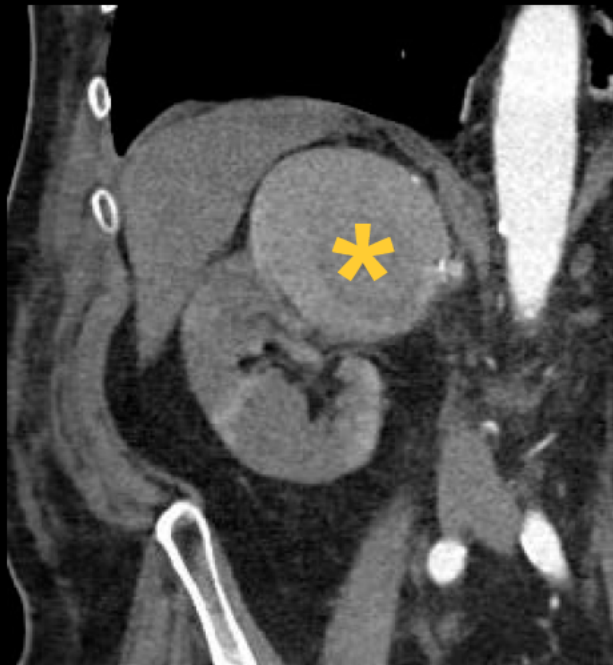




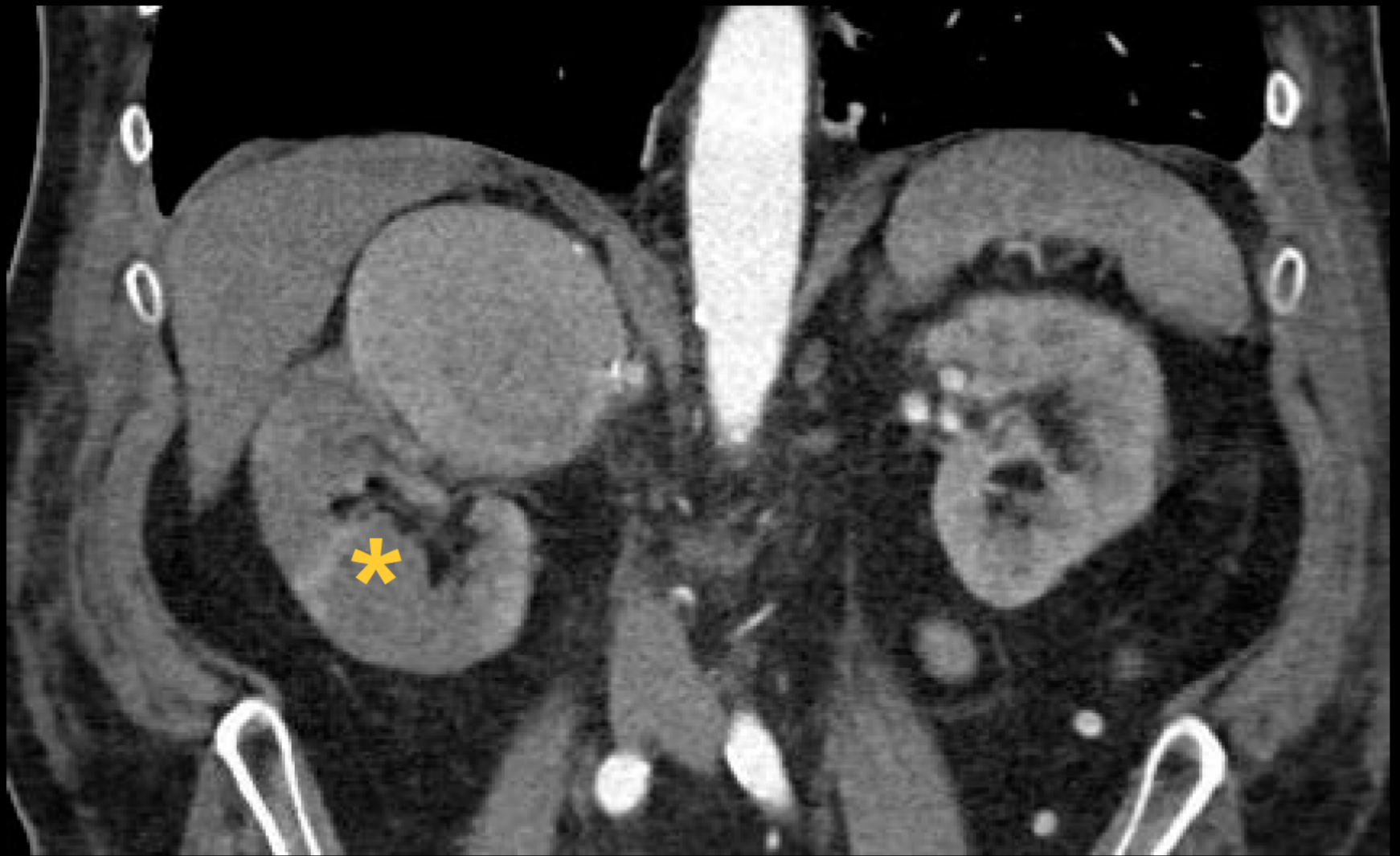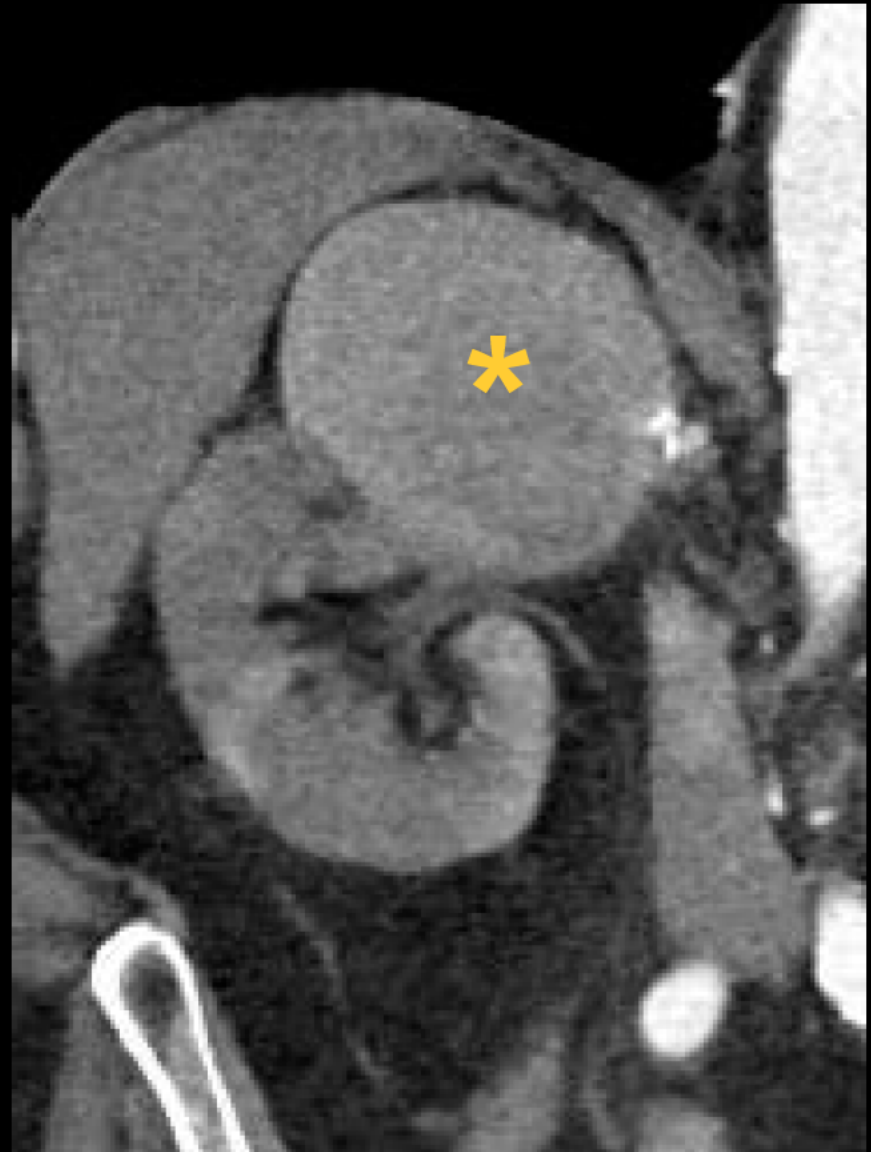
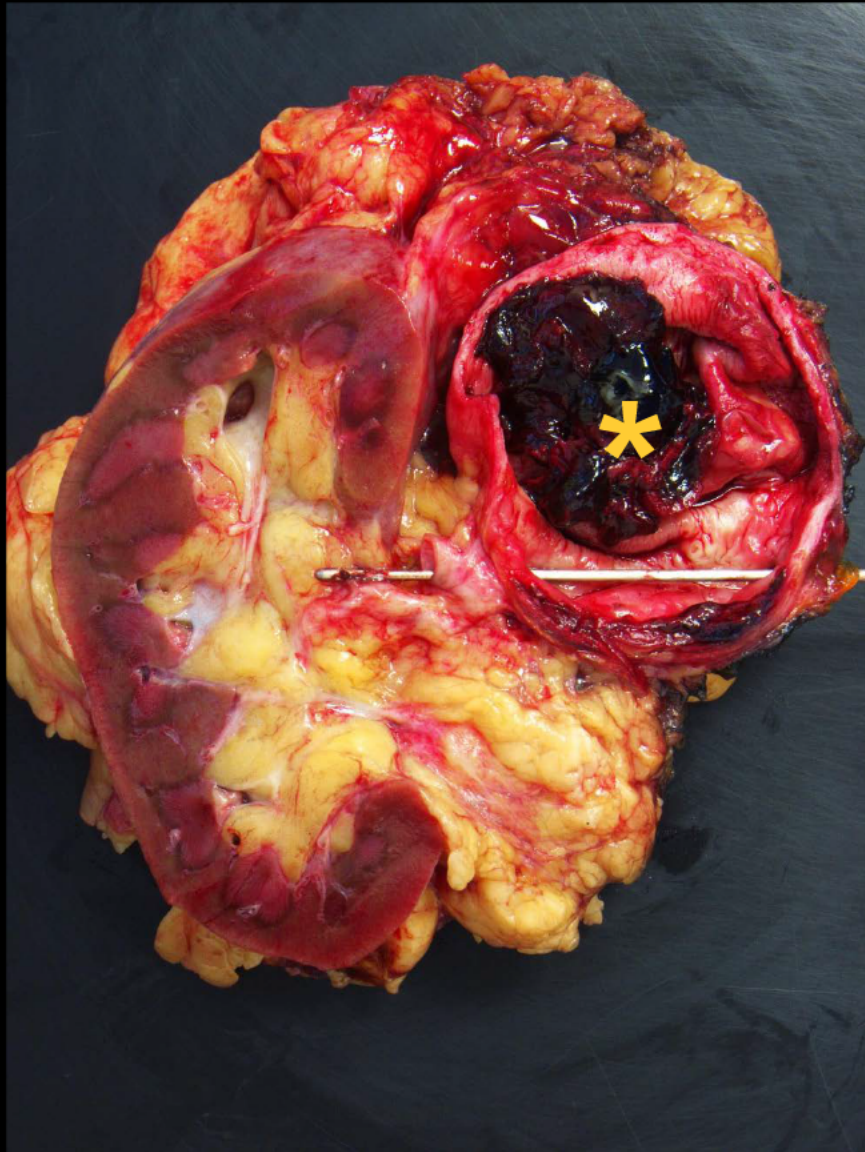


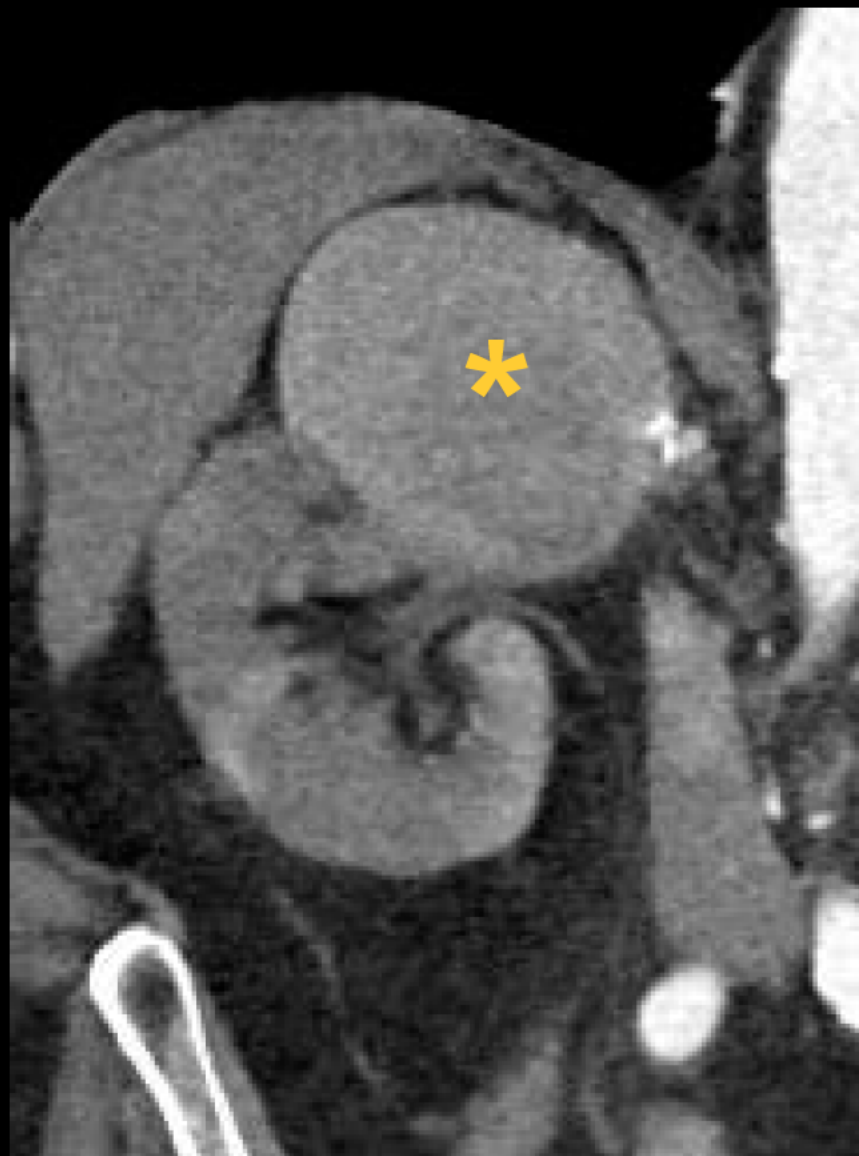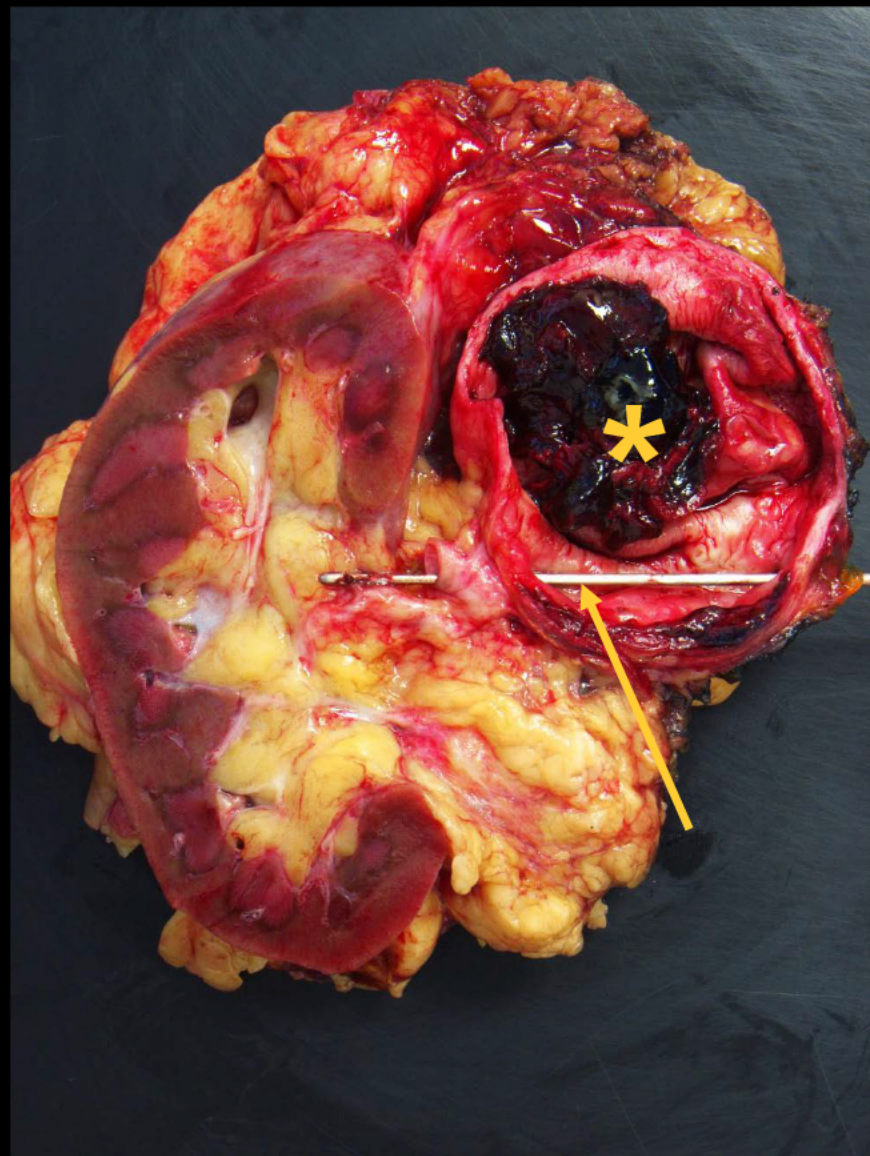


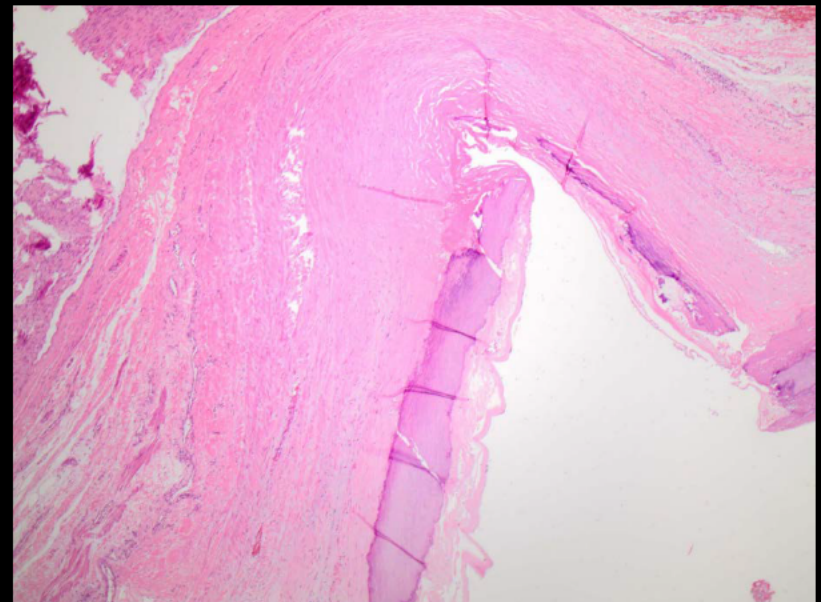
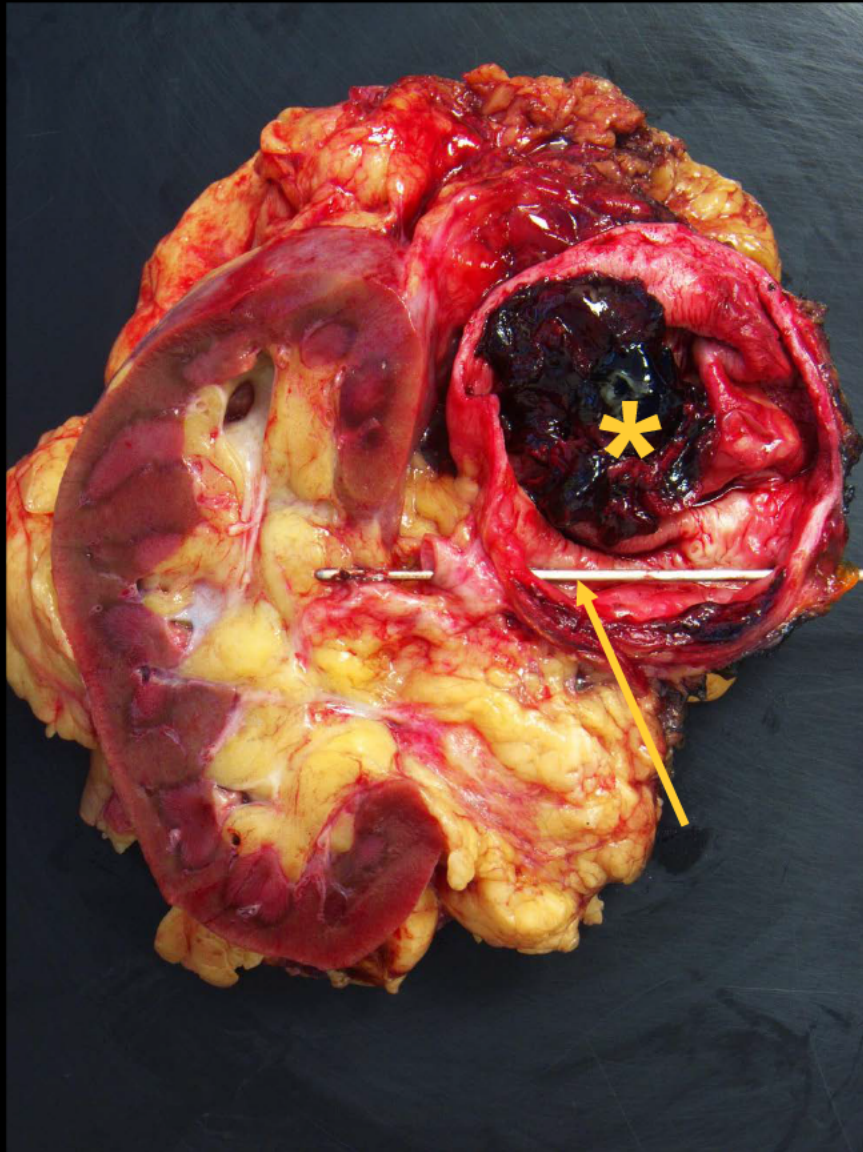


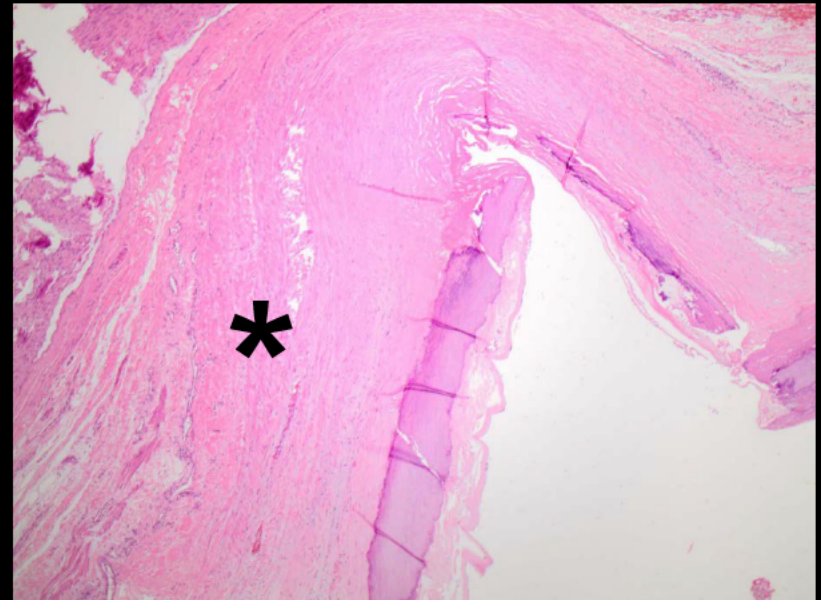
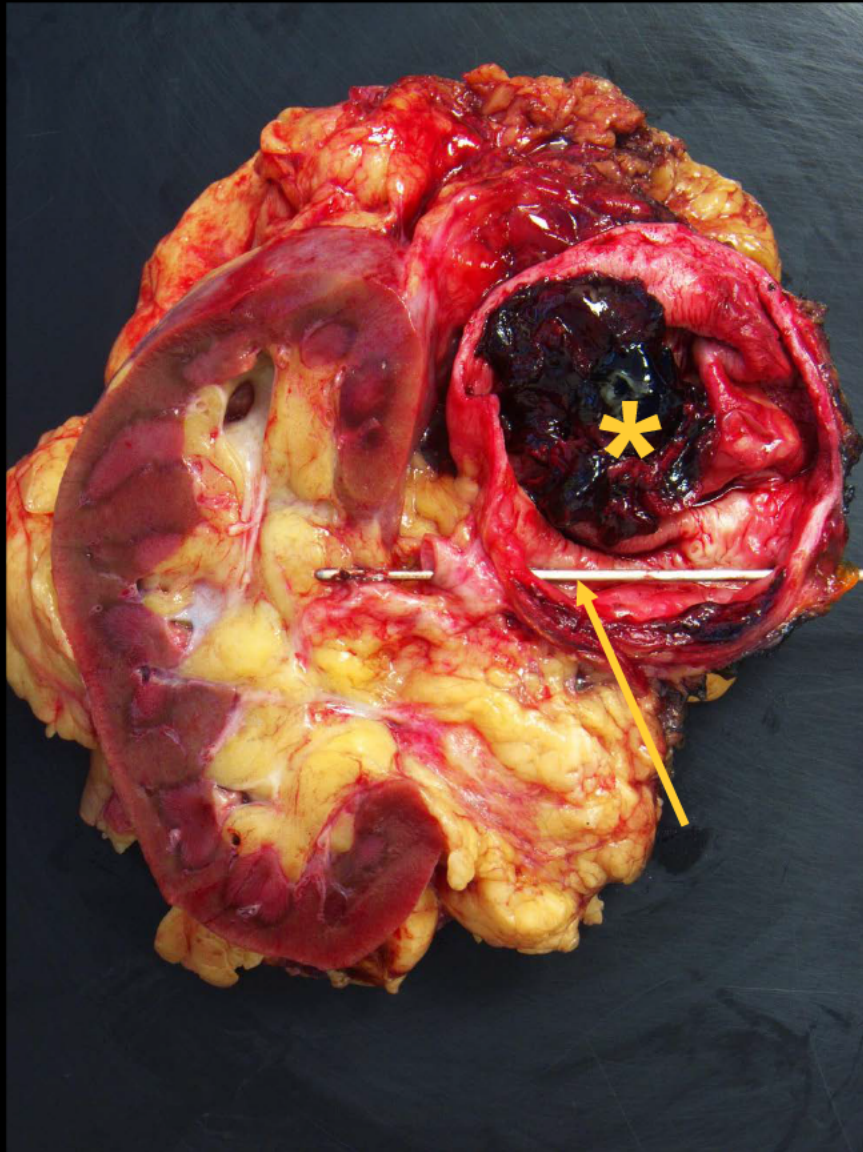












Renal Artery Aneurysm

Anthony Aquino, MD
The Ohio State University
Columbus, OH