

Best Cases of the AIRP

February-March, 2019

AIRPTM

AMERICAN INSTITUTE FOR
RADIOLOGIC PATHOLOGY

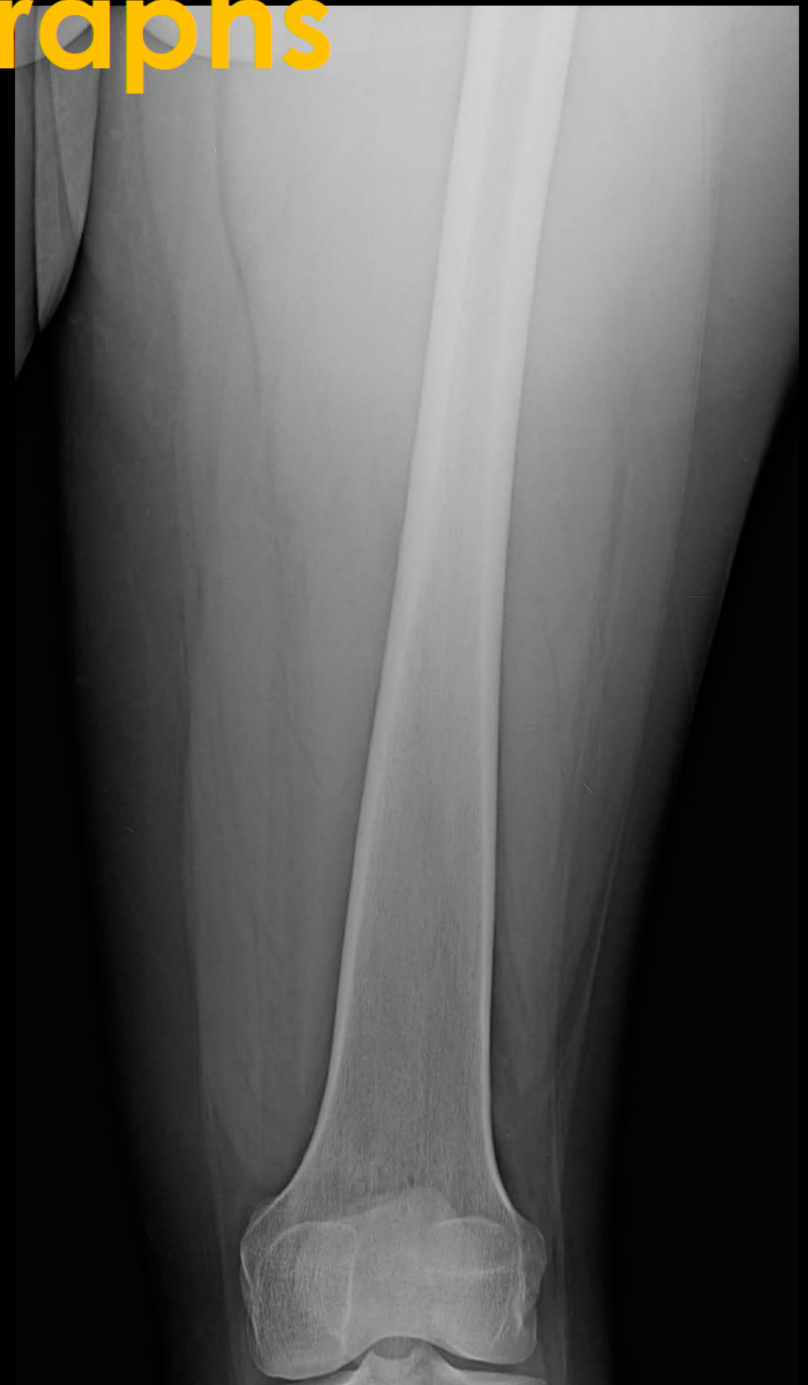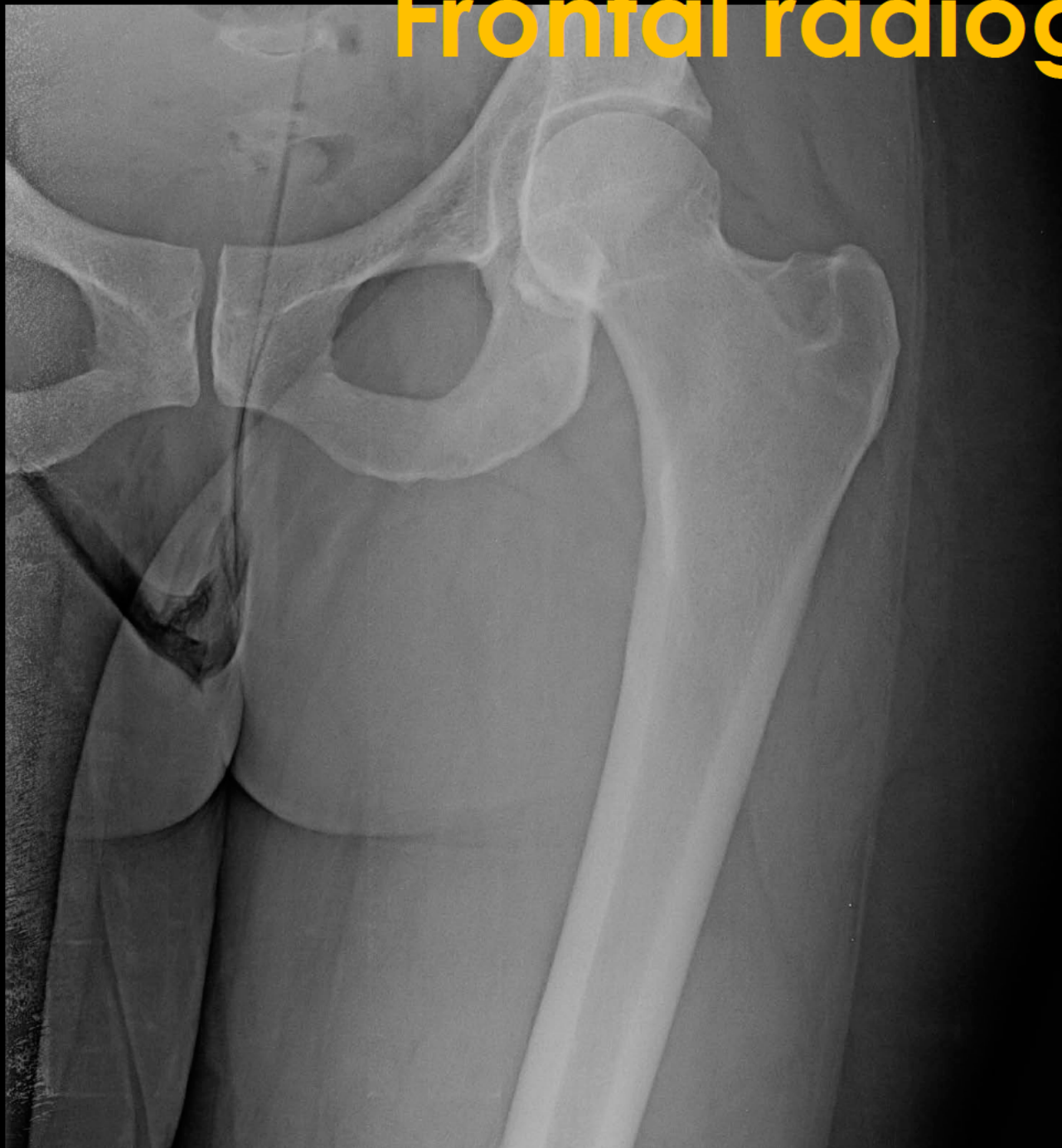A PROGRAM OF THE
AMERICAN COLLEGE OF RADIOLOGY

BEST CASE MSK

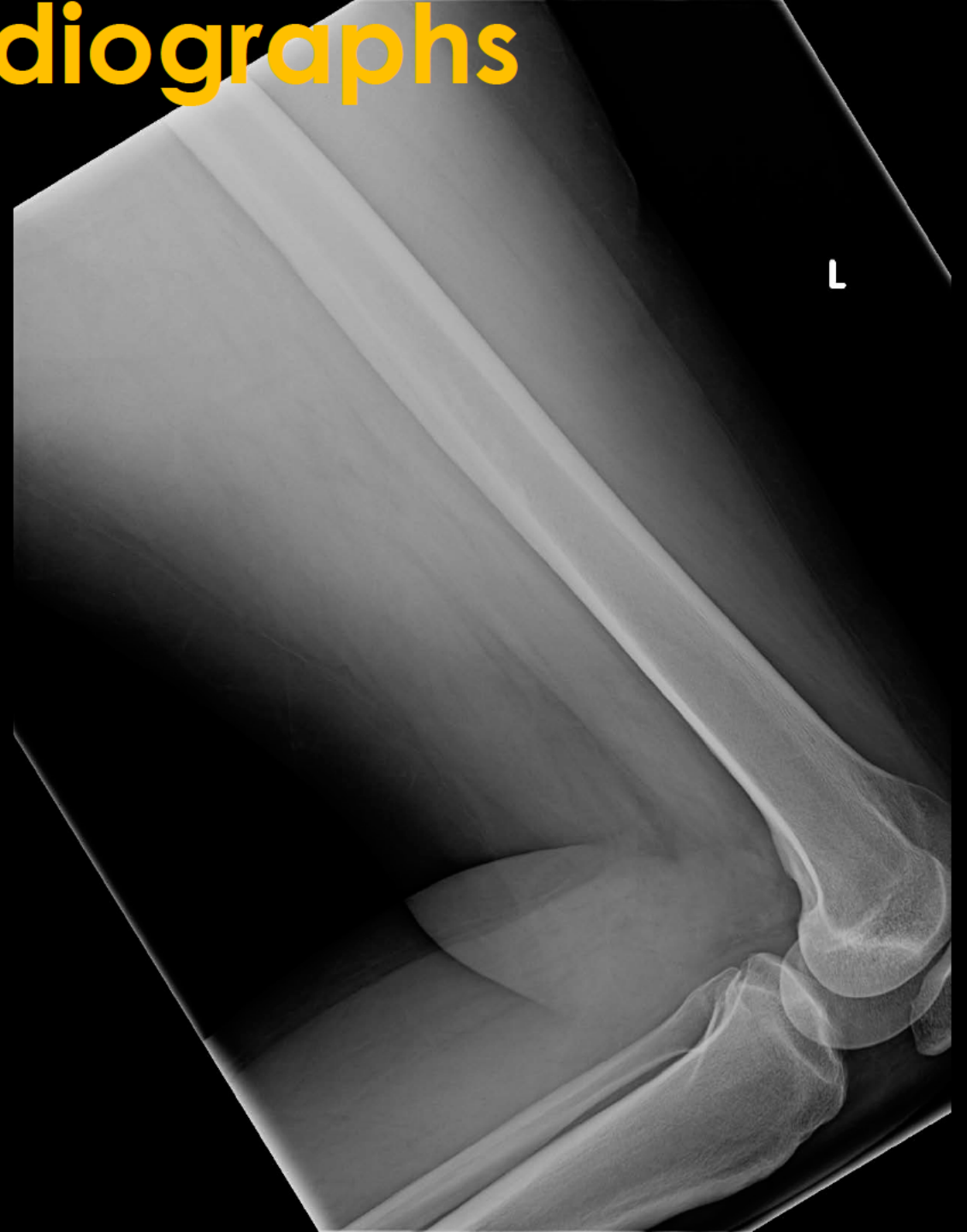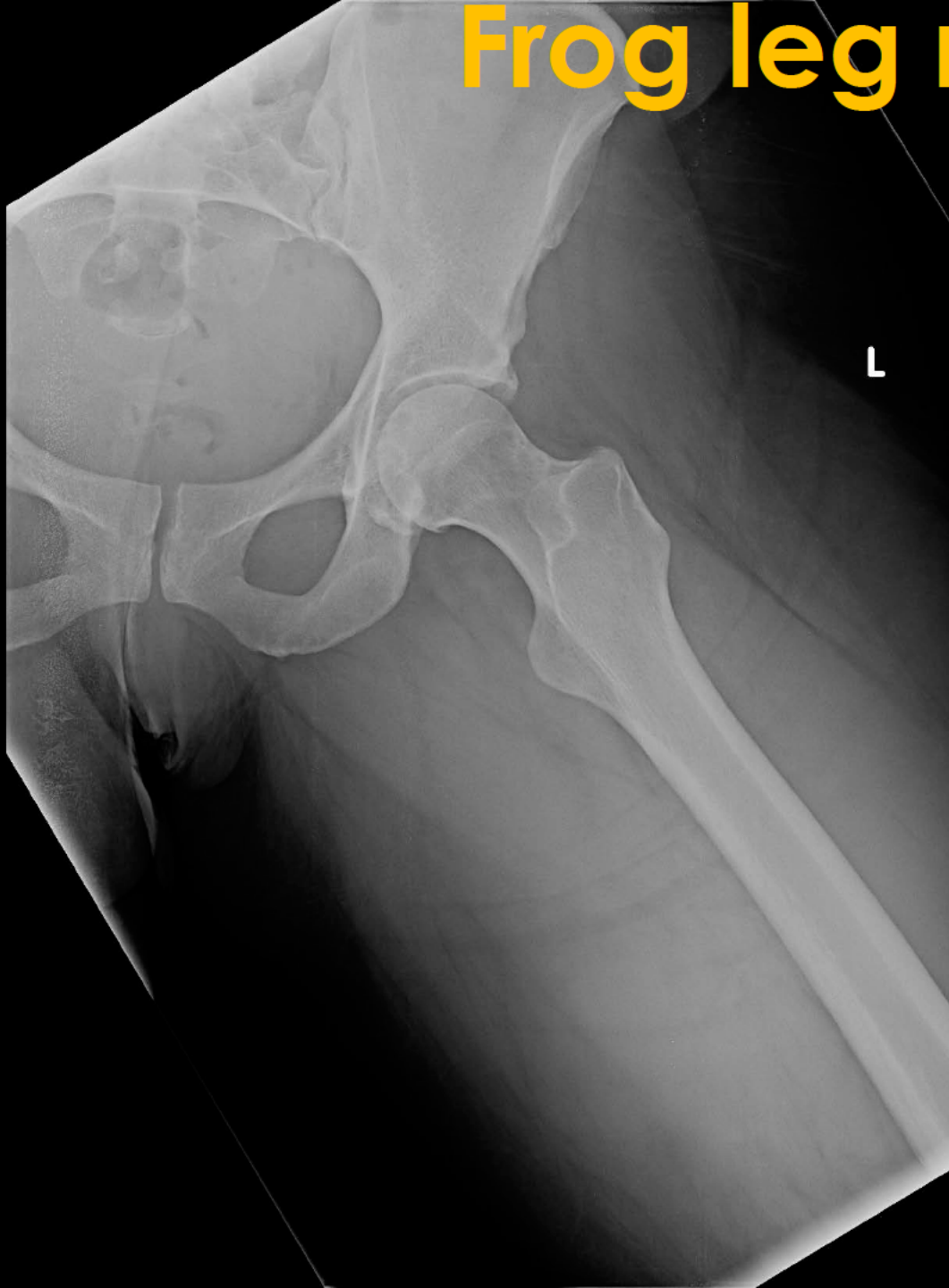February – March 2019

44 year old female complains of a lump in her posterior thigh she noticed 2 years ago; now it has grown and become more painful

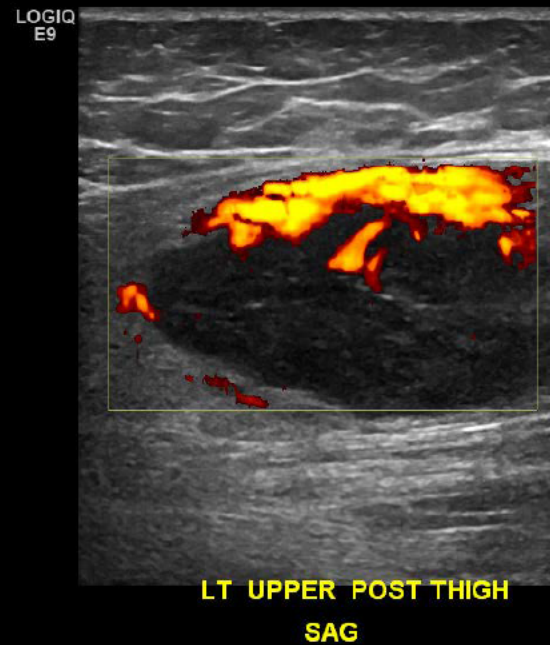
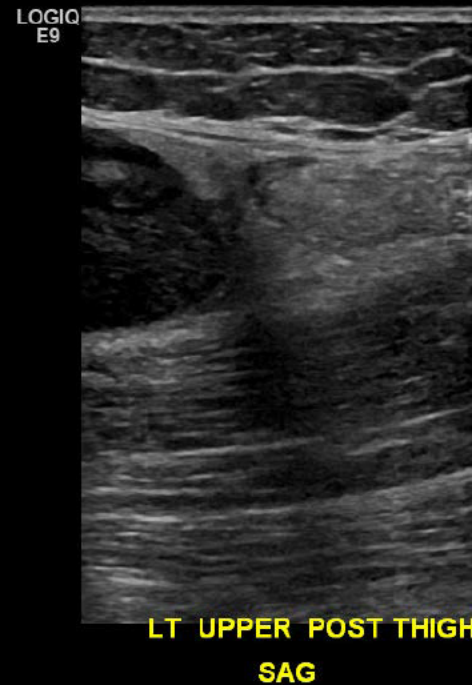
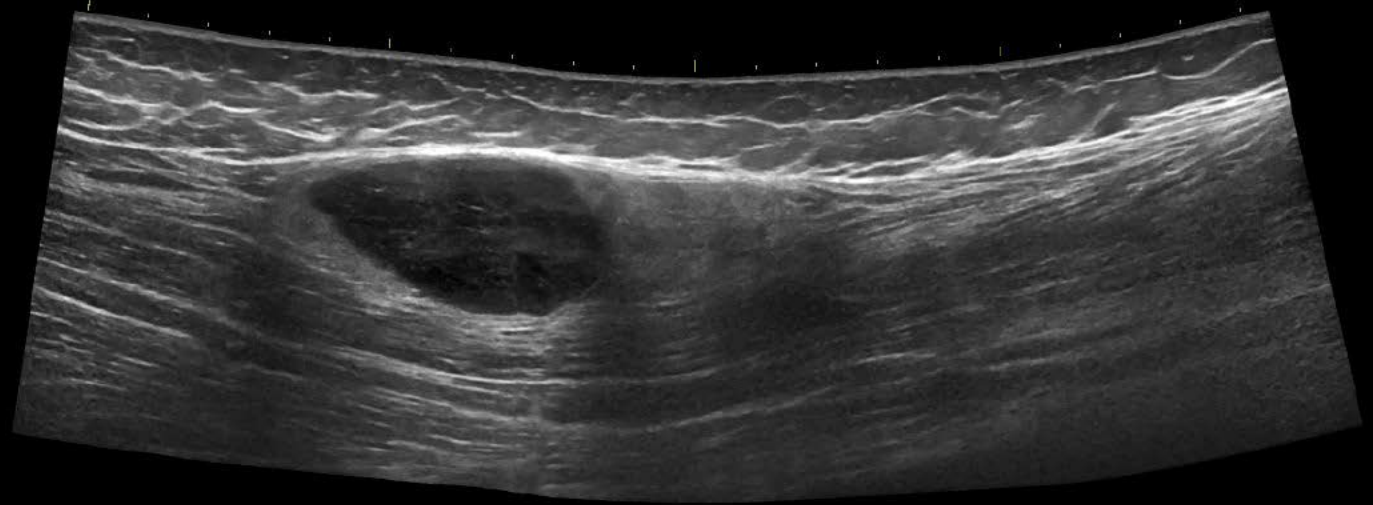
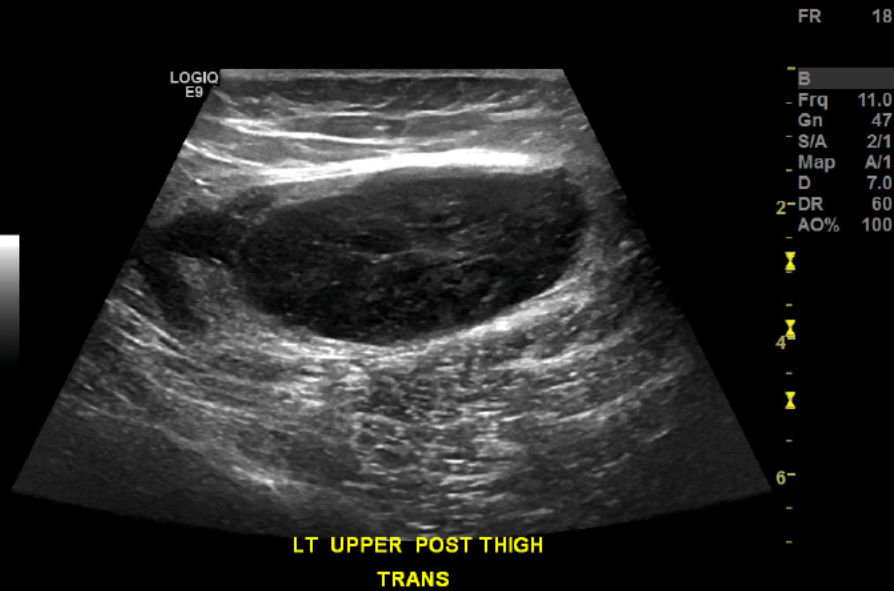
Frontal radiographs



Frog leg radiographs

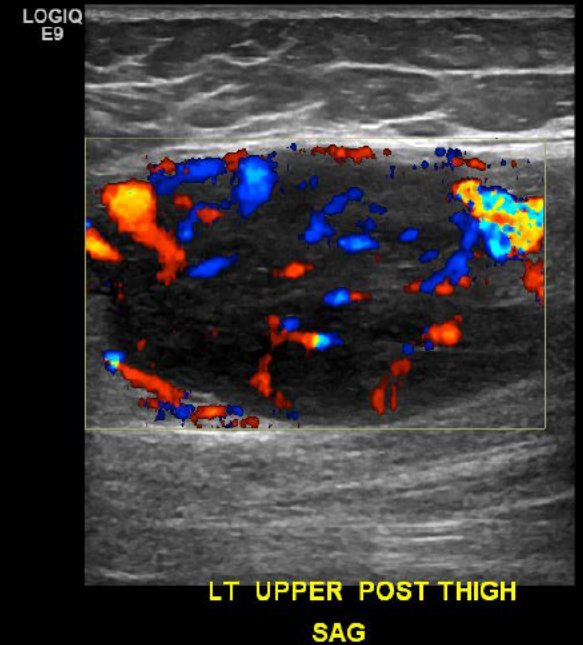


Ultrasound with doppler

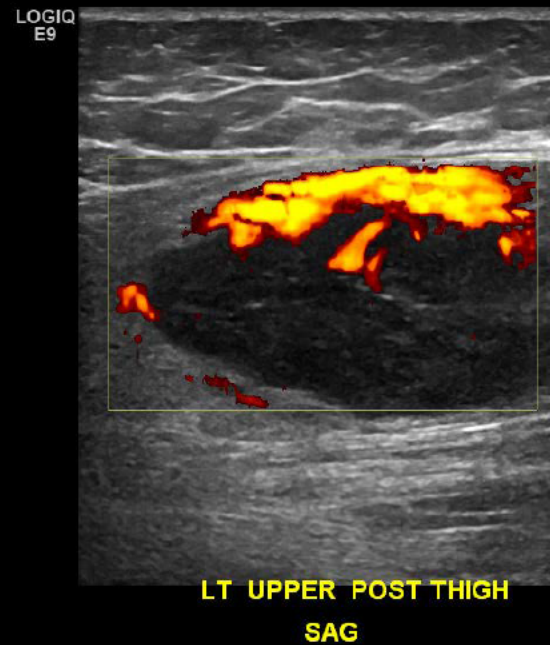
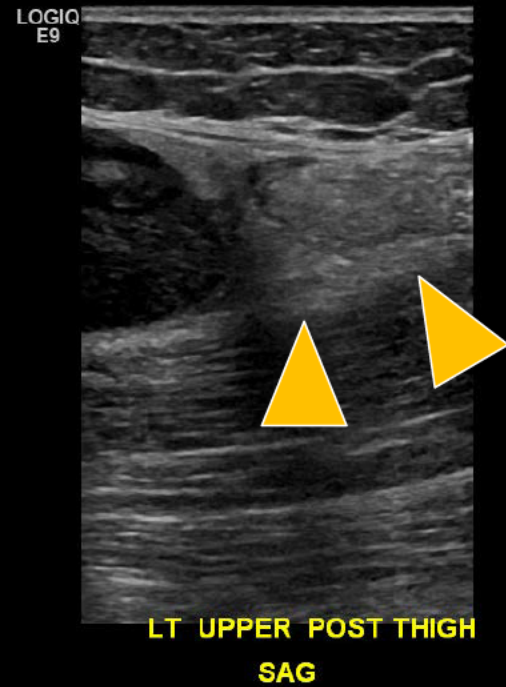
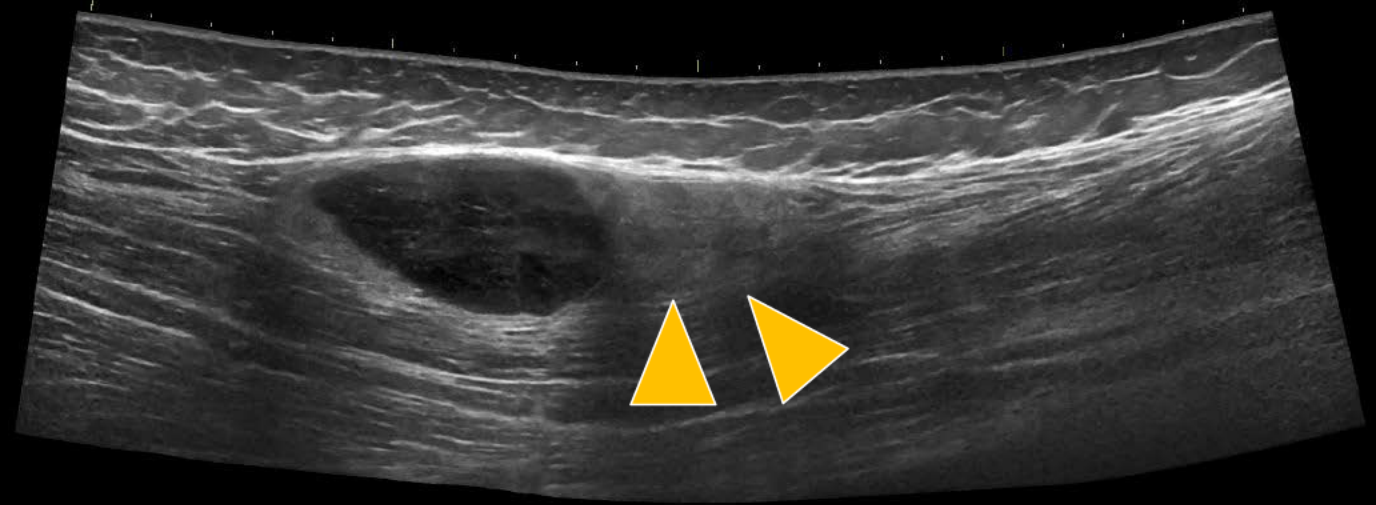
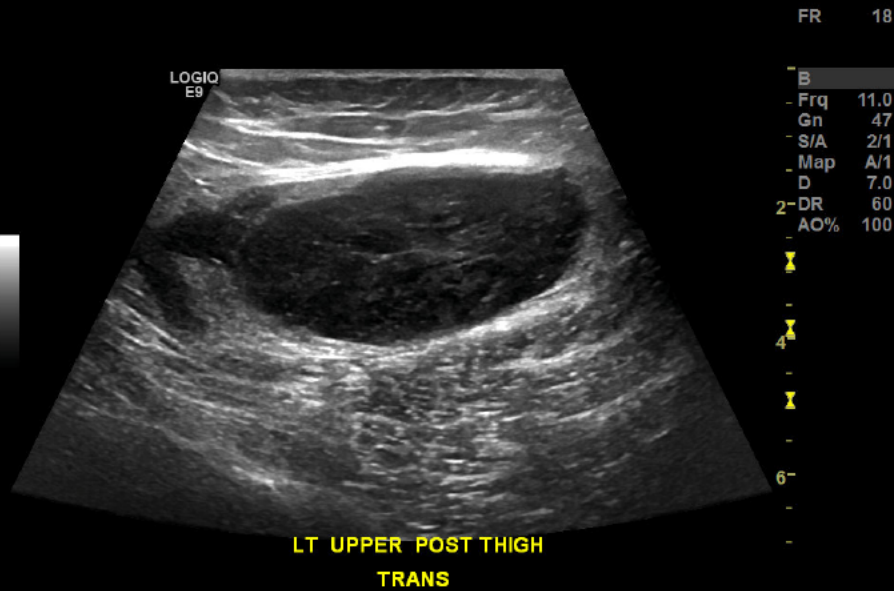


LT UPPER POST THIGH

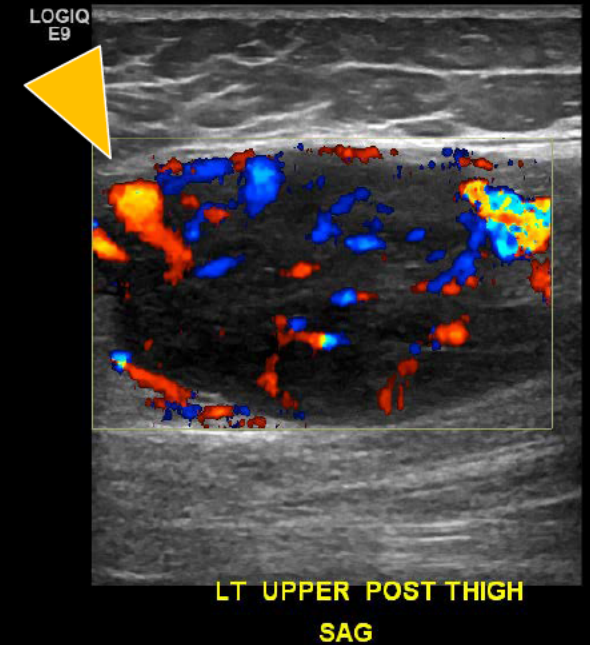
5
-5
cm/s



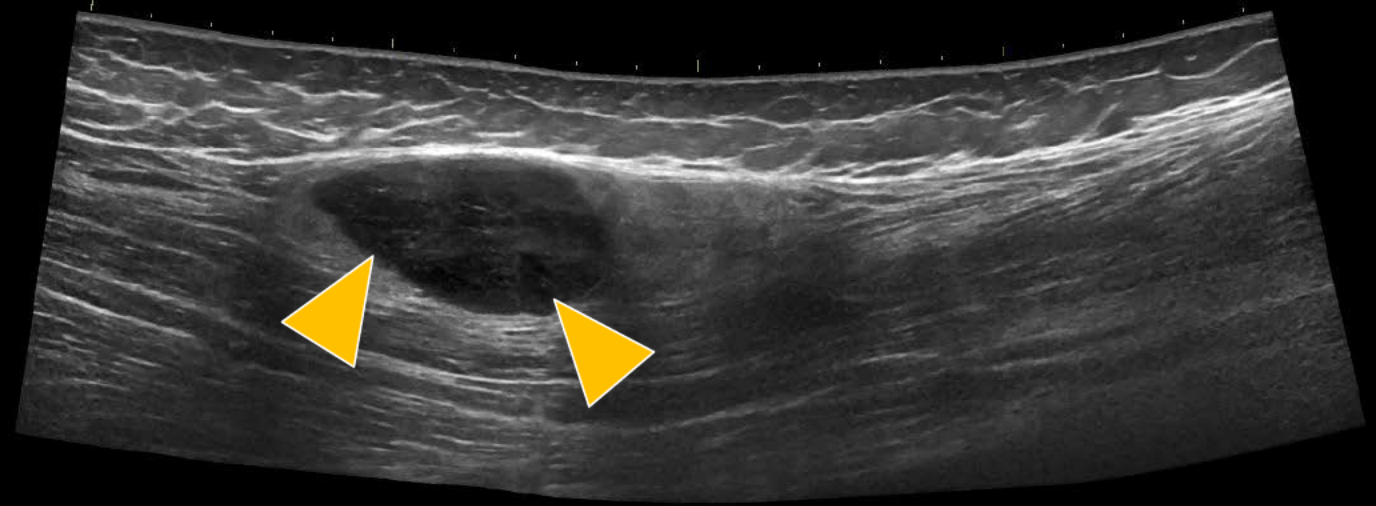
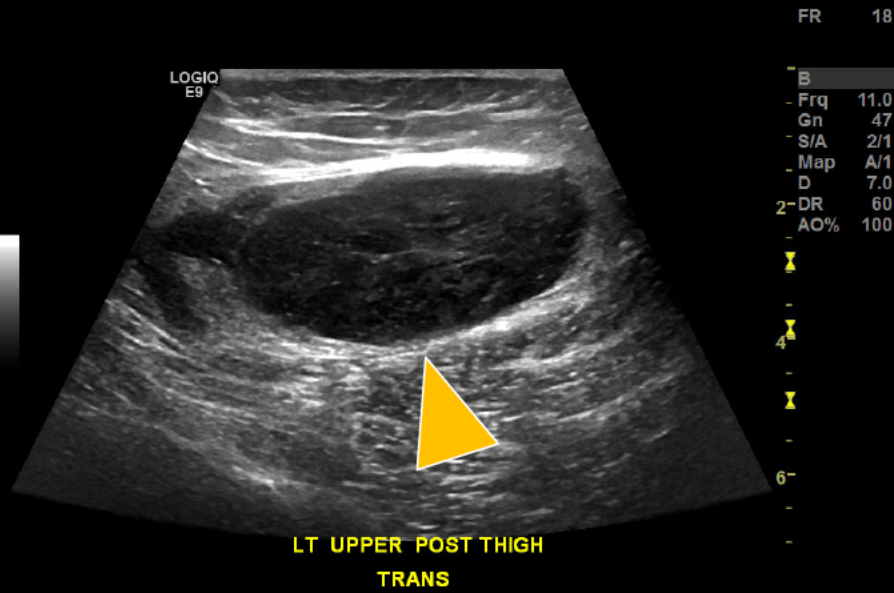
Ultrasound with doppler



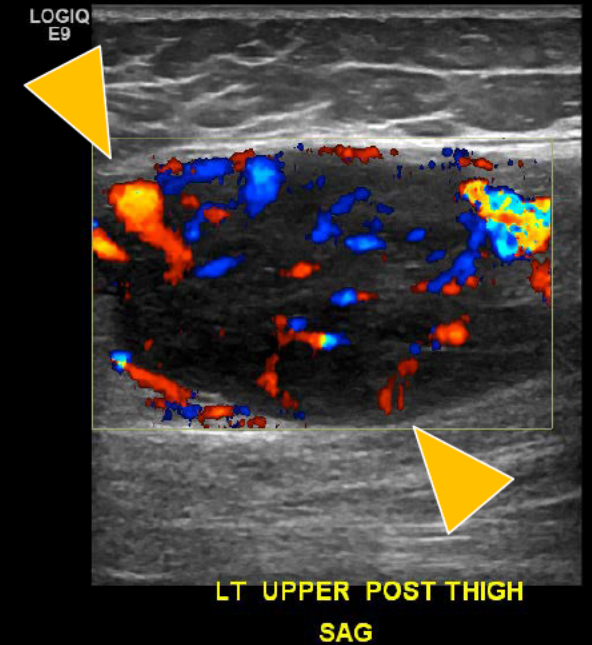
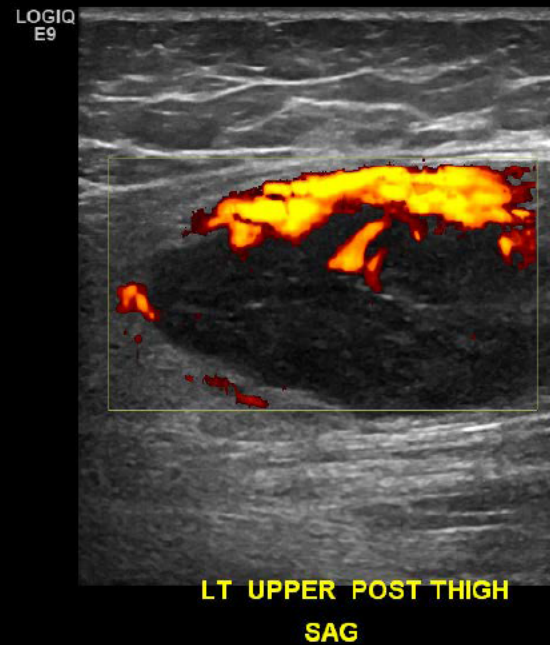
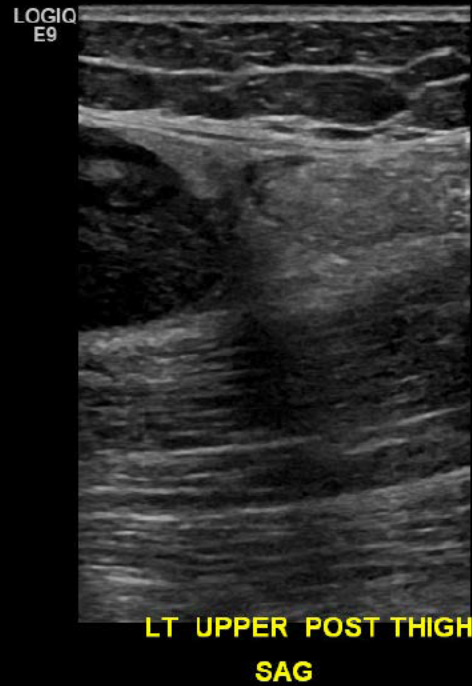LT UPPER POST THIGH



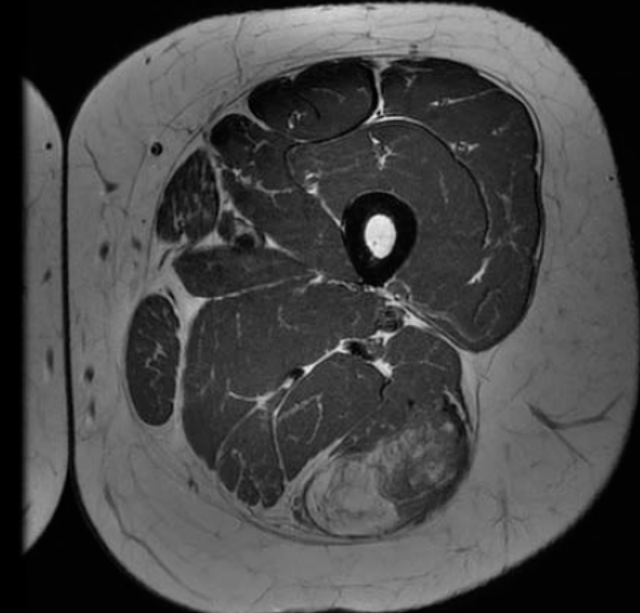
Ultrasound with doppler



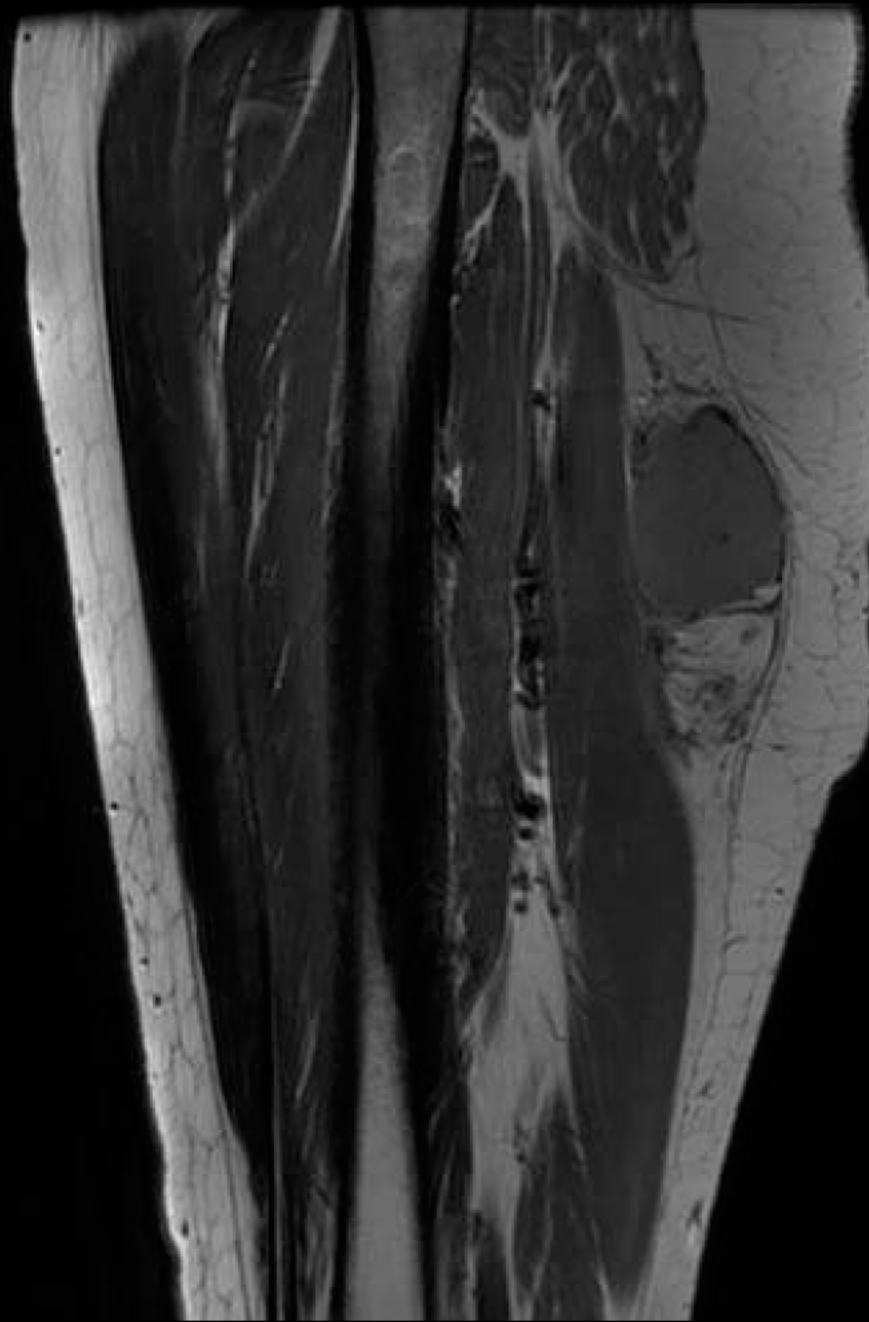
LT UPPER POST THIGH



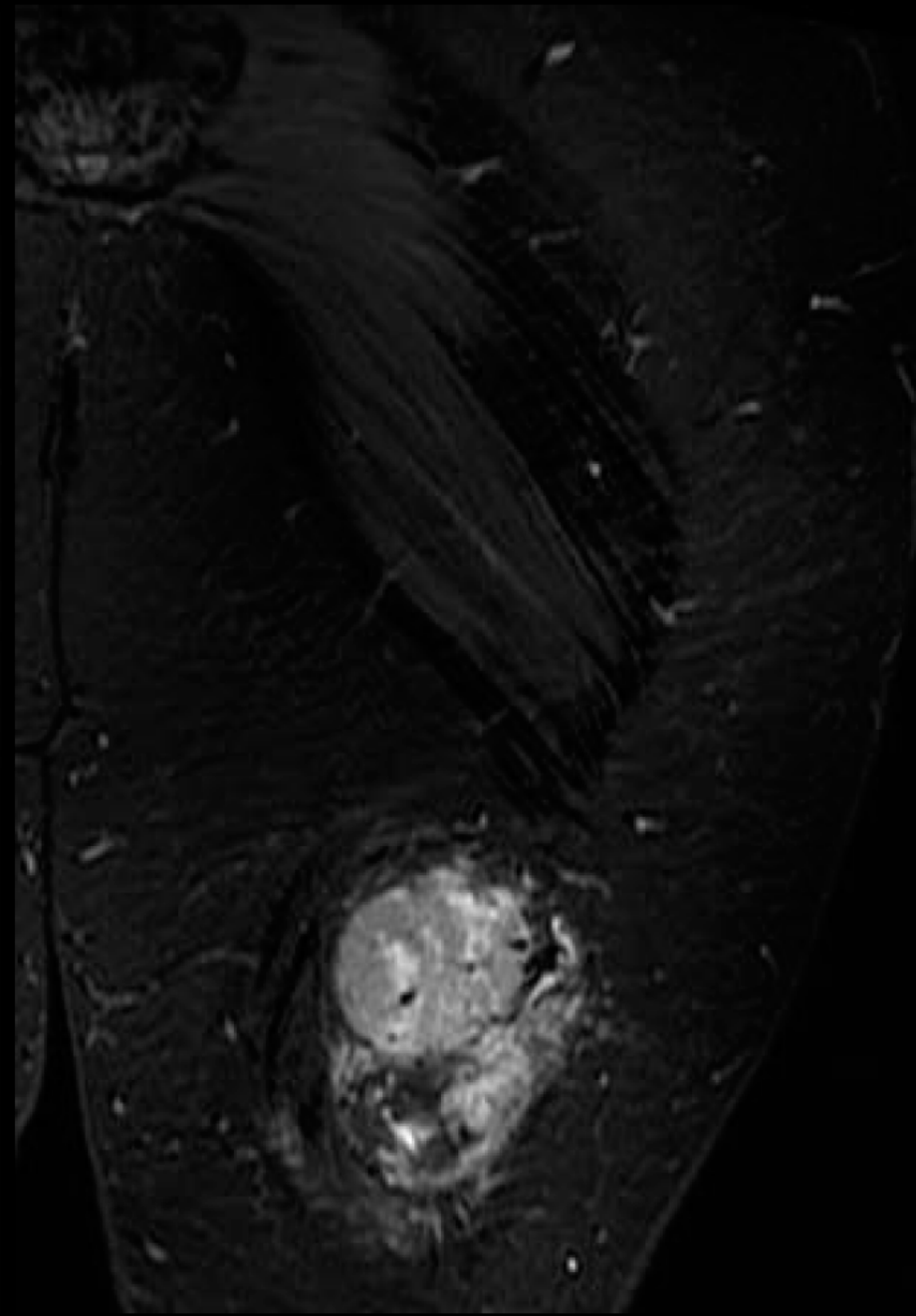
Axial T1 non FS



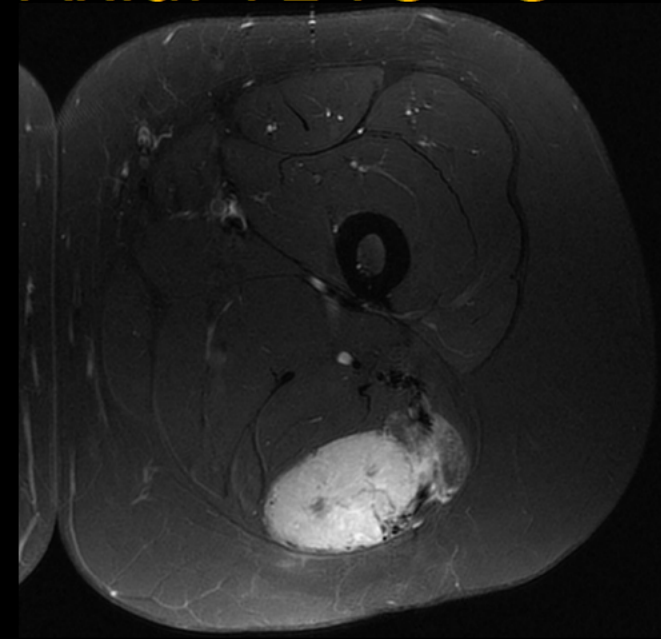
Sagittal T1 non FS



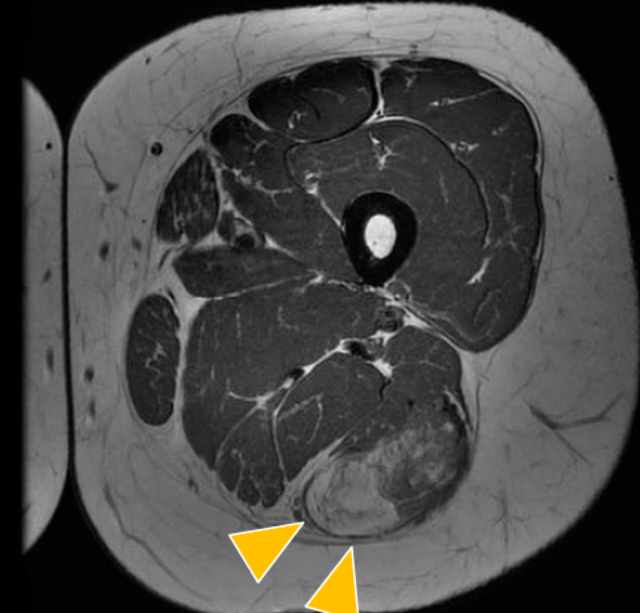
Coronal STIR



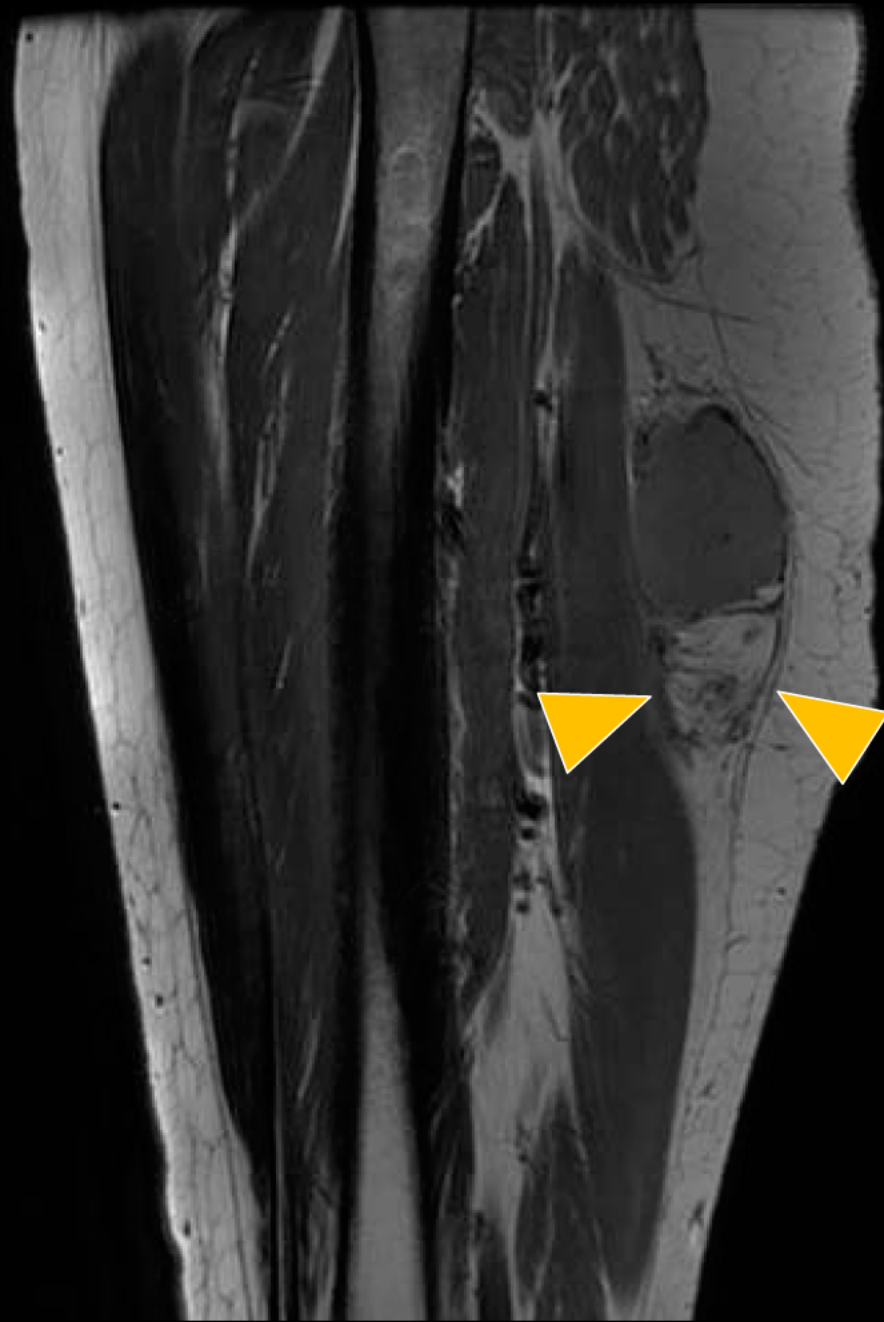Axial T1 FS +C



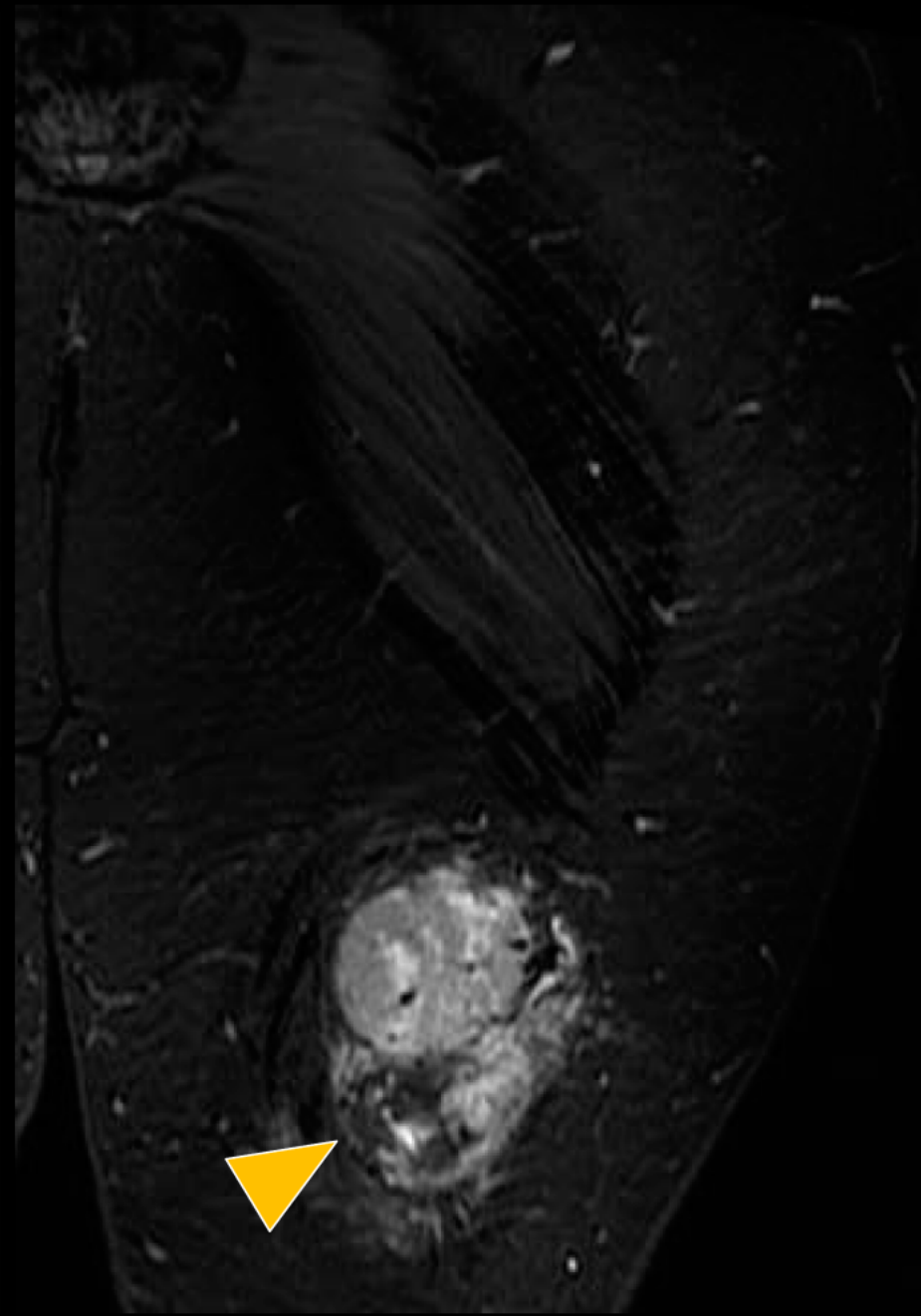
Axial T1 non FS



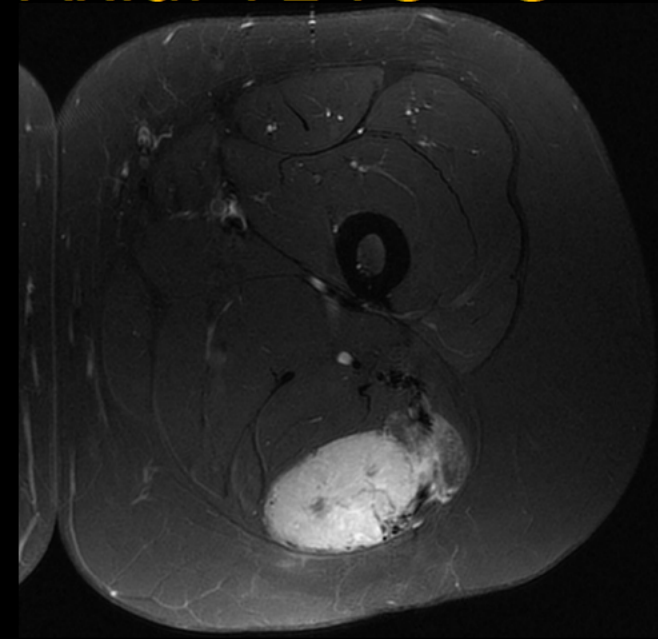
Sagittal T1 non FS



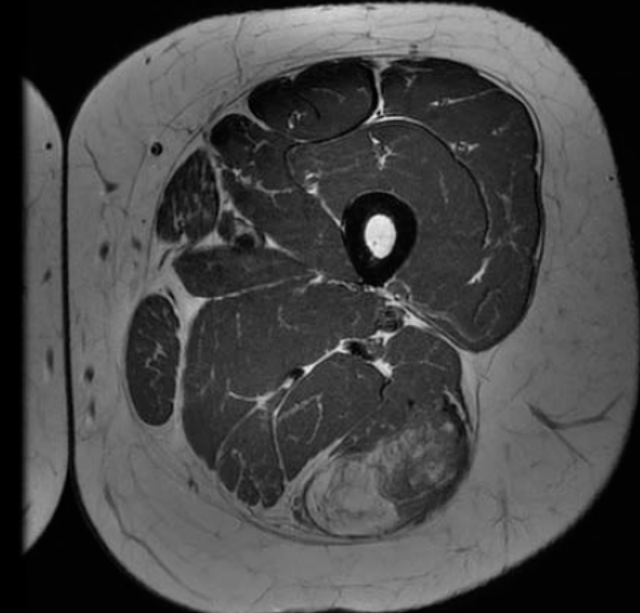
Coronal STIR



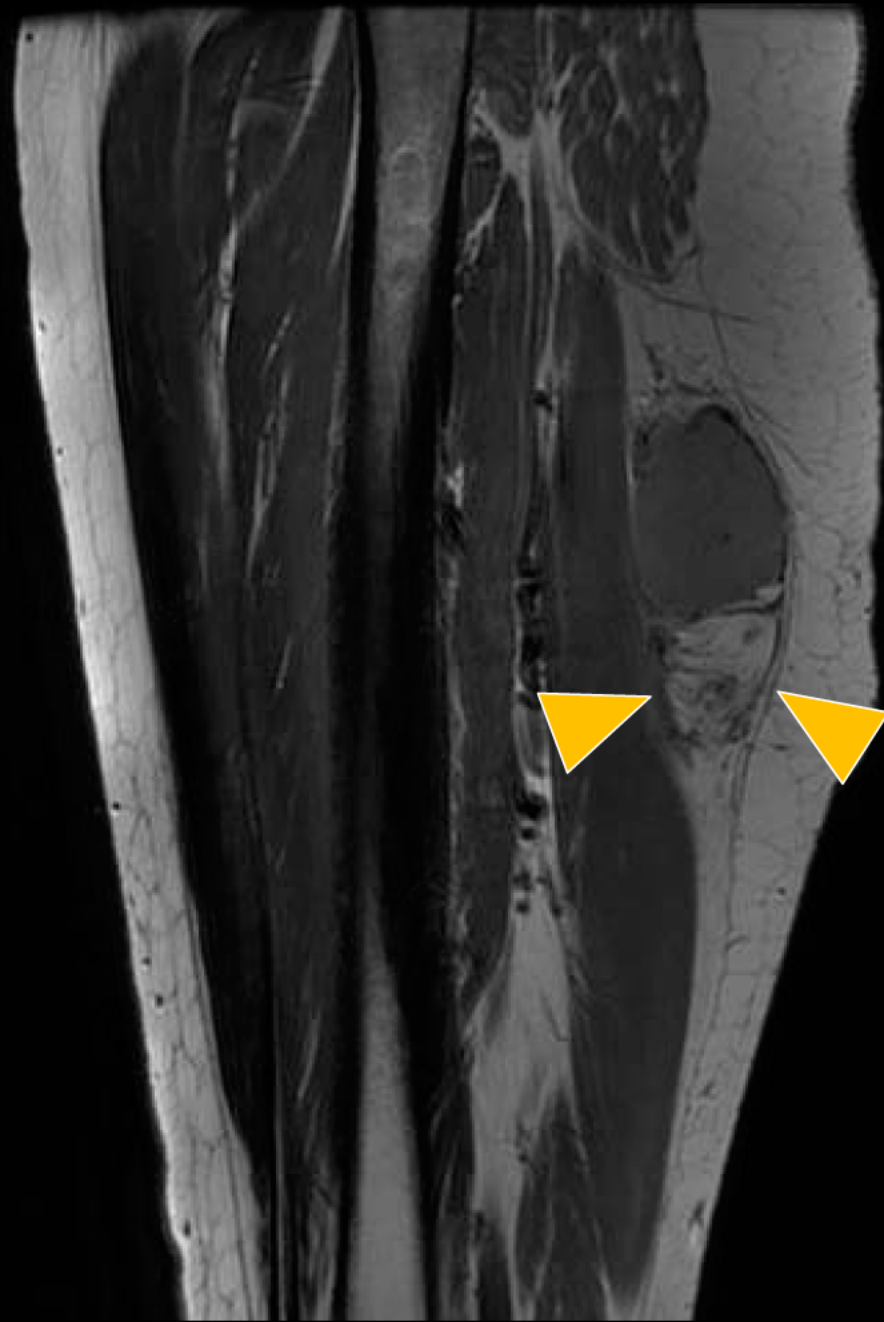Axial T1 FS +C



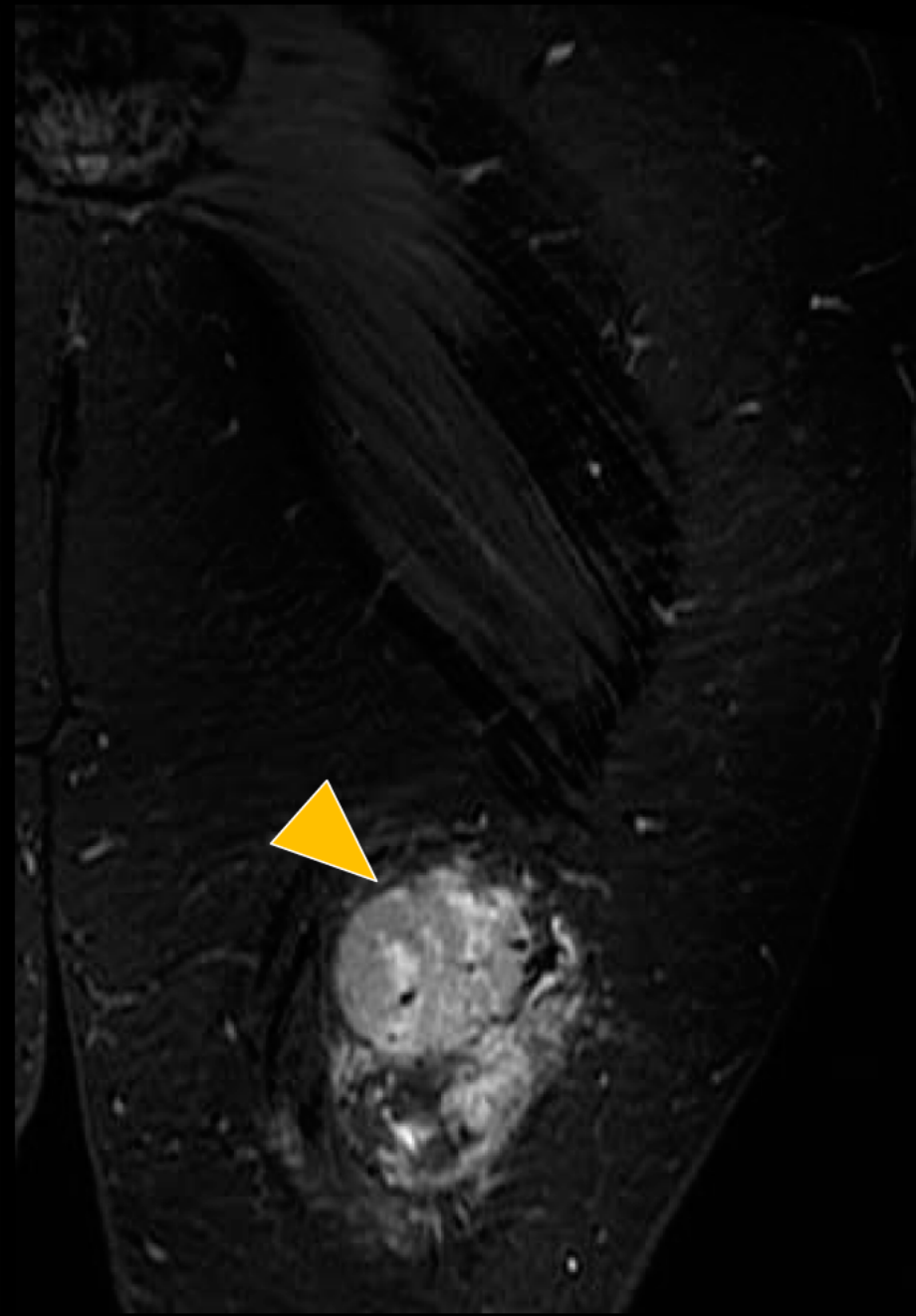
Axial T1 non FS



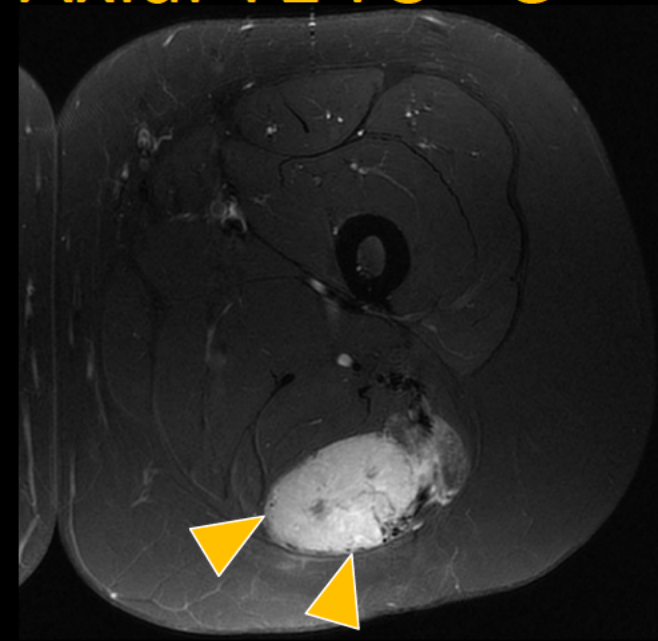
Sagittal T1 non FS



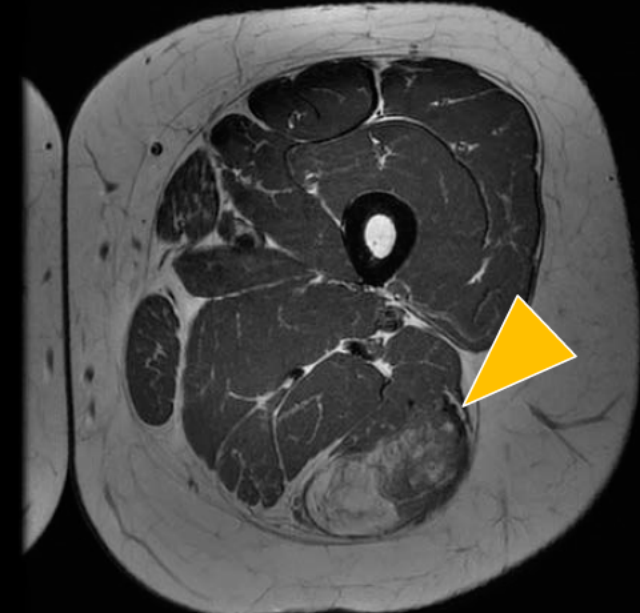
Coronal STIR



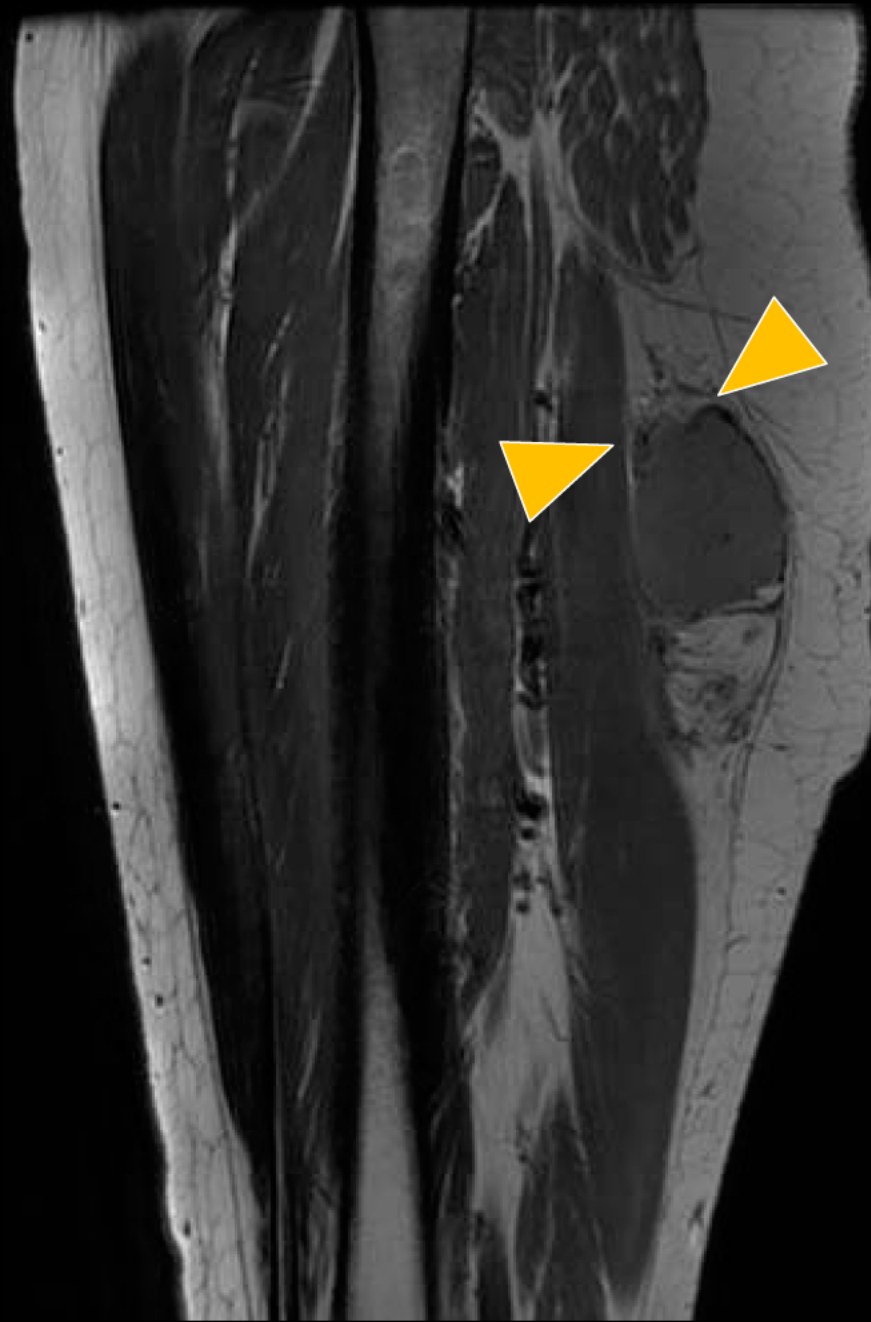
Axial T1 FS +C



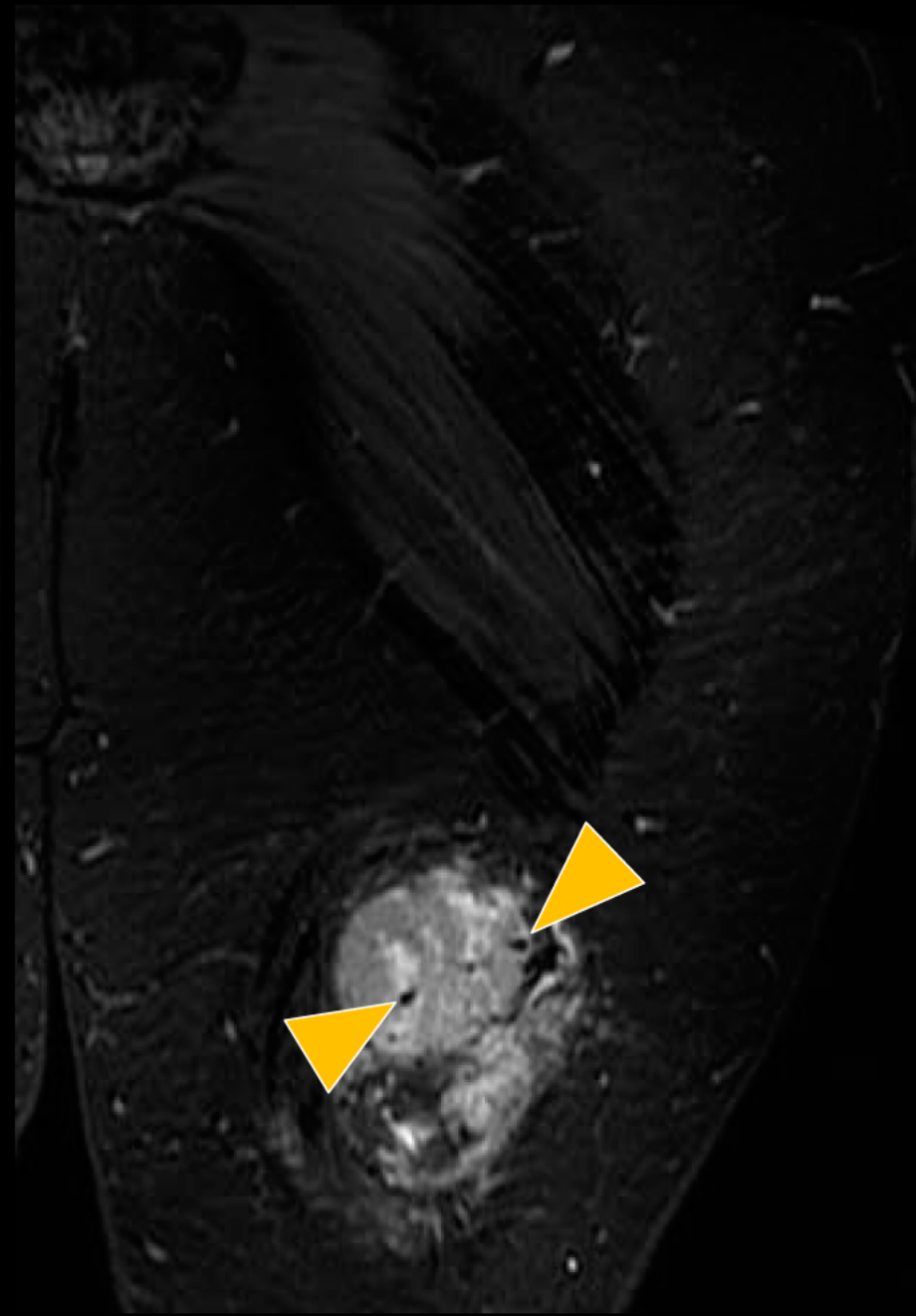
Axial T1 non FS



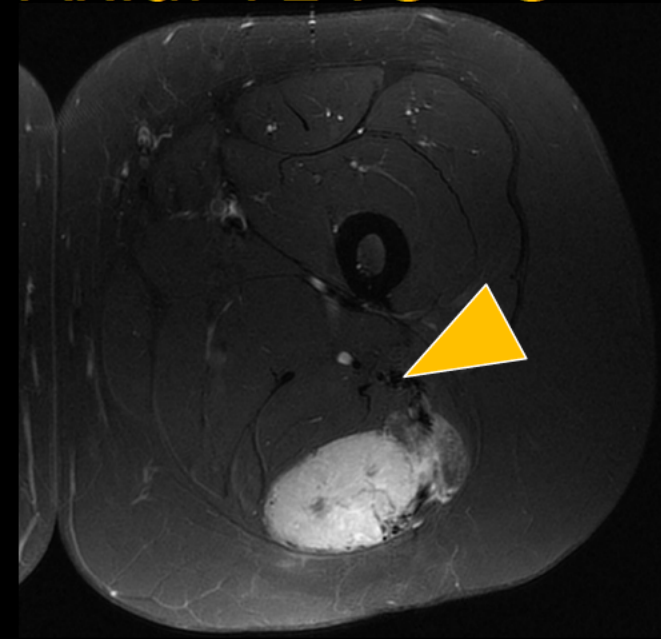
Sagittal T1 non FS

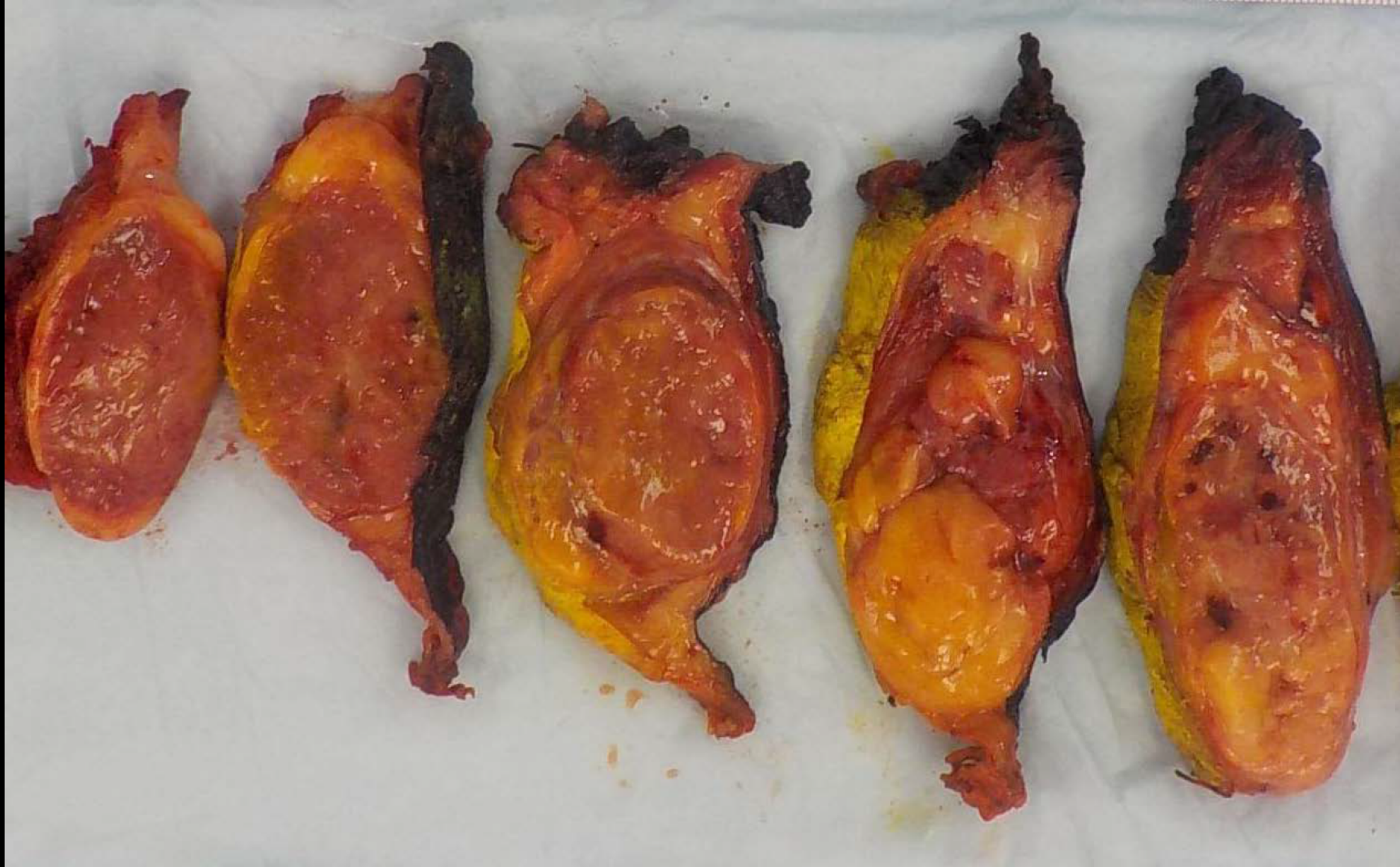

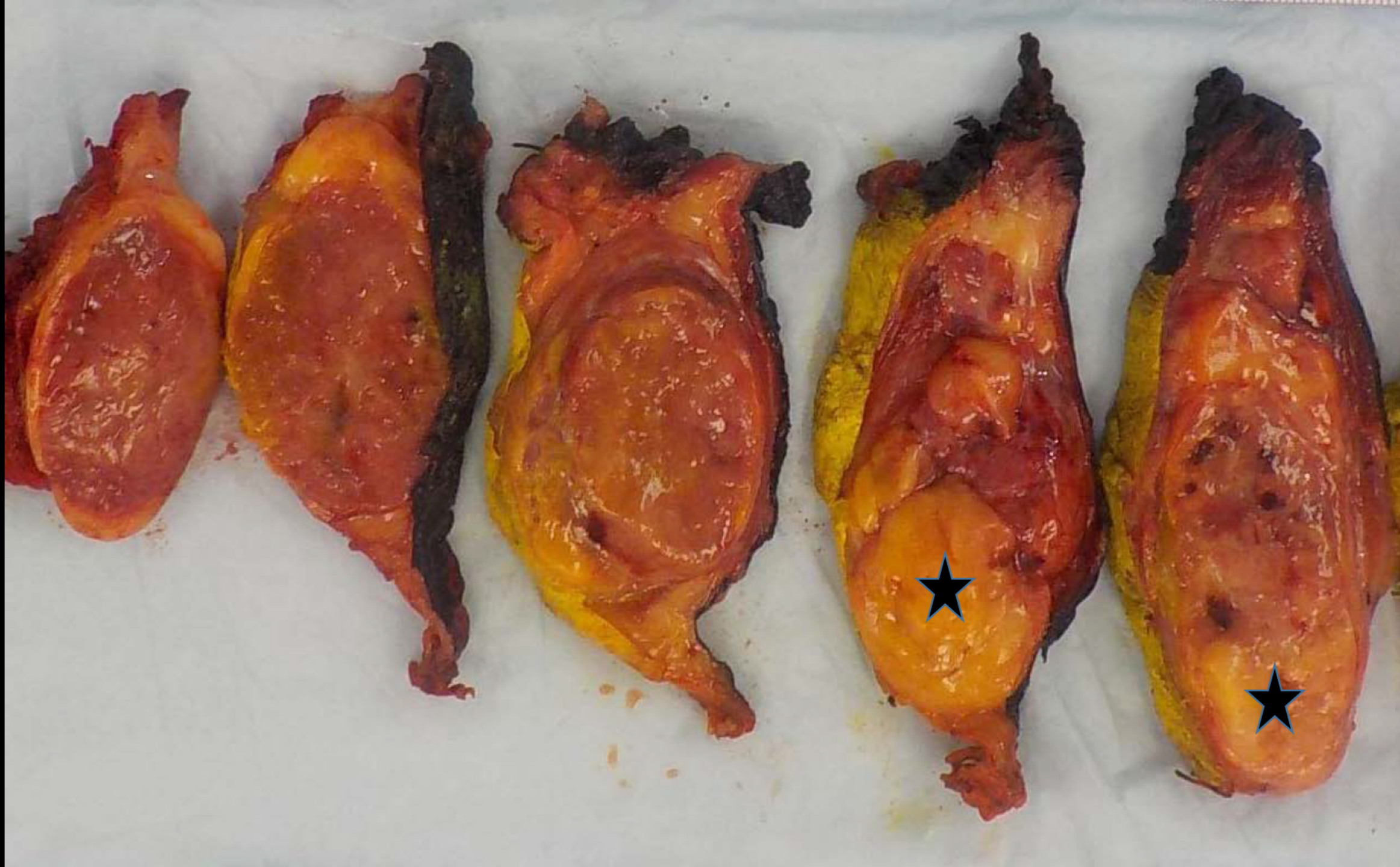
Coronal STIR

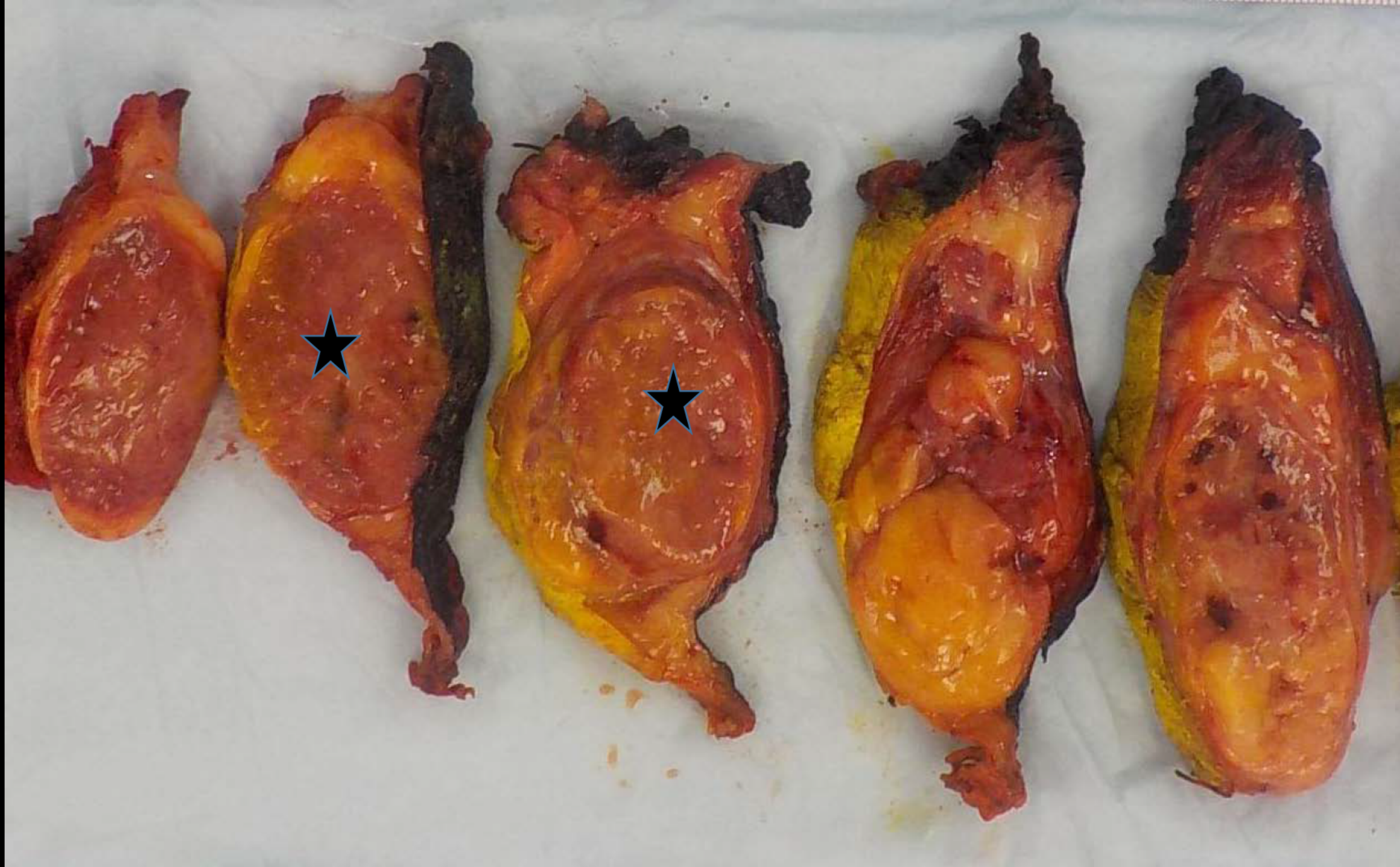


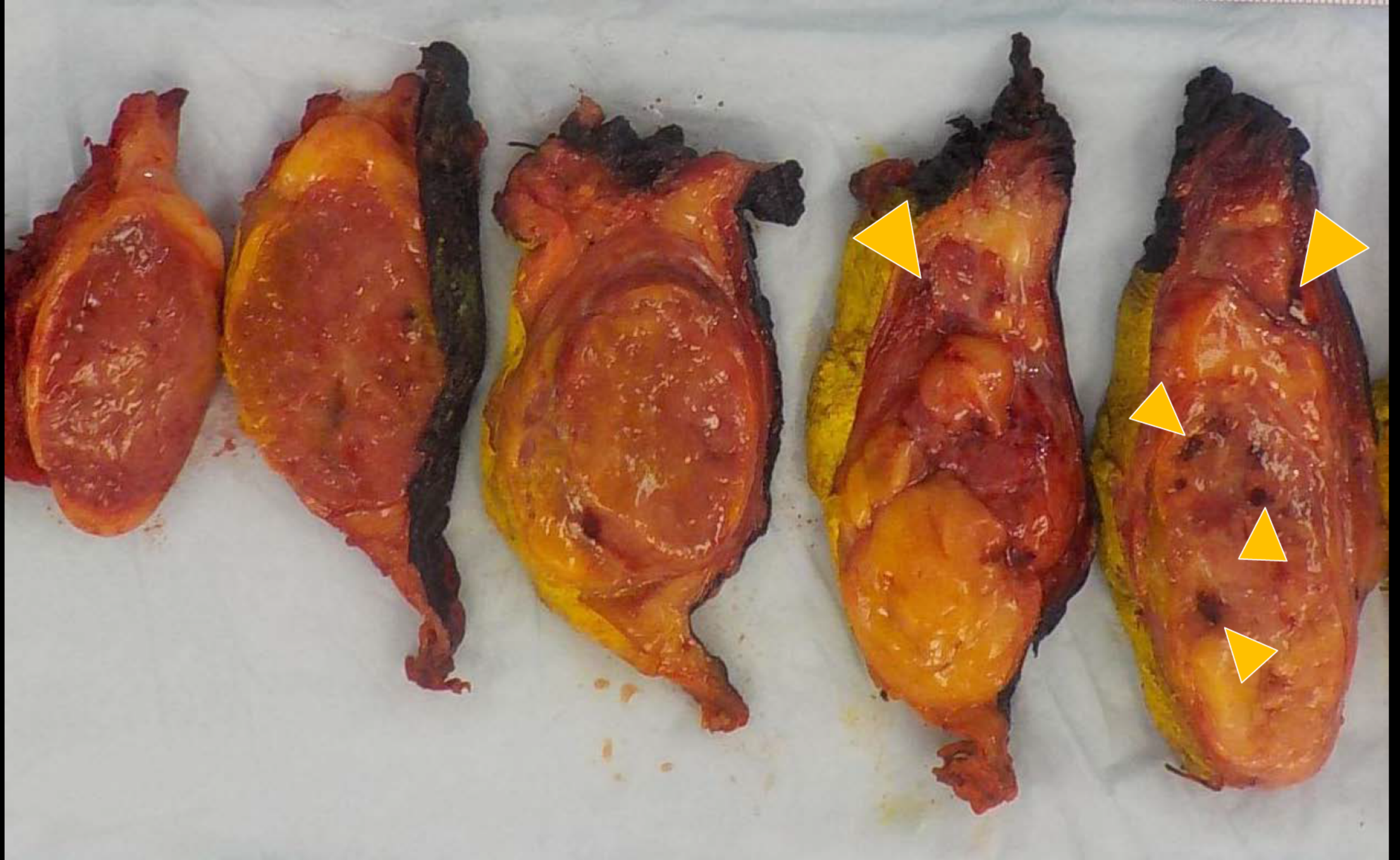Axial T1 FS +C

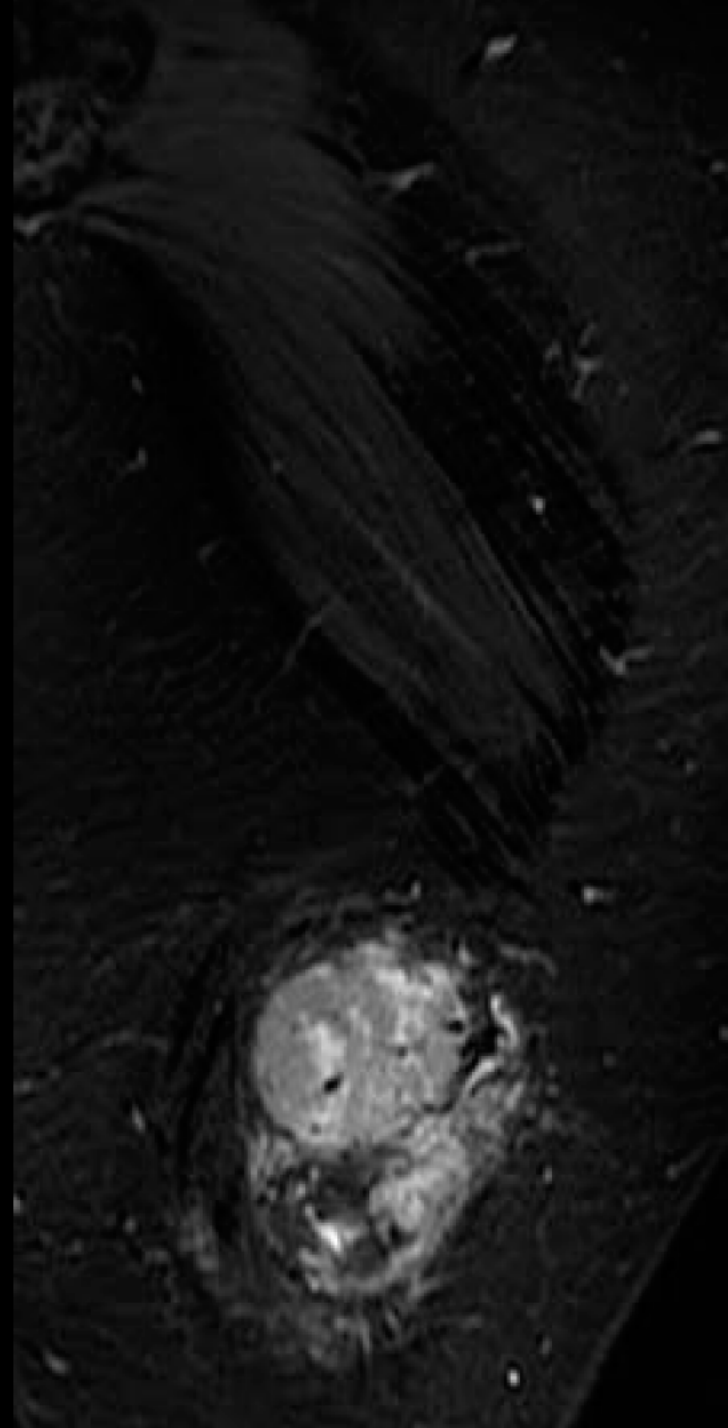
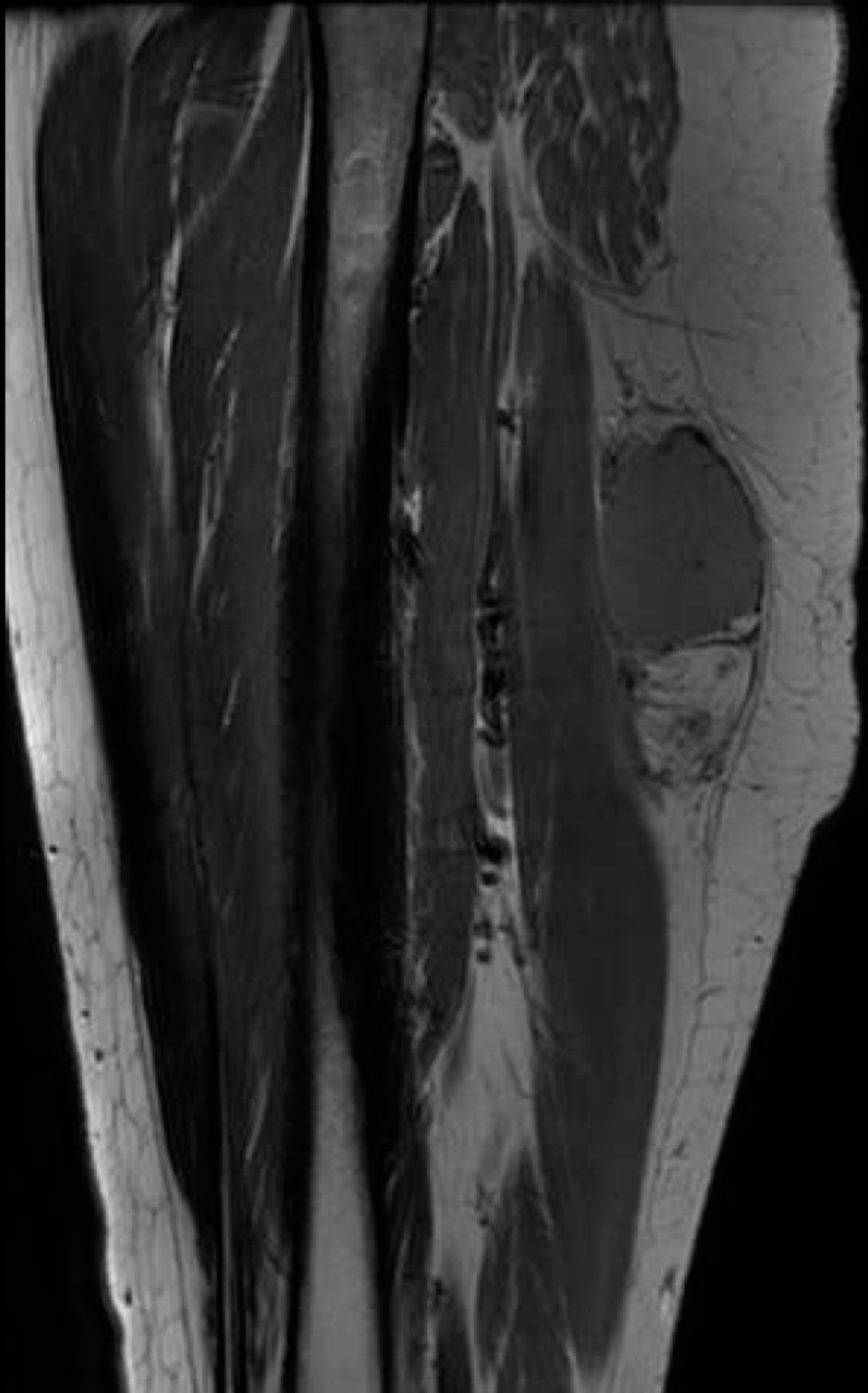


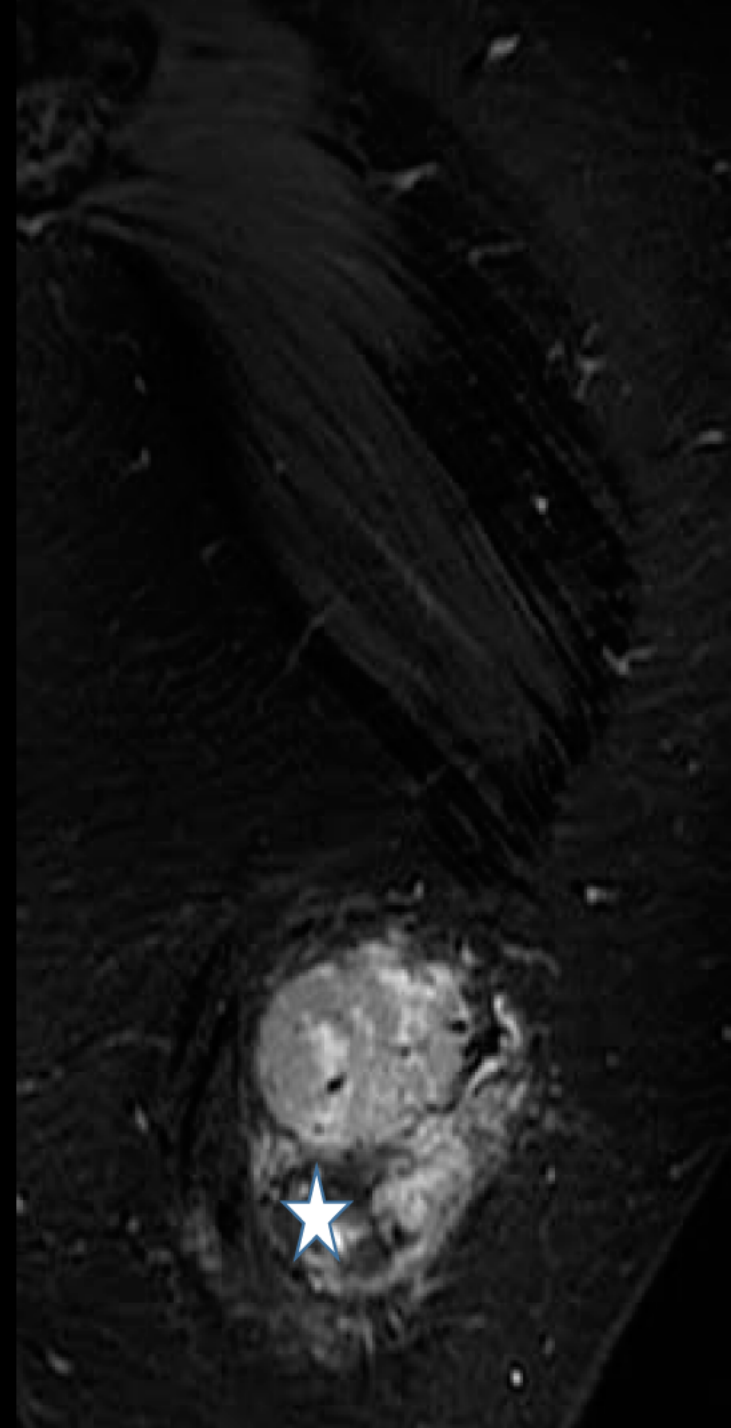
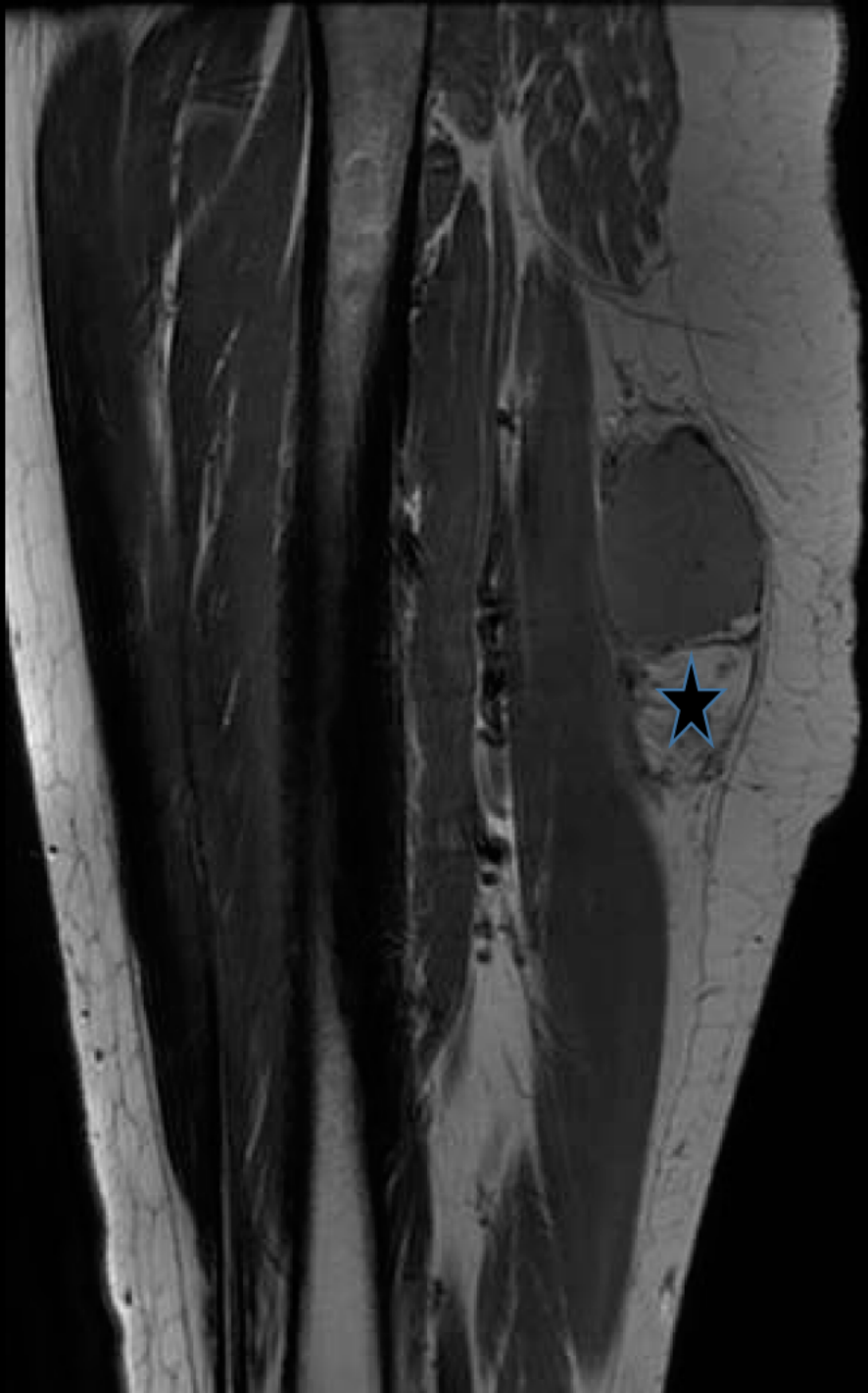



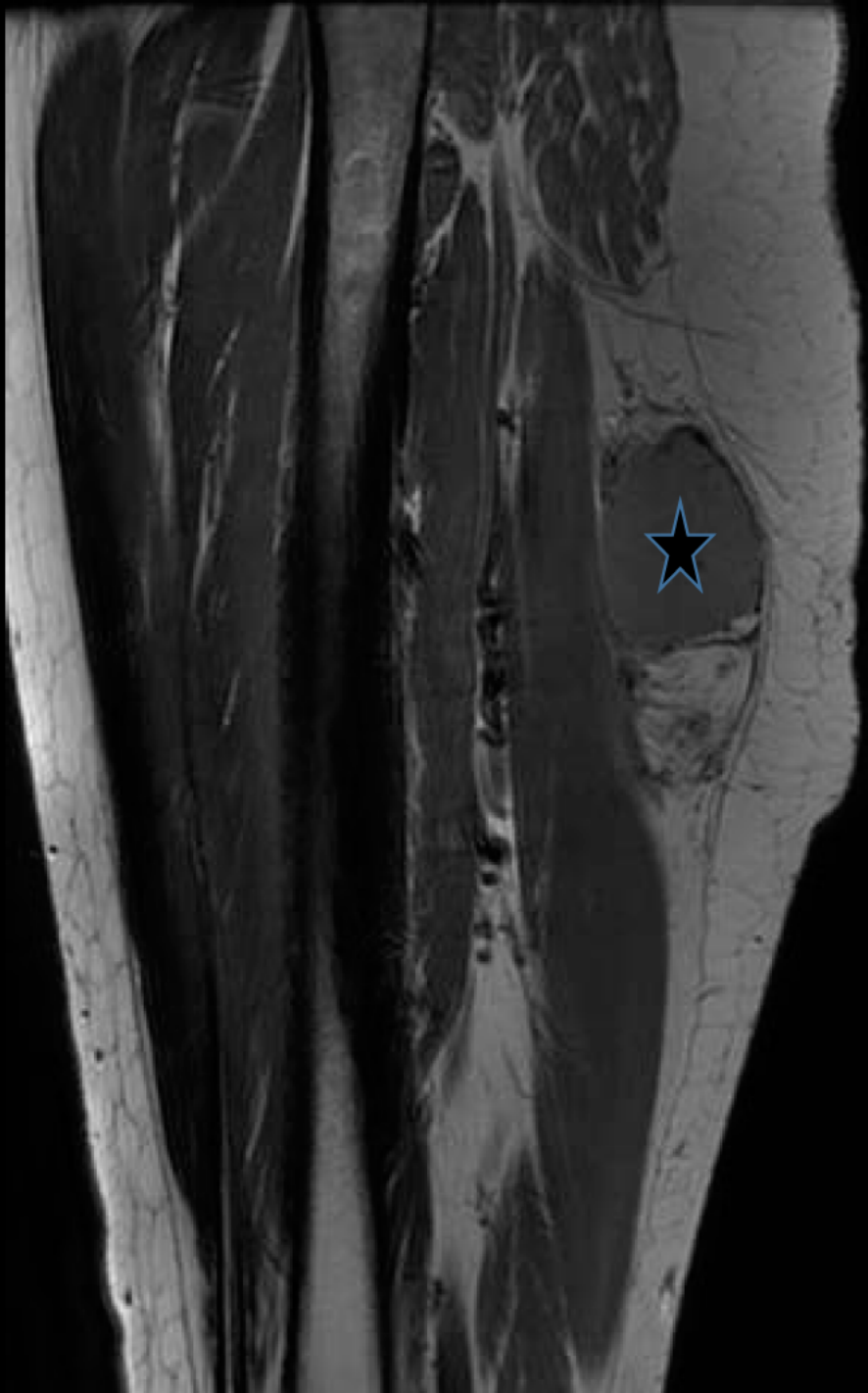


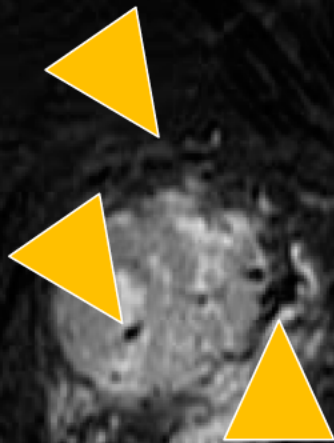
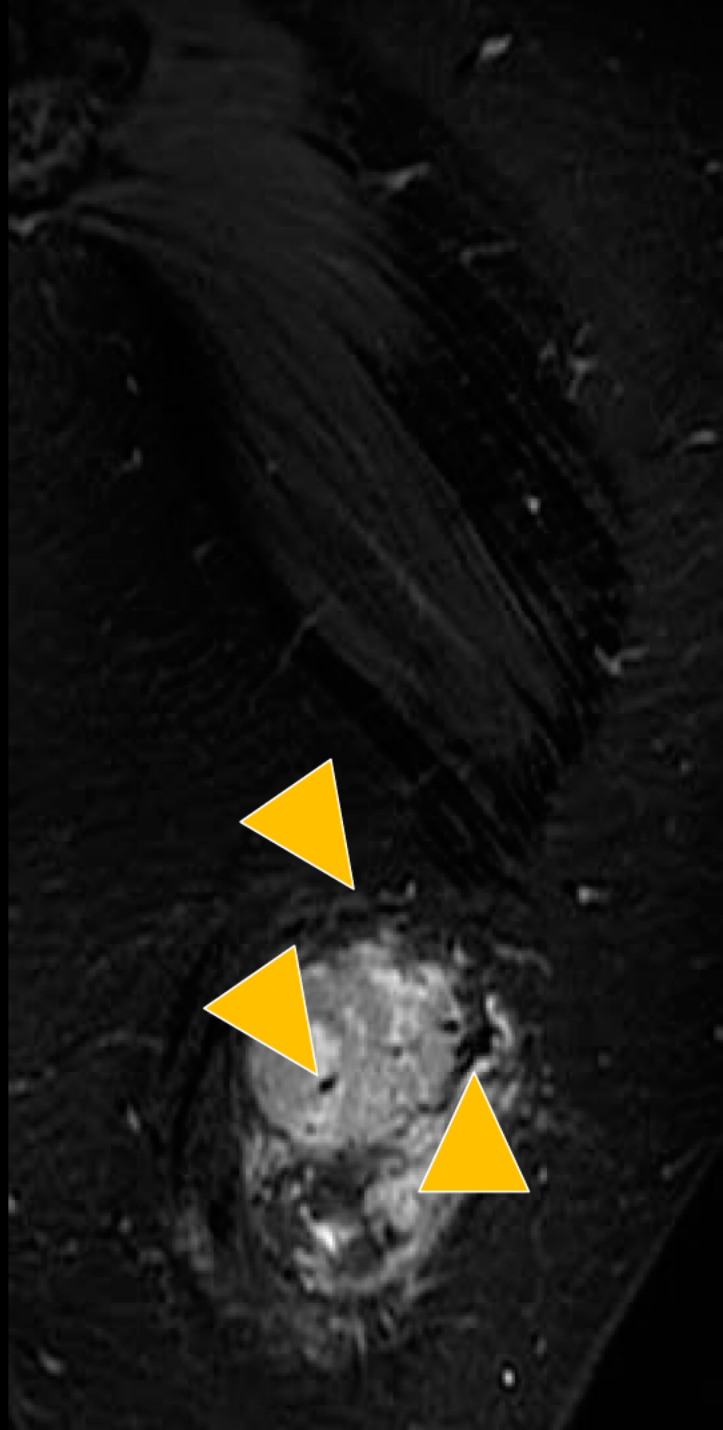

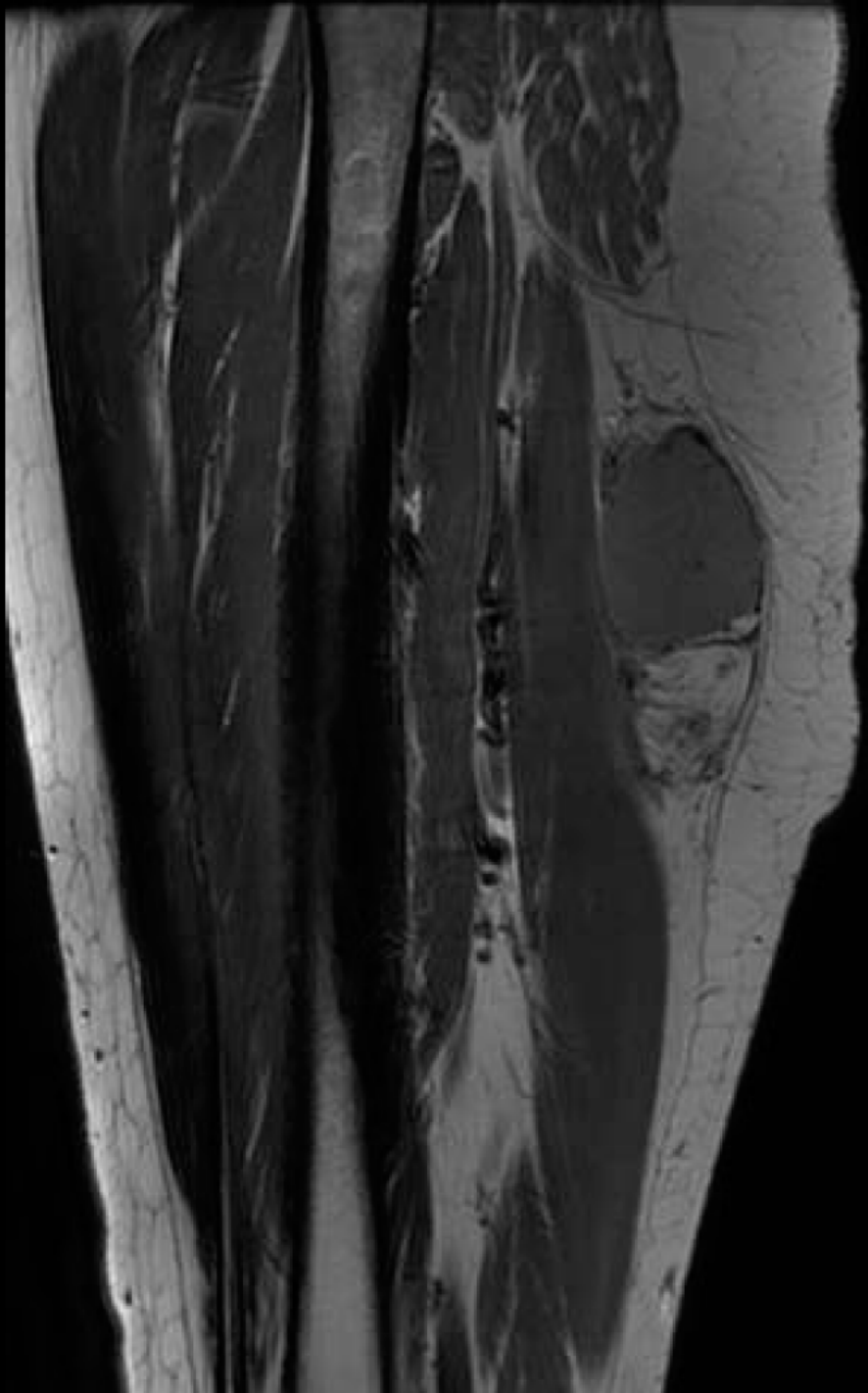


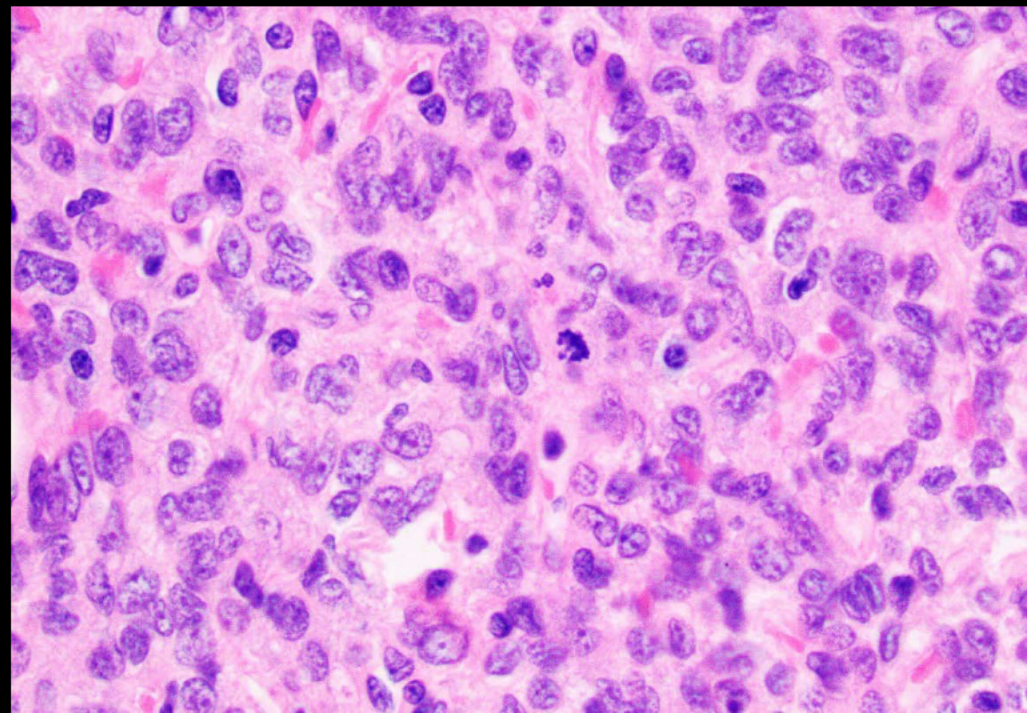
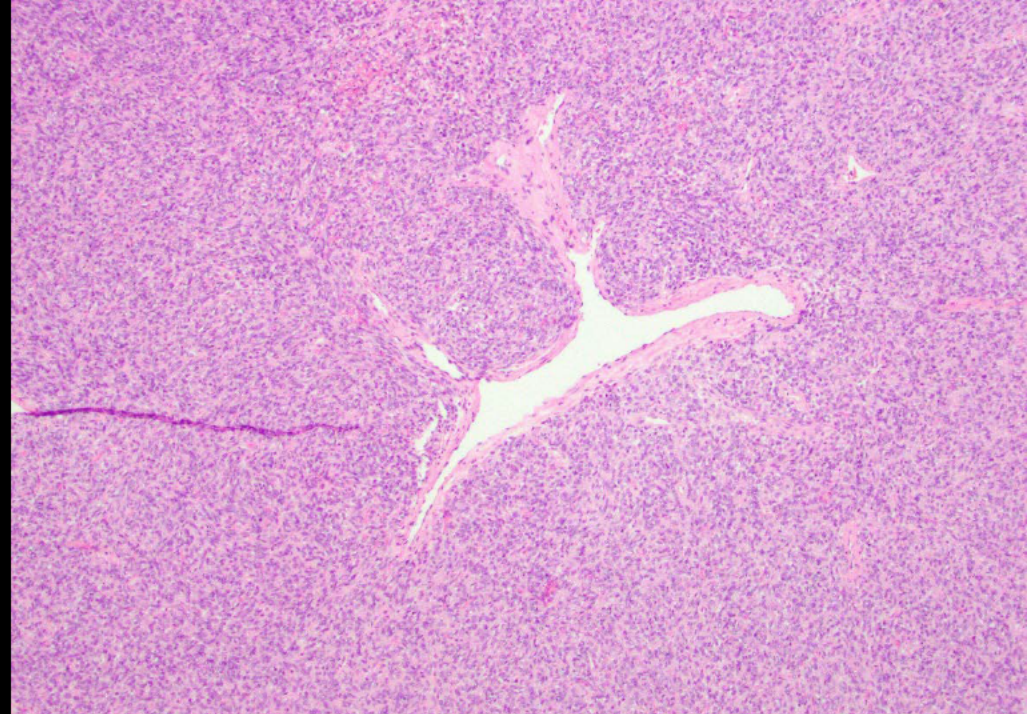
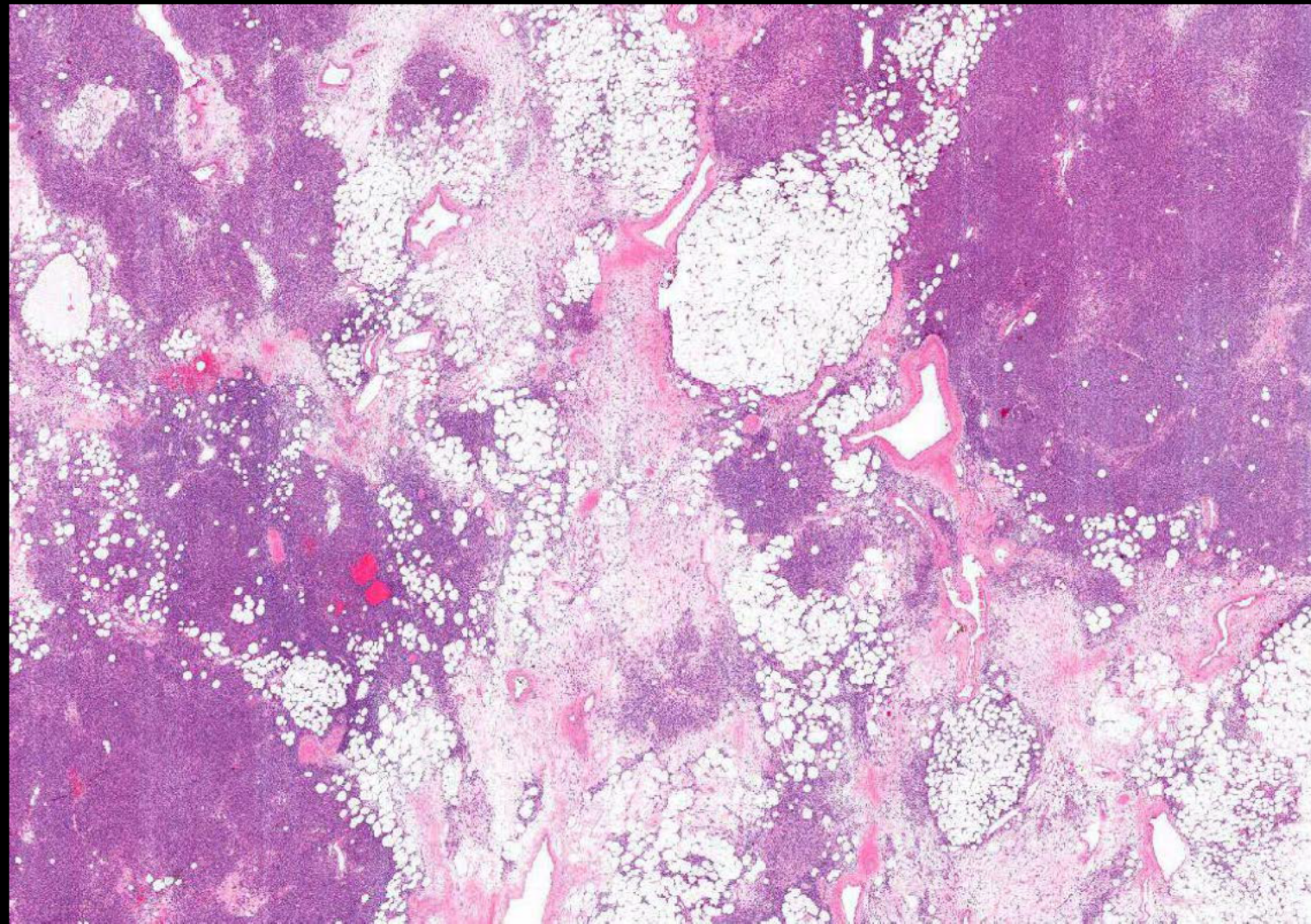


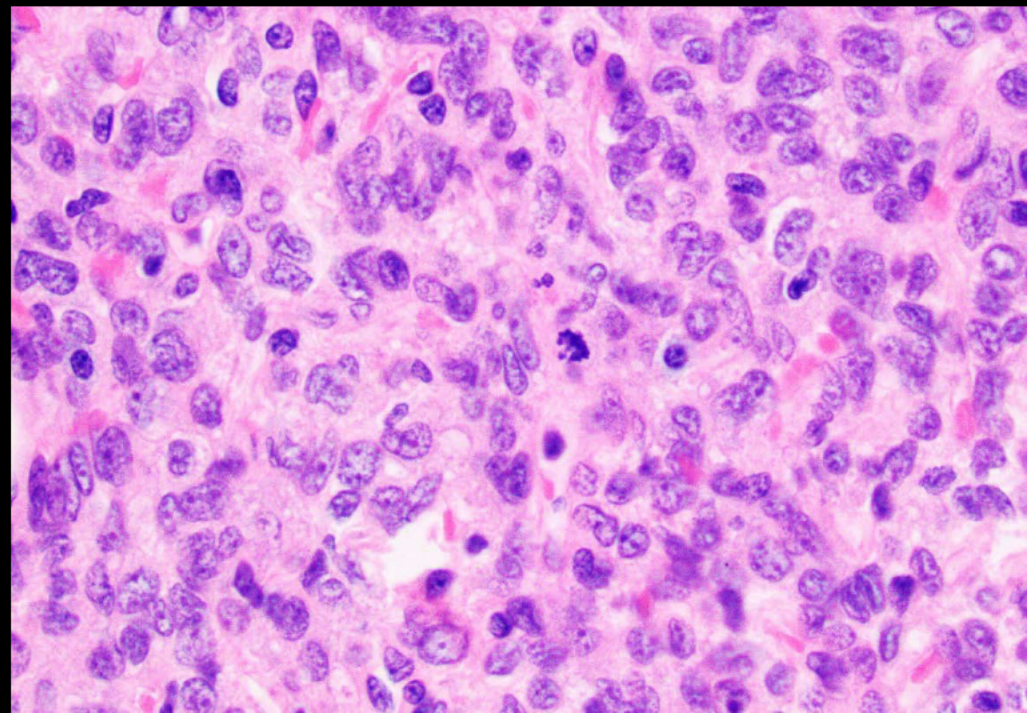
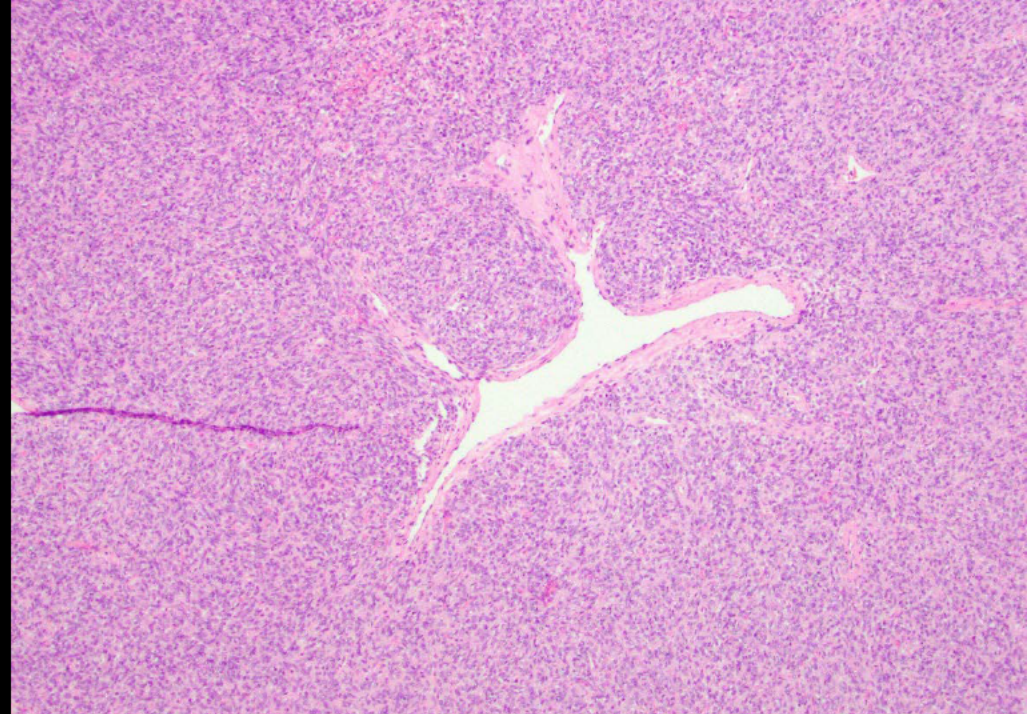
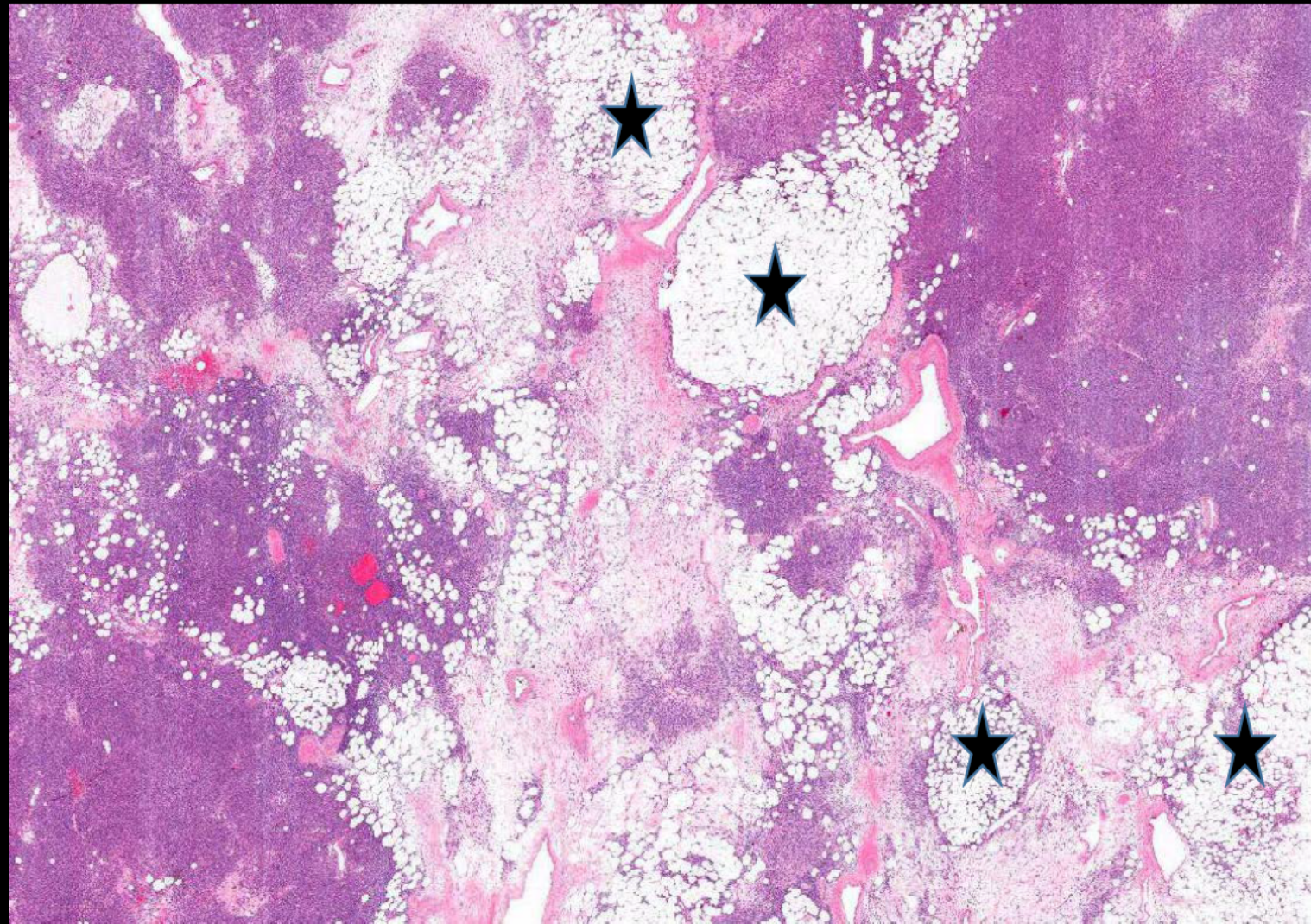


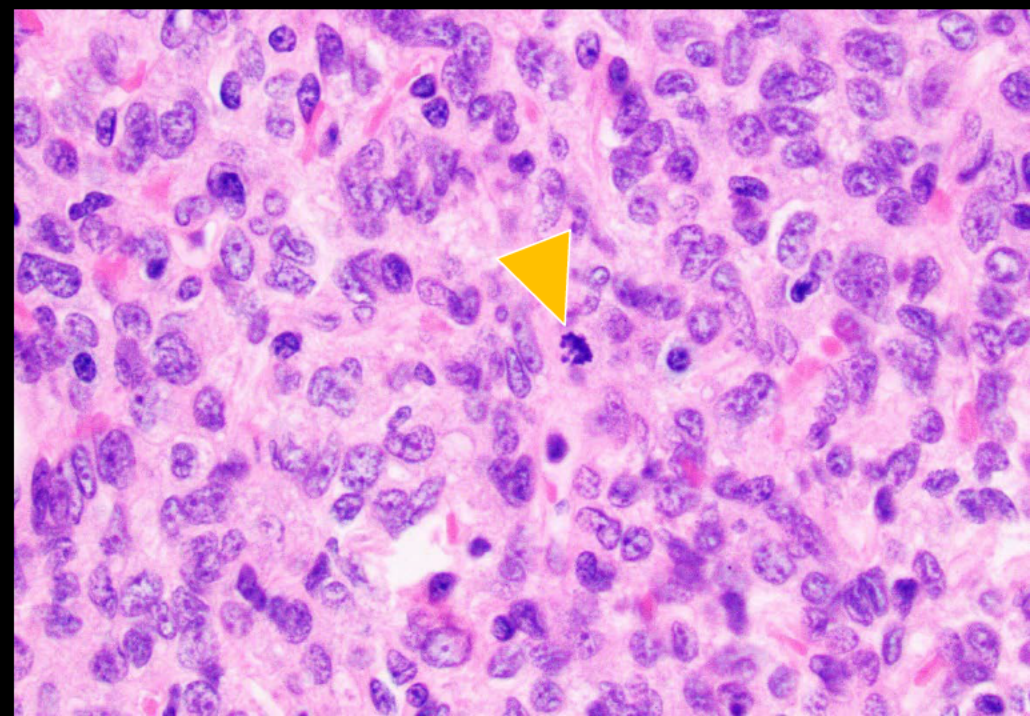
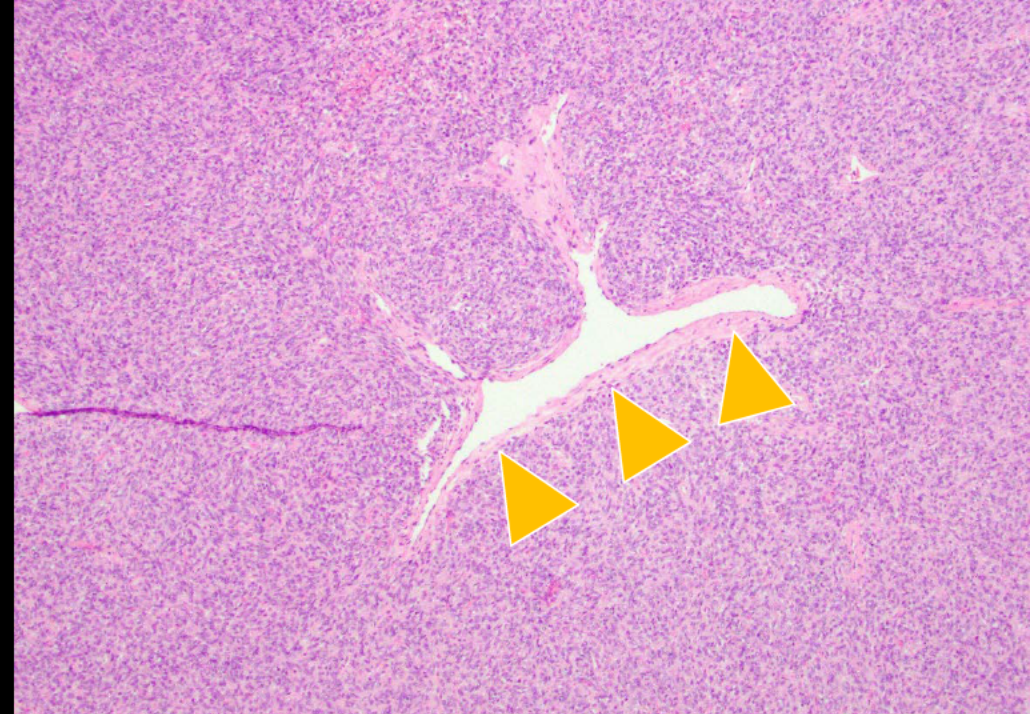
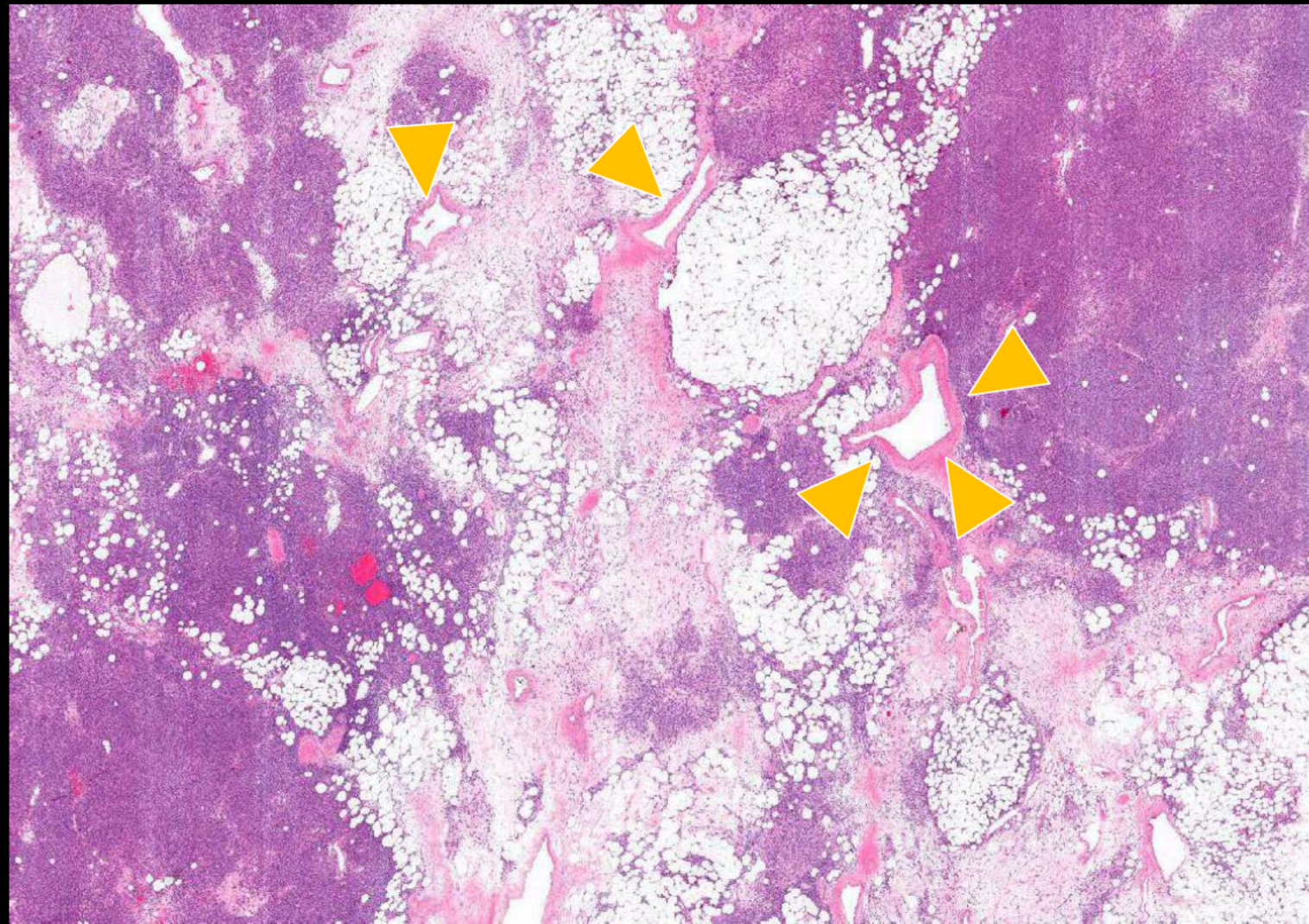












Extrapleural solitary fibrous tumor, lipomatous variant

Dr. Peter Tang
Mount Sinai Hospital
New York, NY

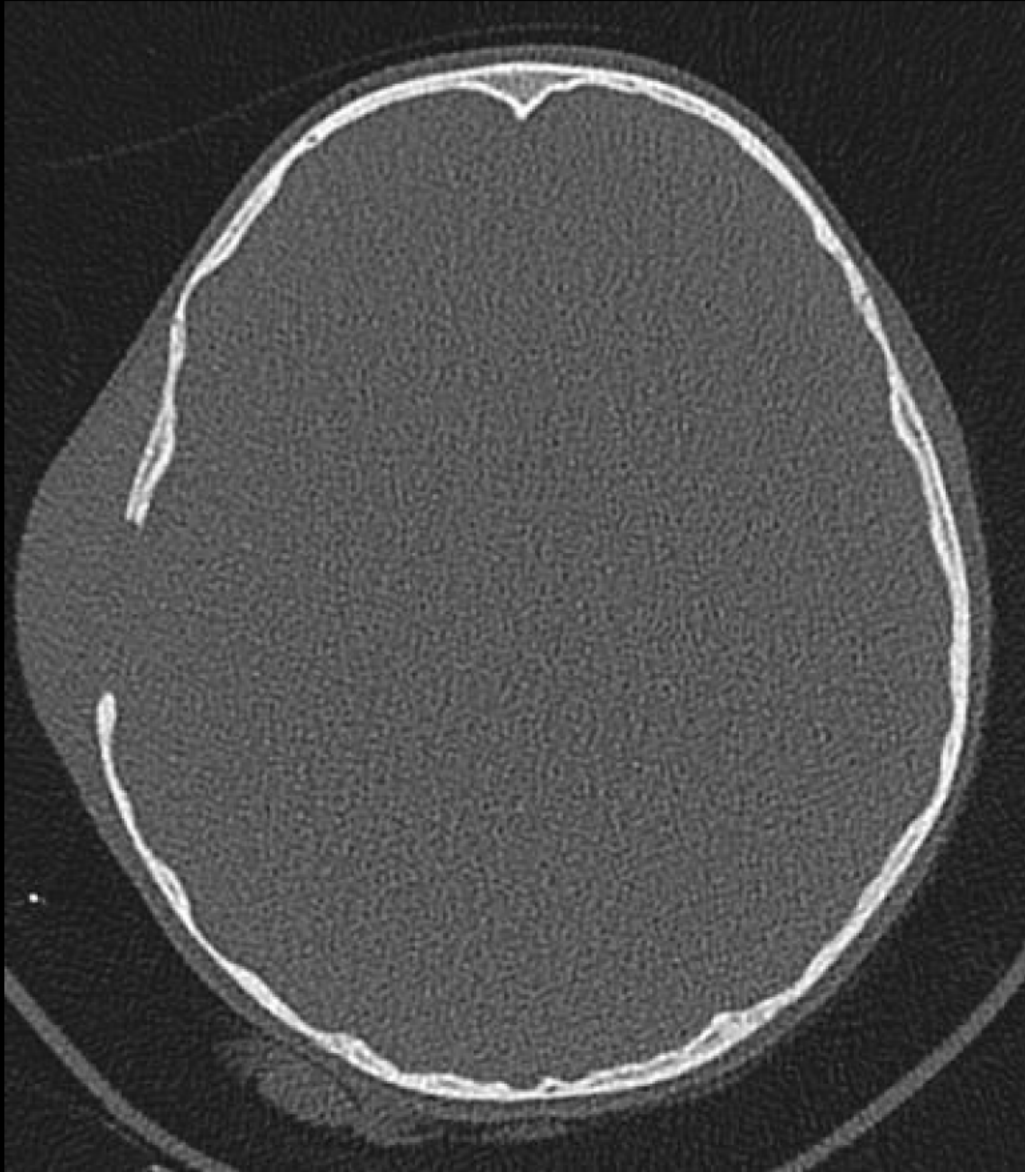
AIRP ACR

HONORABLE MENTION MSK

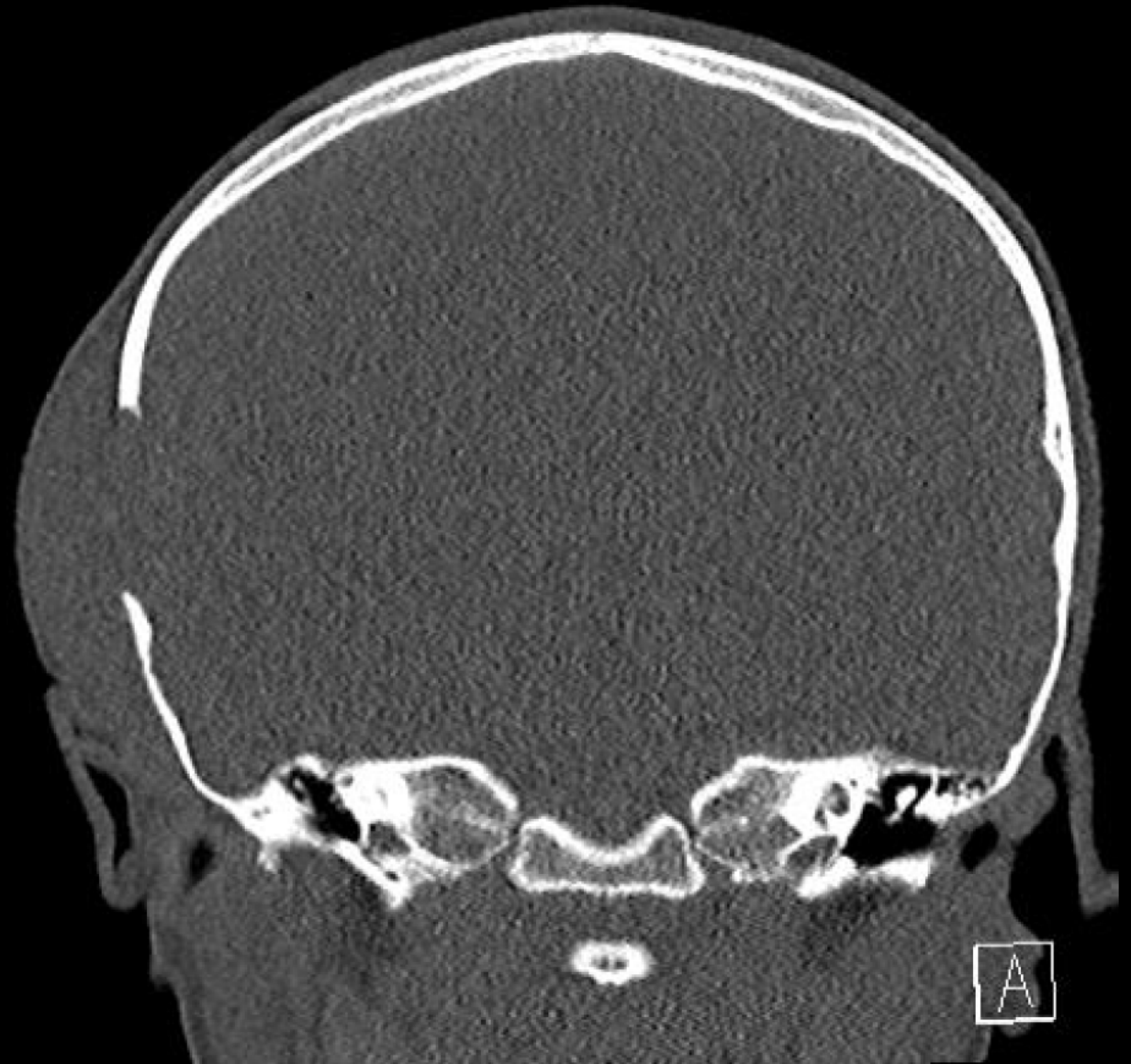
February – March 2019

5 year old female with no PMH
presents with progressively enlarging
painful lump on the right side of her
head. Parents noticed this lump in
the past 3 weeks

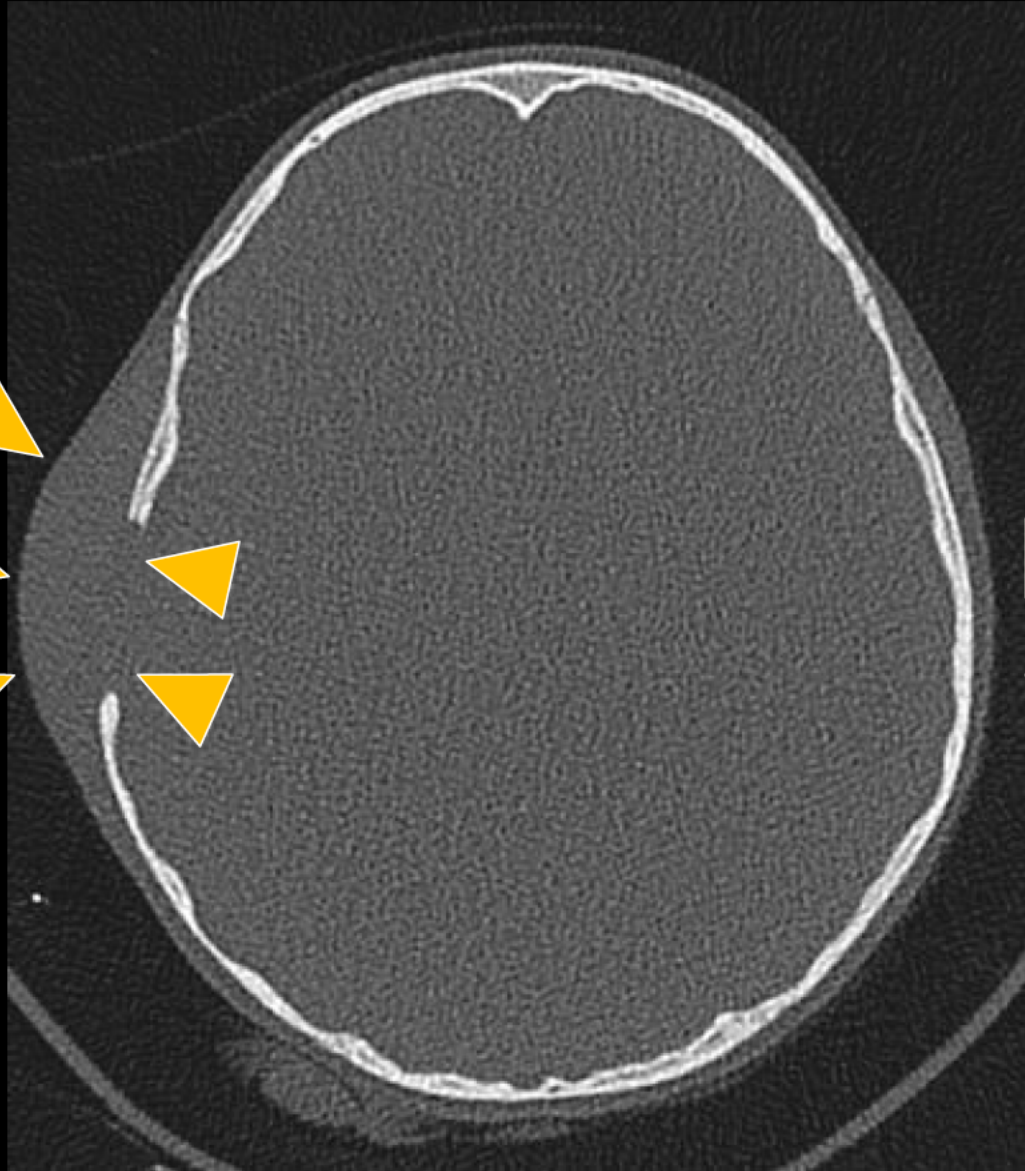
Axial non-contrast CT



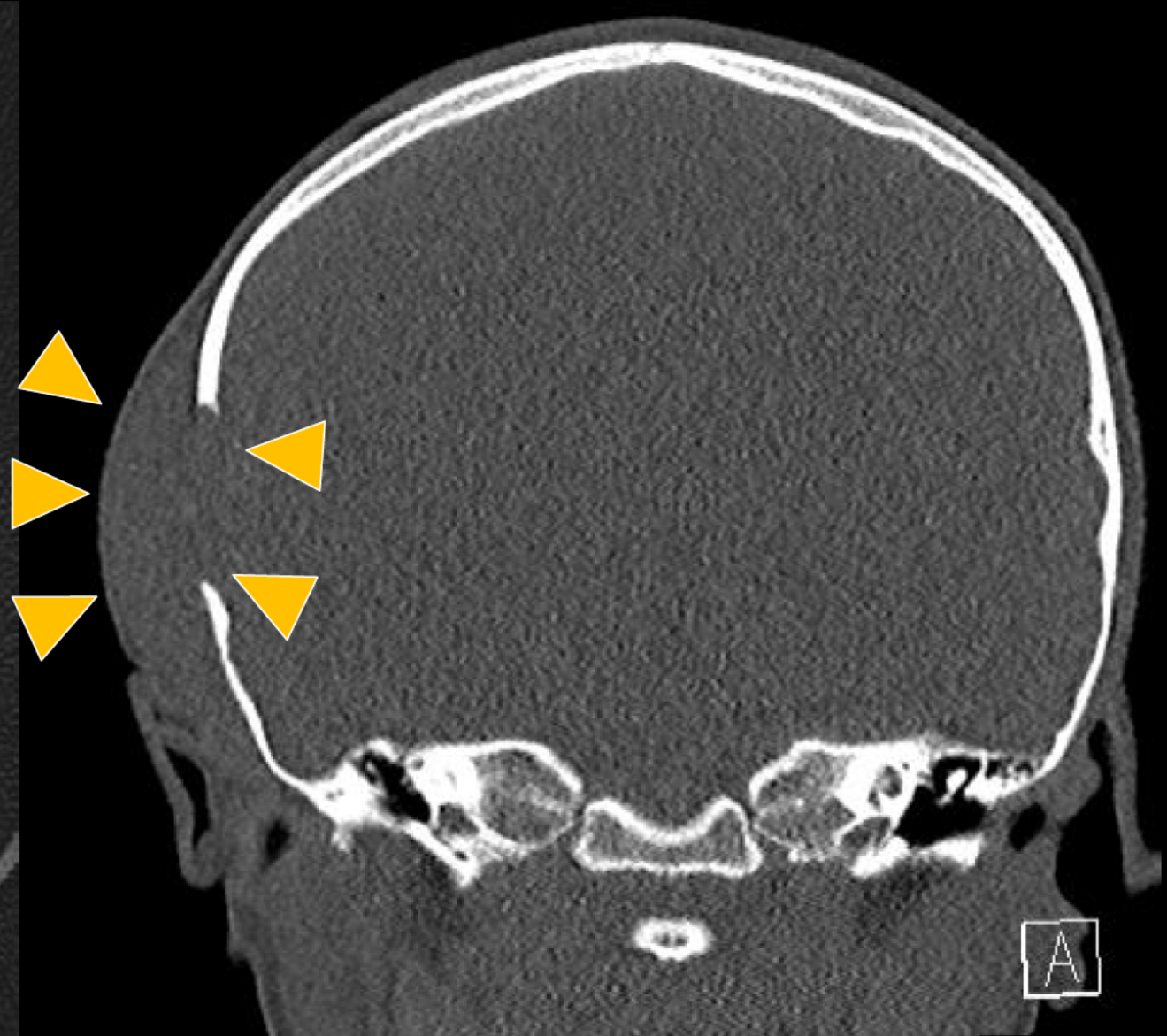
Coronal non-contrast CT



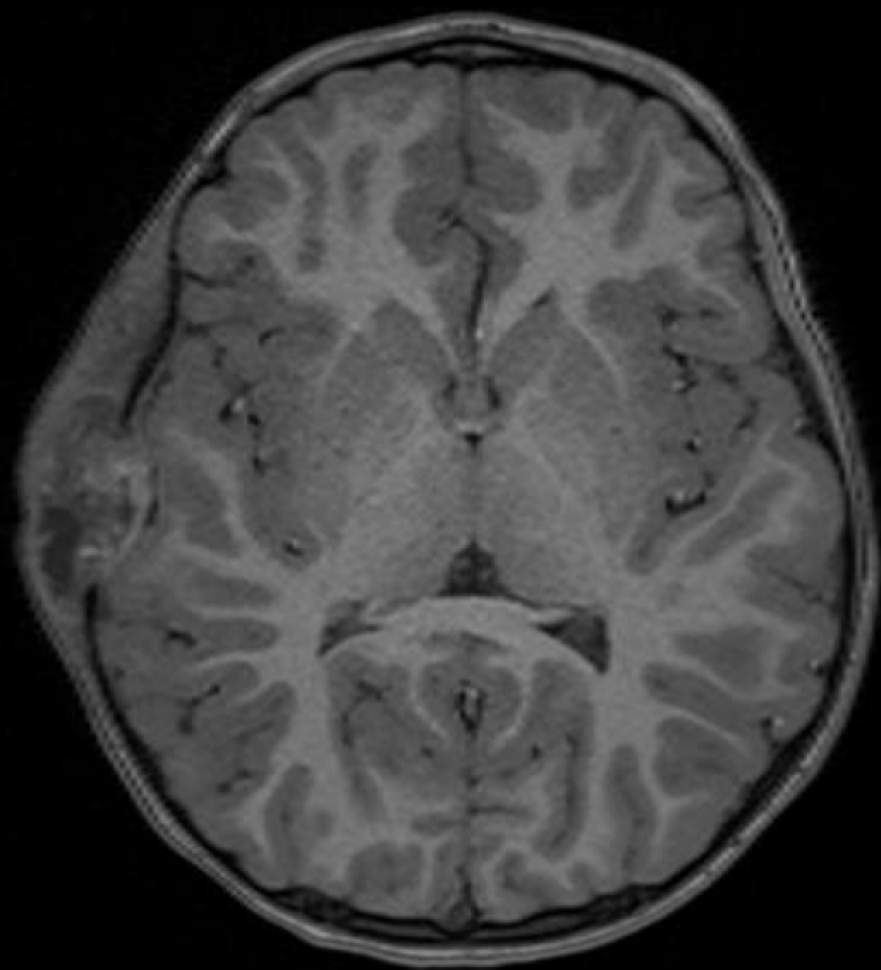
Axial non-contrast CT



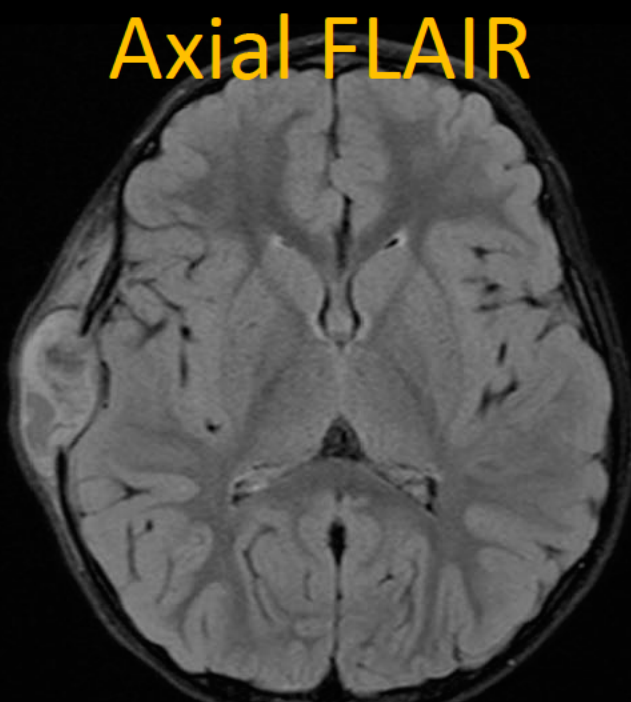
Coronal non-contrast CT



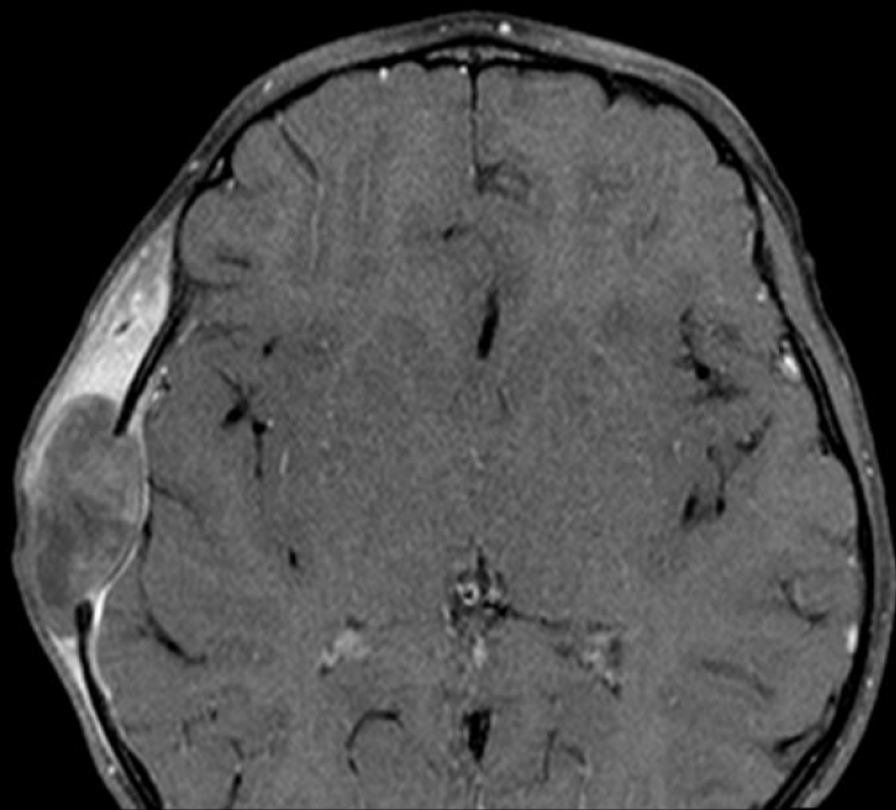
Axial T1 non FS



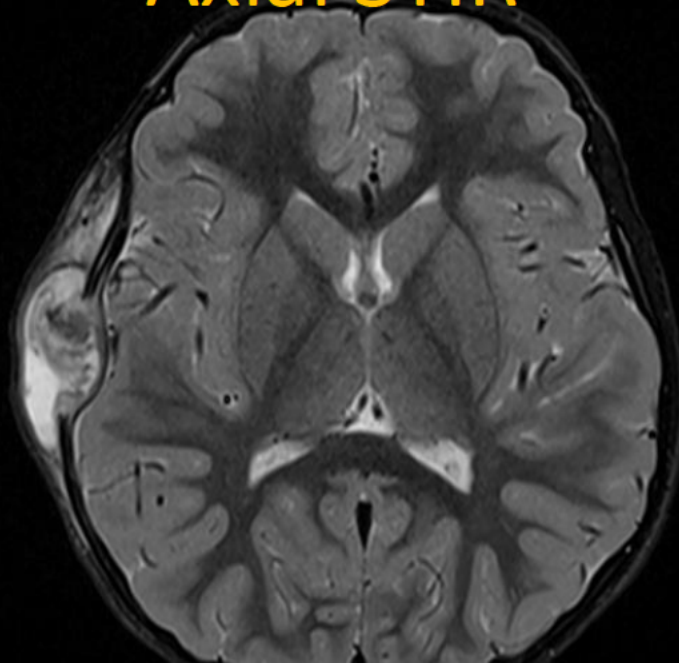
Axial FLAIR



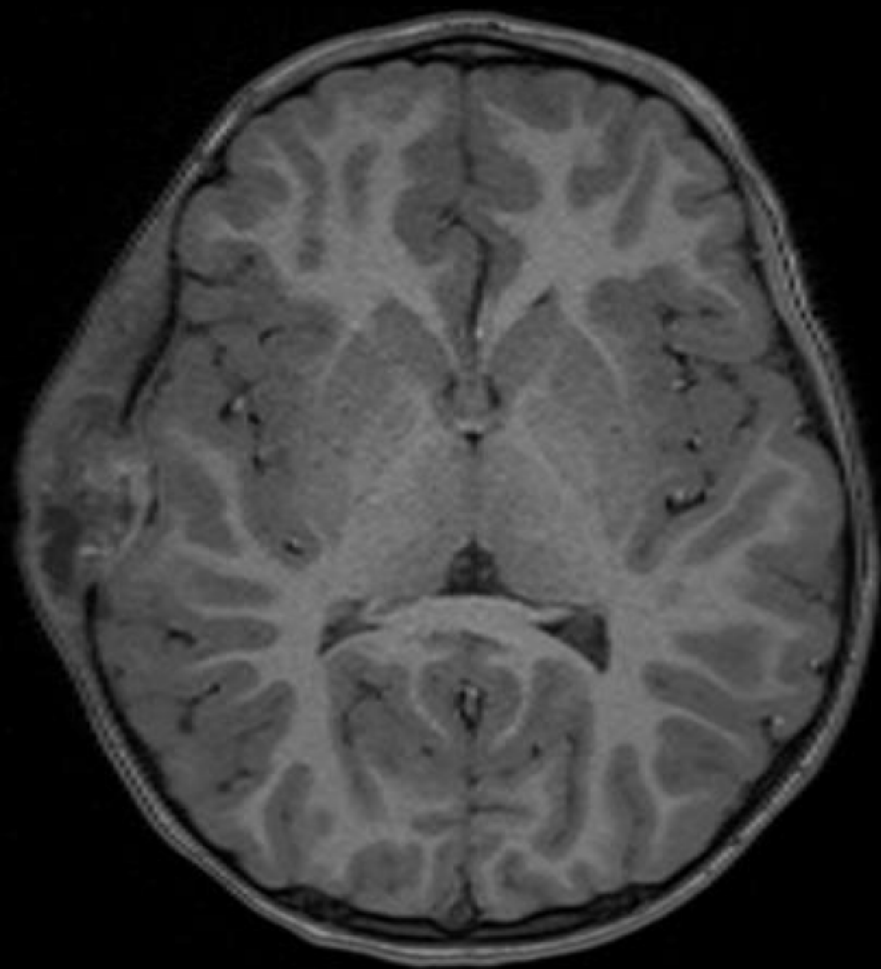
Axial T1 +C



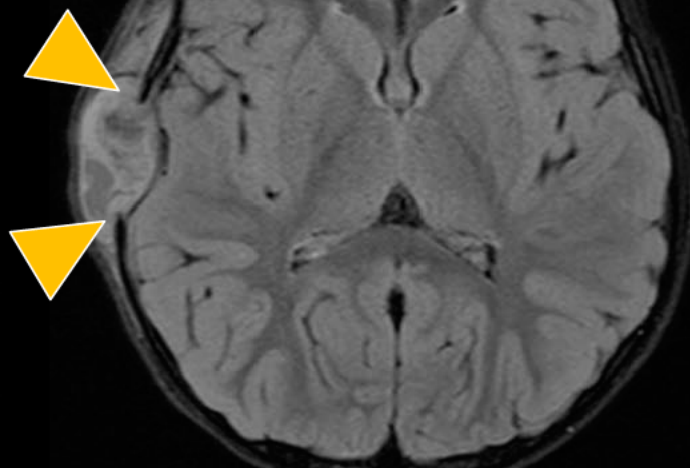
Axial STIR



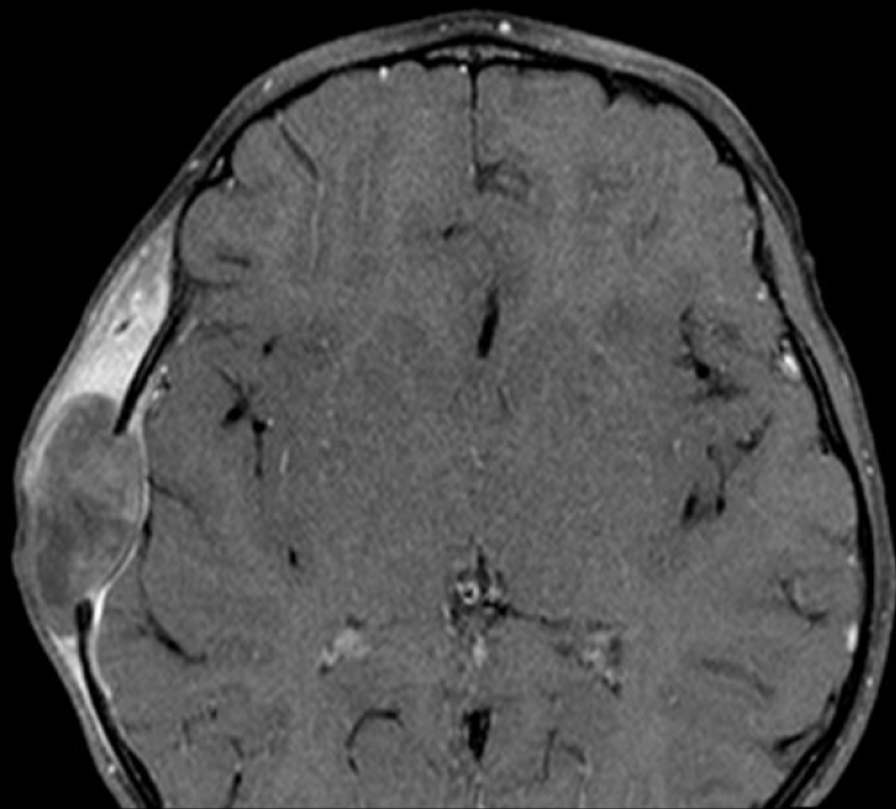
Axial T1 non FS



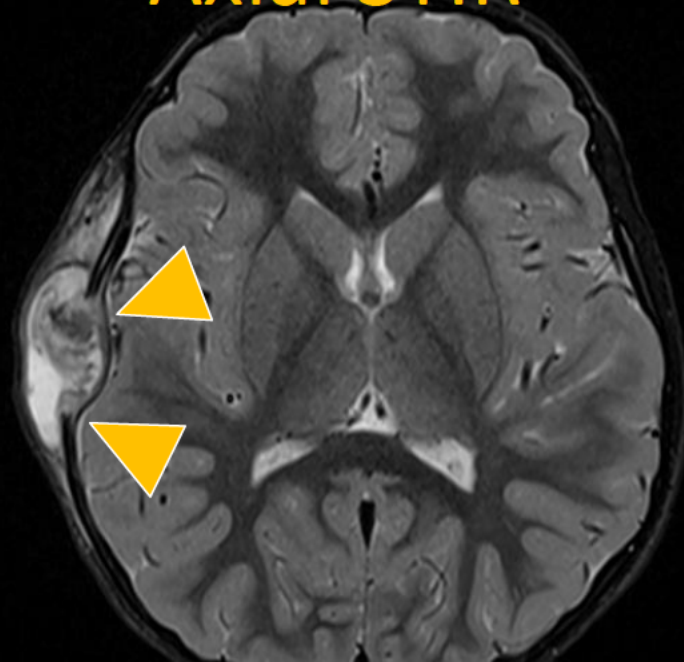
Axial FLAIR

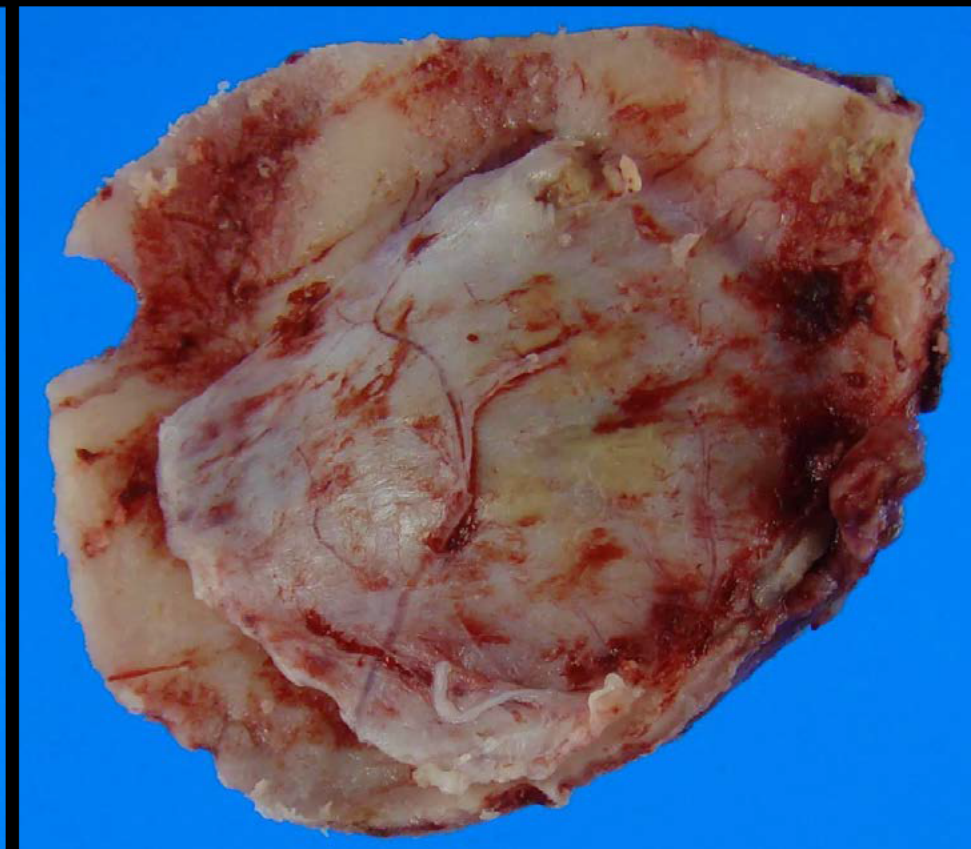
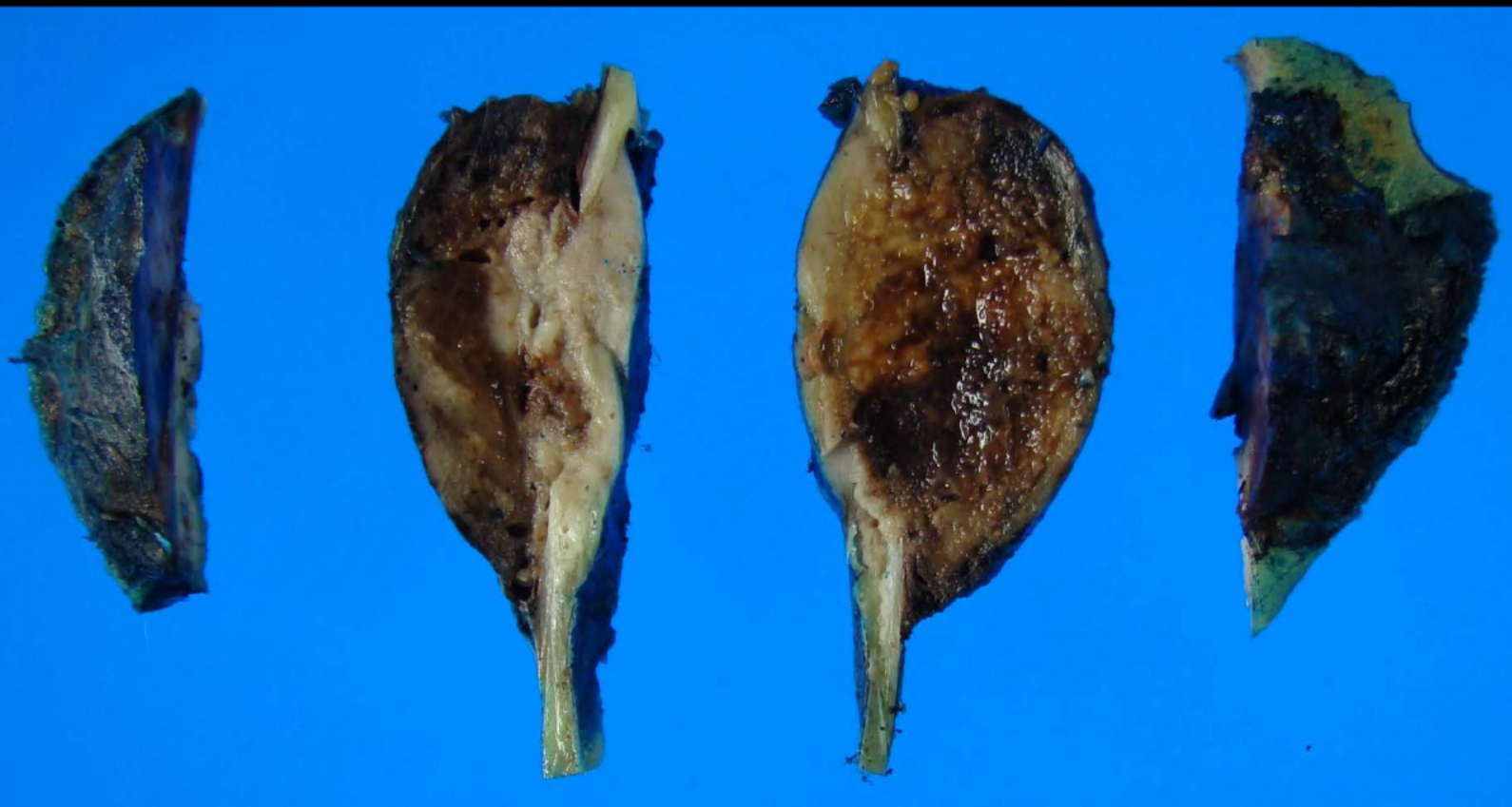
Axial T1 +C

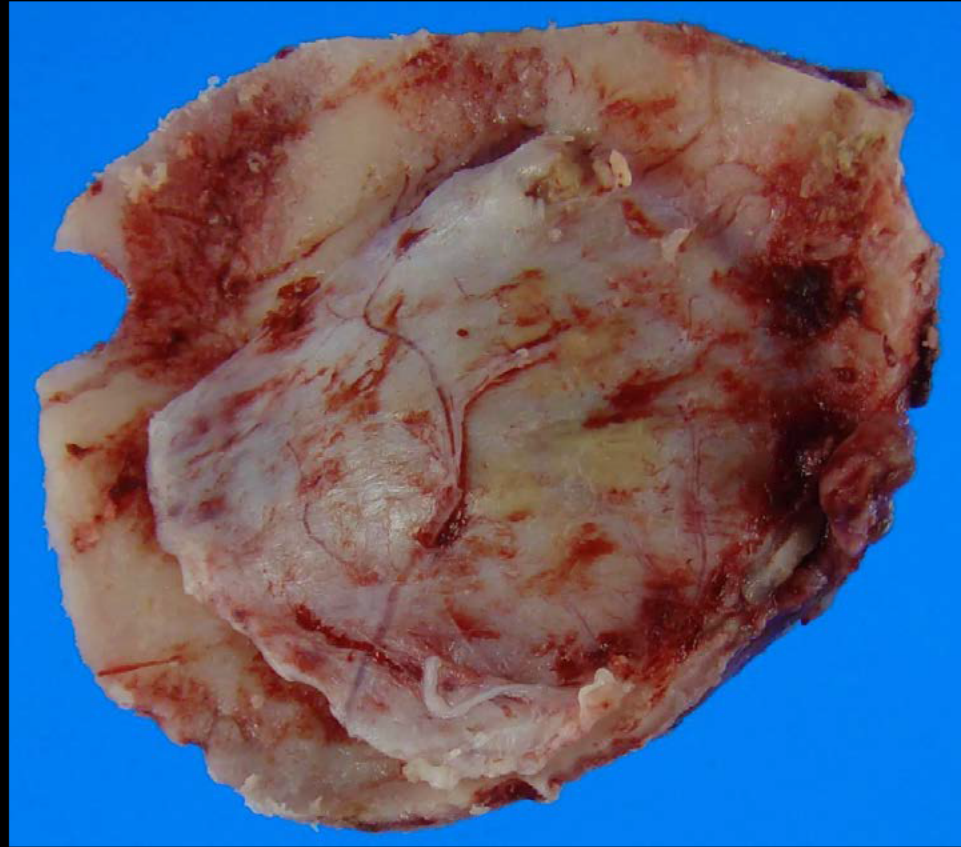
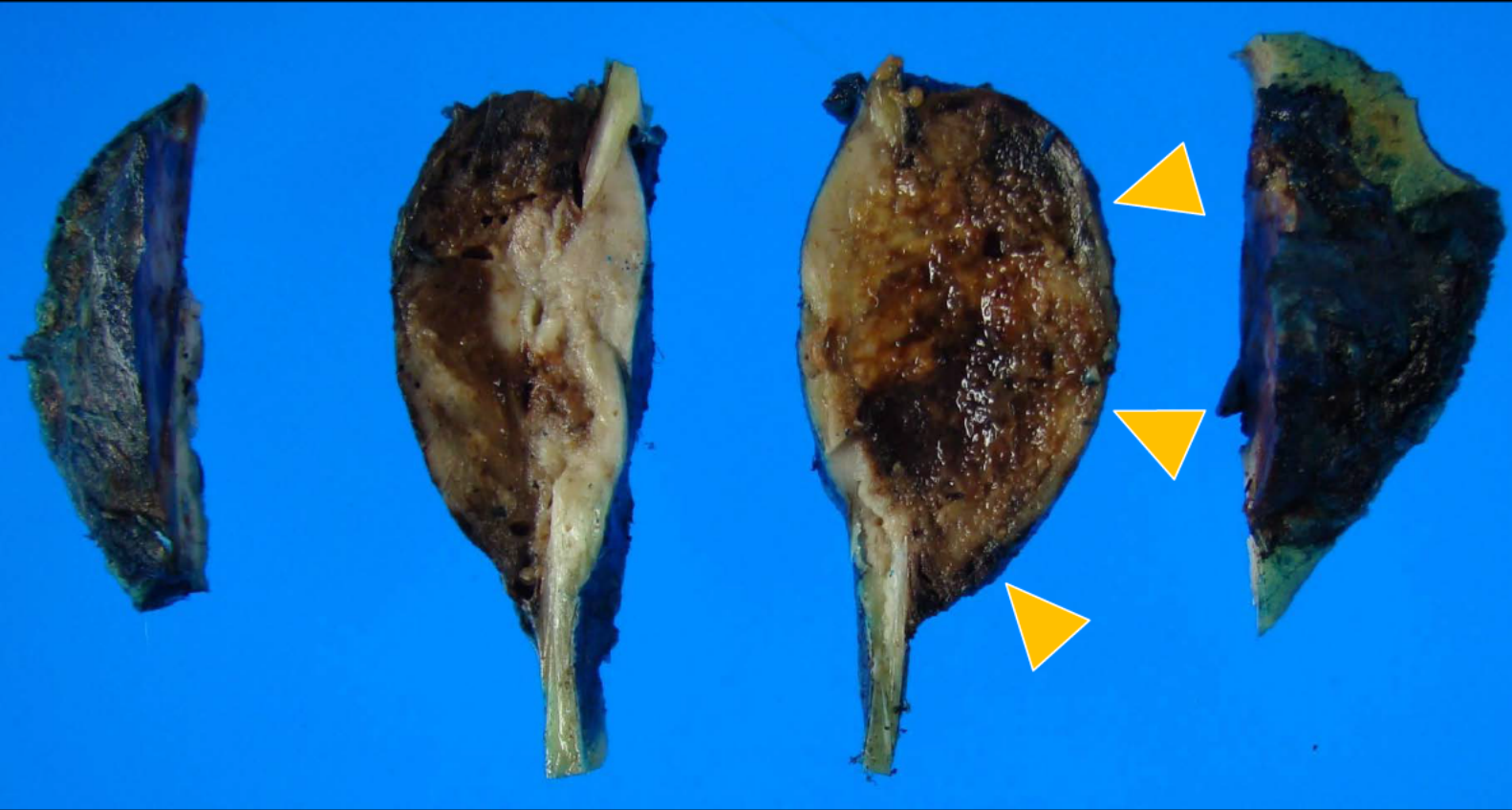
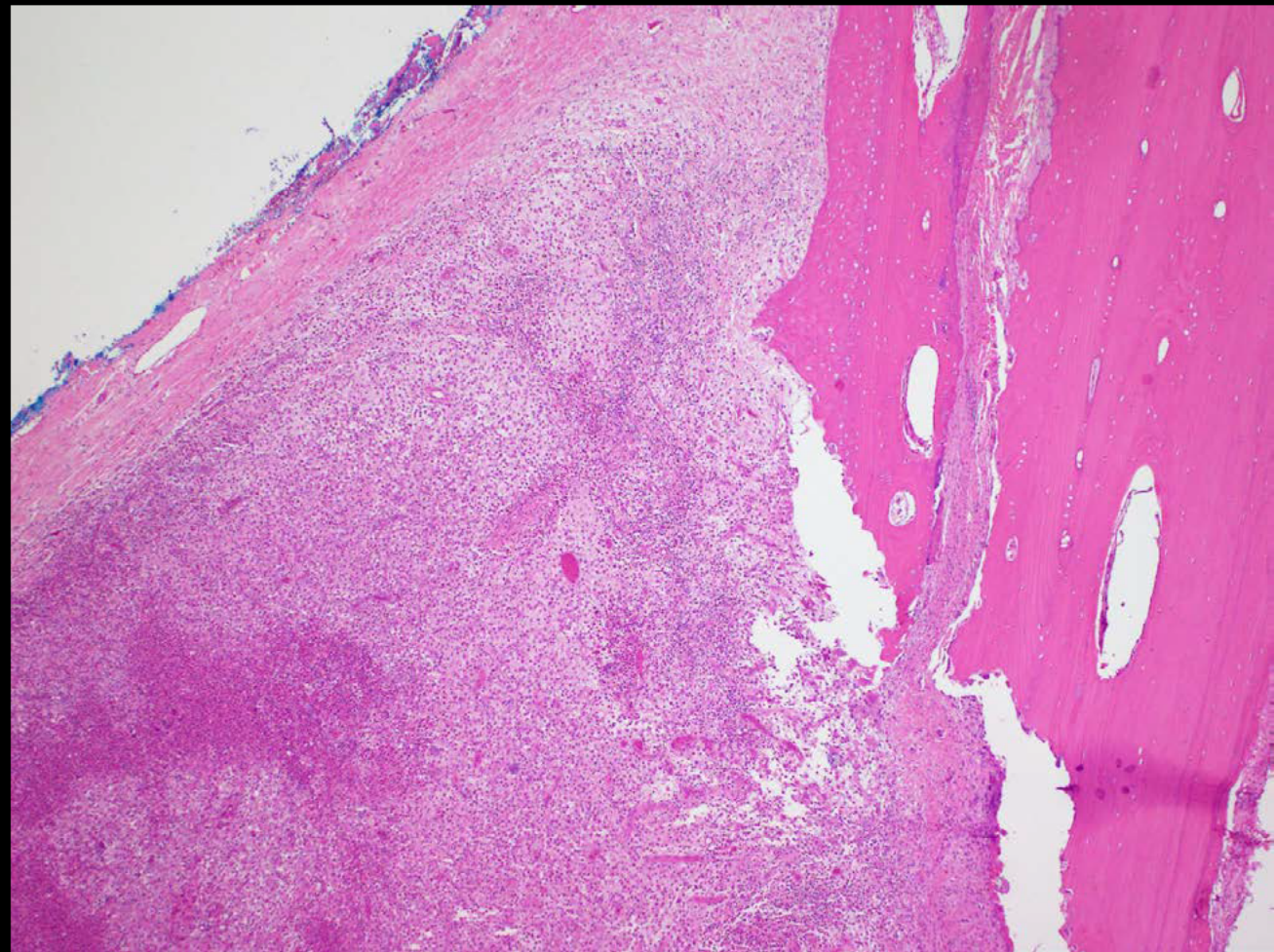
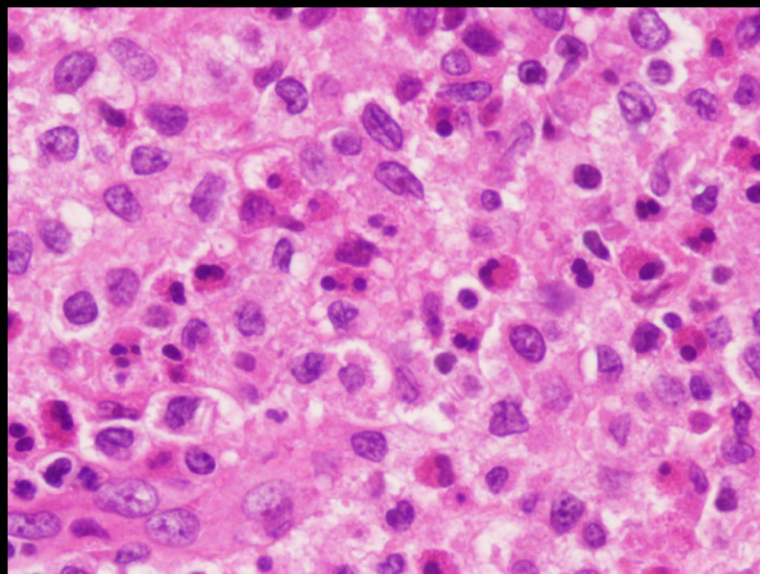
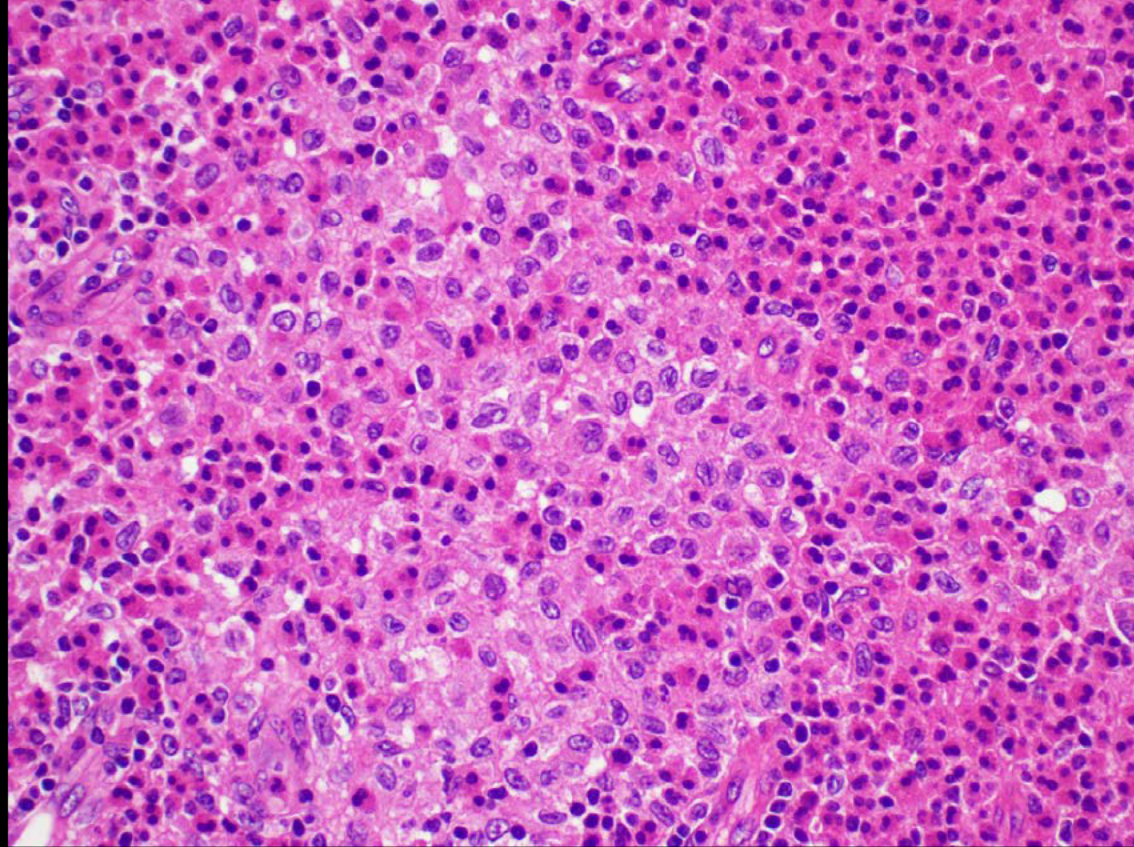
Axial STIR

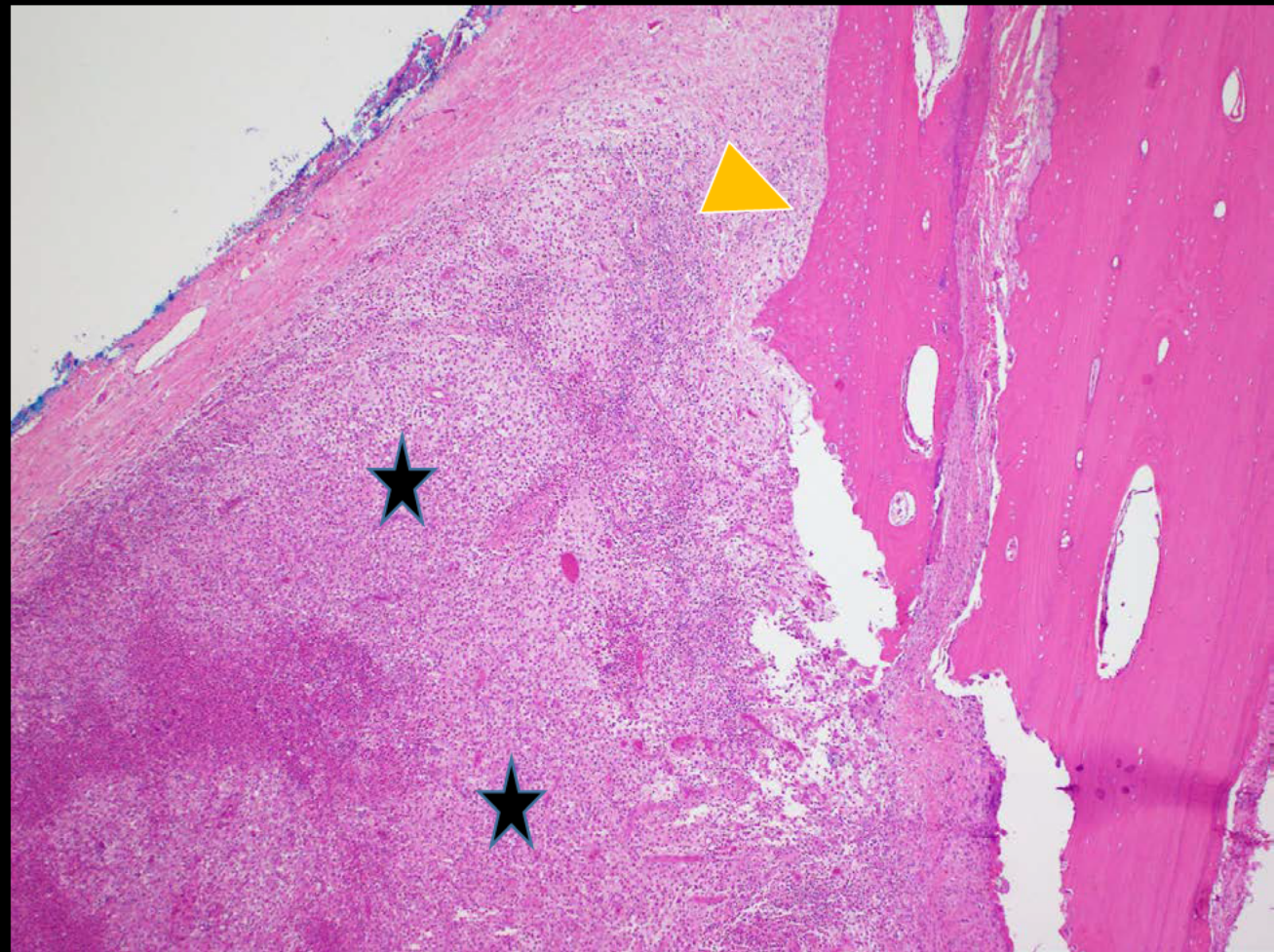
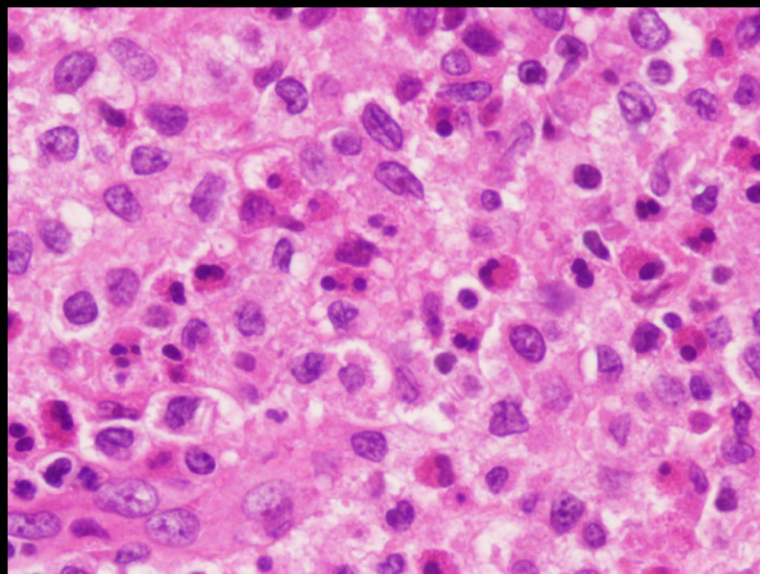
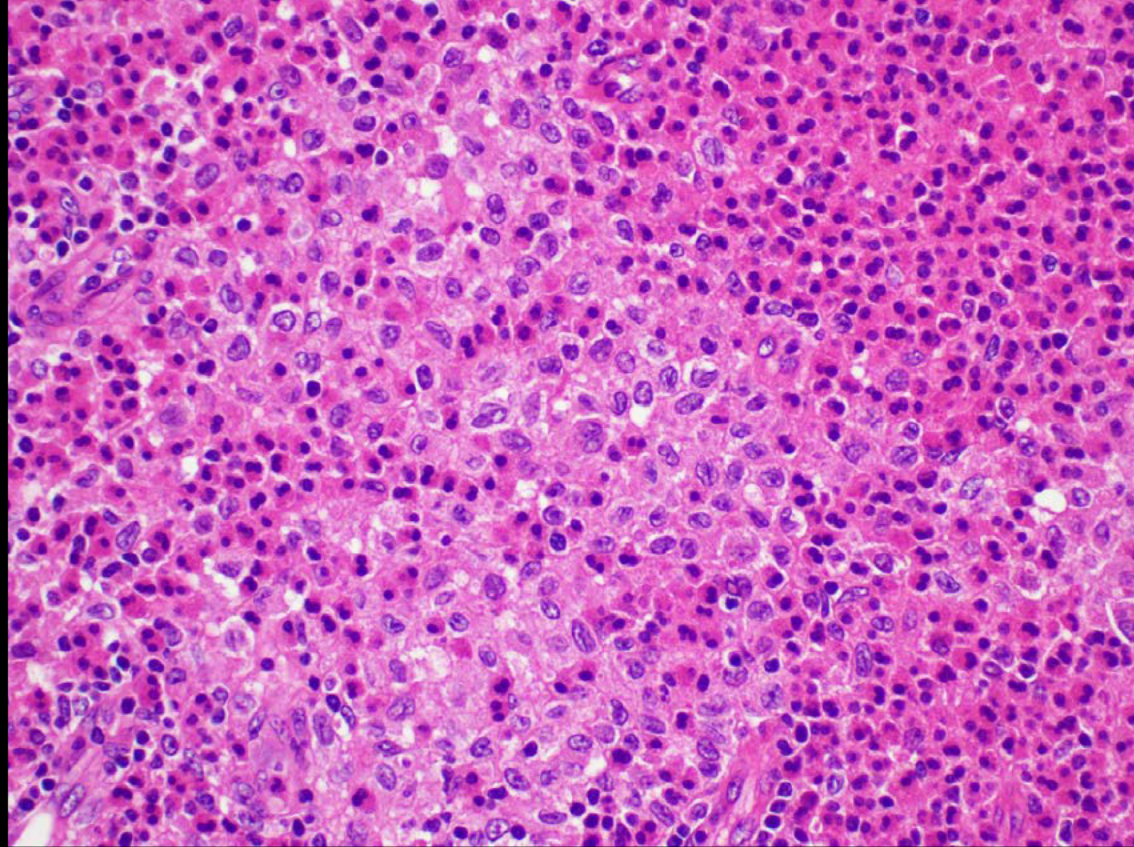


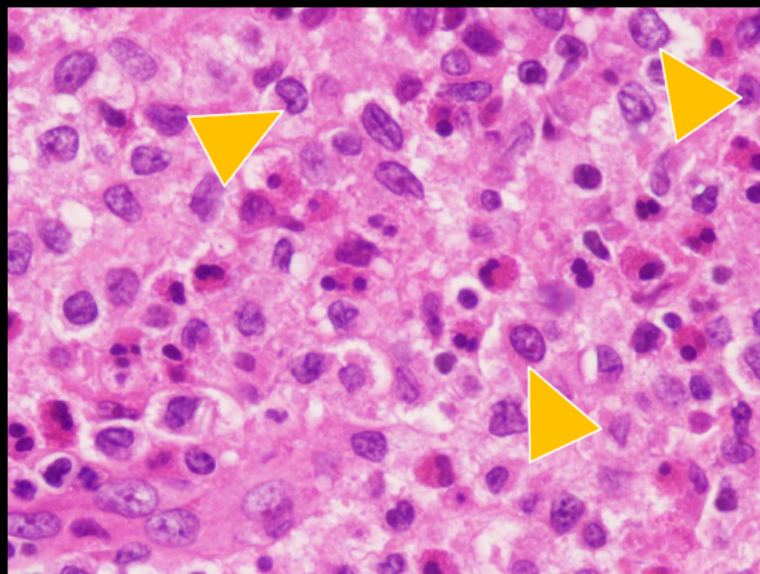
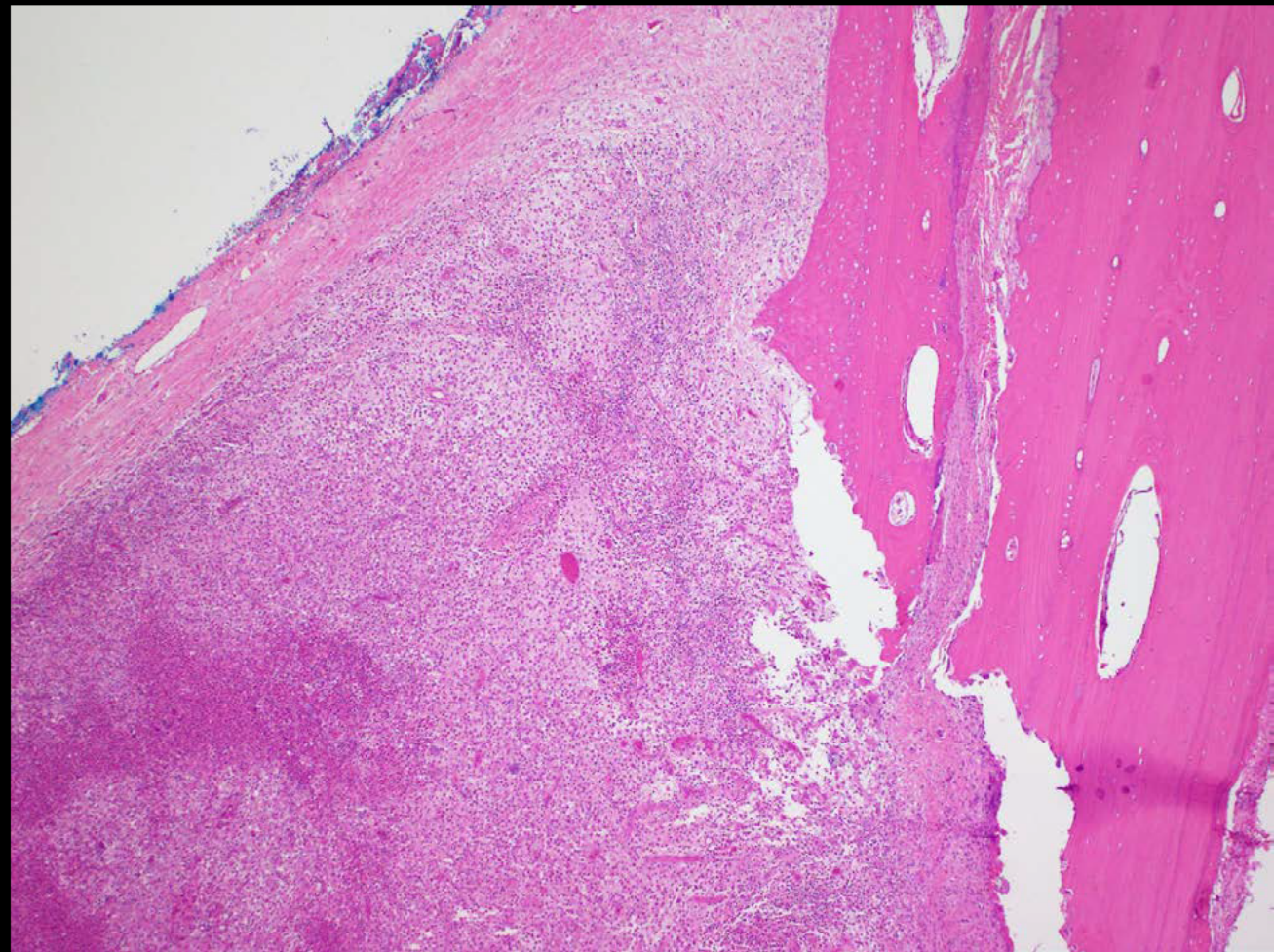
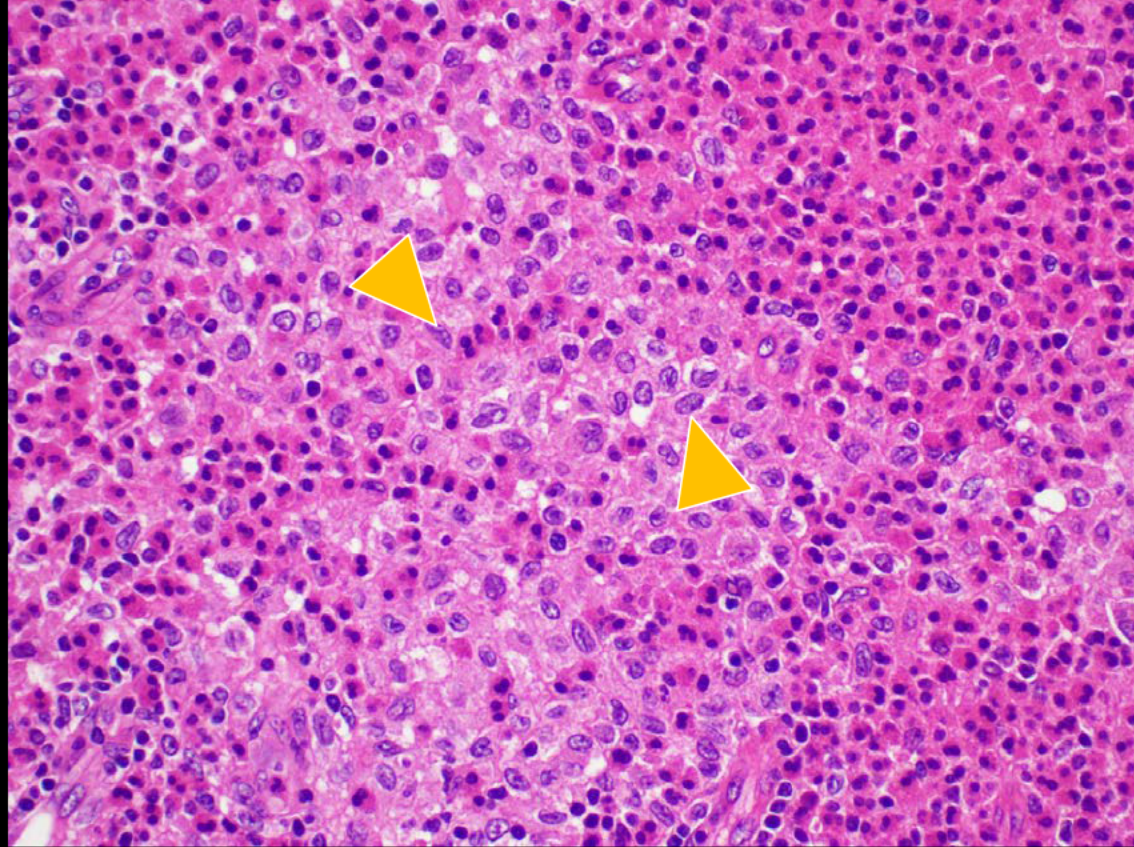


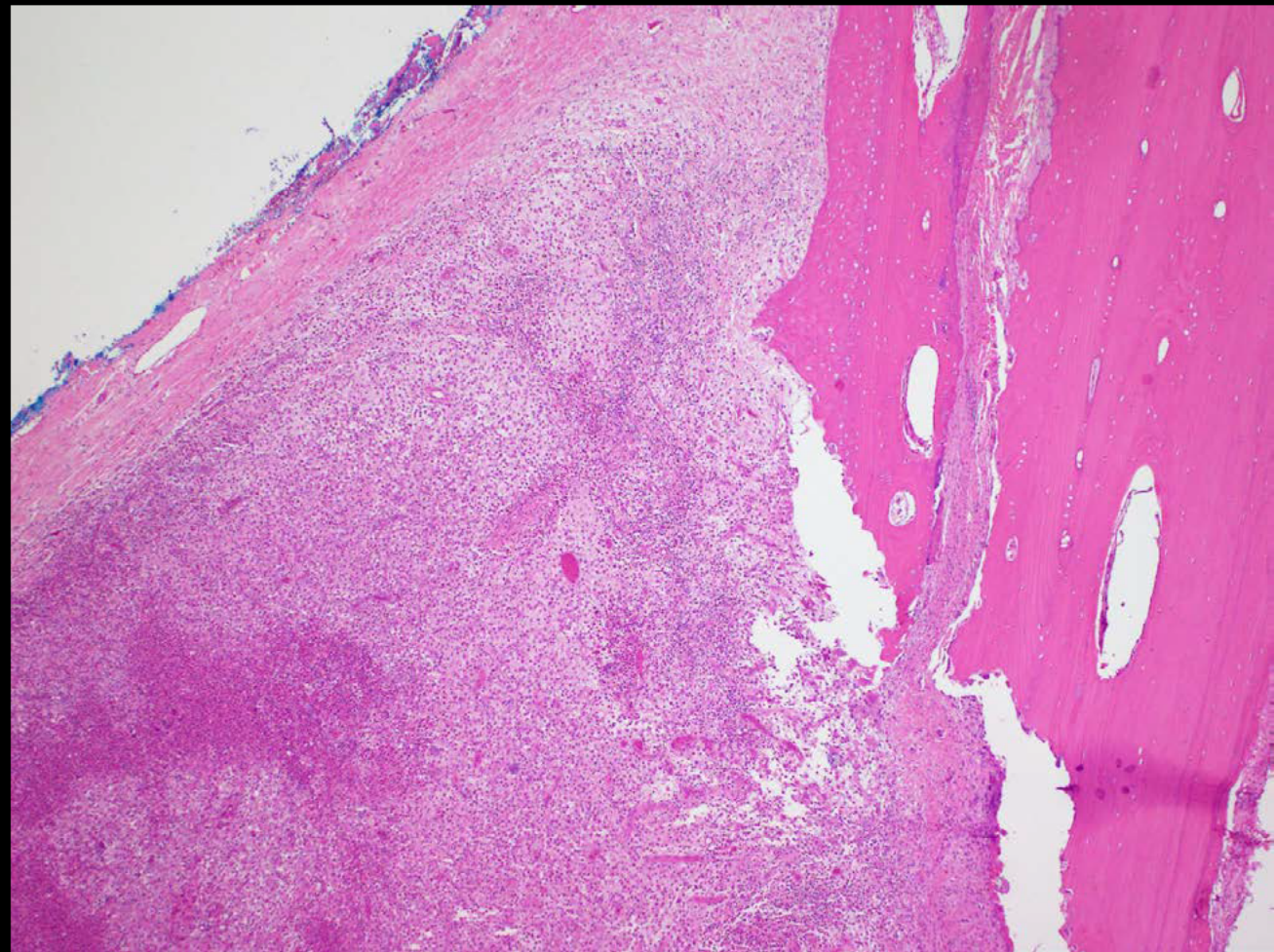
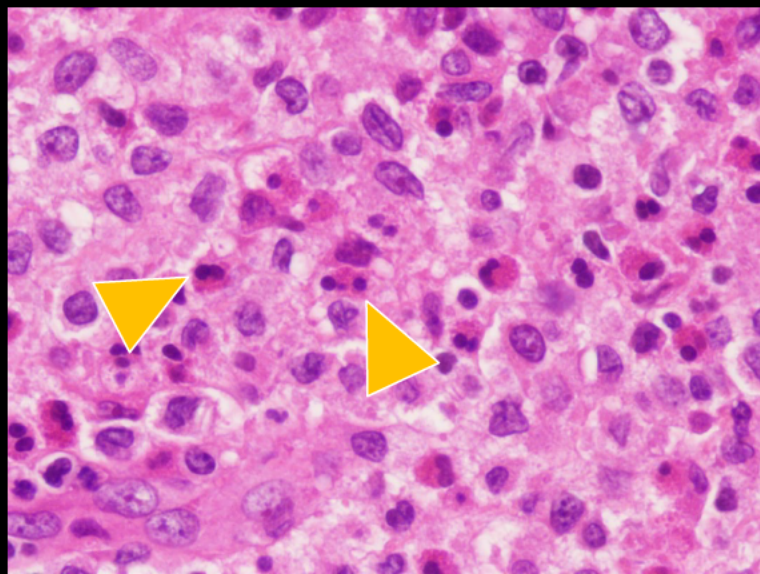
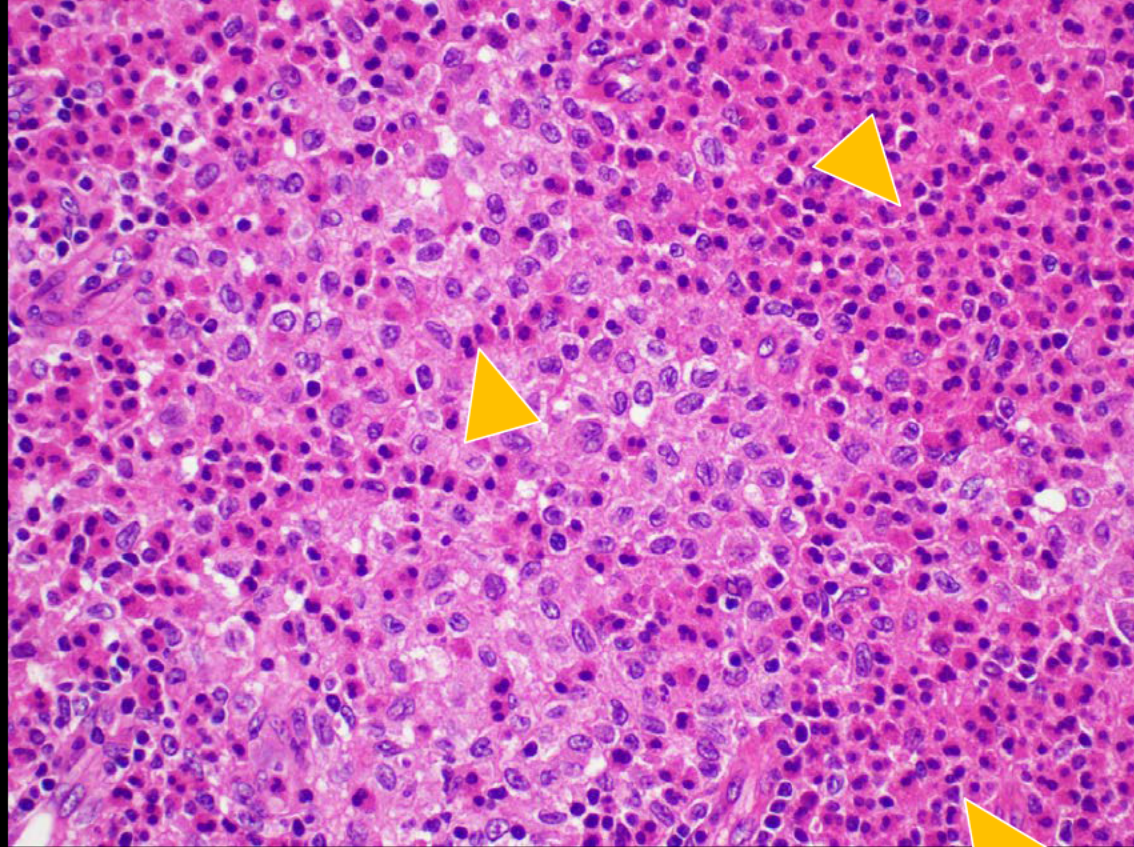
Interior surface









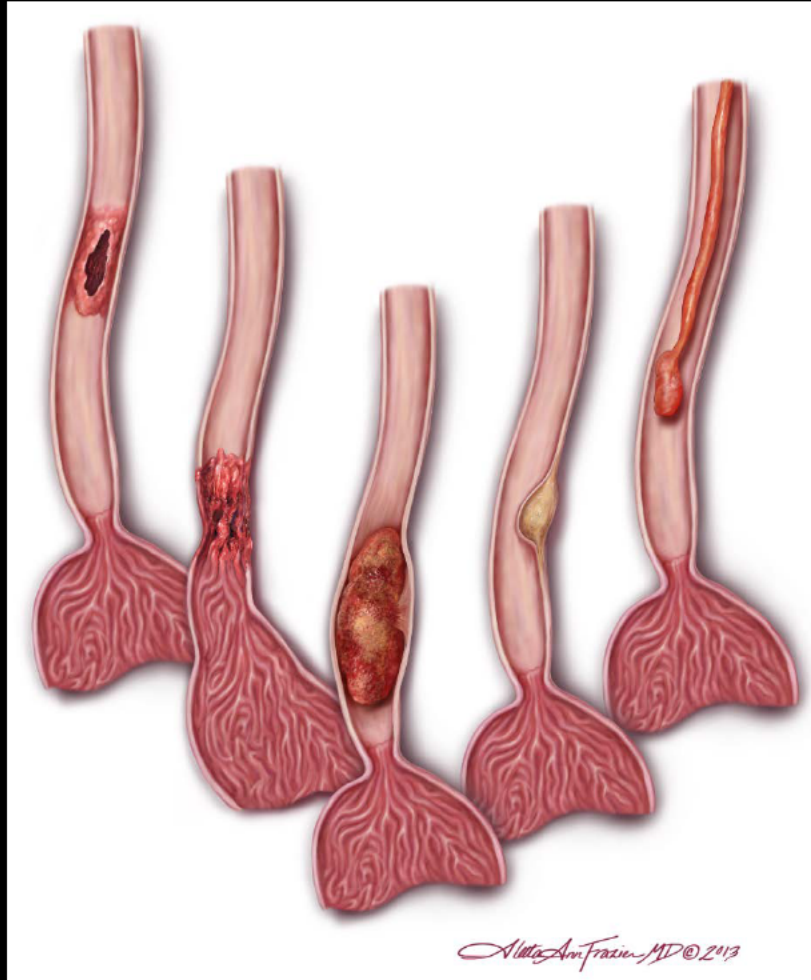


Langerhans Cell Histiocytosis of bone

Dr. Timothy Phelps
Baylor University Medical Center
Dallas, TX

AIRP ACR

Gastrointestinal Best Case

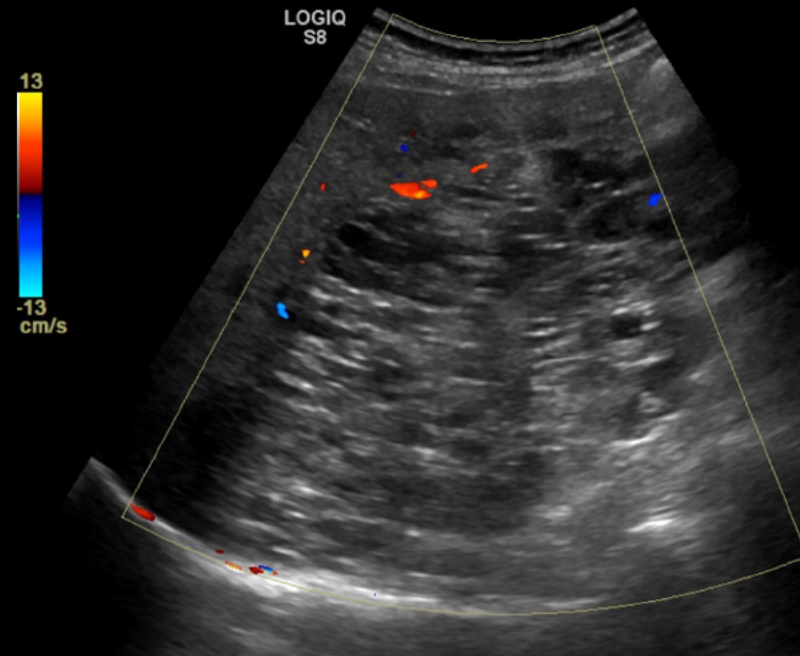
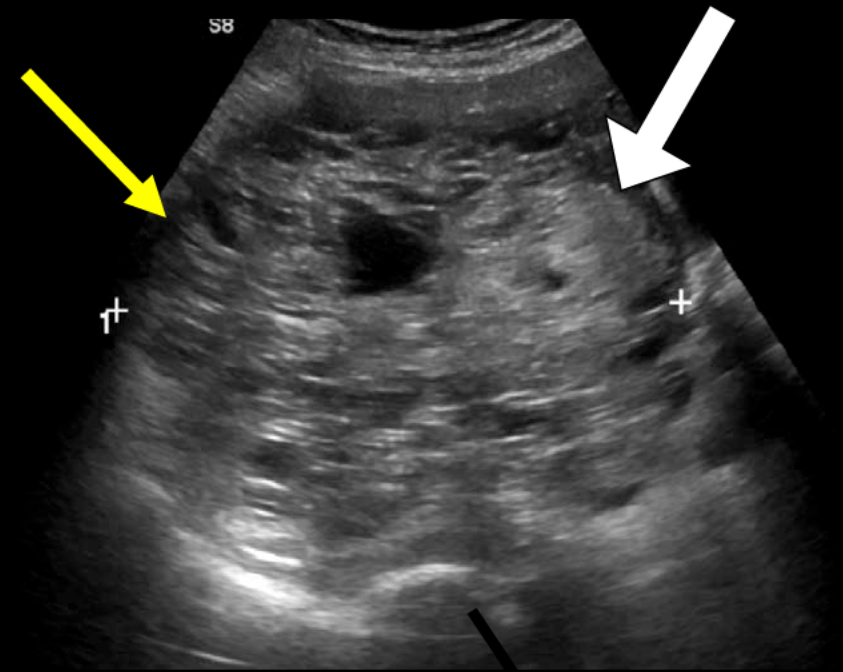
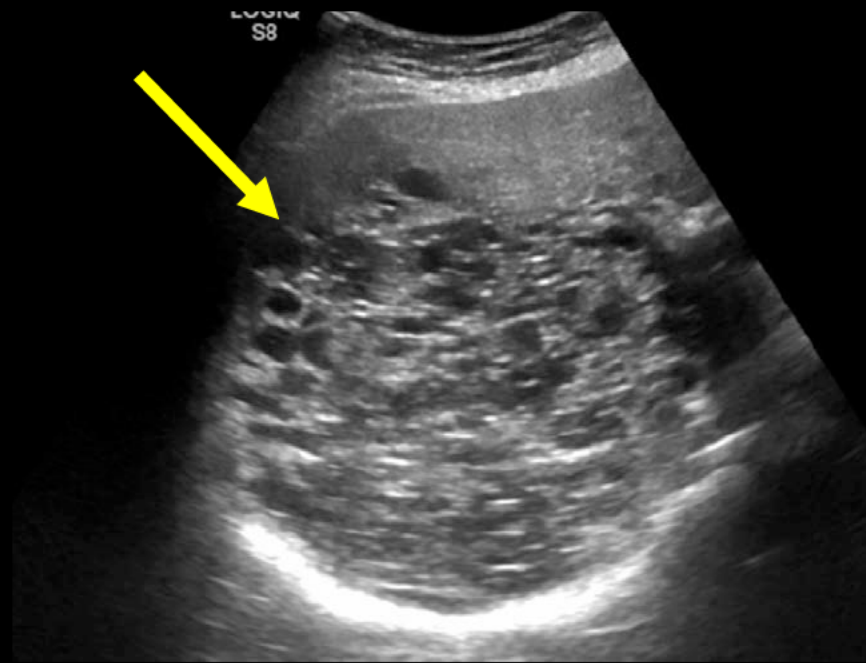


AIRPTM
AMERICAN INSTITUTE FOR
RADIOLOGIC PATHOLOGY

A PROGRAM OF THE
AMERICAN COLLEGE OF RADIOLOGY

Clinical information

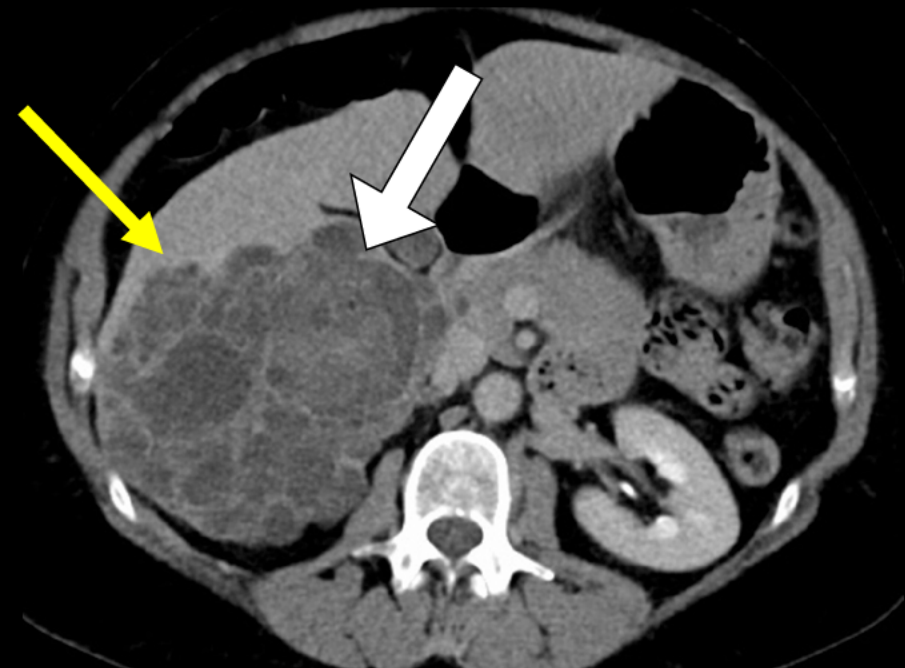
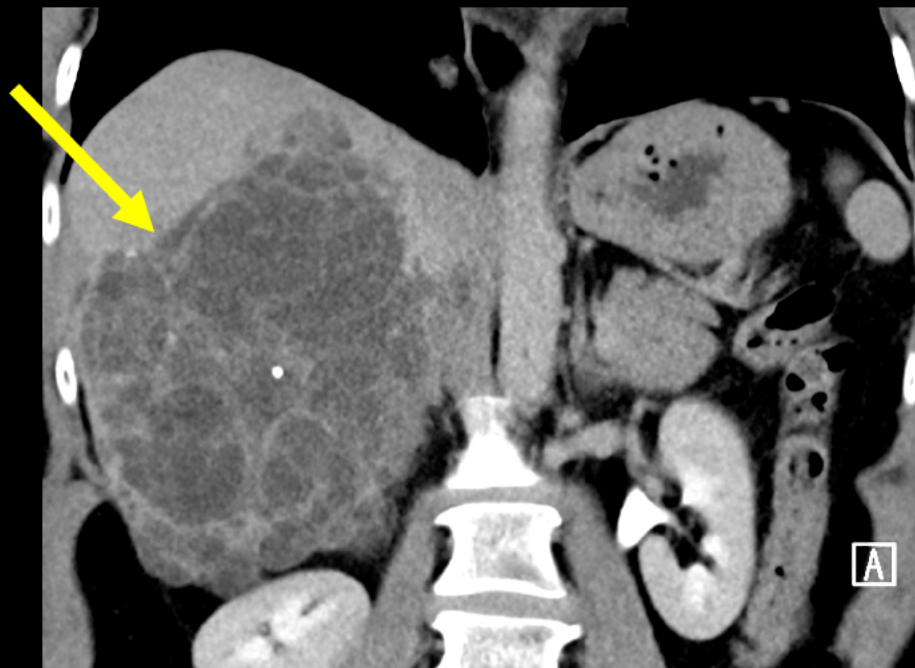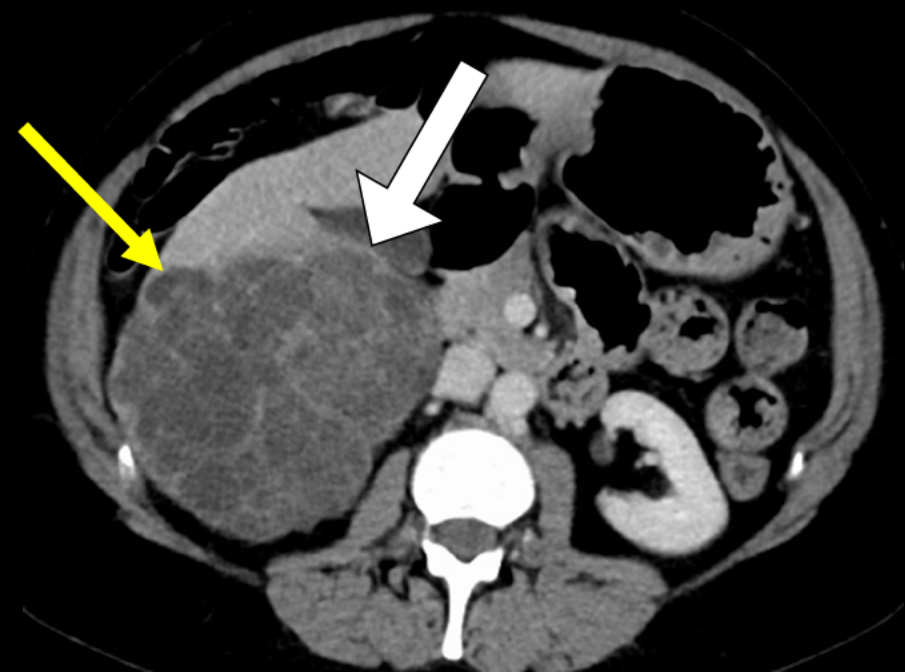
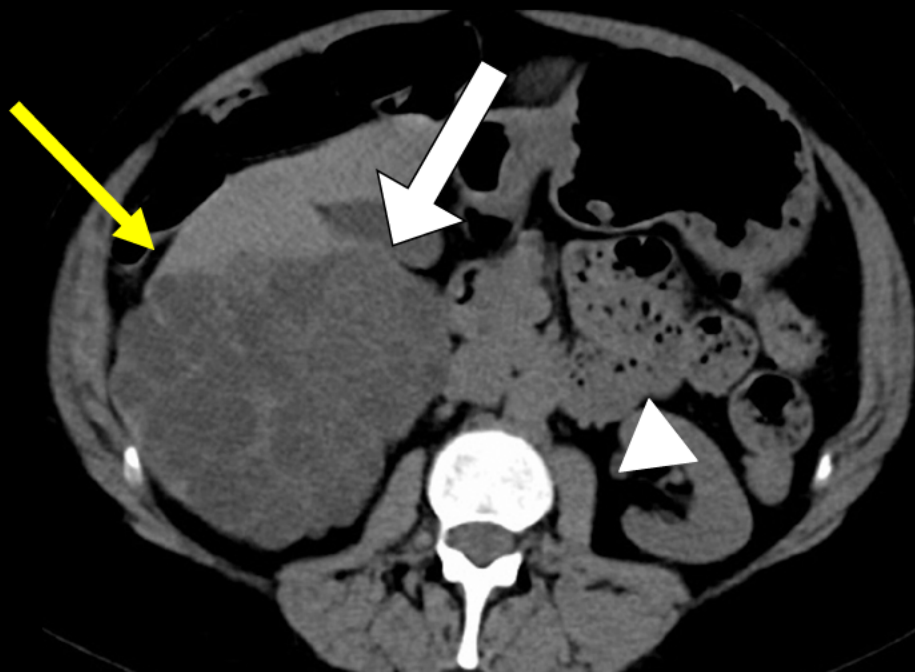
49 year old female incidentally found to have a complex cystic lesion of the liver on ultrasound when she presented with symptoms of diffuse nonspecific abdominal pain and bloating



AIRPTM

AMERICAN INSTITUTE FOR
RADIOLOGIC PATHOLOGY

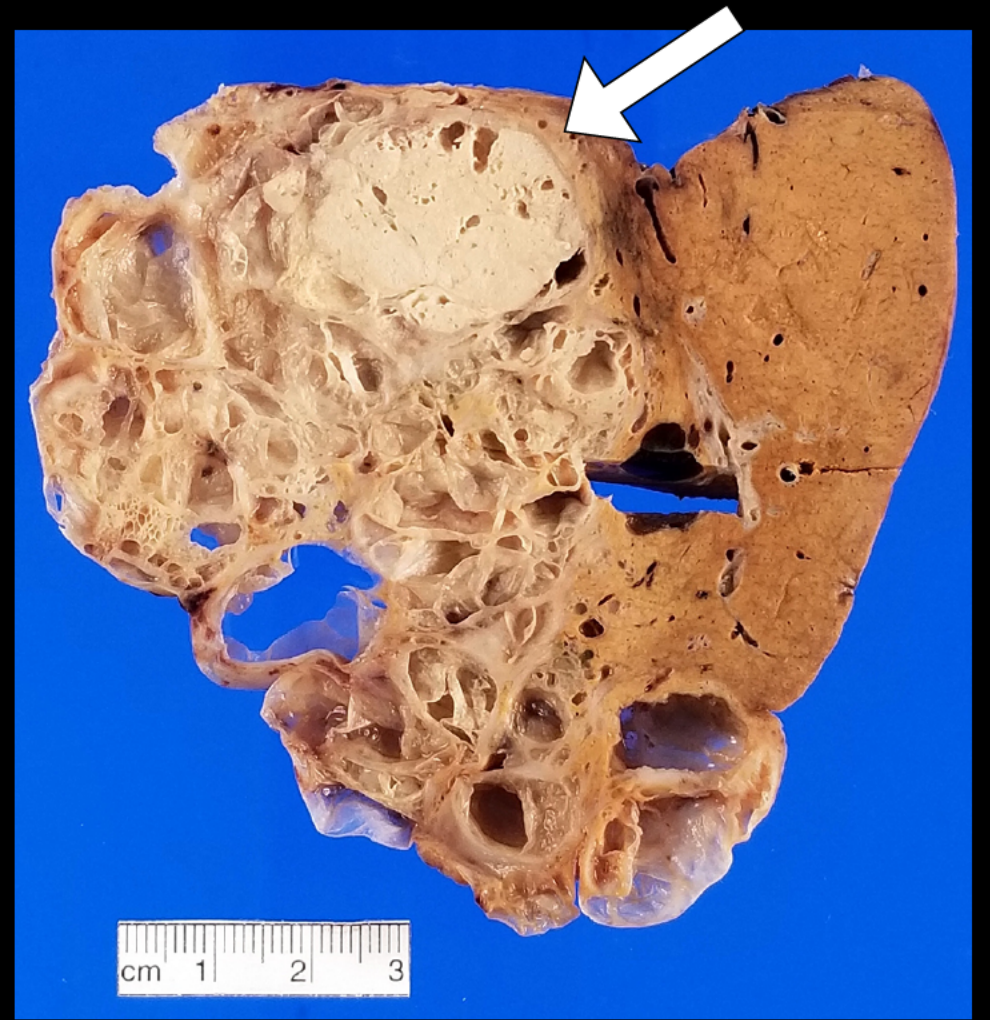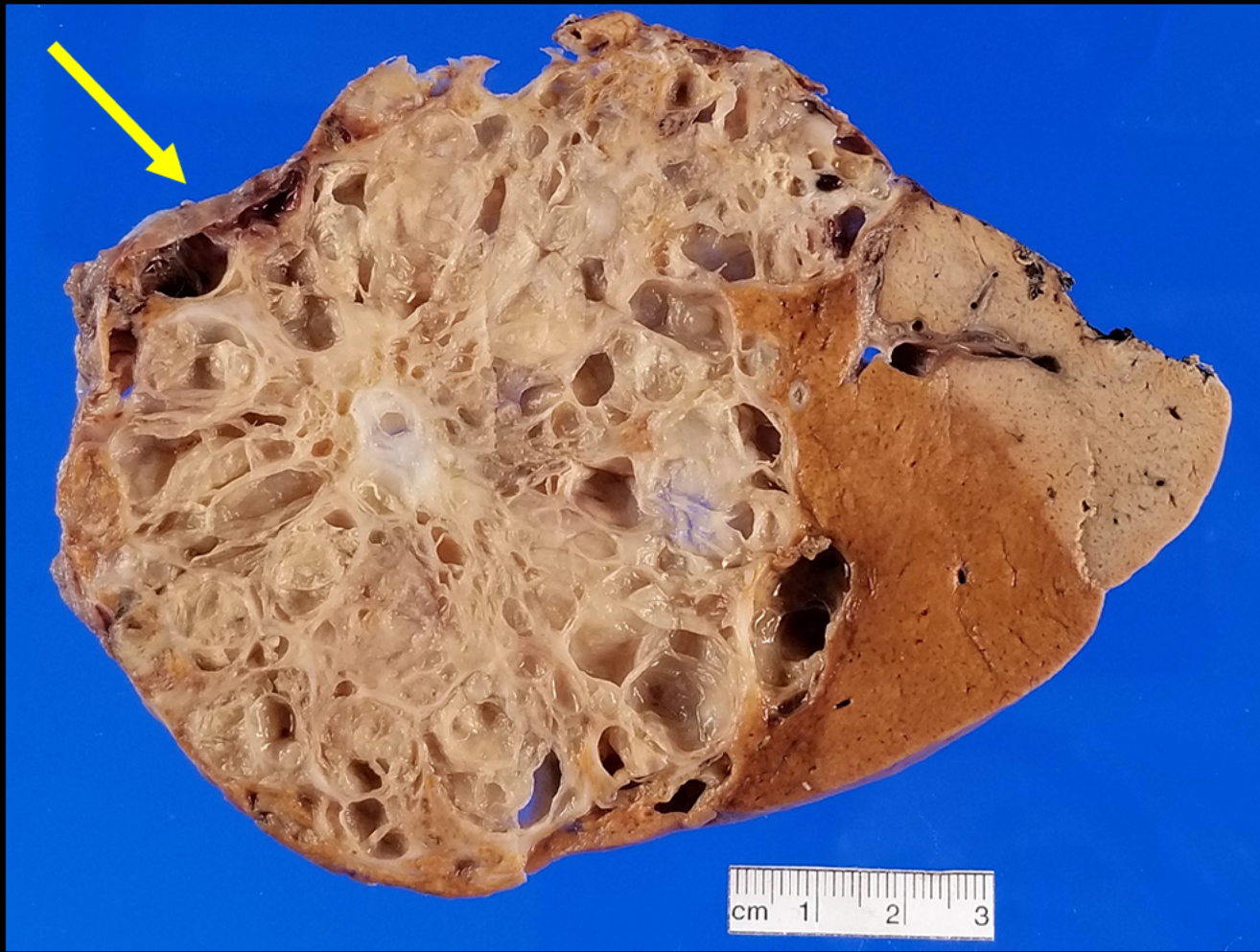A PROGRAM OF THE
AMERICAN COLLEGE OF RADIOLOGY



AIRPTM

AMERICAN INSTITUTE FOR
RADIOLOGIC PATHOLOGY

A PROGRAM OF THE
AMERICAN COLLEGE OF RADIOLOGY



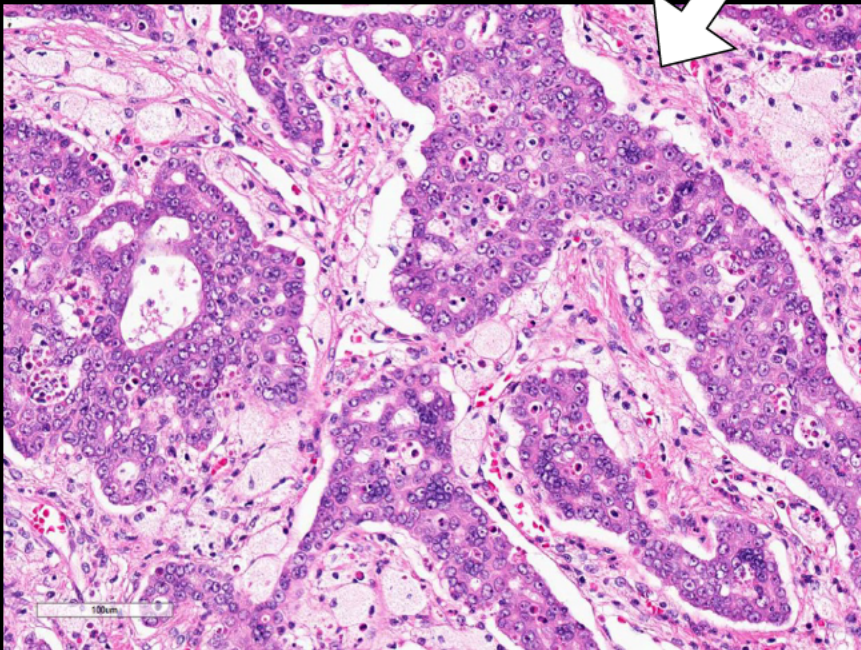
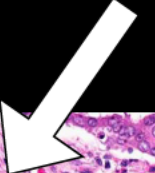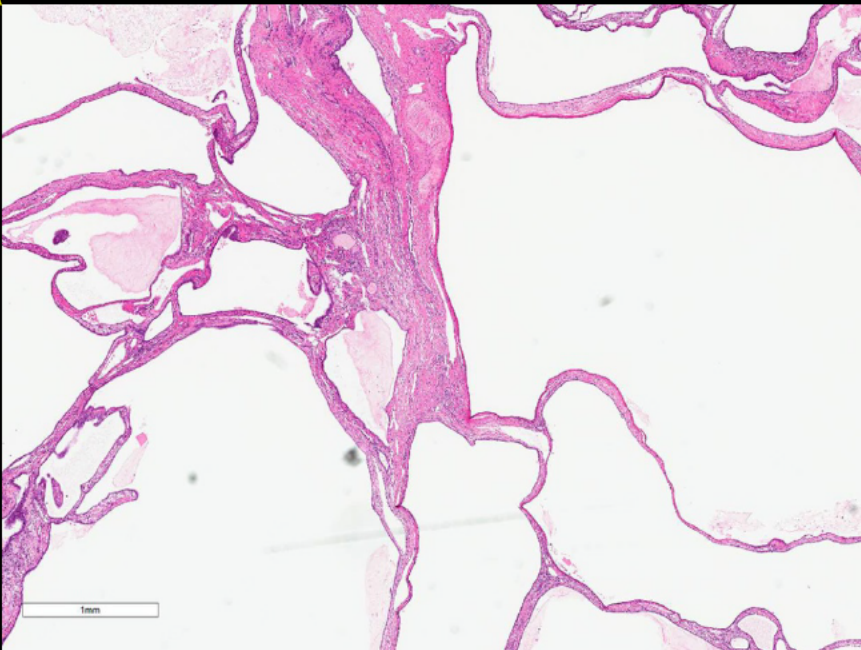
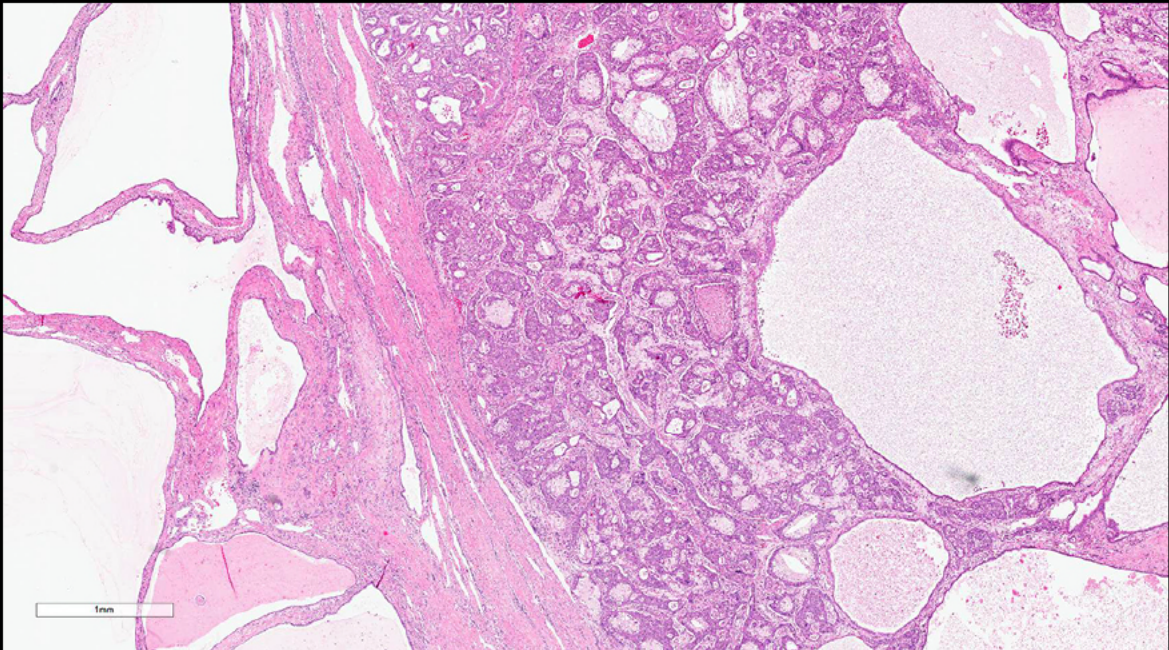
AIRPTM

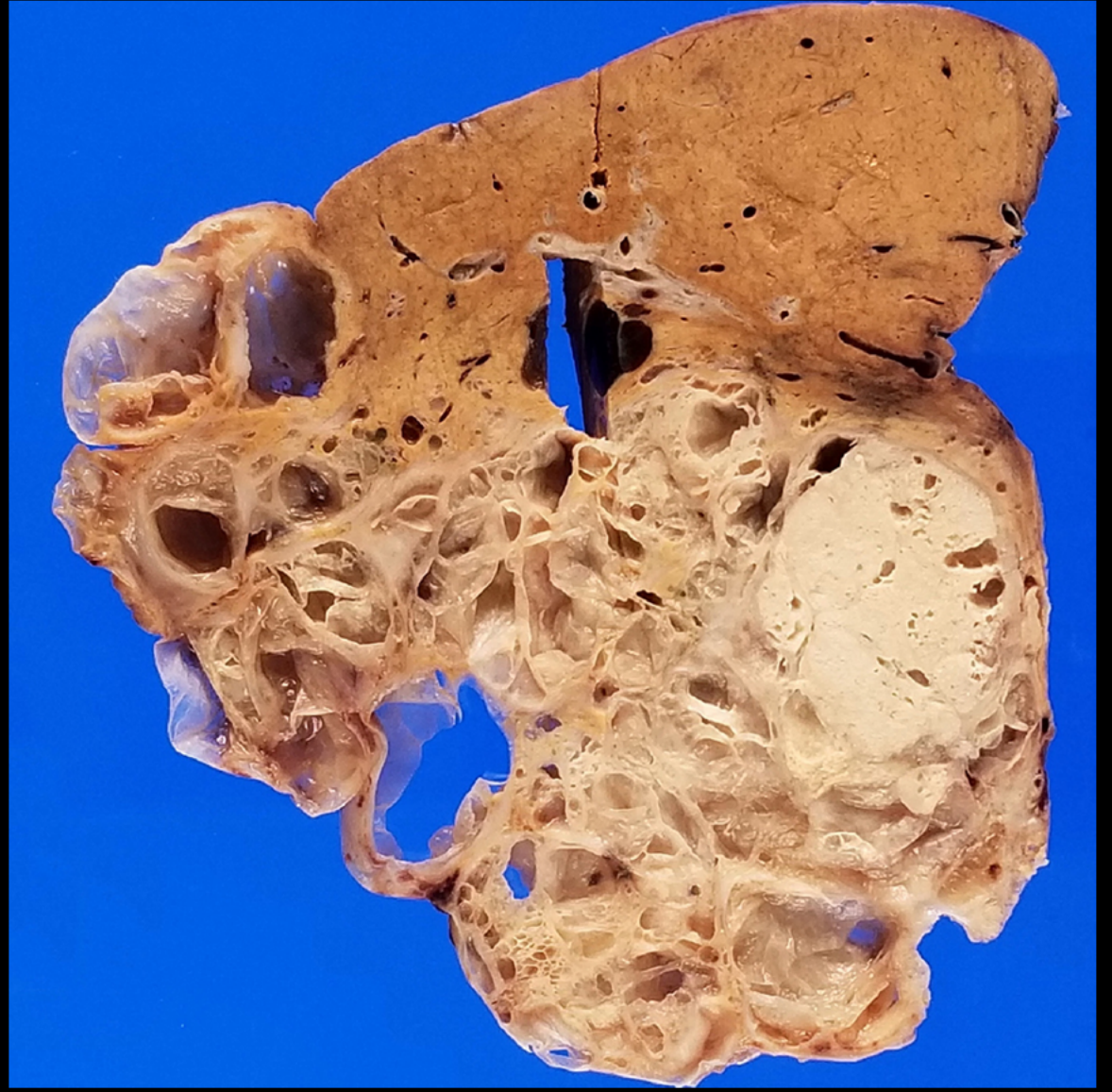
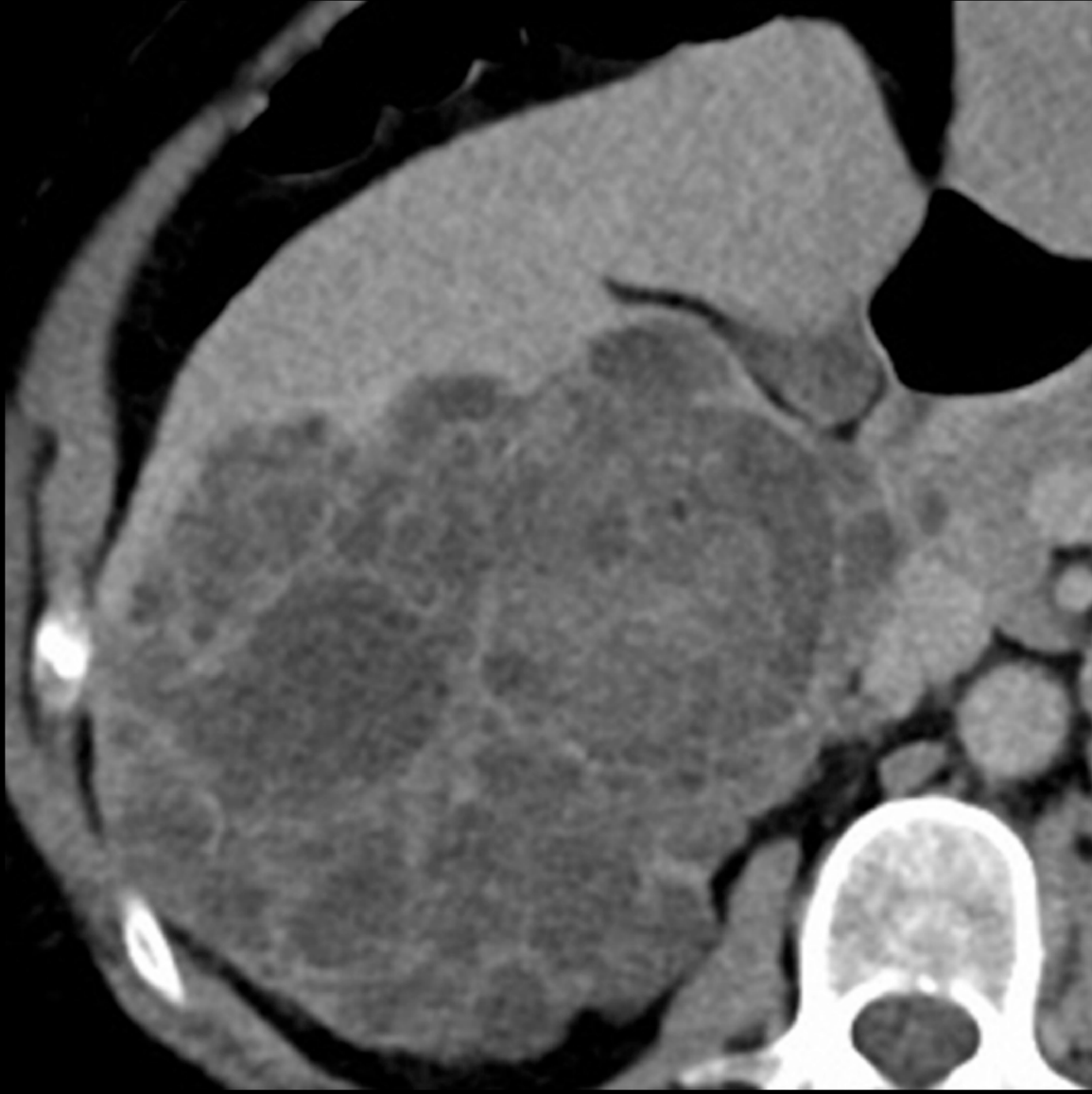
AMERICAN INSTITUTE FOR
RADIOLOGIC PATHOLOGY

A PROGRAM OF THE
AMERICAN COLLEGE OF RADIOLOGY

Immunohistochemistry:

Epithelium (+) biliary origin
Stroma (-) ER, PR, inhibin = not MCN





Biliary adenofibroma complicated by cholangiocarcinoma

Shamir Rai

Vancouver General Hospital

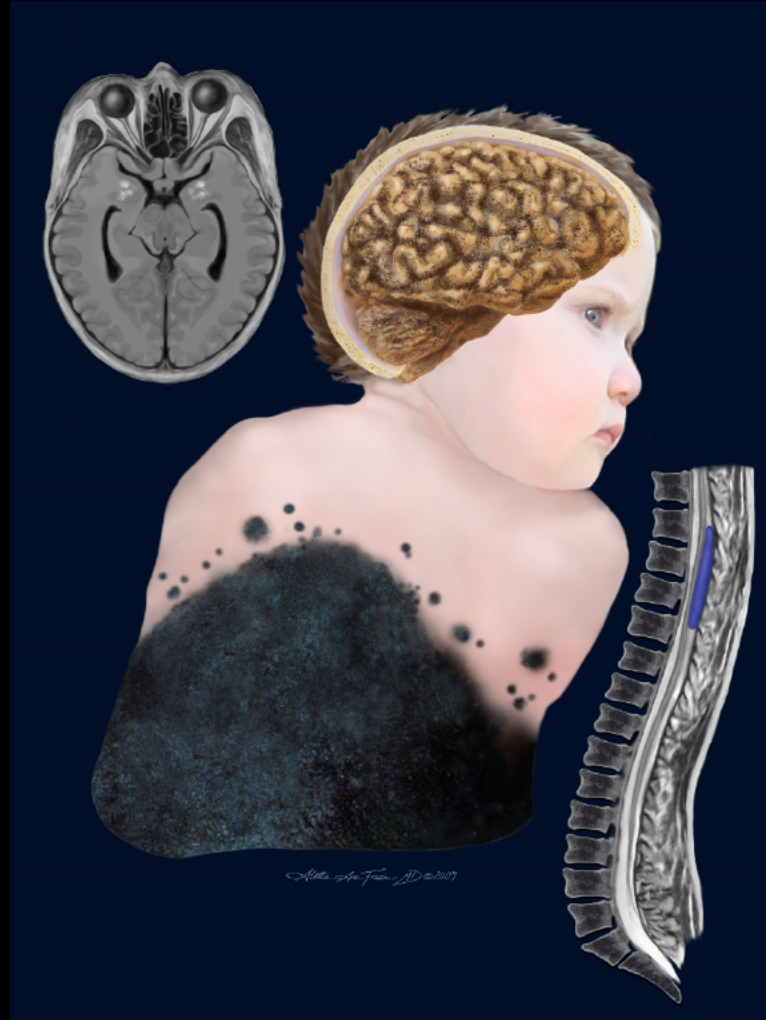Vancouver, BC

AIRPTM

**AMERICAN INSTITUTE FOR
RADIOLOGIC PATHOLOGY**

**A PROGRAM OF THE
AMERICAN COLLEGE OF RADIOLOGY**

Neuroradiology Best Case

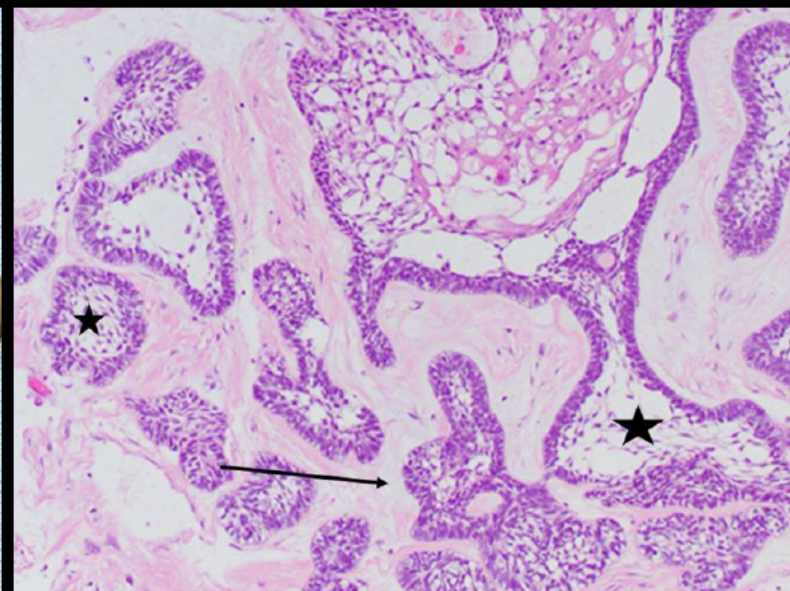
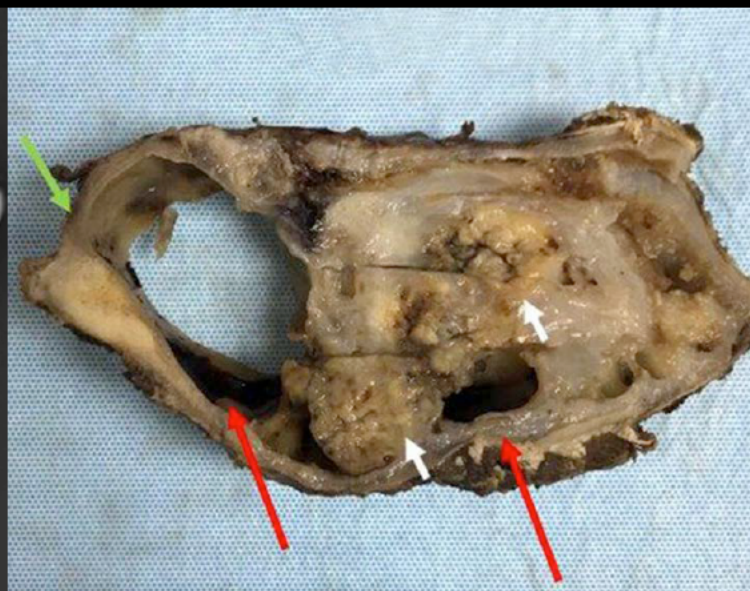
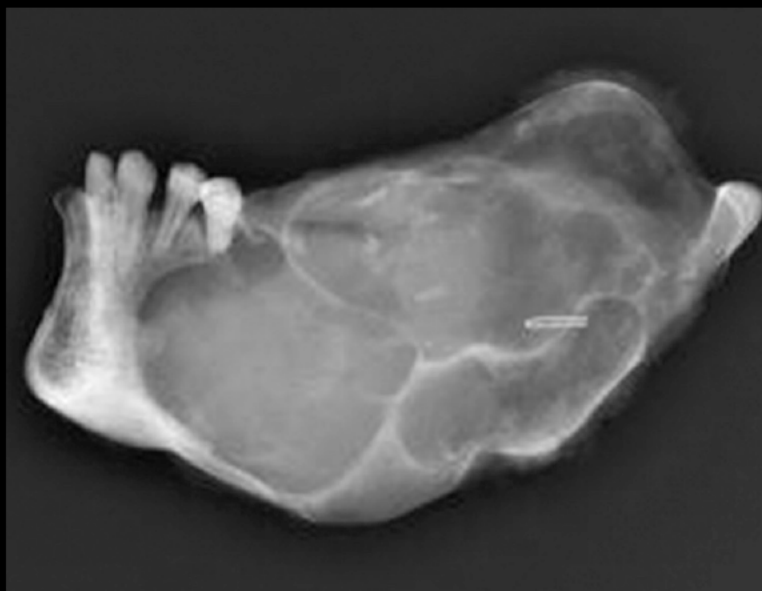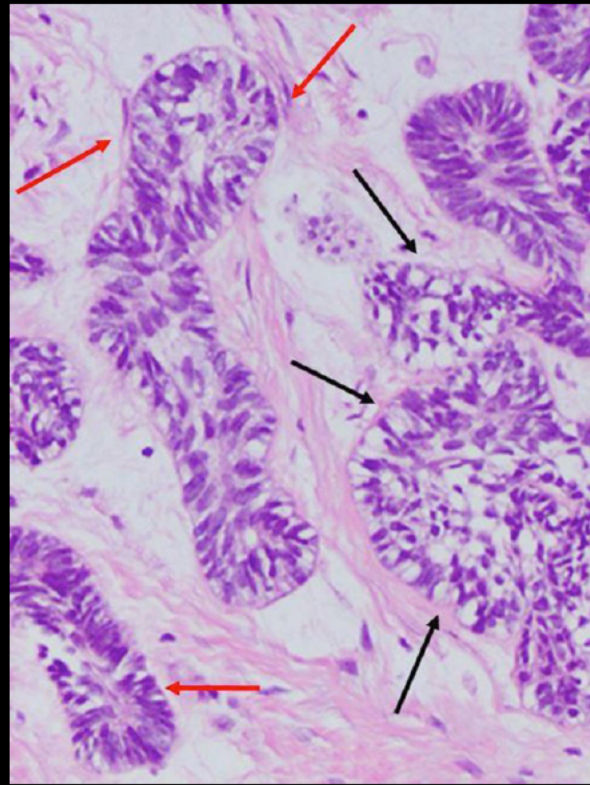
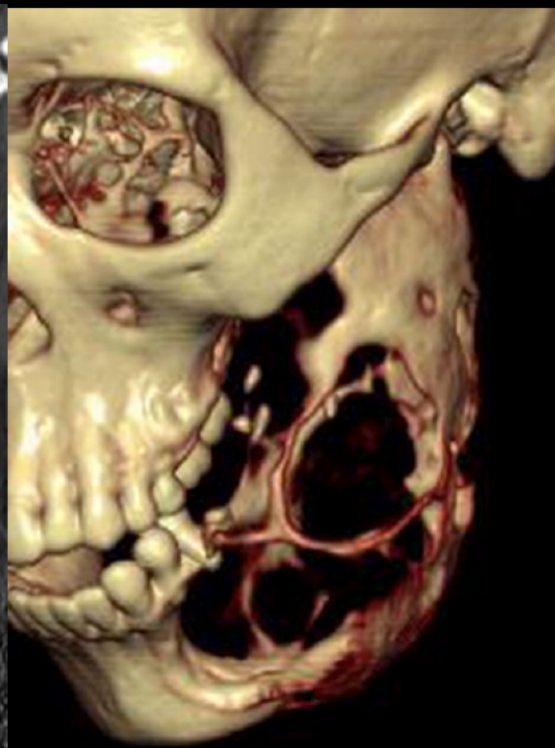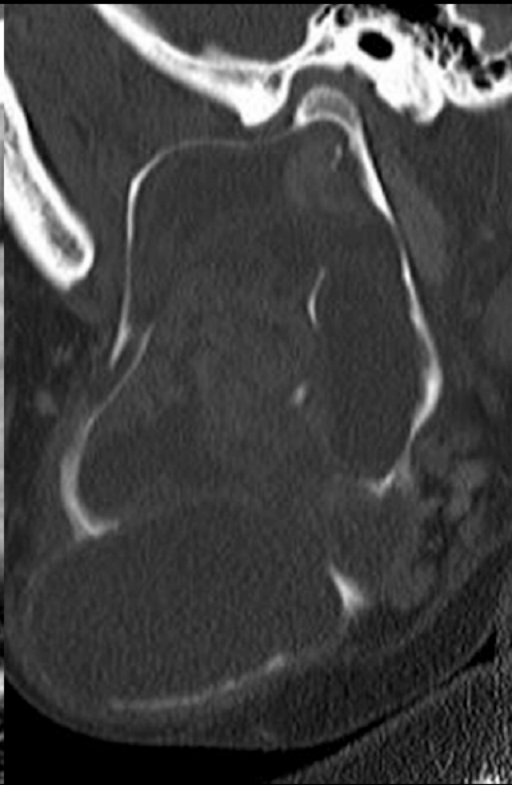


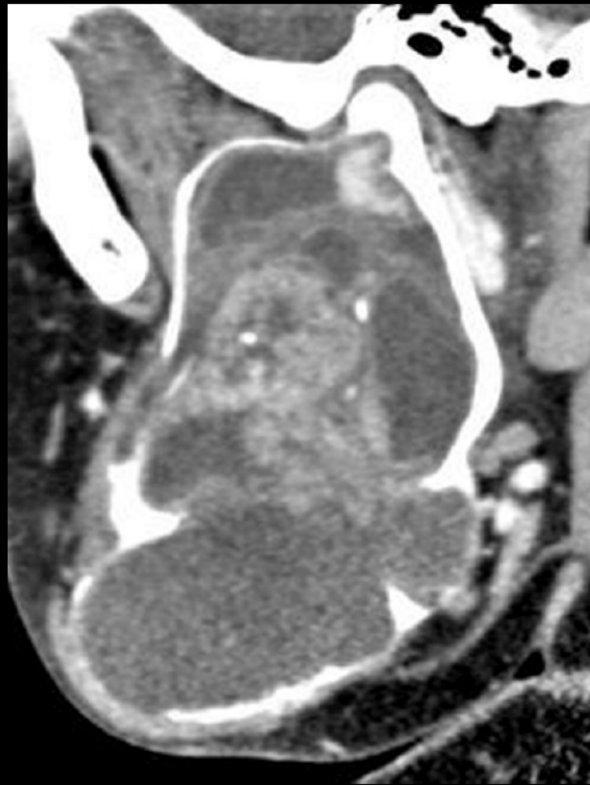AIRPTM
AMERICAN INSTITUTE FOR
RADIOLOGIC PATHOLOGY

A PROGRAM OF THE
AMERICAN COLLEGE OF RADIOLOGY

Clinical information

21-year-old female with progressive discomfort and swelling in left jaw region following tooth extraction 1 year earlier



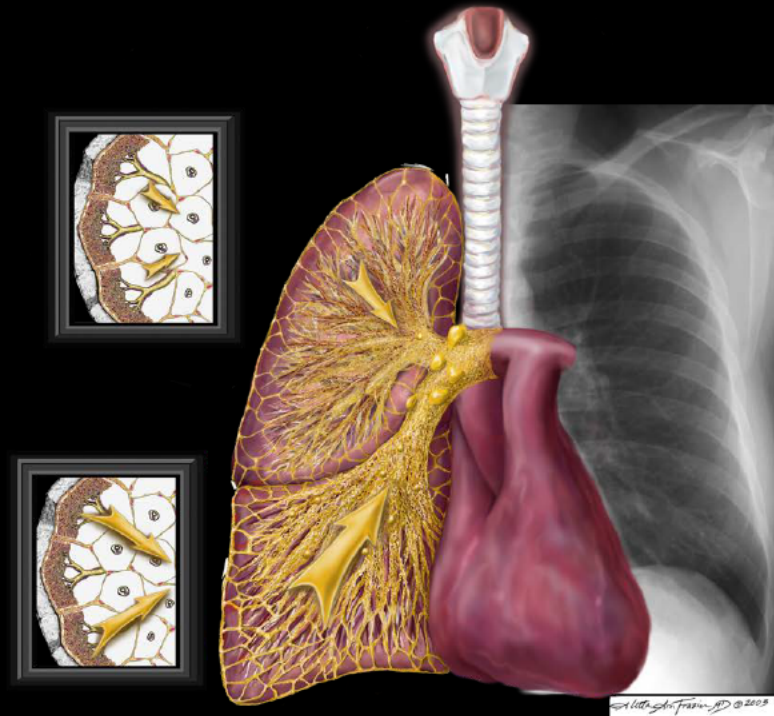
Ameloblastoma

Michael Maggart, M.D.
Jackson Memorial Hospital
Miami, Florida



A PROGRAM OF THE
AMERICAN COLLEGE OF RADIOLOGY

Pulmonary and Mediastinal Best Case



AIRP™

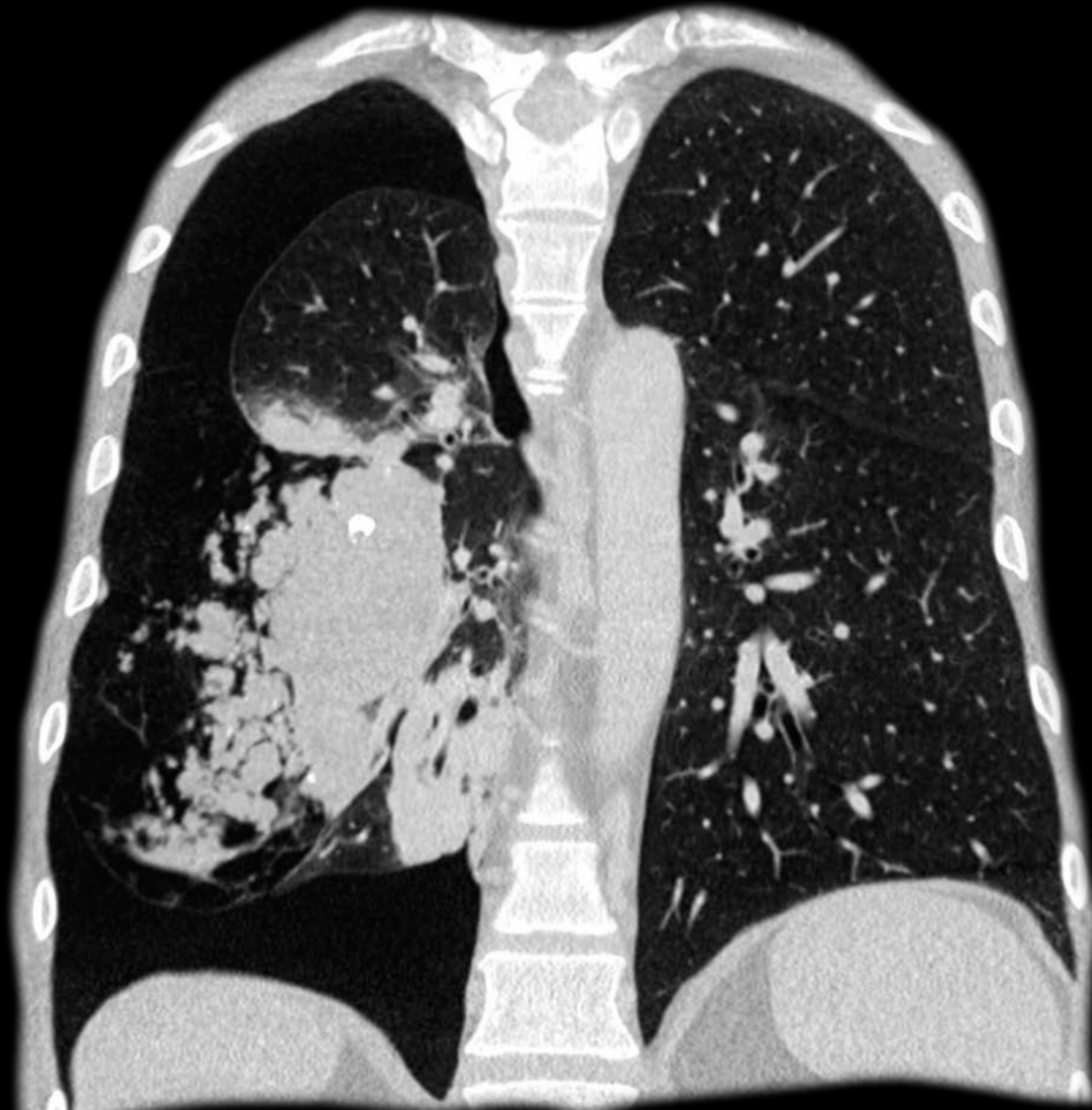
AMERICAN INSTITUTE FOR
RADIOLOGIC PATHOLOGY

A PROGRAM OF THE
AMERICAN COLLEGE OF RADIOLOGY

Clinical information

48 year-old-male with right-sided chest pain and progressive dyspnea over 3 days. A right sided pneumothorax was discovered.

Pneumothorax and mass

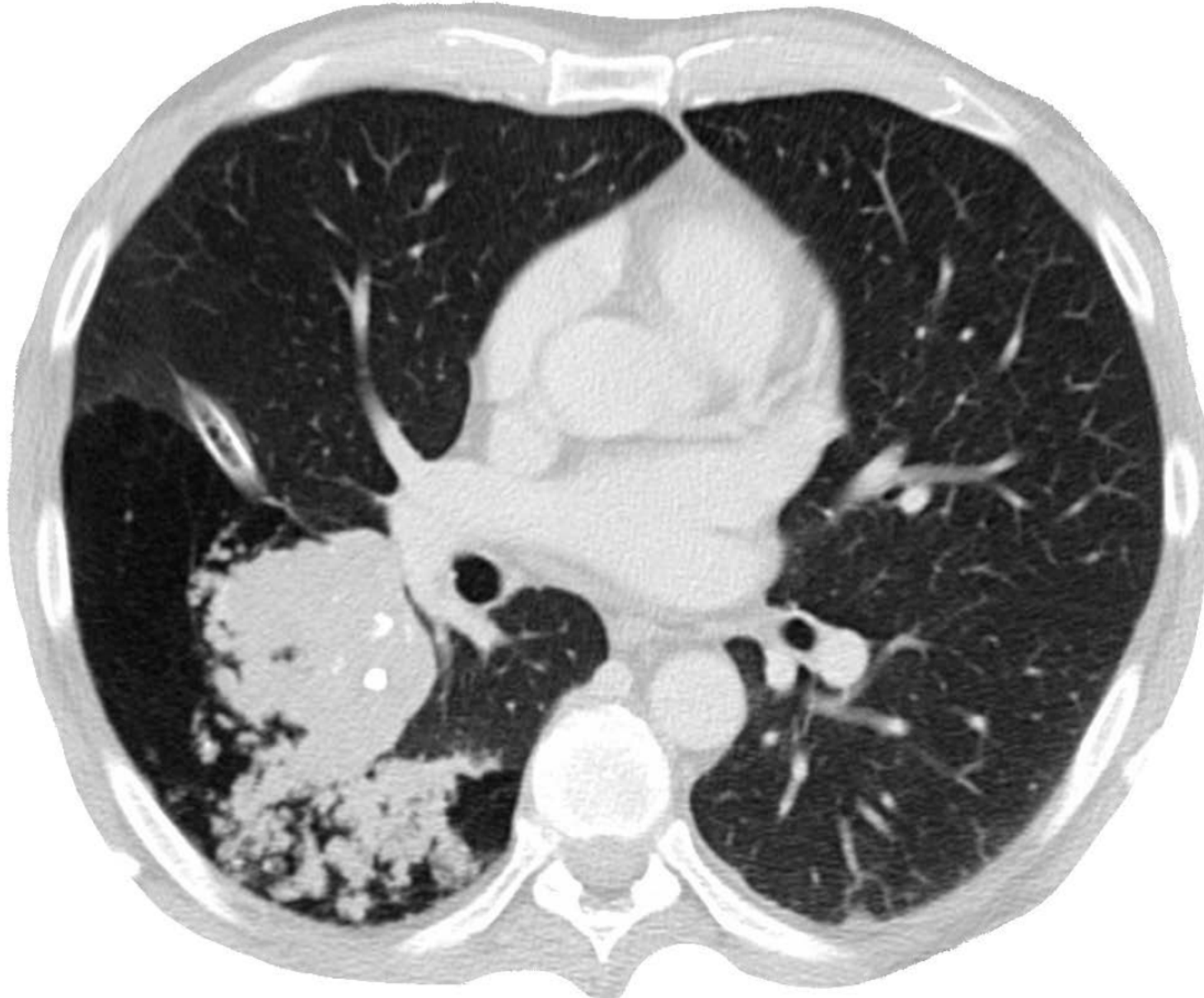


AIRPTM

AMERICAN INSTITUTE FOR
RADIOLOGIC PATHOLOGY

A PROGRAM OF THE
AMERICAN COLLEGE OF RADIOLOGY

Lung mass with calcification

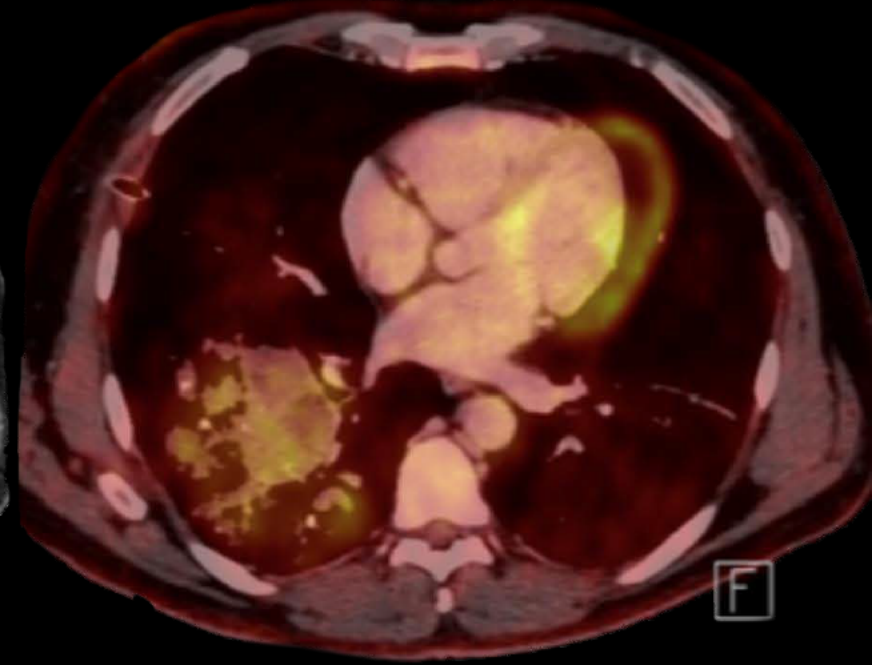
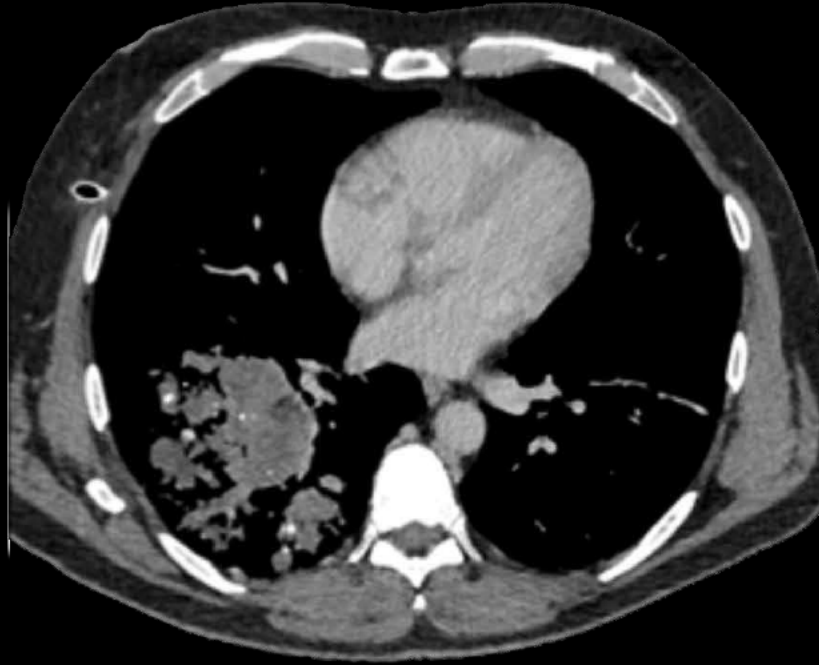
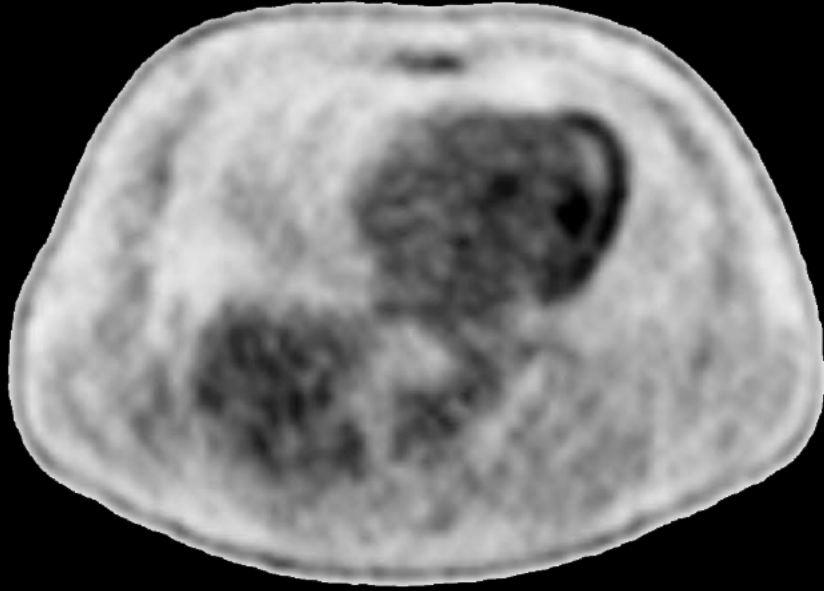


AIRP

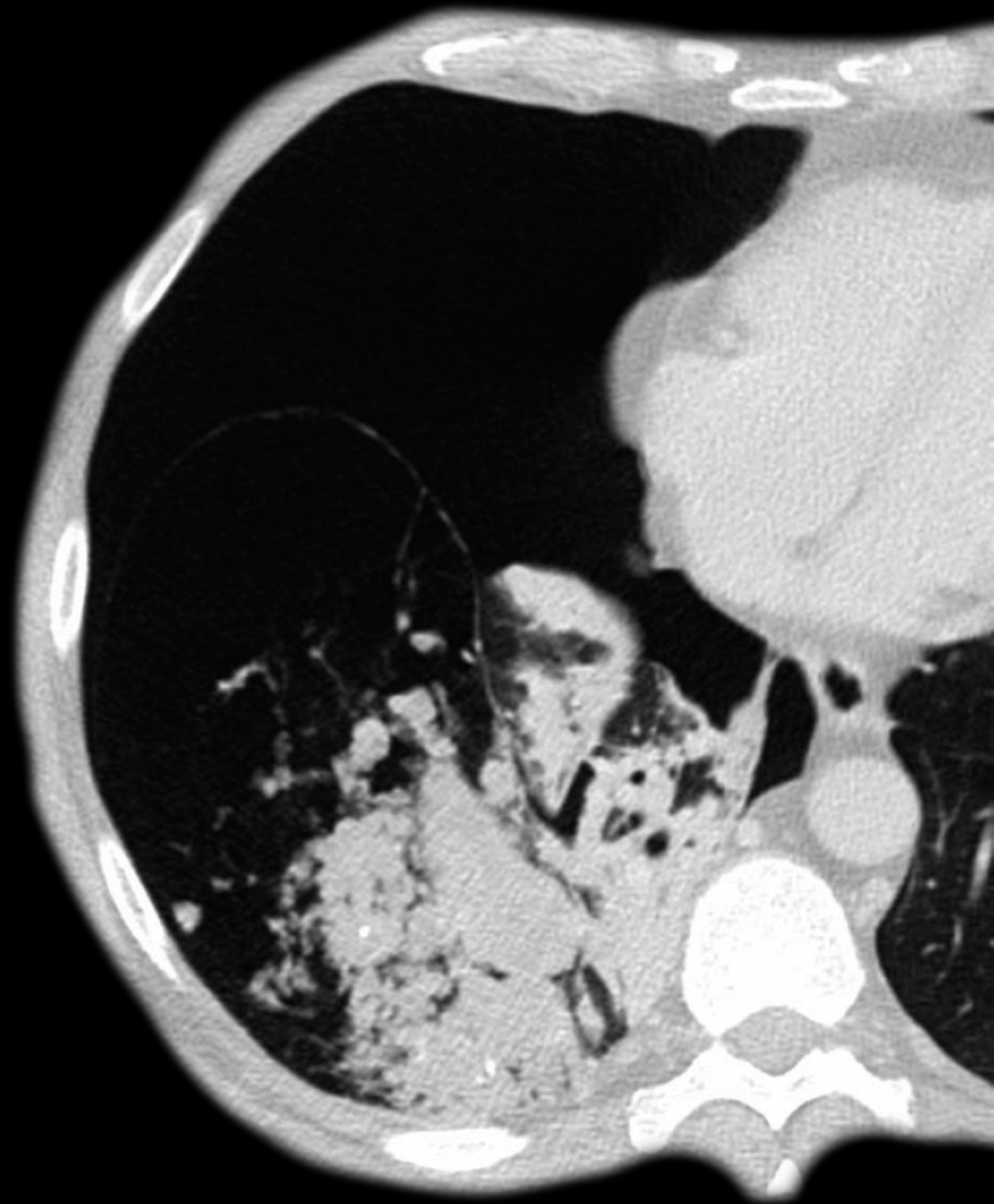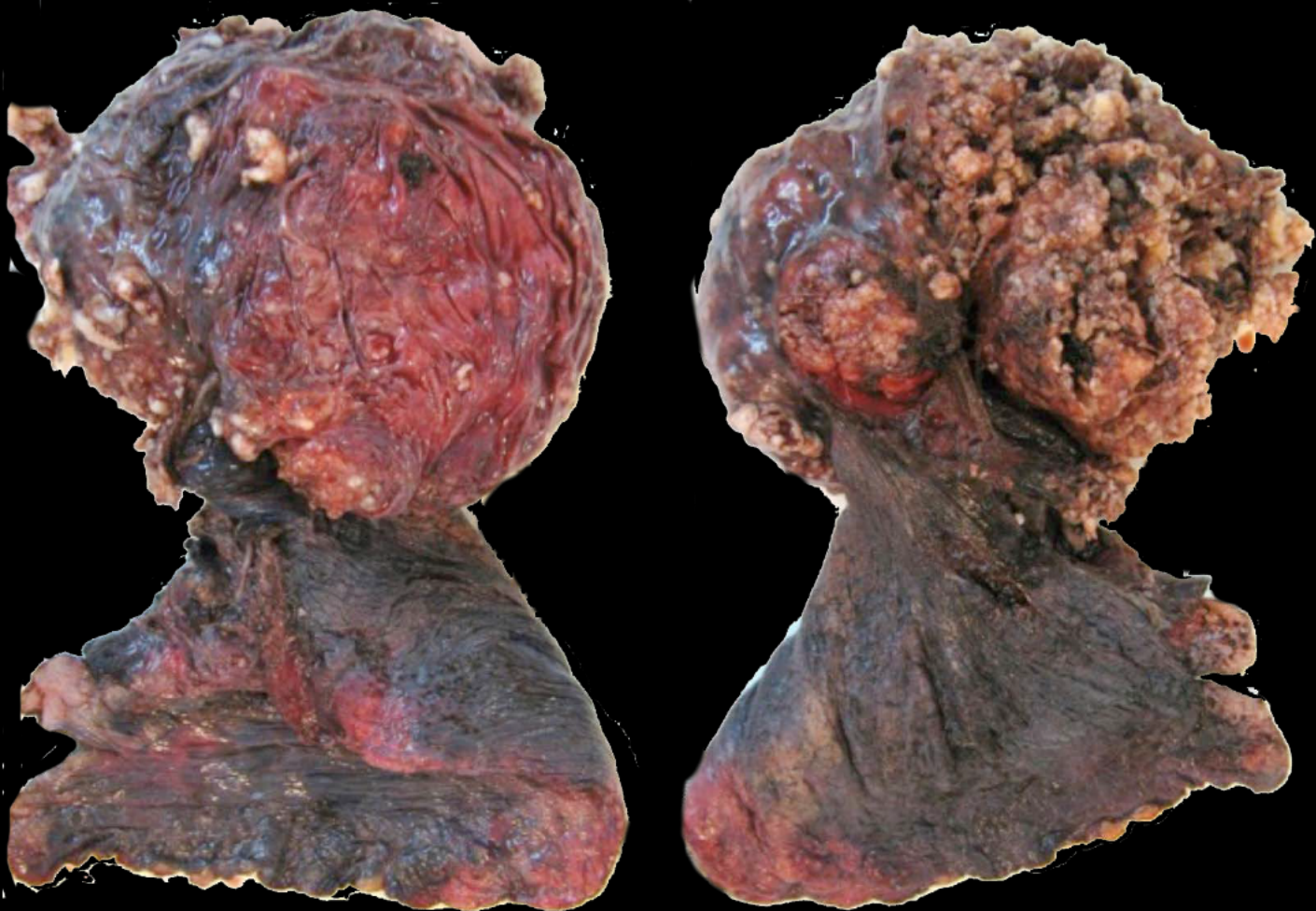AMERICAN INSTITUTE FOR
RADIOLOGIC PATHOLOGY

A PROGRAM OF THE
AMERICAN COLLEGE OF RADIOLOGISTS

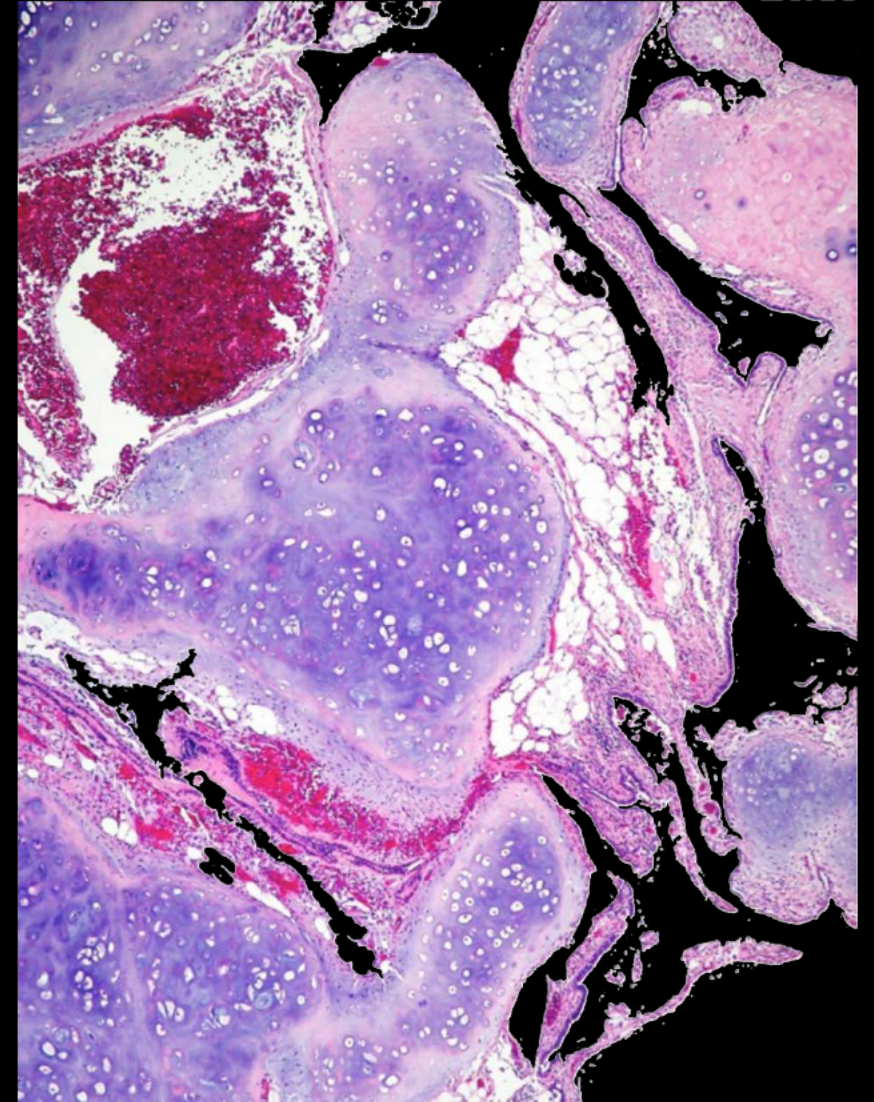
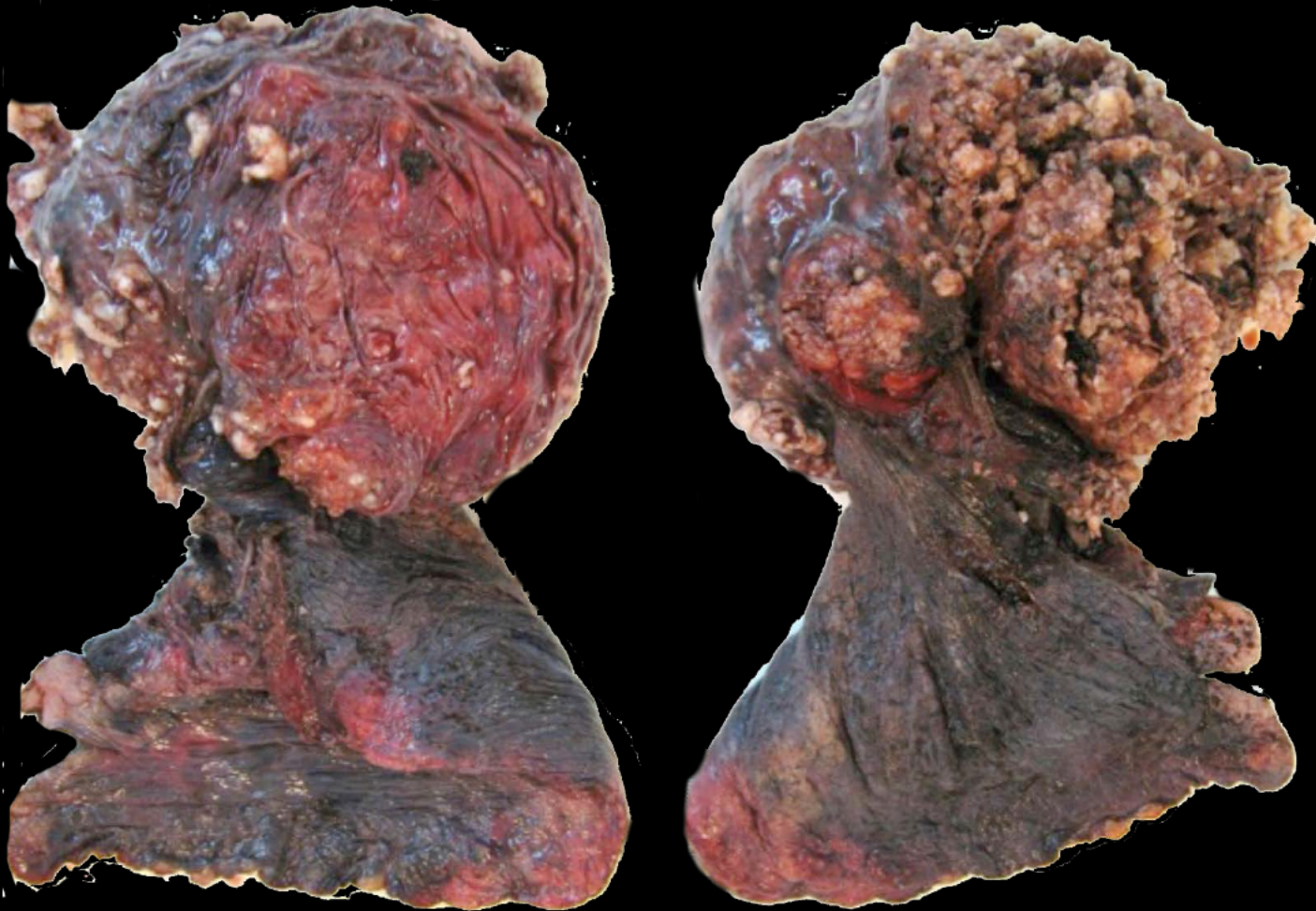PET uptake similar to blood pool



Vascular channels



Hamatoma: cartilage, fat and respiratory epithelium



Hamartoma

Javier Cacho, MD

Clinica Alemana De Santiago

Universidad Del Desarrollo

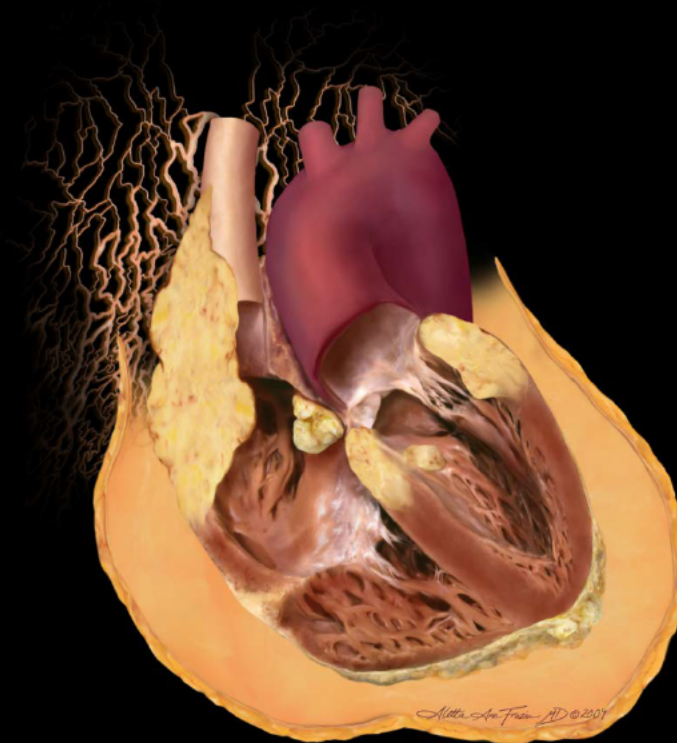
Santiago, Chile



AMERICAN INSTITUTE FOR
RADIOLOGIC PATHOLOGY

A PROGRAM OF THE
AMERICAN COLLEGE OF RADIOLOGY

Cardiovascular Best Case

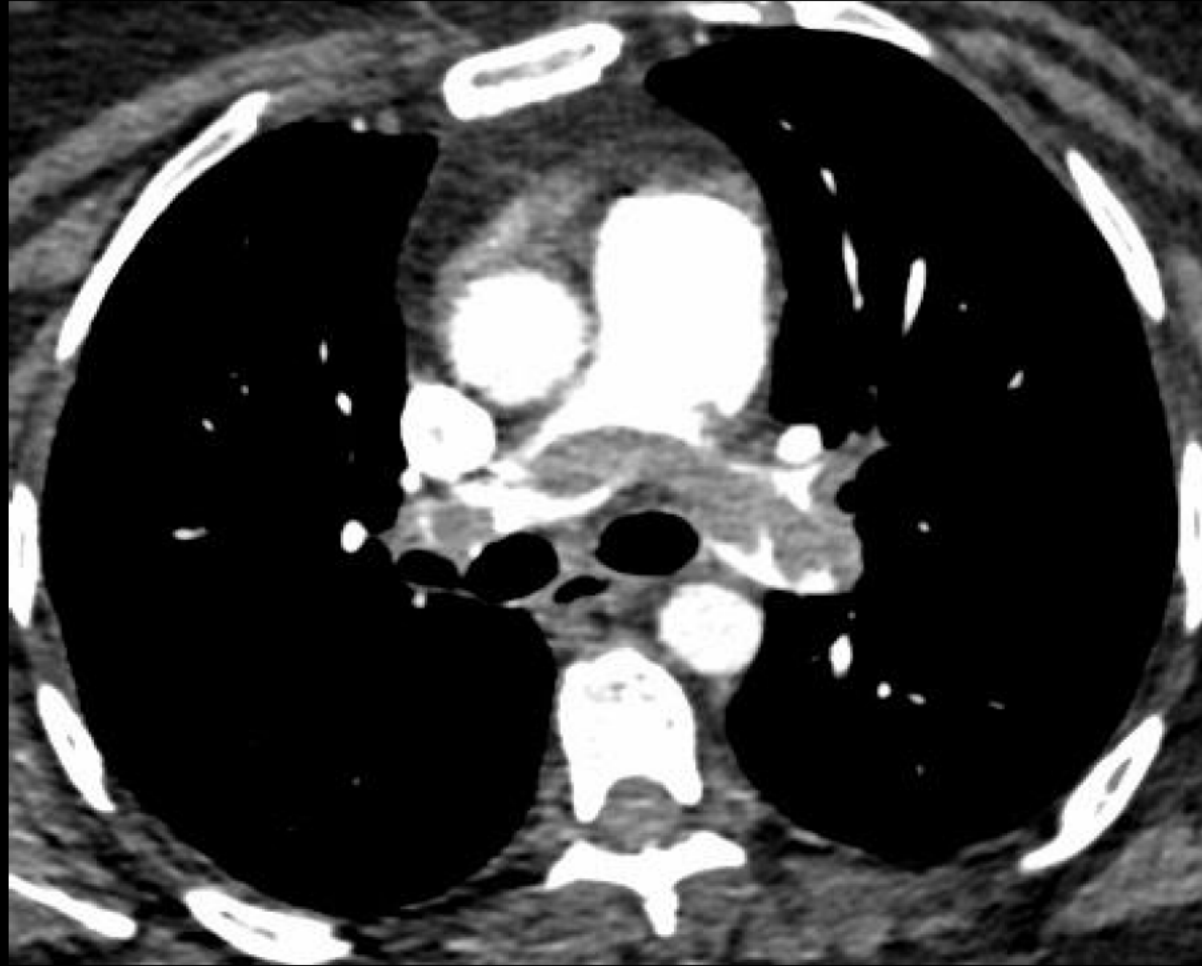


AIRPTM

AMERICAN INSTITUTE FOR
RADIOLOGIC PATHOLOGY

A PROGRAM OF THE
AMERICAN COLLEGE OF RADIOLOGY

51 year old female with progressive dyspnea.

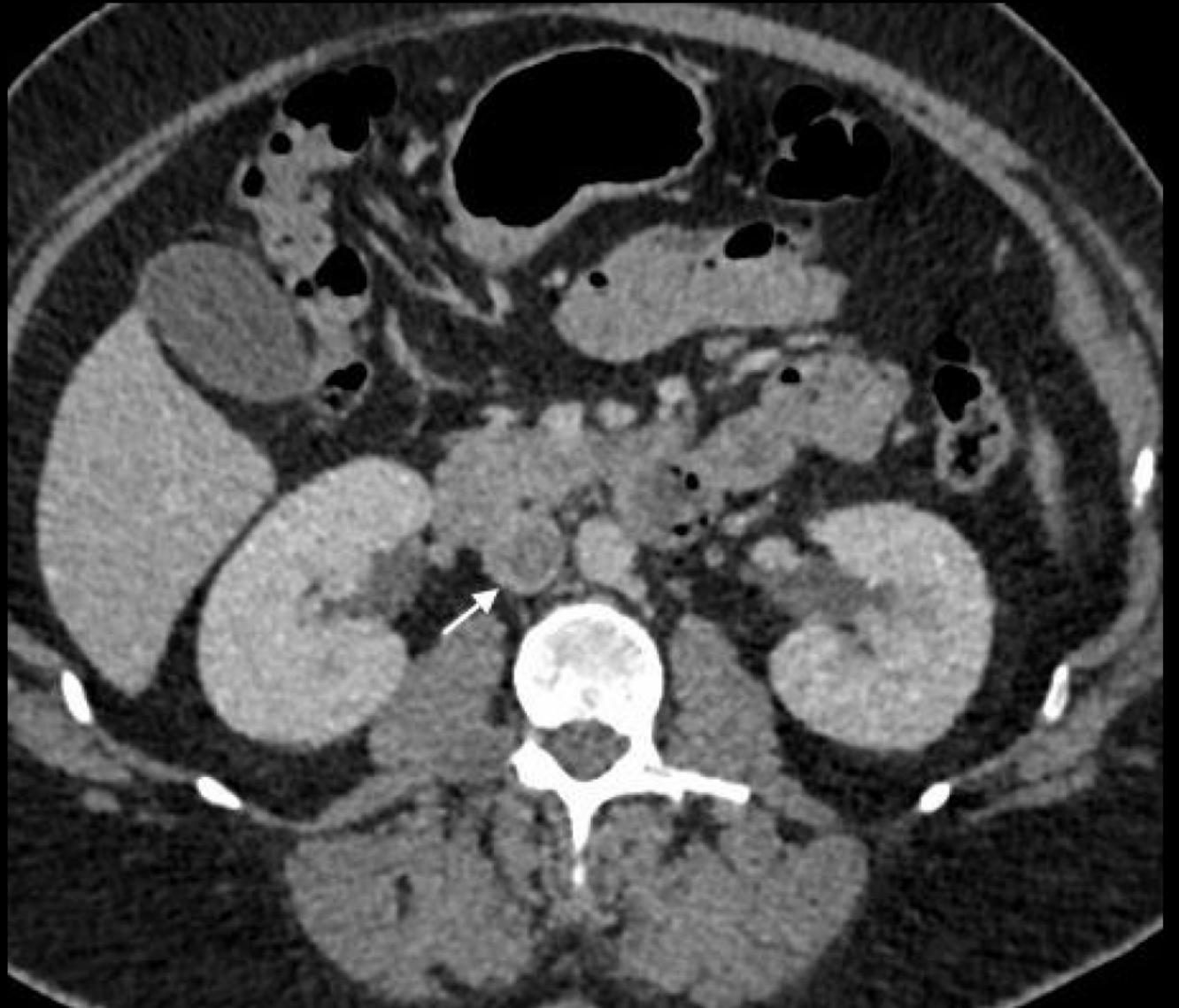
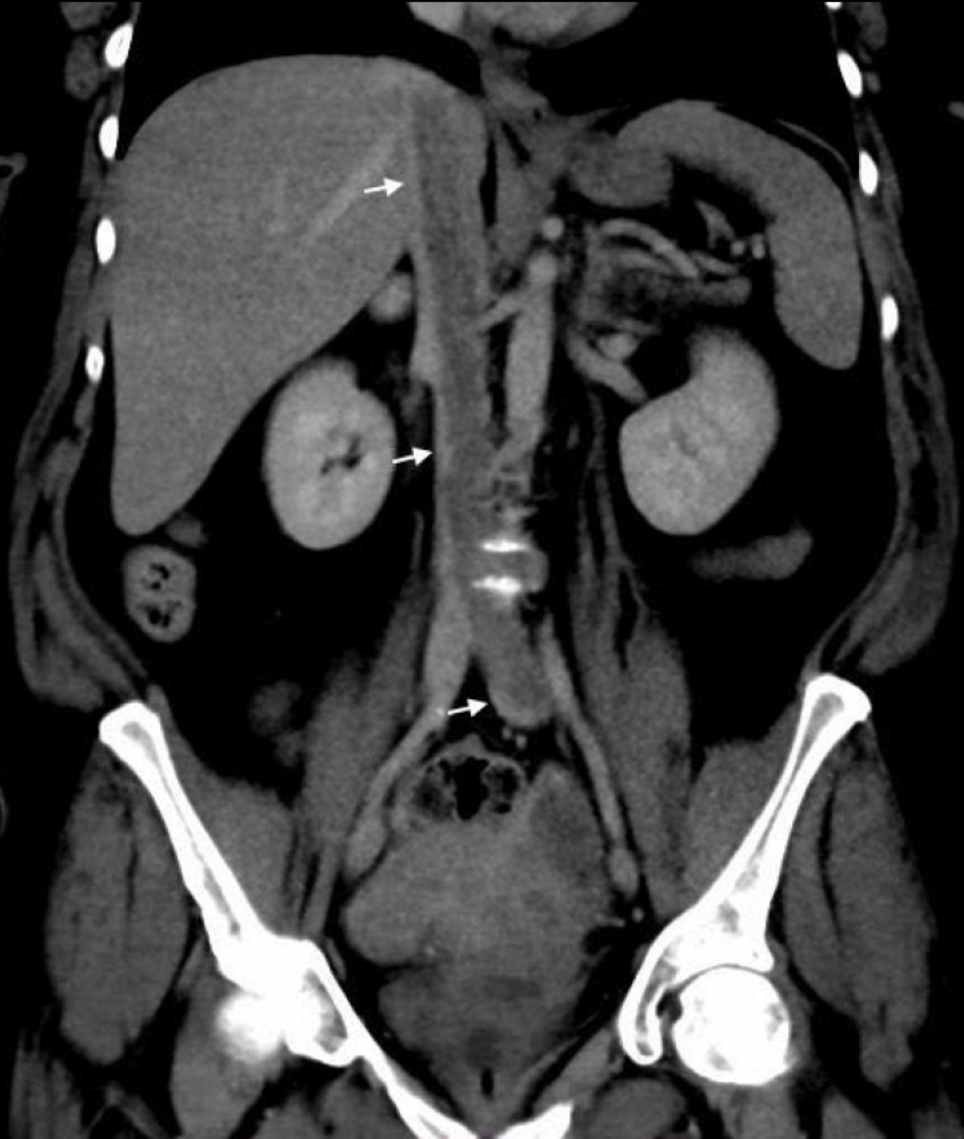


AIRPTM
AMERICAN INSTITUTE FOR
RADIOLOGIC PATHOLOGY

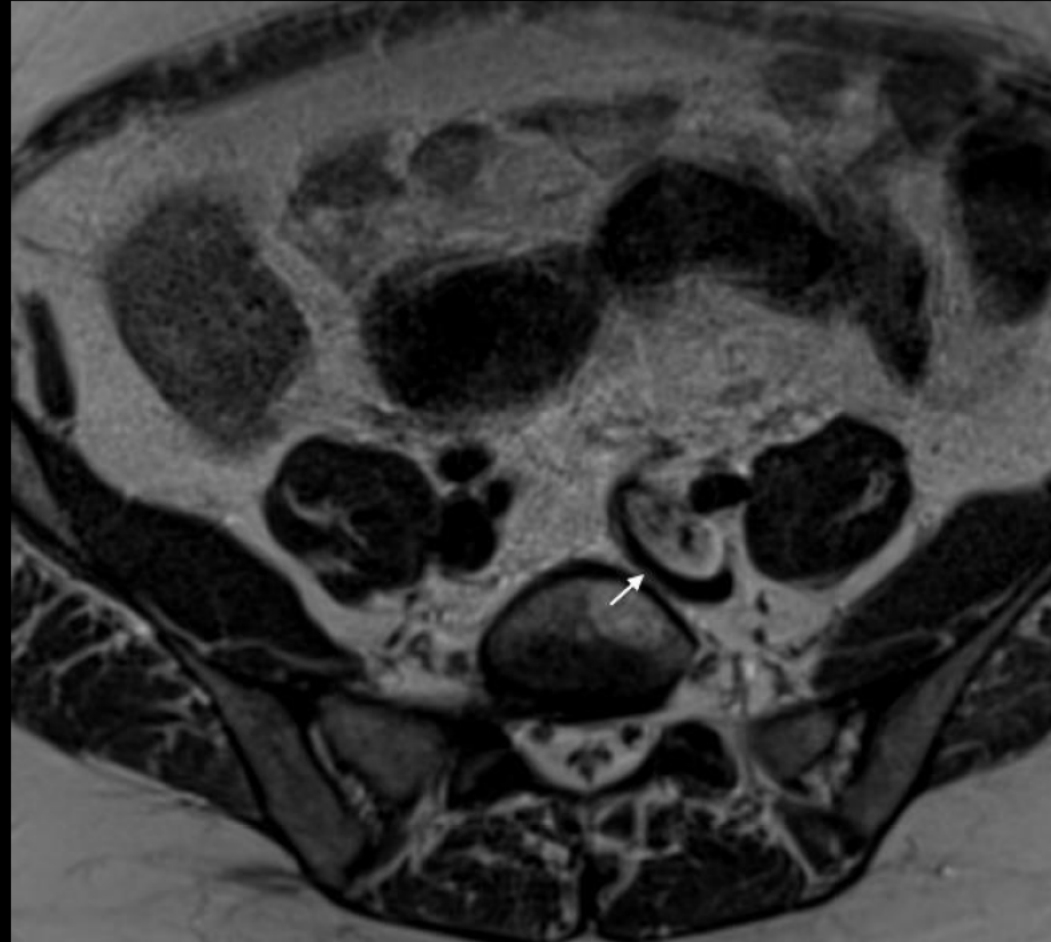
A PROGRAM OF THE
AMERICAN COLLEGE OF RADIOLOGY

Chest CT angiography shows saddle pulmonary embolism.

CT also shows an elongated and partly enhancing intravascular soft tissue mass filling the IVC and left iliac vein (arrows).



MRI (T2 blade sequence) shows mixed signal intensity within the left common iliac vein filling defect (arrow), compatible with internal vascularity. This feature argues against bland thrombus.



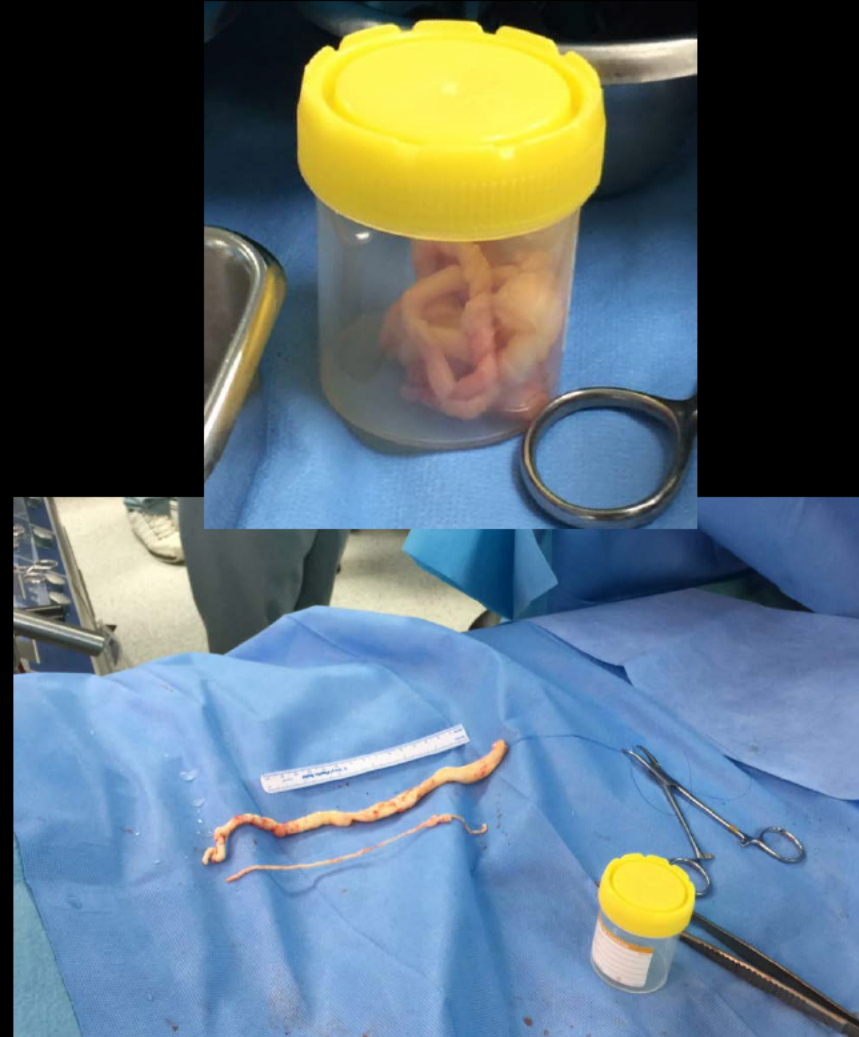AIRPTM

AMERICAN INSTITUTE FOR
RADIOLOGIC PATHOLOGY

A PROGRAM OF THE
AMERICAN COLLEGE OF RADIOLOGY

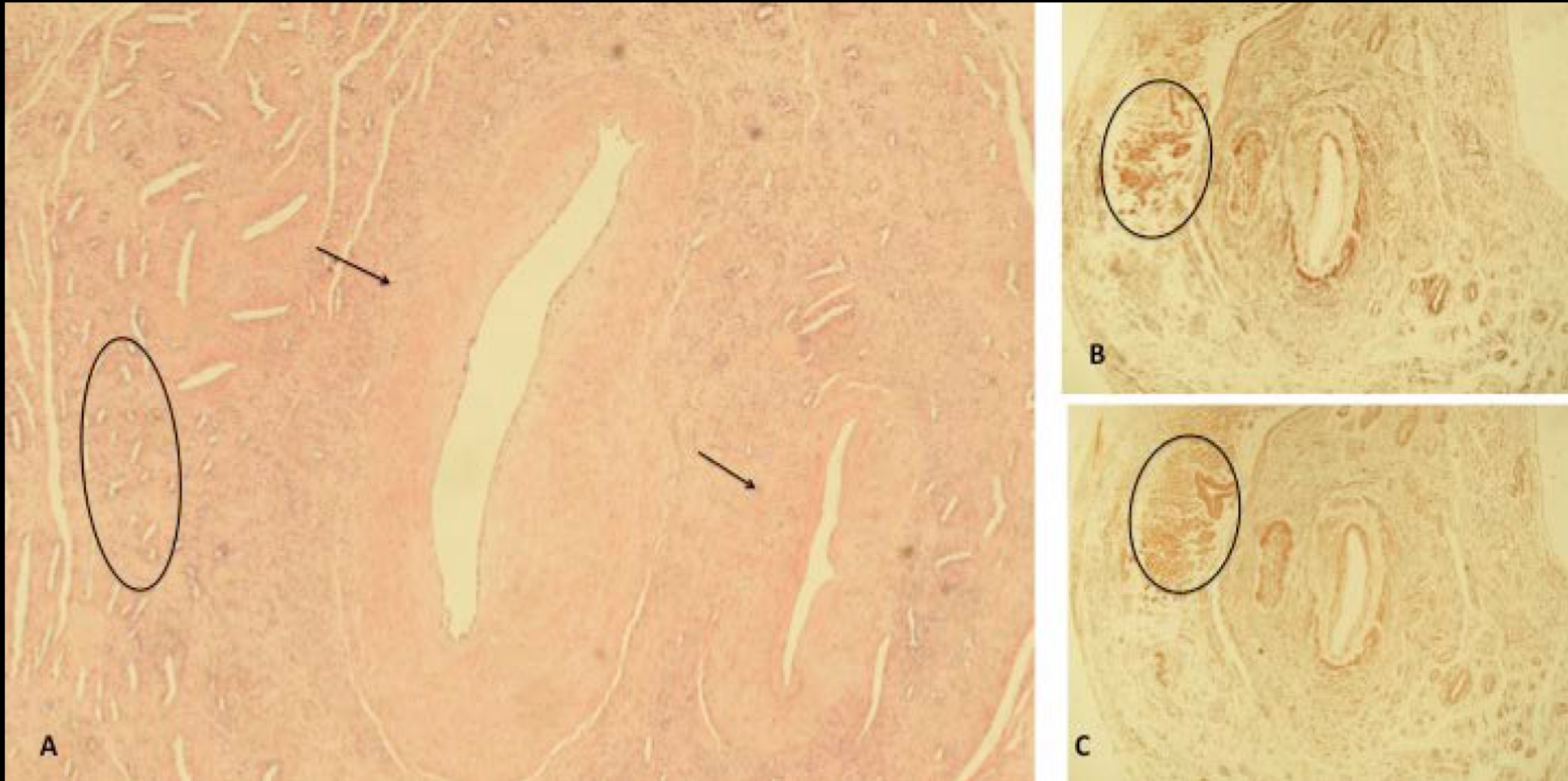
OPERATING ROOM PHOTOGRAPHY:

Elongated IVC intravascular tumor resected, only partly adherent to luminal wall.



Photomicroscopy (LEFT) shows partly adherent intravascular tumor (arrows) and smooth muscle cell proliferation (oval).

Immunohistochemistry (RIGHT) shows tumor cells stain positive for desmin (B) and actin (C).



IVC leiomyomatosis, with fragments filling the pulmonary arteries

Alexandra Murphy, MD

The Mater Misericordiae University Hospital

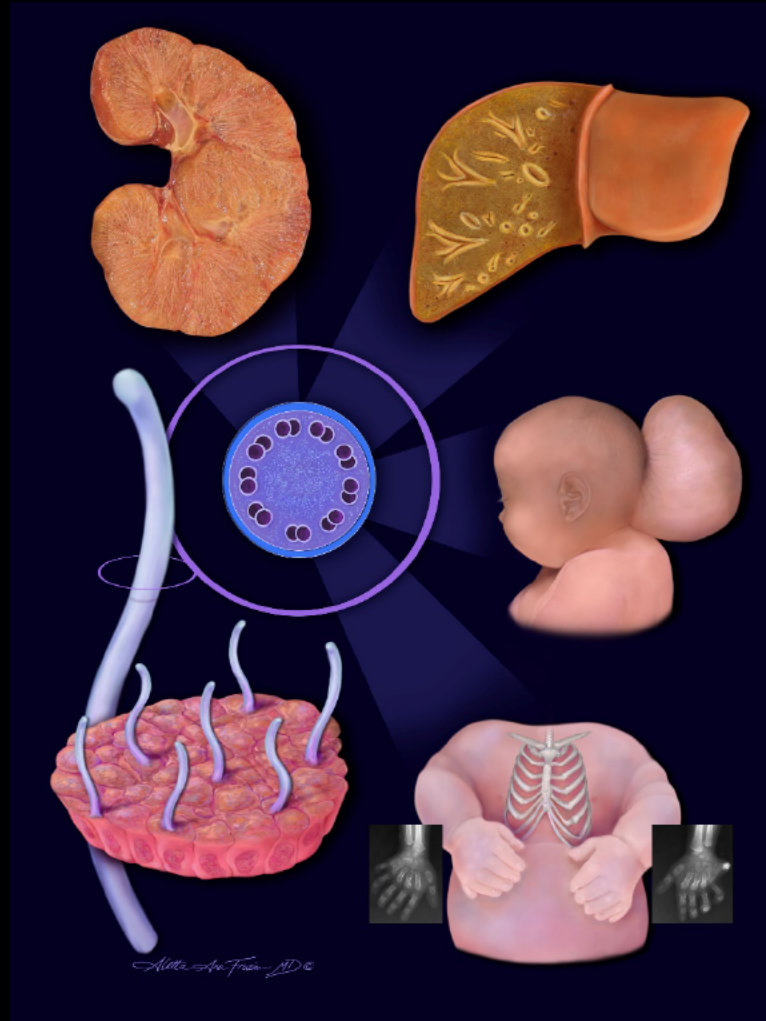
Dublin, Ireland

AIRPTM

AMERICAN INSTITUTE FOR
RADIOLOGIC PATHOLOGY

A PROGRAM OF THE
AMERICAN COLLEGE OF RADIOLOGY

Pediatric Best Case



AIRPTM

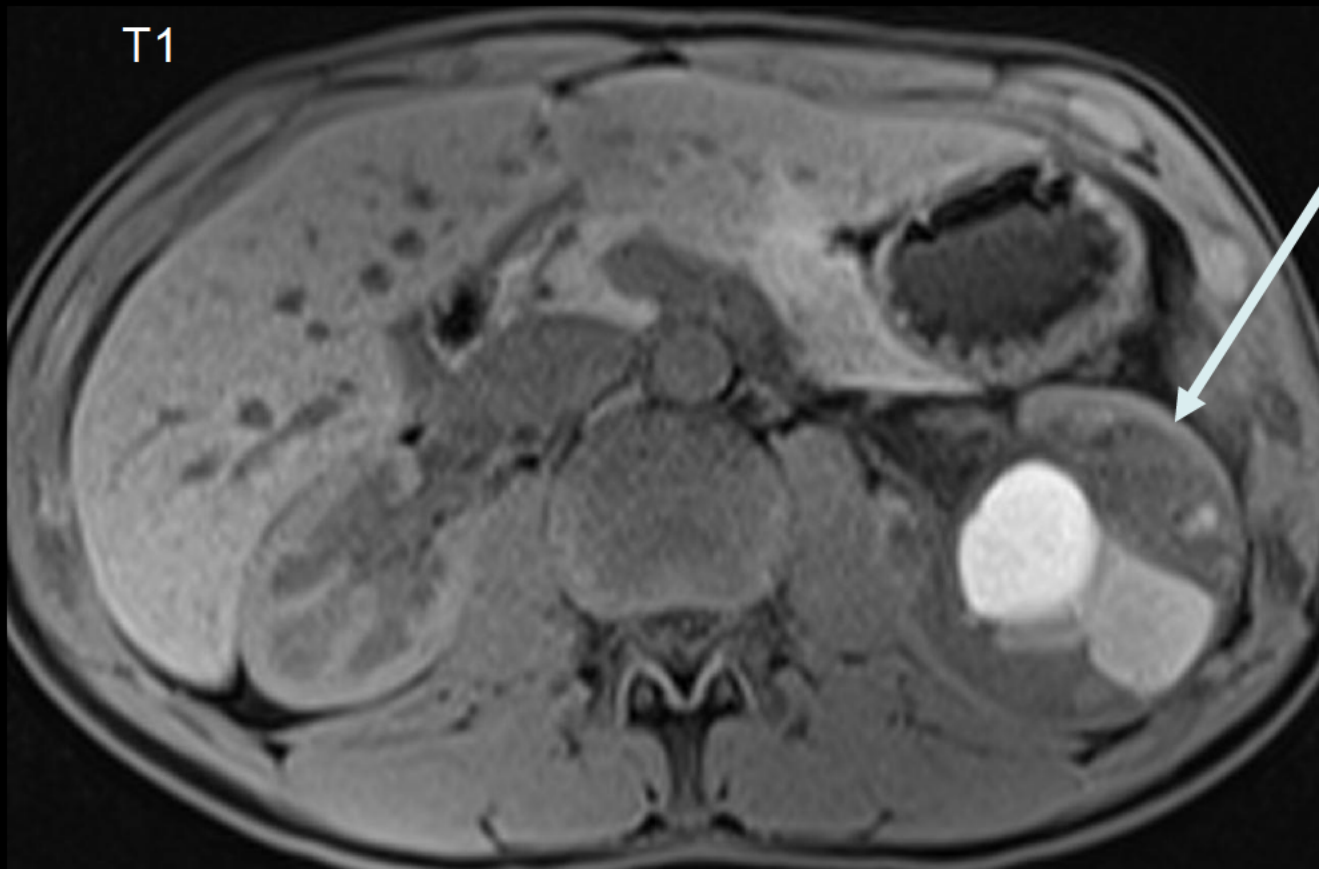
AMERICAN INSTITUTE FOR
RADIOLOGIC PATHOLOGY

A PROGRAM OF THE
AMERICAN COLLEGE OF RADIOLOGY

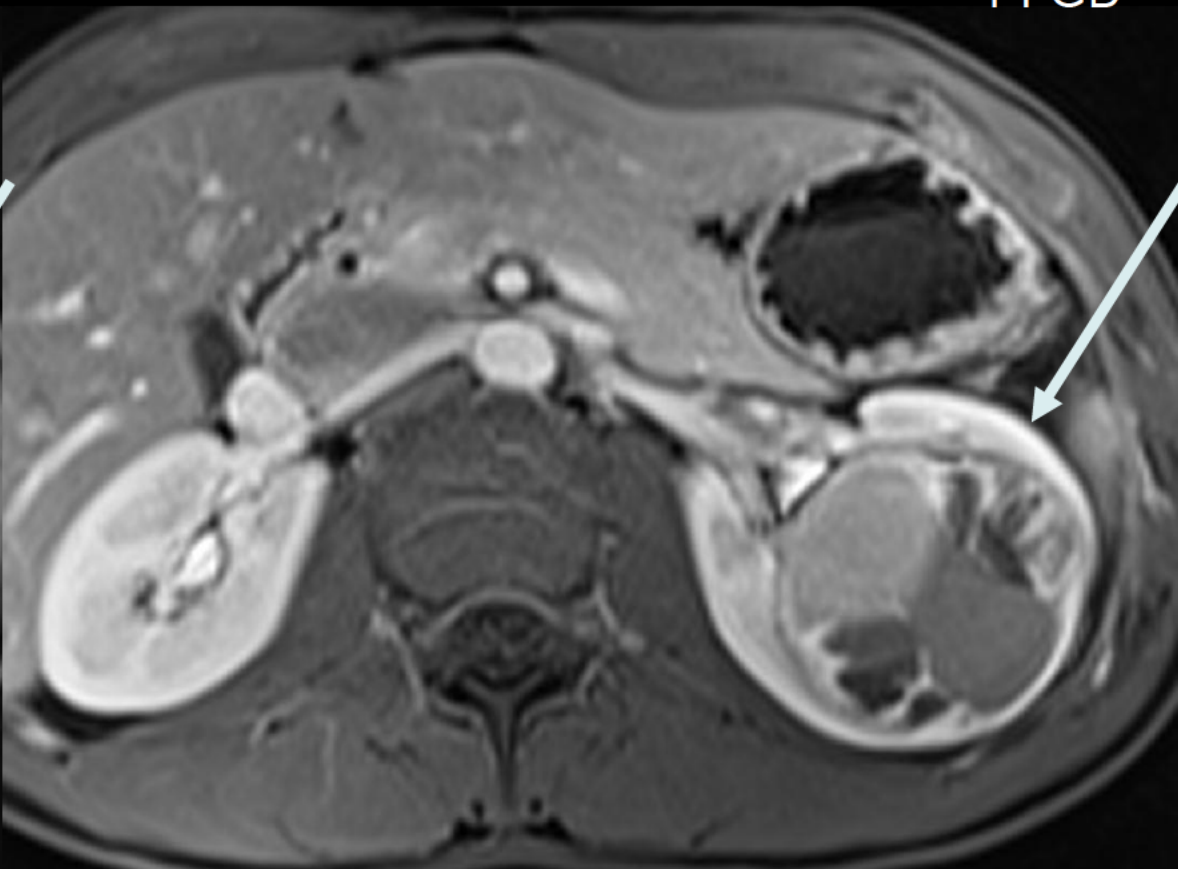
Clinical information

14-year-old male with no significant past medical history presented with 2 month history of abdominal pain, nausea, headaches and fatigue. He has had a 7 pound weight loss over the last month.

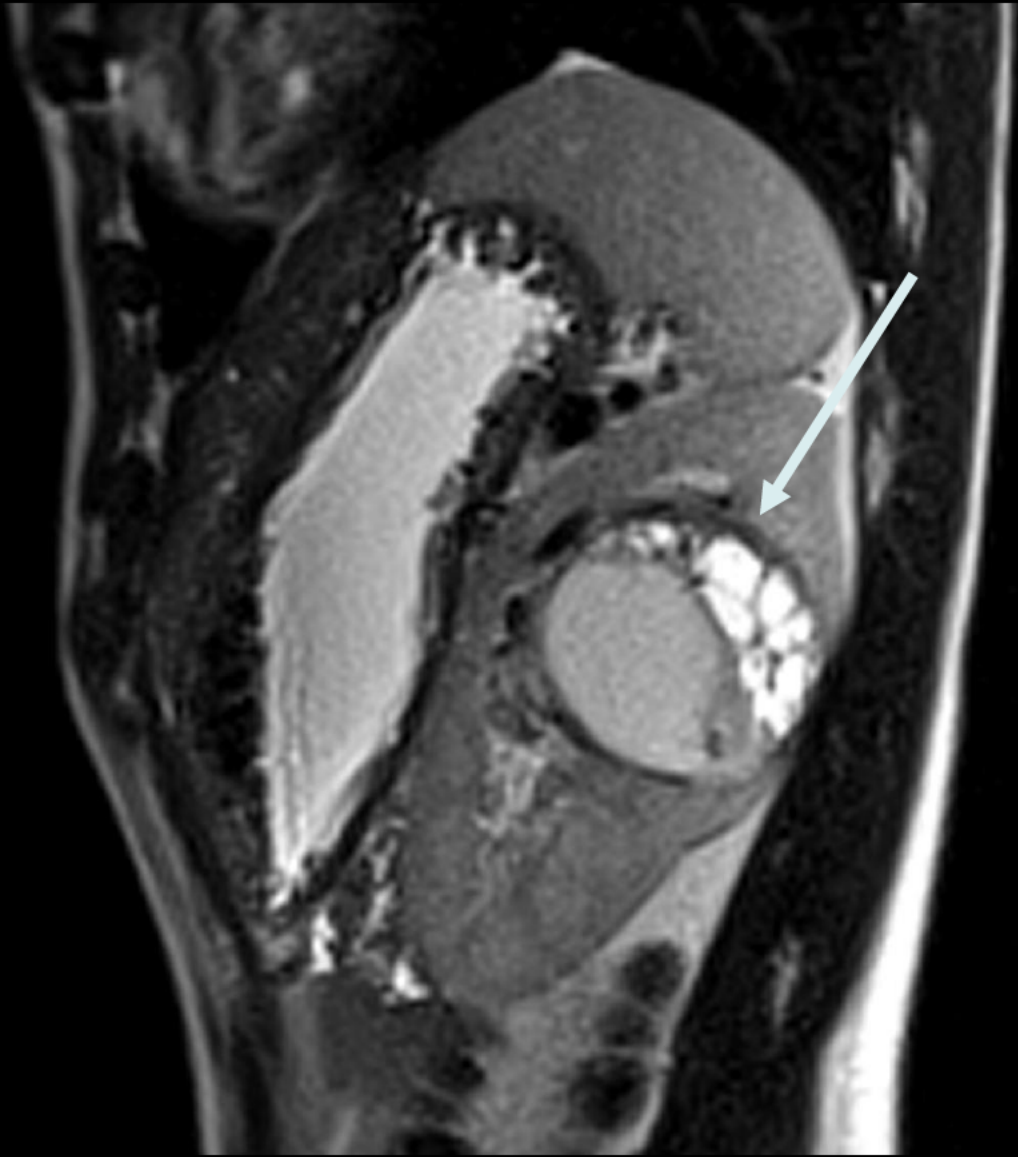T1



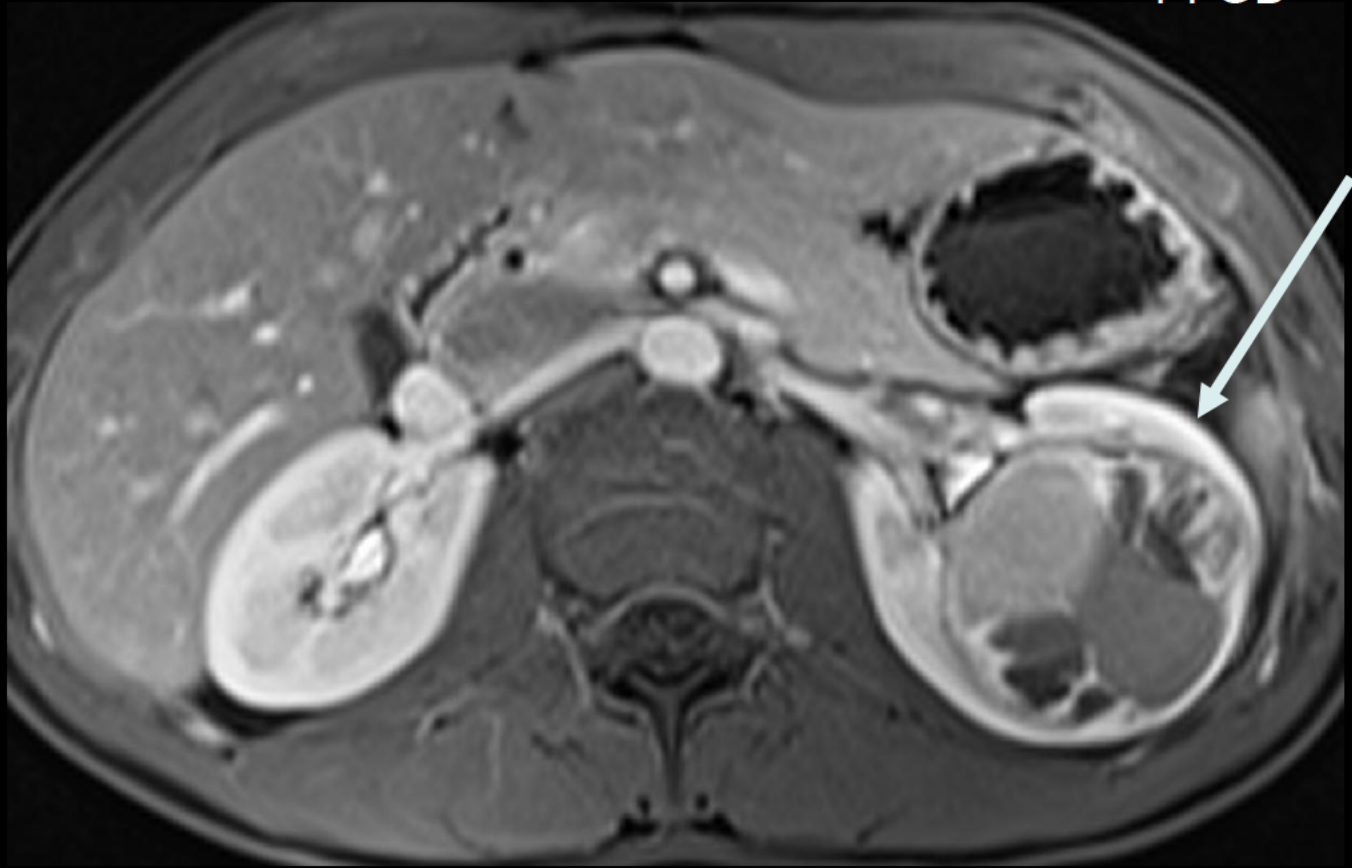
T1 GD



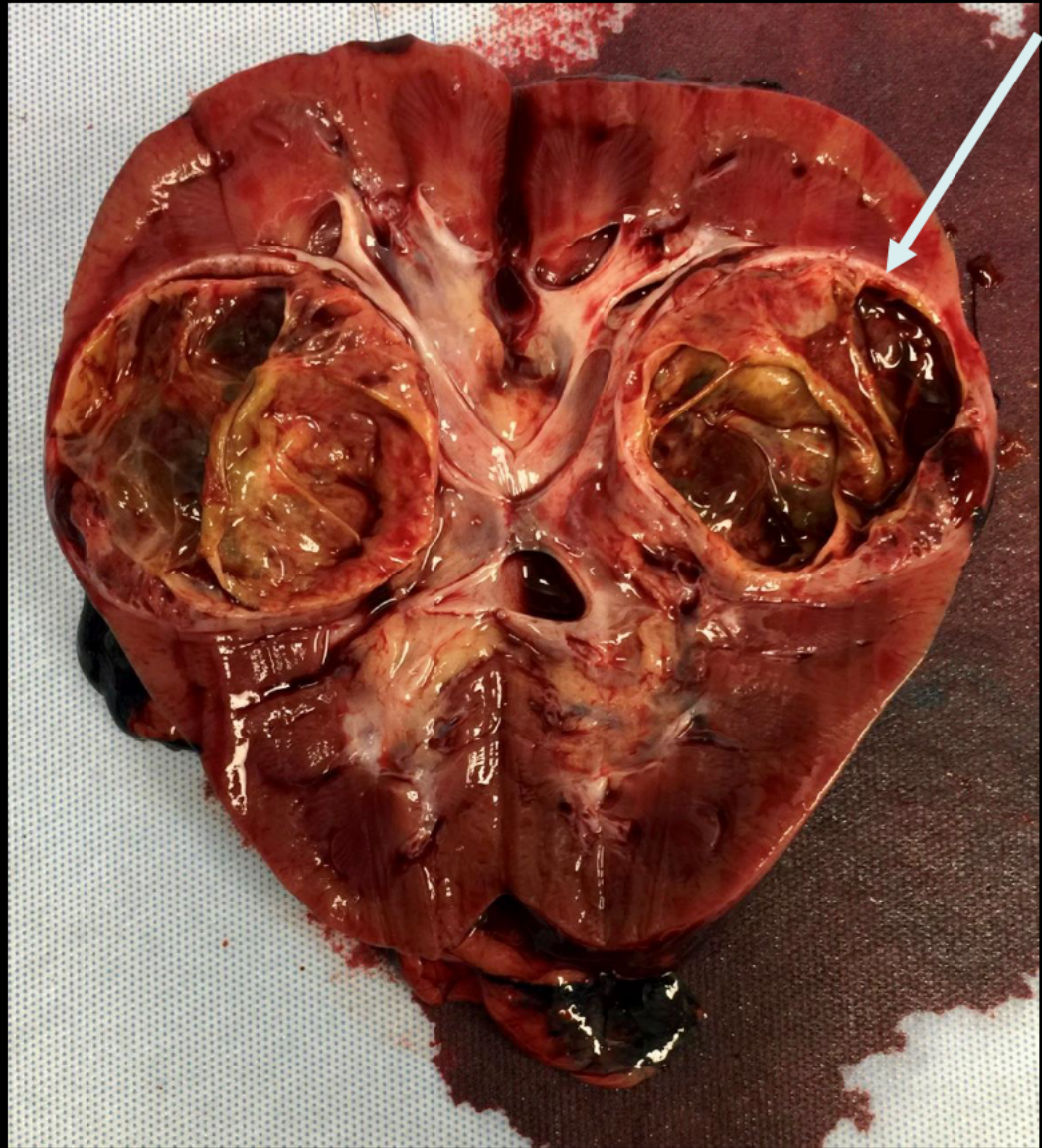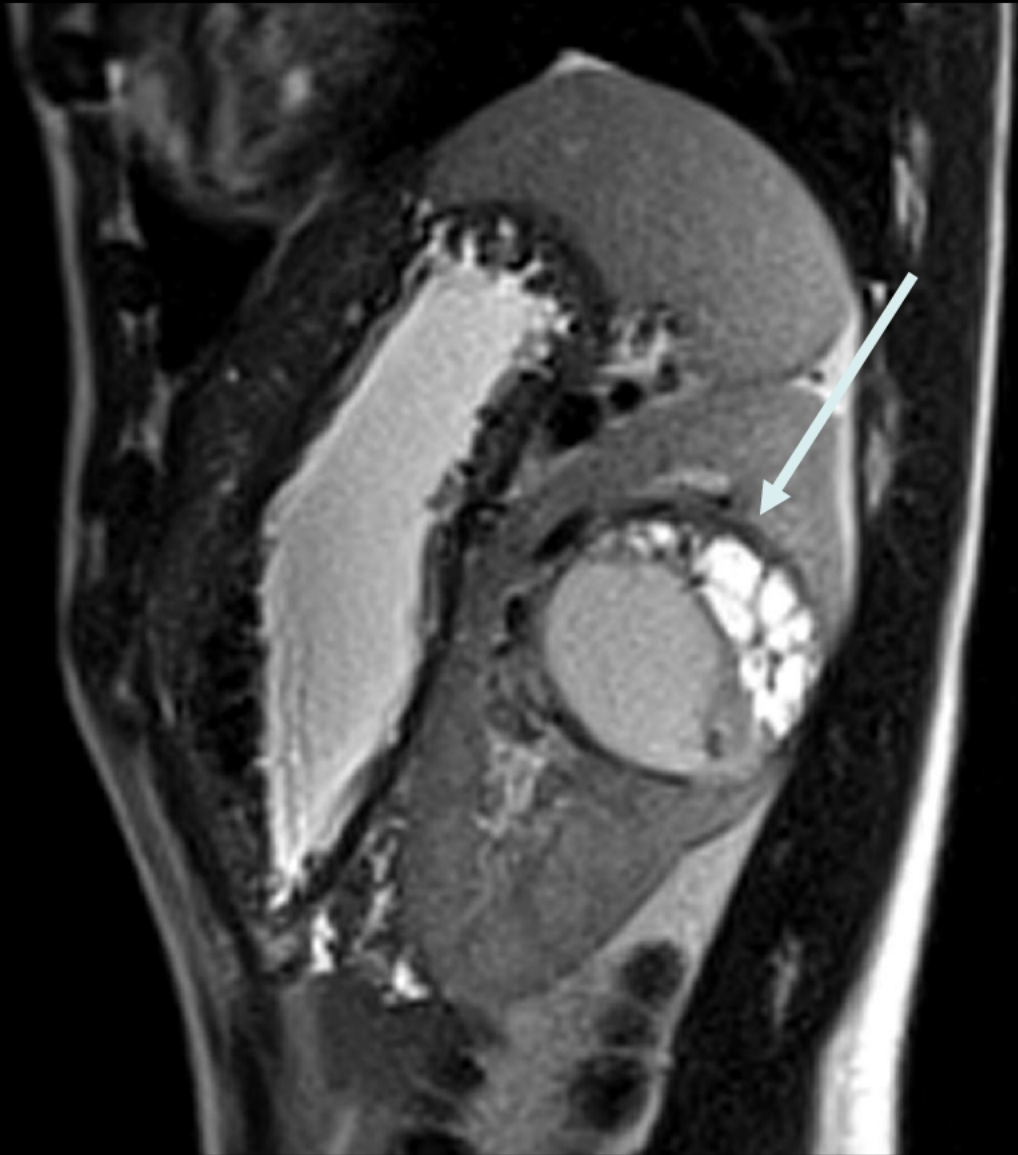T2

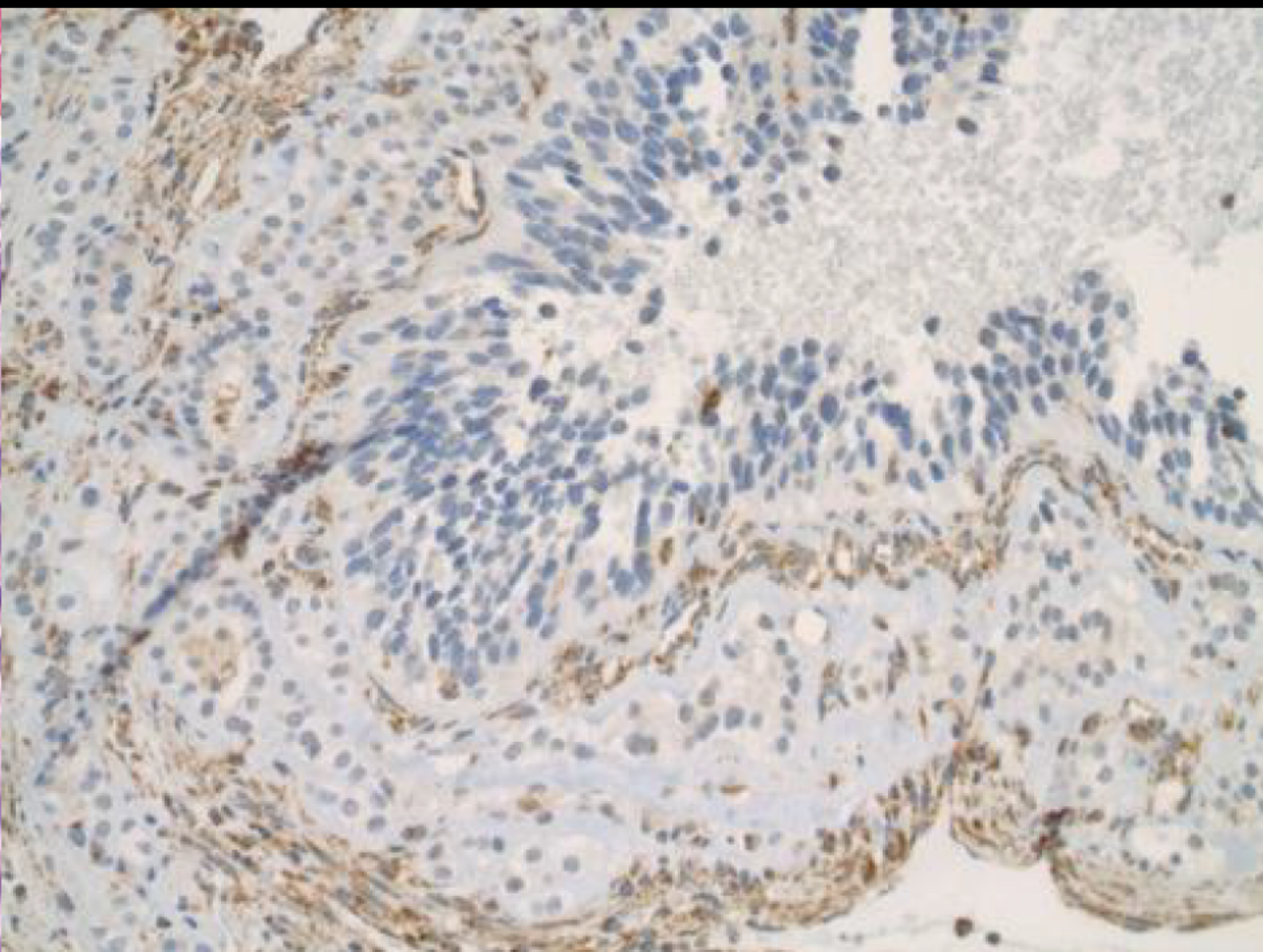
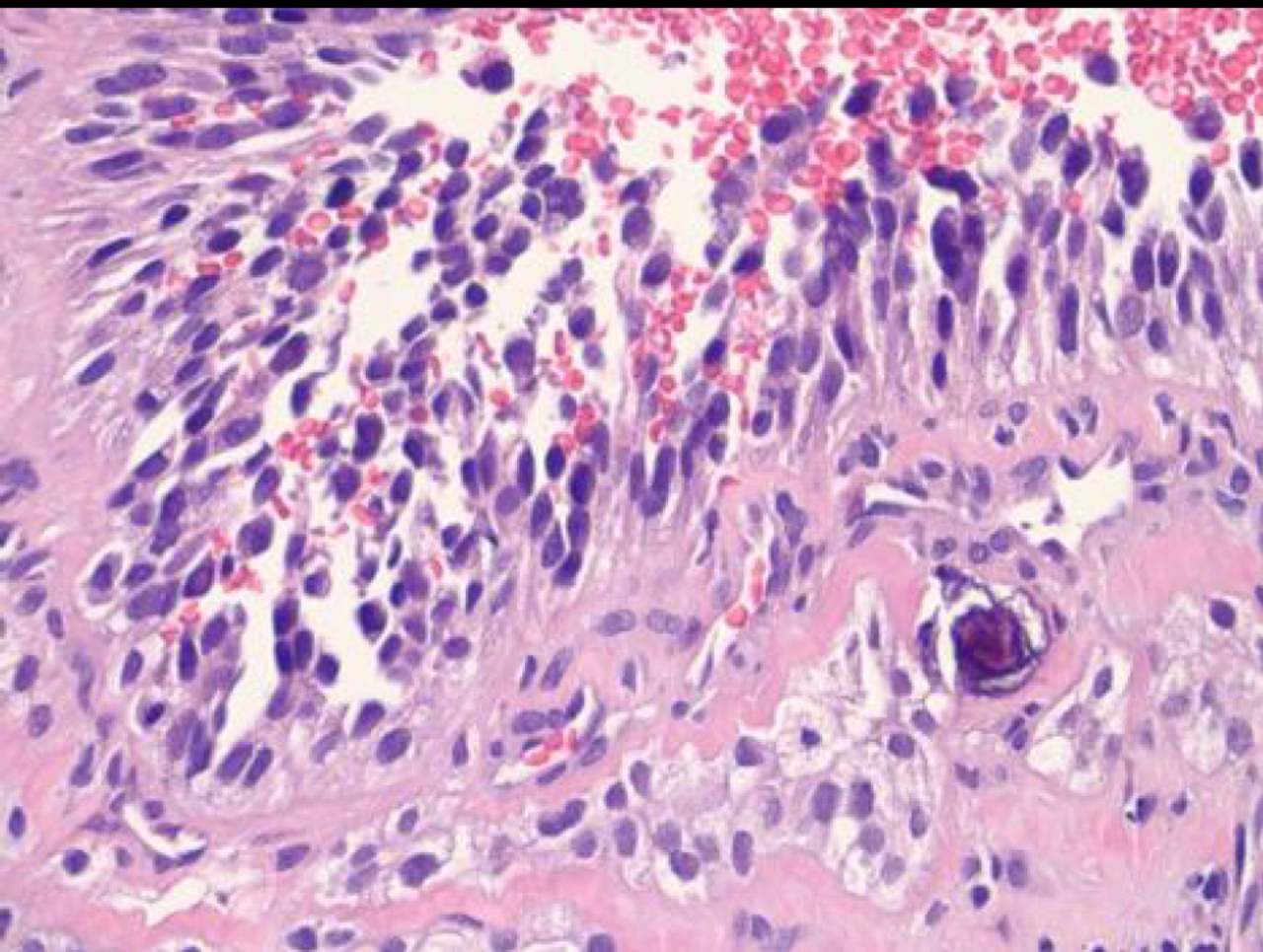


T1 GD



T2





Succinate Dehydrogenase Deficient Renal Cell Carcinoma

Atul Kumar

University of Connecticut

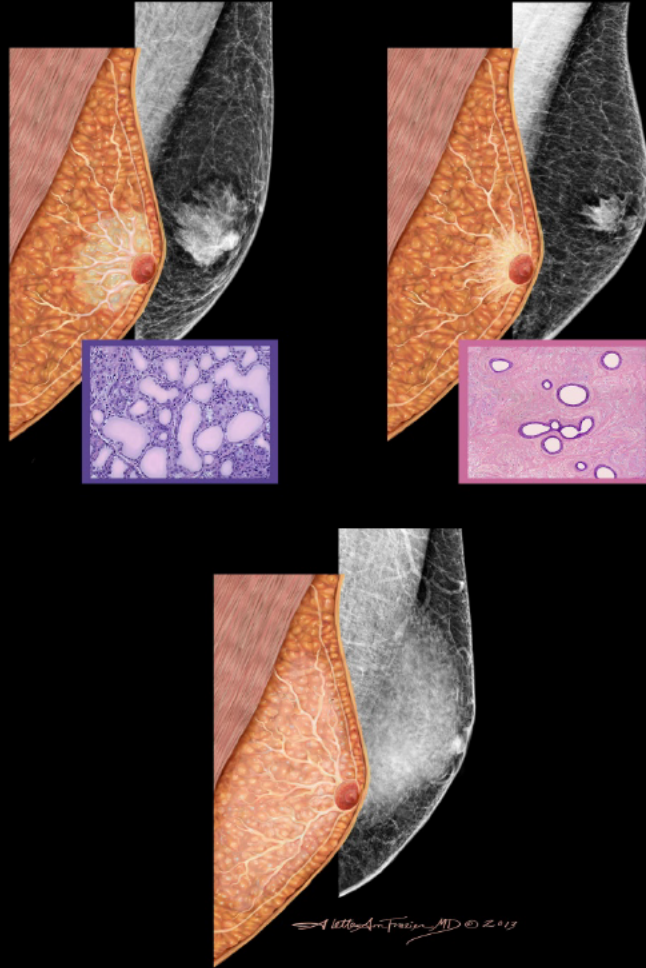
Hartford, CT



AMERICAN INSTITUTE FOR
RADIOLOGIC PATHOLOGY

A PROGRAM OF THE
AMERICAN COLLEGE OF RADIOLOGY

Breast Best Case



AIRPTM

AMERICAN INSTITUTE FOR
RADIOLOGIC PATHOLOGY

A PROGRAM OF THE
AMERICAN COLLEGE OF RADIOLOGY

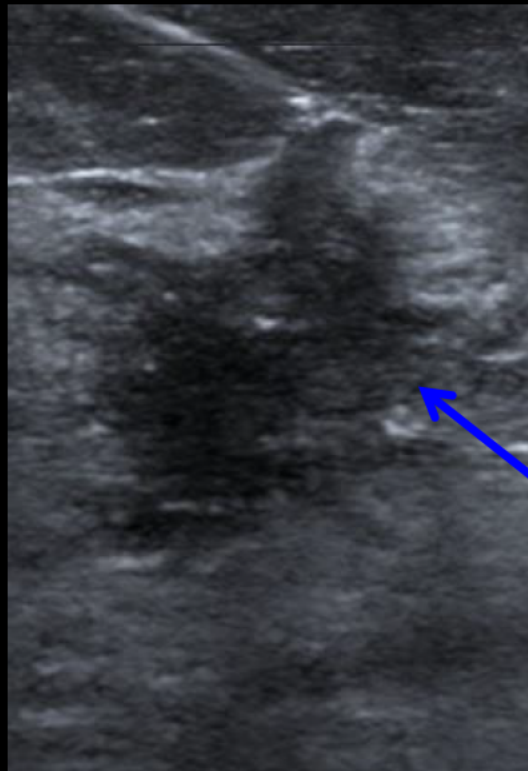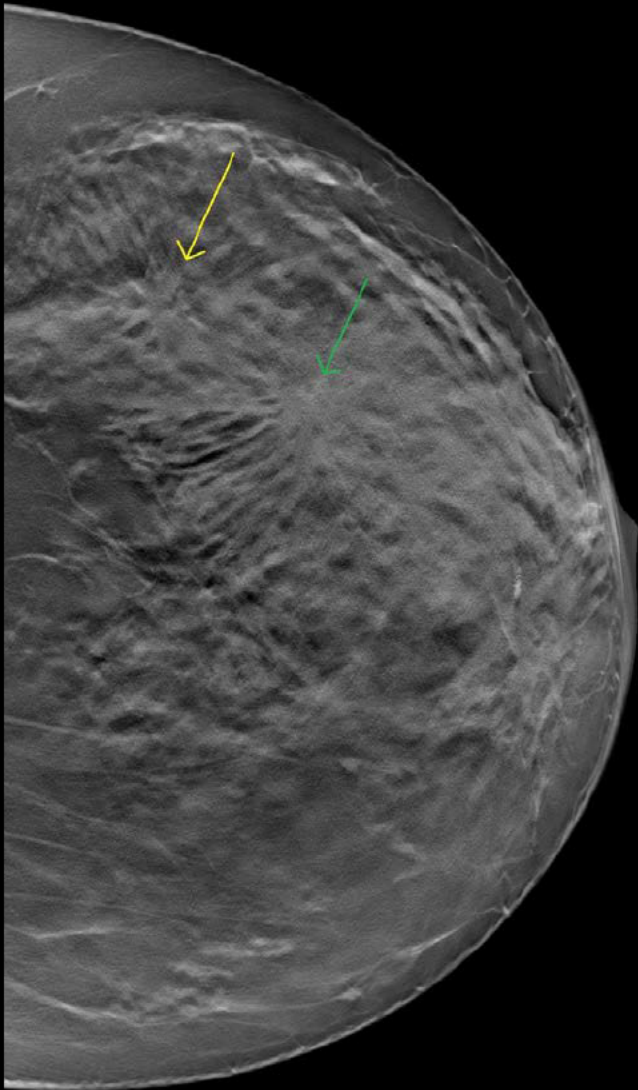
Clinical Information

**45-year-old female presented for routine
mammogram for breast cancer screening**

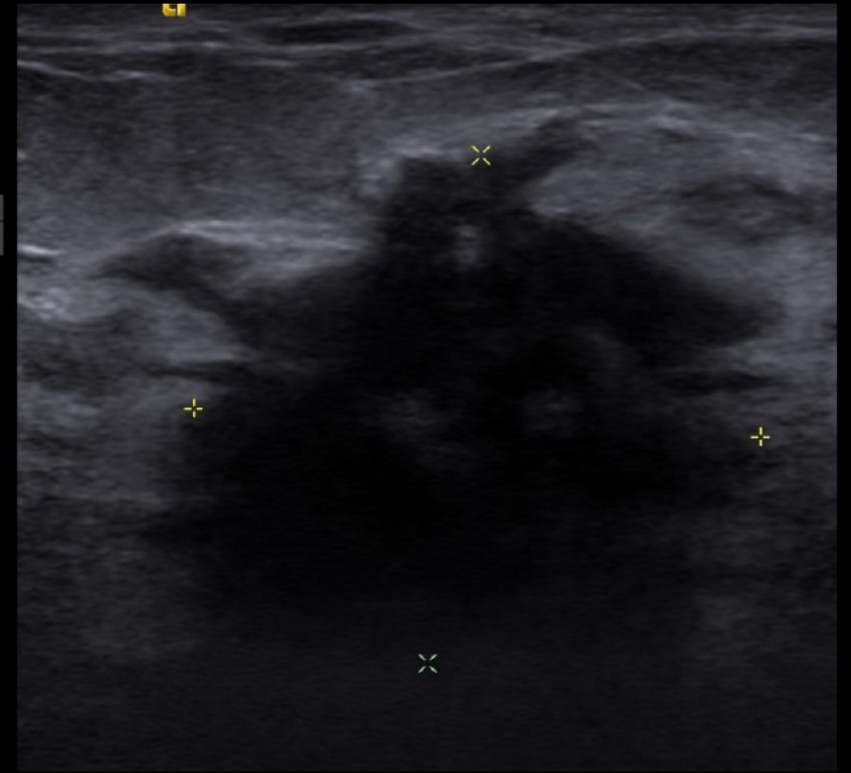


A PROGRAM OF THE
AMERICAN COLLEGE OF RADIOLOGY

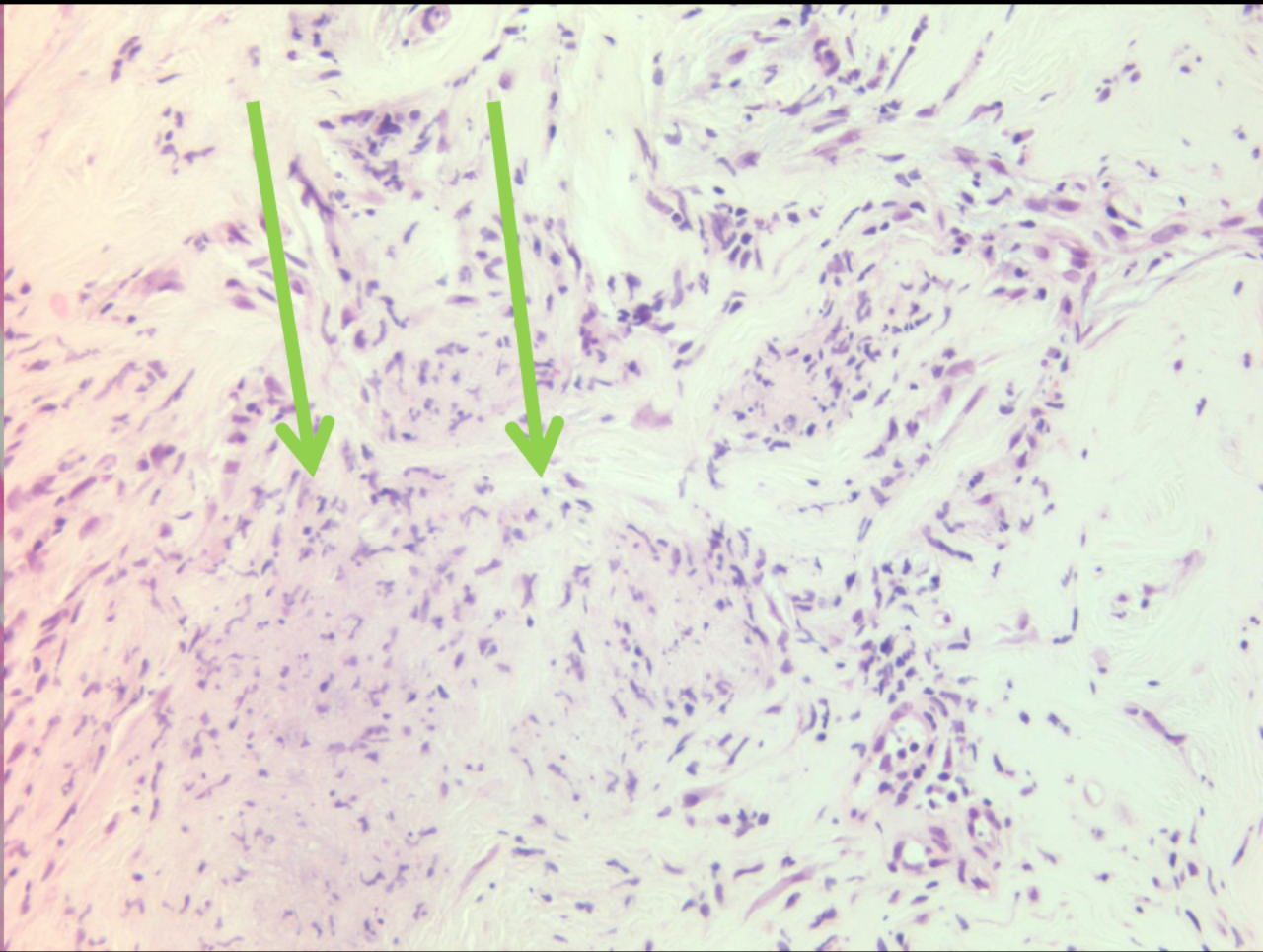
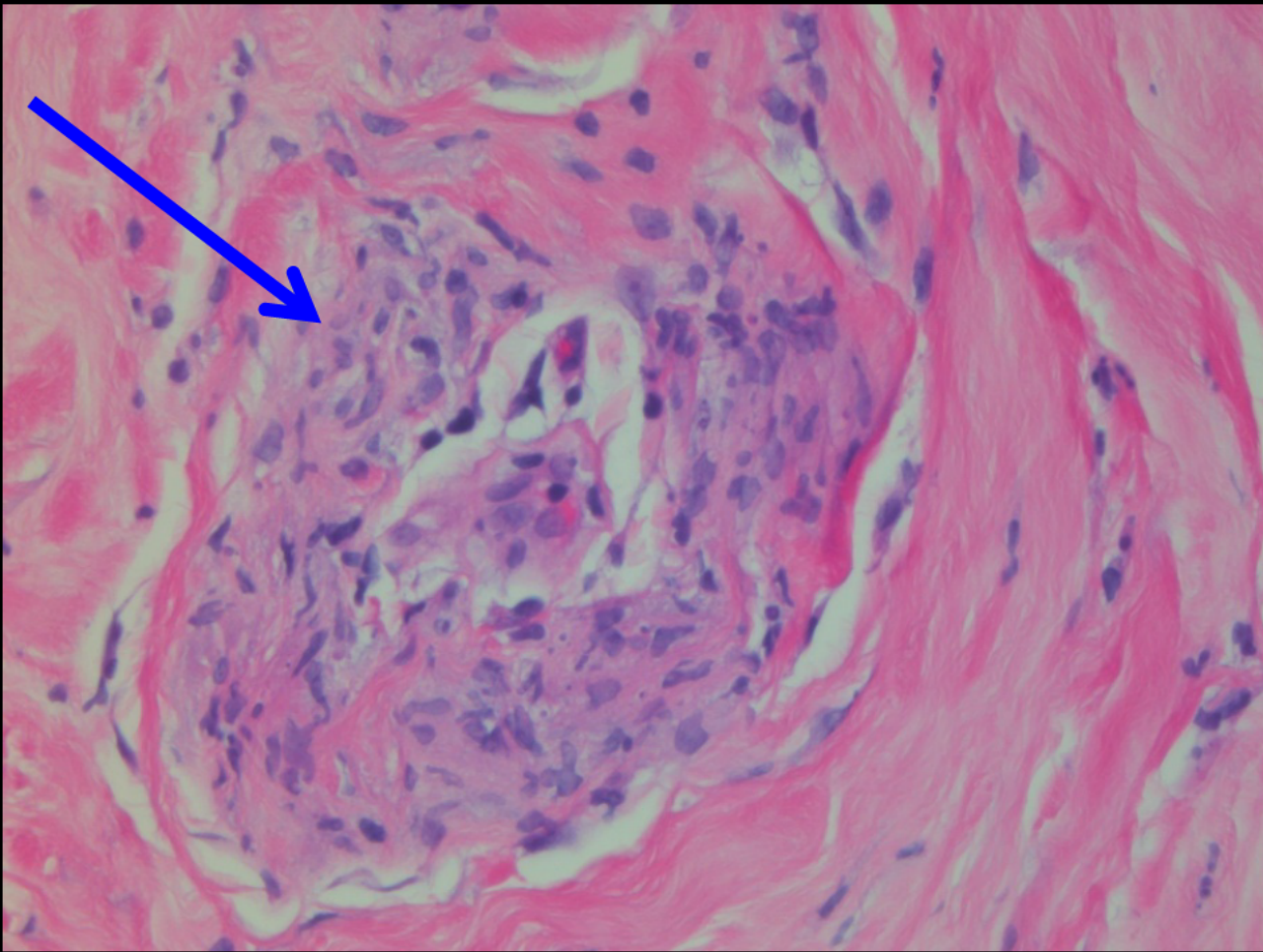
Mammogram and US



D=2.39 cm
D±2.15 cm



Histology



Granulomatosis with Polyangiitis (GPA)(“Wegeners”)

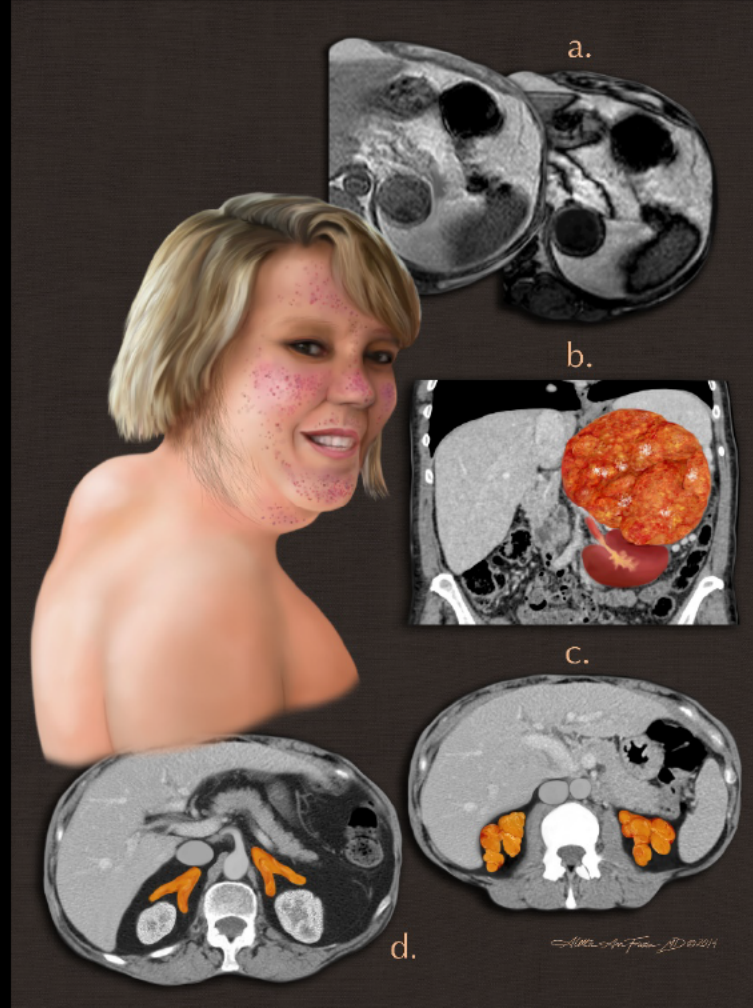Daniel Lee

Pennsylvania Hospital
Philadelphia, Pennsylvania

AIRPTM
AMERICAN INSTITUTE FOR
RADIOLOGIC PATHOLOGY

A PROGRAM OF THE
AMERICAN COLLEGE OF RADIOLOGY

Genitourinary Best Case



AIRPTM

AMERICAN INSTITUTE FOR
RADIOLOGIC PATHOLOGY

A PROGRAM OF THE
AMERICAN COLLEGE OF RADIOLOGY

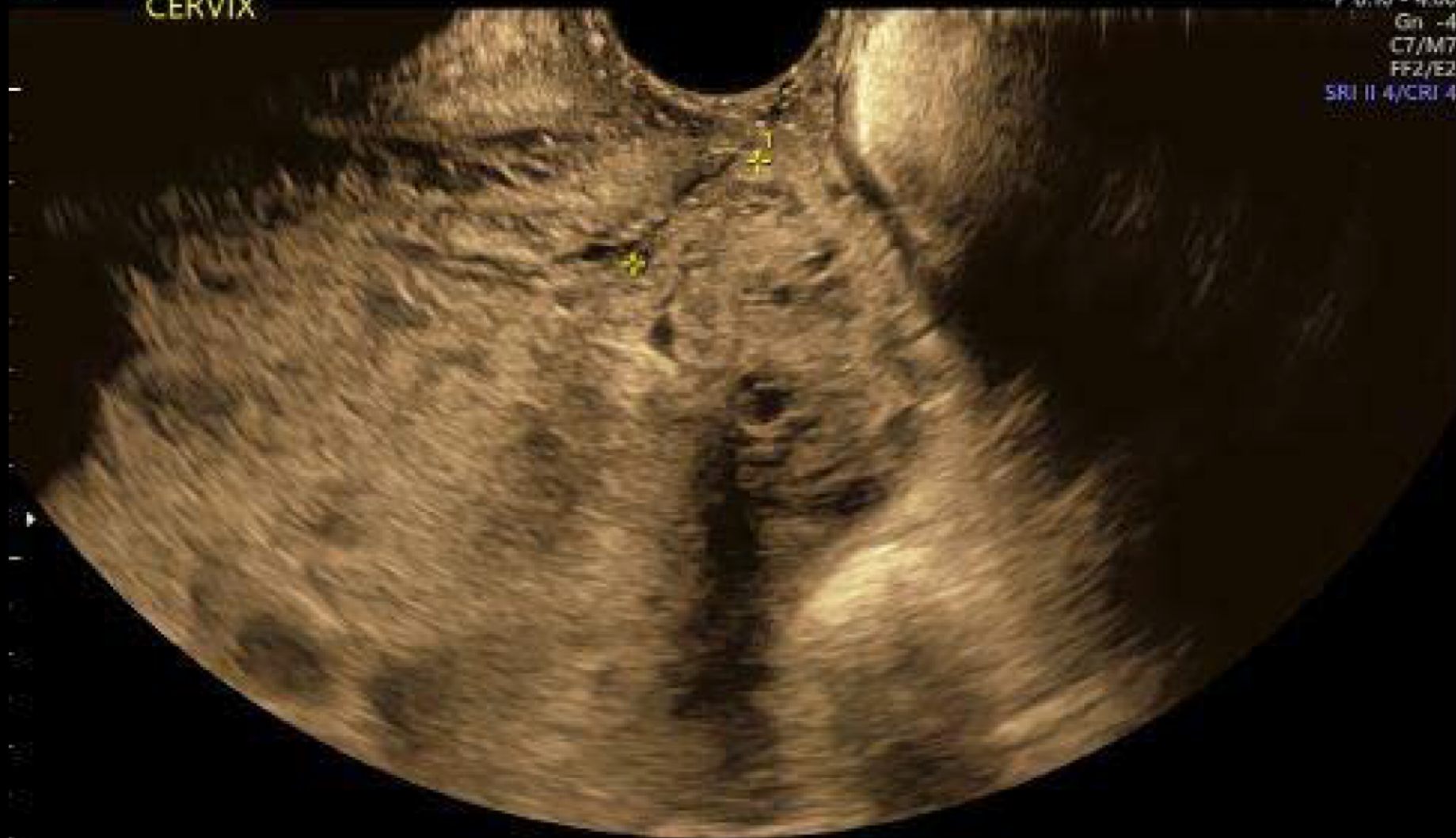Clinical Information

**31 year old with multiple prior cesarean sections
presents with vaginal bleeding during the 2nd
trimester of her current pregnancy**

Volume
E20

CERVIX

180°/1.3
Penetration/OB
P 8.10 - 4.00
Gn -4
C7/M7
FF2/E2
SRI II 4/CRI 4




1 D 1.72cm

Video
E2D

CERVIX

Internal Cervical os




180°/L3
Penetration/OB
P 8.10 - 4.00
Gn -4
C7/M7
FF2/E2
SRI II 4/CRI 4

1 D 1.72cm

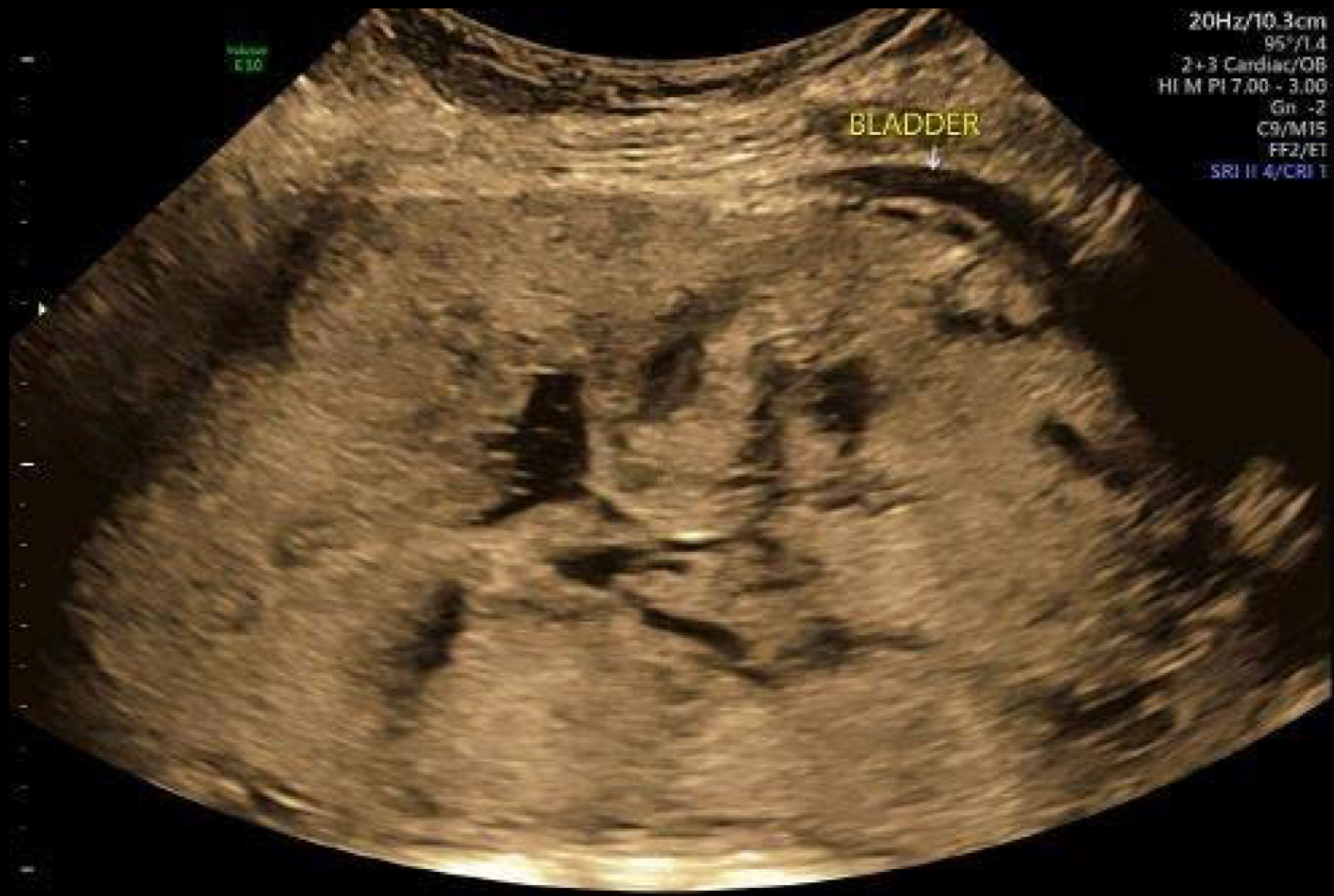180°/1.3
Penetration/08
P 8.10 - 4.00
Gn -4
C7/M7
FF2/E2
SRI II 4/CRI 4

CERVIX

Internal Cervical os

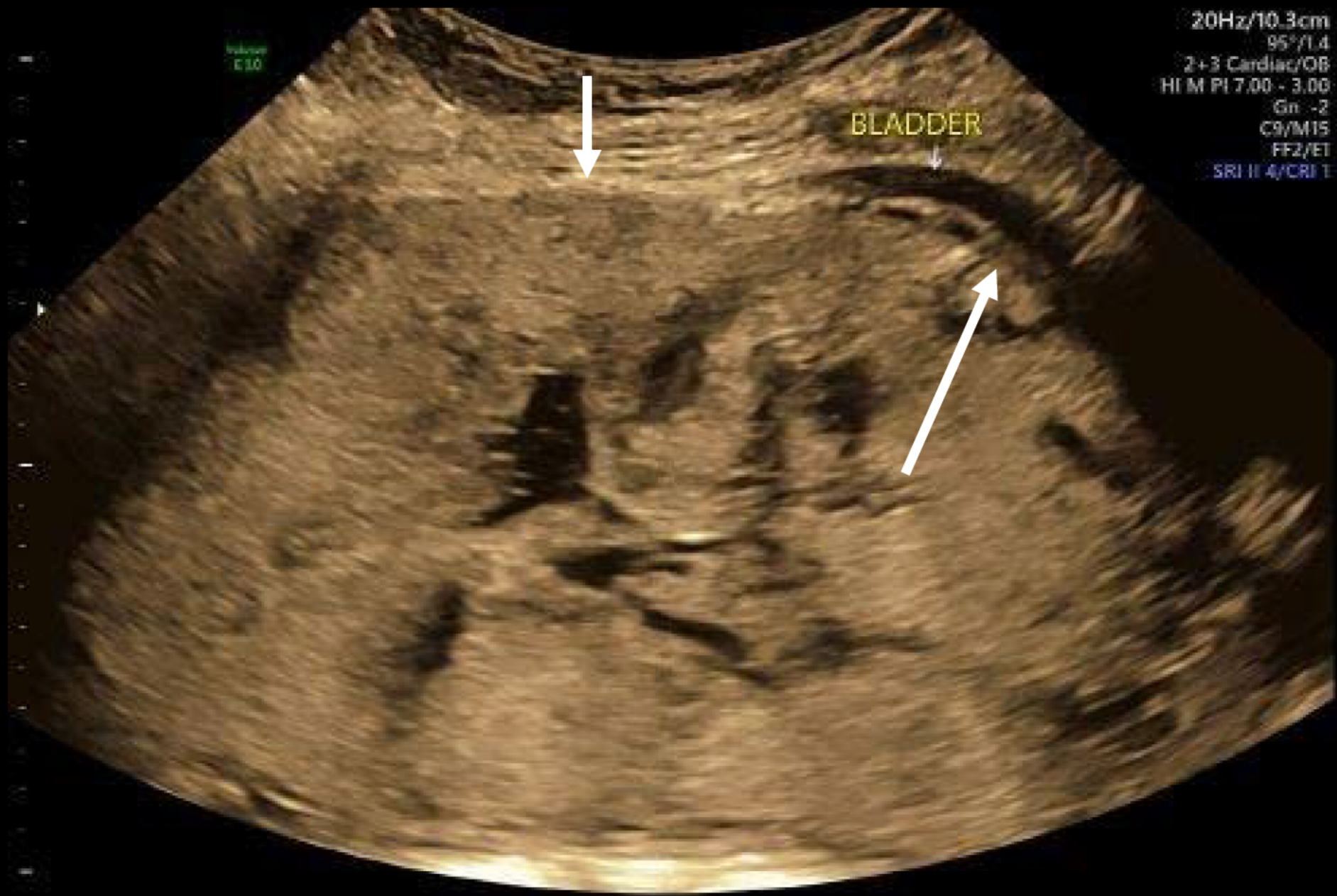

1 D 1.72cm



20Hz/10.3cm
95°/1.4
2+3 Cardiac/OB
HI M PI 7.00 - 3.00
Gn -2
C9/M15
FF2/ET
SRI II 4/CRI 1

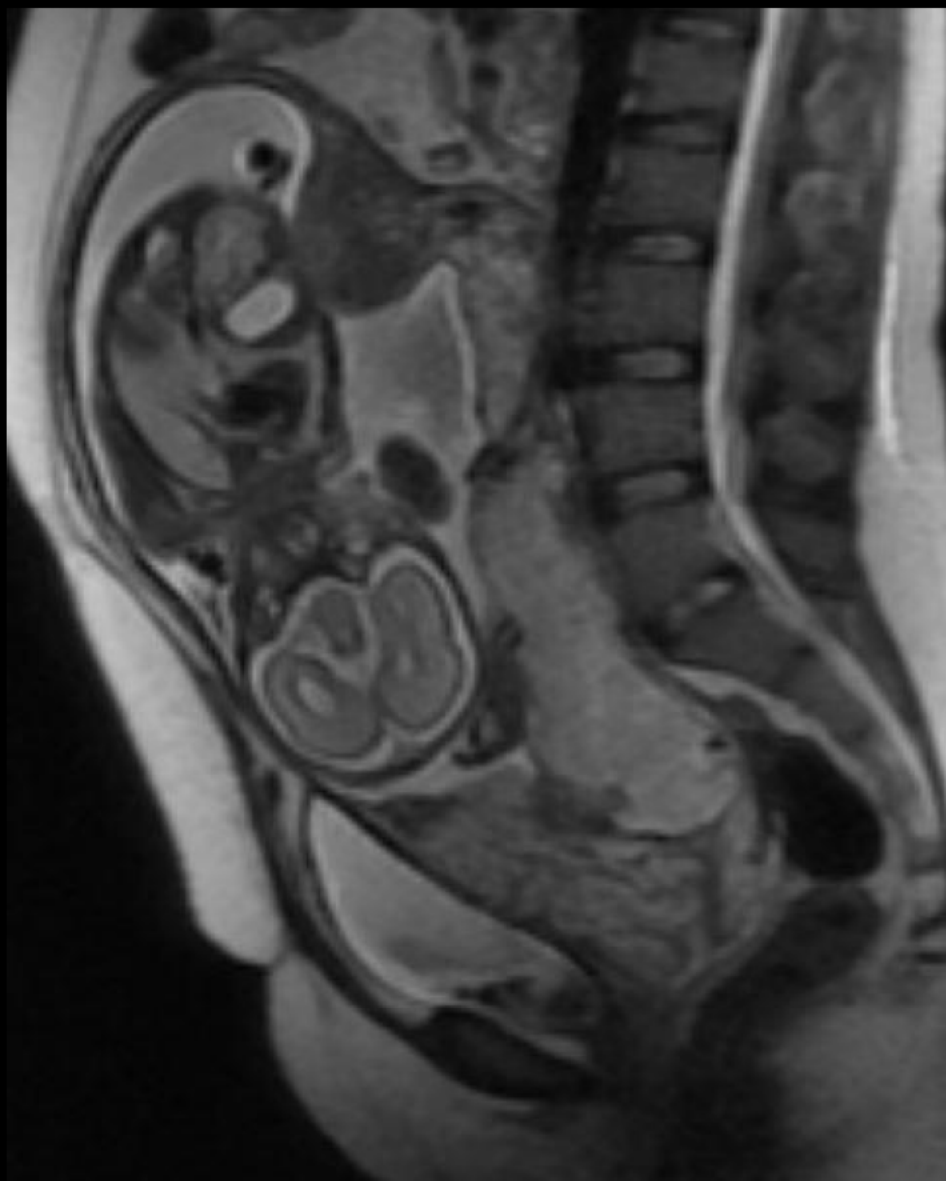
Volume
C10



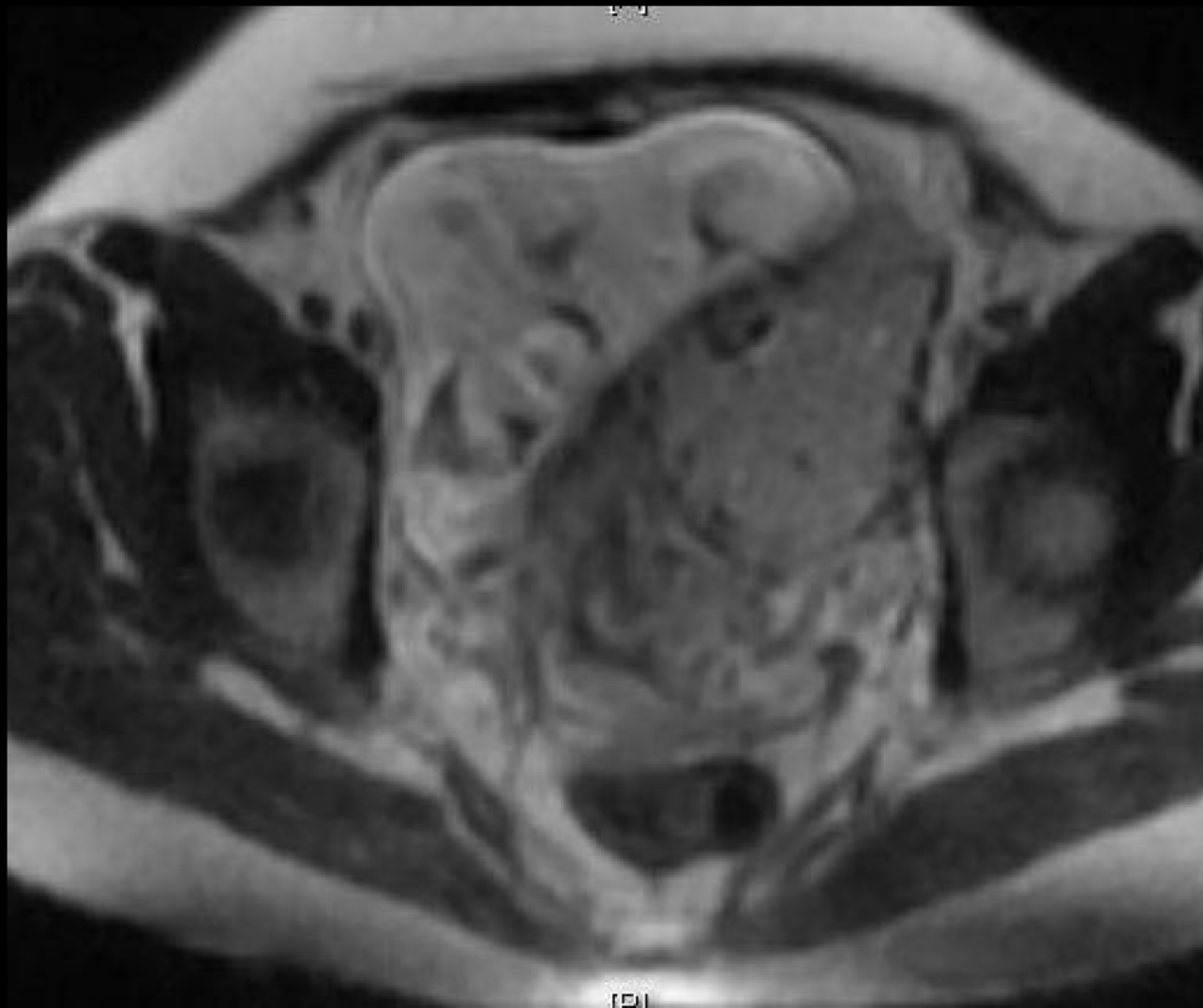
20Hz/10.3cm
95°/1.4
2+3 Cardiac/OB
HI M PI 7.00 - 3.00
Gn -2
C9/M15
FF2/ET
SRI II 4/CRI 1

BLADDER

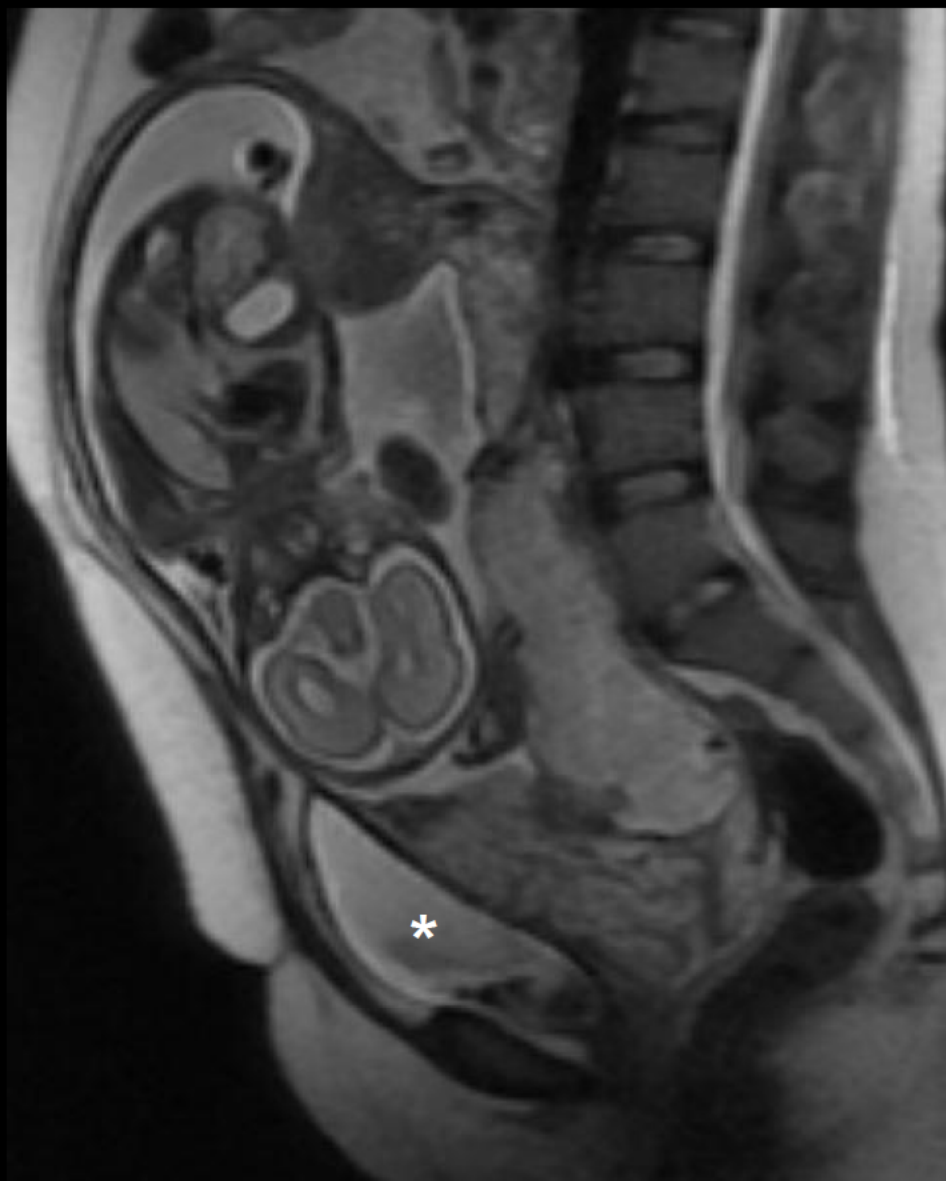
Volume
C10



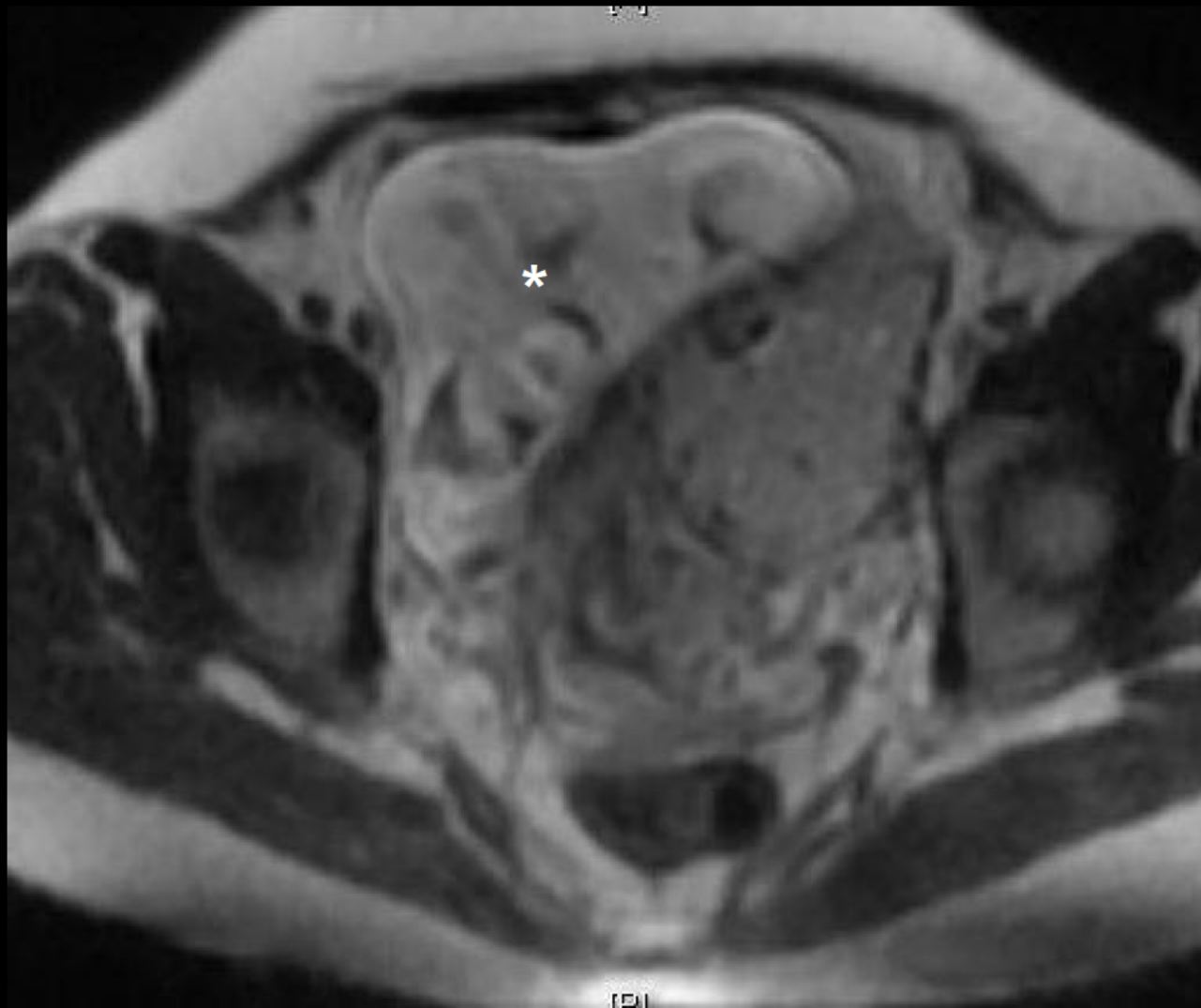
Sagittal T2



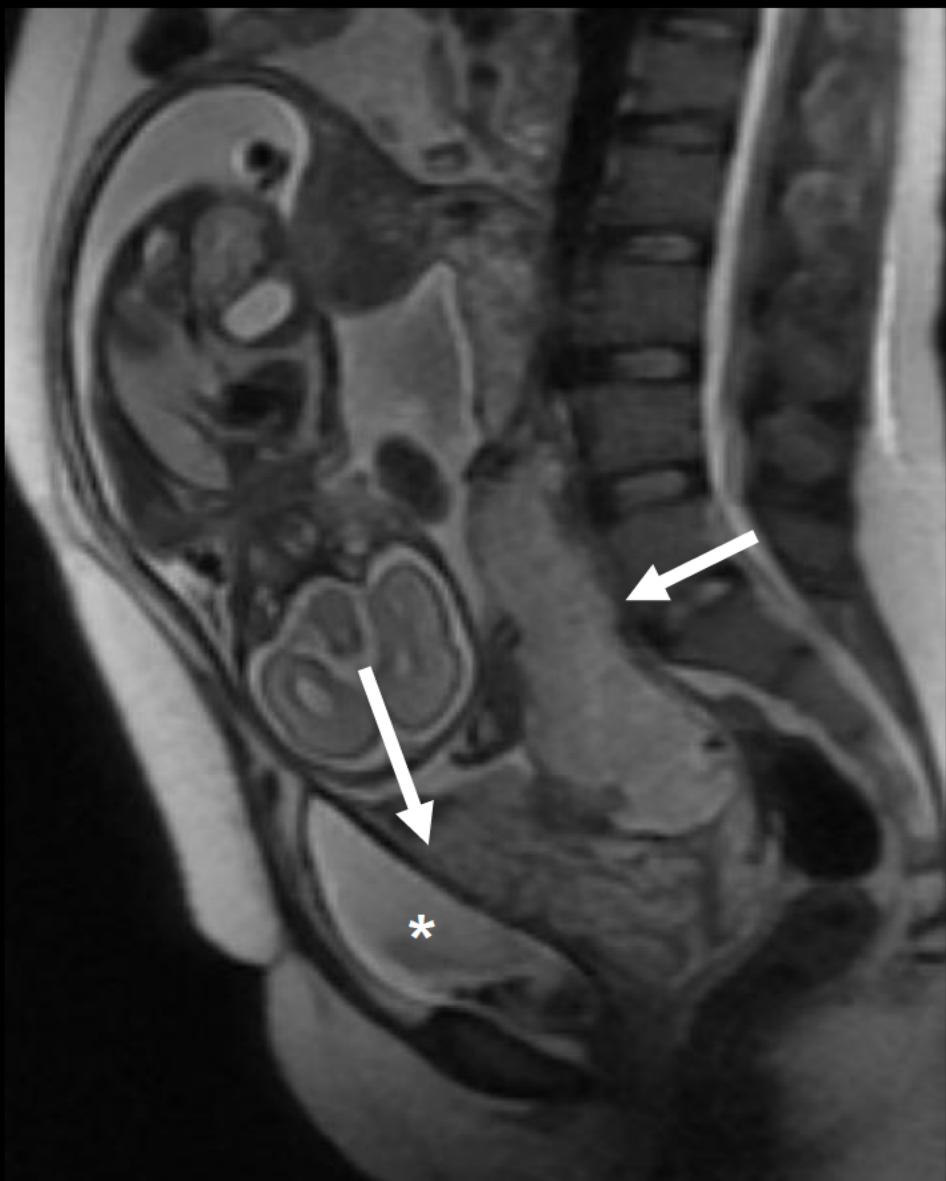
Axial T2



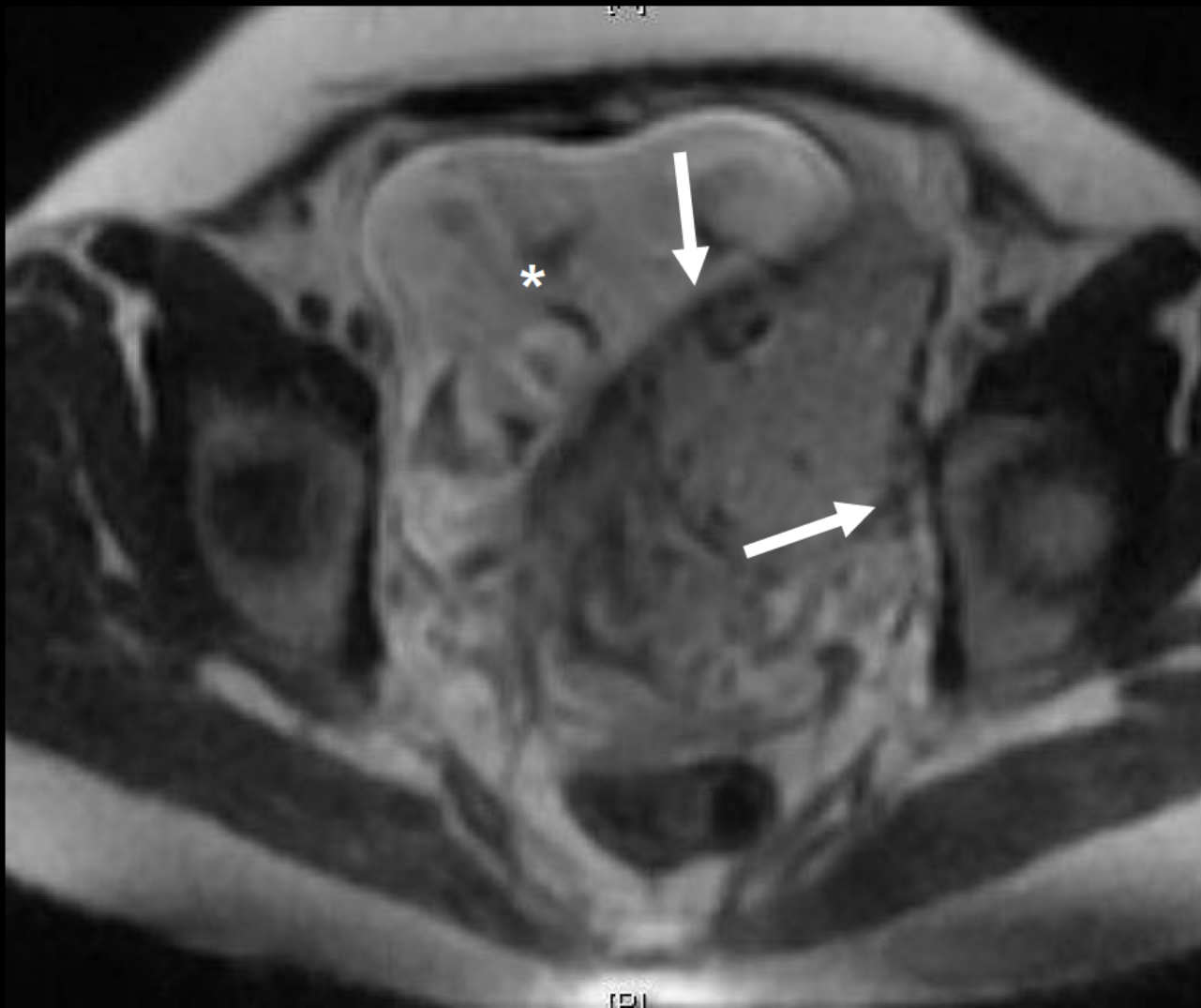
Sagittal T2



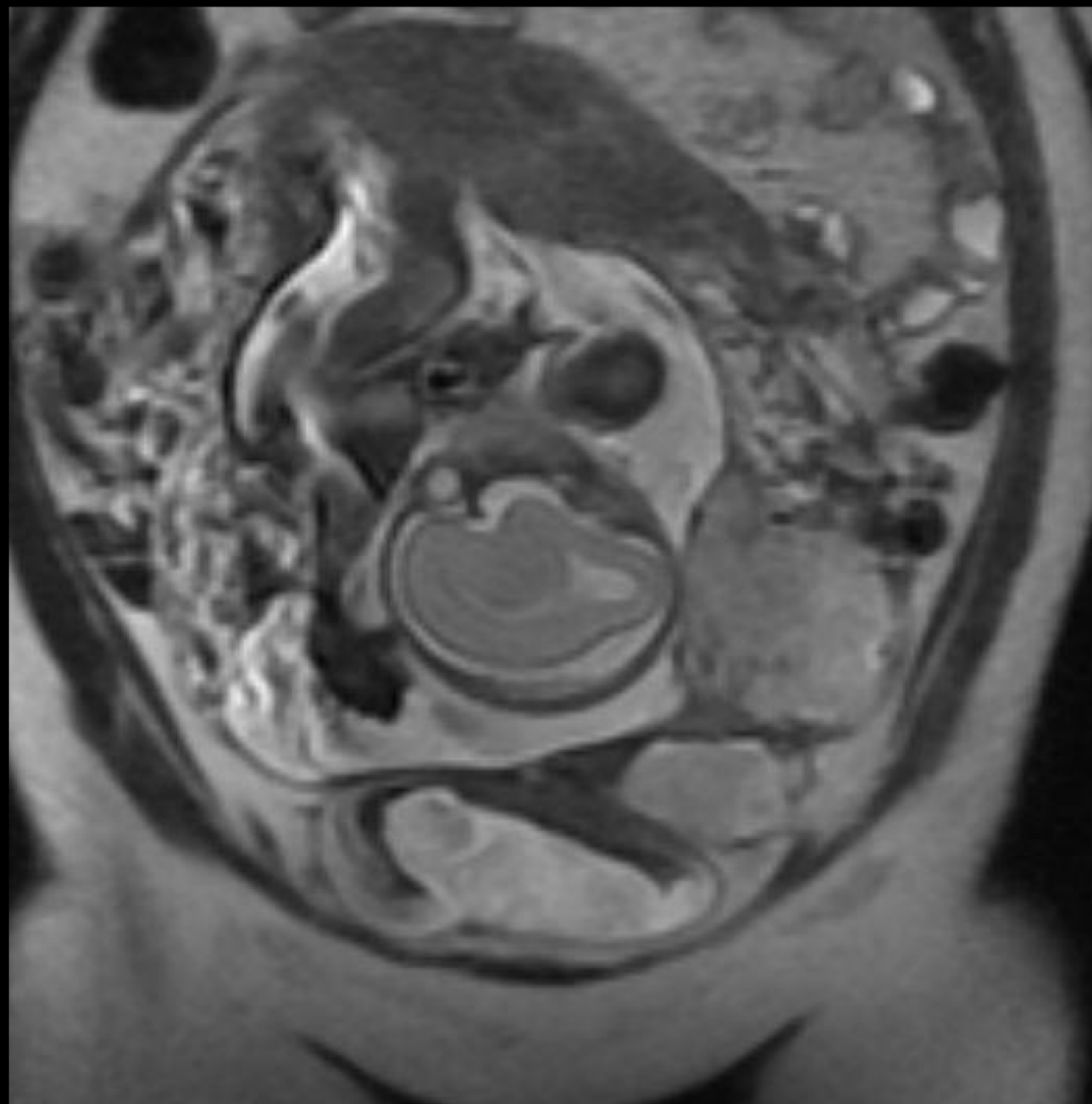
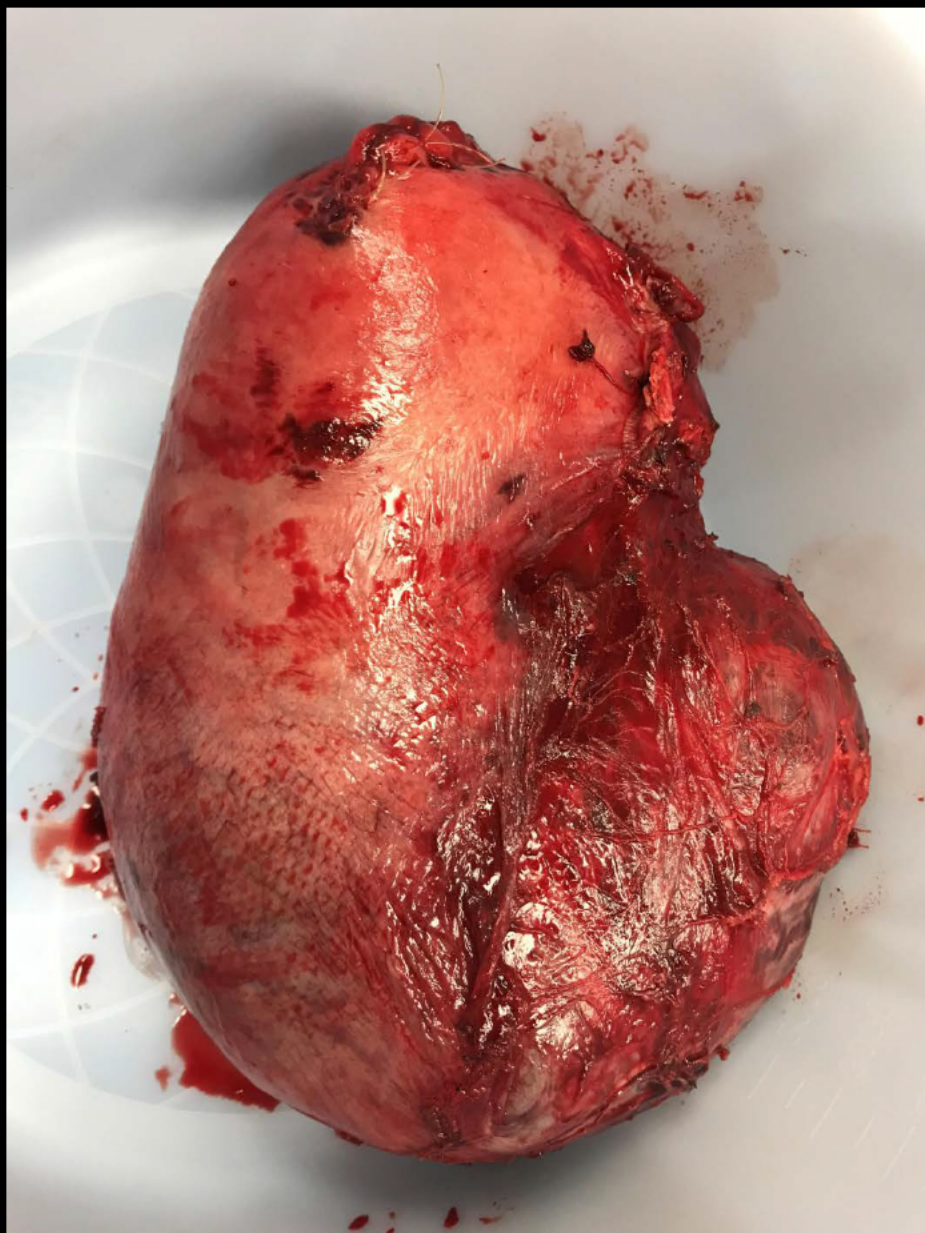Axial T2

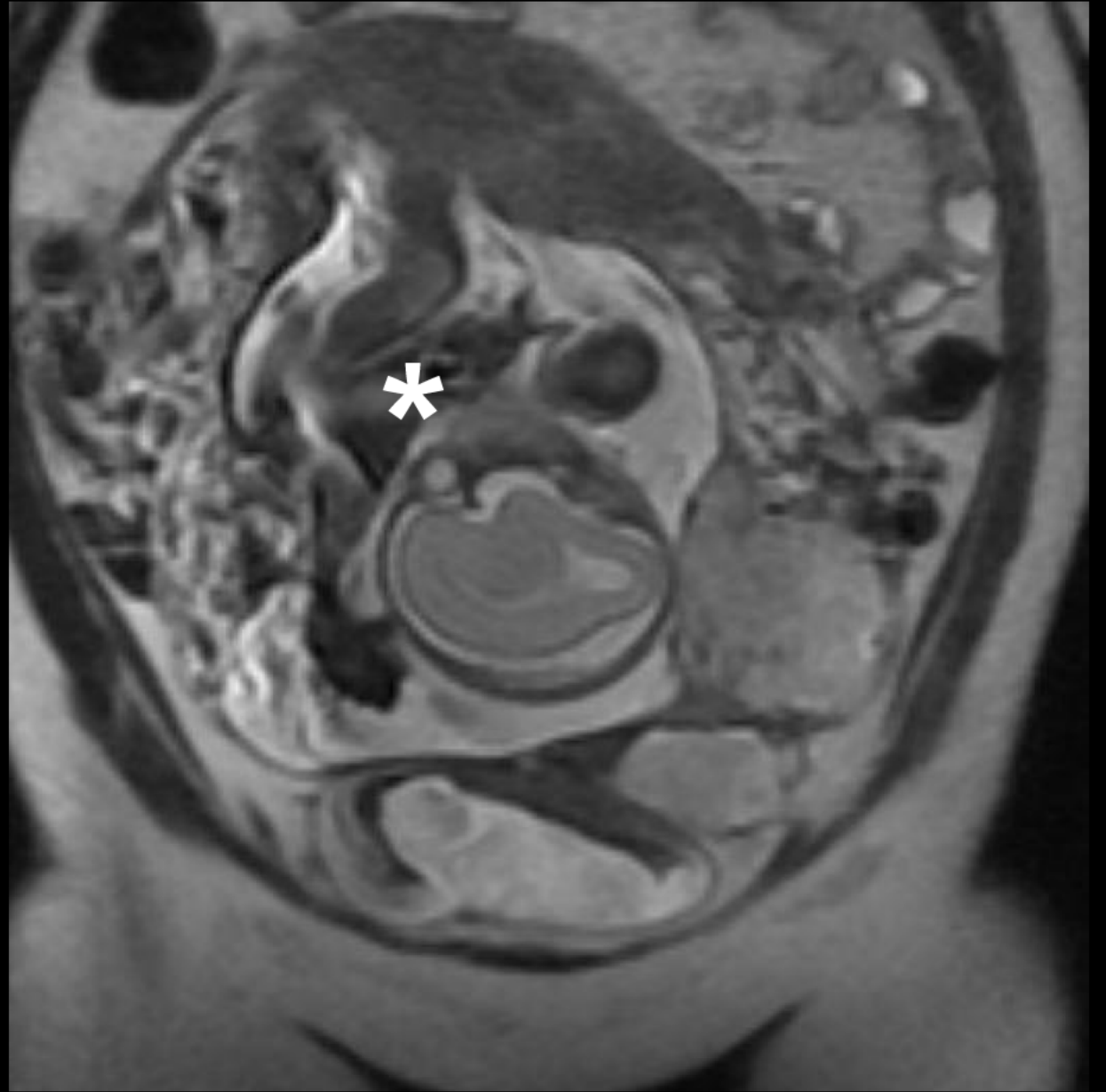
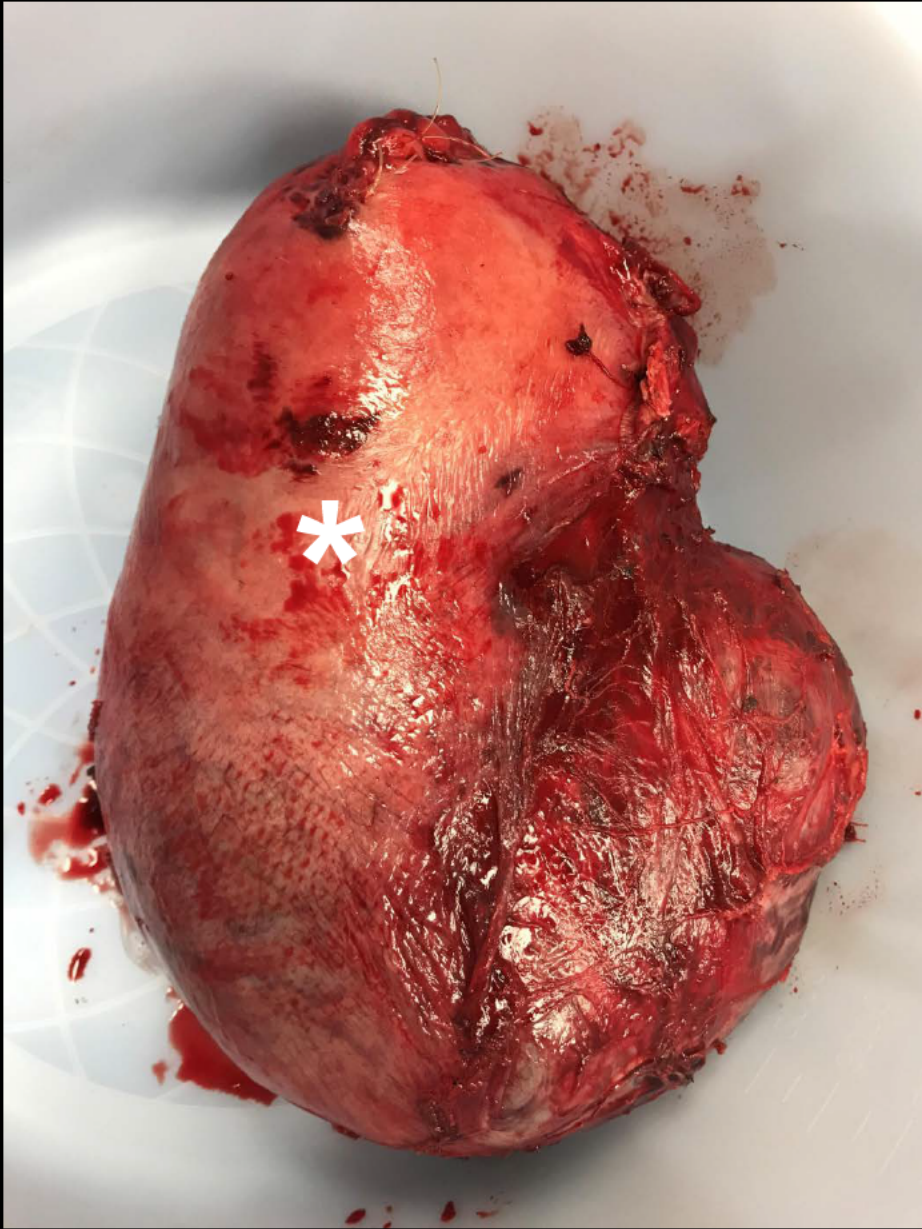

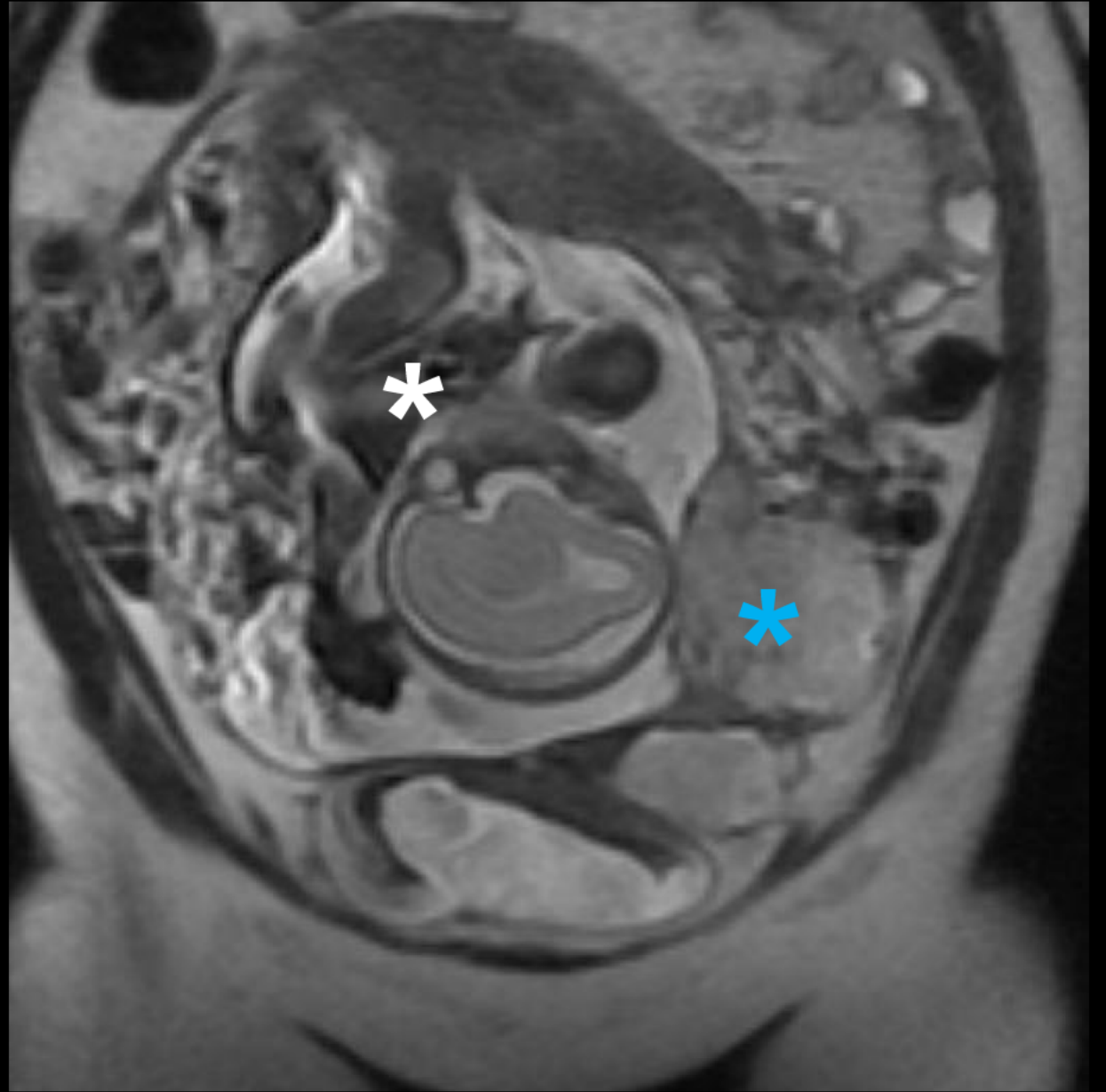
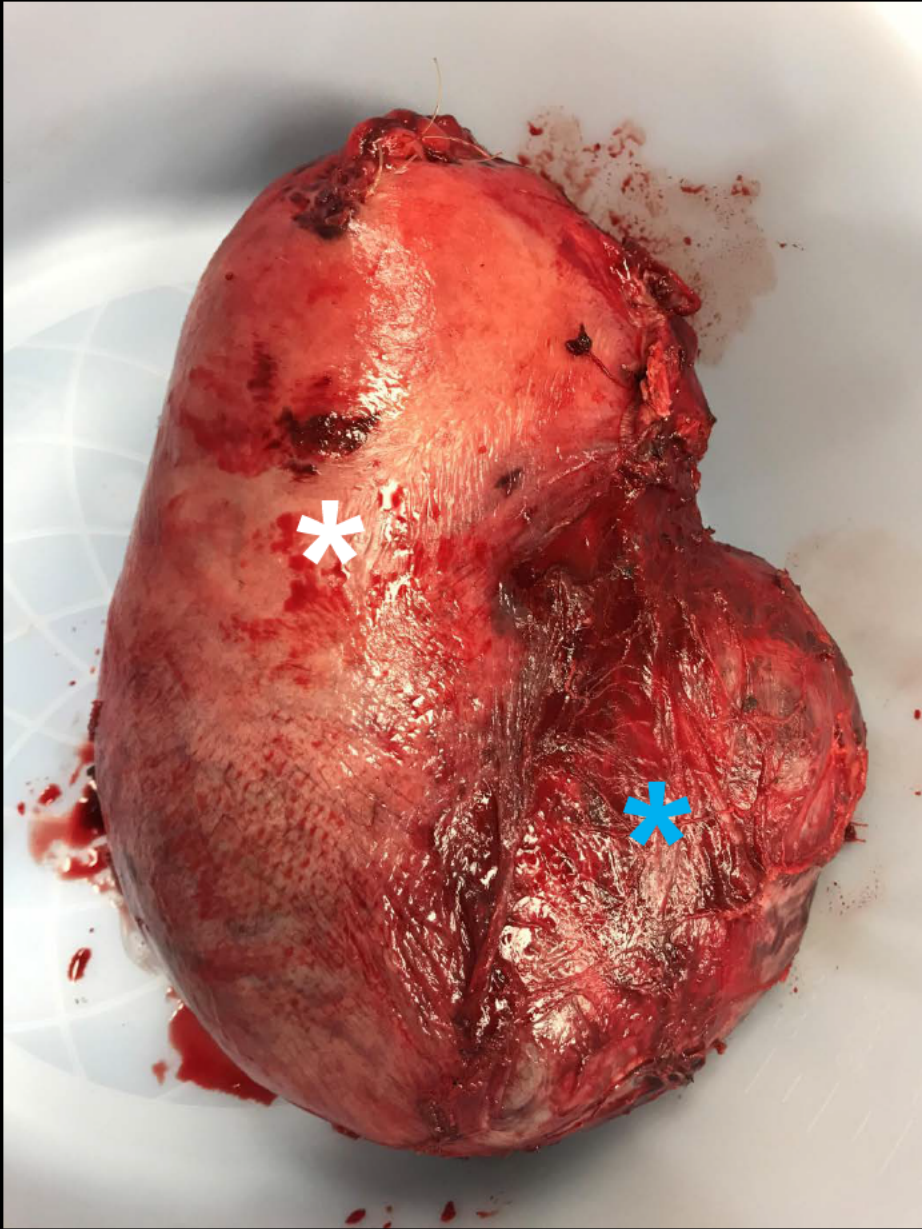Sagittal T2

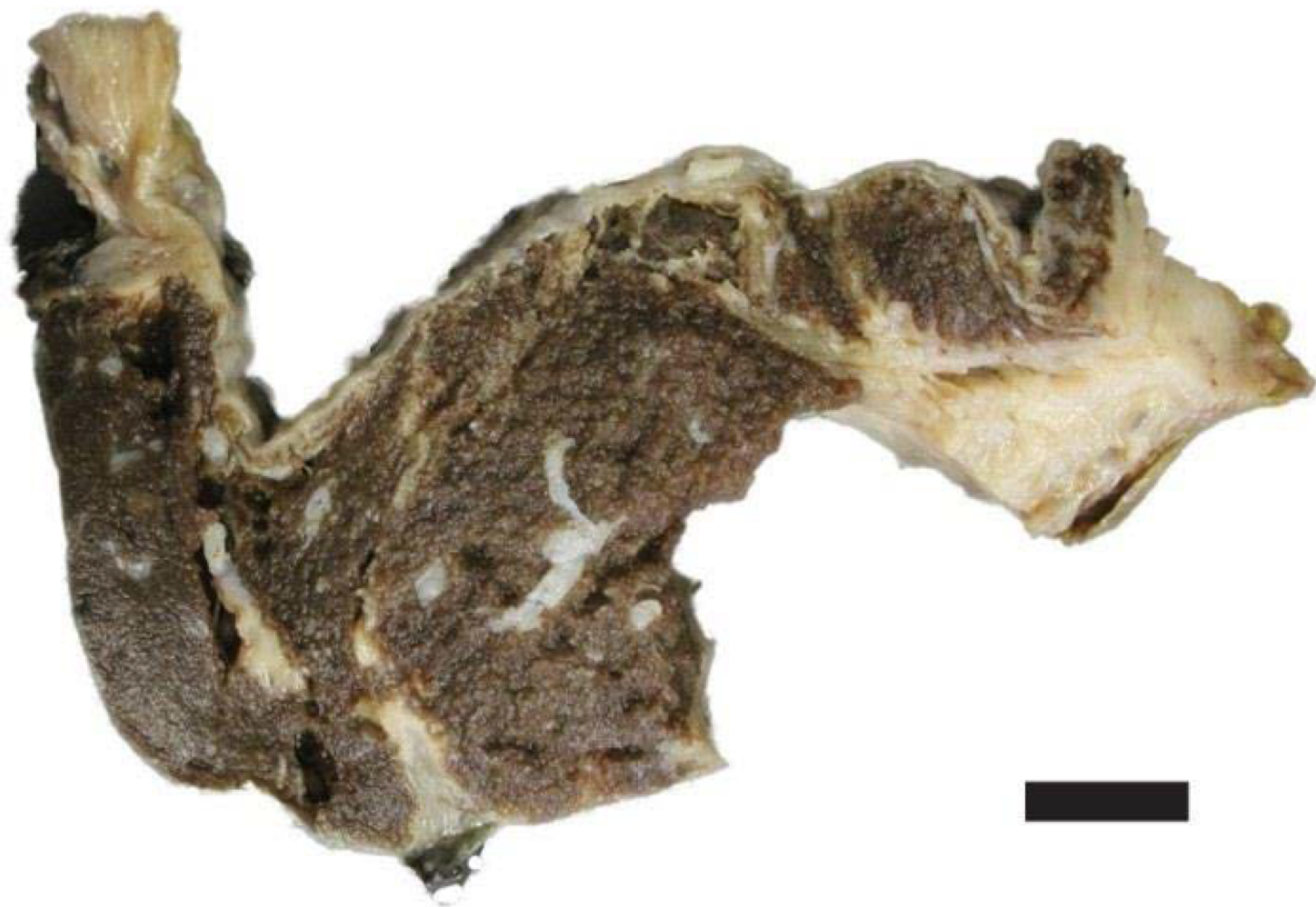

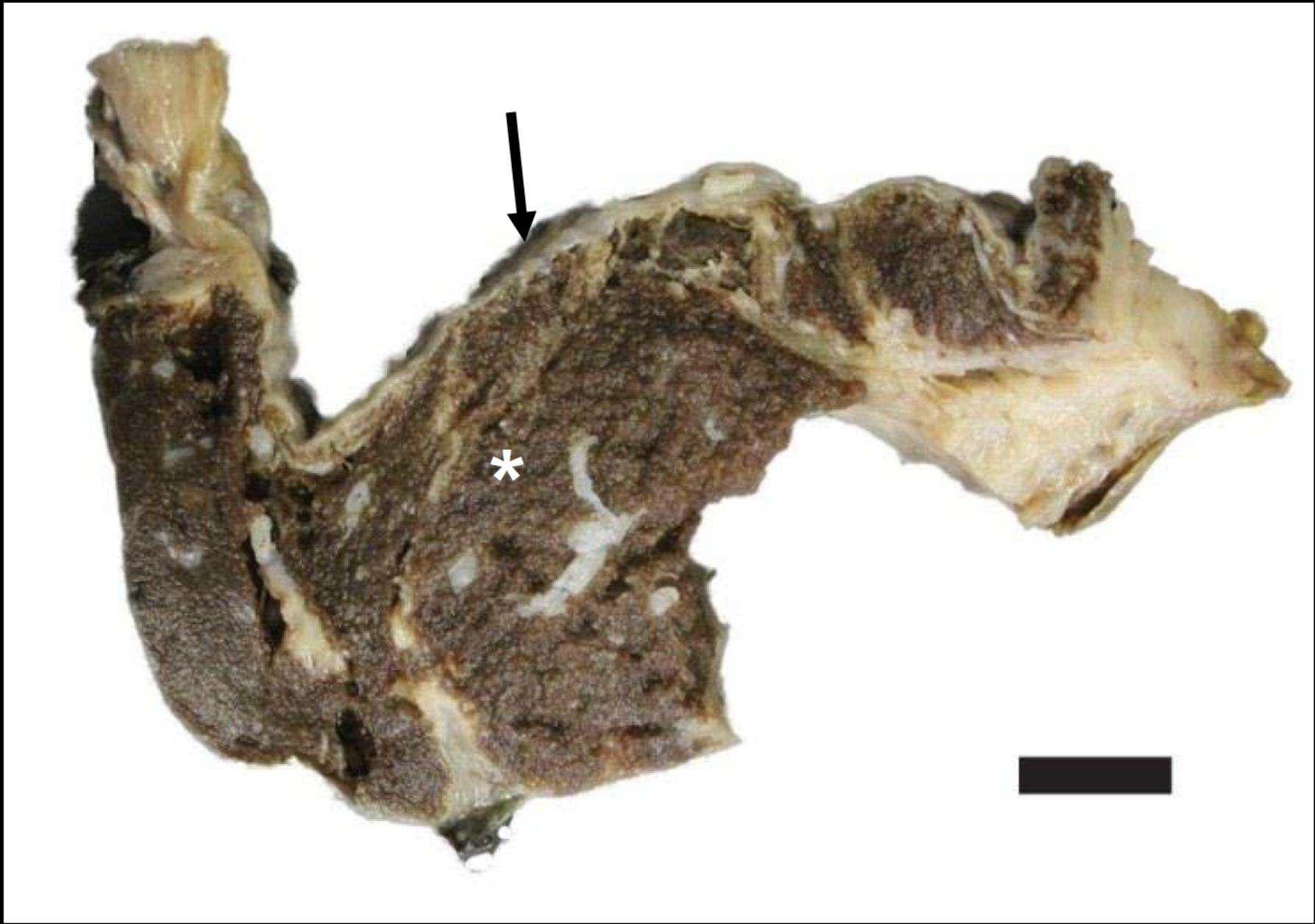
Axial T2

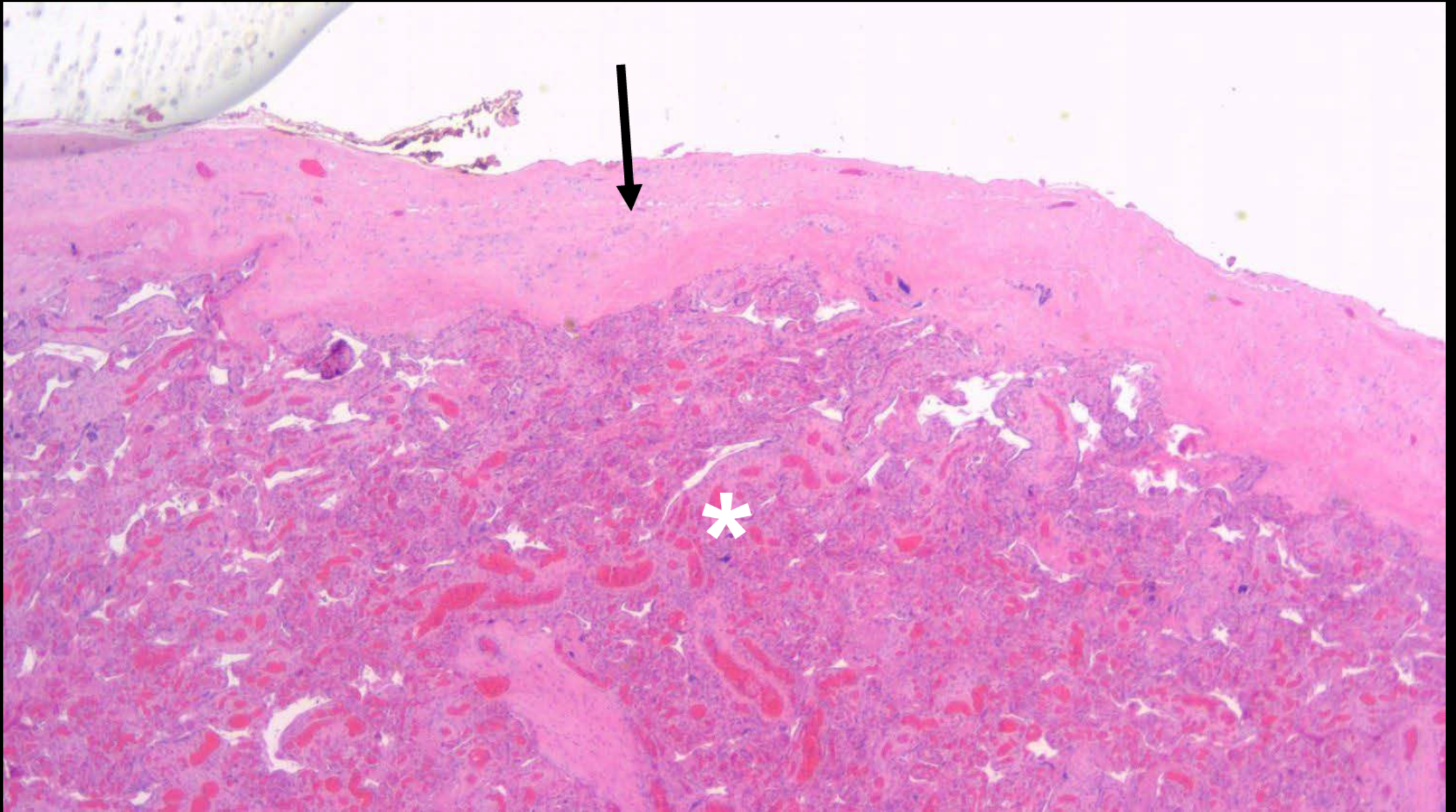












Placenta Percreta

Steffen Haider, MD

New York-Presbyterian-Columbia

New York, NY



**AMERICAN INSTITUTE FOR
RADIOLOGIC PATHOLOGY**

**A PROGRAM OF THE
AMERICAN COLLEGE OF RADIOLOGY**