

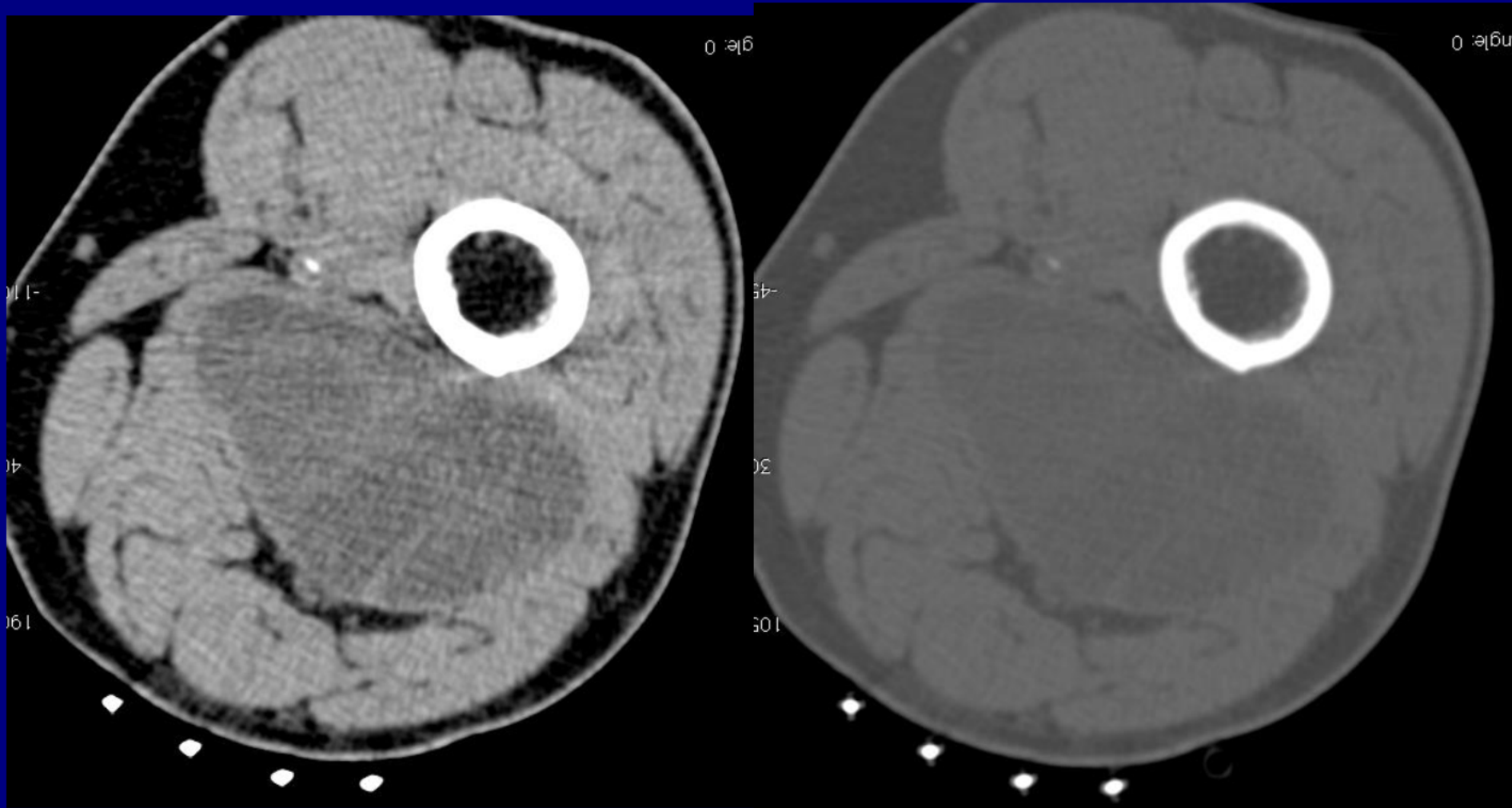
BEST CASES OF THE AIRP

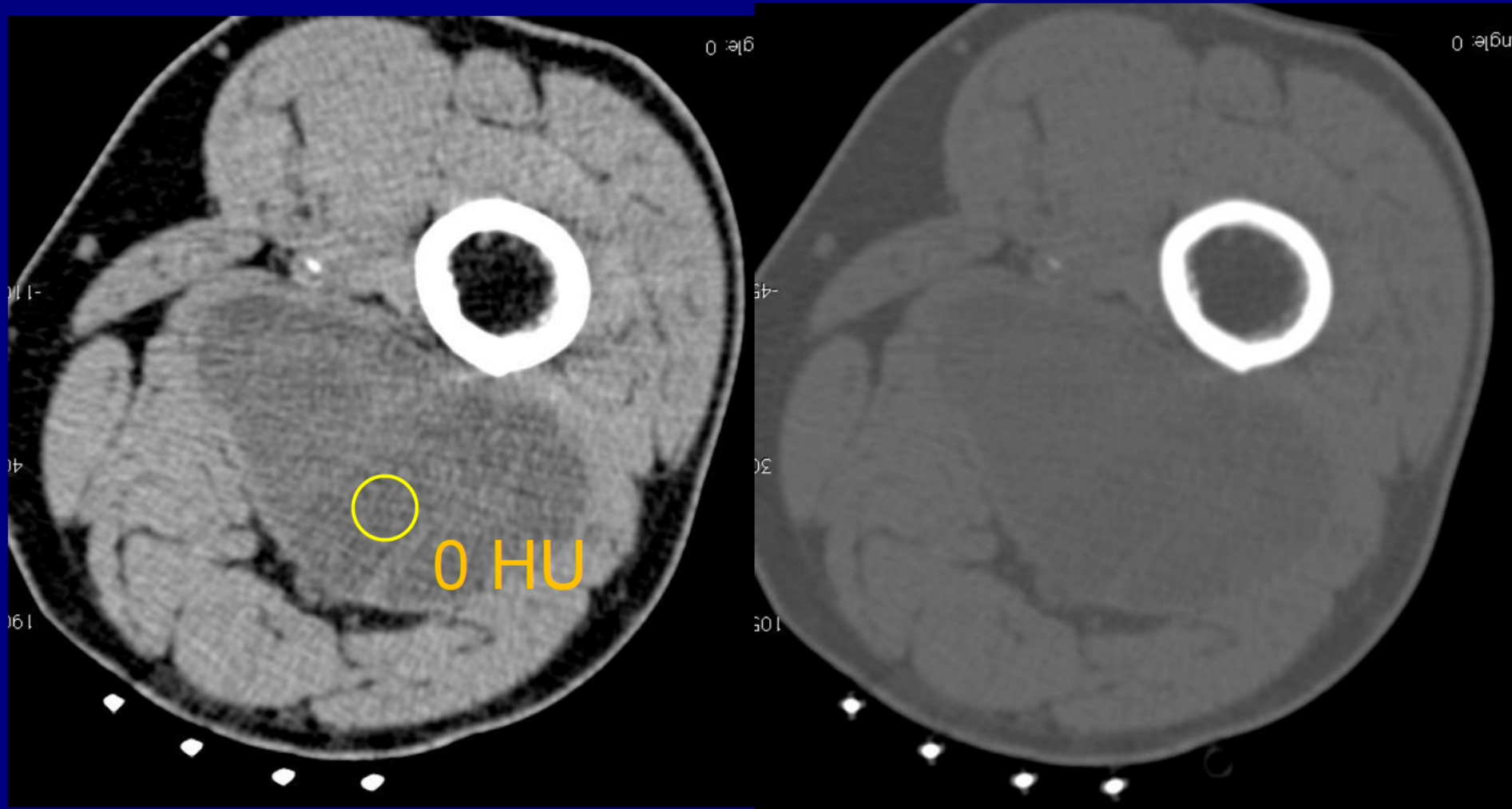
7 Mar – 1 Apr 2011

Musculoskeletal Best Case

82 year old Armenian male
immigrant with thigh mass

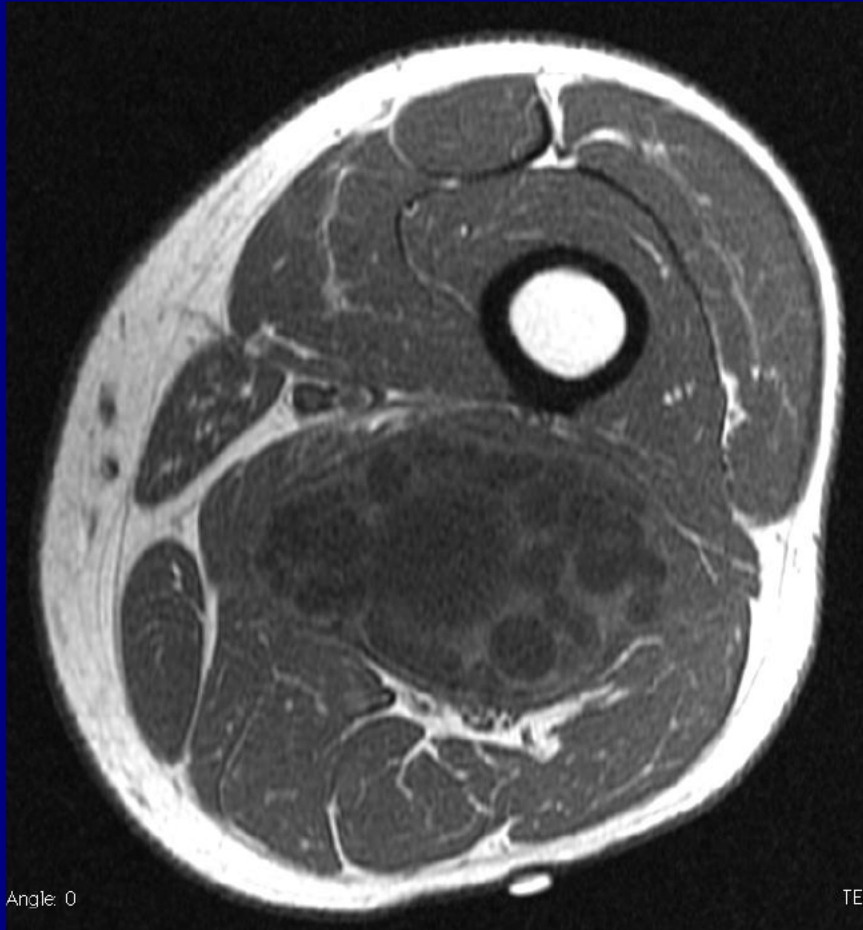
Noncontrast CT



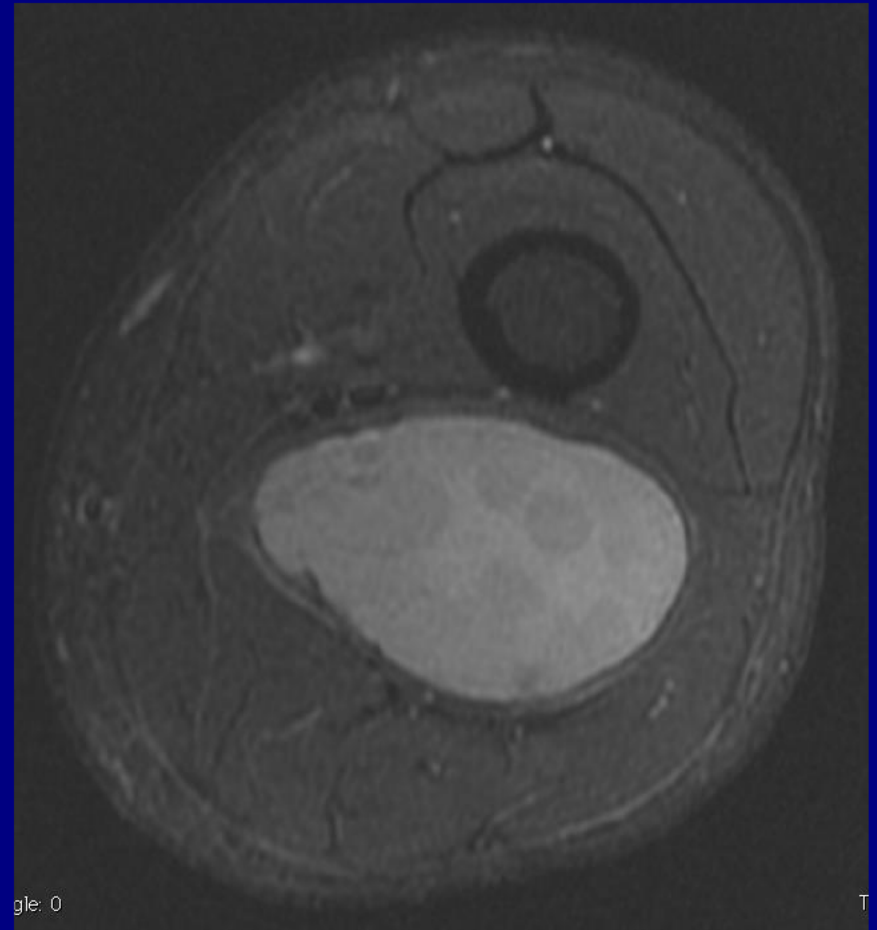


Cystic mass in the adductor magnus muscle

AX T1



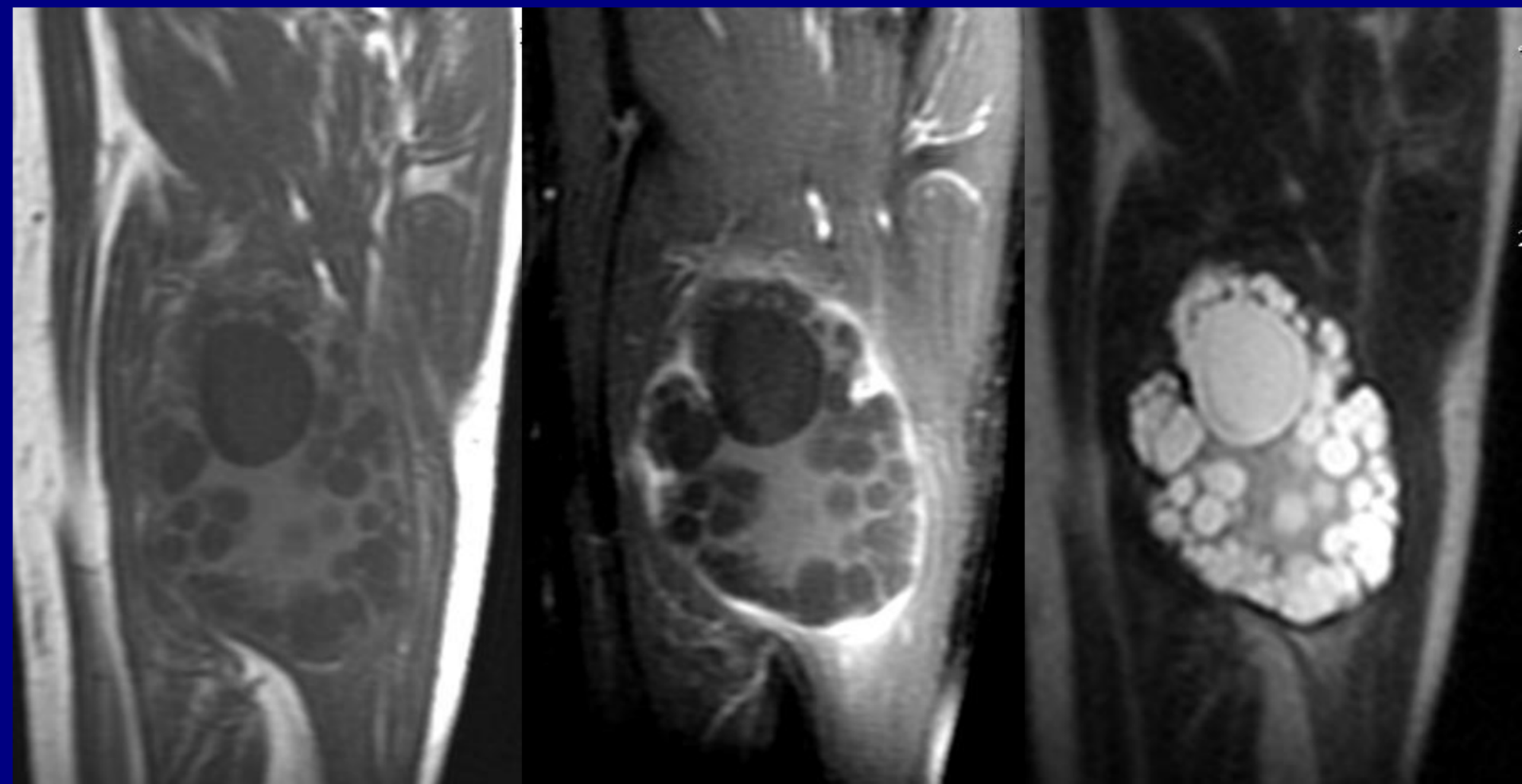
AX STIR



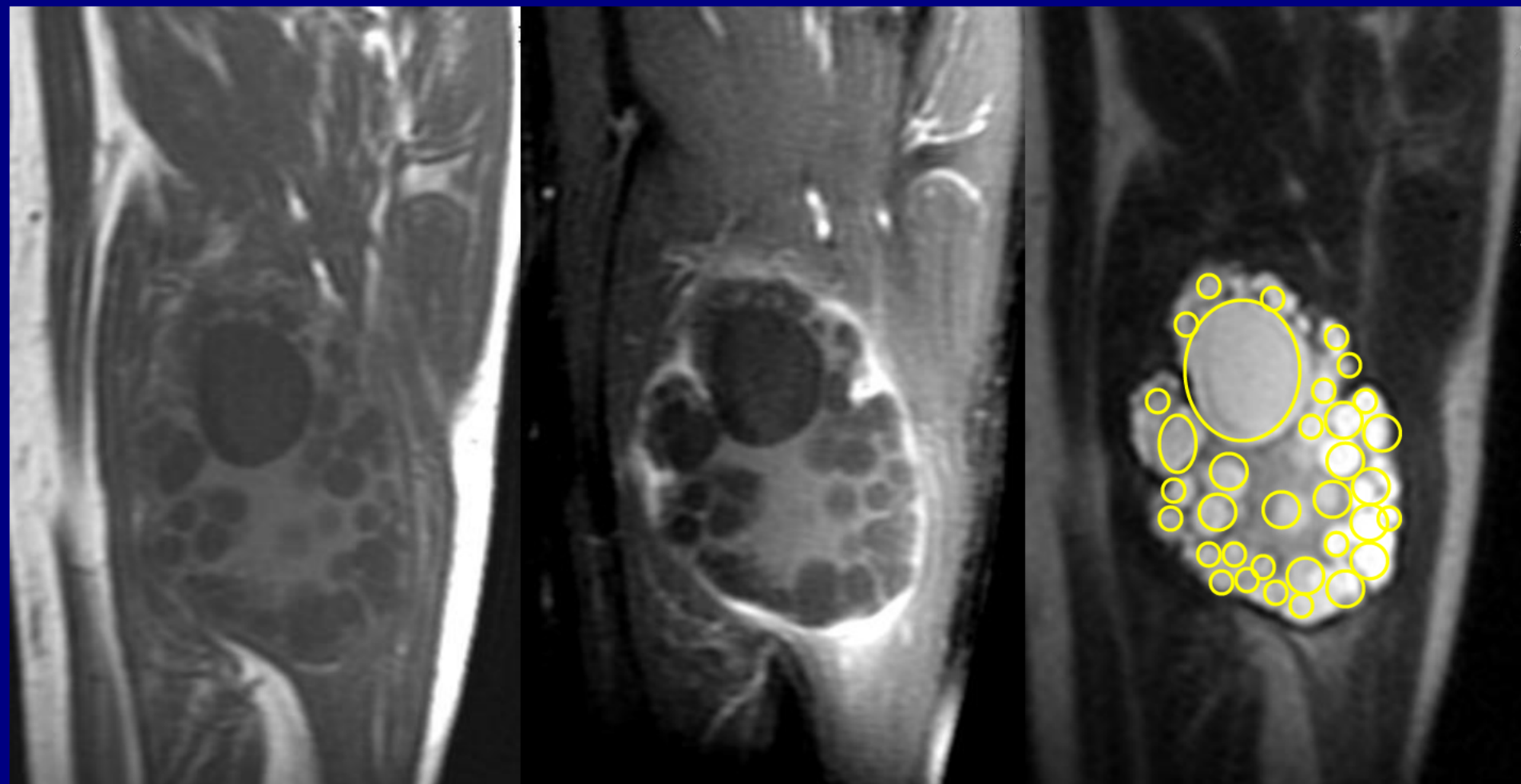
COR T1

T1 FS GD

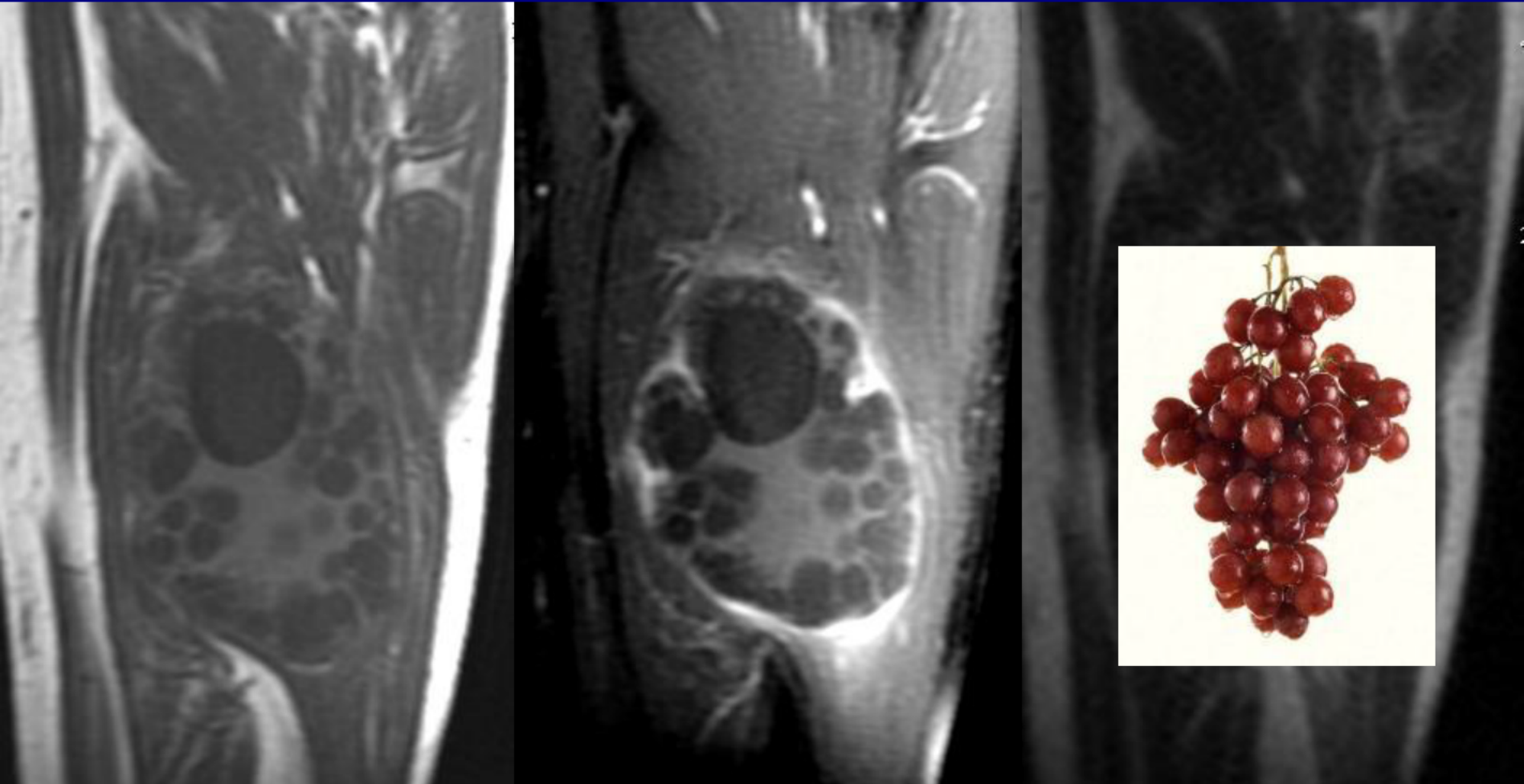
COR T2



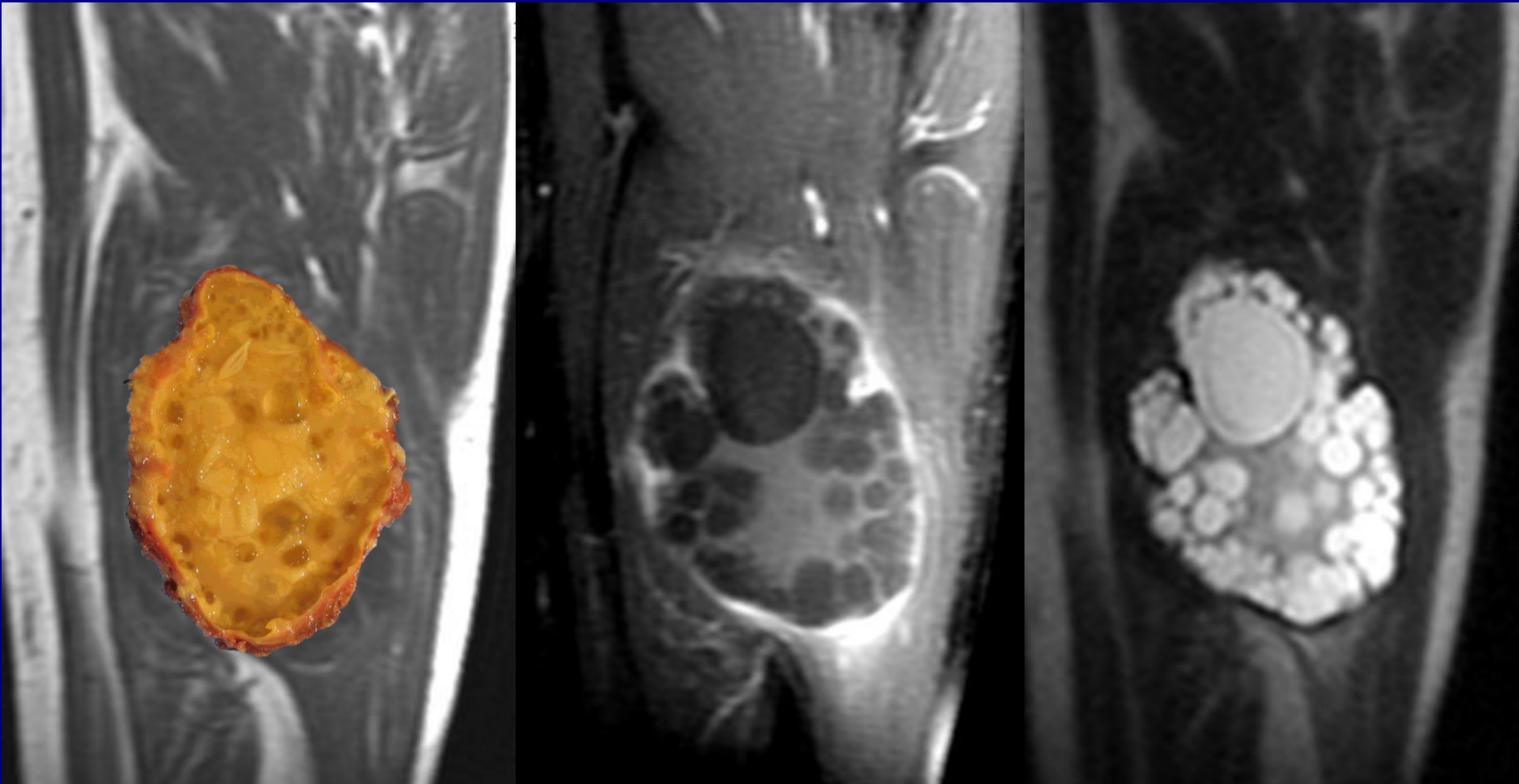
Looks like...

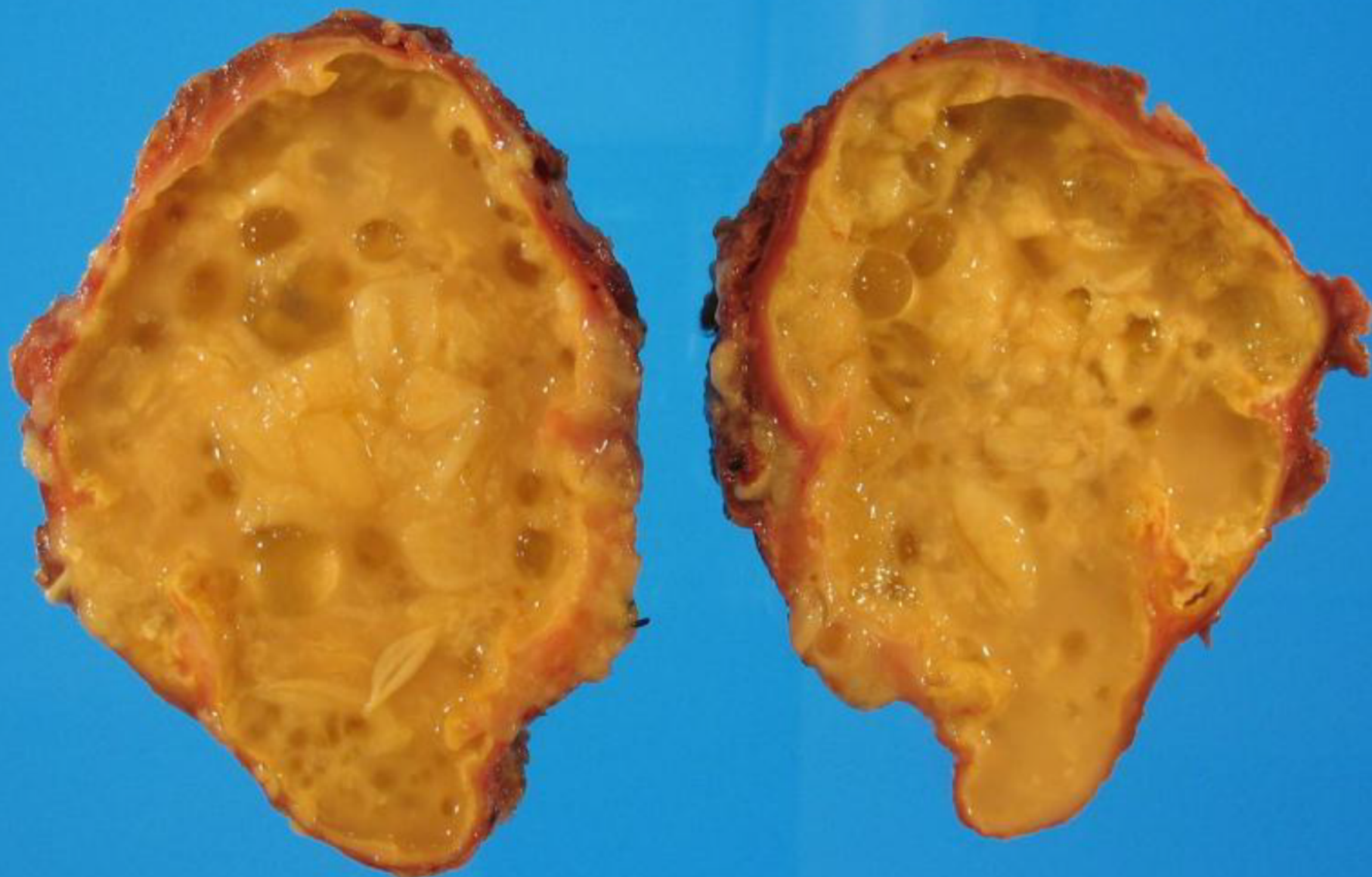


Looks like...

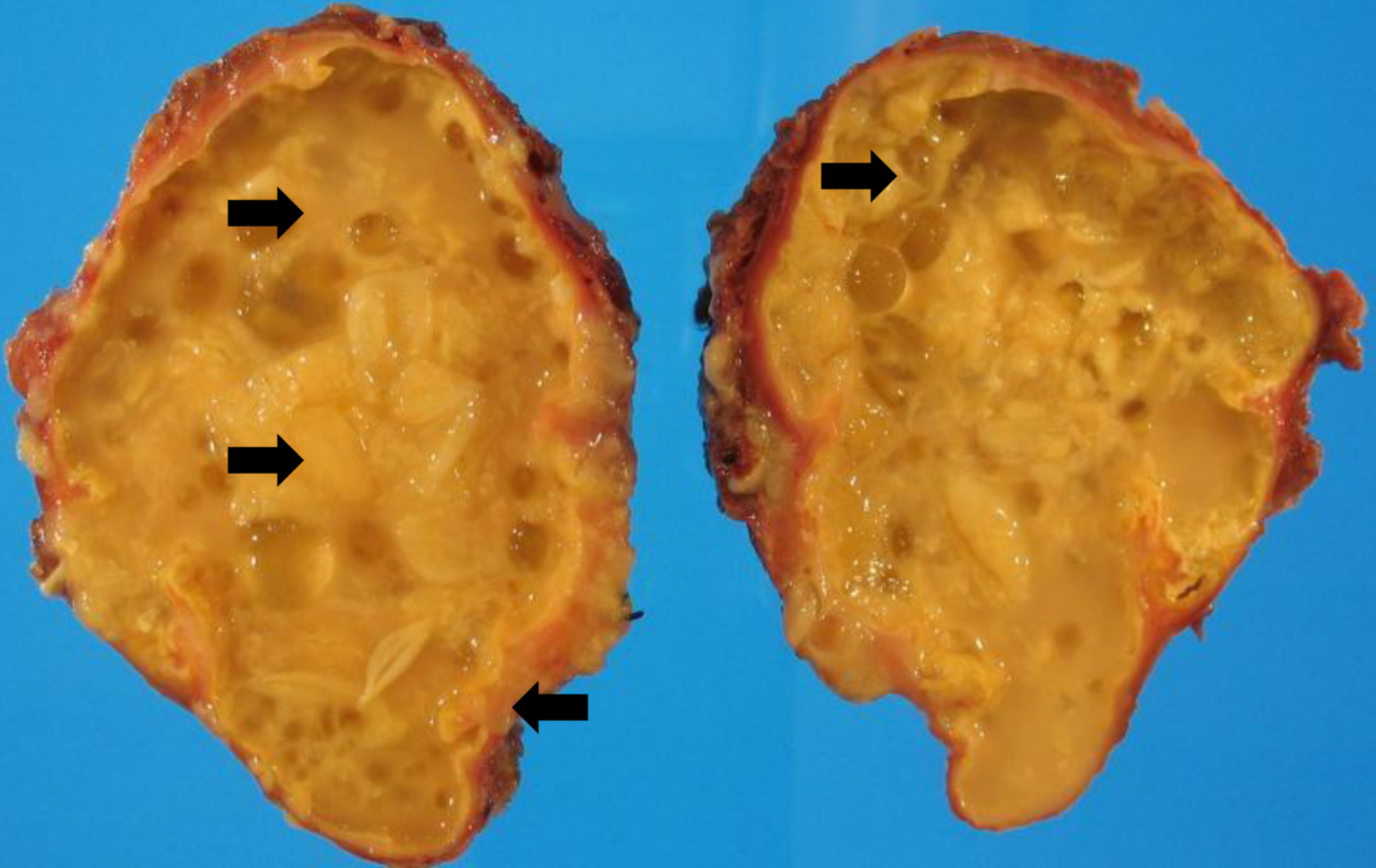


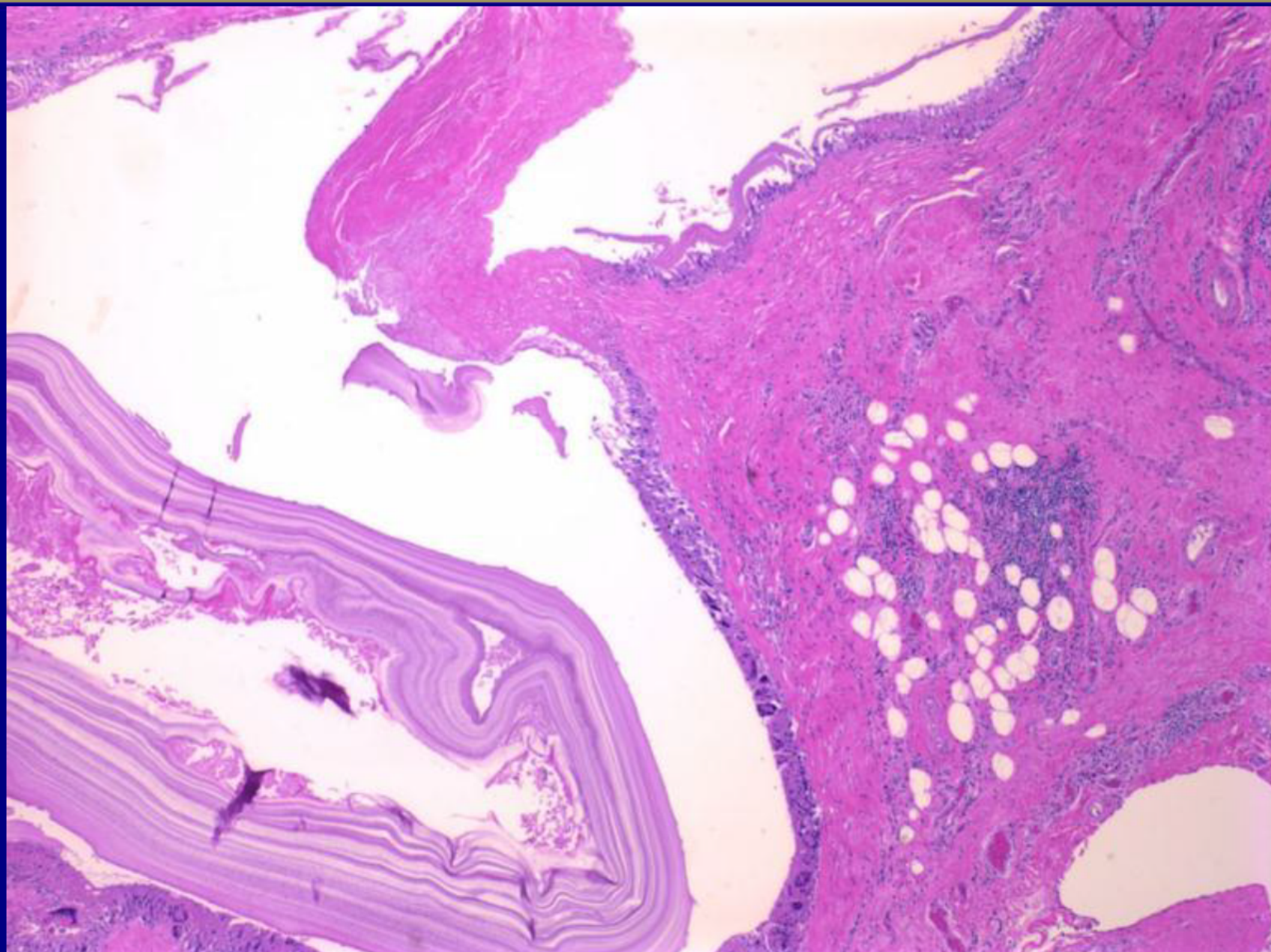
Gross fusion

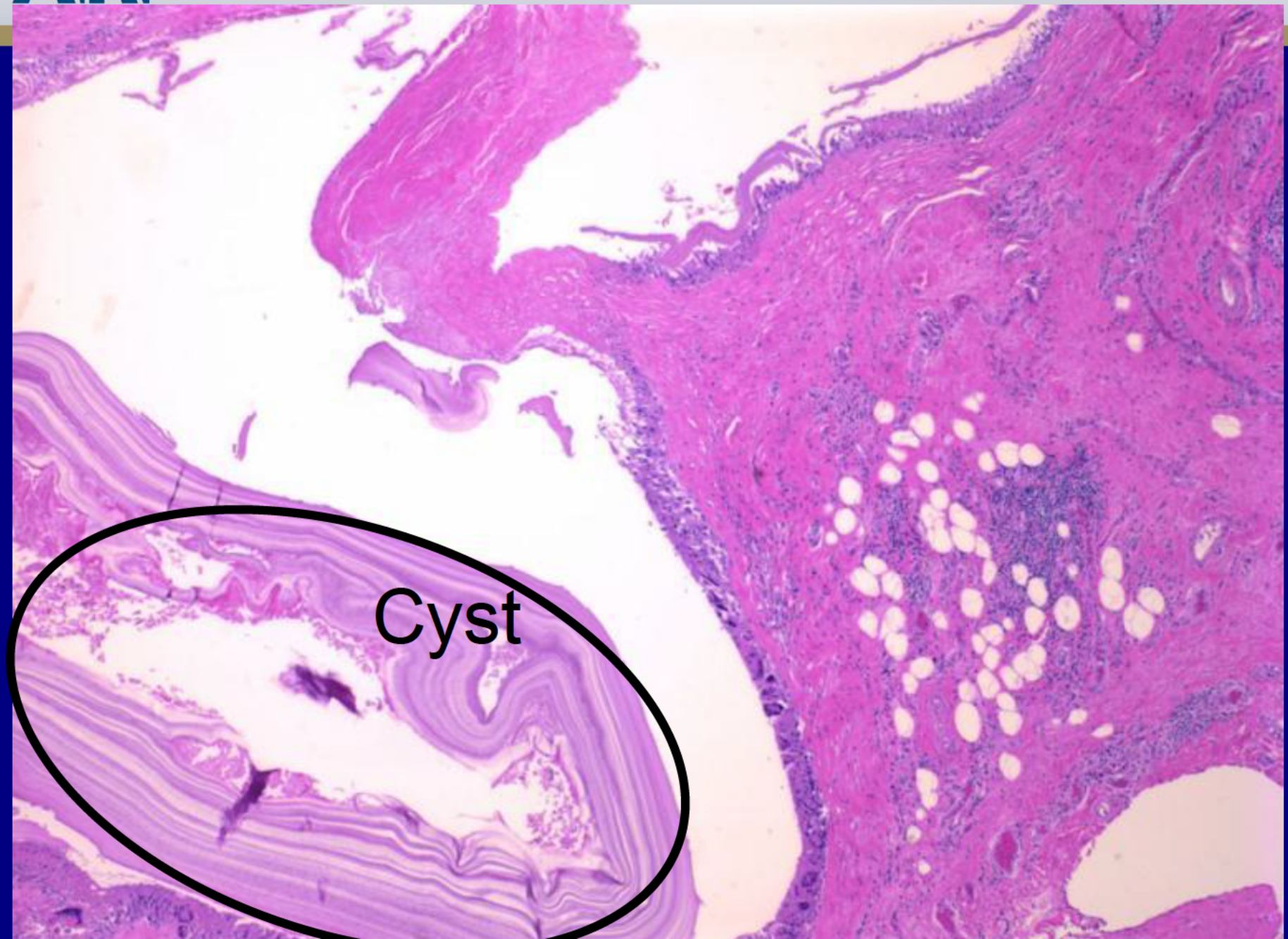



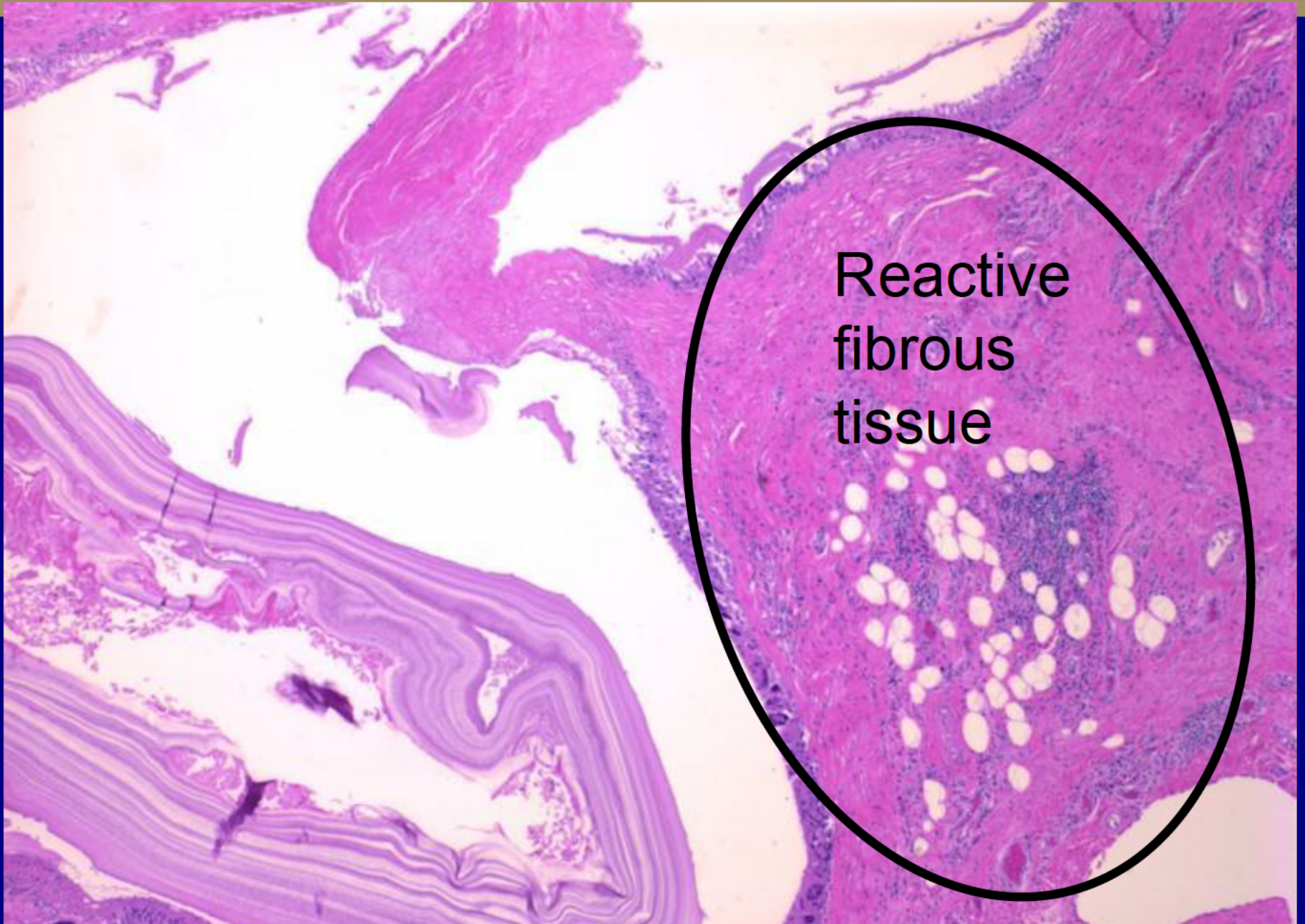
Multiple Cysts







Cyst



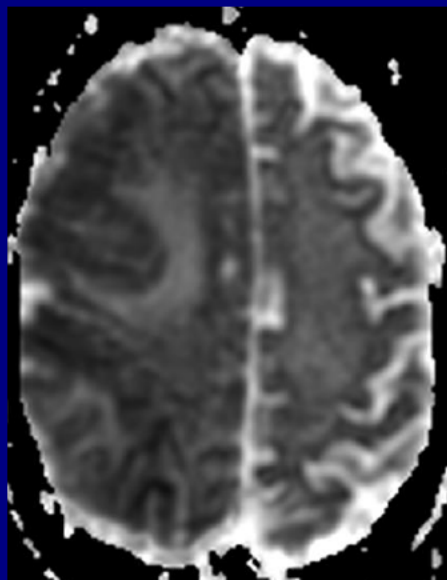
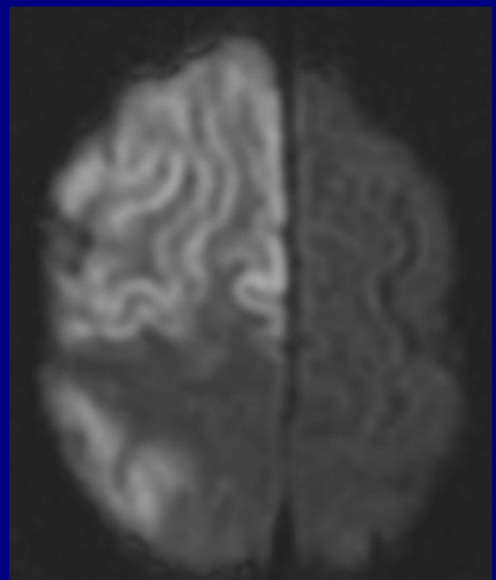
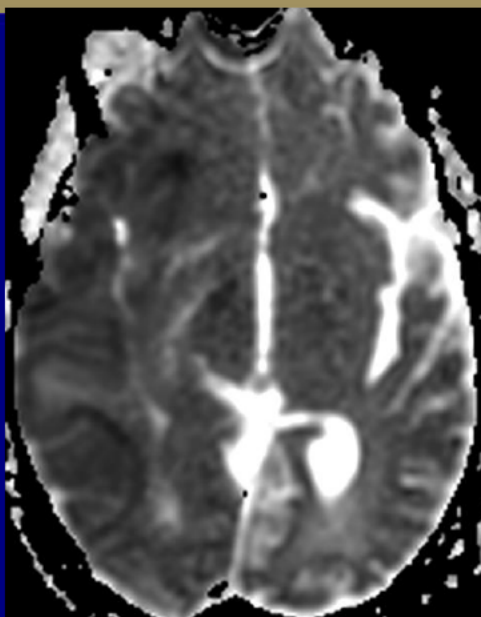
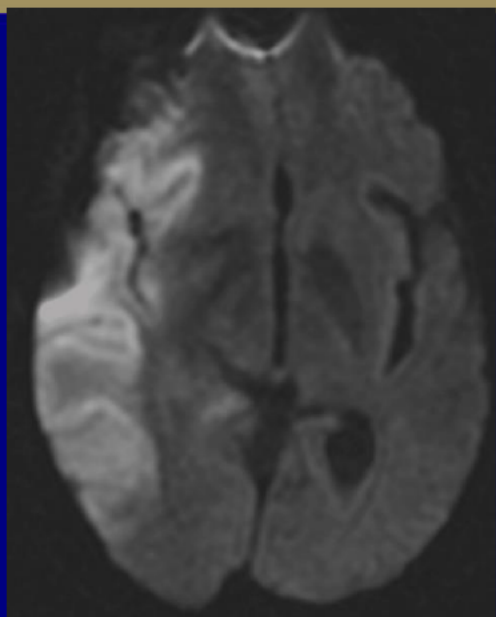
Reactive
fibrous
tissue

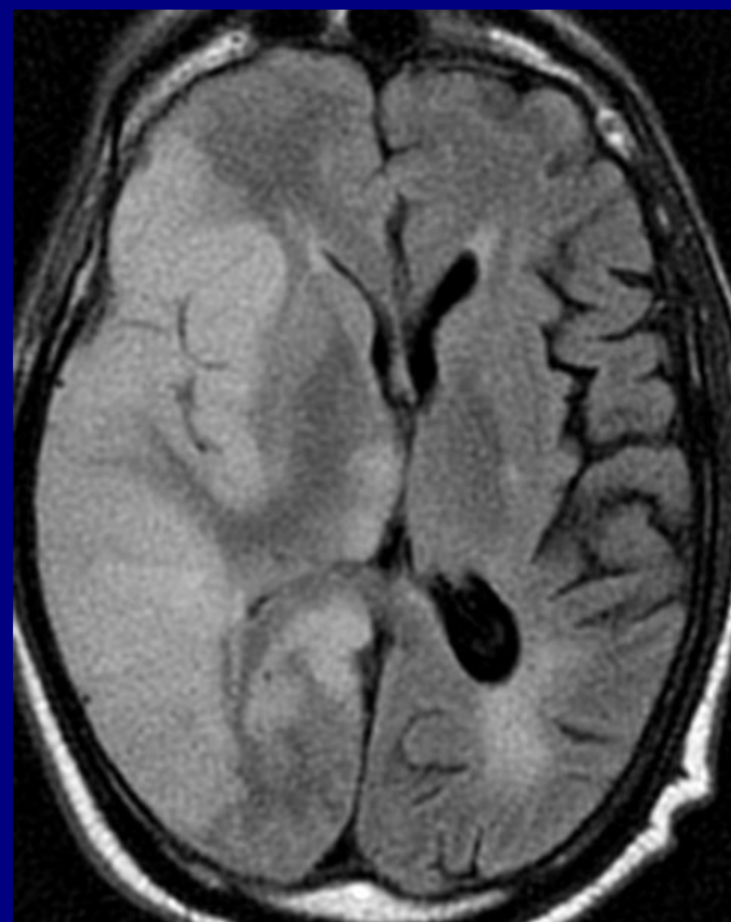
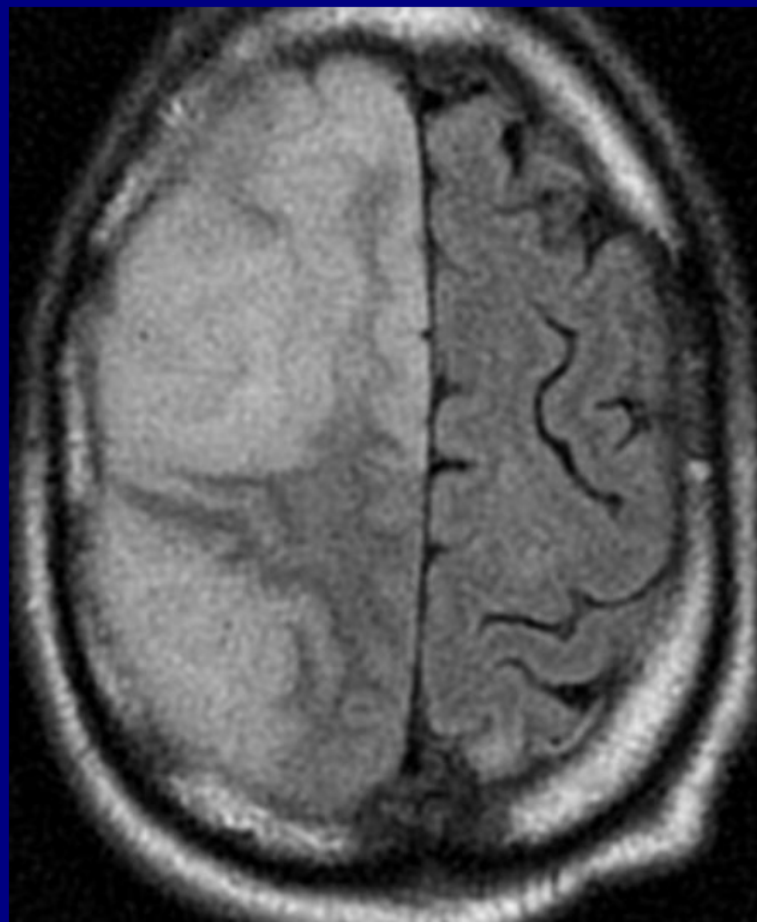
Diagnosis: Echinococcus infection

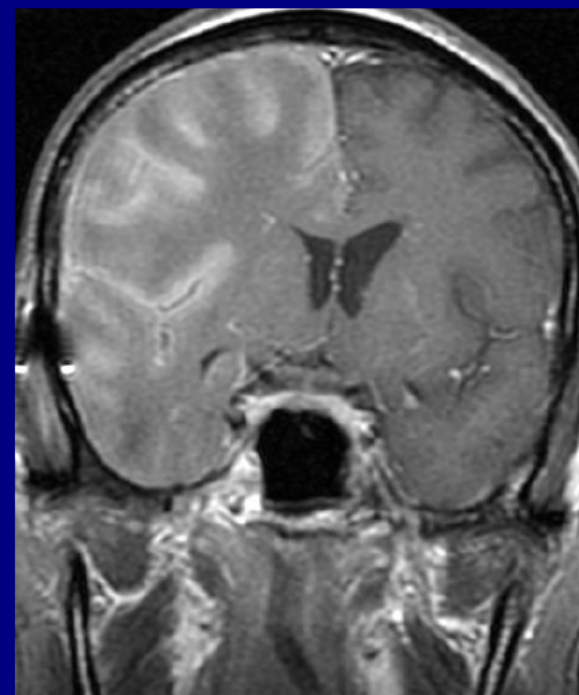
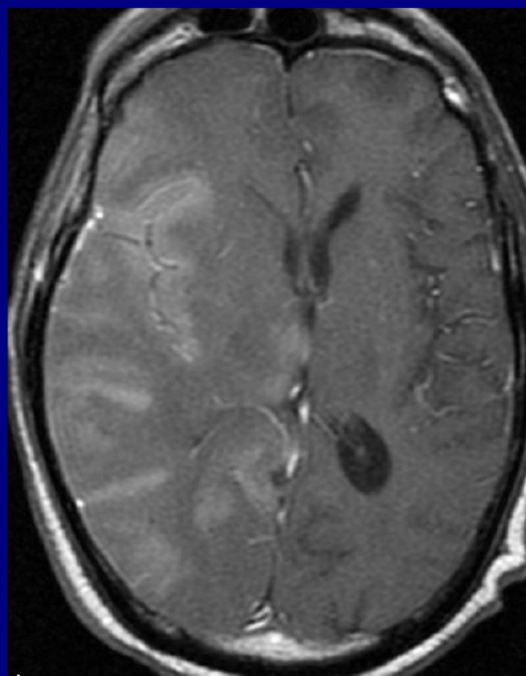
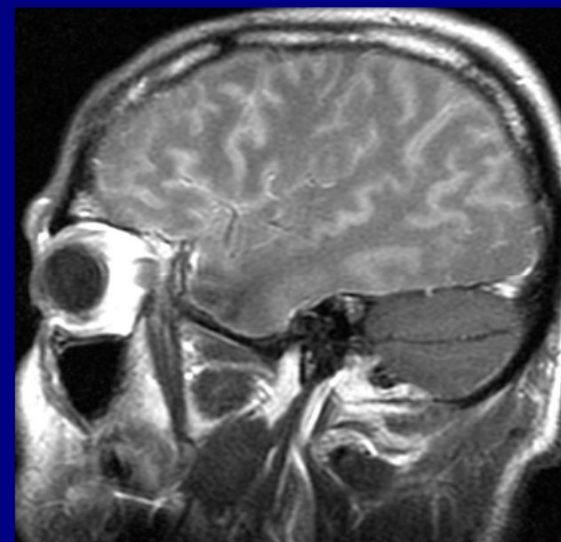
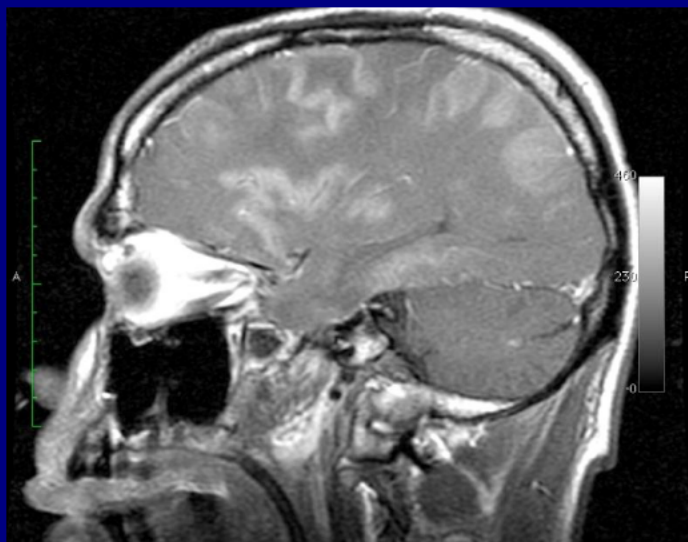
Shareef Riad
David Geffen School of Medicine
UCLA Medical Center
Los Angeles, CA, USA

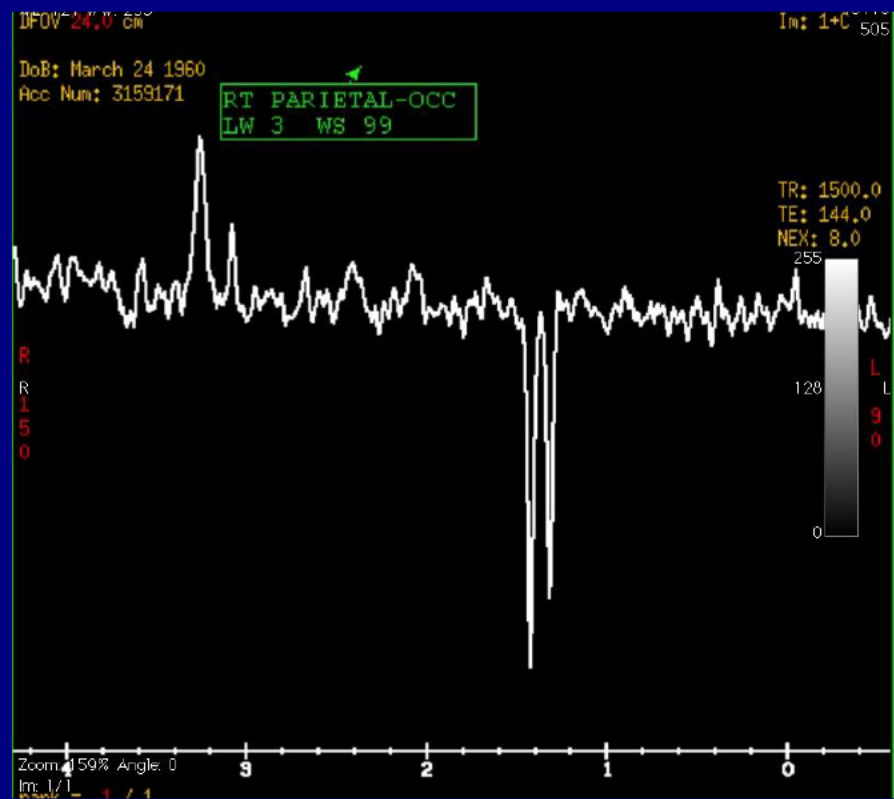
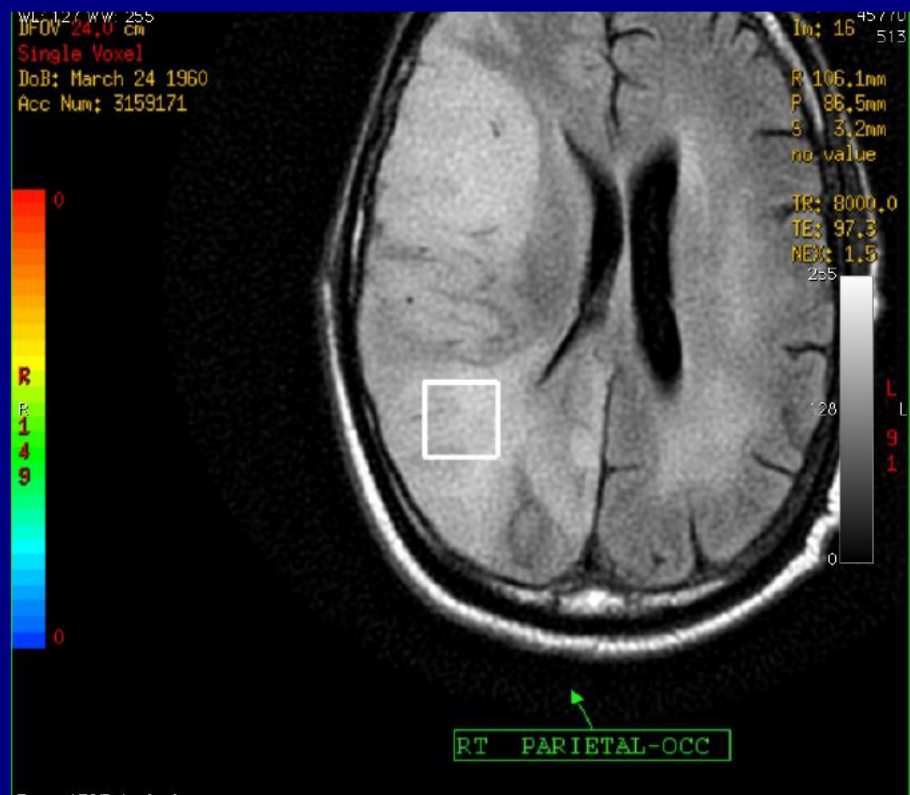
Neuroradiology Best Case

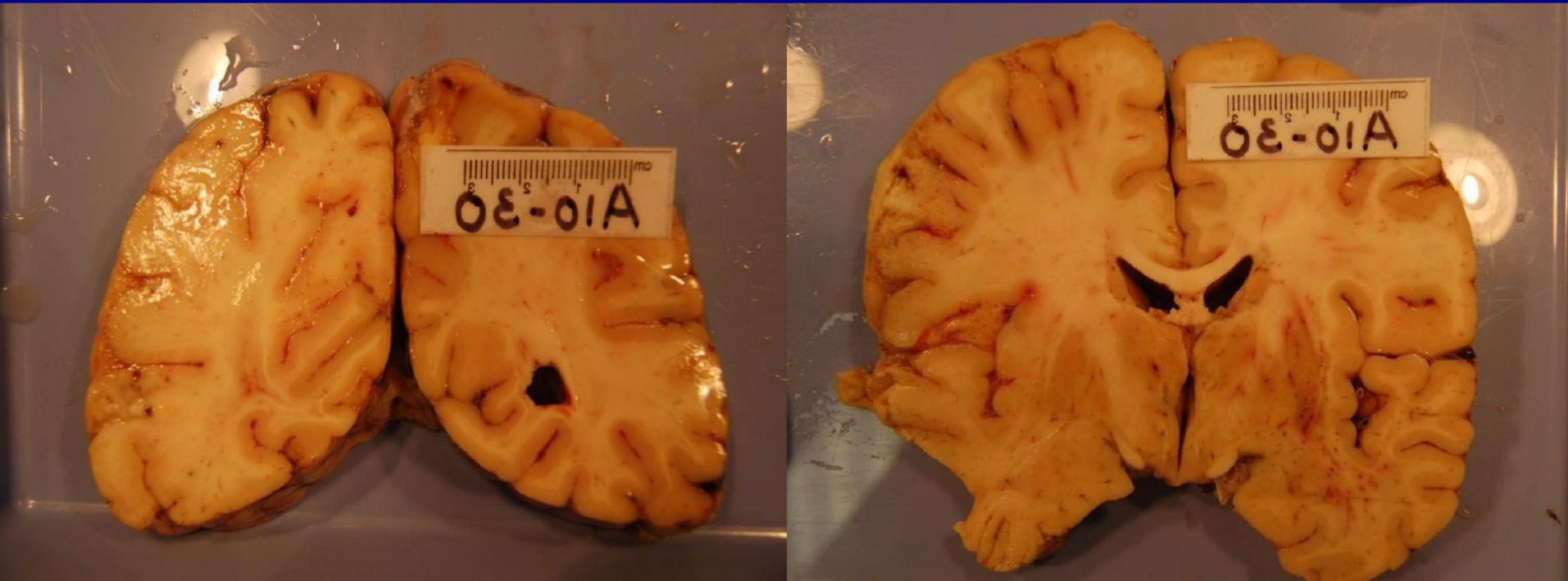
50-year-old man with h/o HIV and non-Hodgkin's lymphoma with 2 prior brain mets who presented with increased involuntary limb movements and left sided weakness and numbness

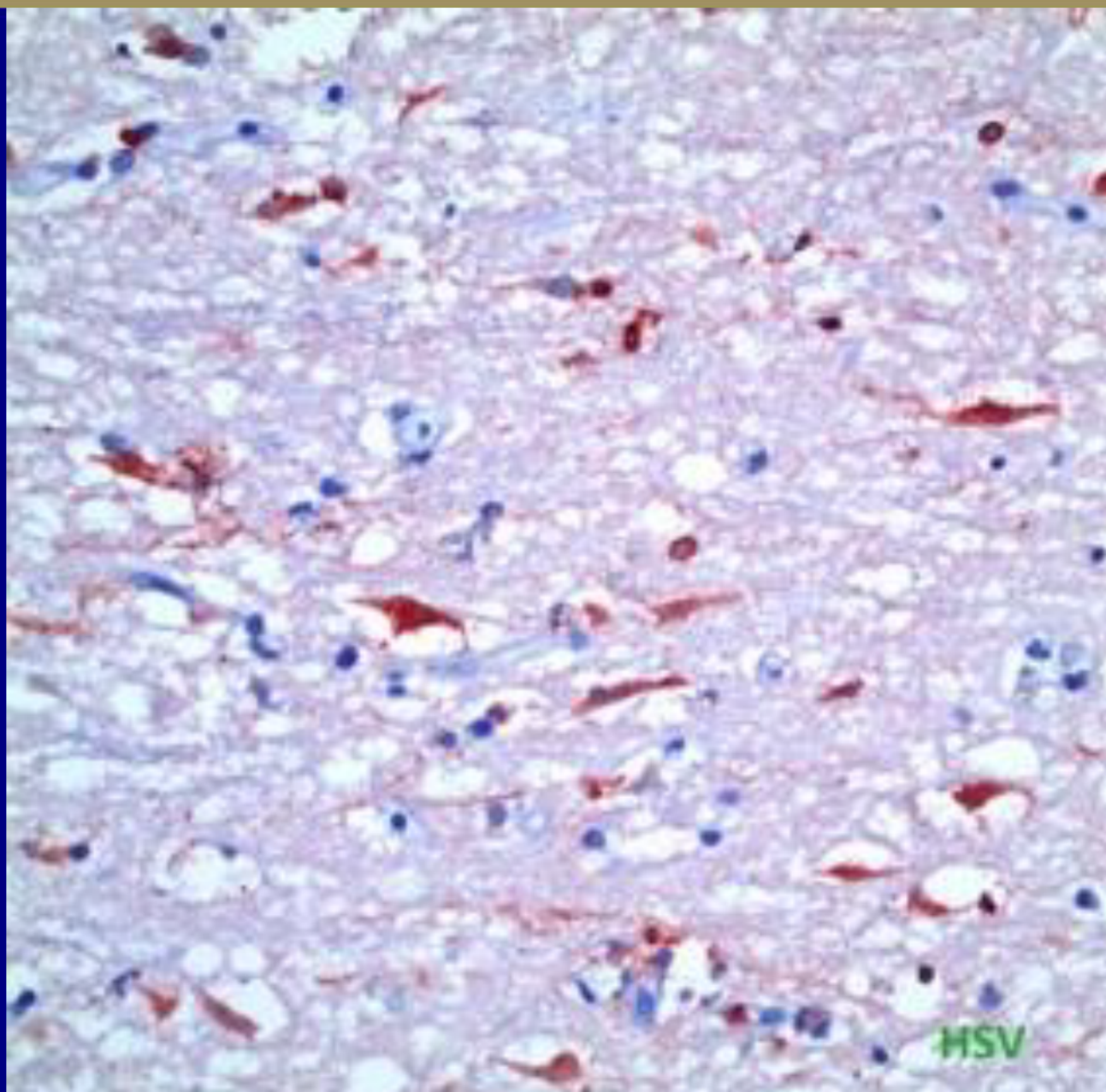


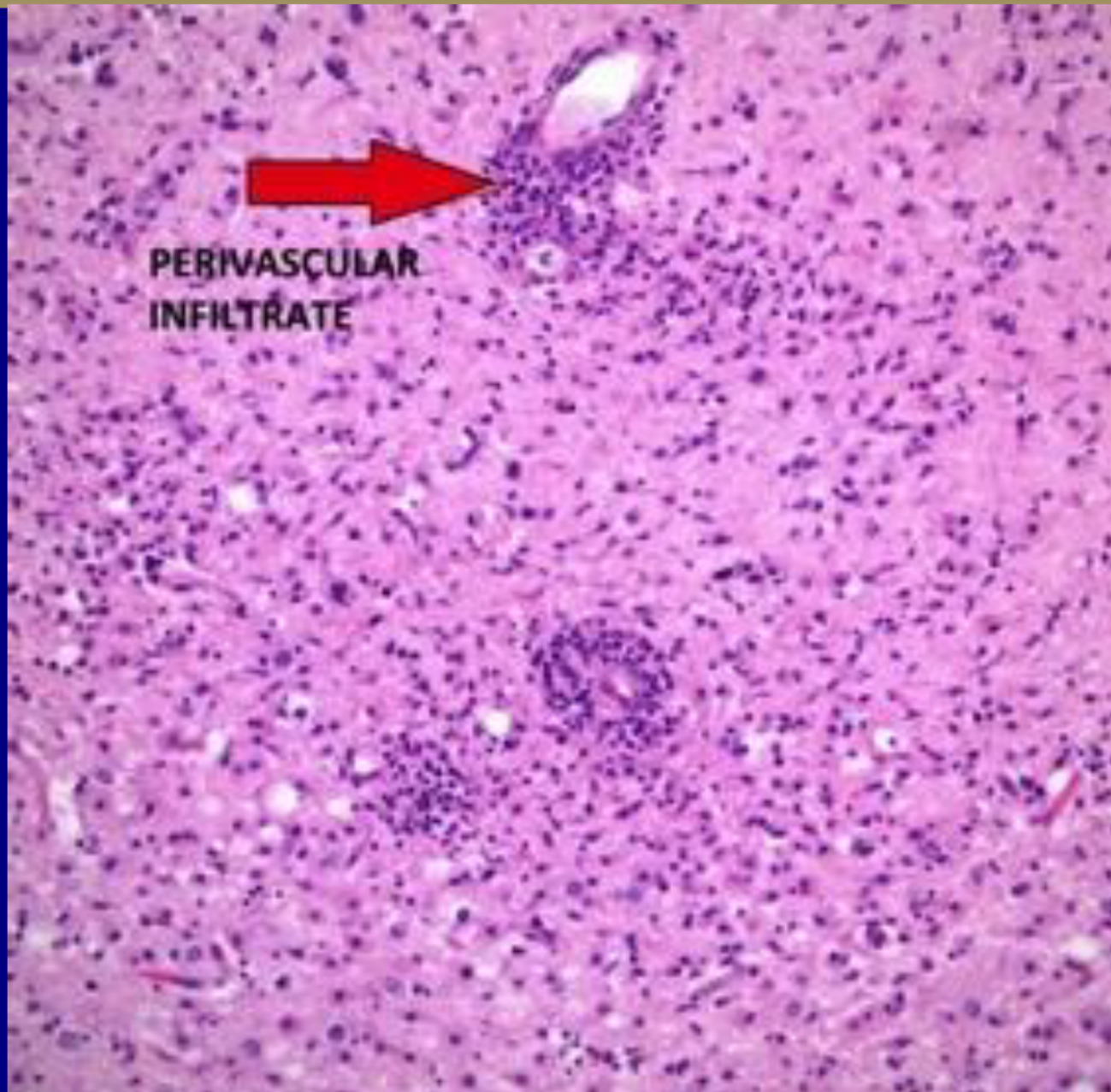










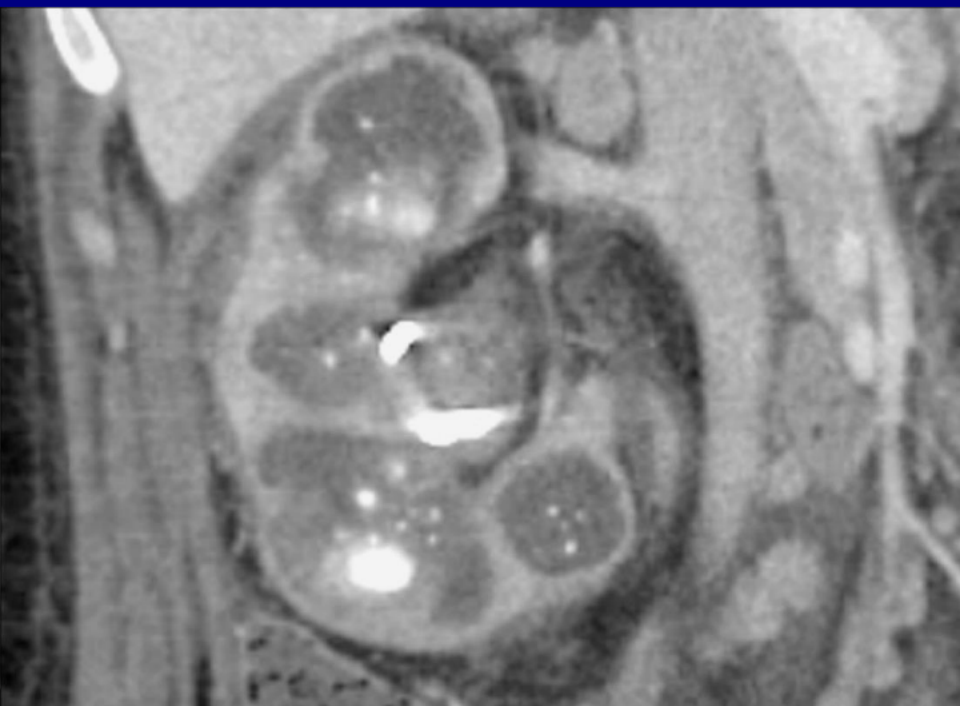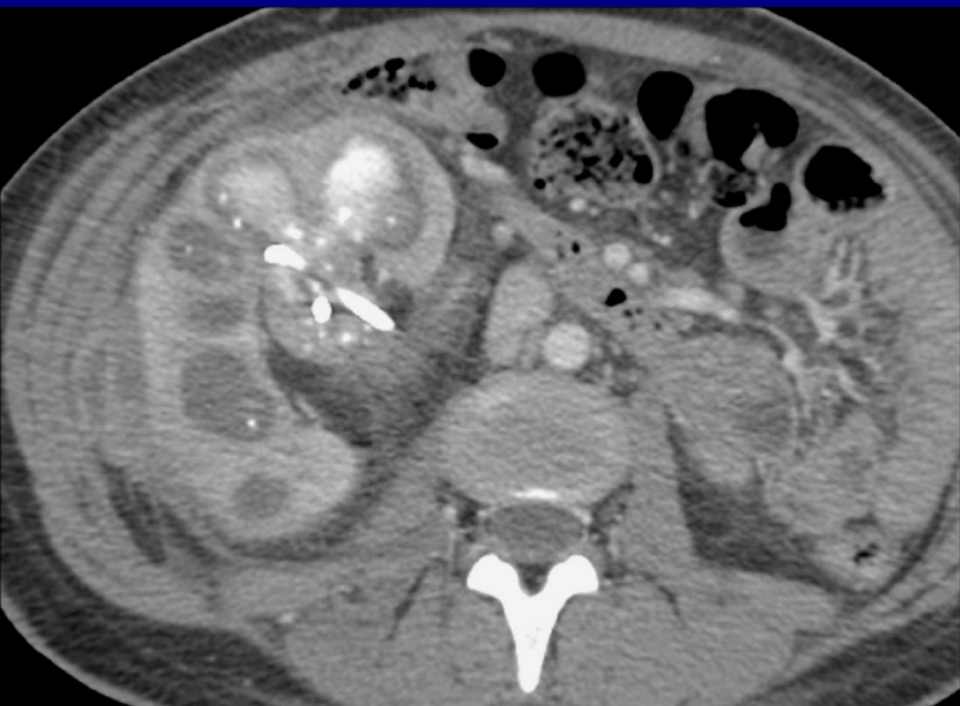


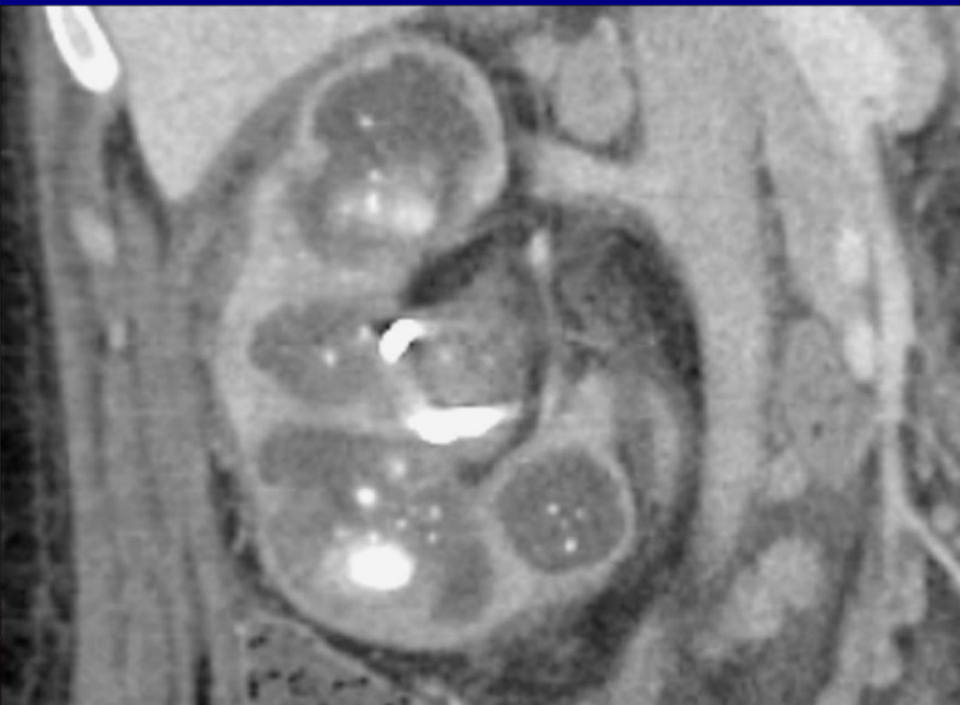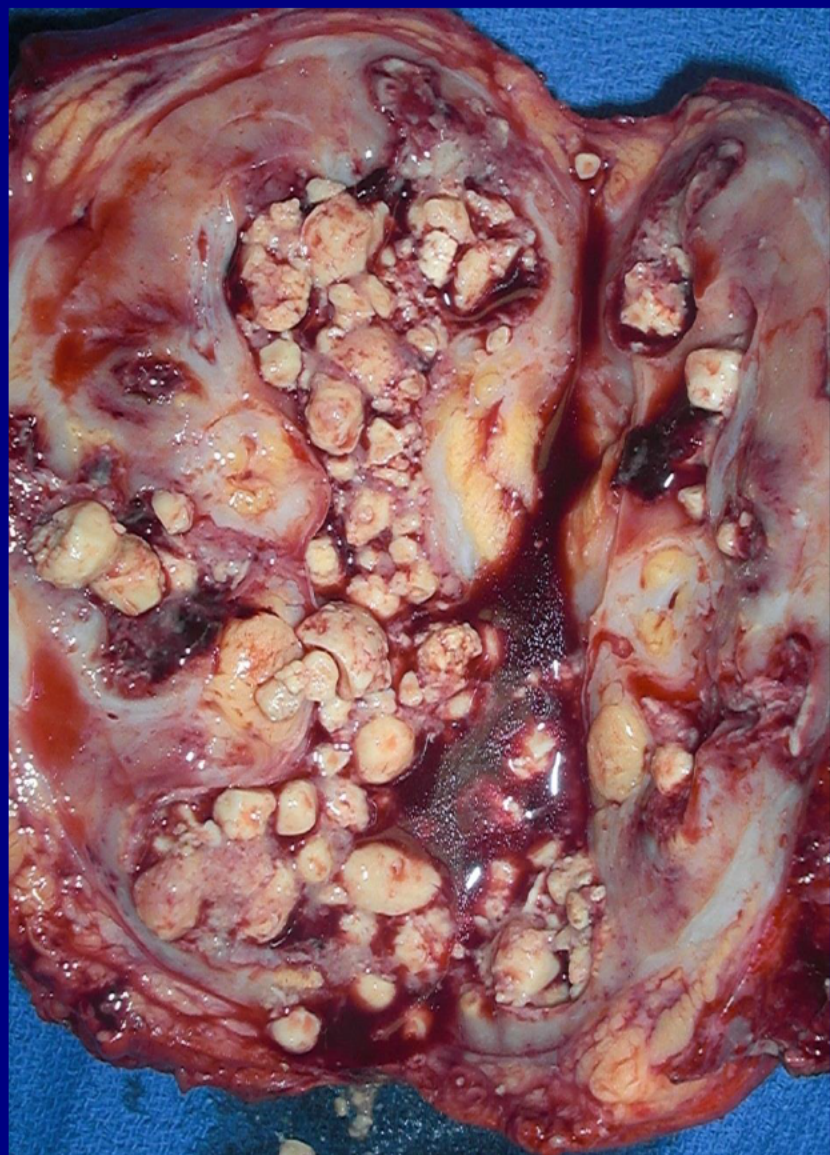HSV Encephalitis

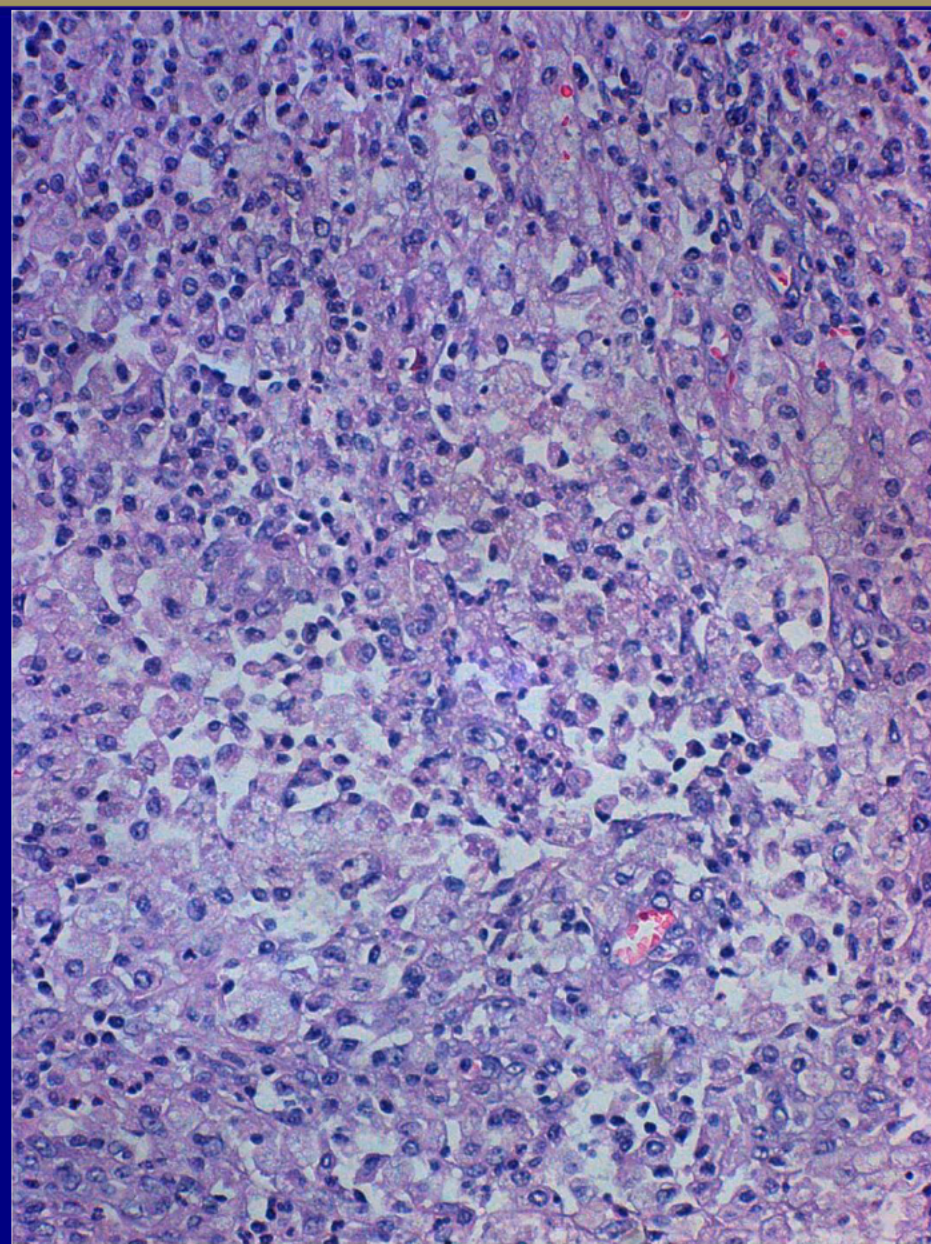
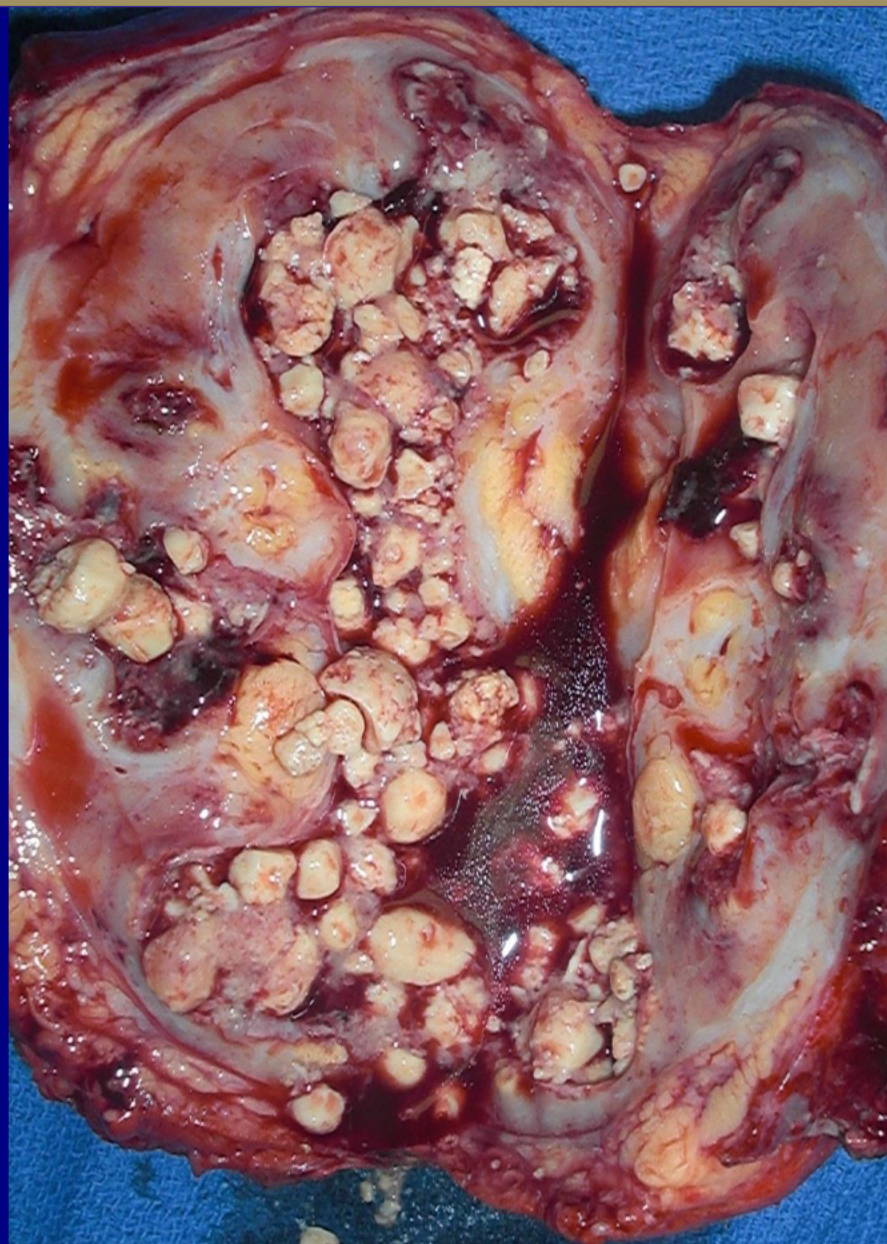
Seema Prakash
Hartford Hospital
Hartford, Connecticut

Genitourinary Best Case

20-year-old female with remote history of right-sided nephrolithiasis now presenting with worsening right flank pain



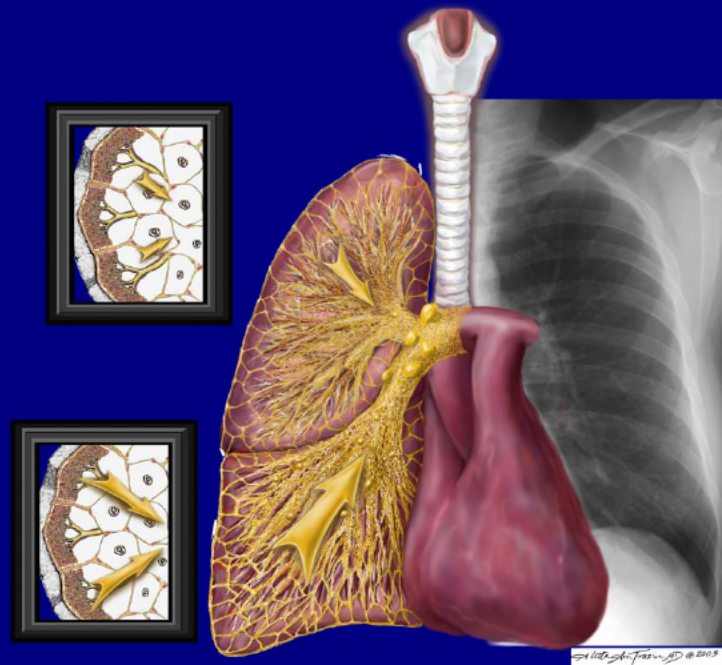




Xanthogranulomatous Pyelonephritis

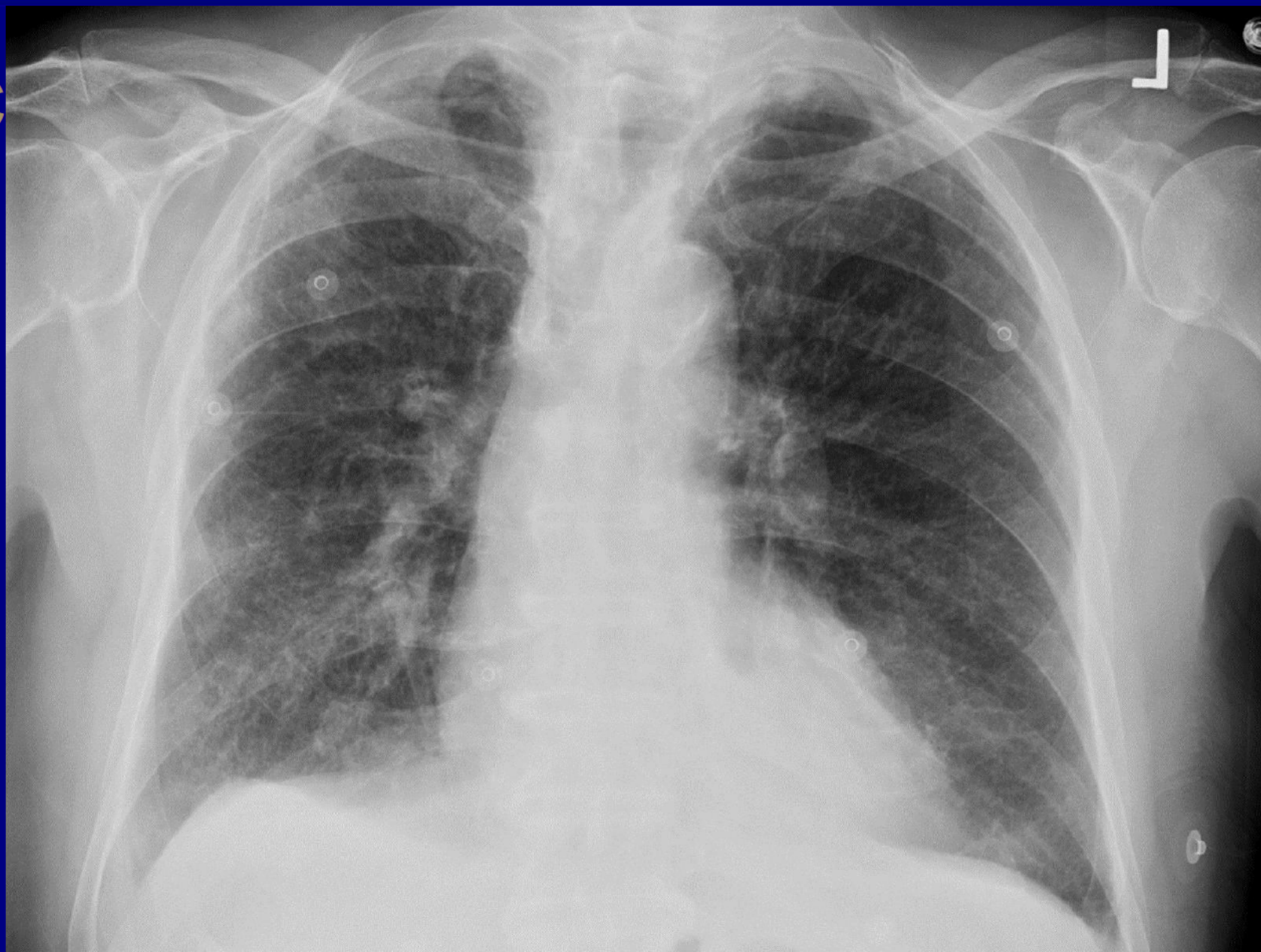Hamidreza Torshizy
UCSD Medical Center
San Diego, California

PULMONARY AND MEDIASTINAL IMAGING

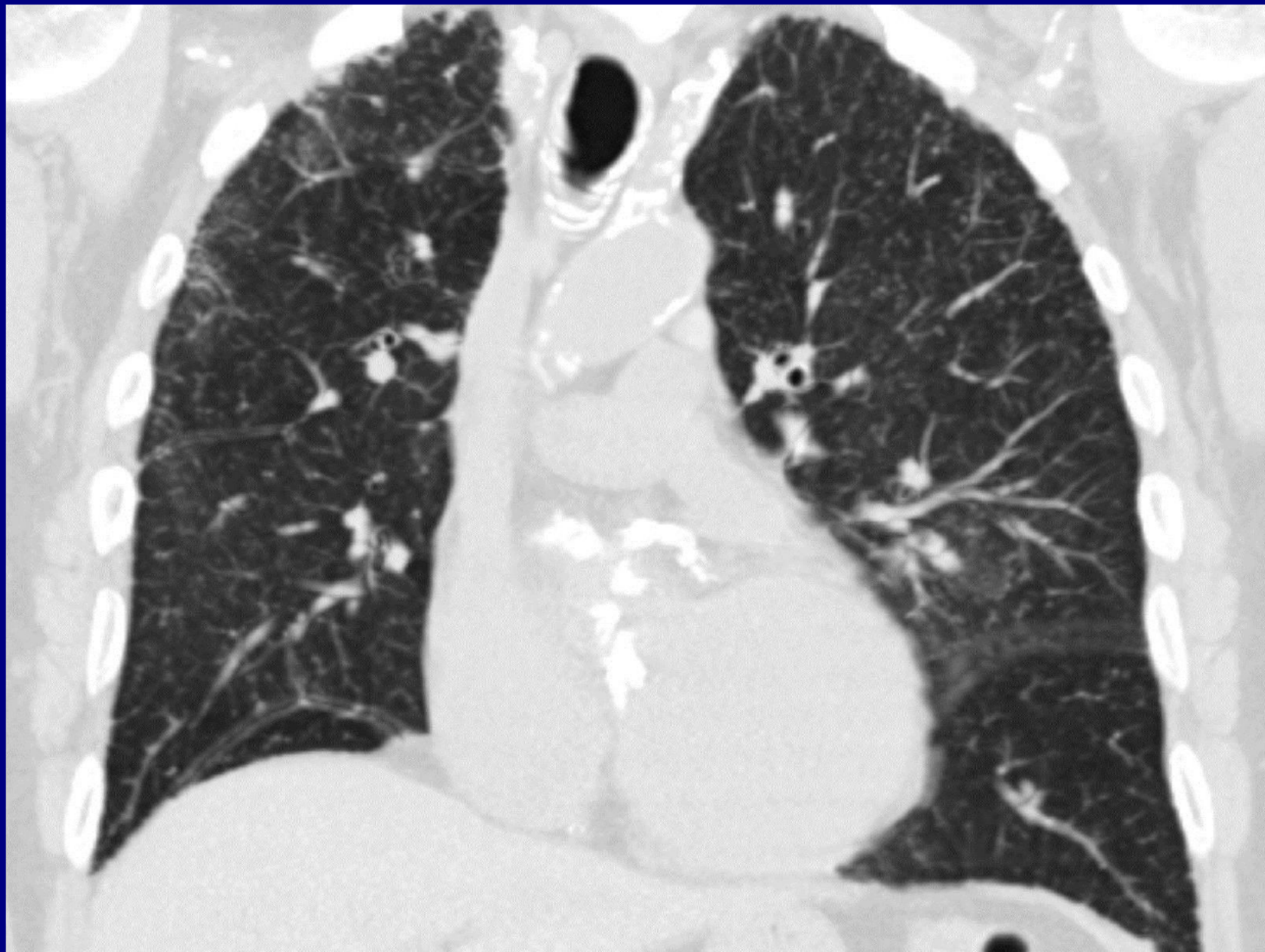

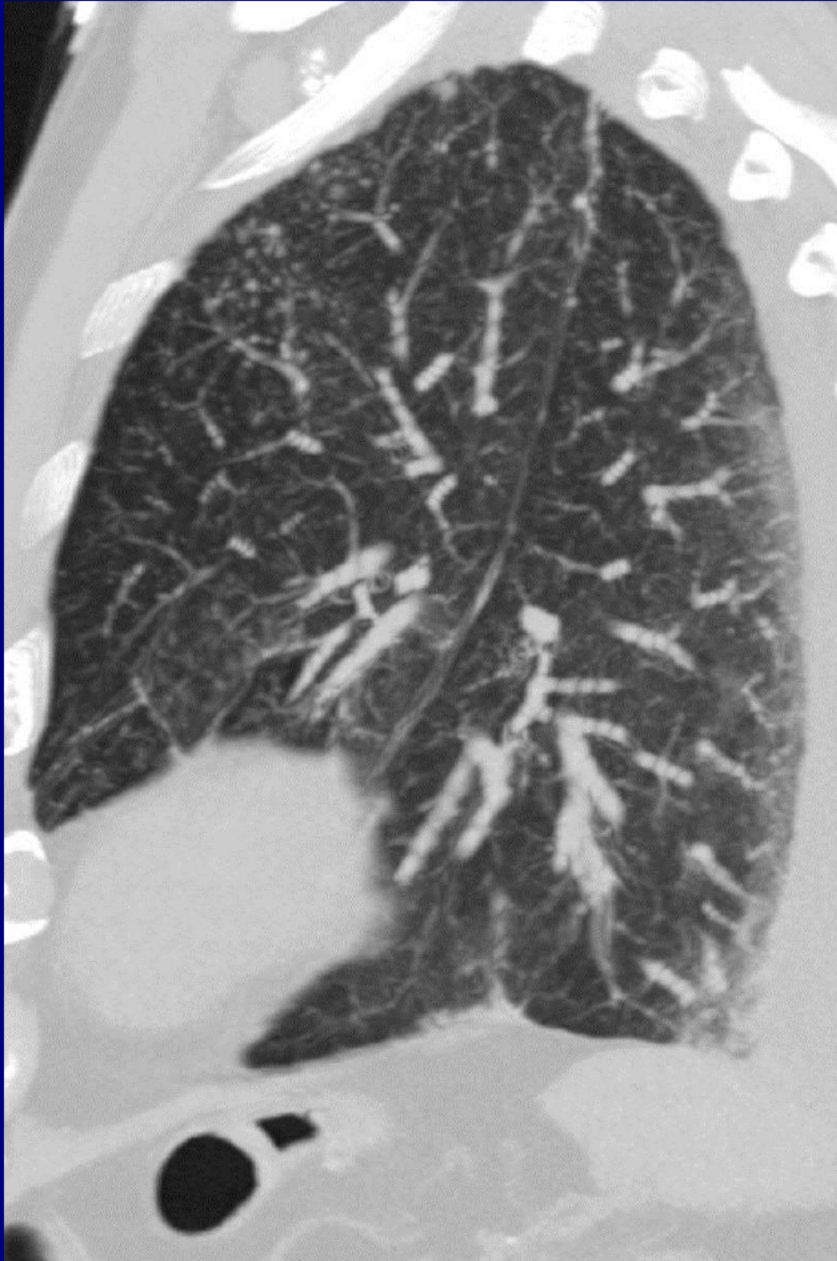
89-year-old former foundry worker

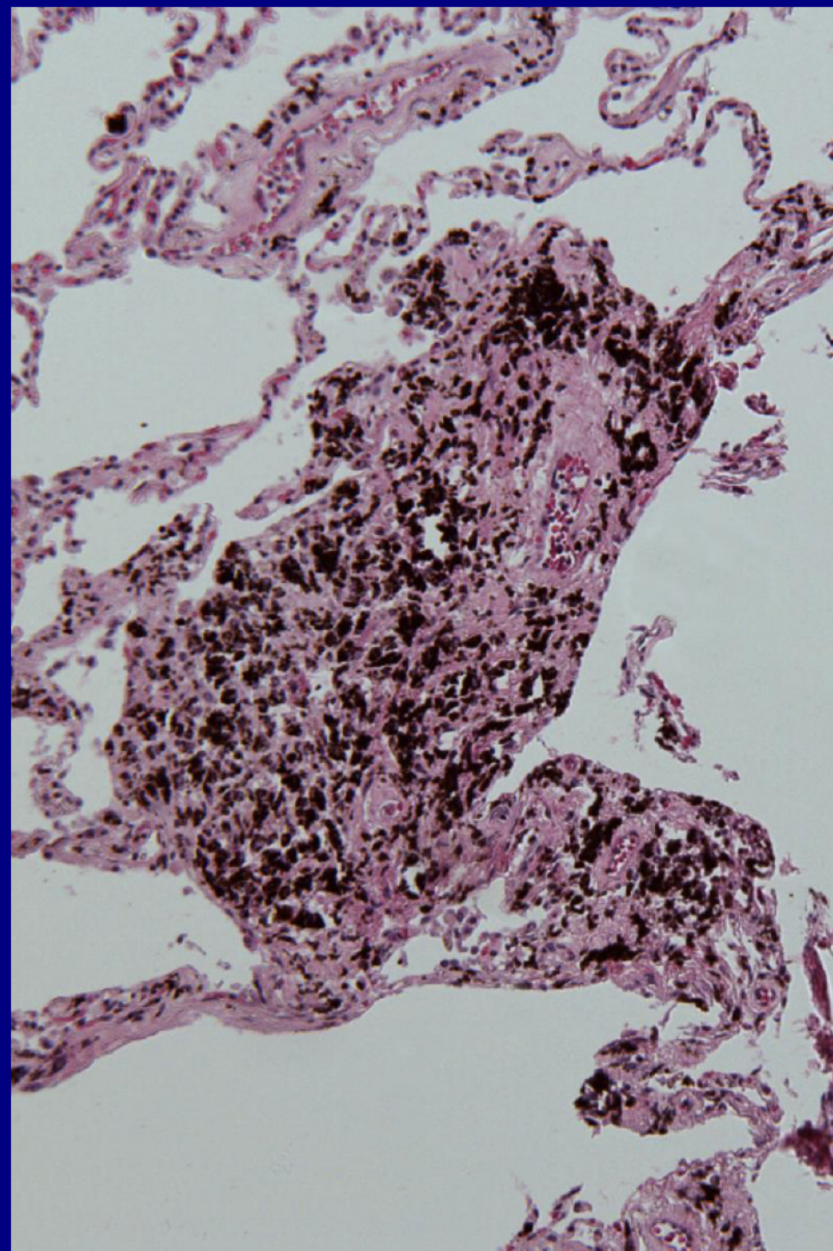
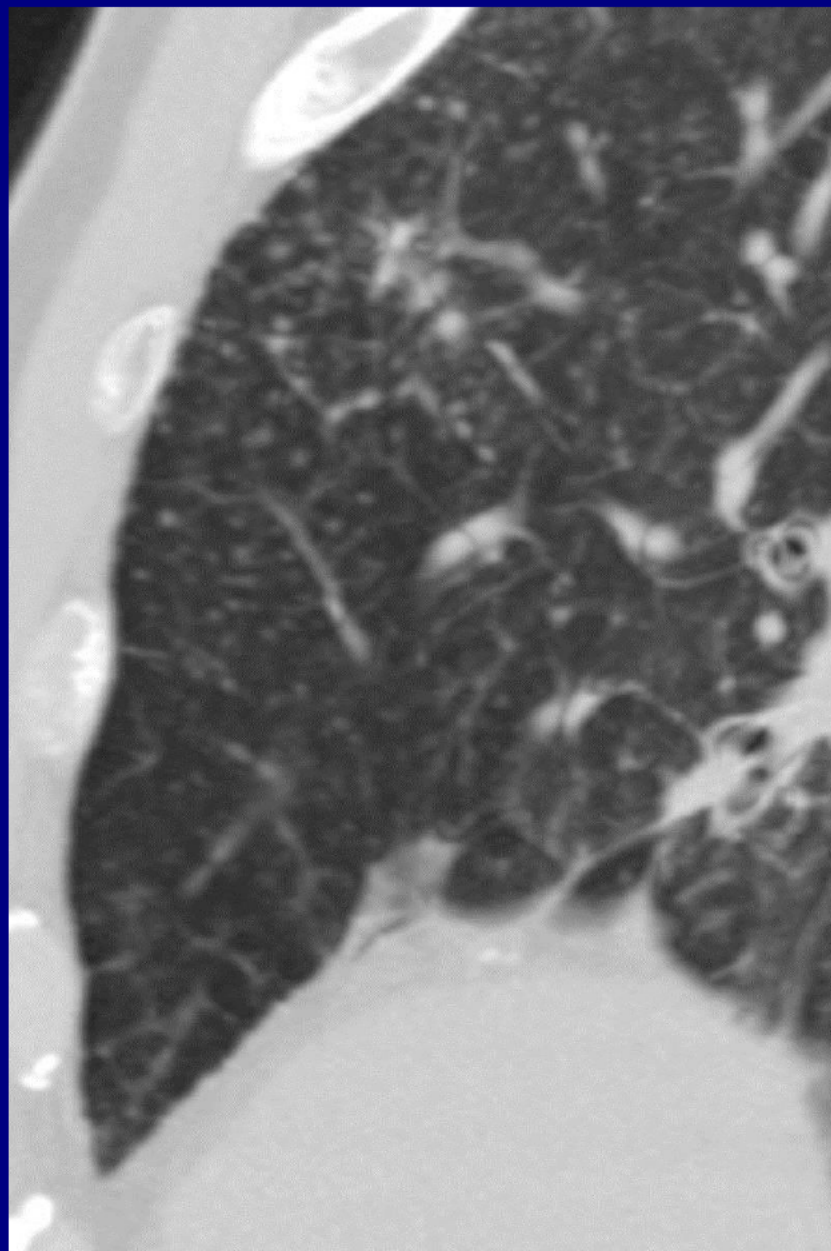
C



C



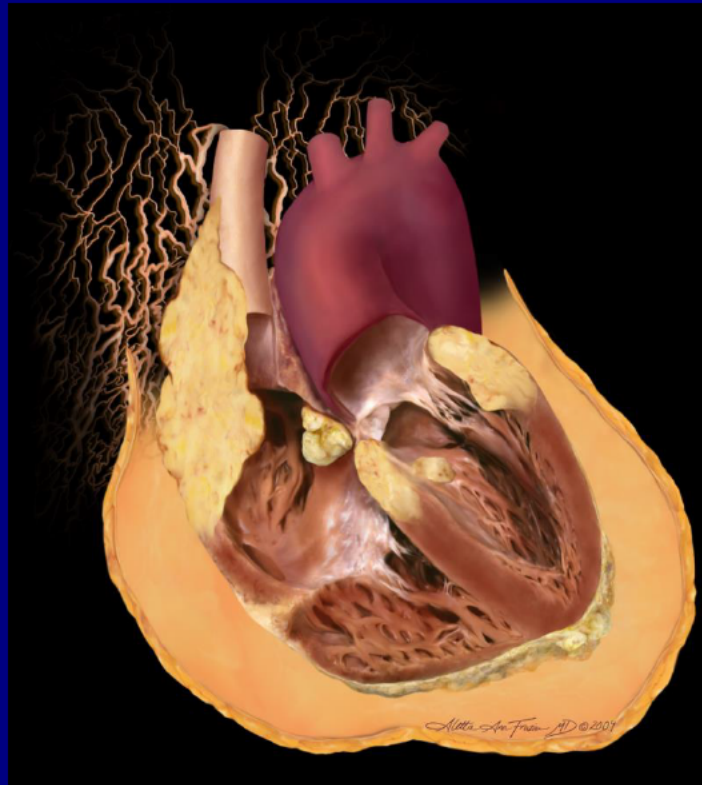



Mixed Dust Pneumoconiosis

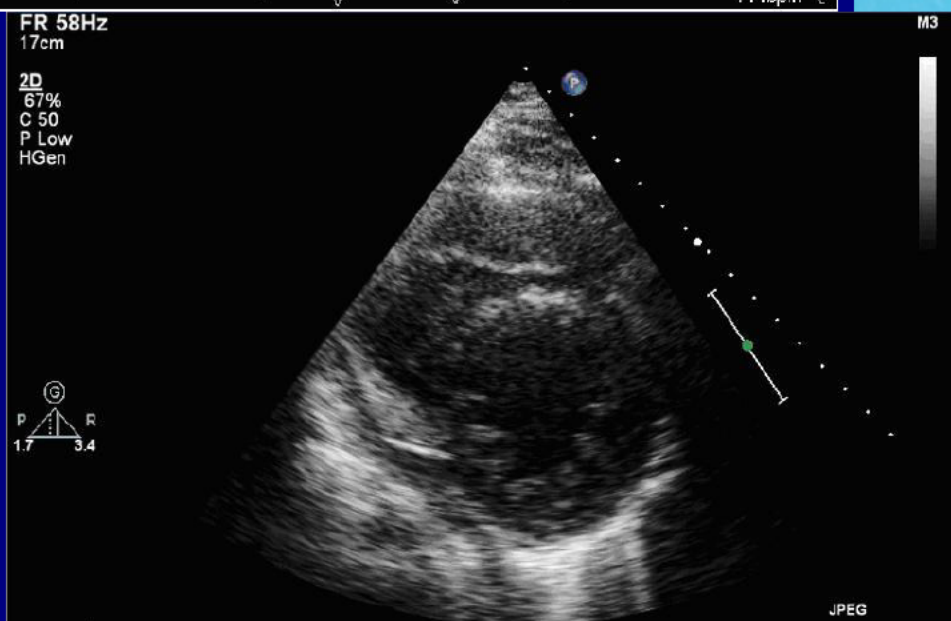
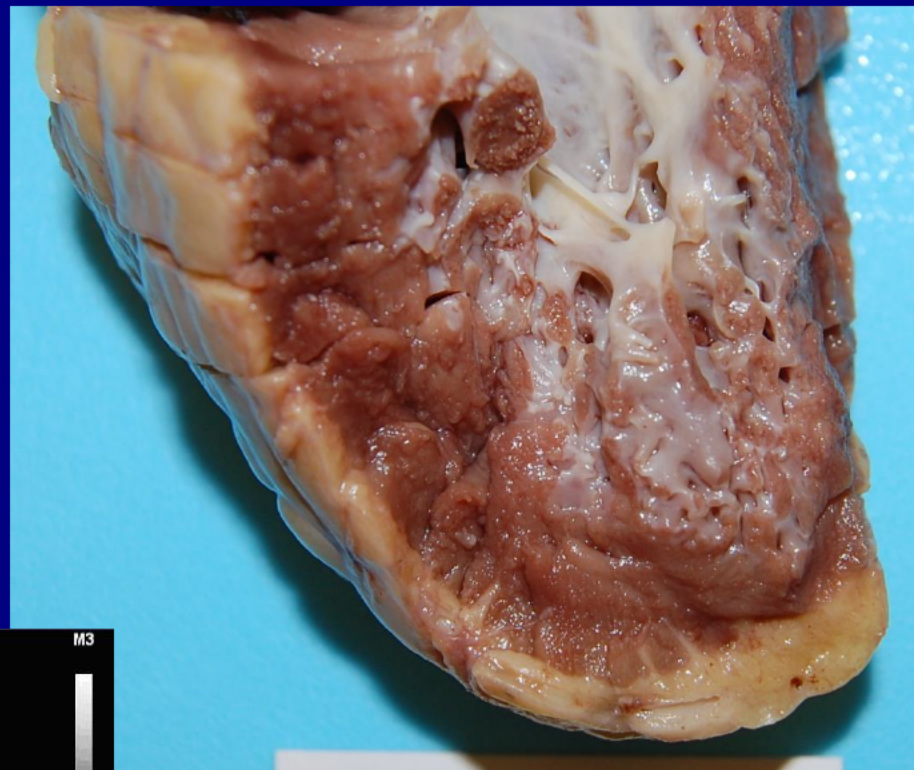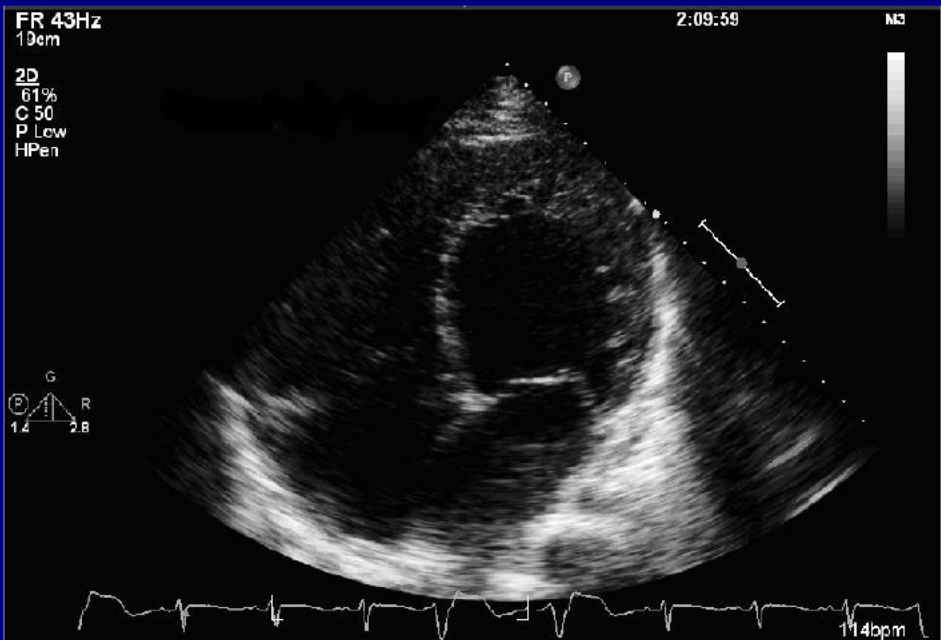
Shaan Shah
Brigham and Women's Hospital
Boston, Massachusetts

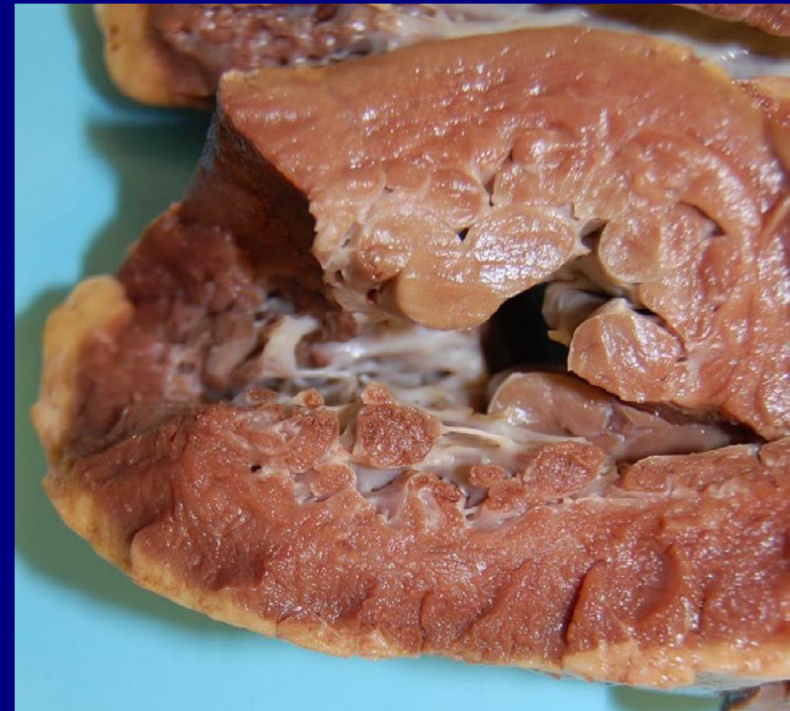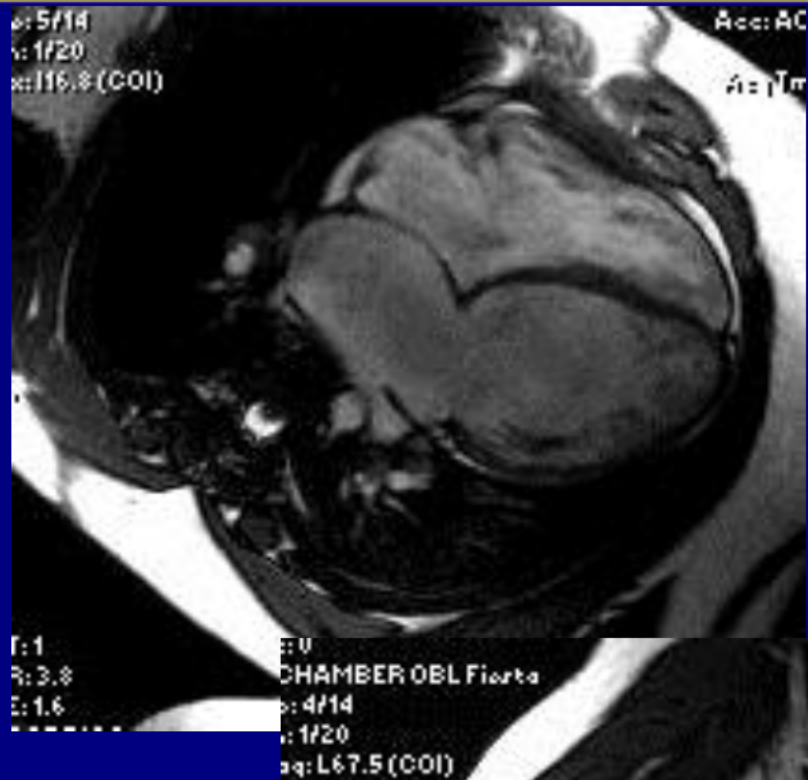
Cardiovascular Imaging

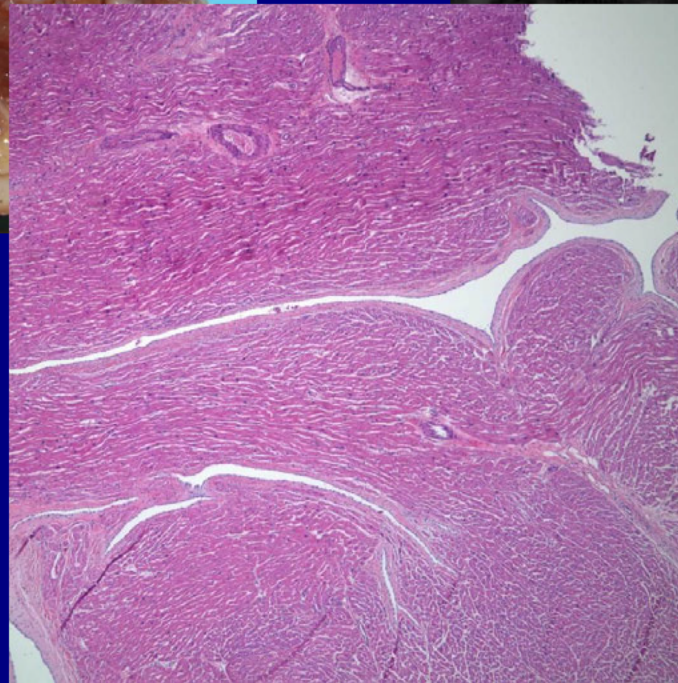
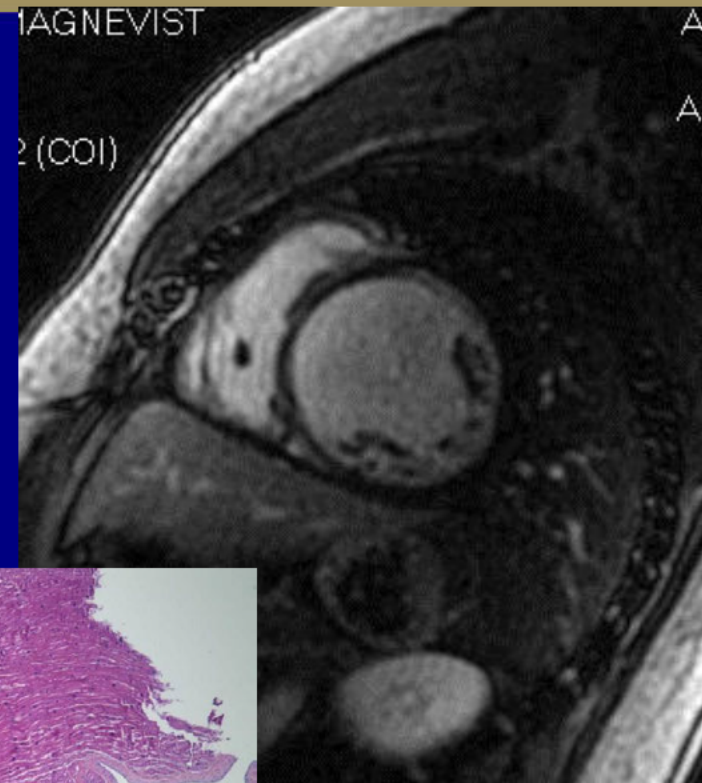
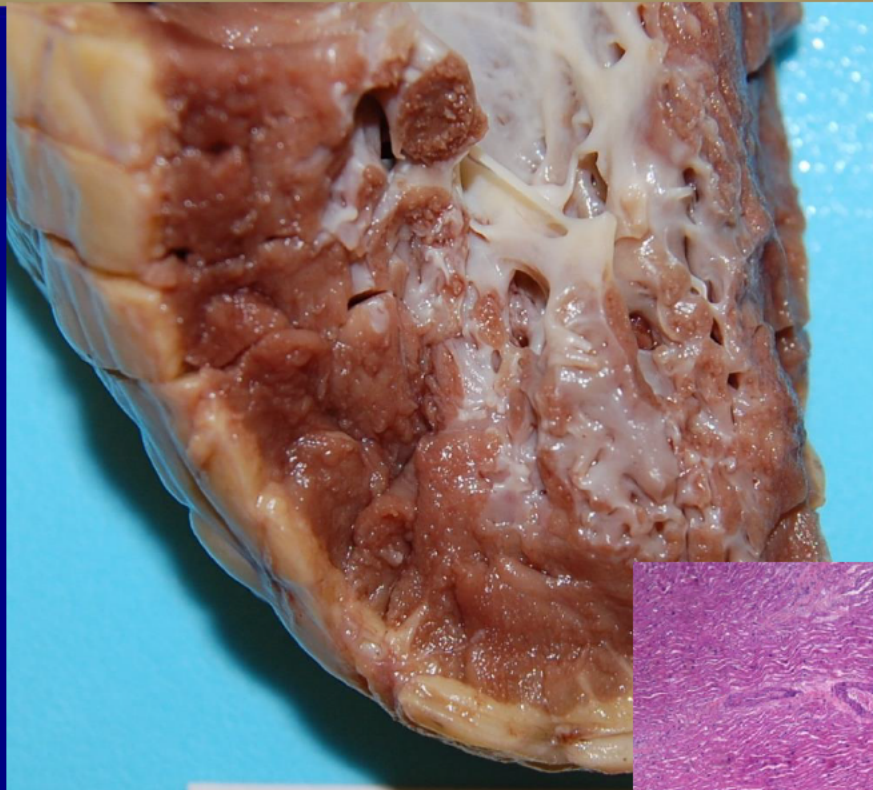


17 year old male with family history of cardiomyopathy presents with dyspnea and progressive cough, productive of red sputum. CXR suggestive pneumonia, and he was treated with antibiotics.

Symptoms, however, worsened and he developed lower extremity edema and orthopnea. B-type natriuretic peptide levels increased (669 to 2439); troponins remained negative. Patient subsequently underwent orthotopic heart transplant.







Left Ventricular Noncompaction

Christine Kim

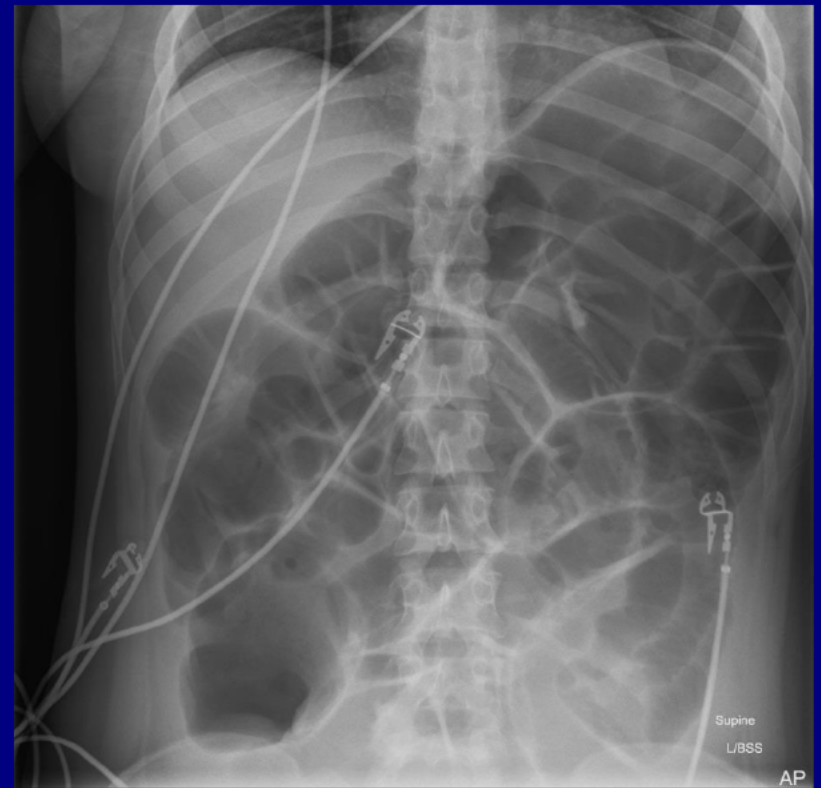
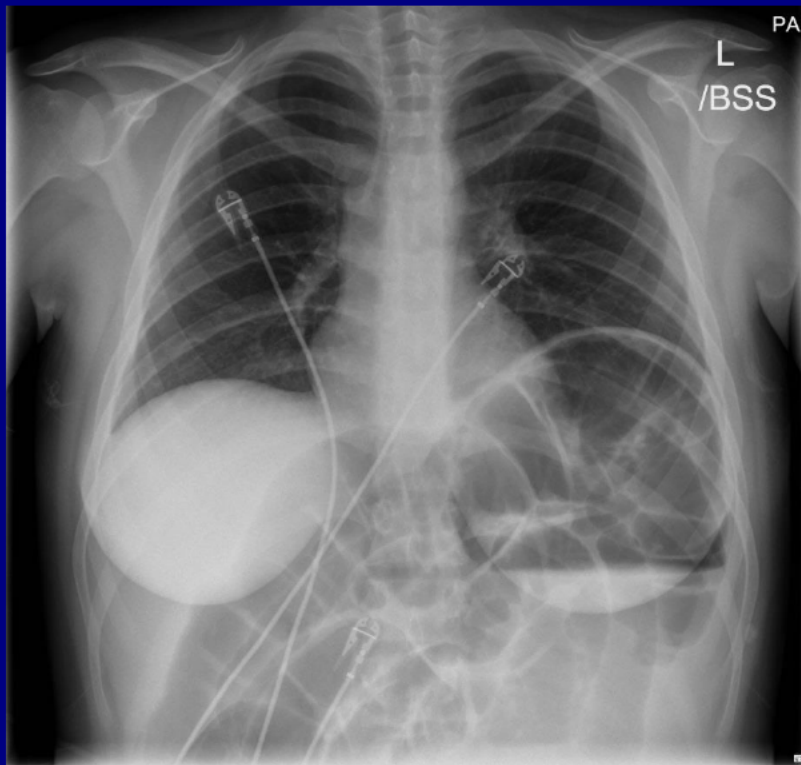
University of Connecticut Health Center
Farmington, Connecticut

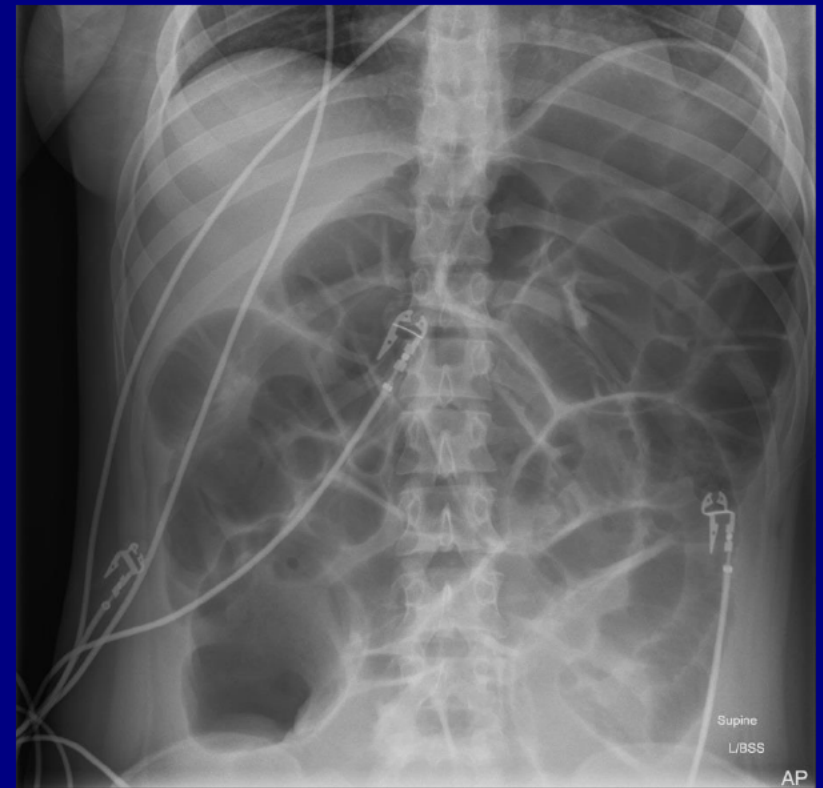
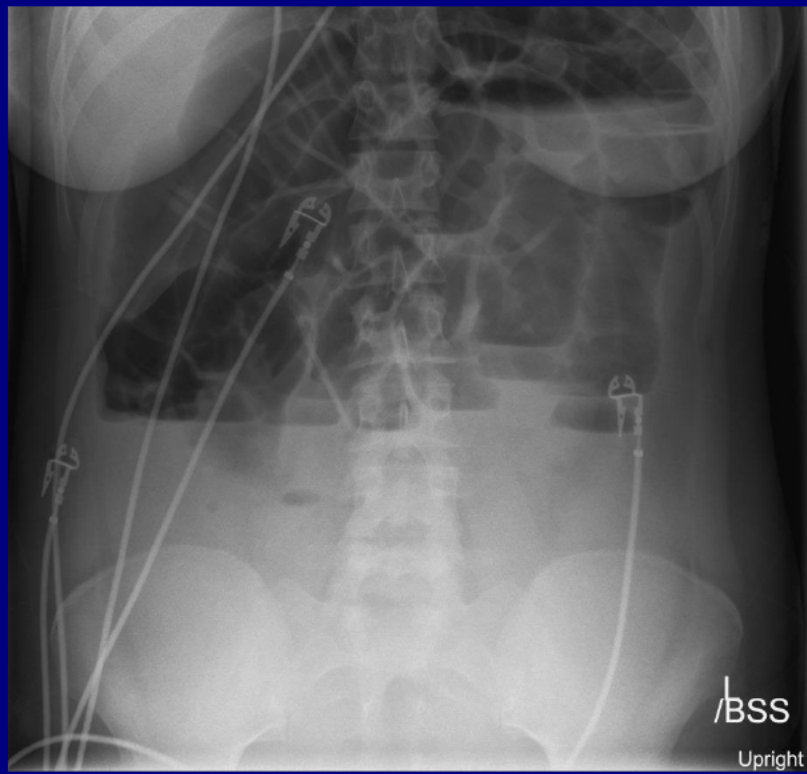
A rare disorder of endomyocardial morphogenesis characterized by thin epicardium but thick endocardium (characterized by excessive trabeculations & deep intratrabecular recesses). Complications & prognosis are variable (depending on degree of severity).

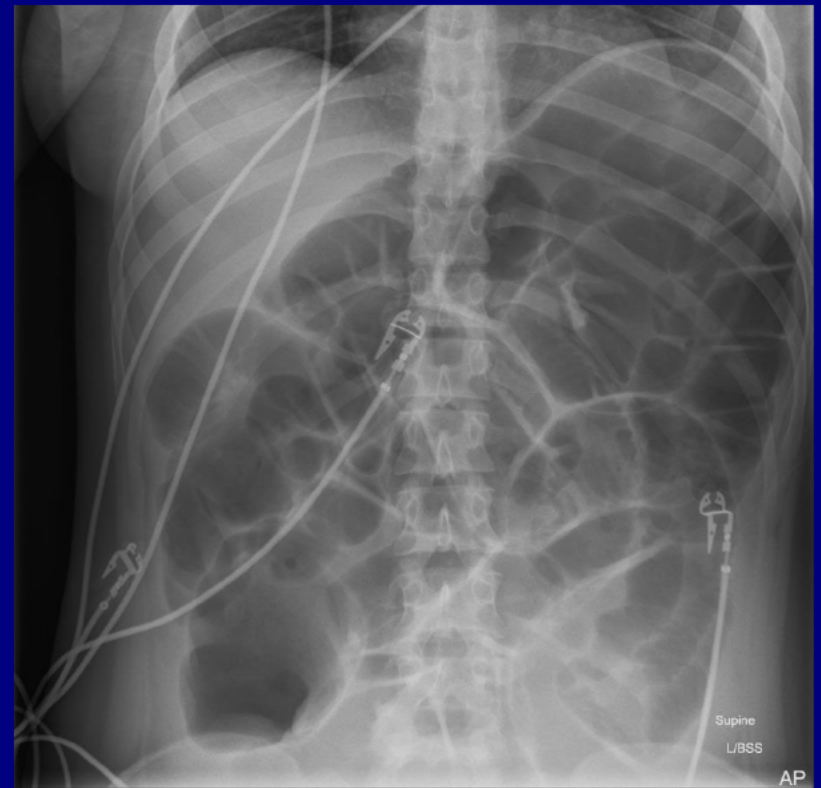
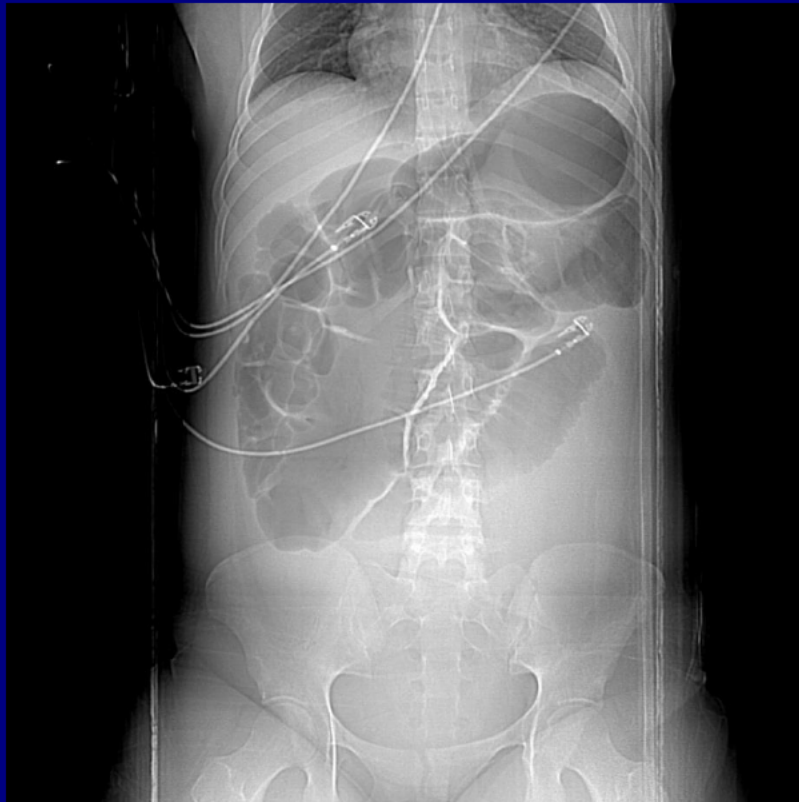Patients may require heart transplantation.

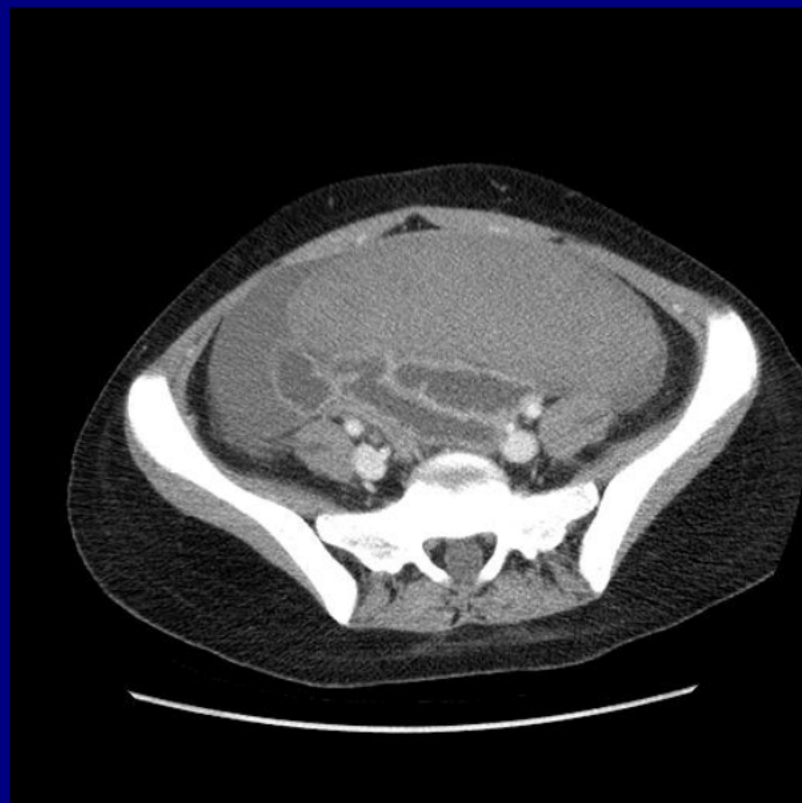
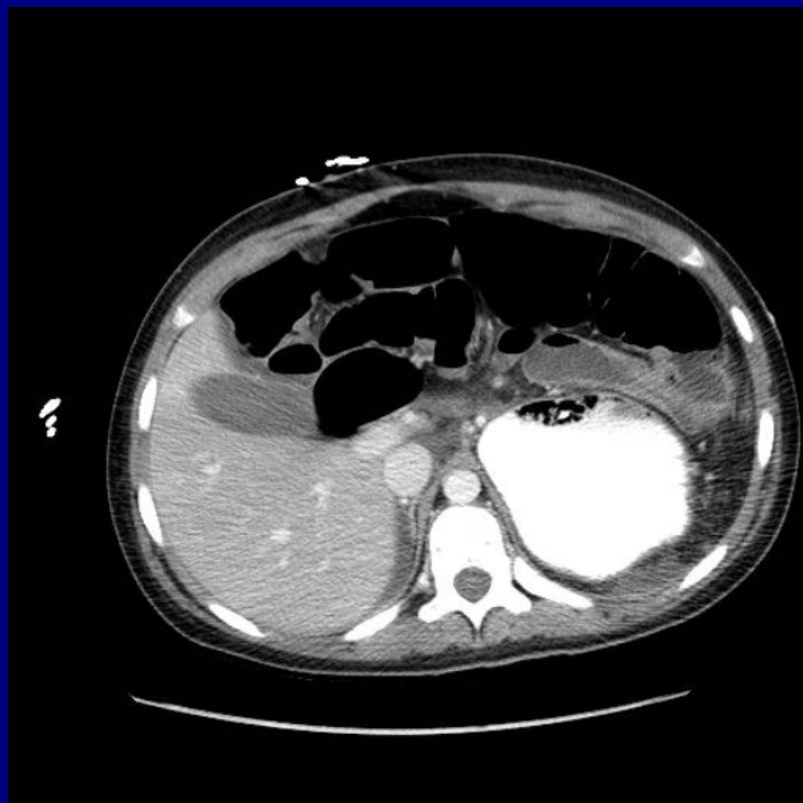Pediatric Best Case

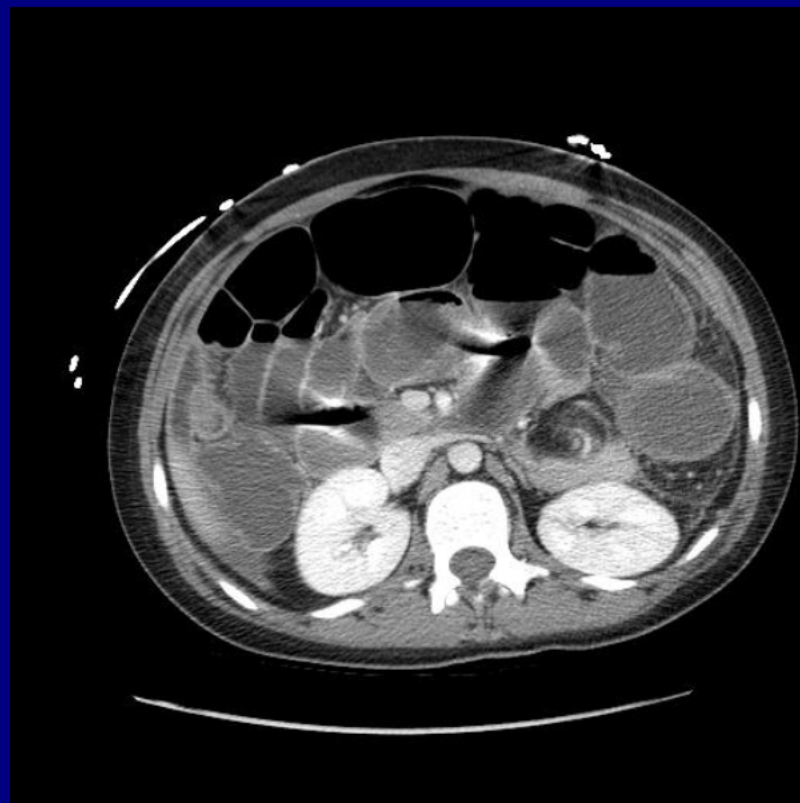
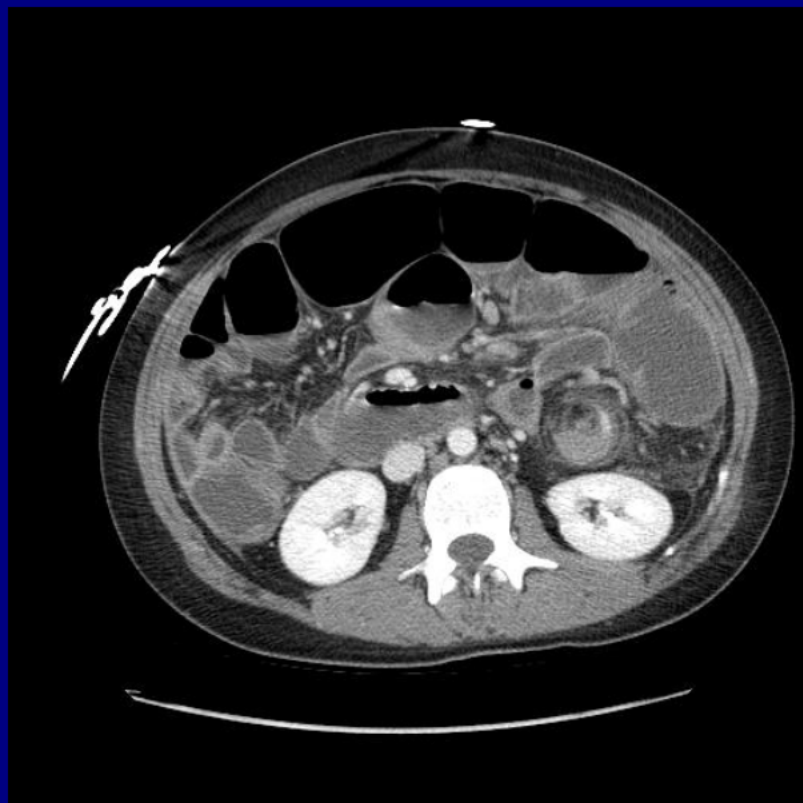
17-year-old girl hospitalized for
craniotomy for ruptured arachnoid cyst
who developed post operative
refractory nausea

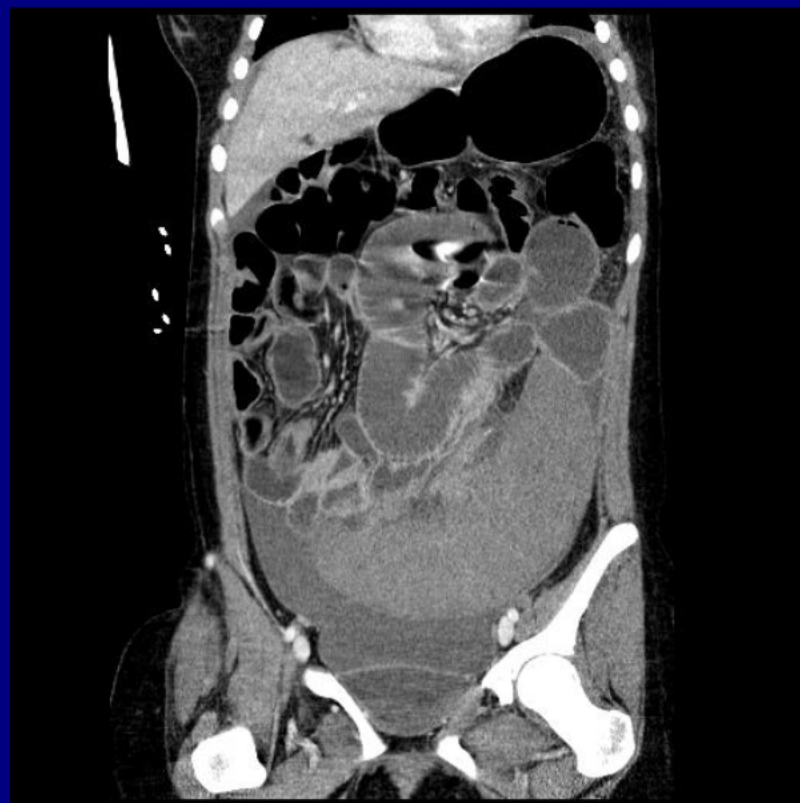
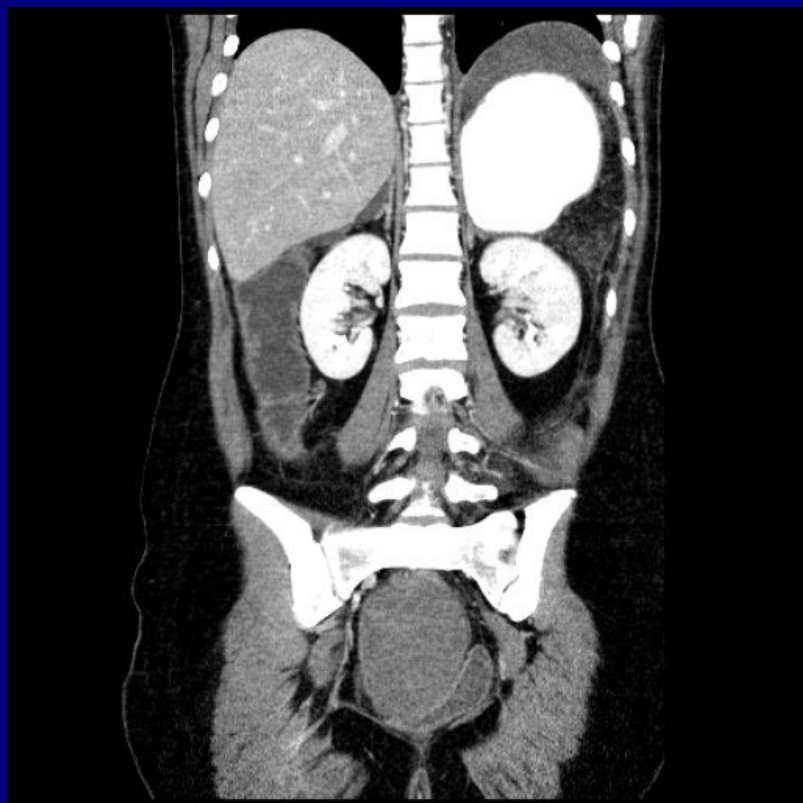


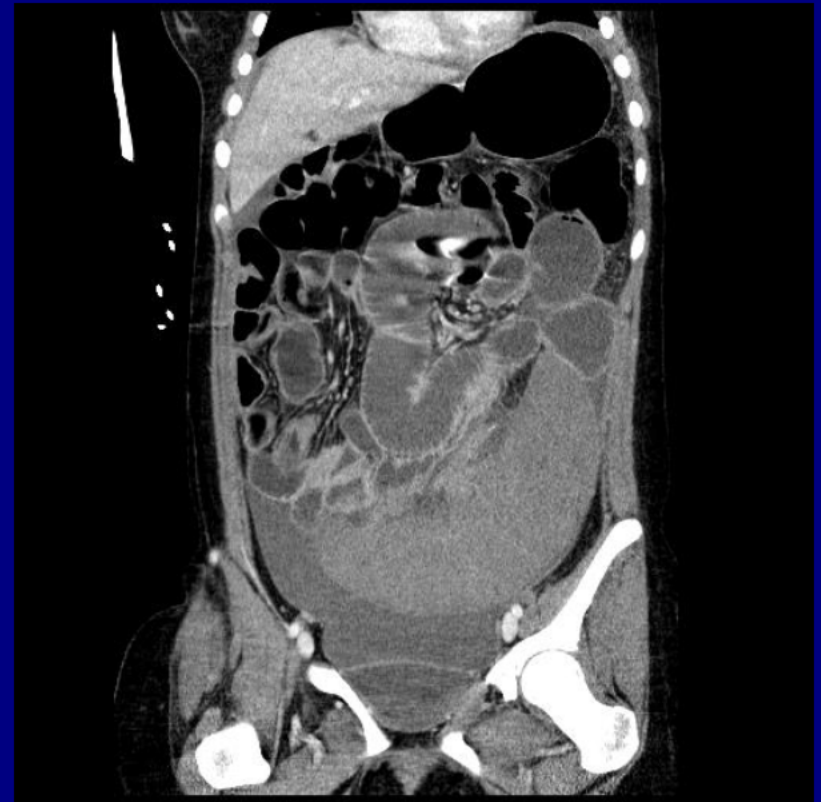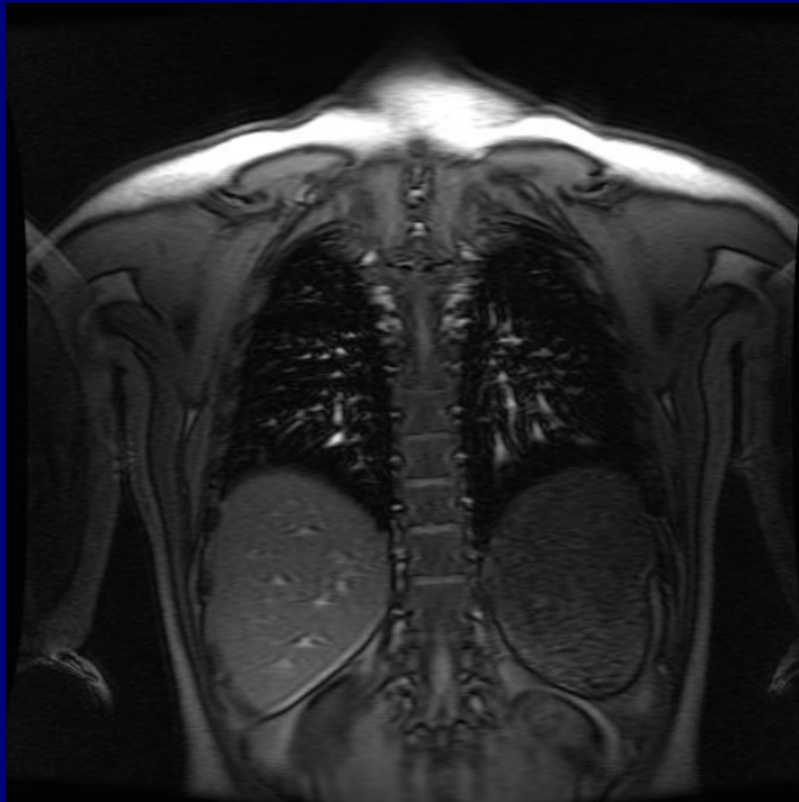


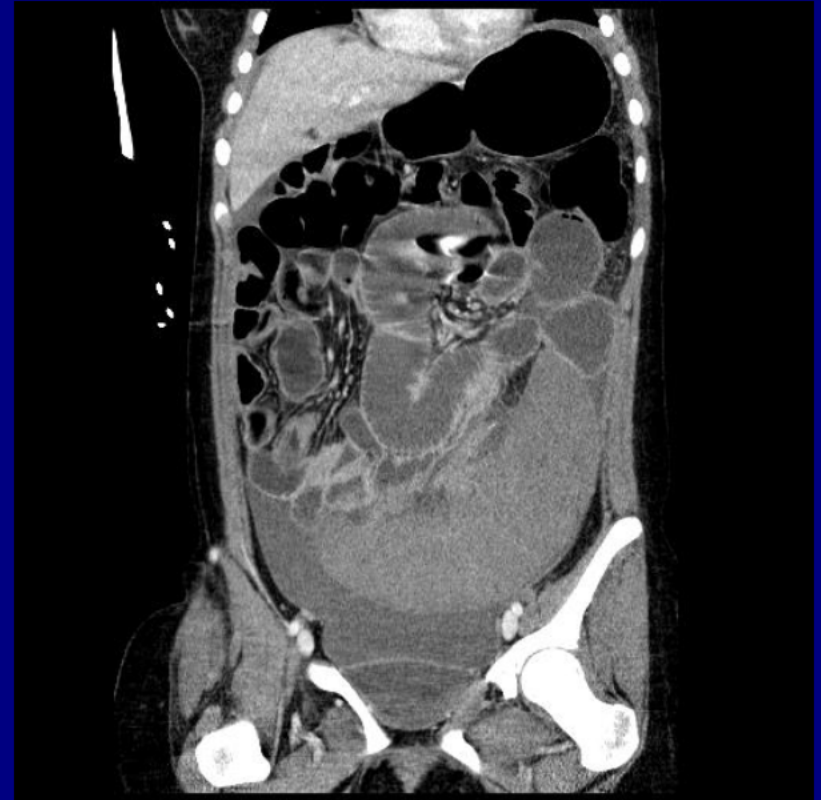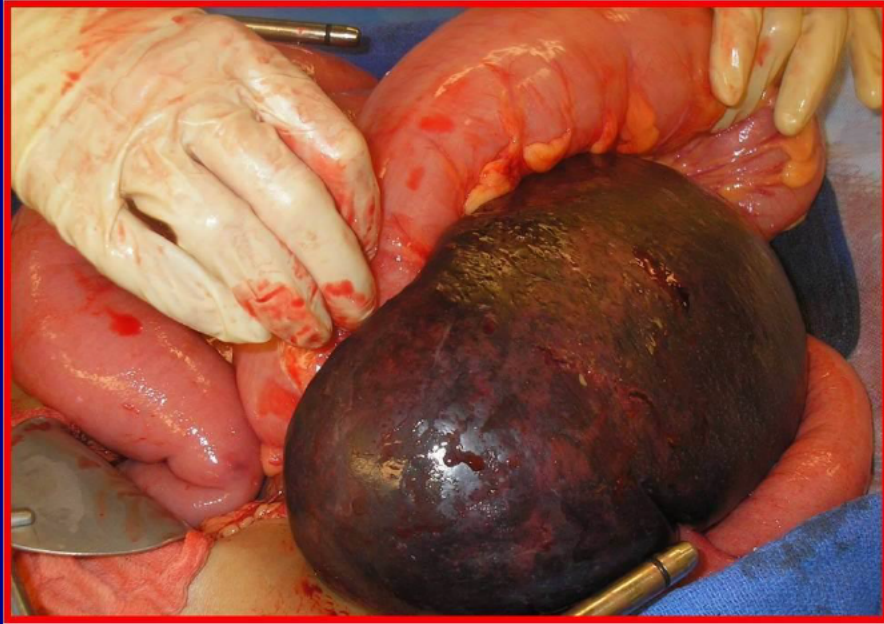










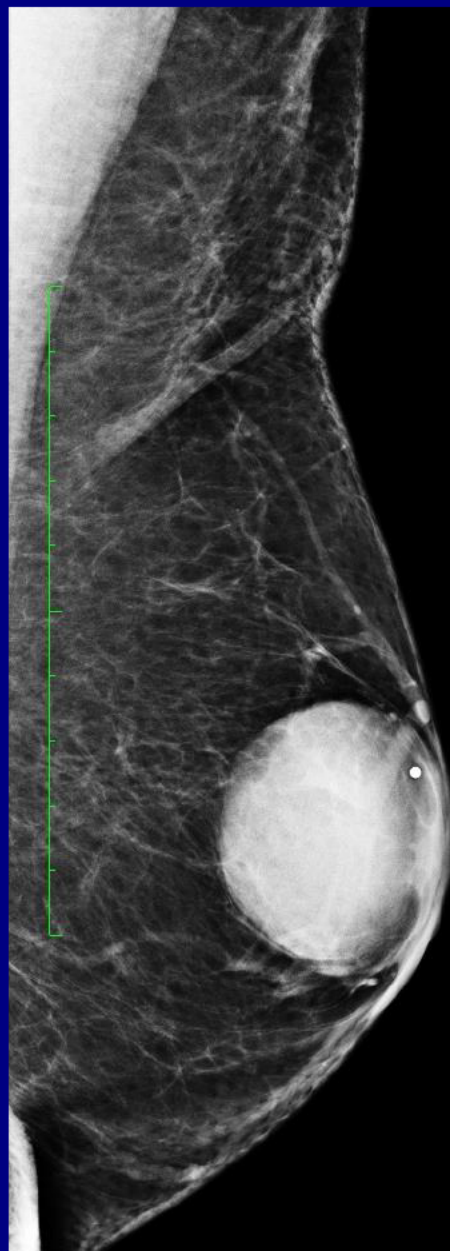
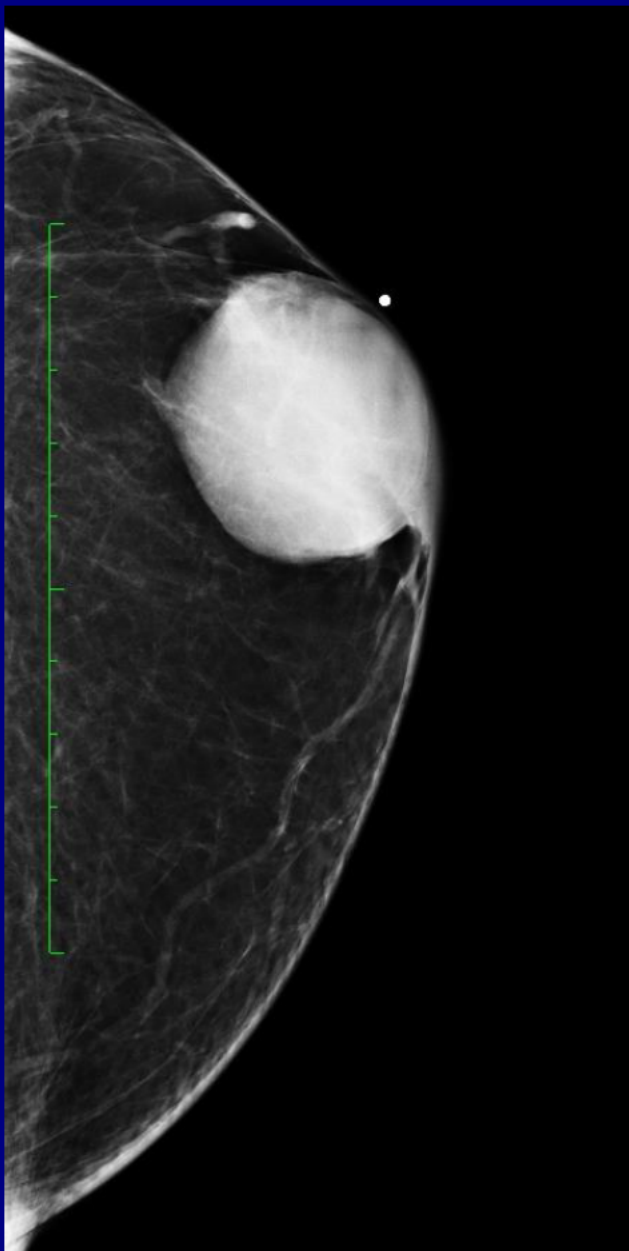


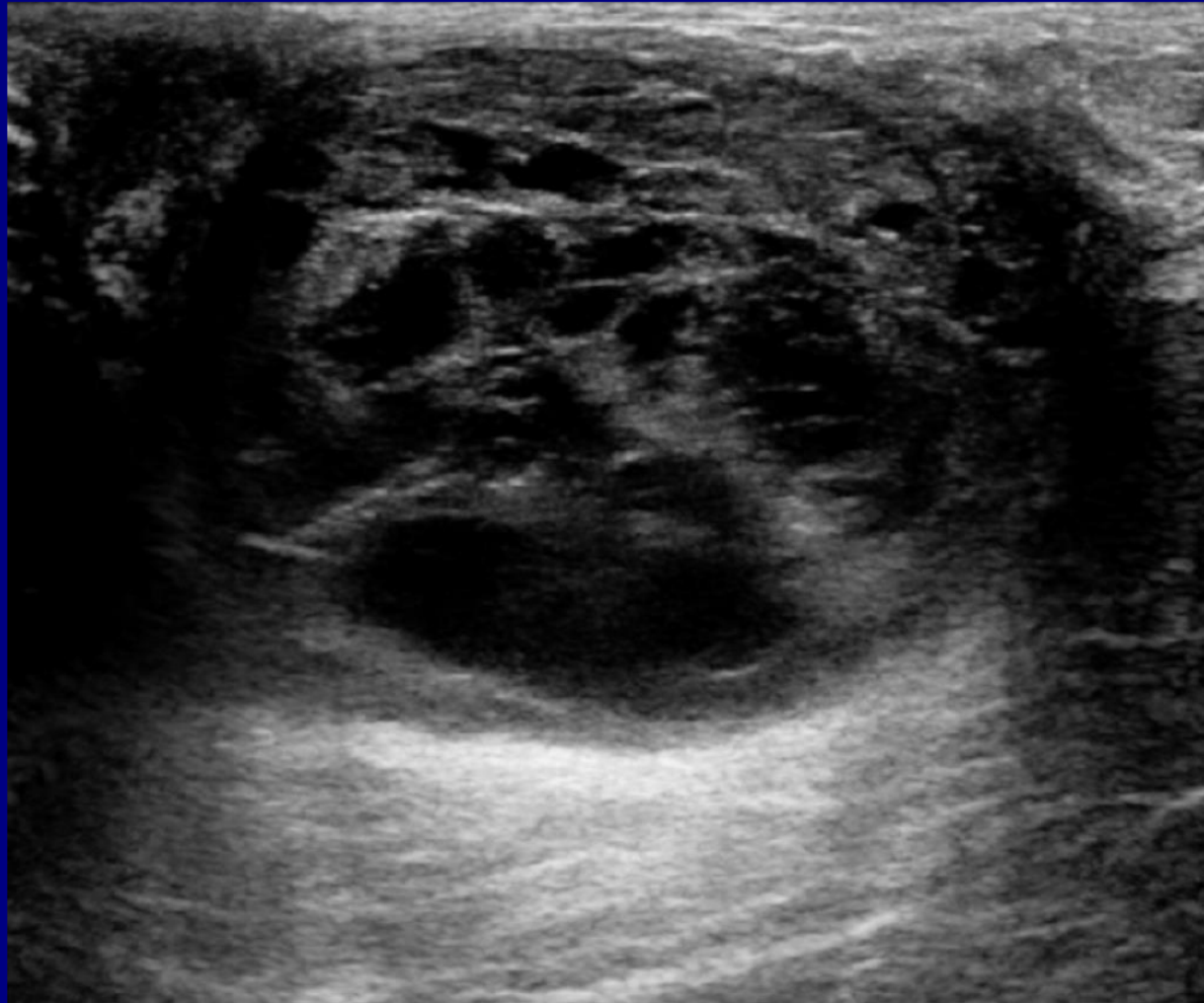Torsion and infarction of wandering spleen and sigmoid volvulus

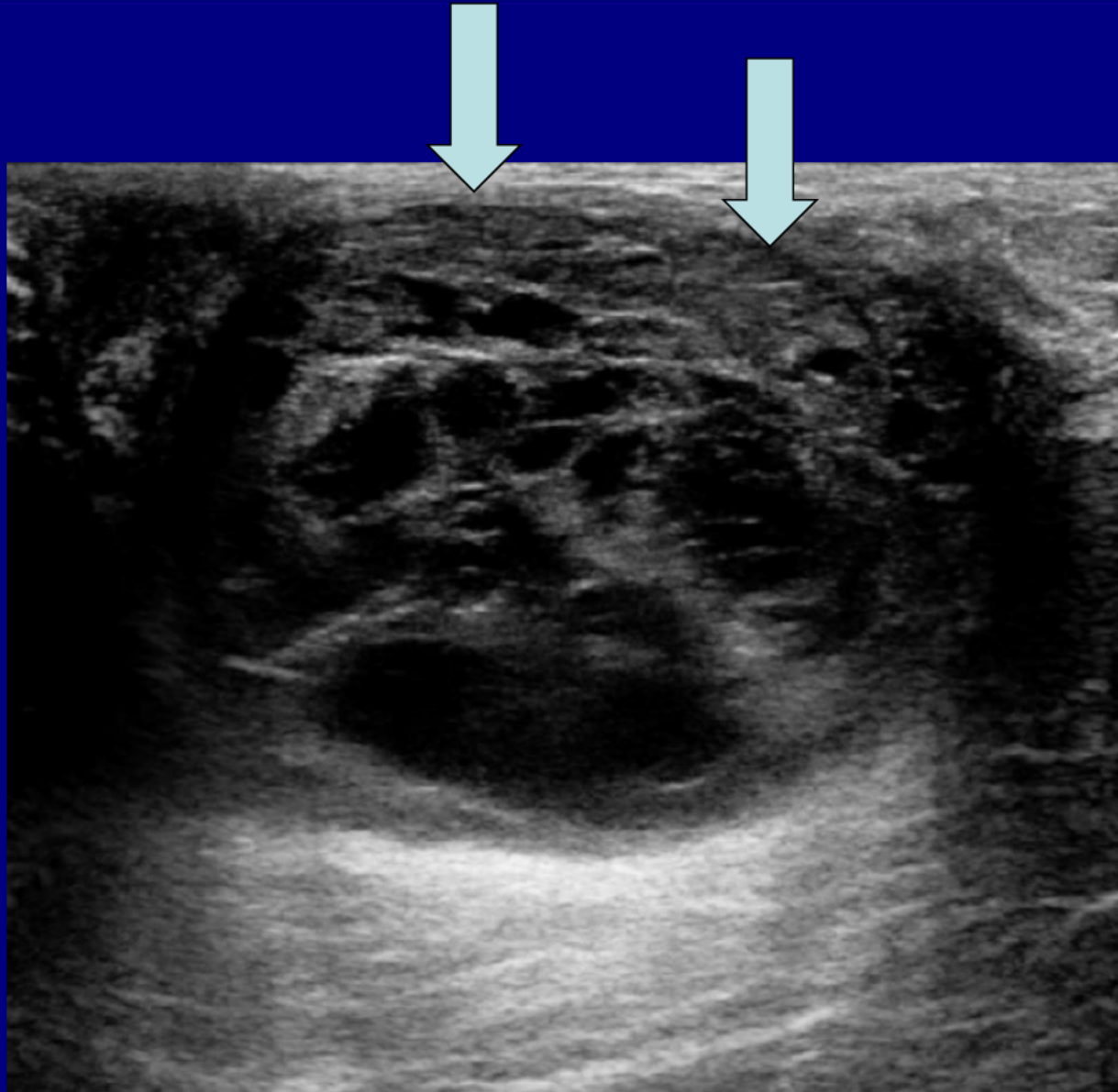
Daniel Gibson
Dartmouth-Hitchcock Medical Center
Lebanon, New Hampshire

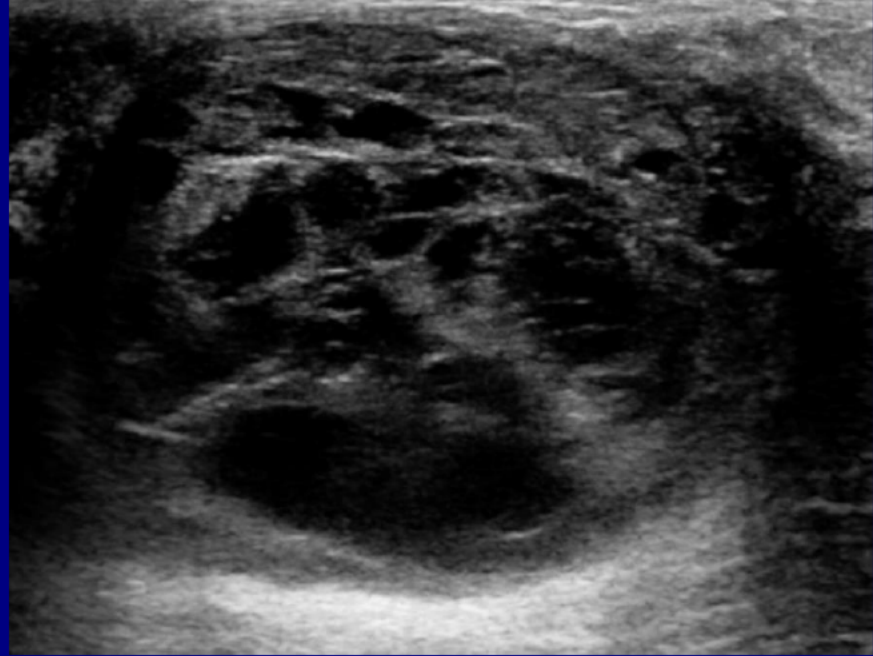
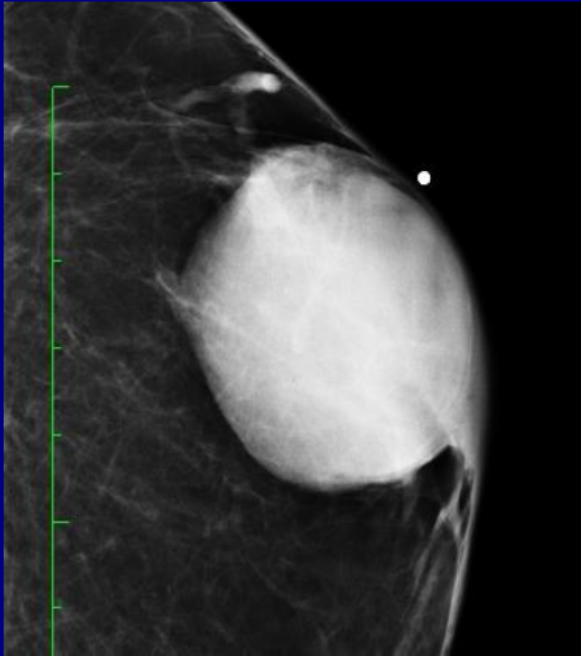
Breast Best Case

57 year old male with an
enlarging left breast mass for
approximately 1 year

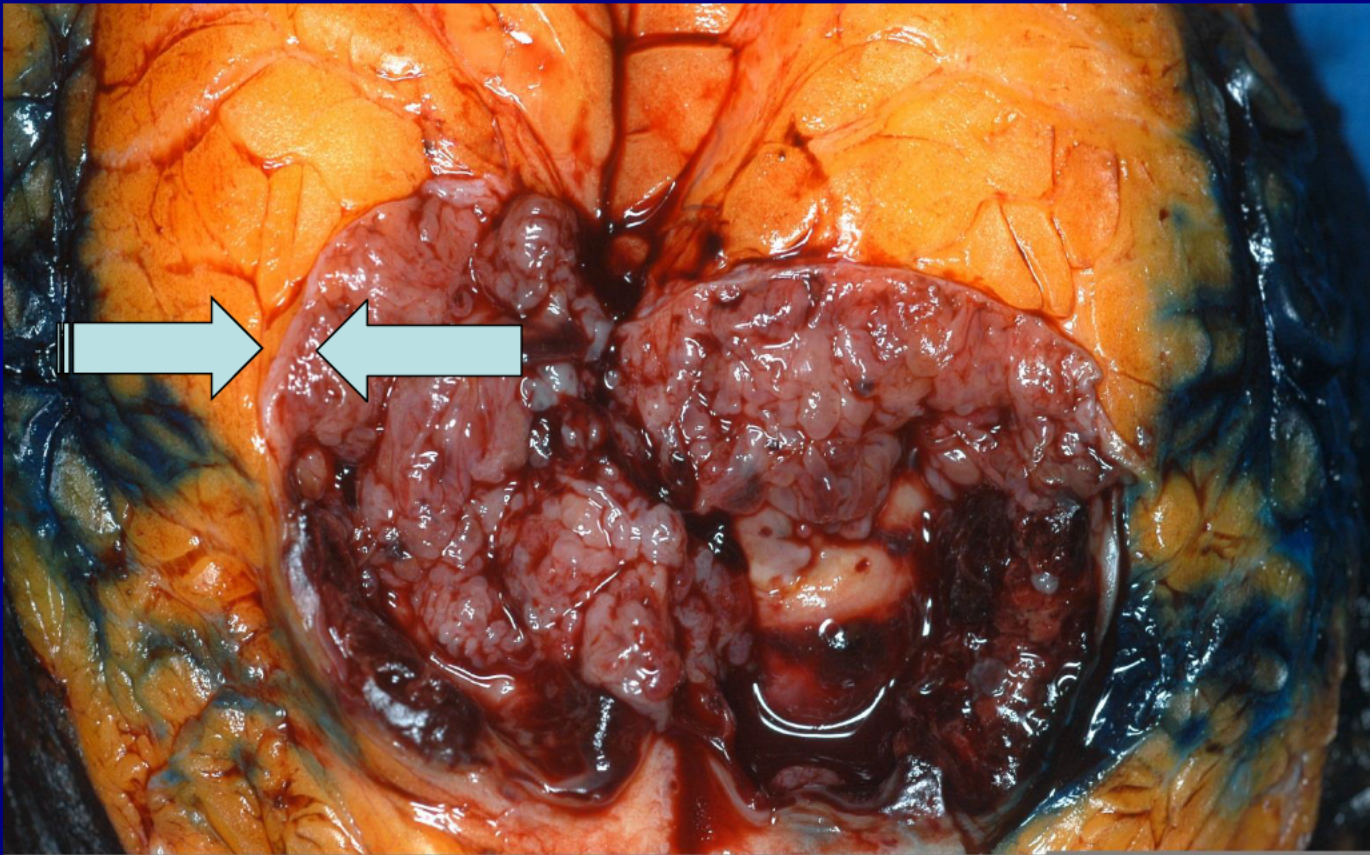








Encysted Papillary Carcinoma



Encysted Papillary Carcinoma

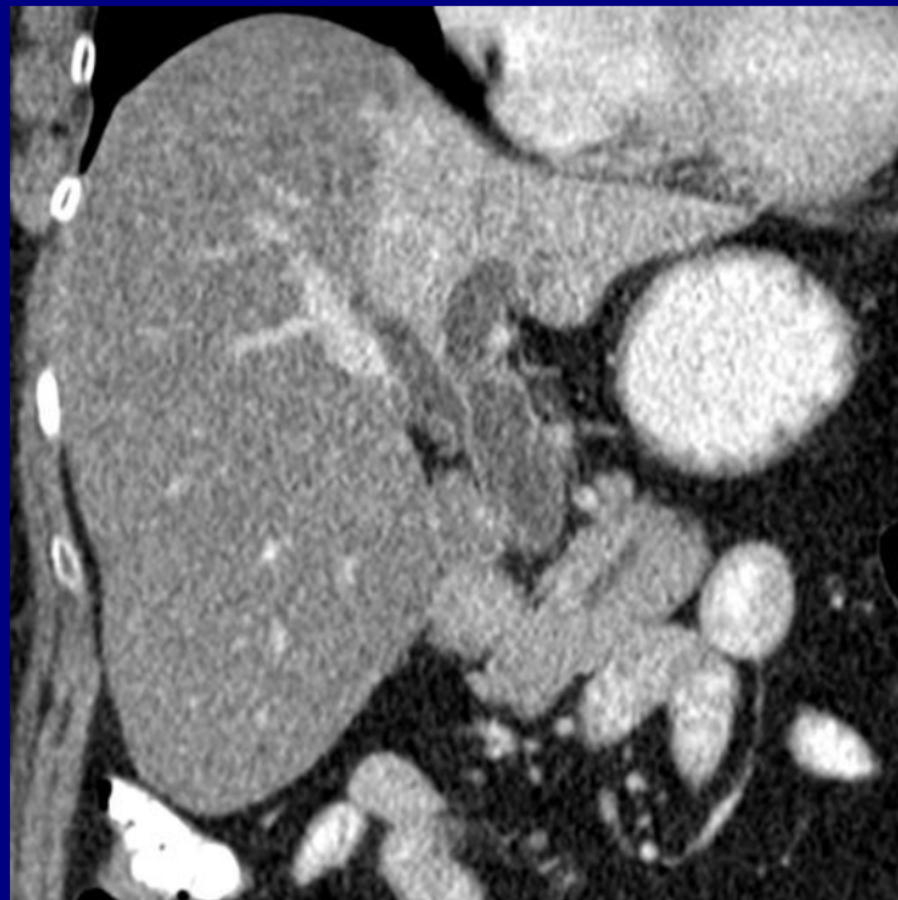
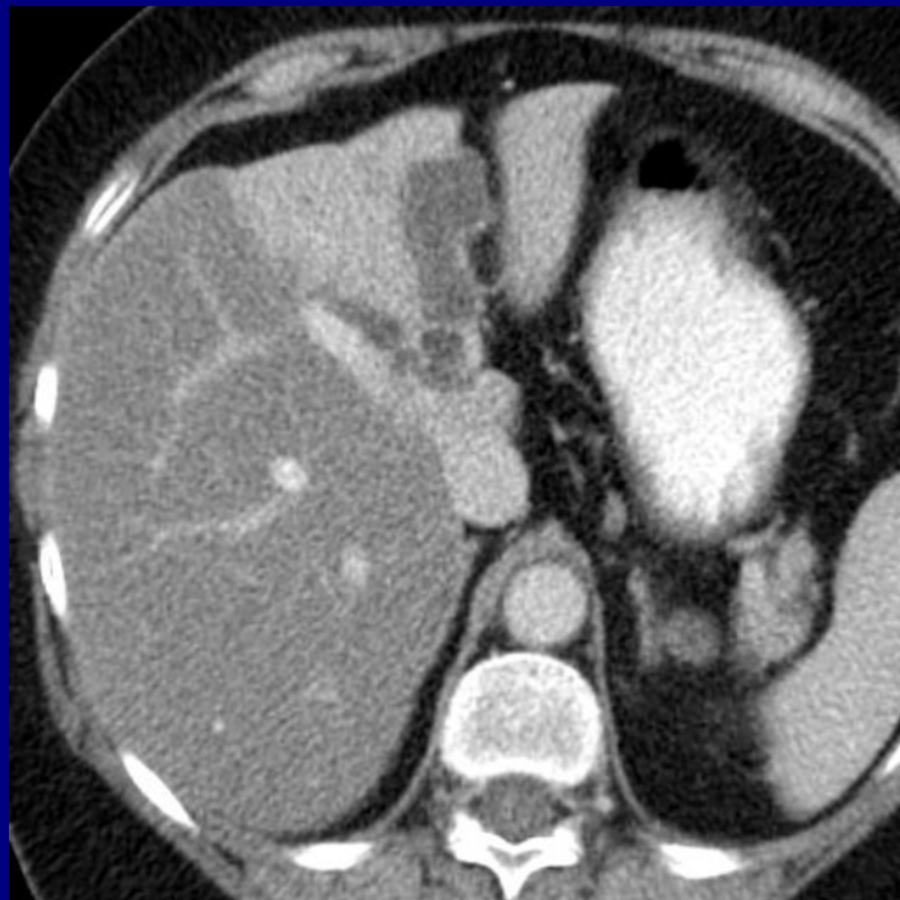Fred Dawson

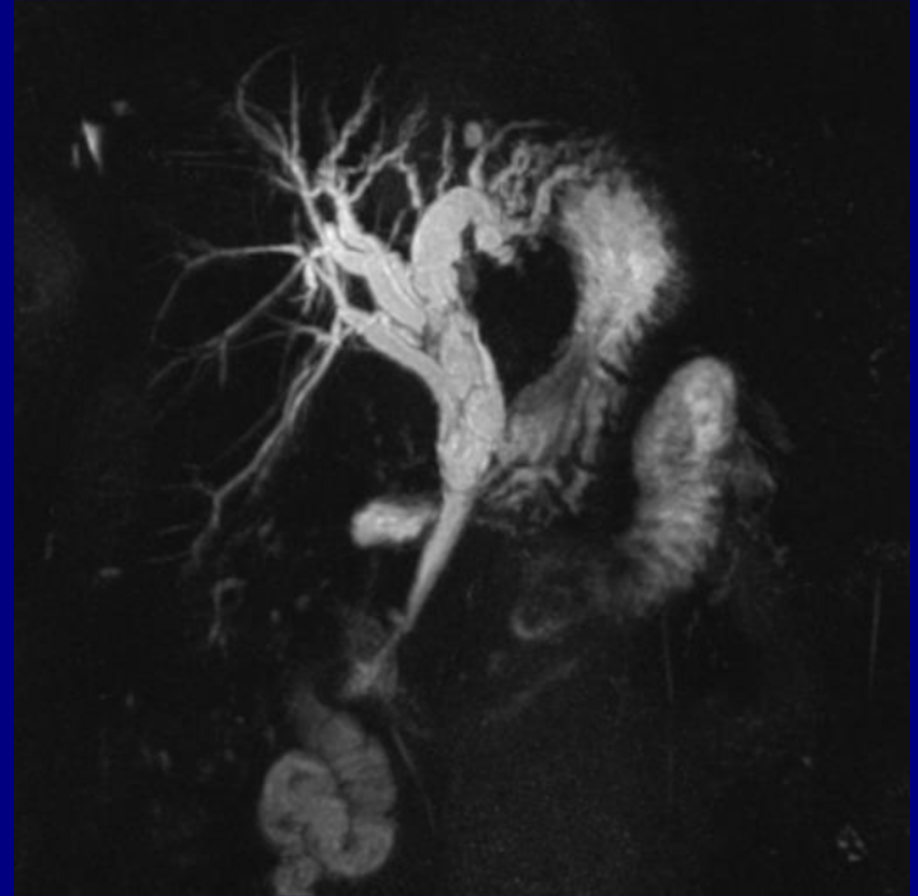
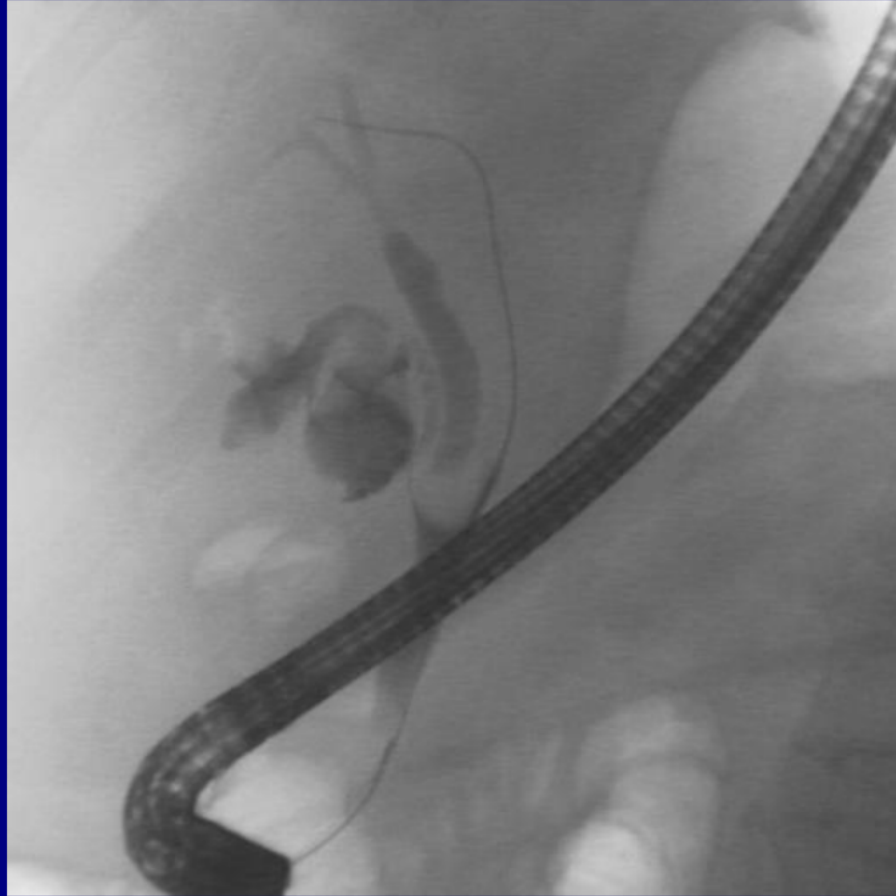
Indiana University School of Medicine

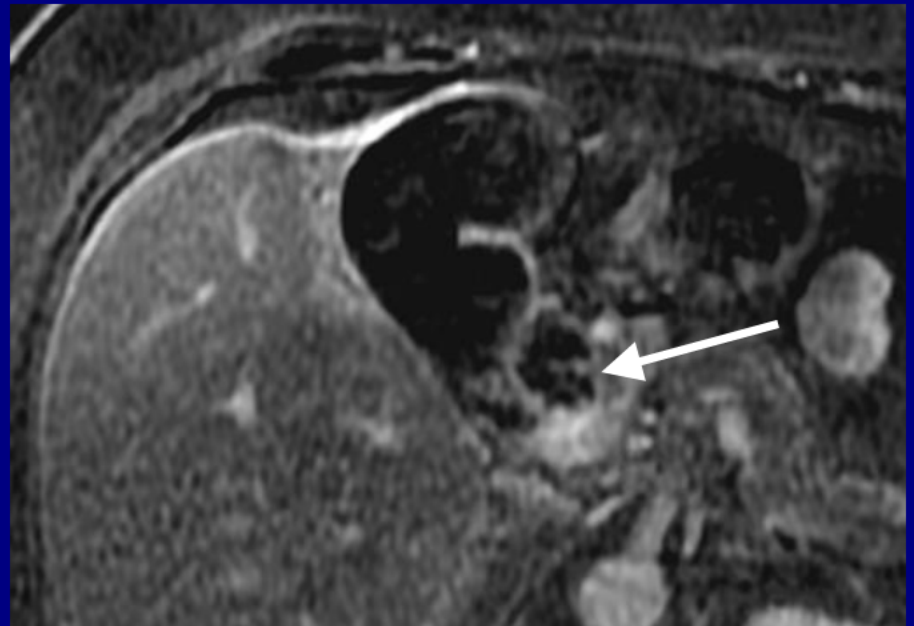
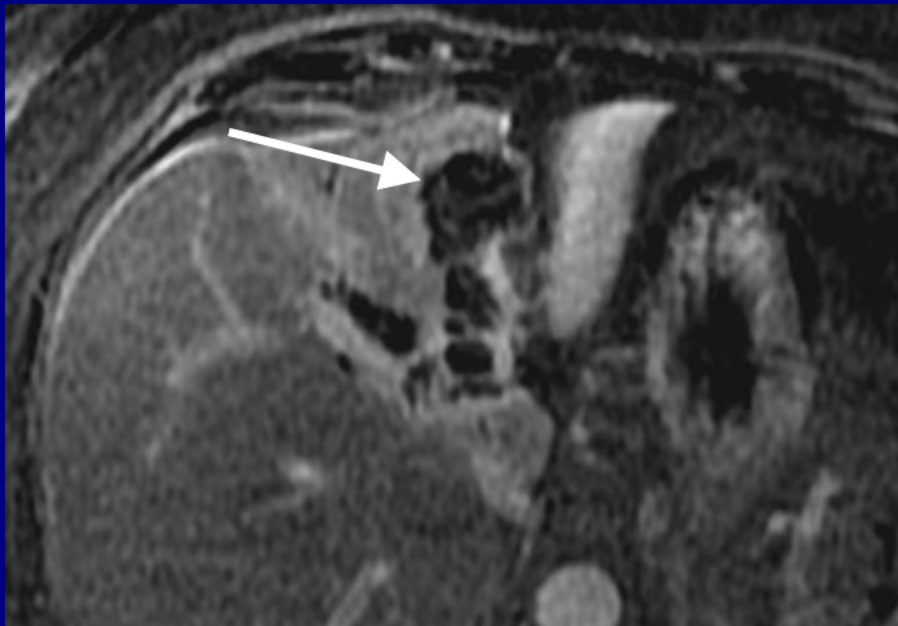
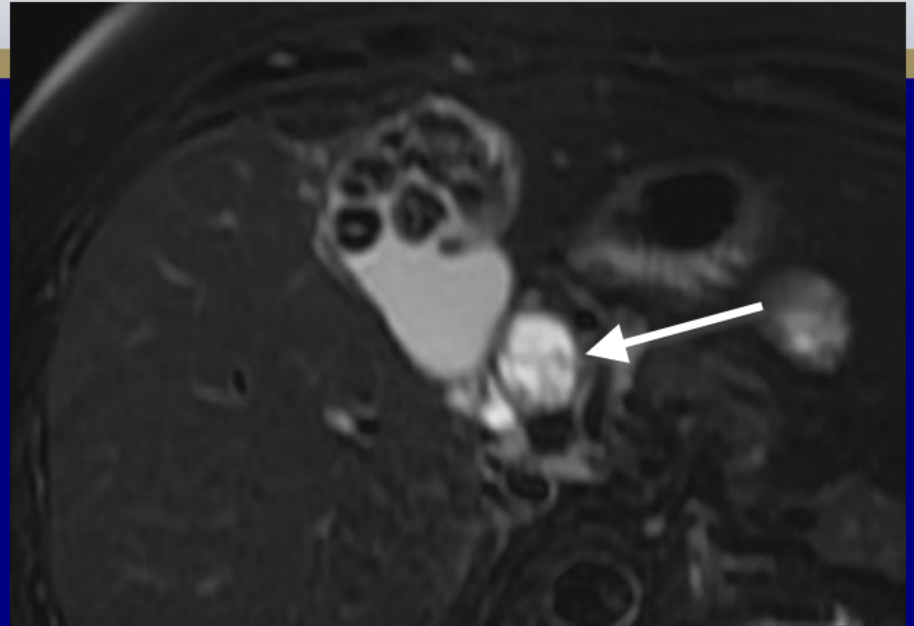
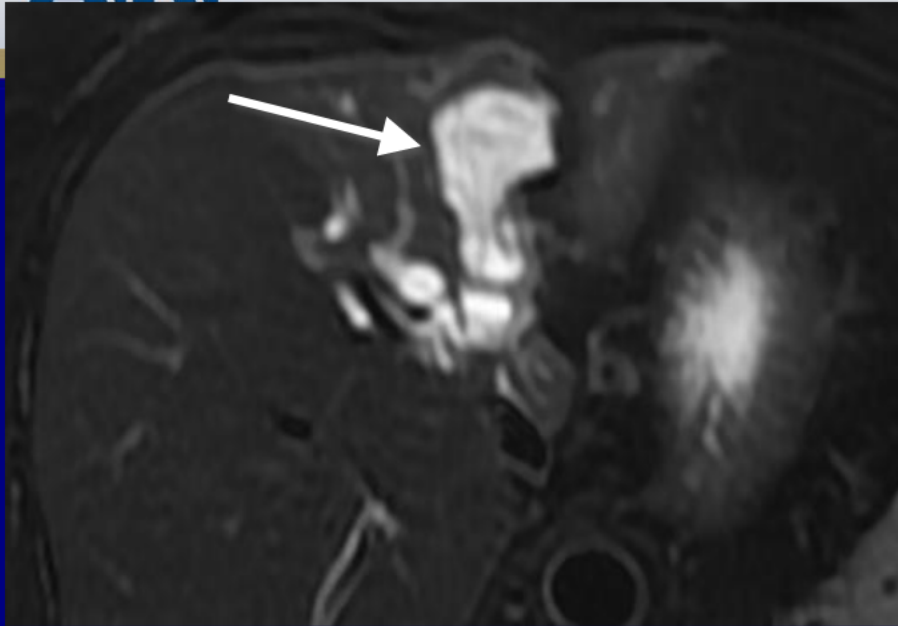
Indianapolis, IN

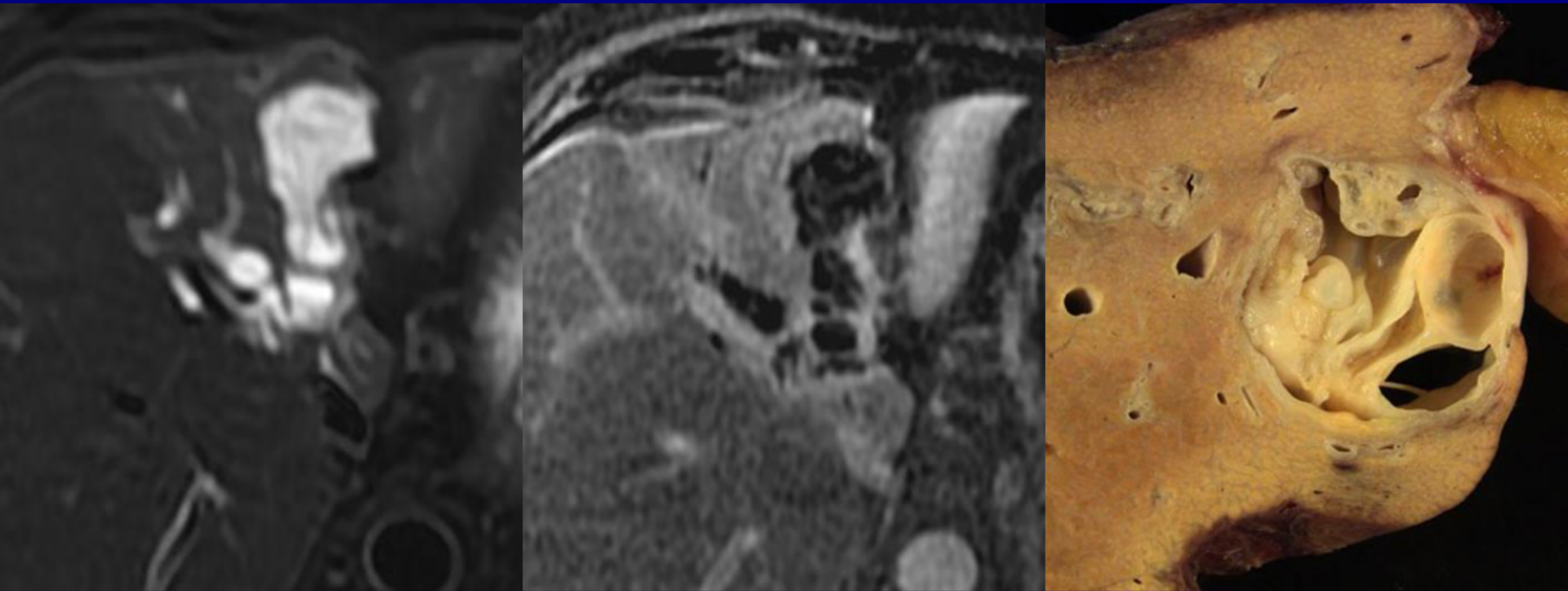
Gastrointestinal Best Case

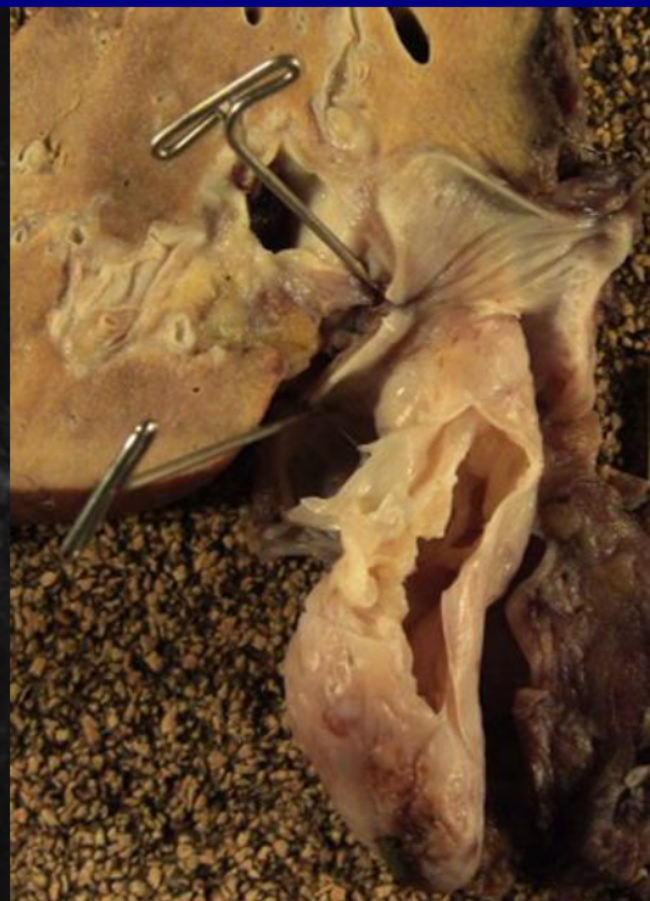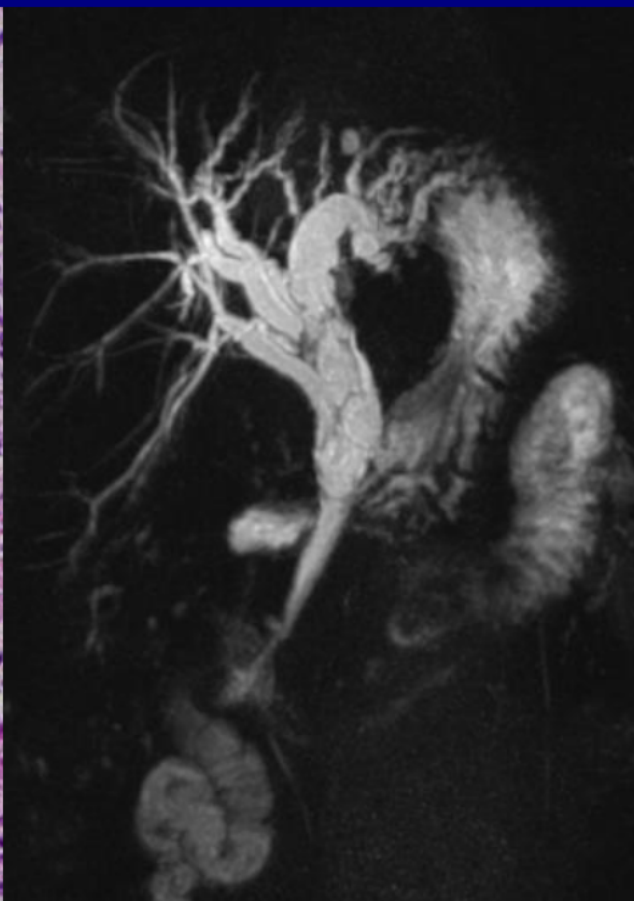
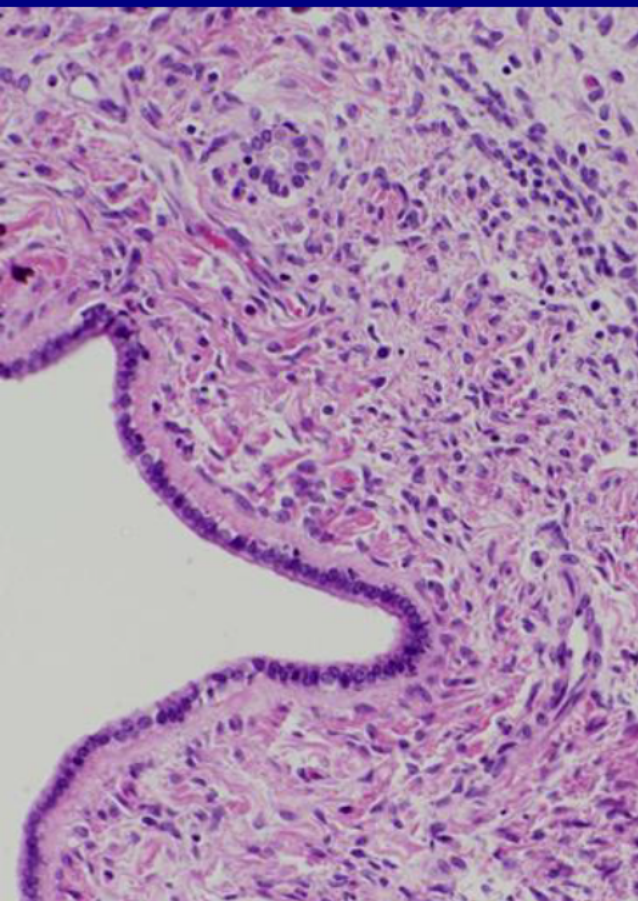
62-year-old woman with history of breast cancer presents with elevated liver enzymes and dark urine











Intrahepatic Biliary Cystadenoma with Herniation into the Common Bile Duct

Dianne Soochan
Dalhousie University,
Halifax, Nova Scotia, Canada

Many thanks to all of you for
submitting such great cases!
Have a safe trip home -

From the staff of the
American Institute for Radiologic Pathology