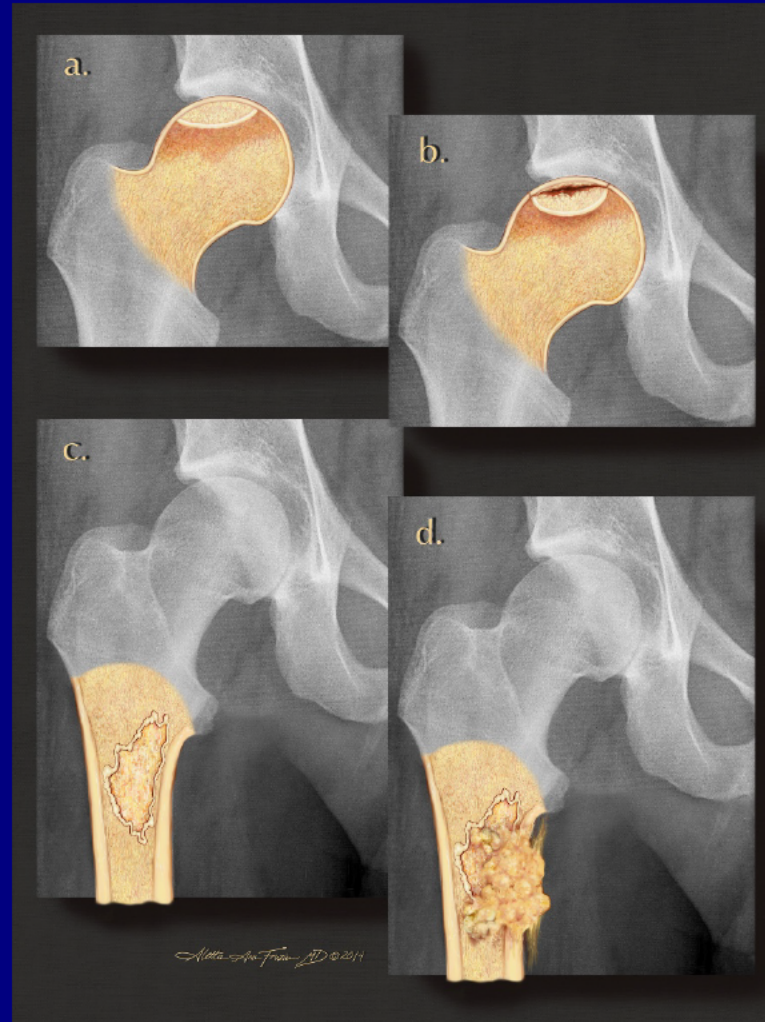


Best Cases of the AIRP

March-April, 2015

Musculoskeletal Best Case

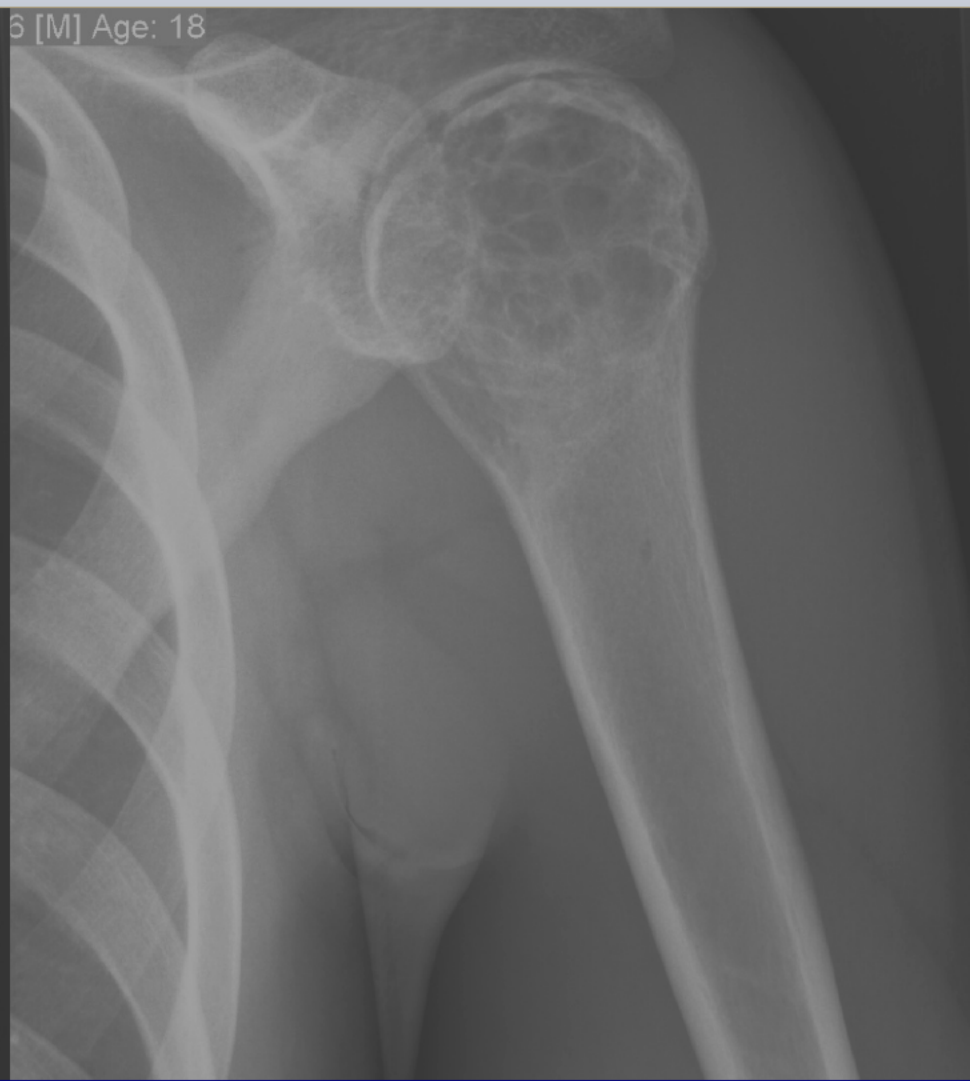


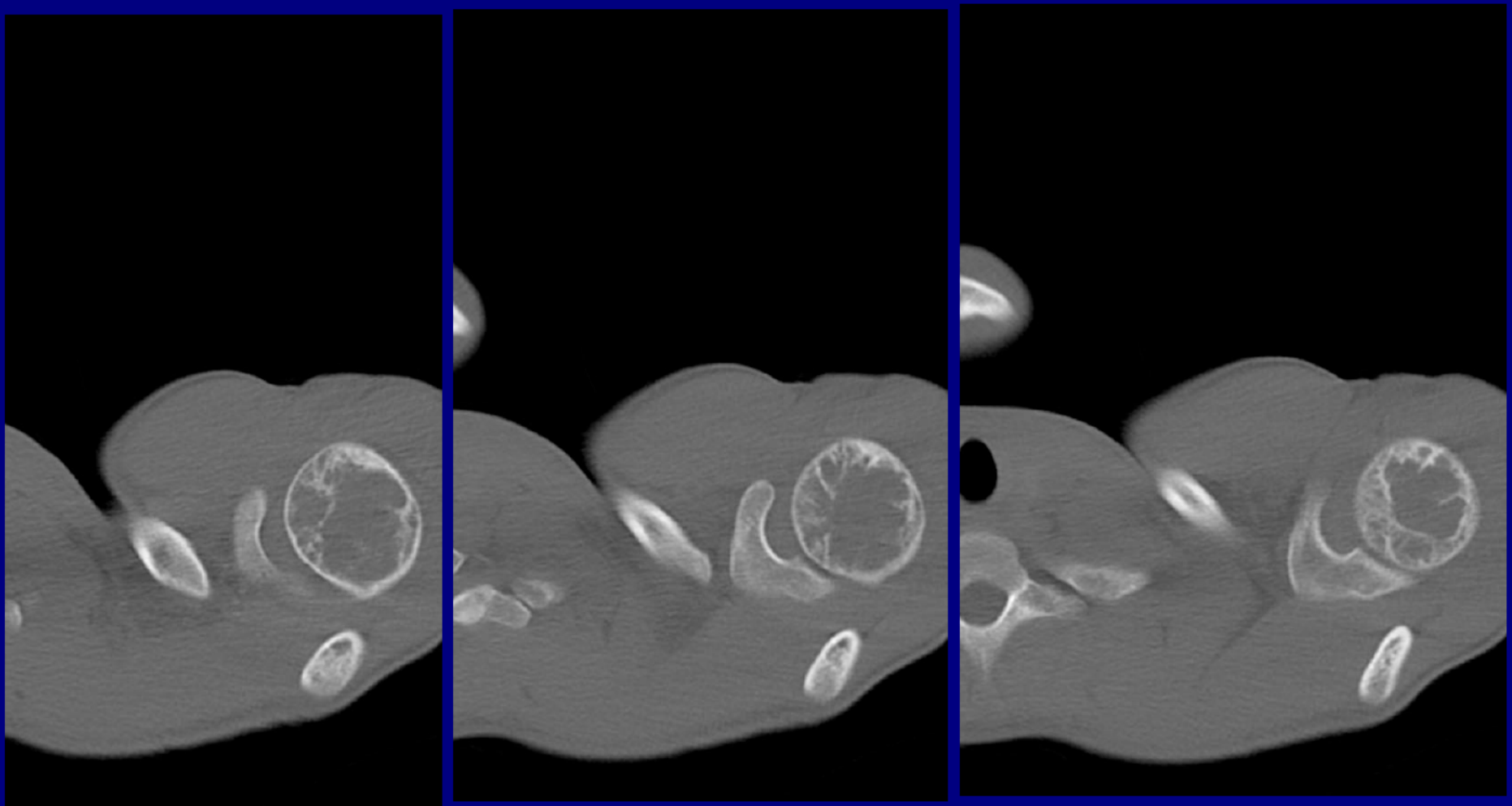
**18 year old male who presented to
the ED following a minor MVC**

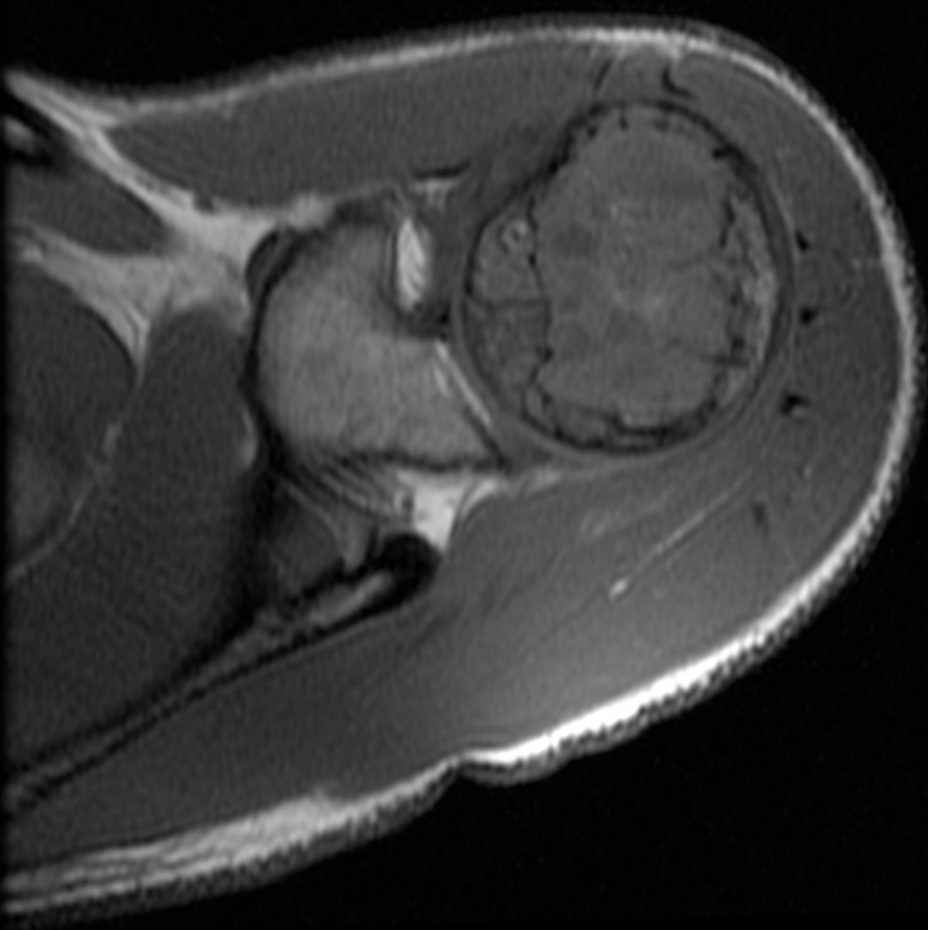8



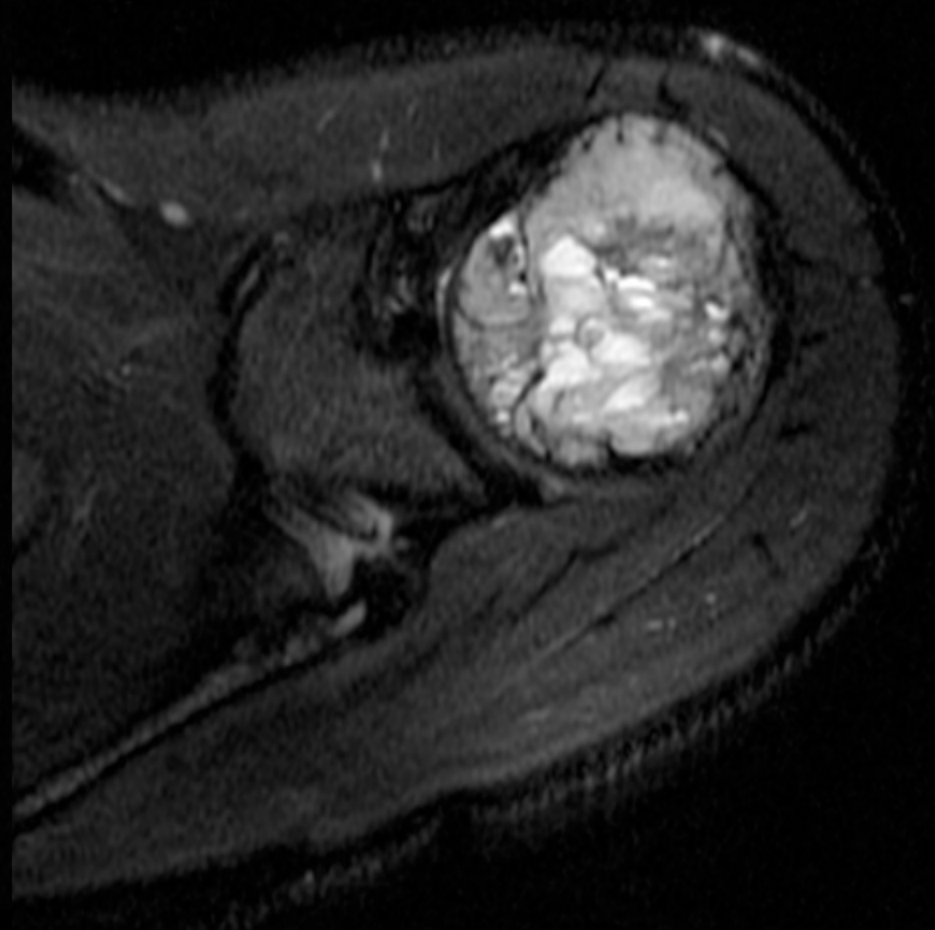
6 [M] Age: 18



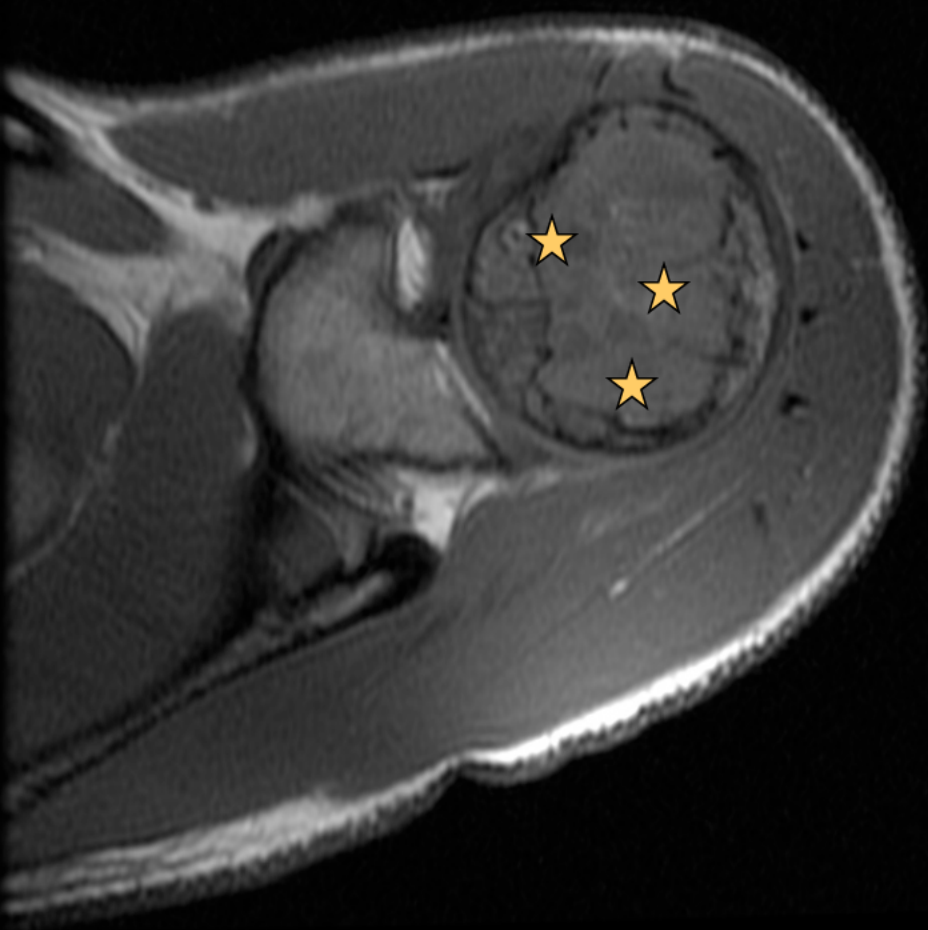



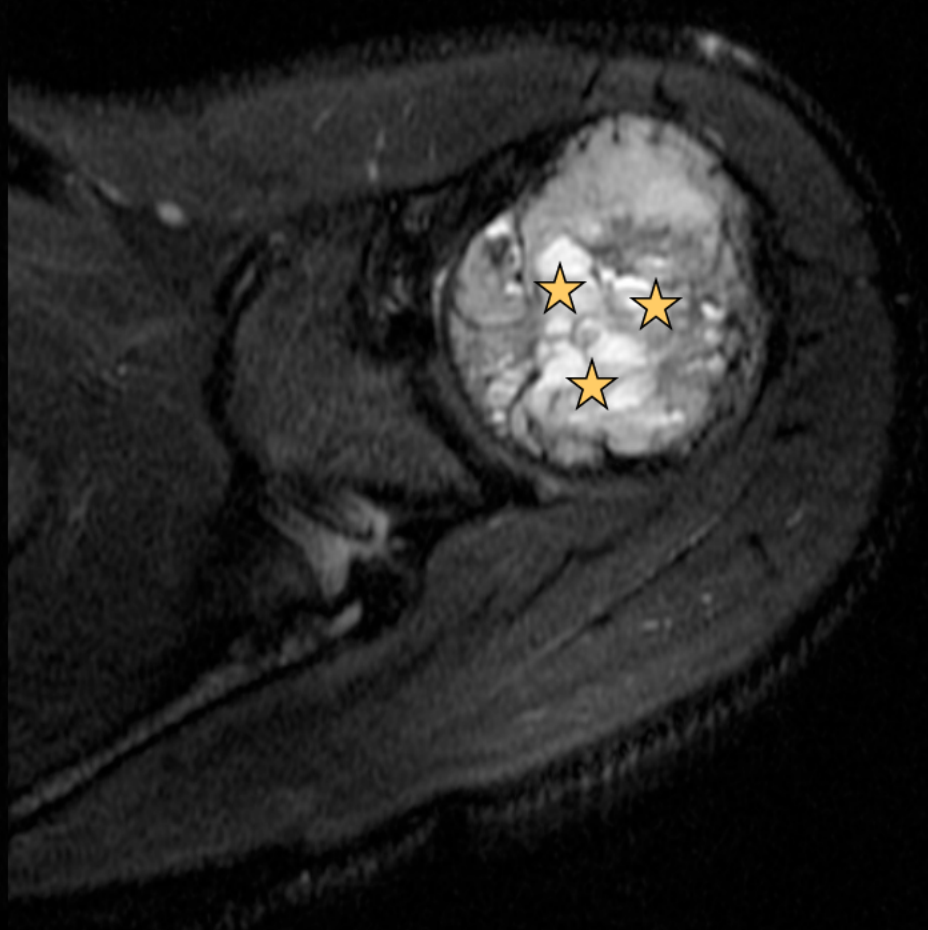
T1



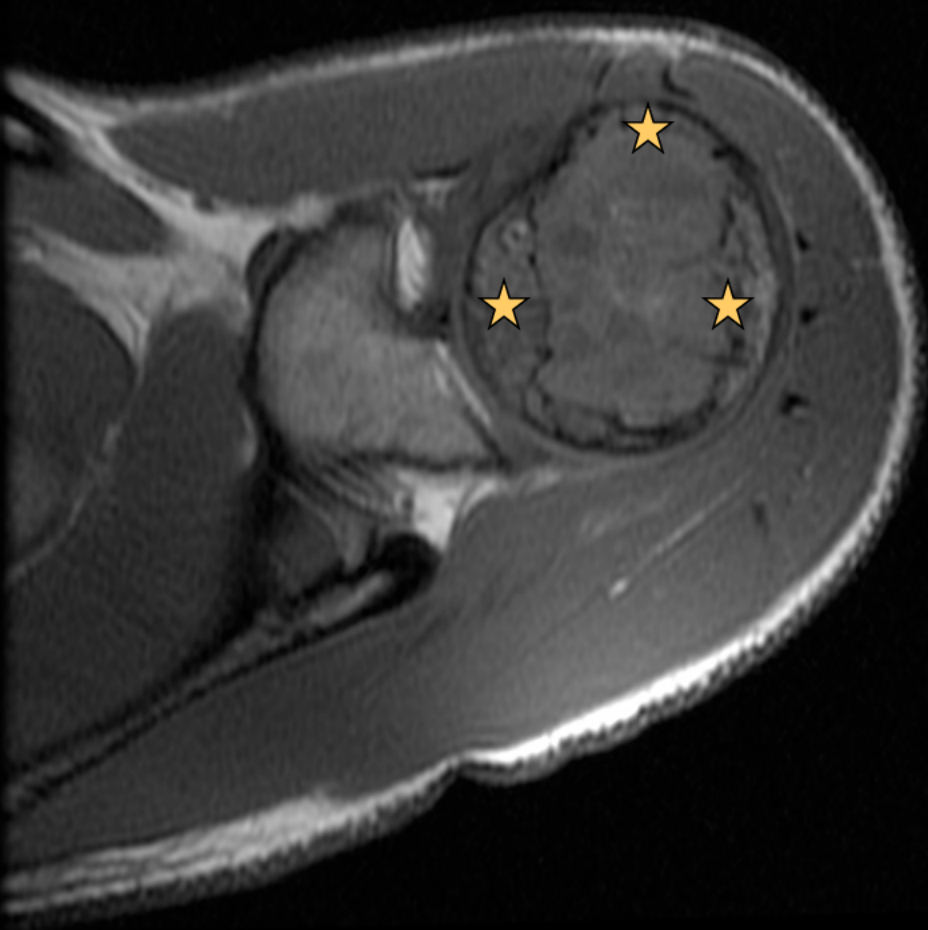
T2FS



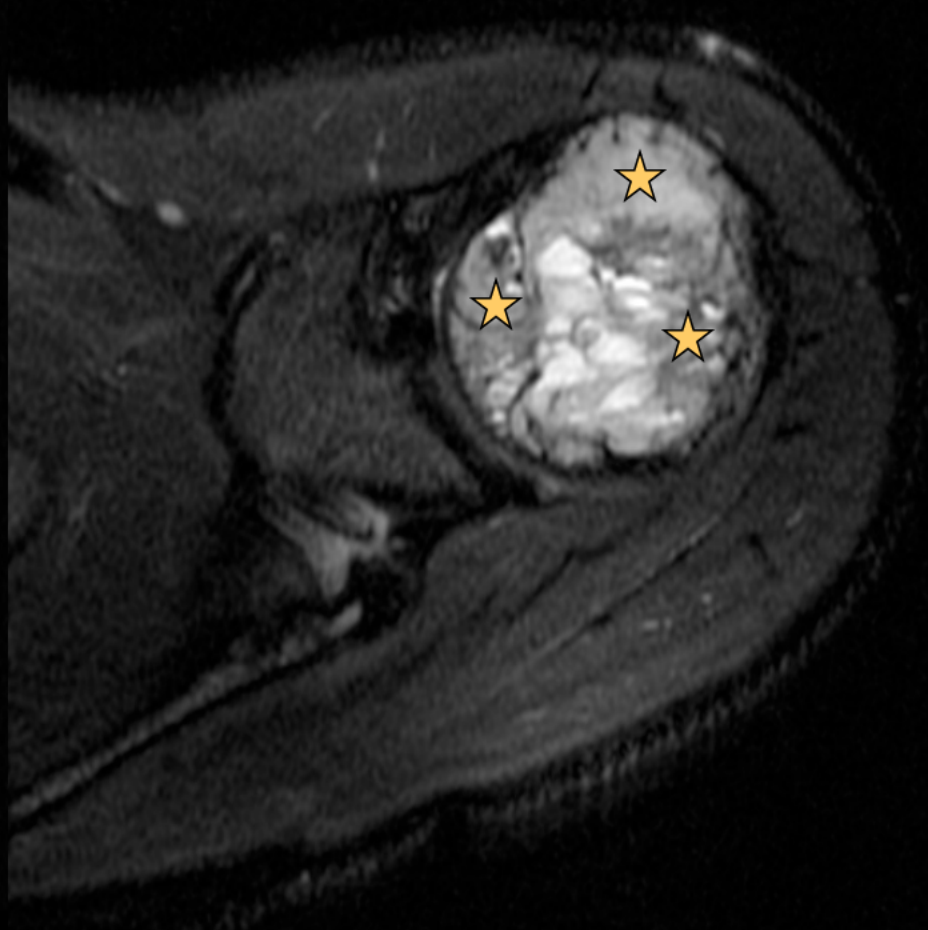
T1



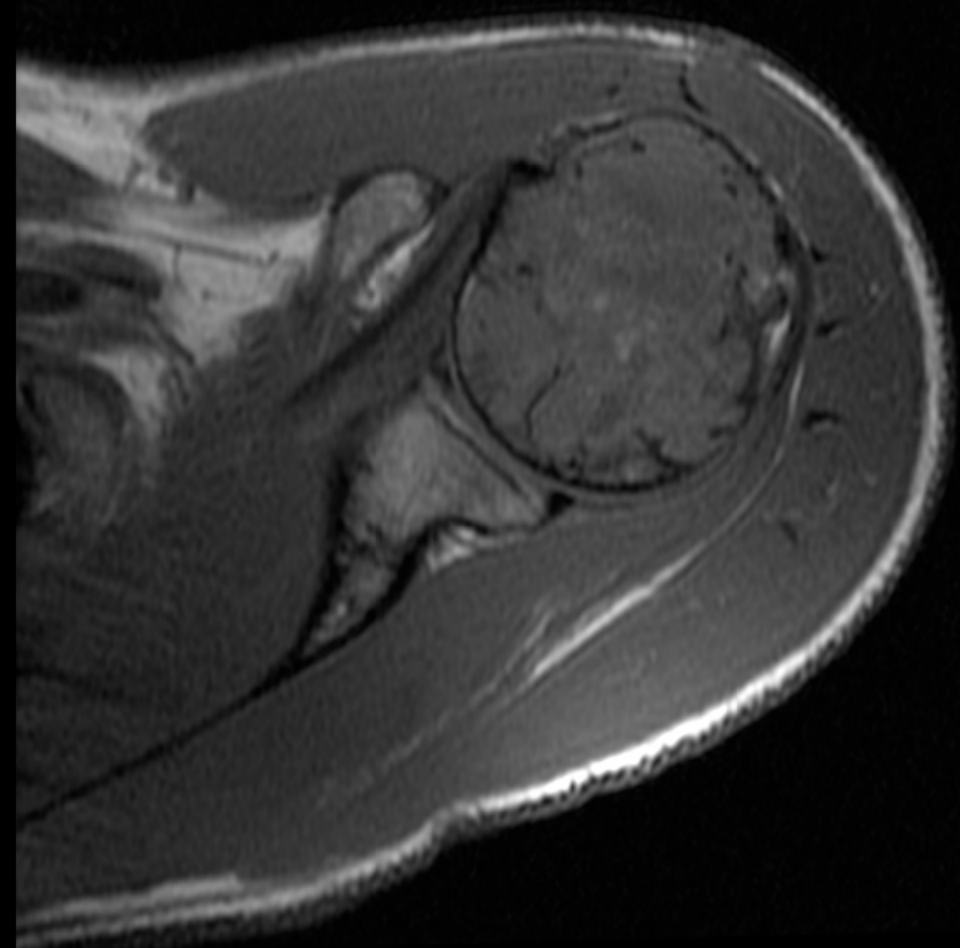
T2FS



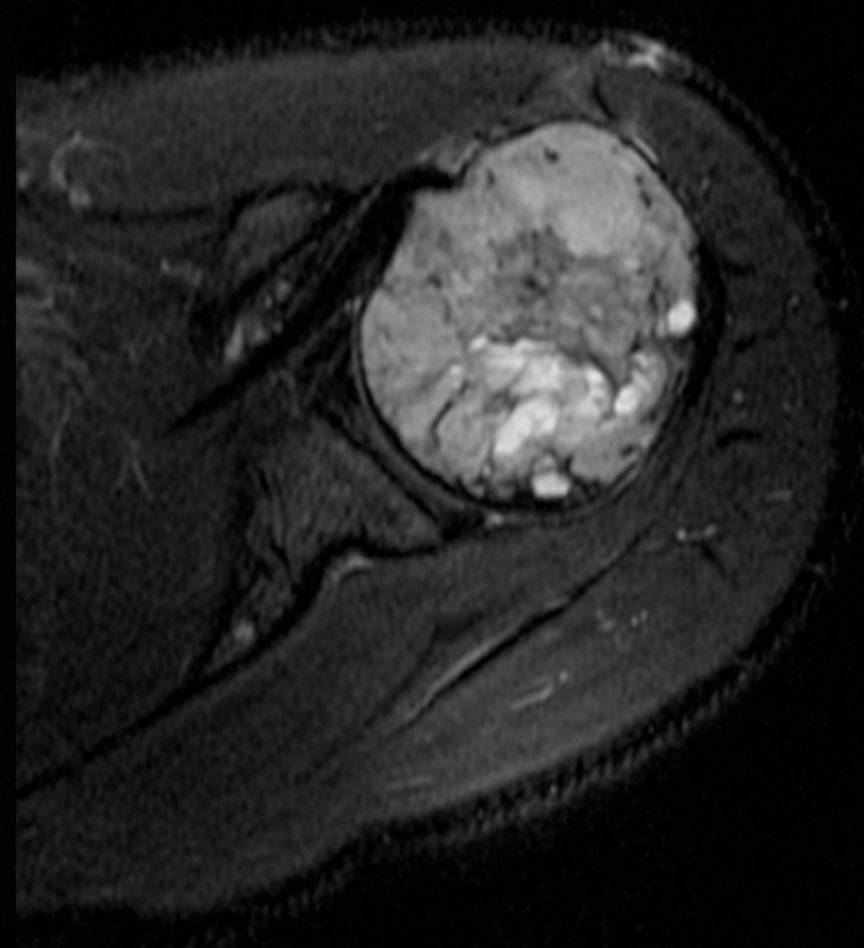
T1



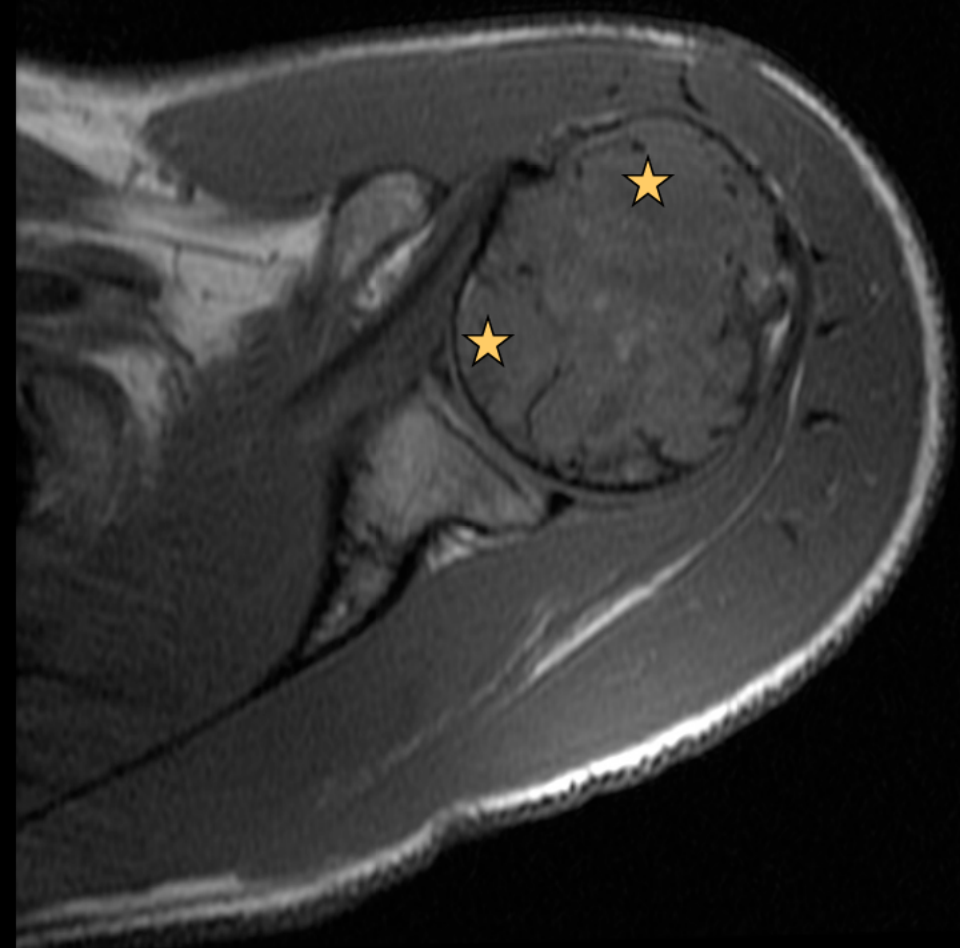
T2FS



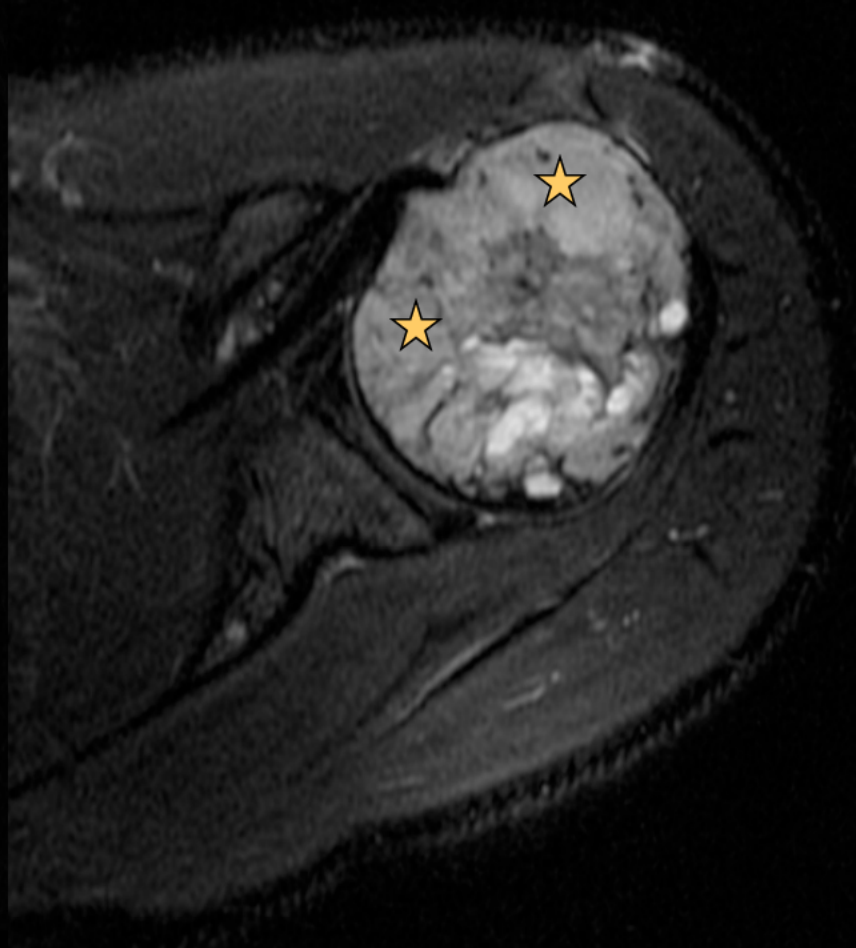
T1



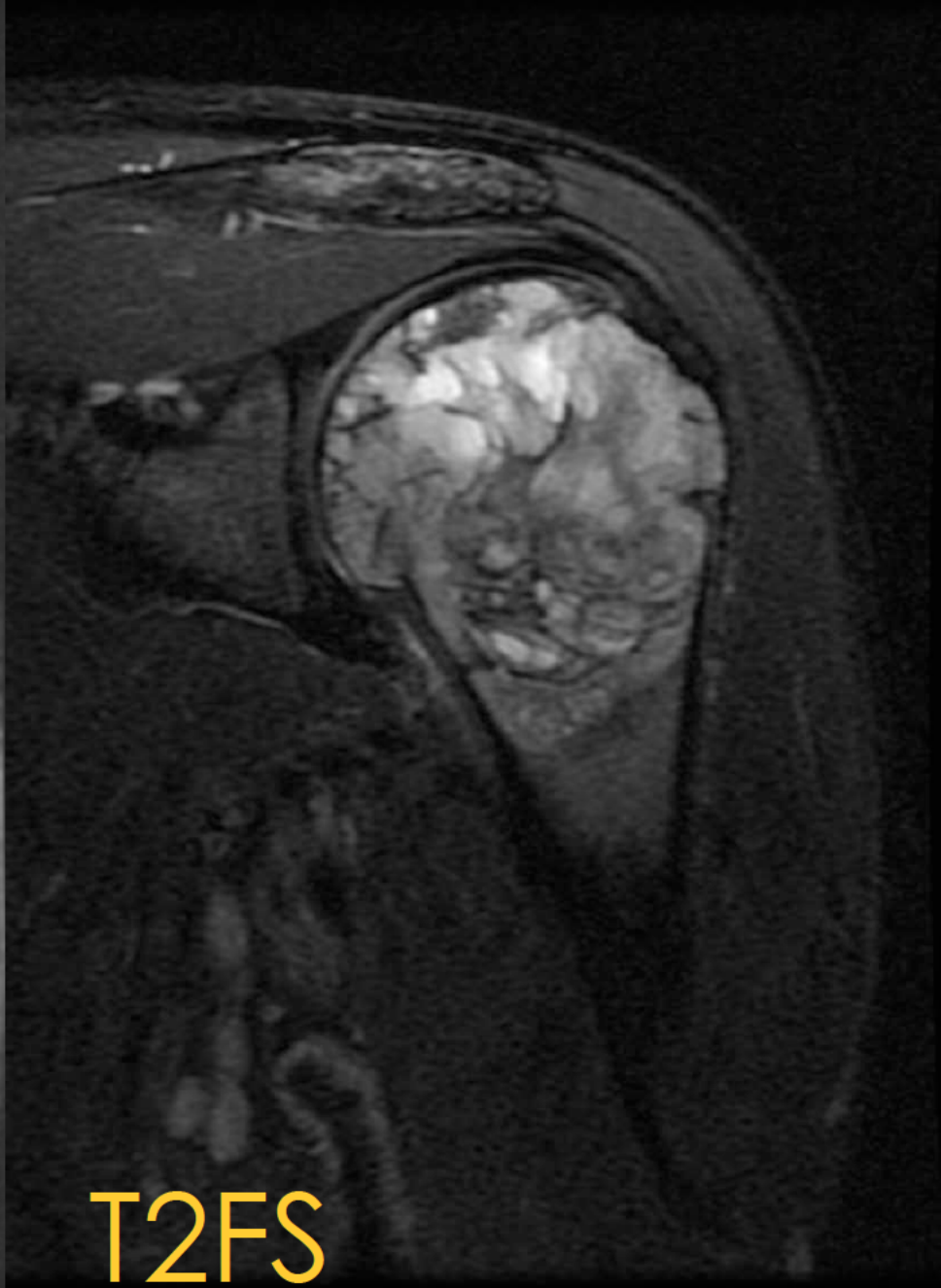
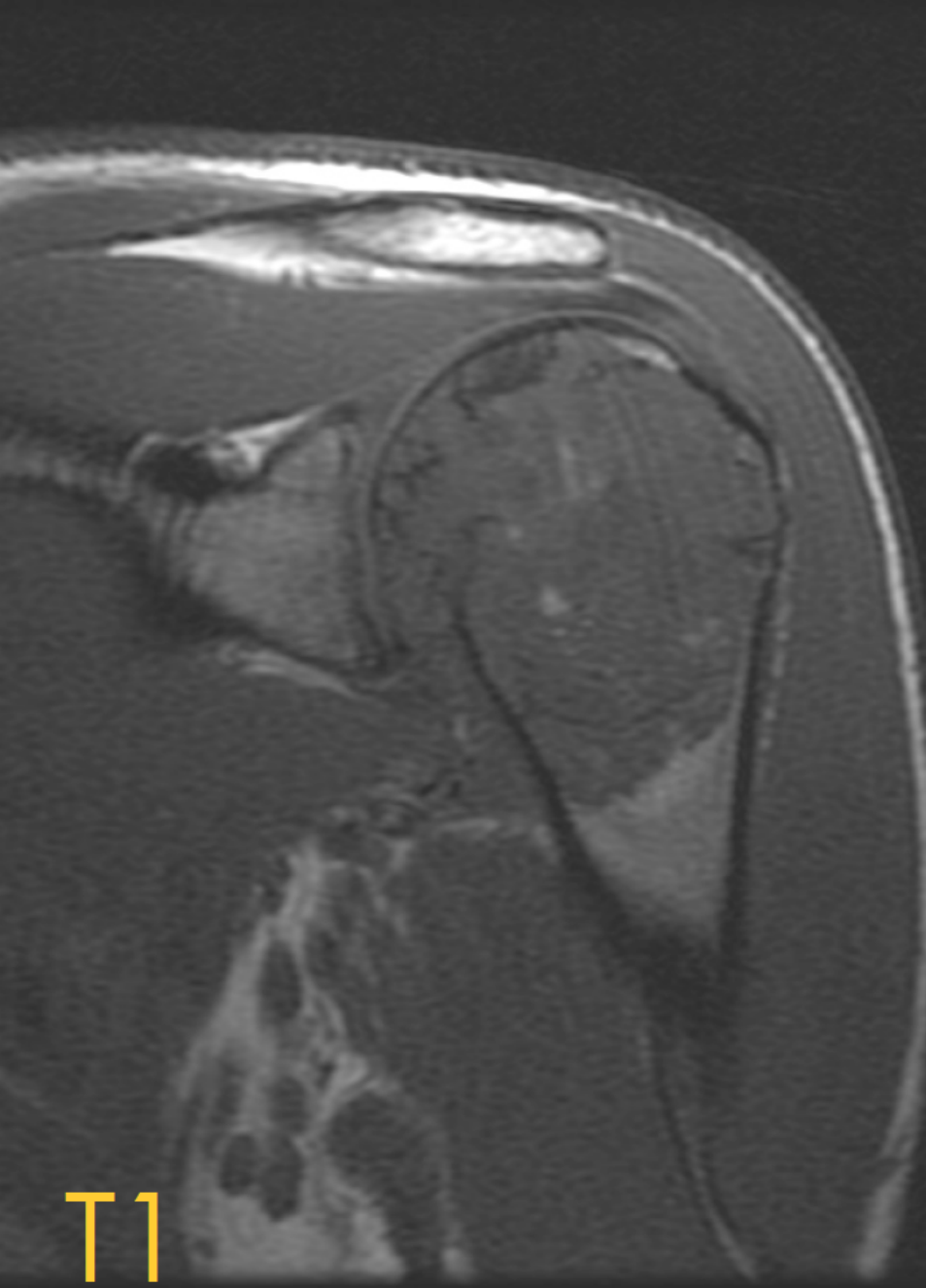
T2FS

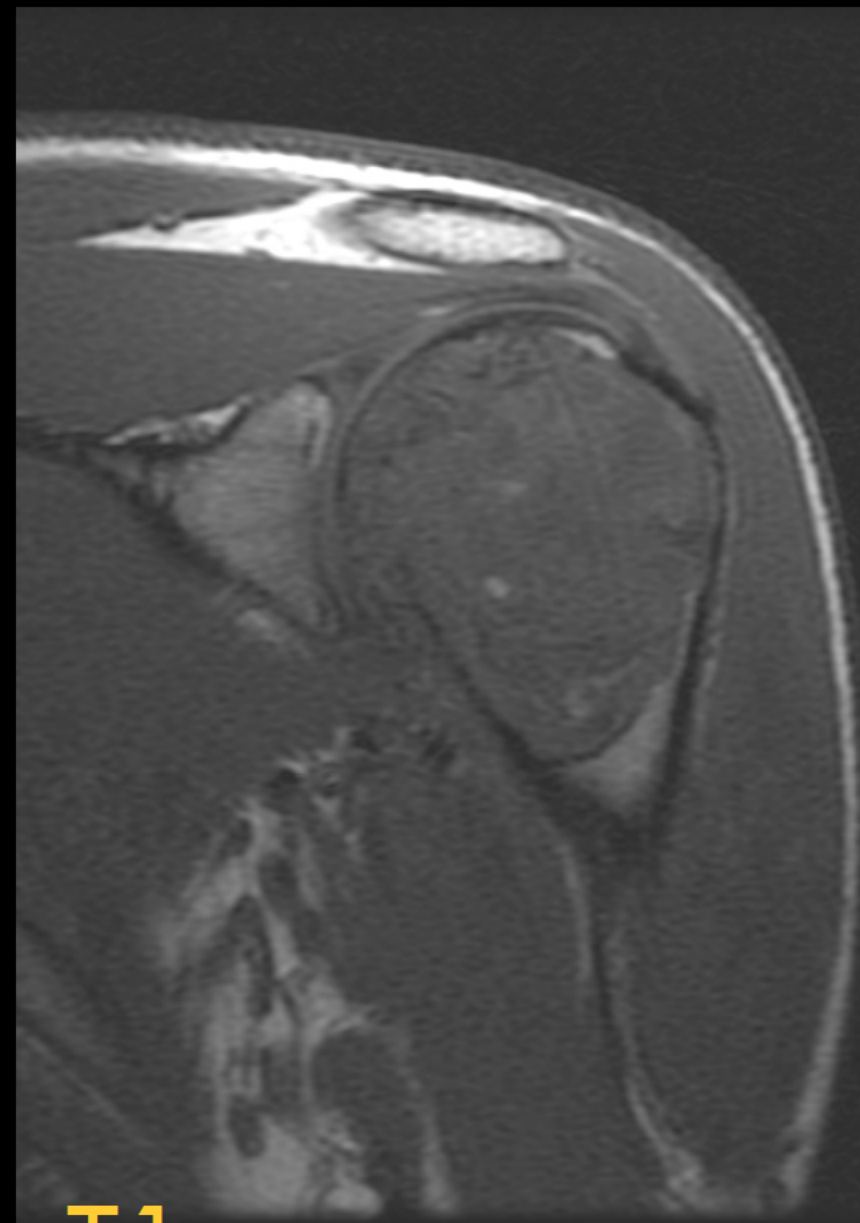


T1

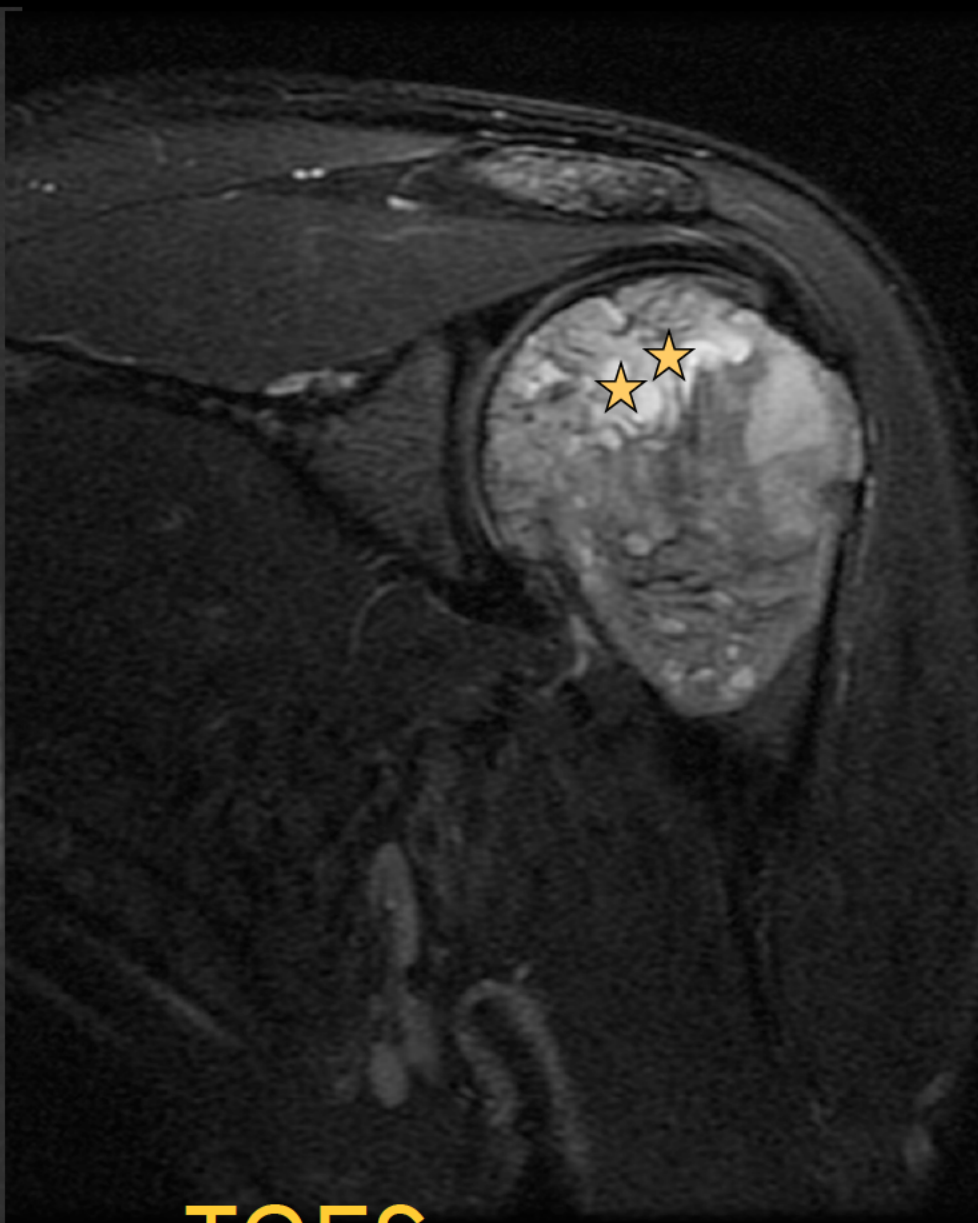


T2FS

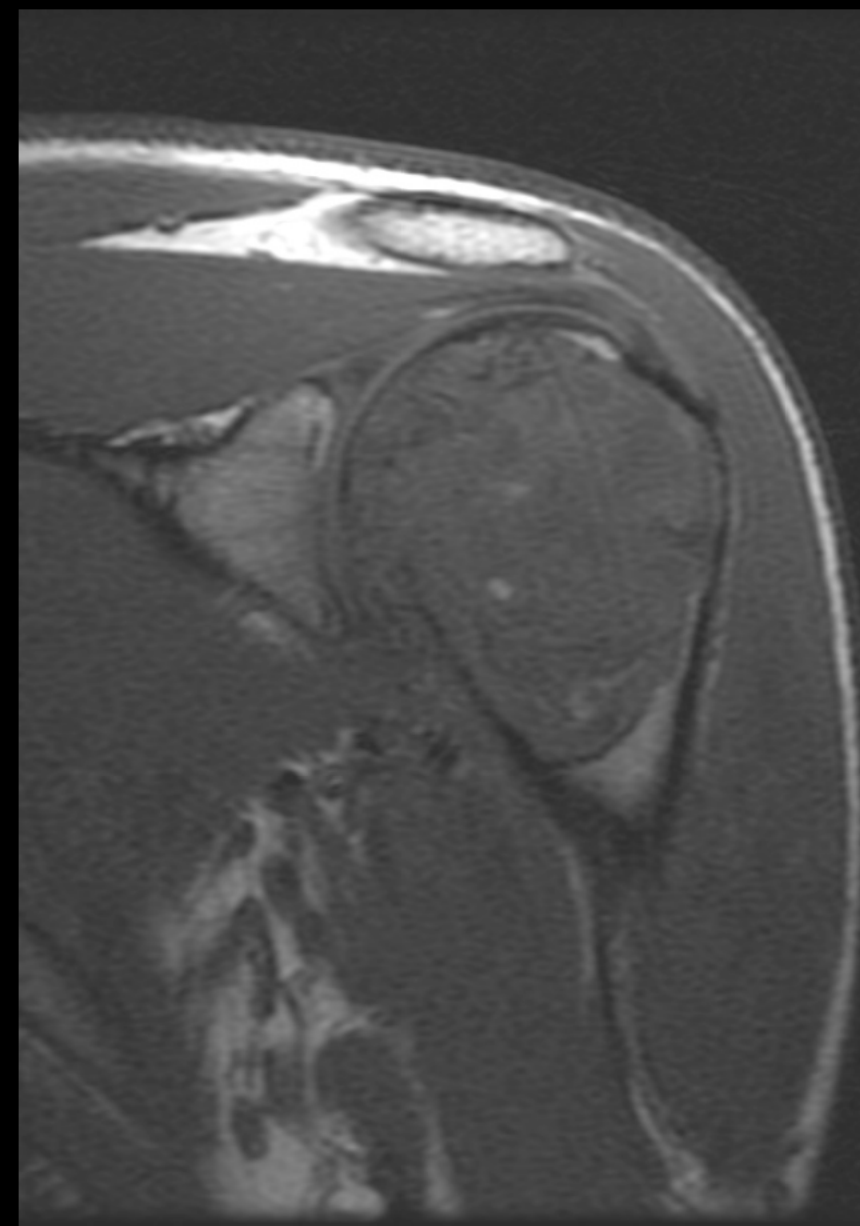




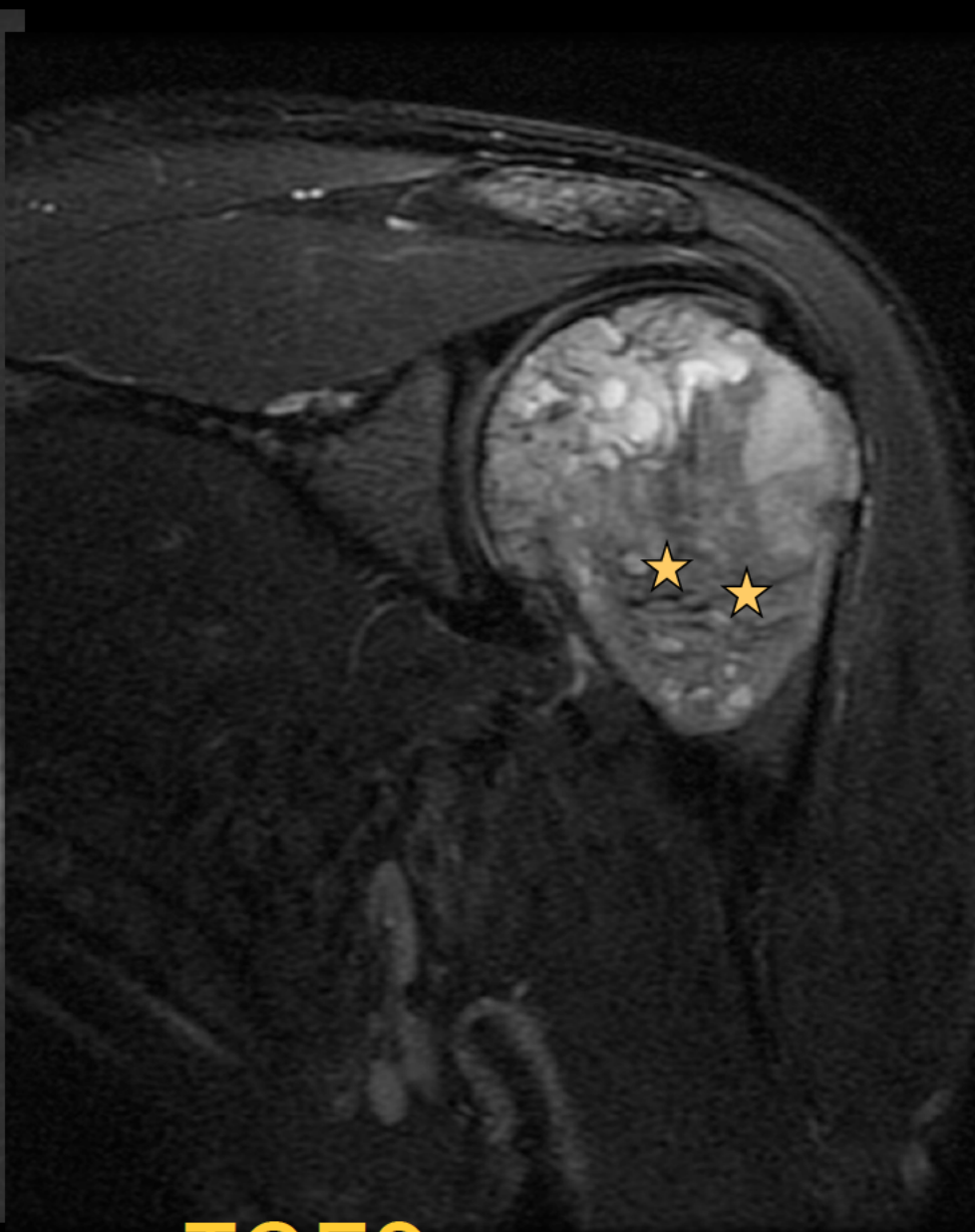
T1



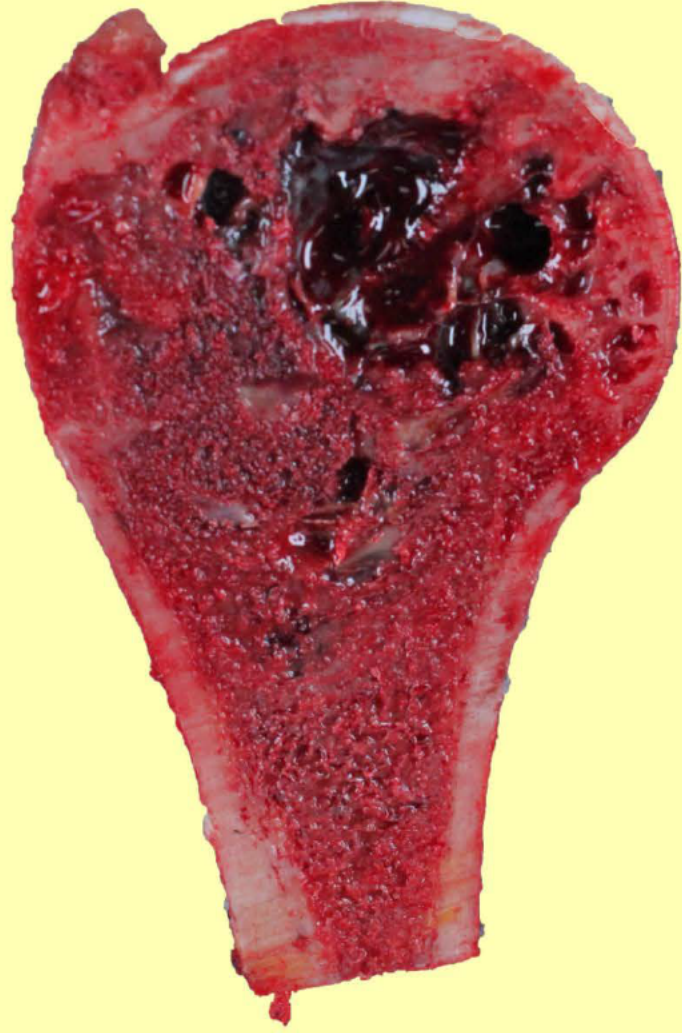
T2FS

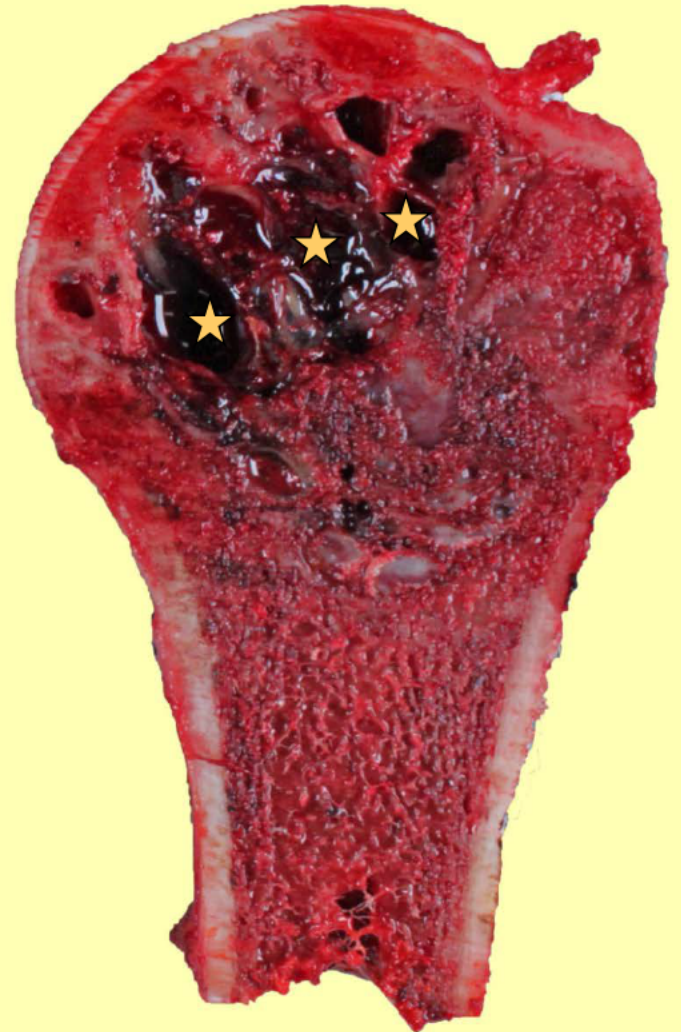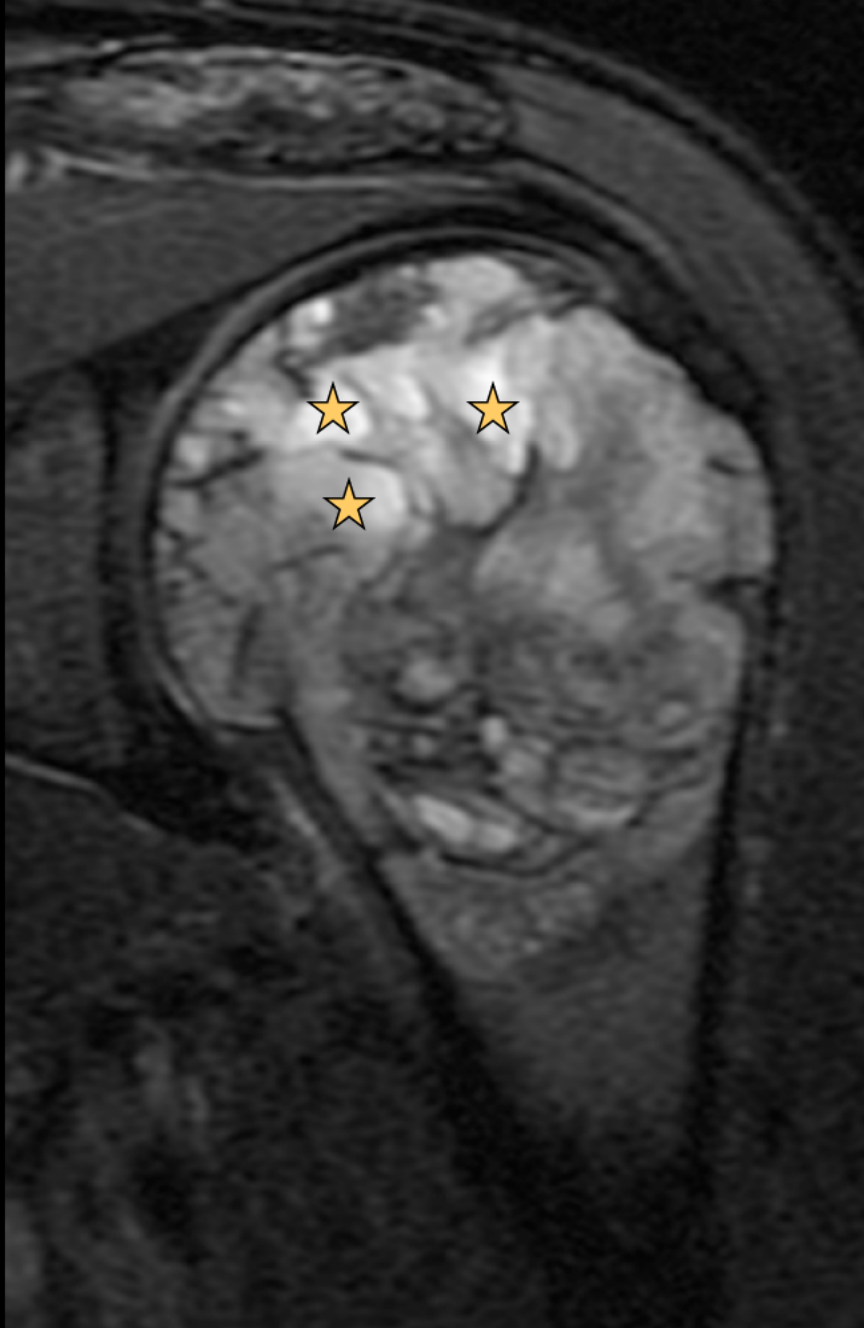


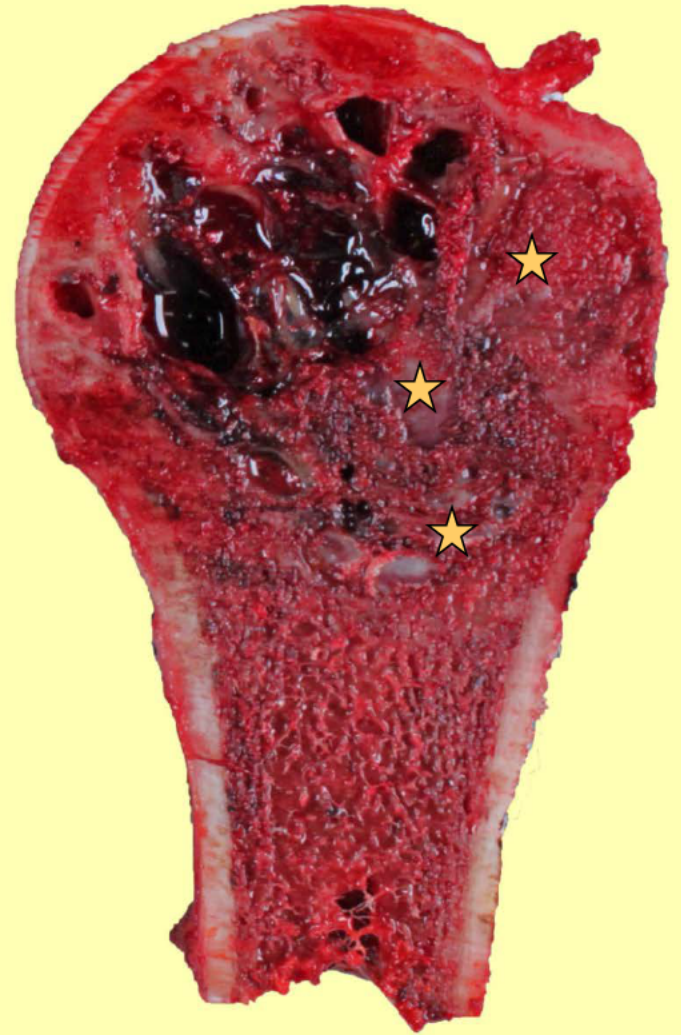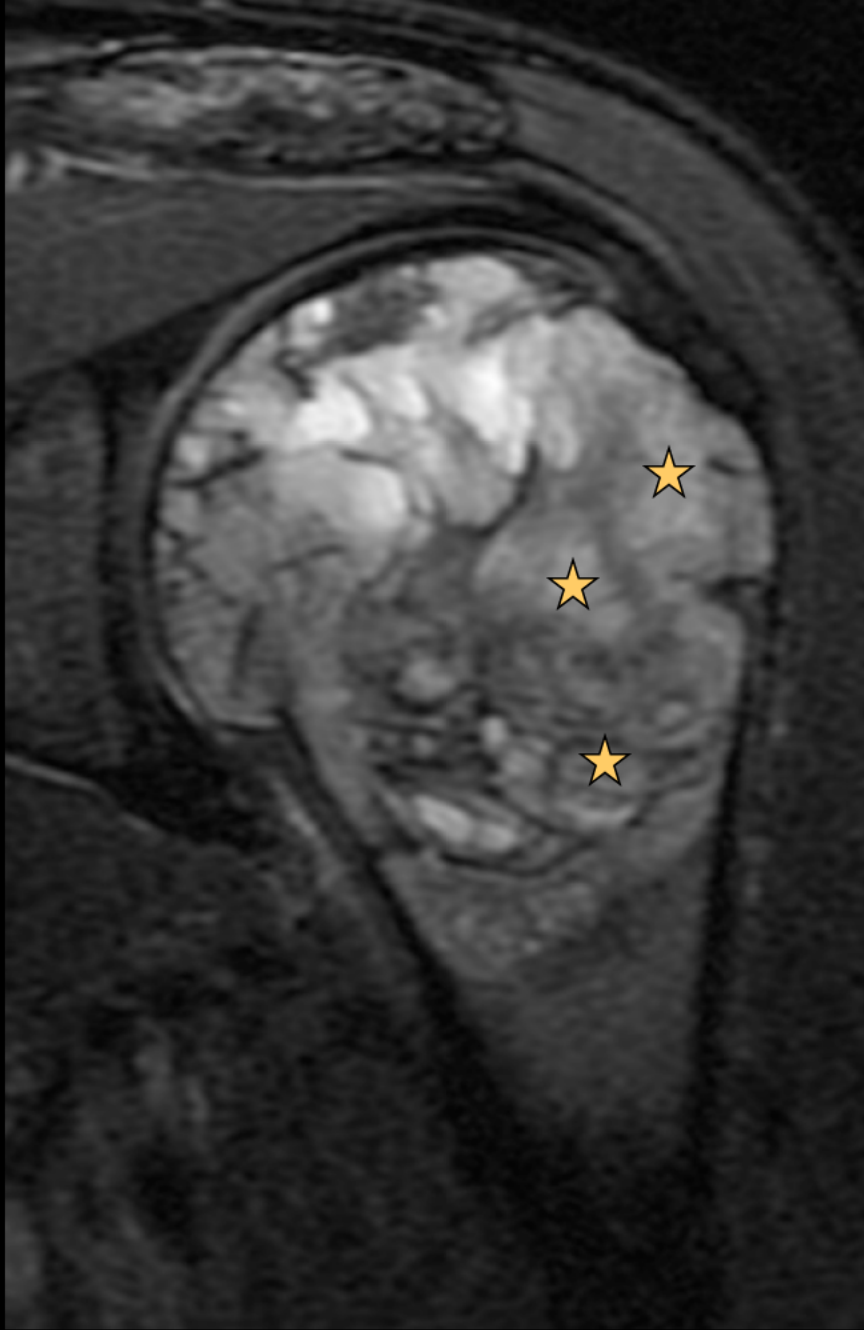
T1

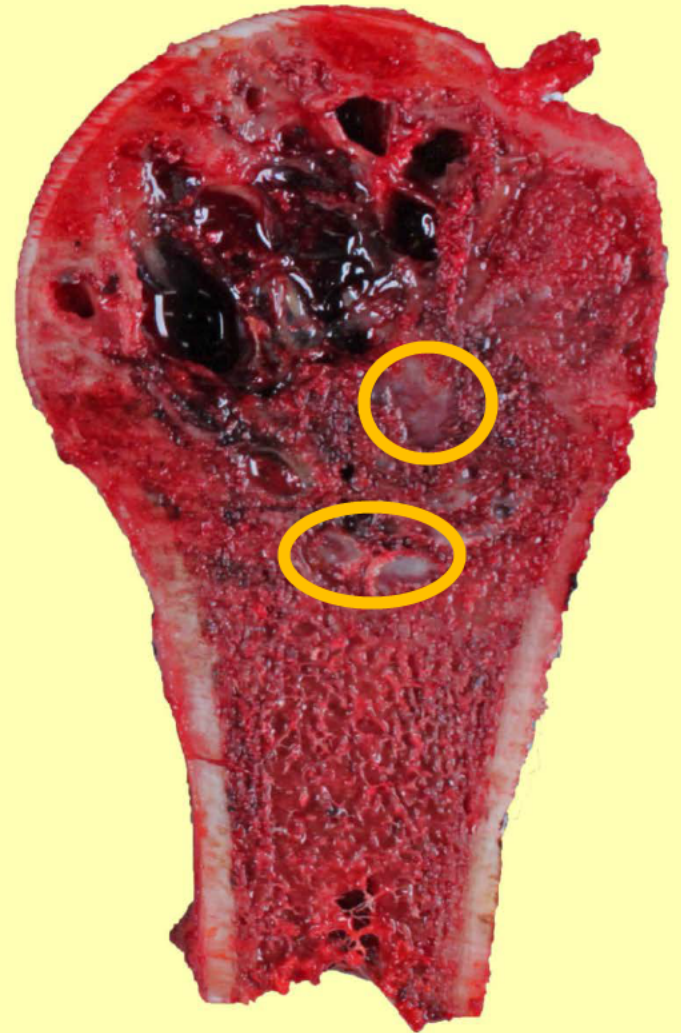
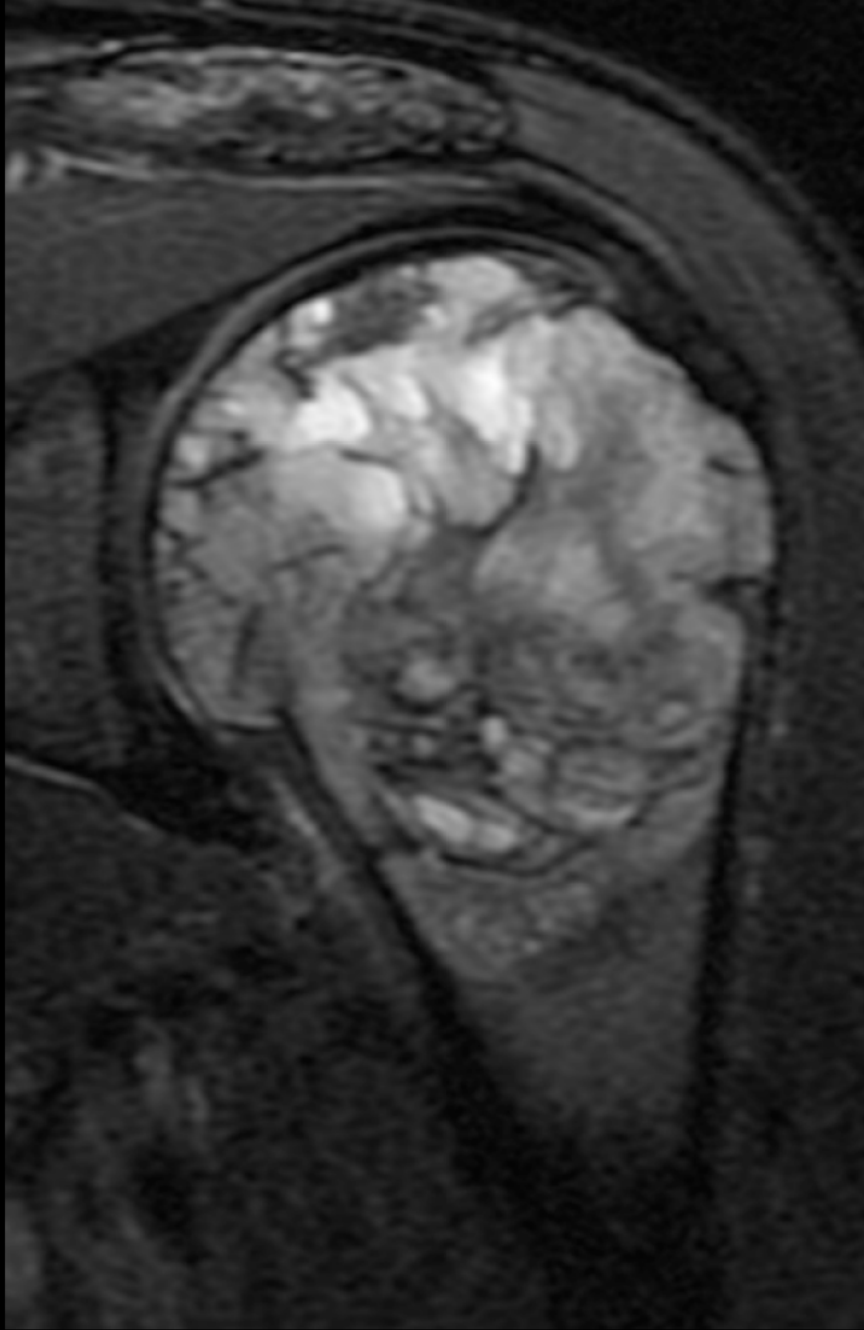


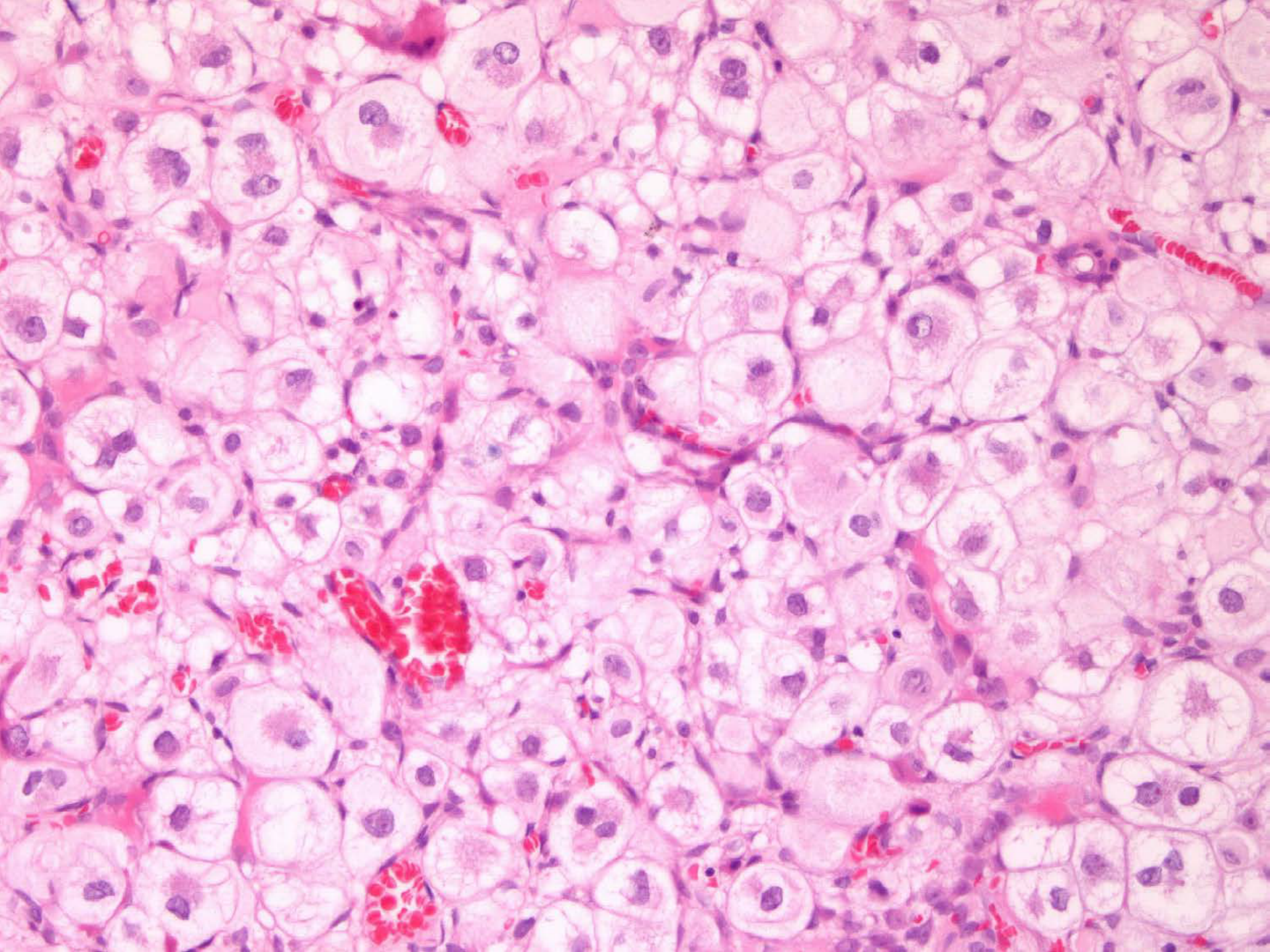
T2FS

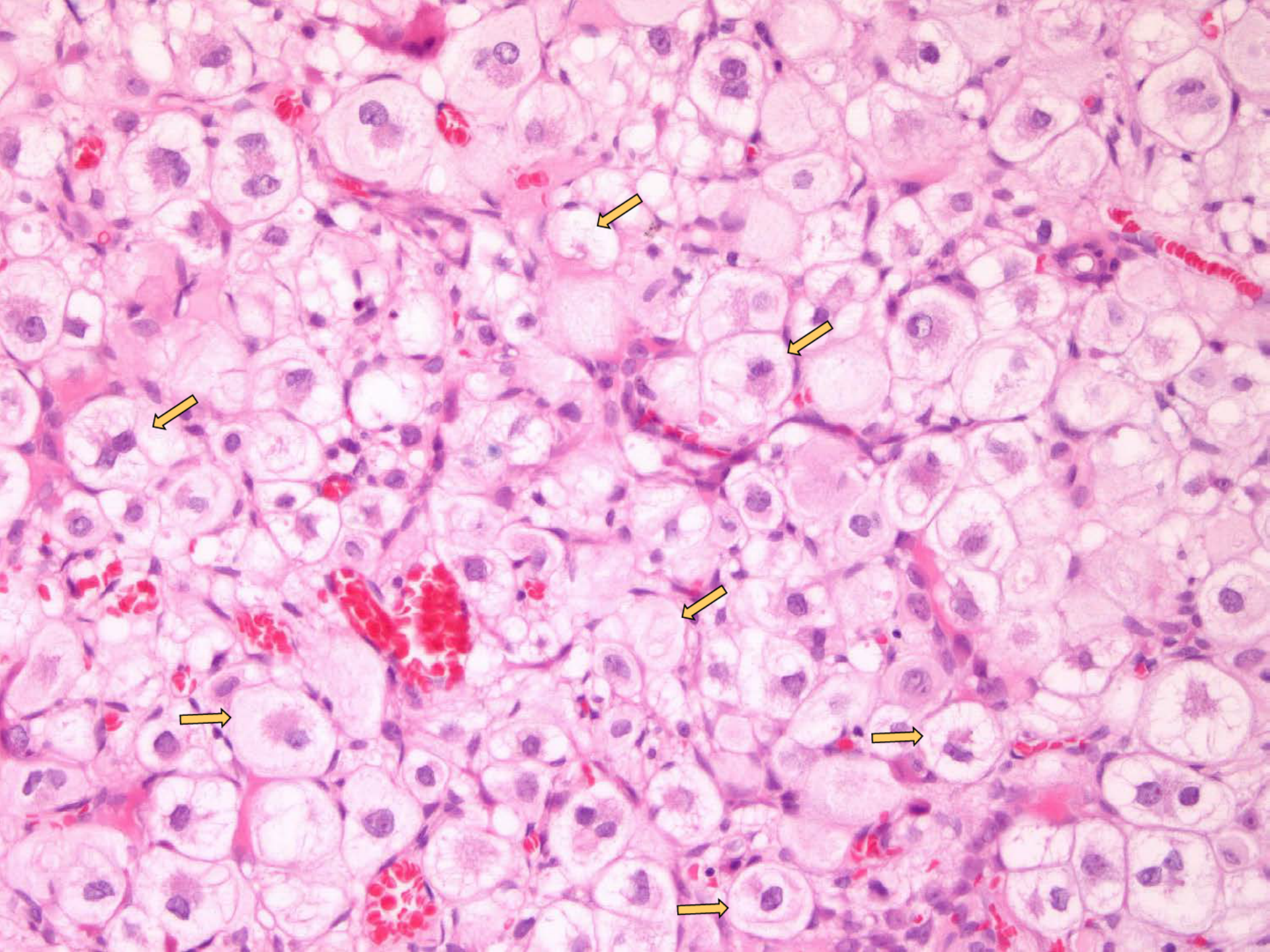








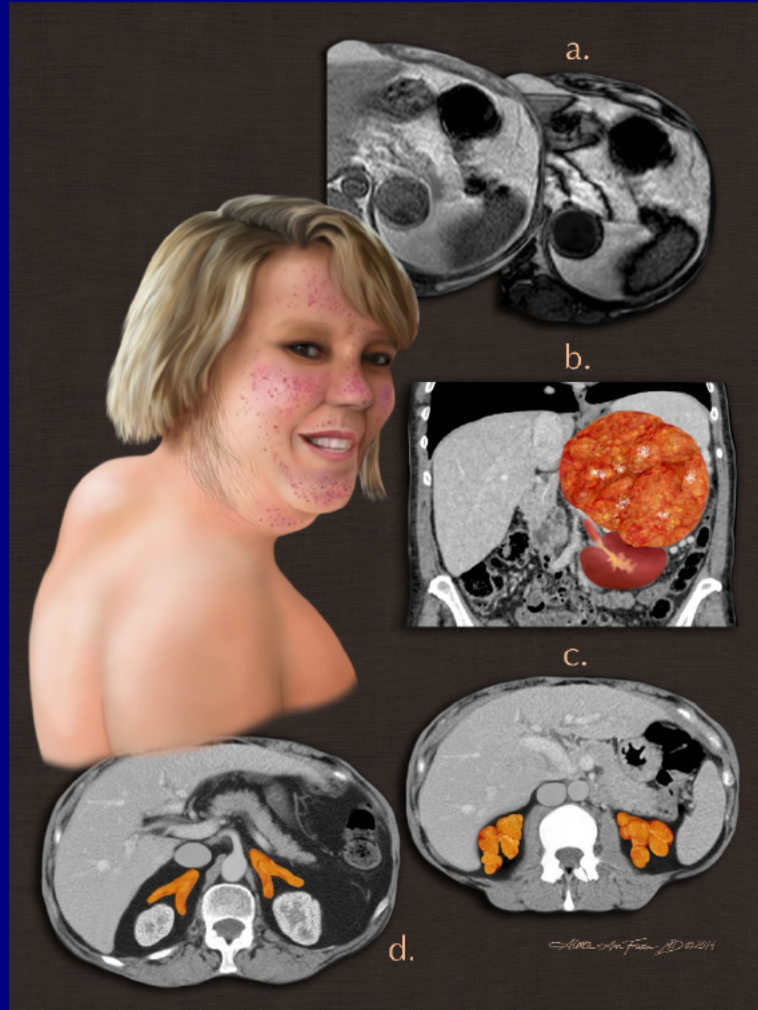




CLEAR CELL CHONDROSARCOMA WITH AN ABC COMPONENT

**Jillian Lazor, MD
University of Pennsylvania
Philadelphia, PA**

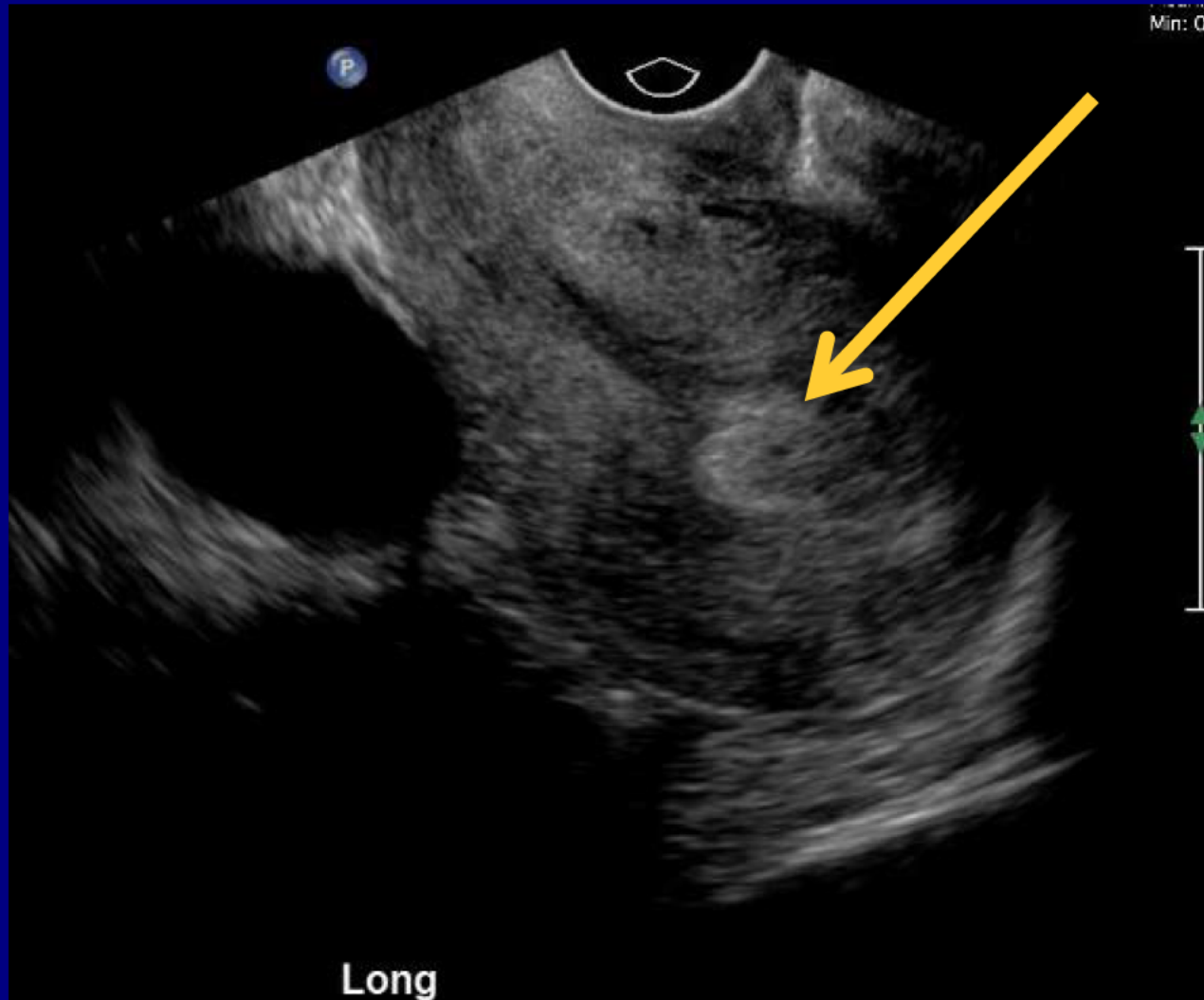
Genitourinary Best Case



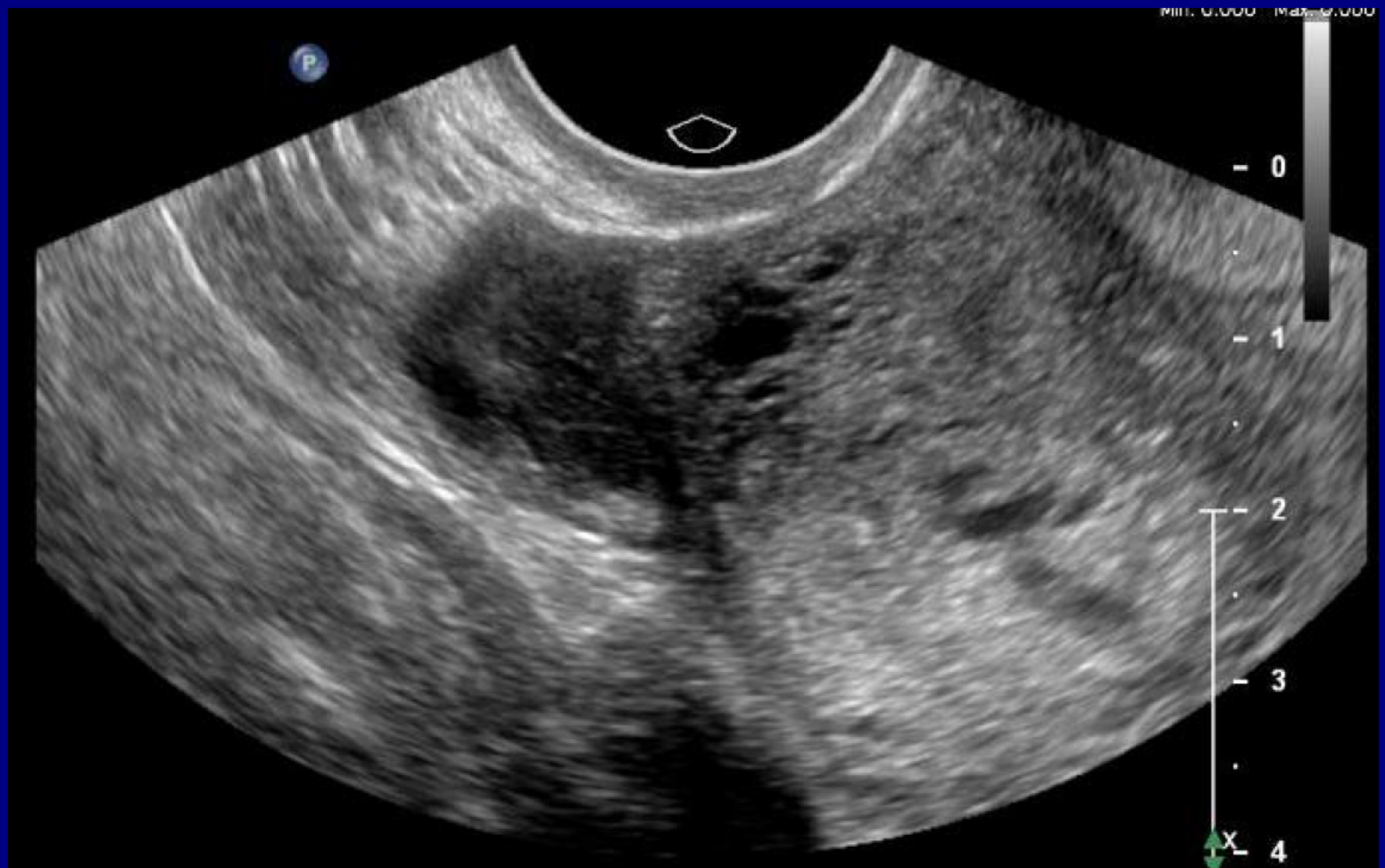
Clinical Information

27 yo G2P1 female presented with 2-3 week history of abdominal cramping and nausea/vomiting. LMP 10 weeks prior. bHCG 375,401.

Ultrasound

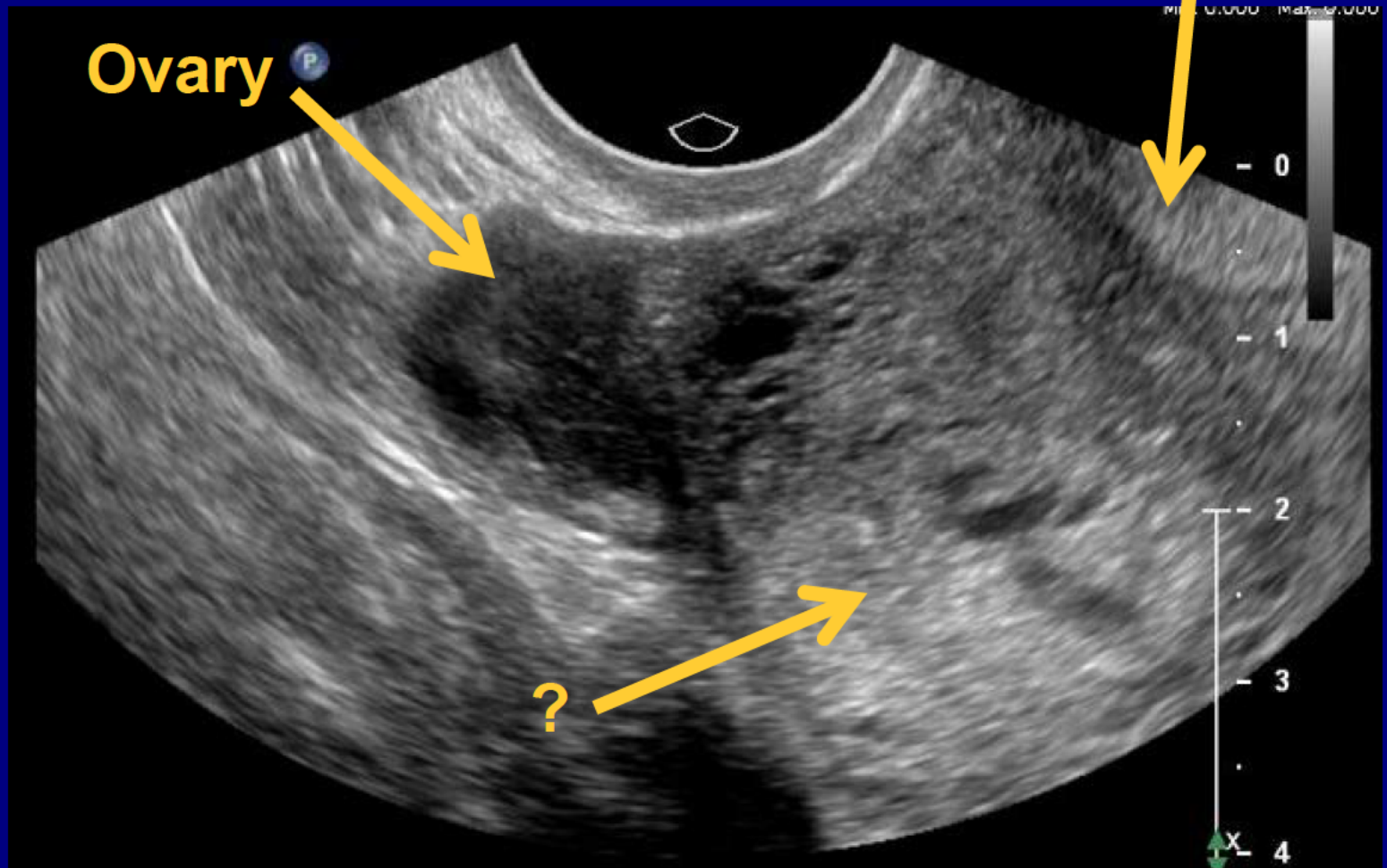


Ultrasound

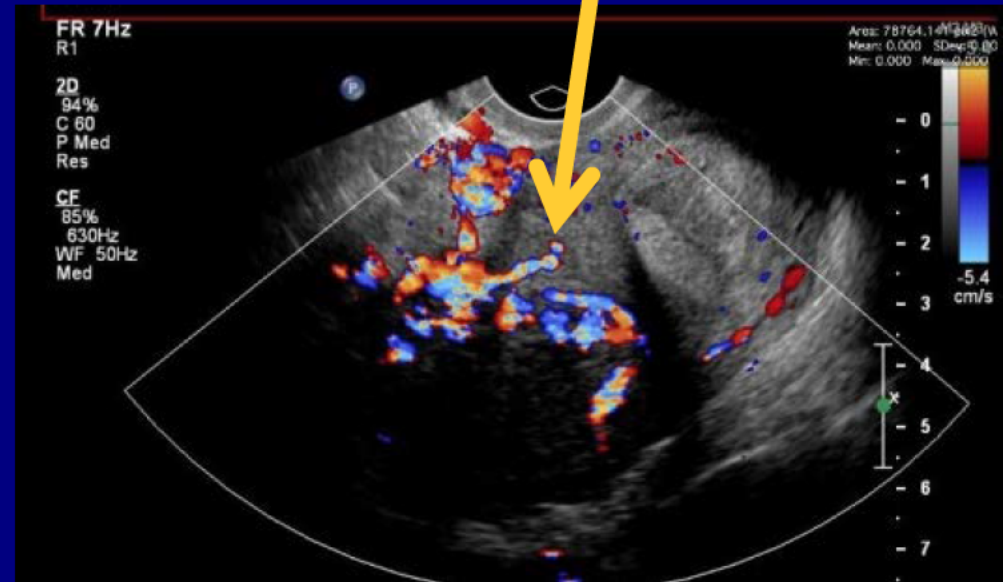
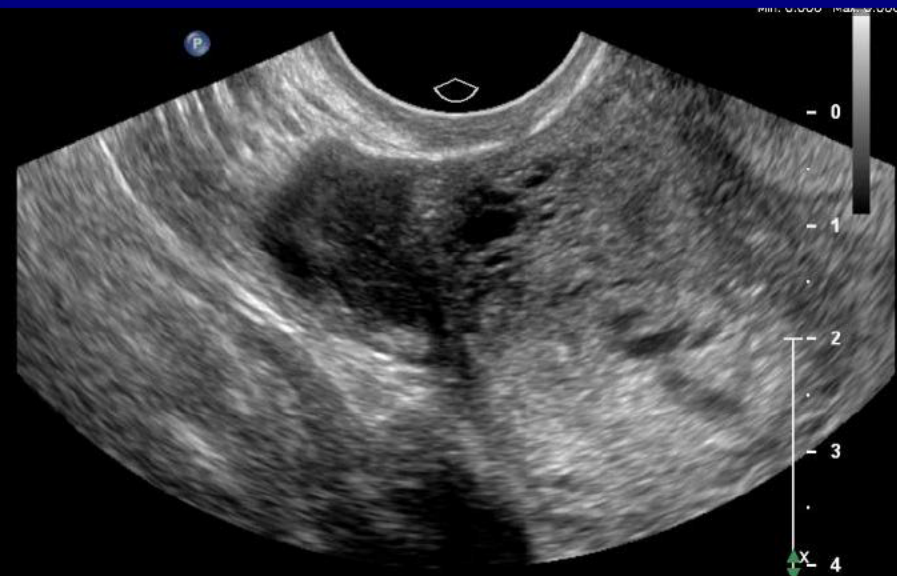


Endometrial Canal

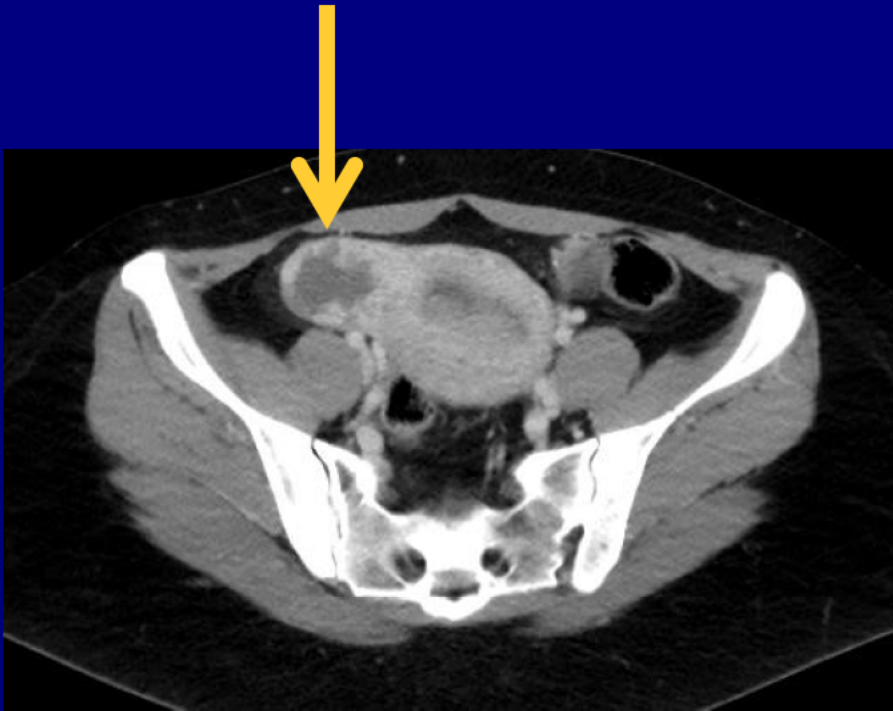
Ovary



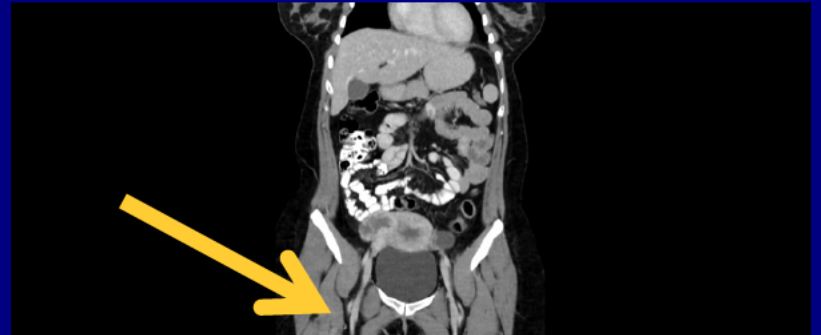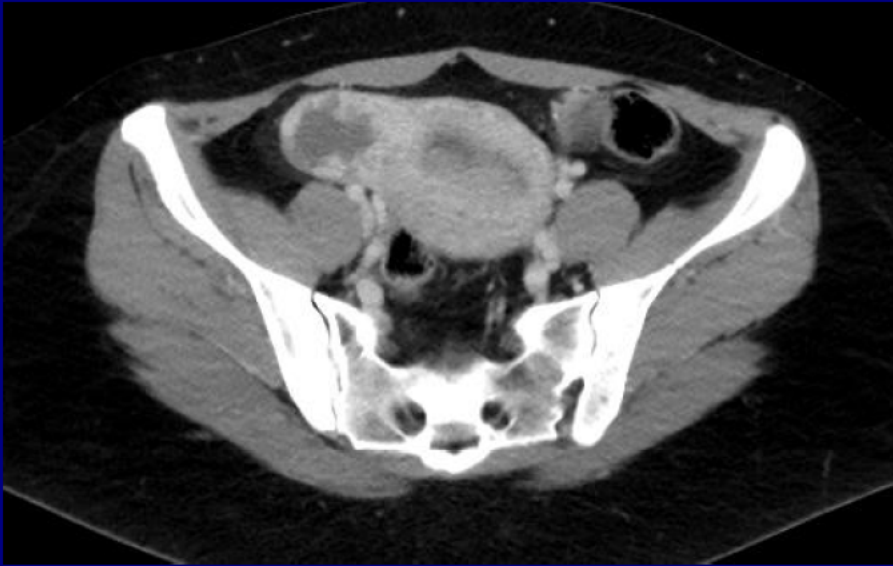Ultrasound



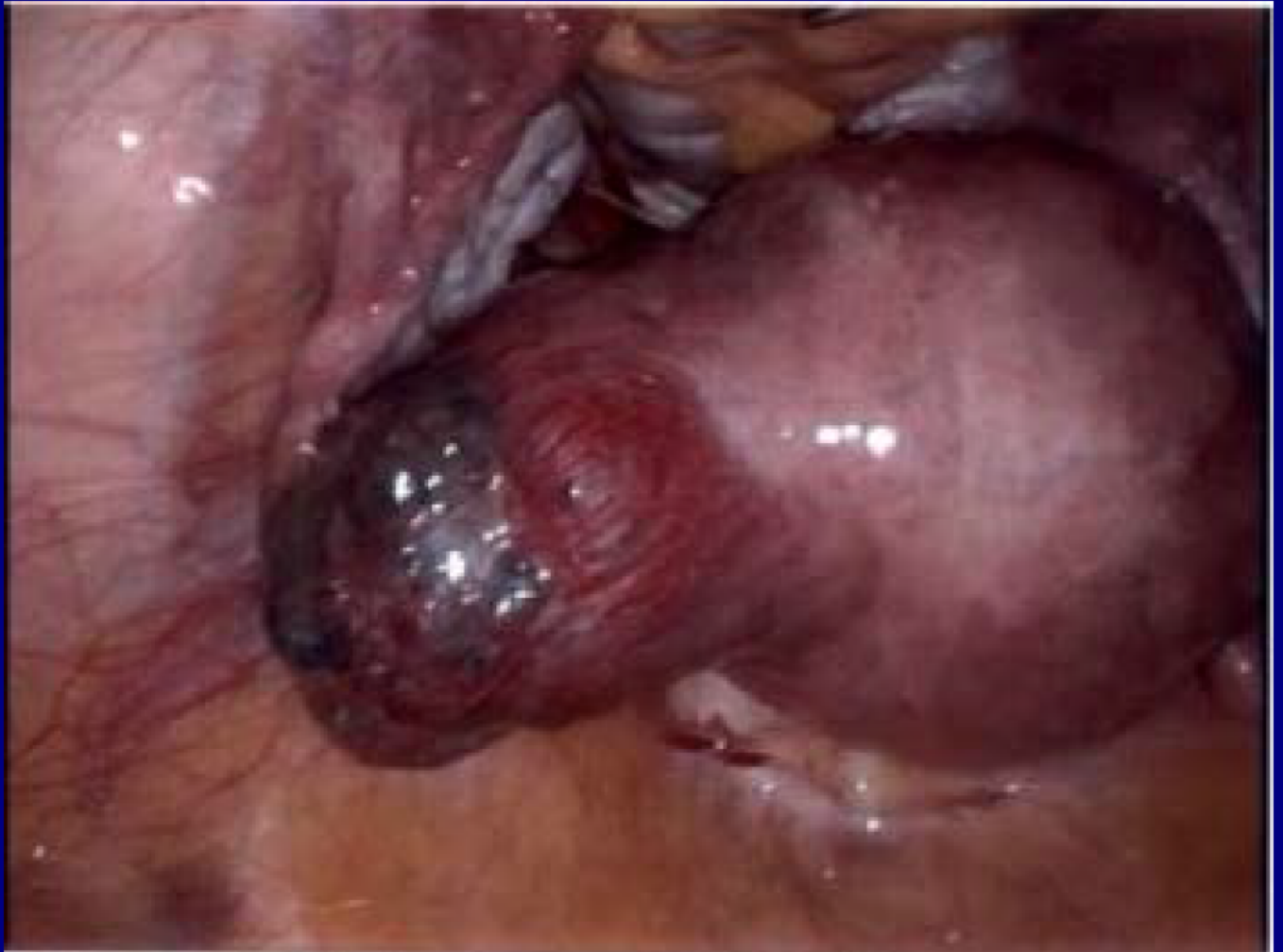CT



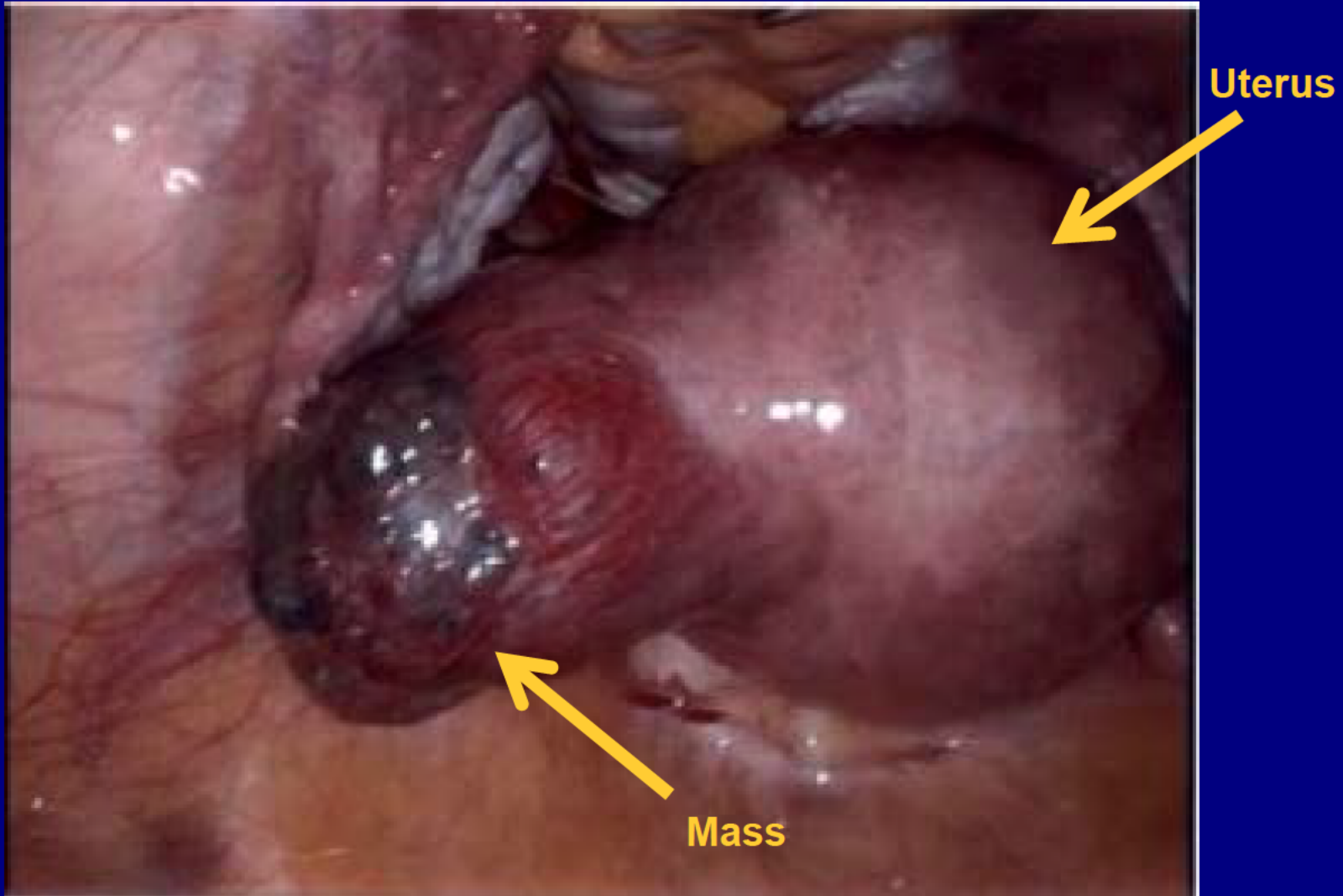
CT



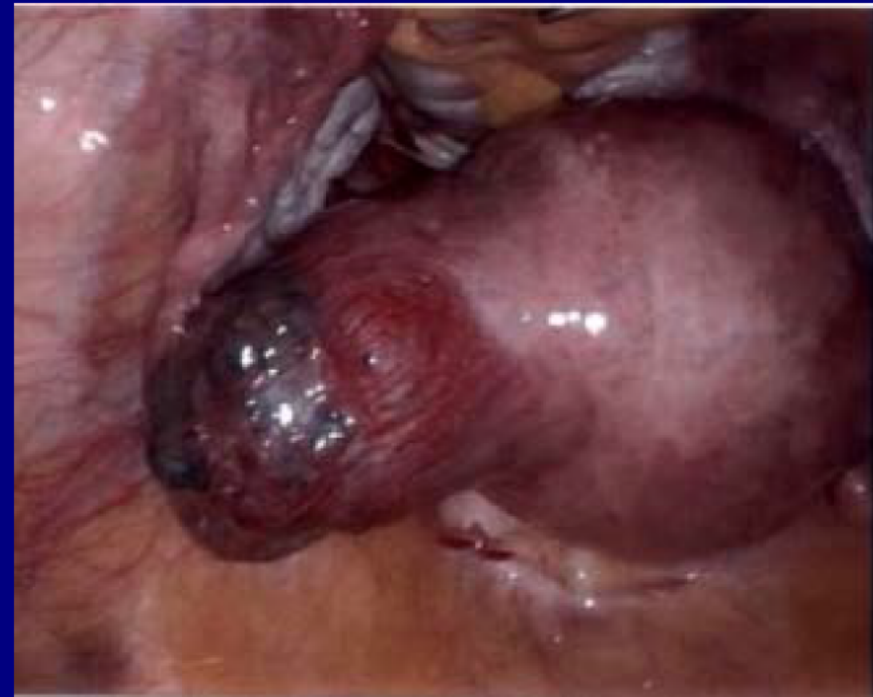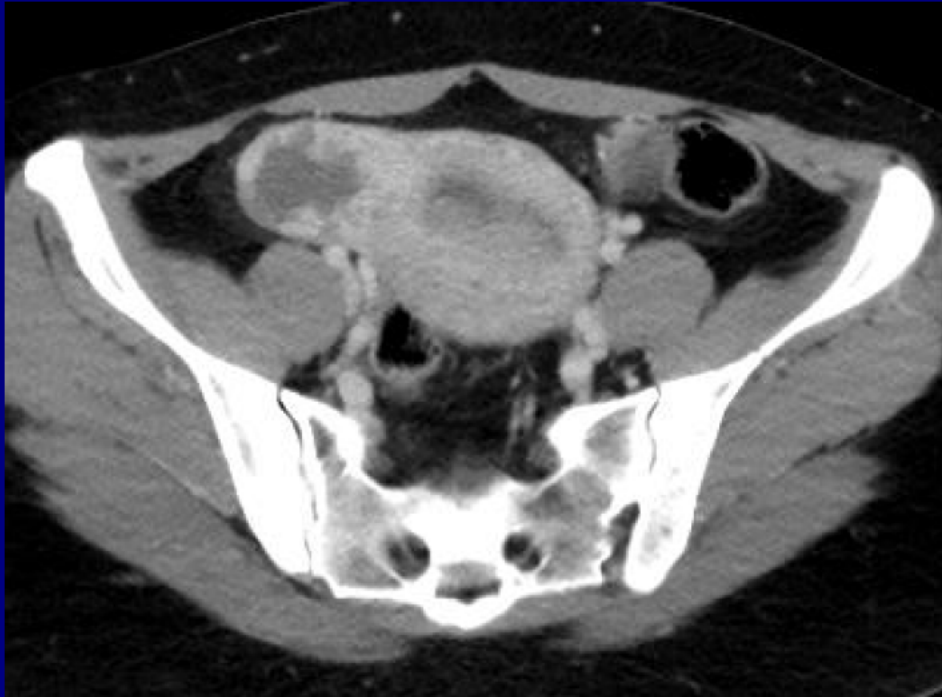
Laproscopy



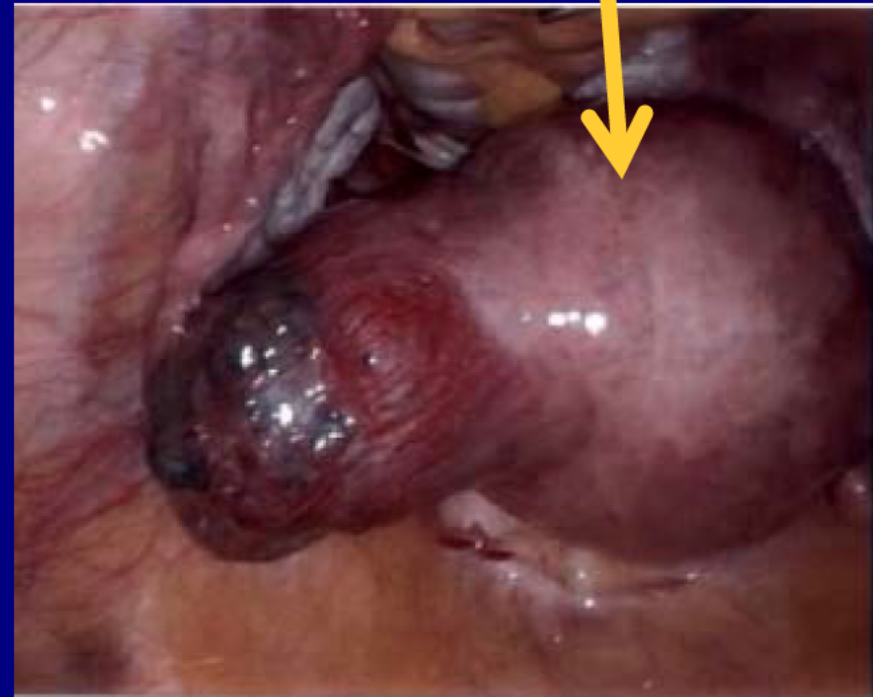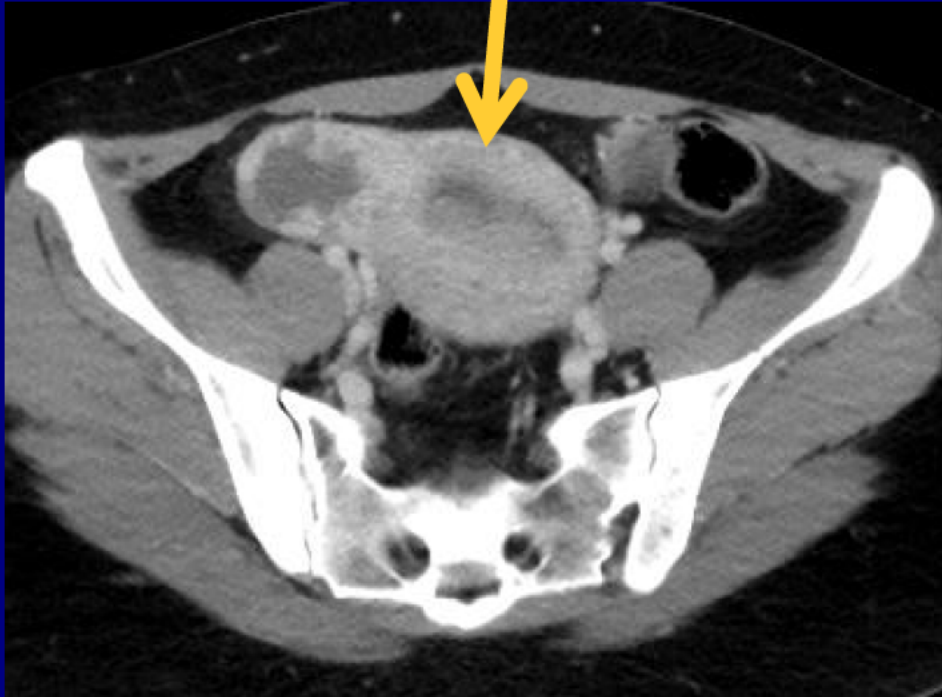Laproscopy



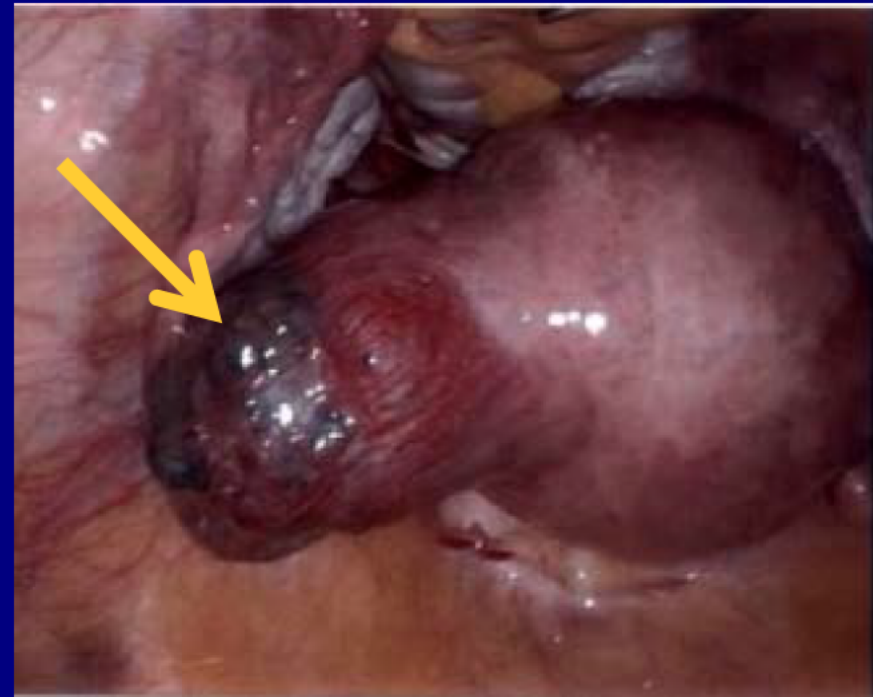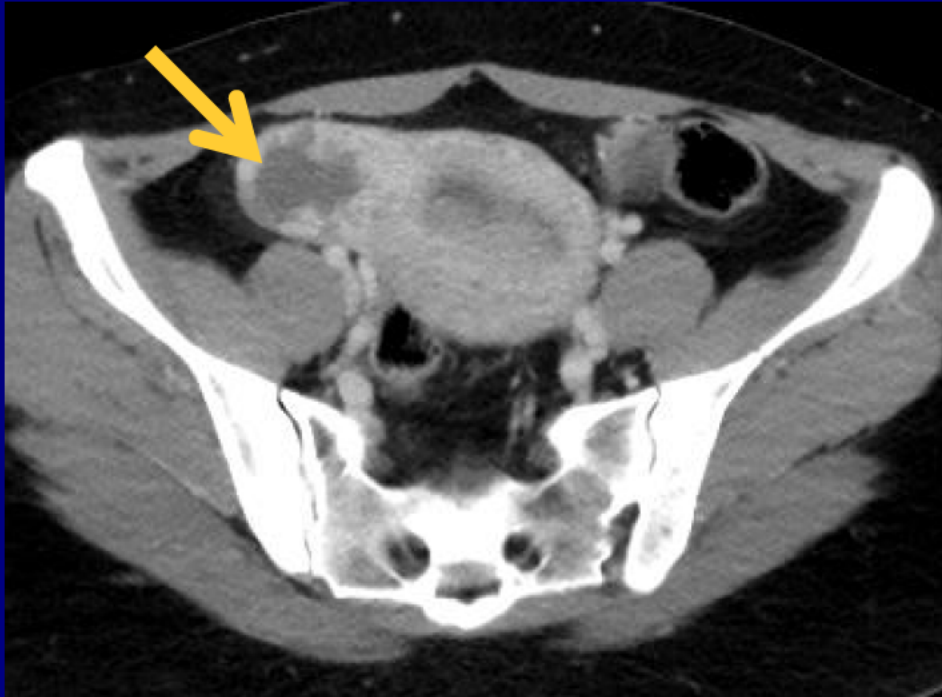
Laproscopy



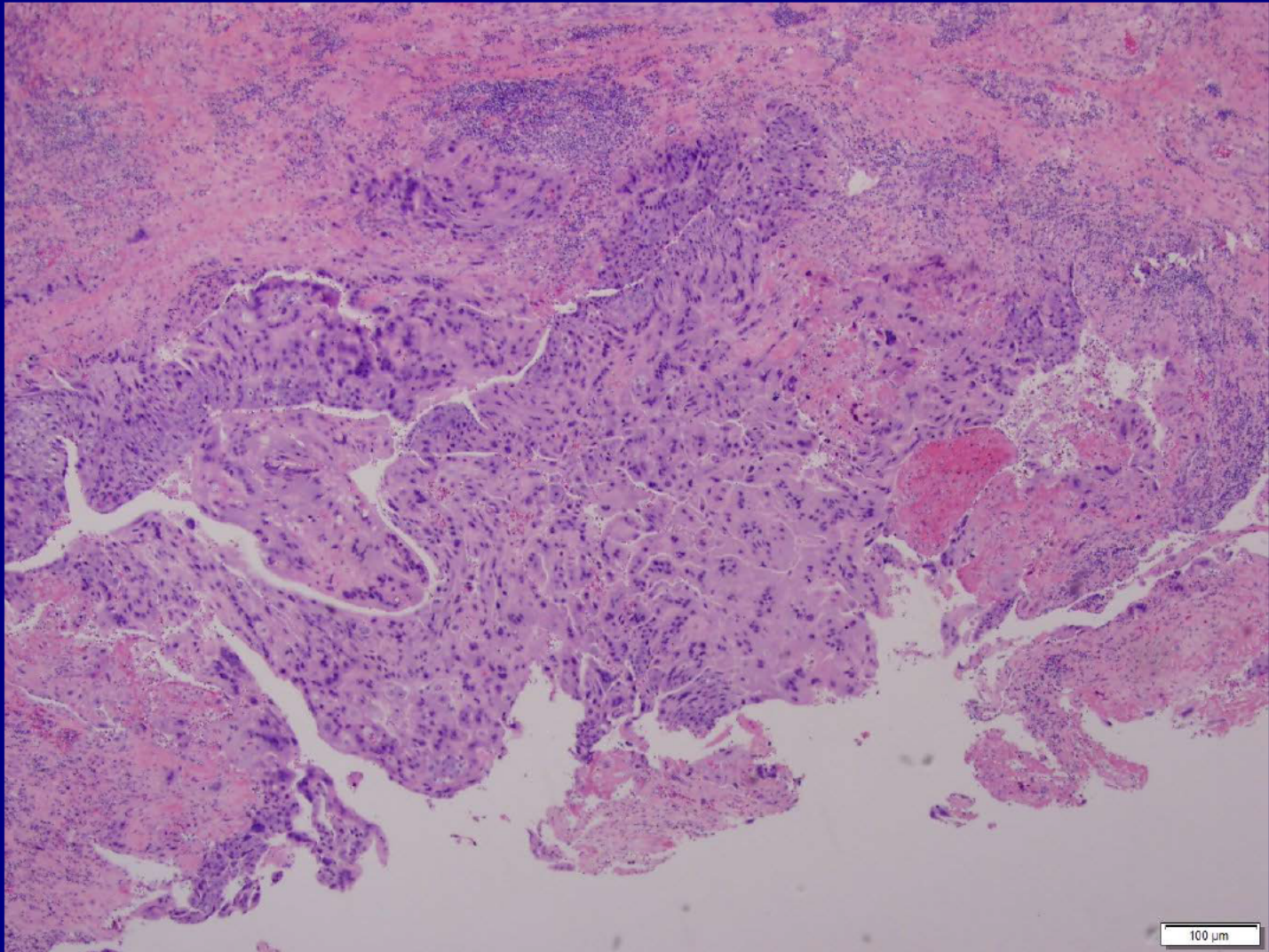
Laproscopy



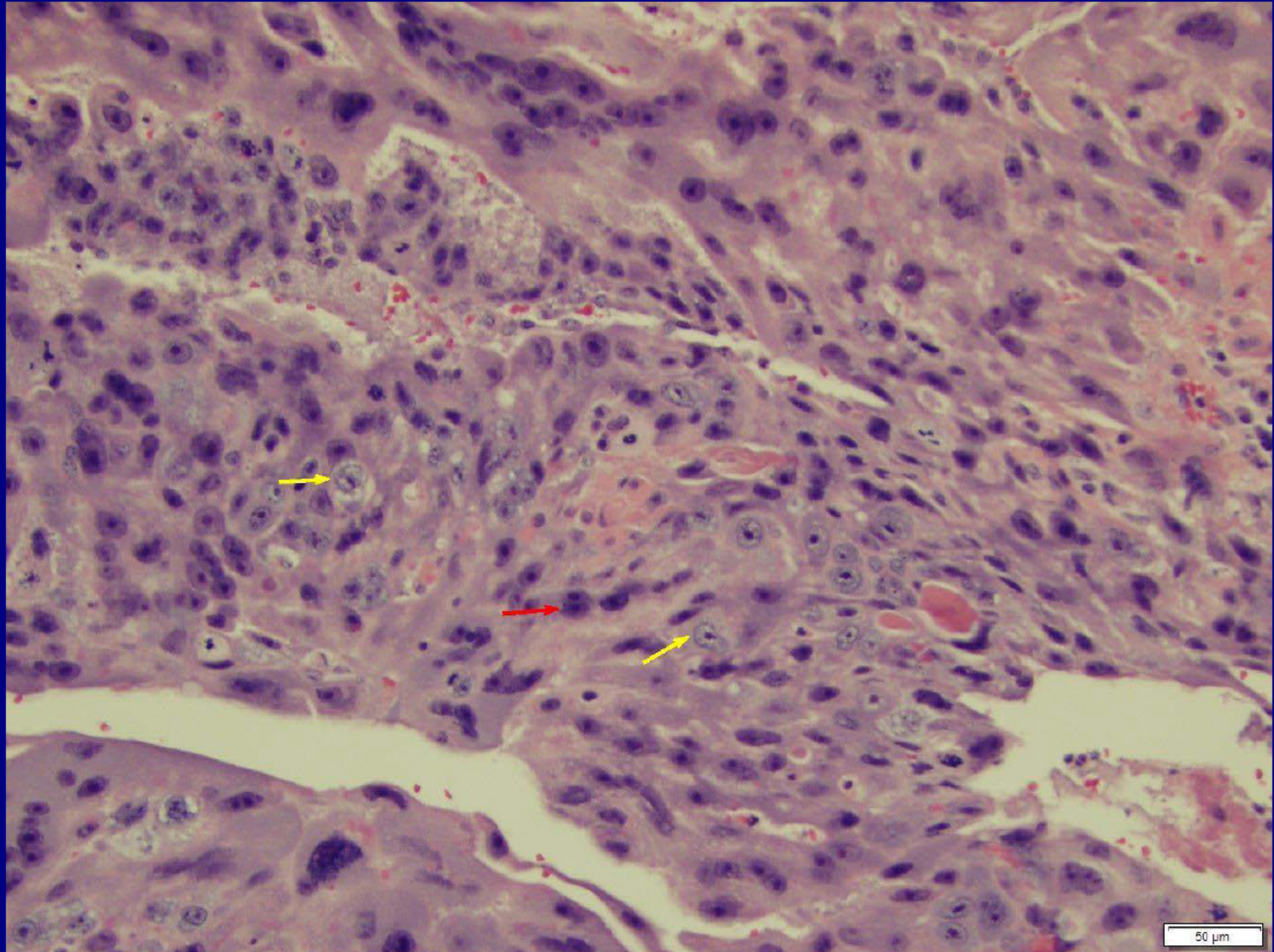
Laproscopy



Histology



Histology



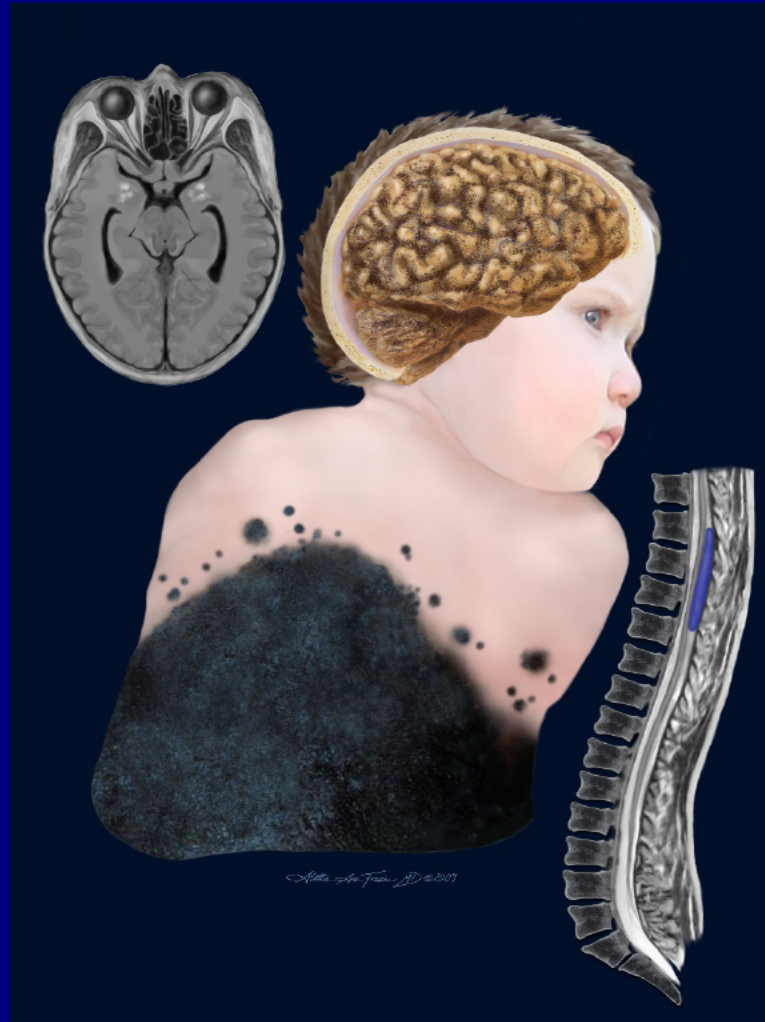Choriocarcinoma

Rachel Shields, MD

University of Rochester Medical Center

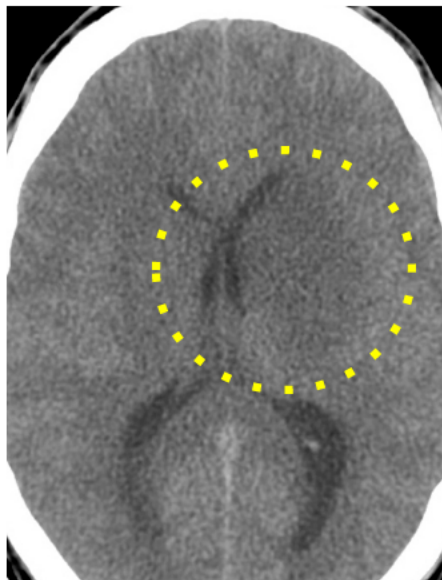
Rochester, NY

Neuroradiology Best Case

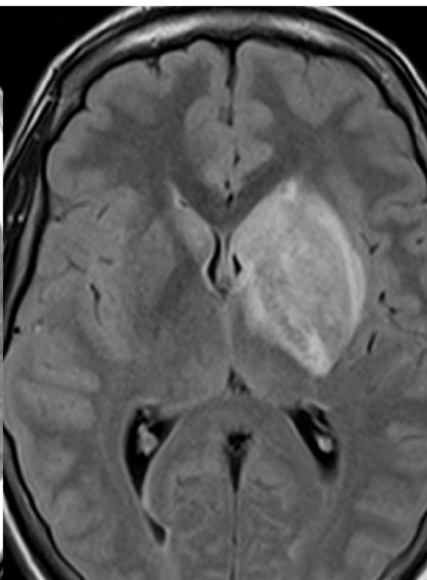


Clinical Information

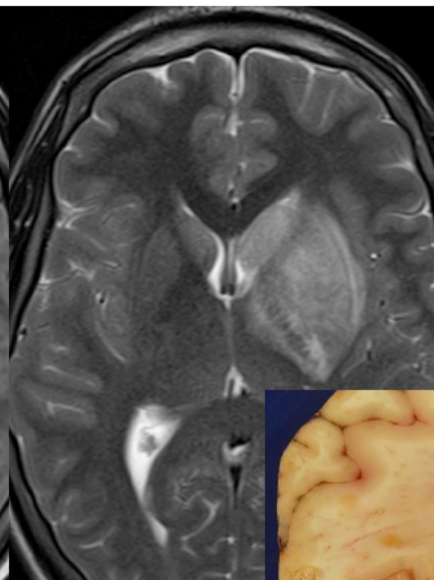
23-year-old male with progressively altered mental status. Known intranasal heroin user.



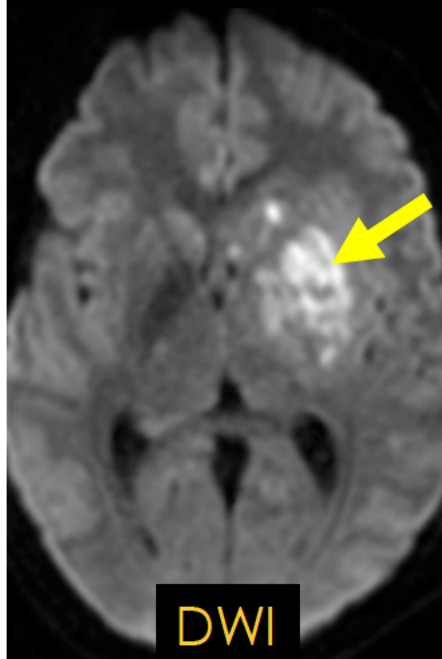
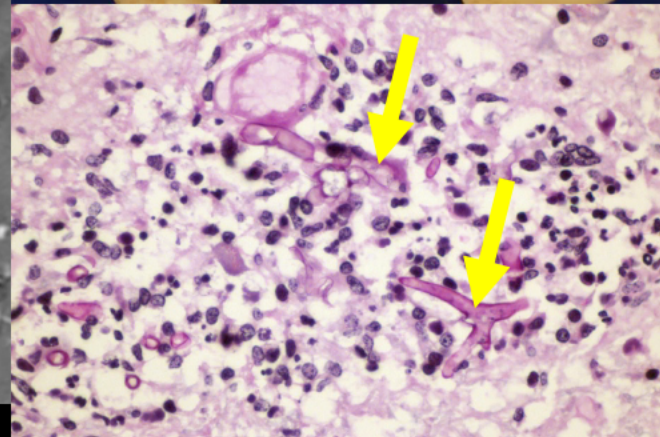
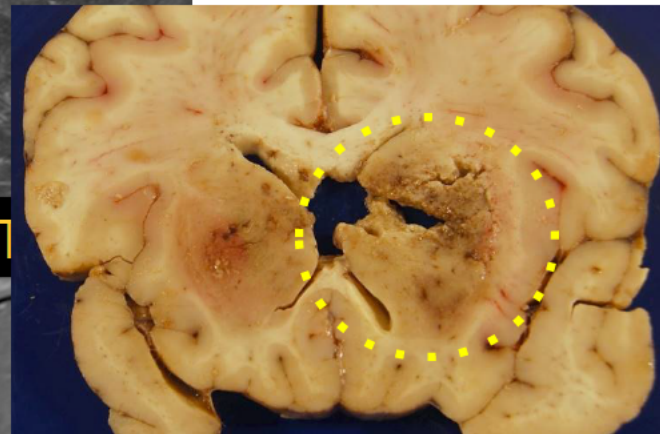
CT without



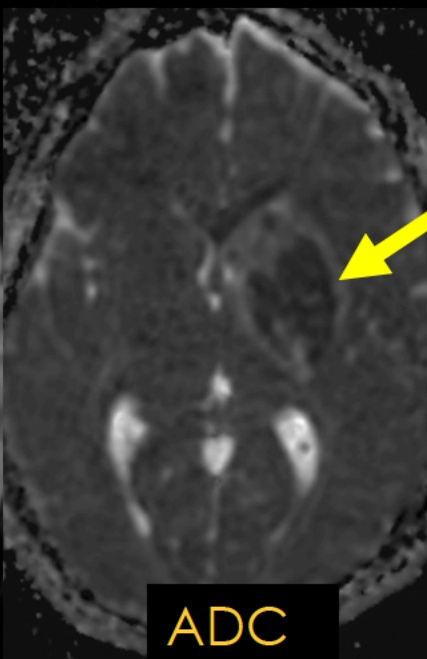
Ax FLAIR



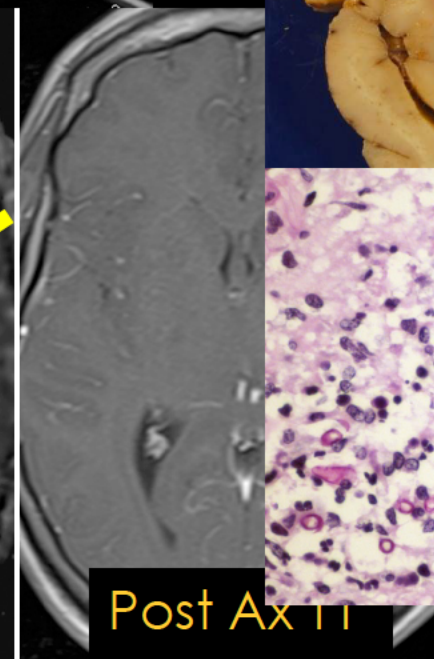
Ax T2



DWI



ADC

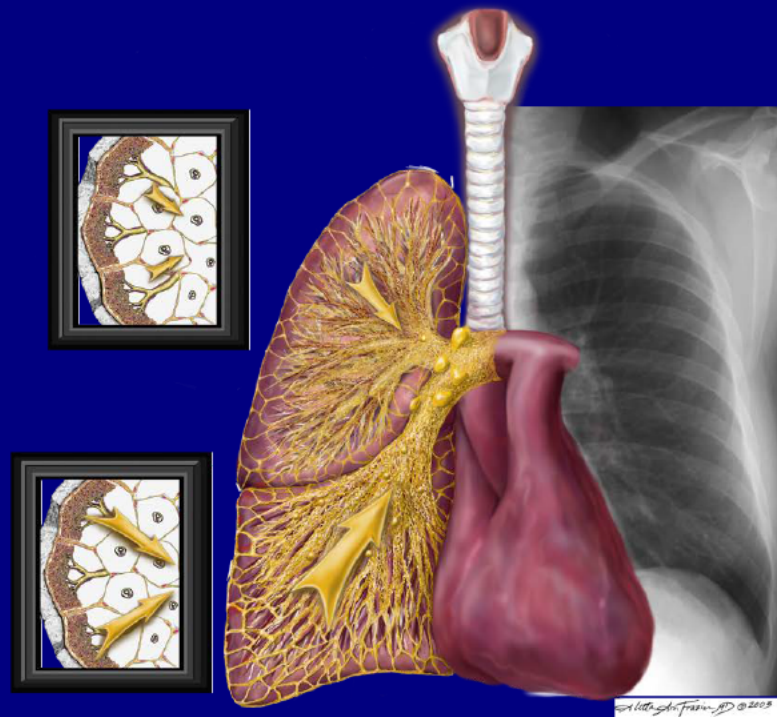


Post Ax T1

Zygomycosis (probable mucormycosis)

Emily Orschein, MD
University of Cincinnati
Cincinnati, Ohio

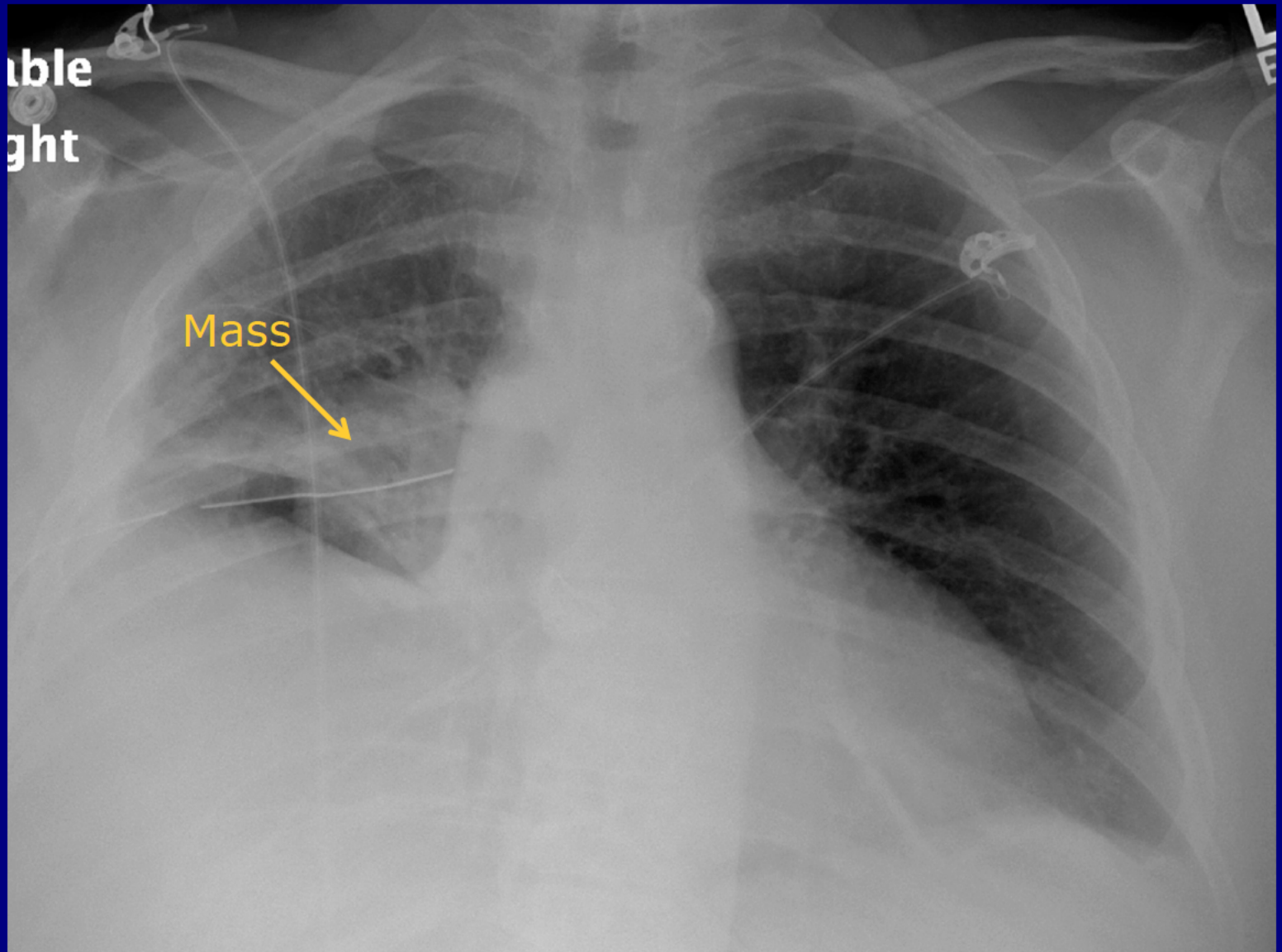
Pulmonary and Mediastinal Best Case



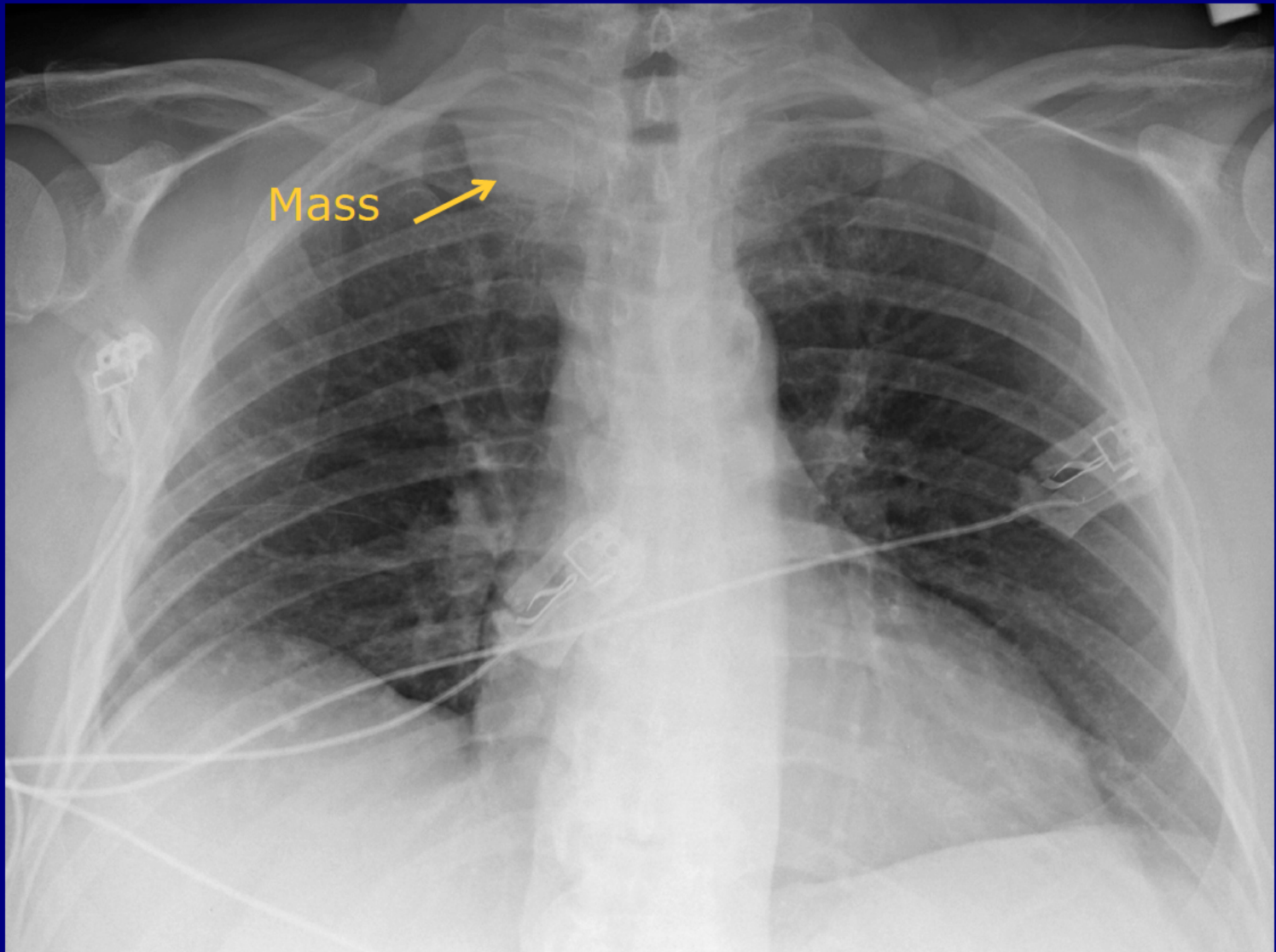
Clinical Information

70 year old female transferred to the emergency room status post lung biopsy of a right apical lung mass

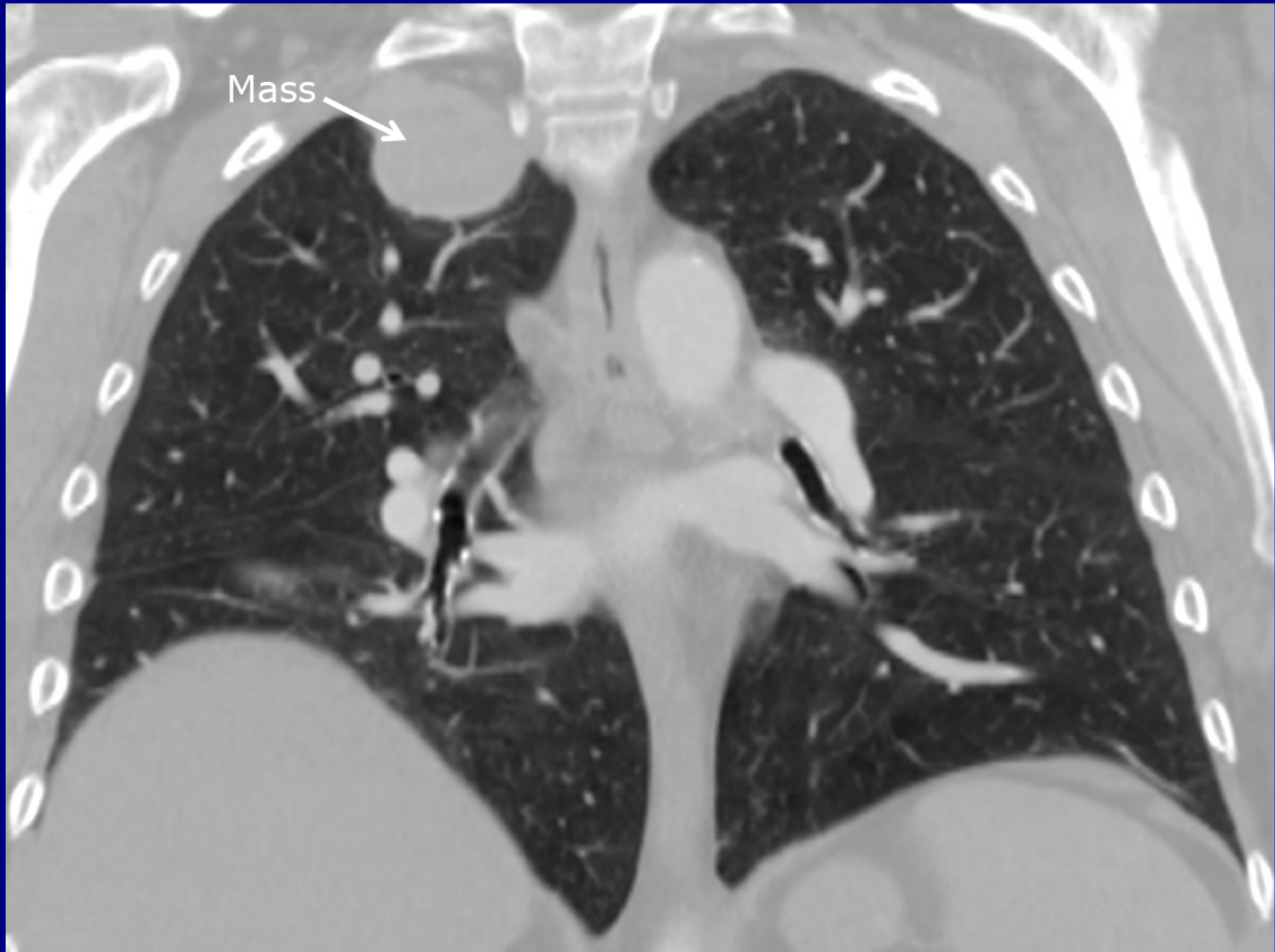Post biopsy position of the mass



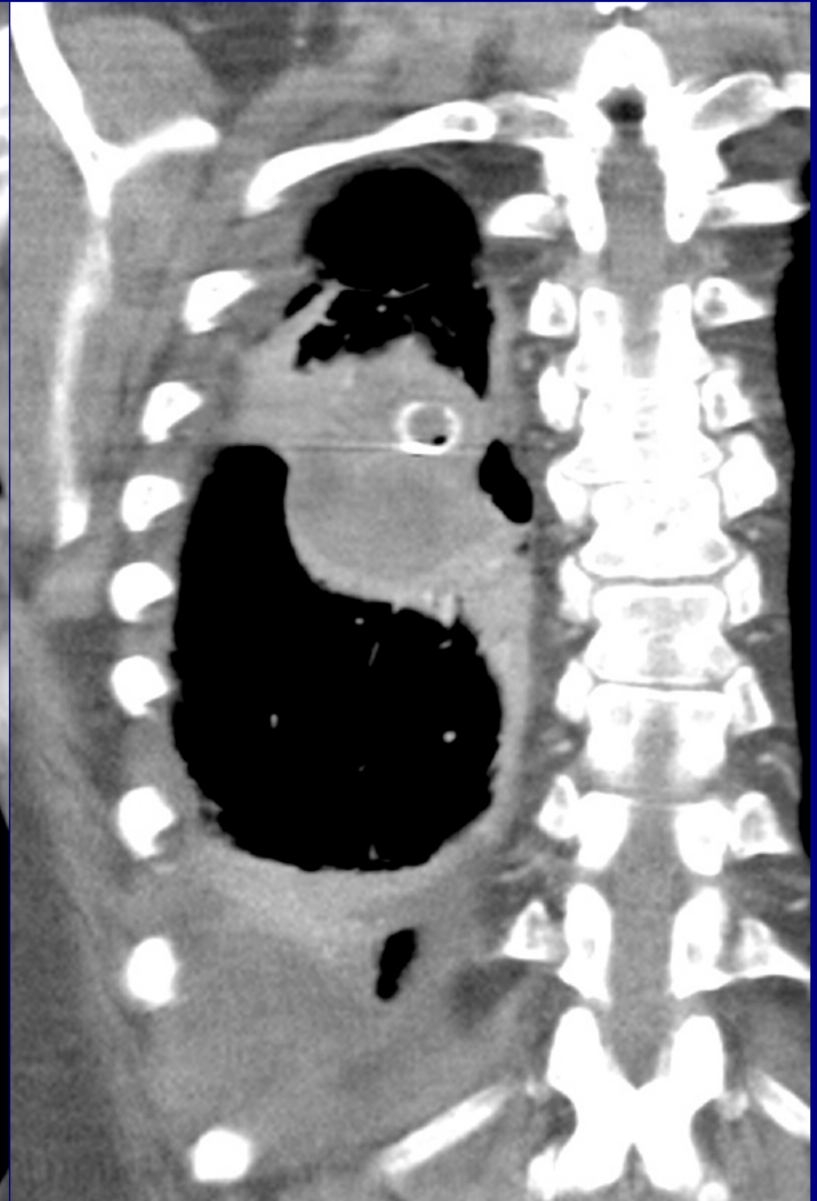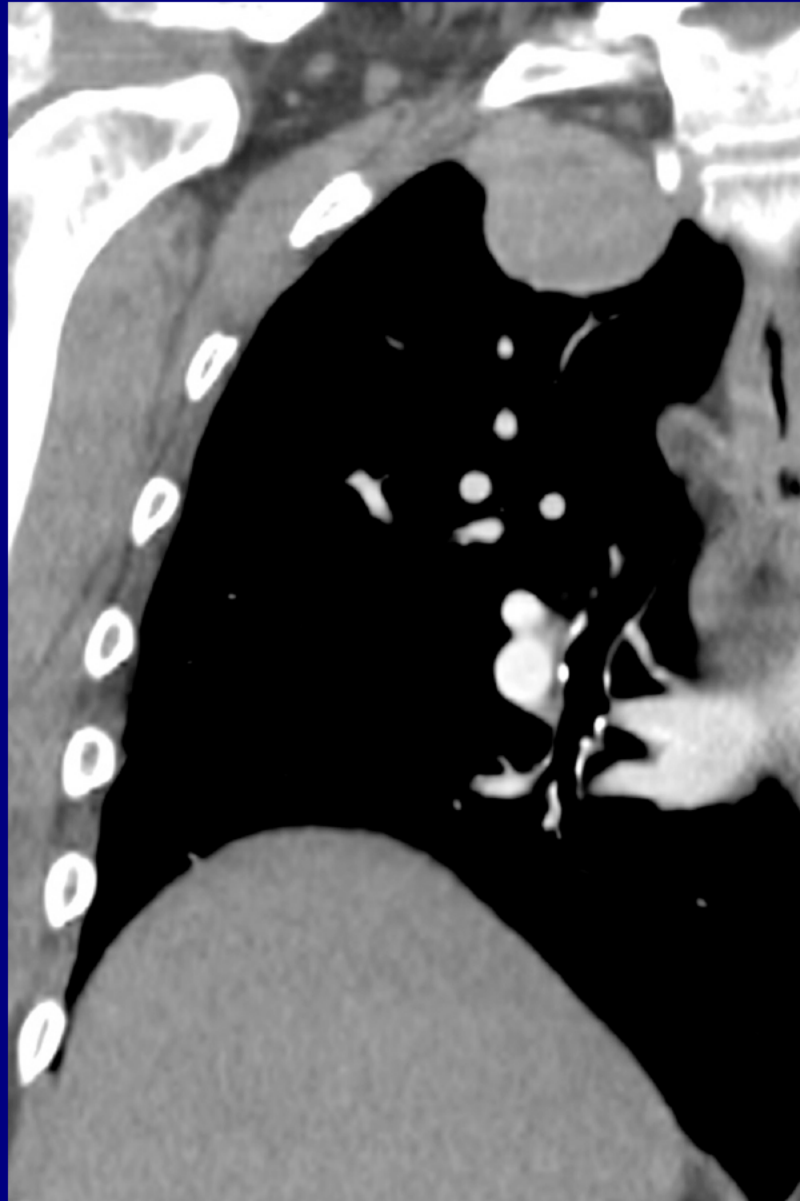
Mass position prior to biopsy



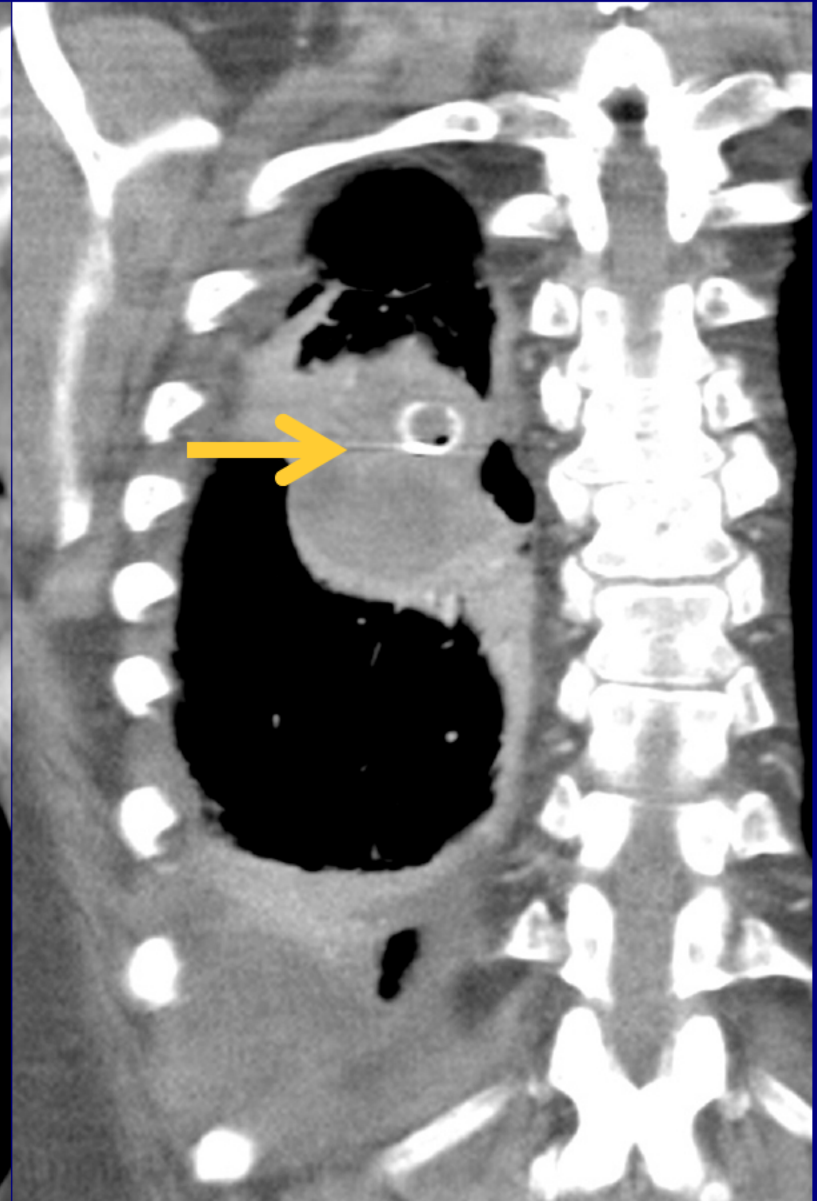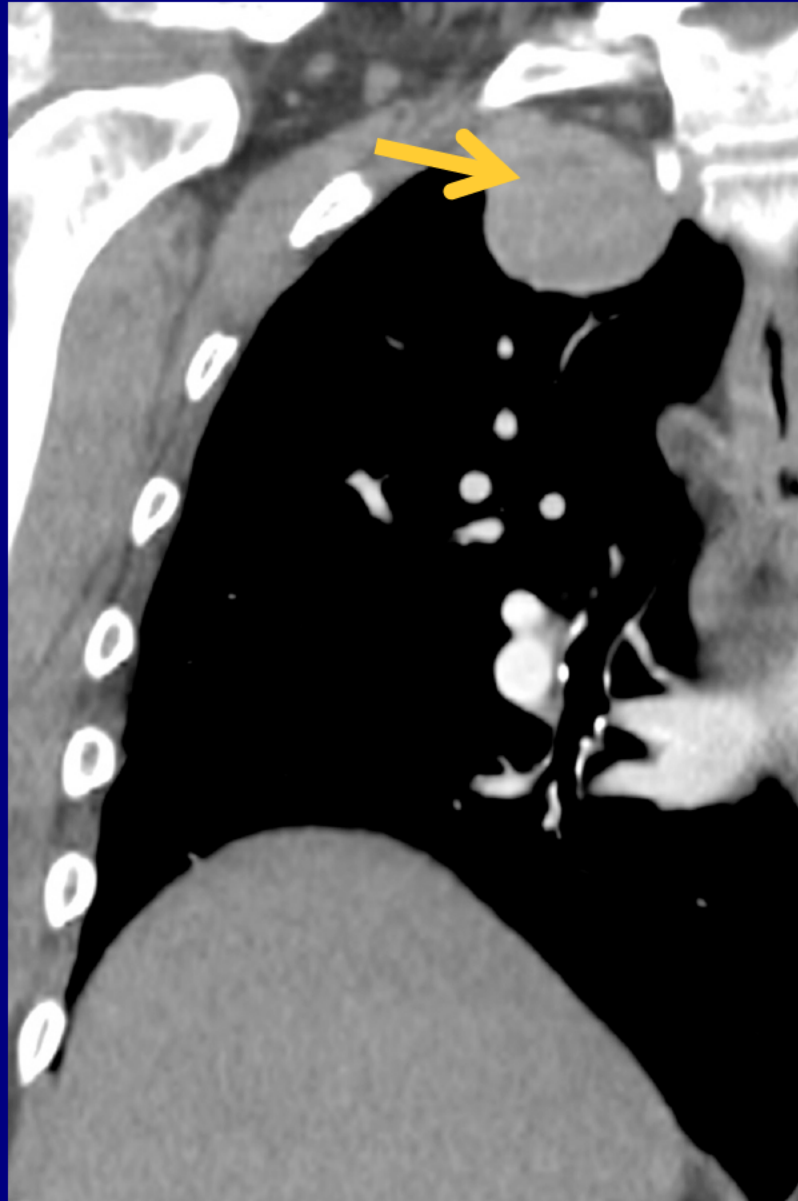
Mass position prior to biopsy



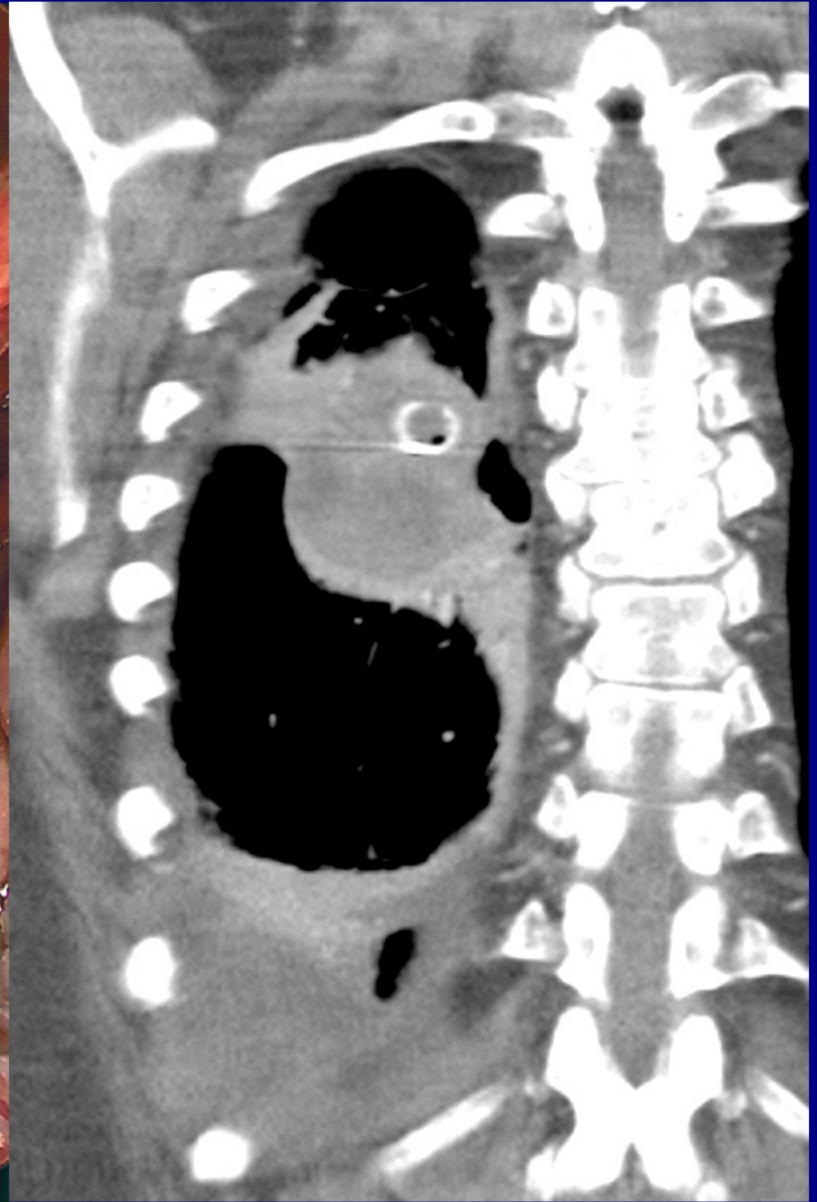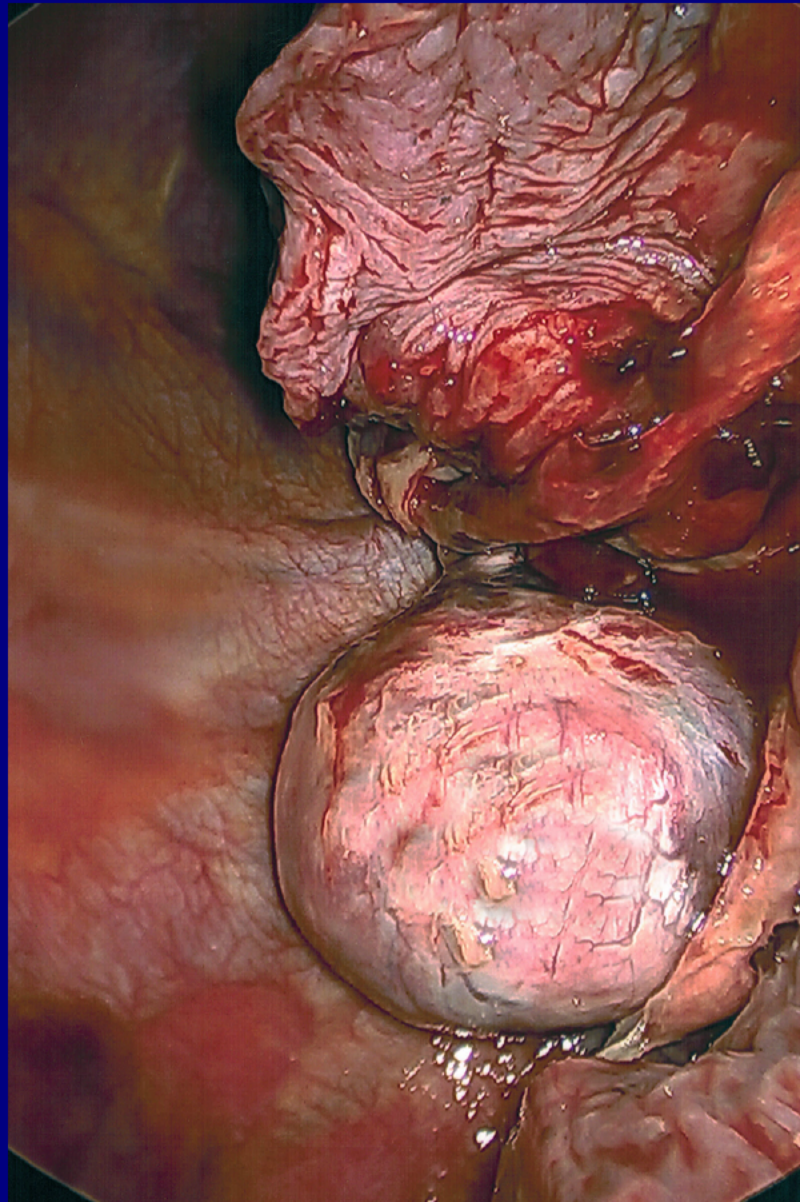
Change in position of the mass



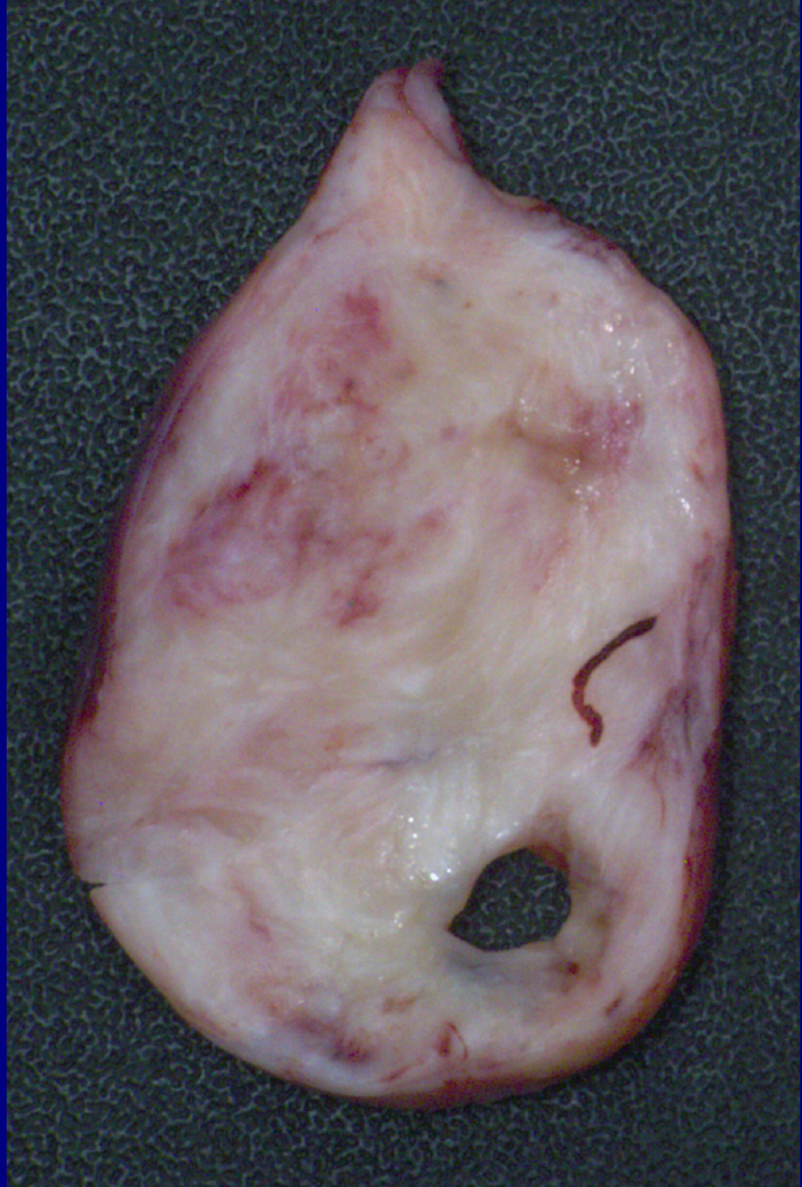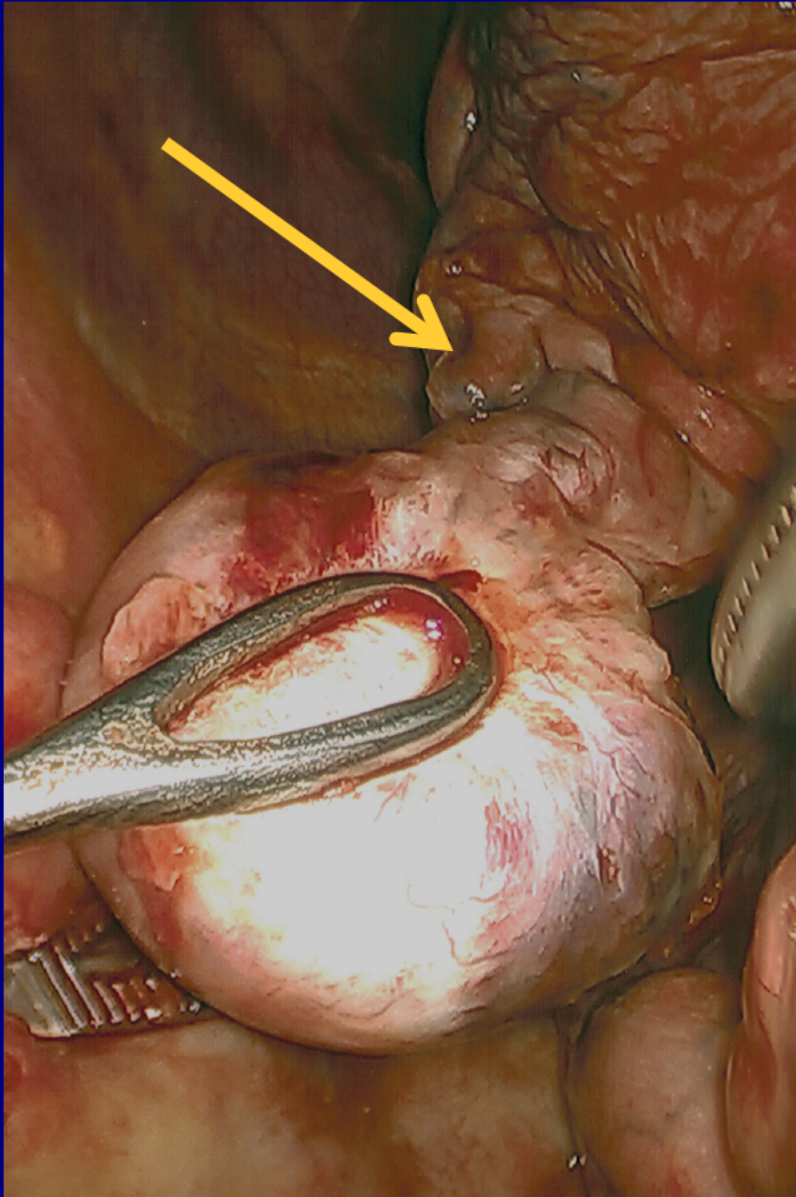
Change in position of the mass



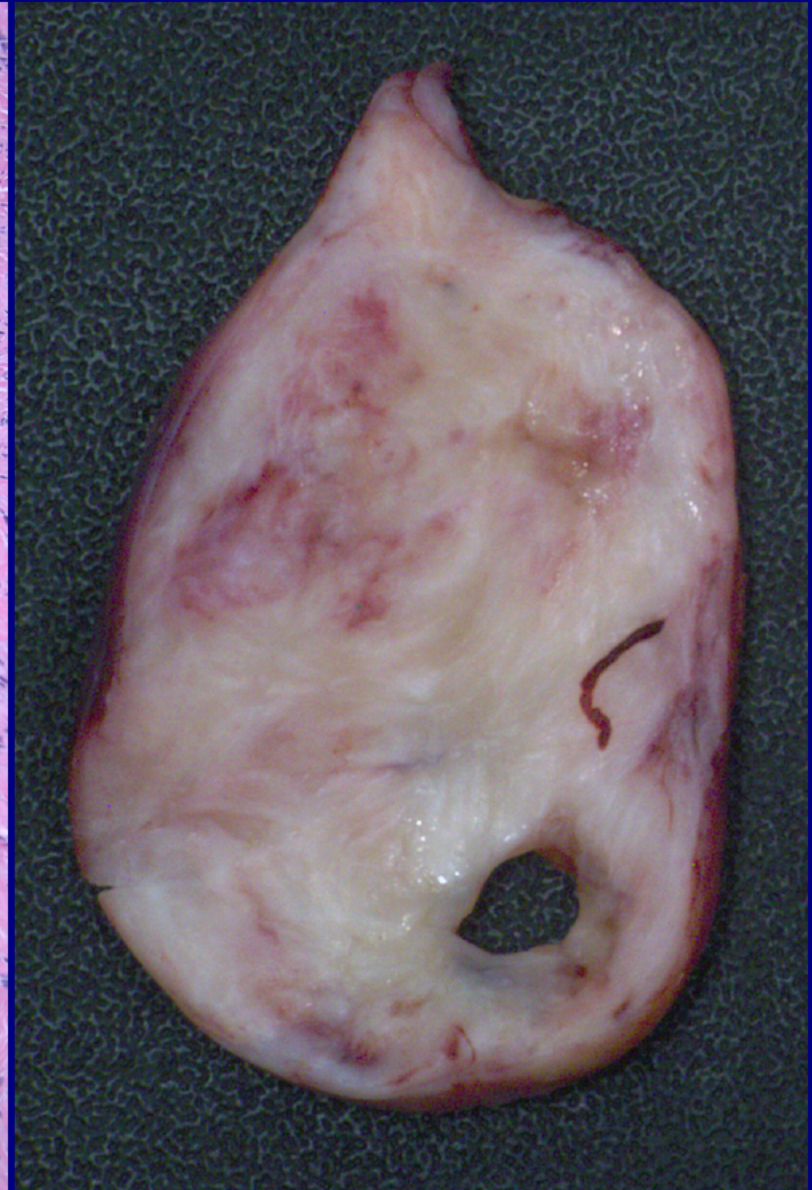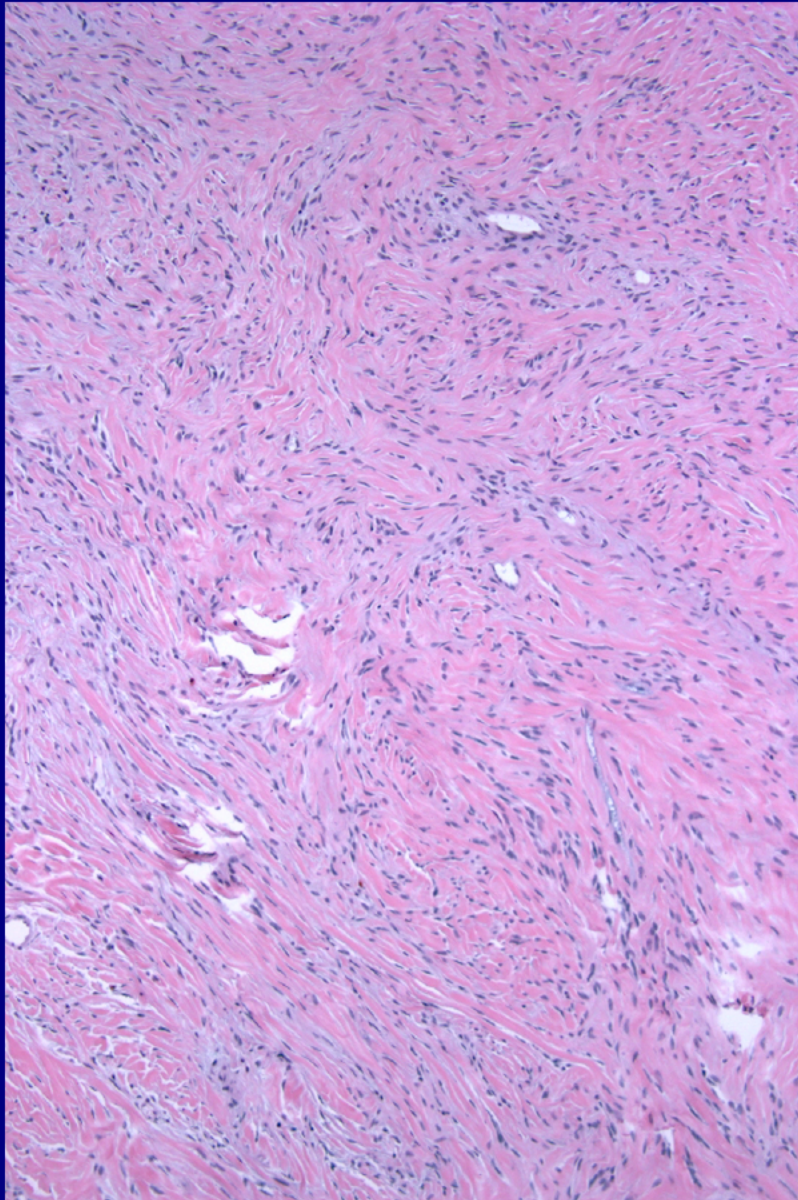
Mass on a vascular pedicle



Mass on a vascular pedicle



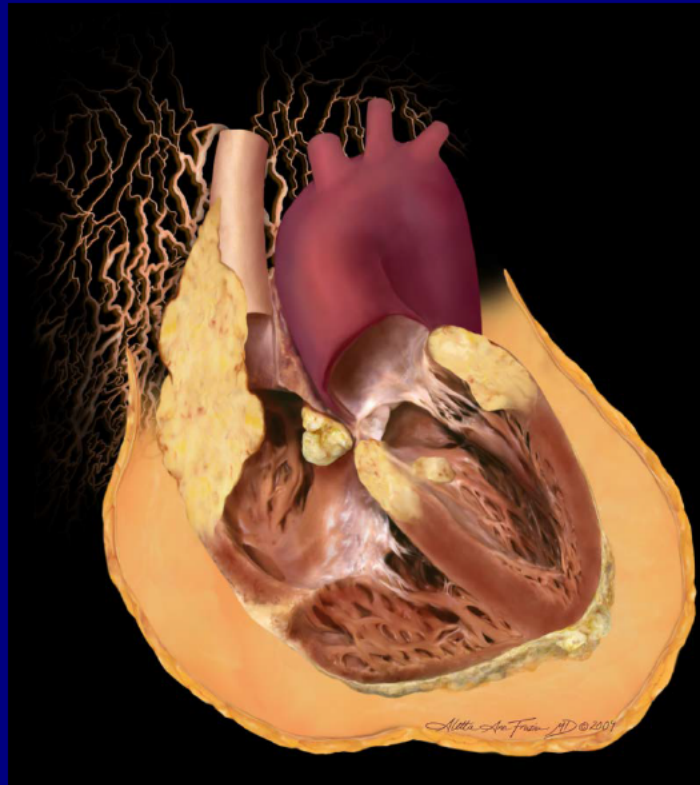Solitary Fibrous Tumor



Solitary Fibrous Tumor

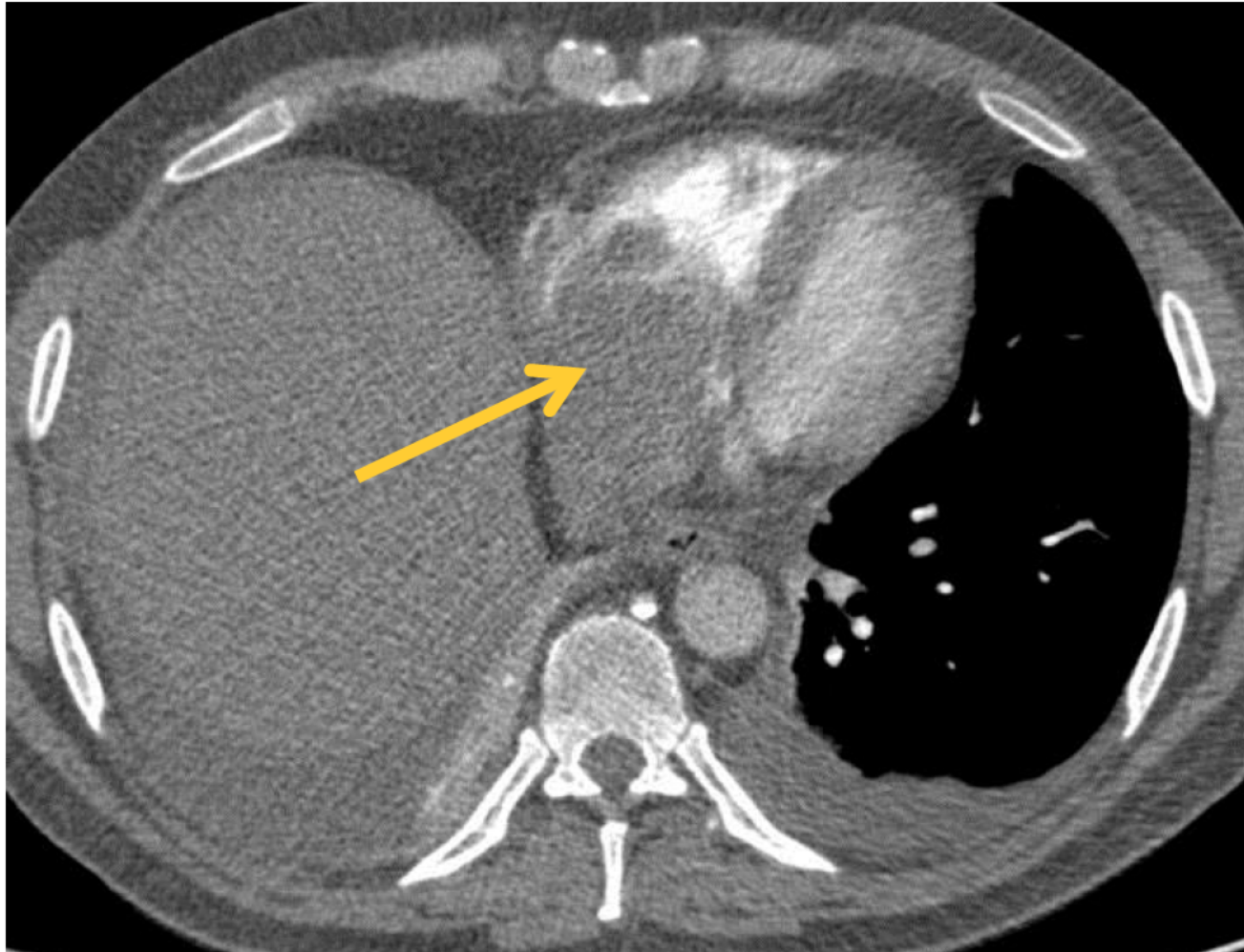
Christopher Bailey, MD
West Virginia University
Morgantown, WV

Cardiovascular Best Case

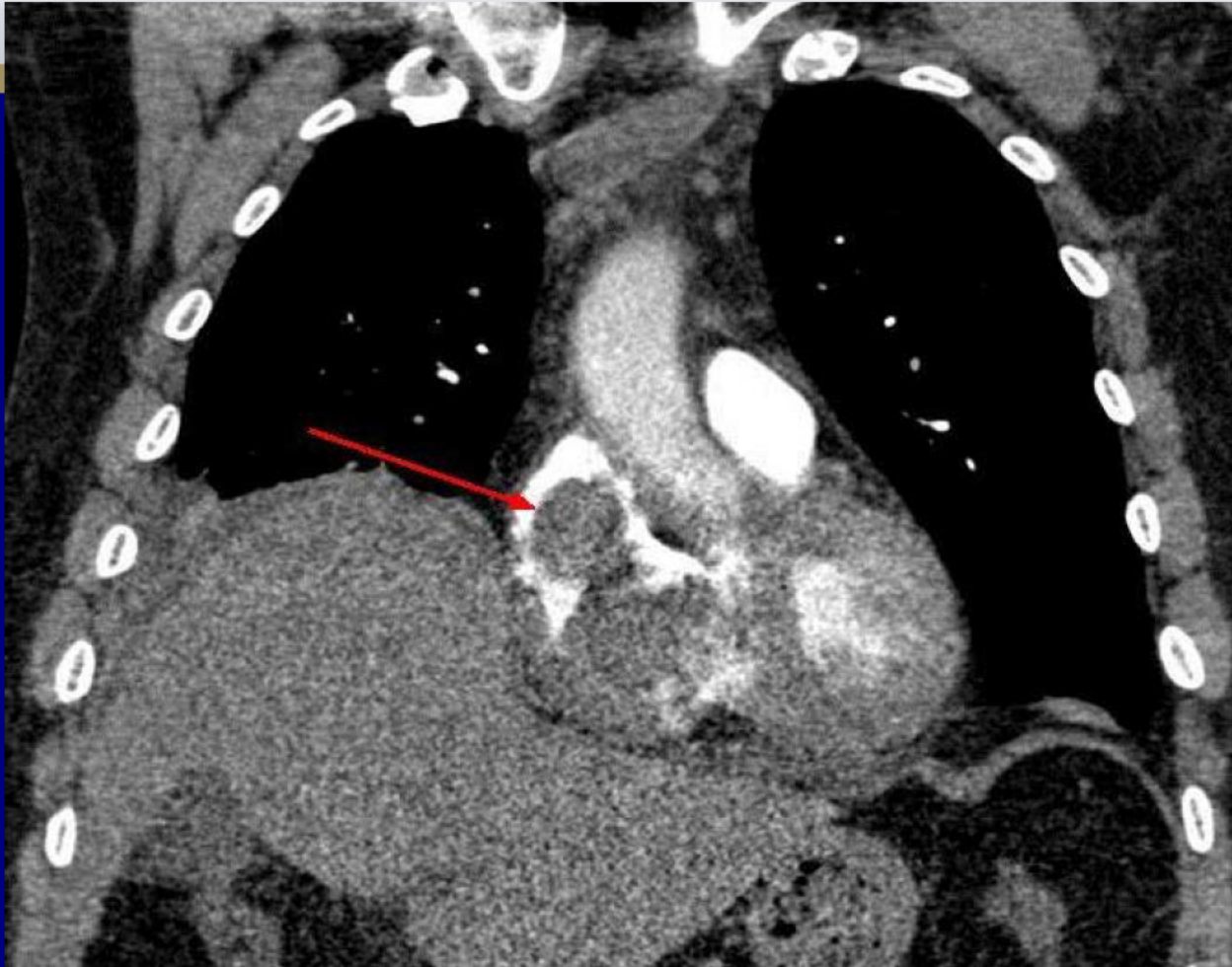


Clinical Information

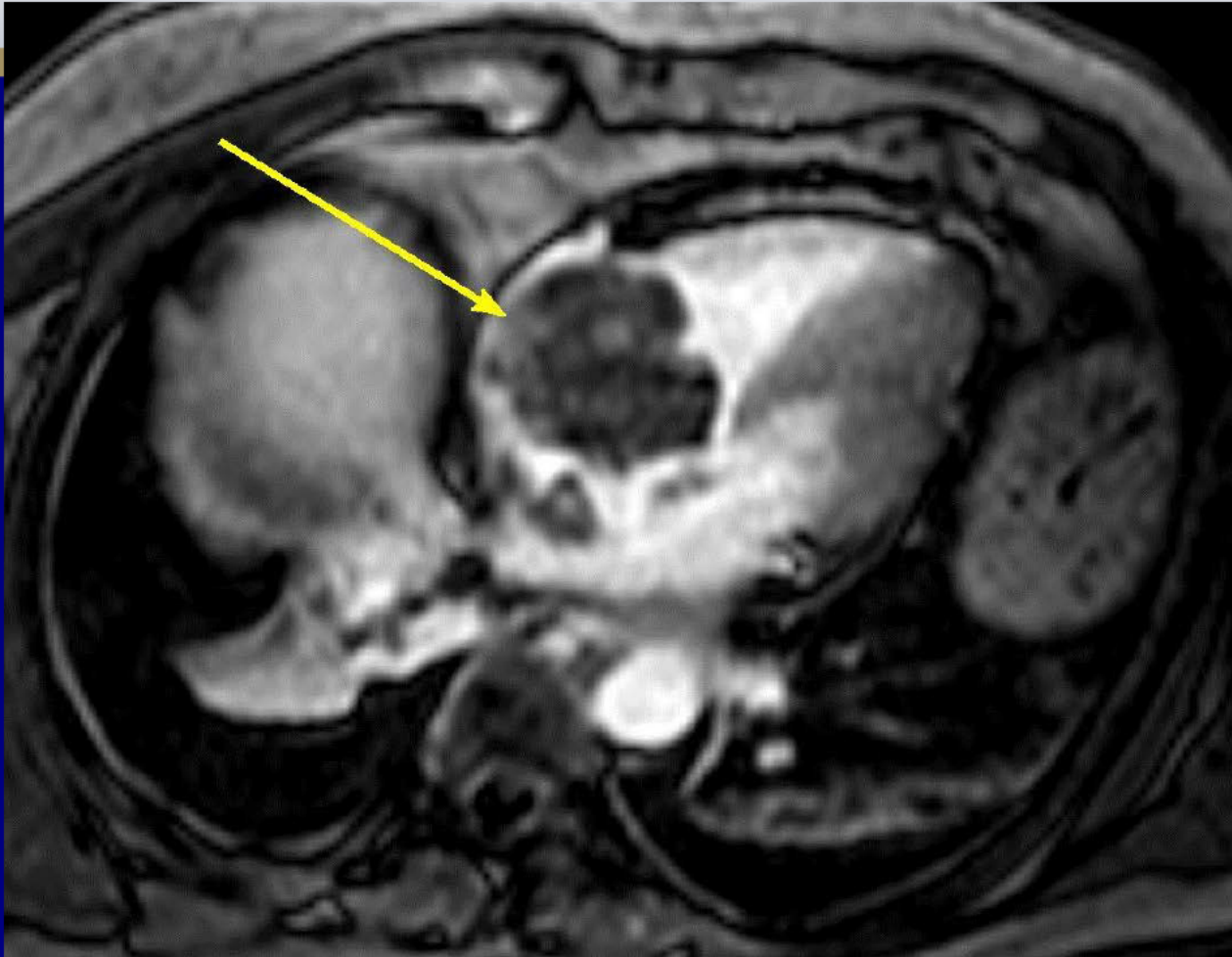
54 yo male presents to ER with
increasing dyspnea, orthopnea and
dry cough



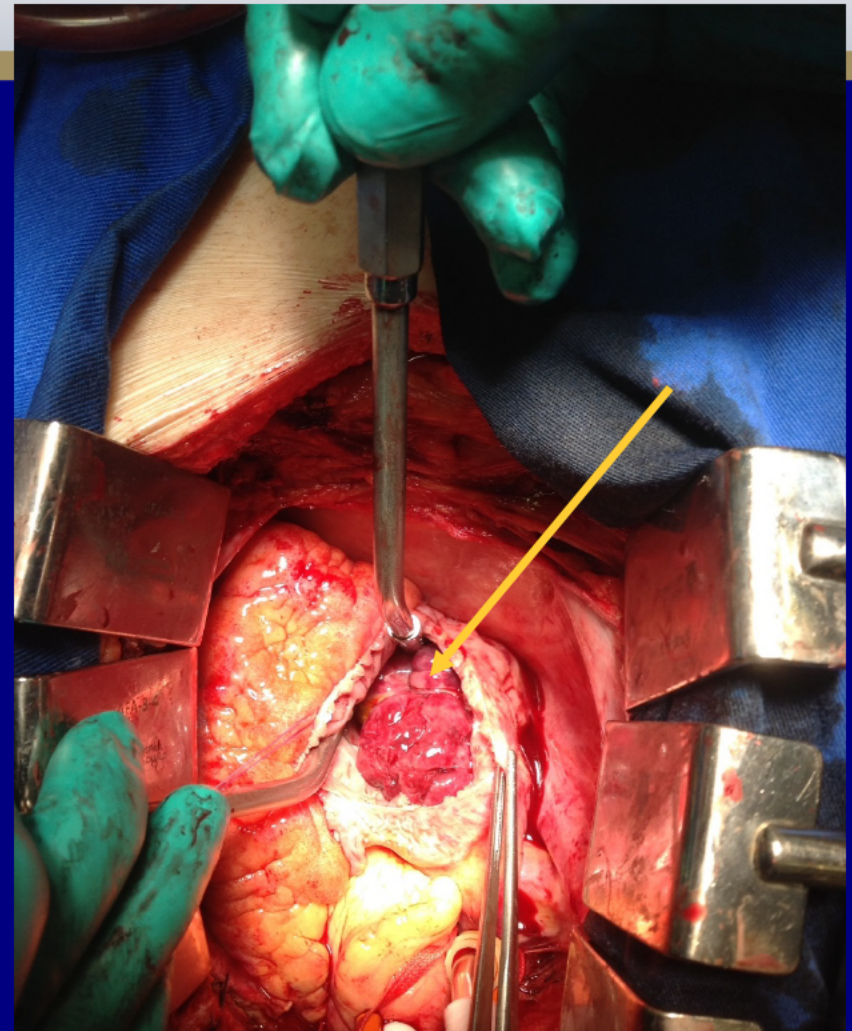
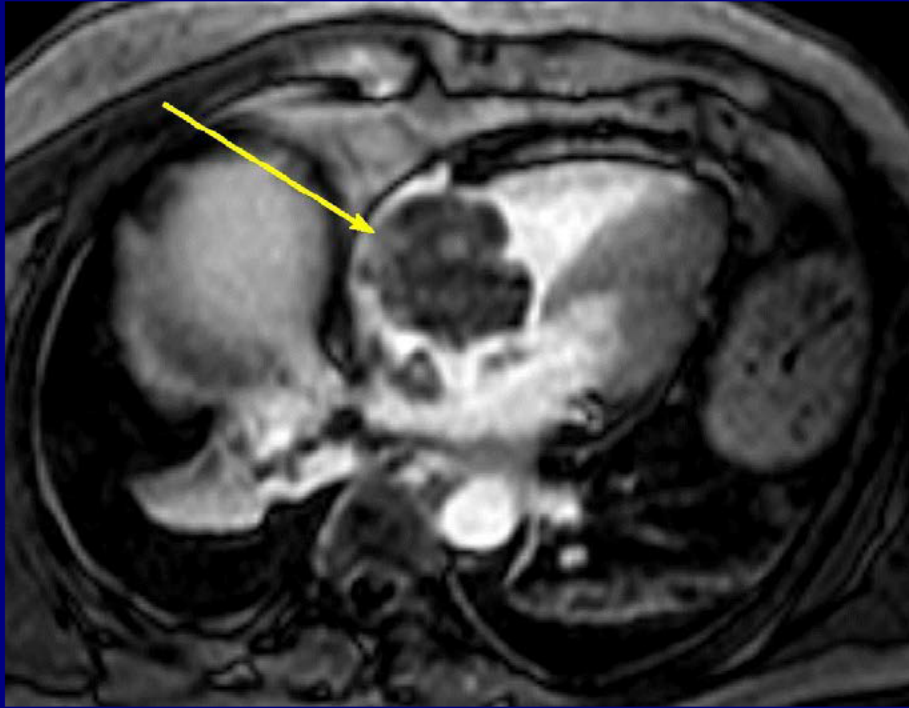
Contrast-enhanced CT of the chest shows a multilobulated soft tissue filling defect within the right atrium



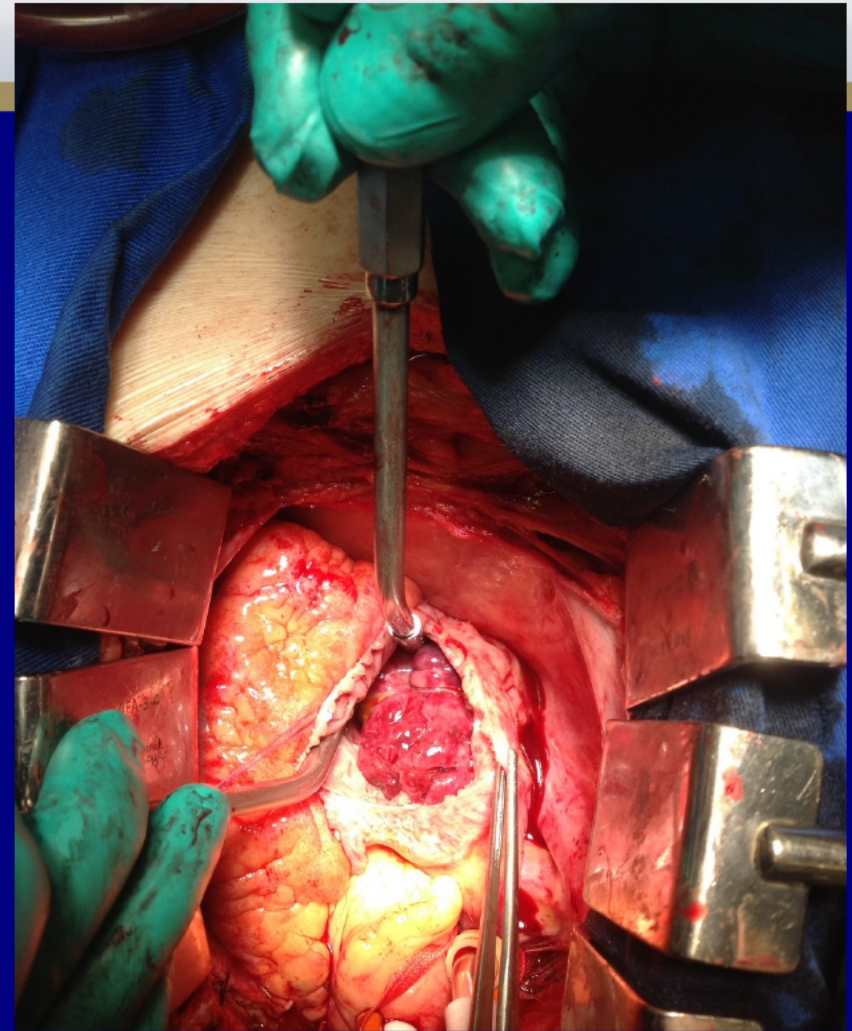
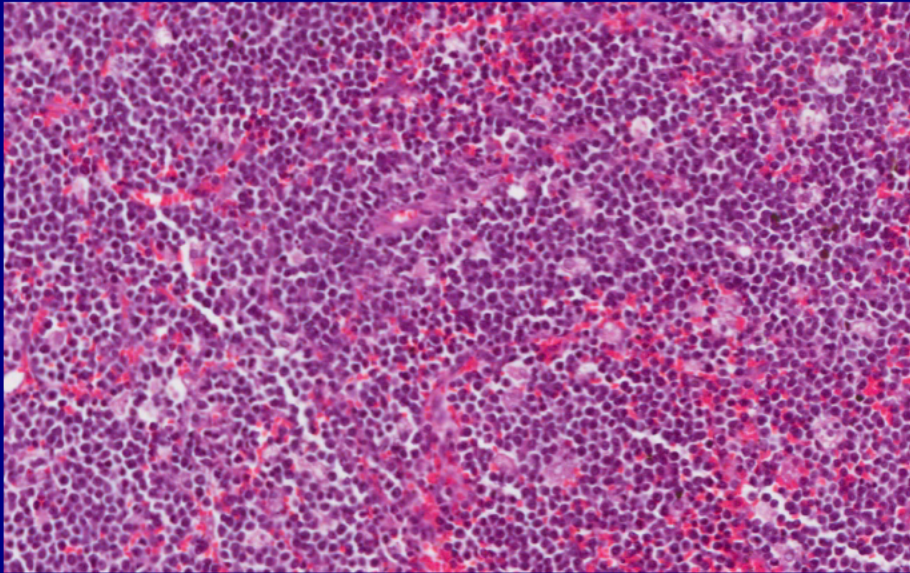
Contrast-enhanced CT of the chest (coronal reformat) confirms multilobulated soft tissue filling defect (red arrow) within right atrium



Axial T1-weighted post-gadolinium MR image shows heterogeneous contrast enhancement of the right atrial mass (yellow arrow)



Intraoperative view of opened right atrium shows multi-lobulated pink vascular mass within the chamber

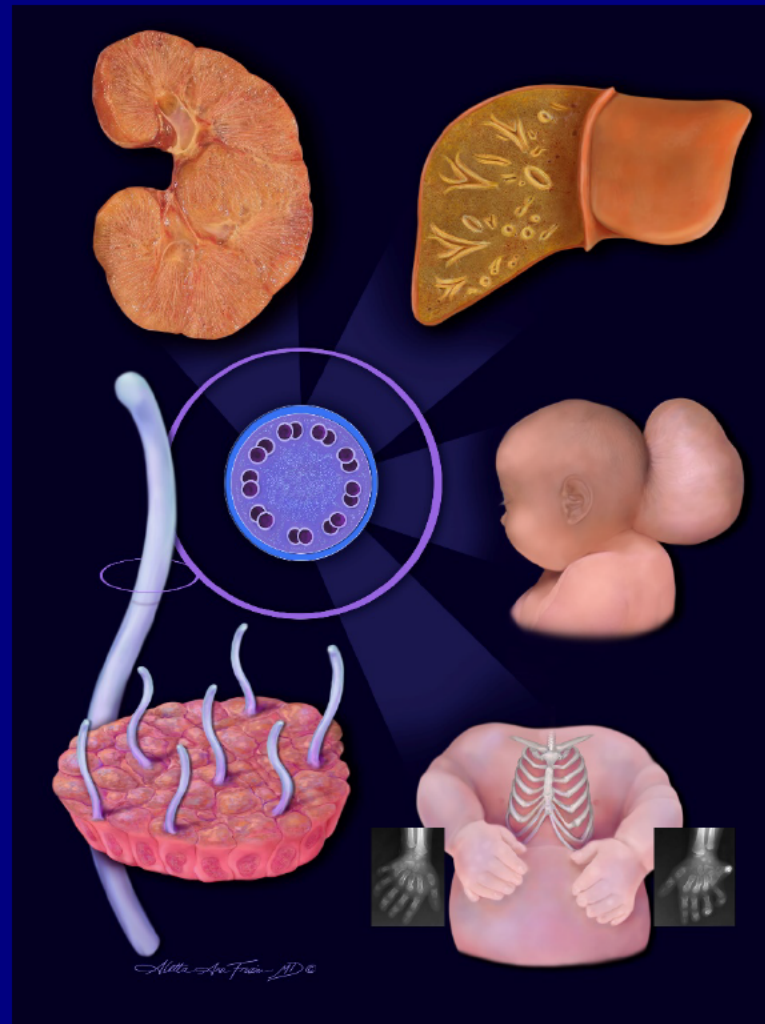


Histologic examination shows a “starry sky” appearance of densely packed tumor cells packed around macrophages.

B cell (Burkitt's) Lymphoma

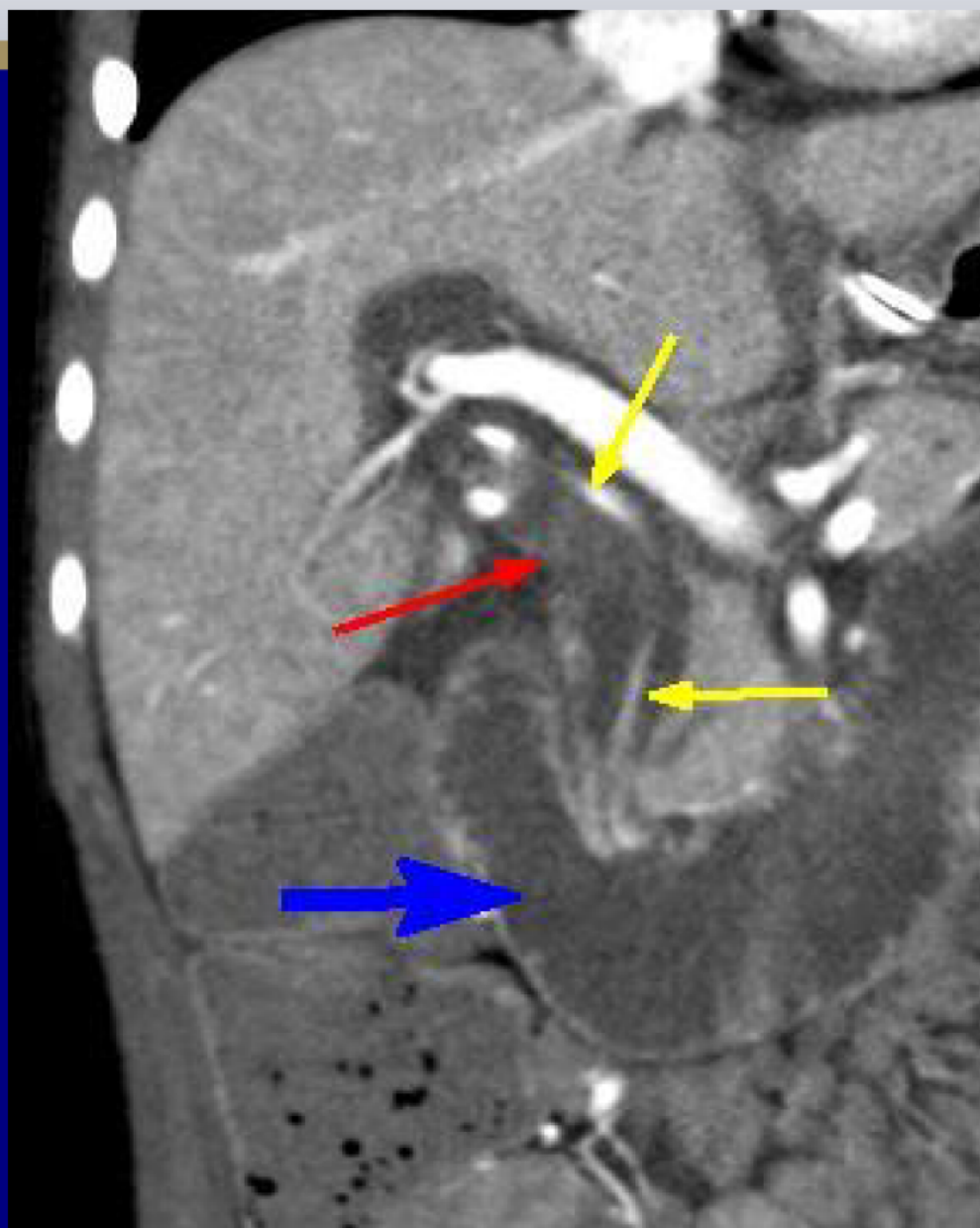Janaina Johnsson, MD
Hospital Sao Camilo
Sao Paulo, Brazil

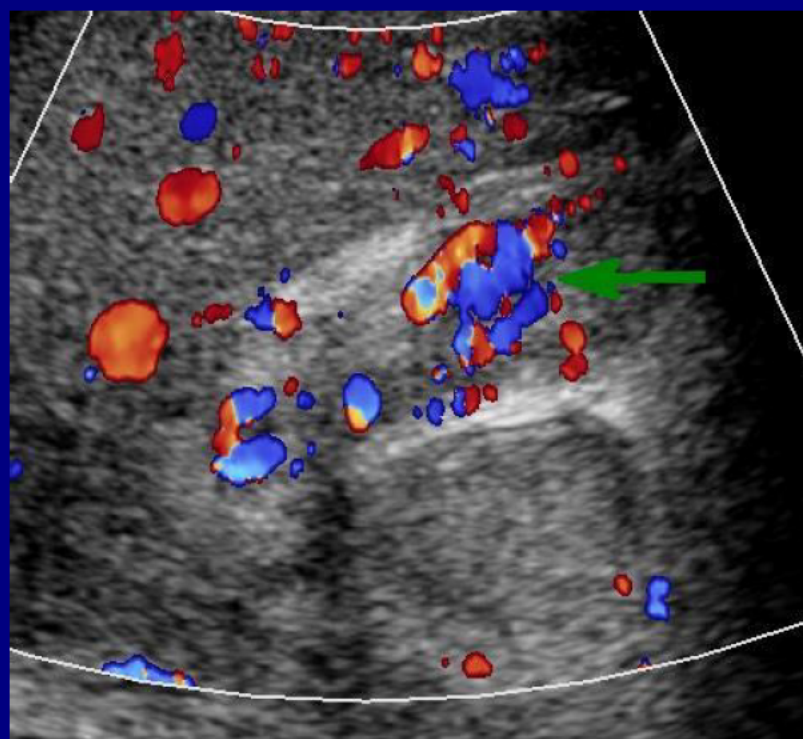
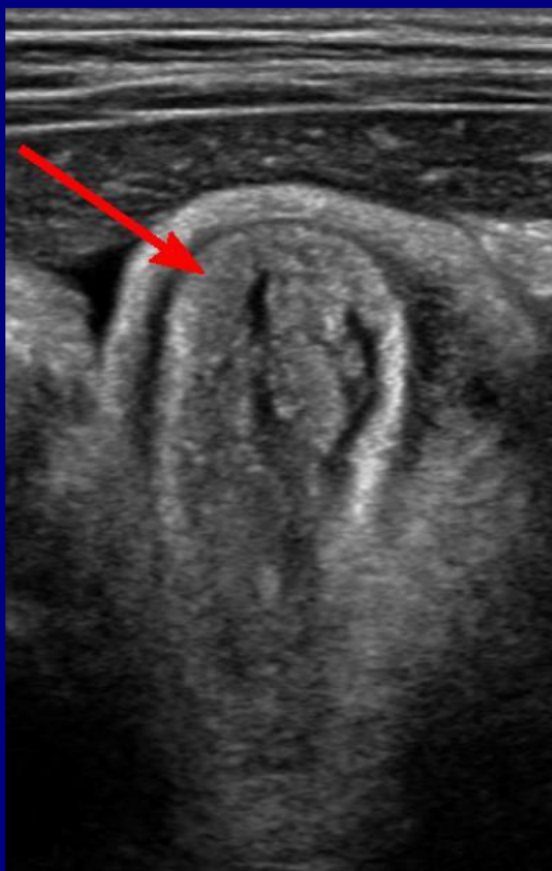
Pediatric Best Case

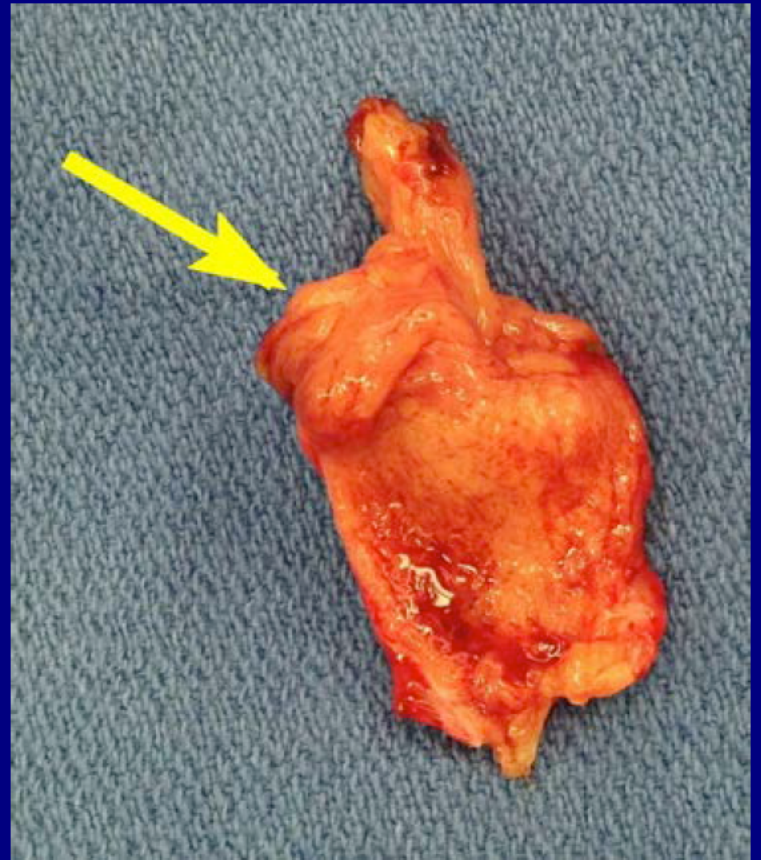
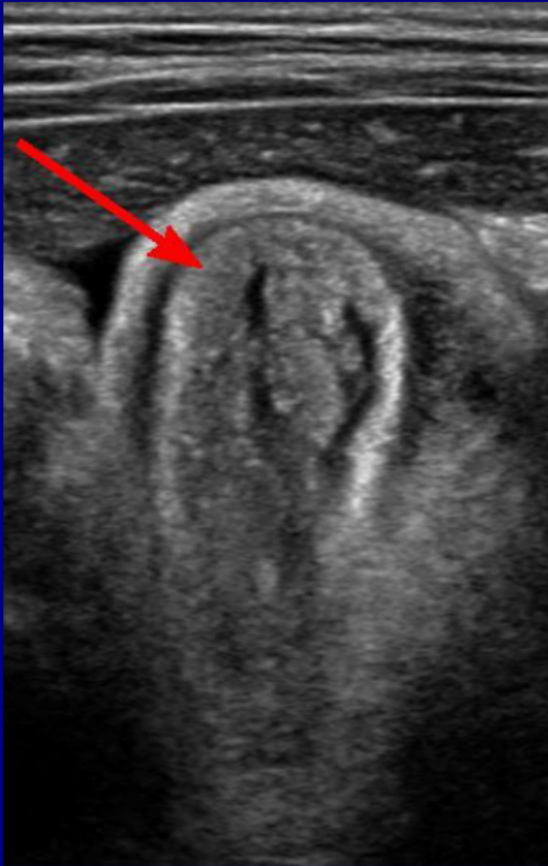


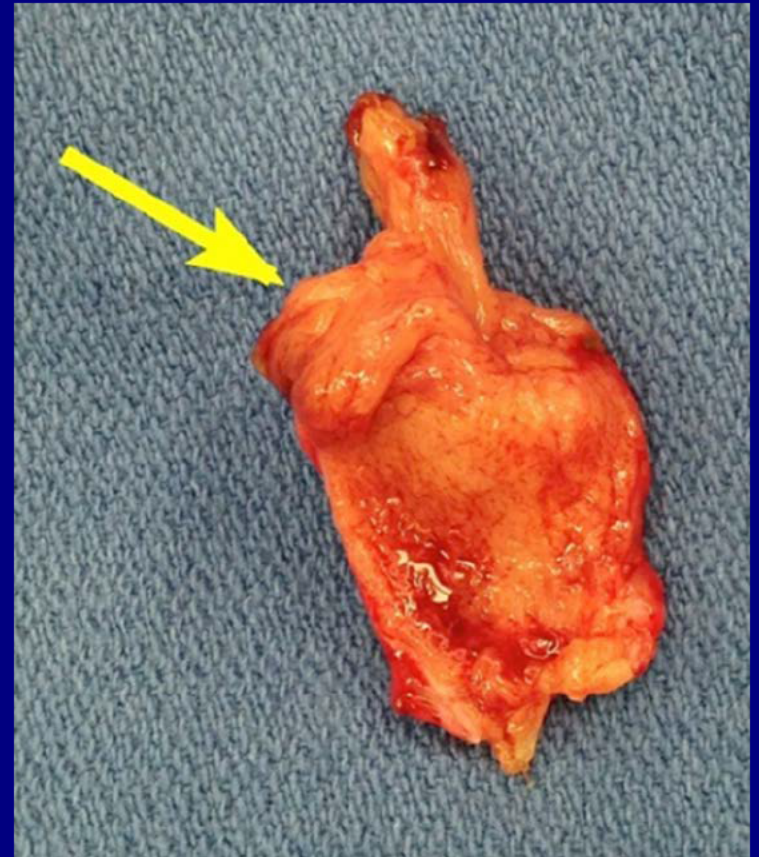
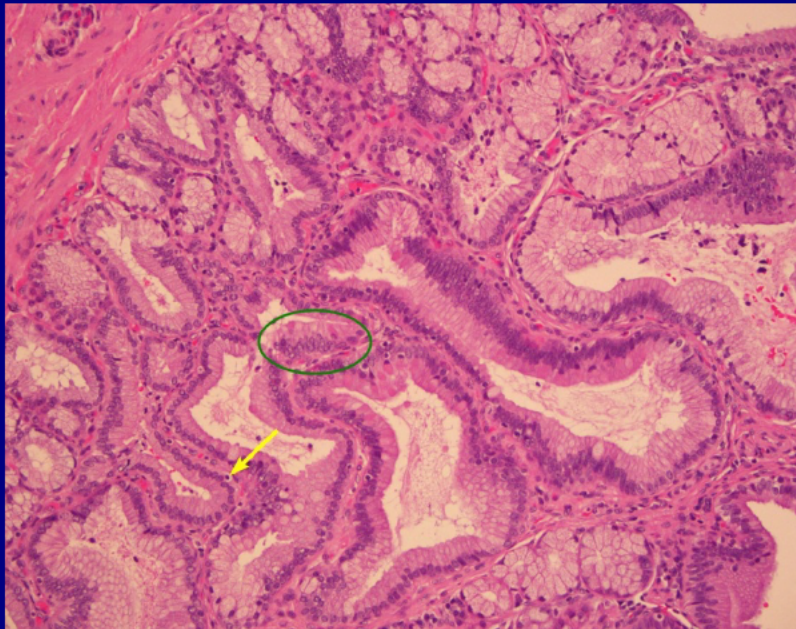
Clinical Information

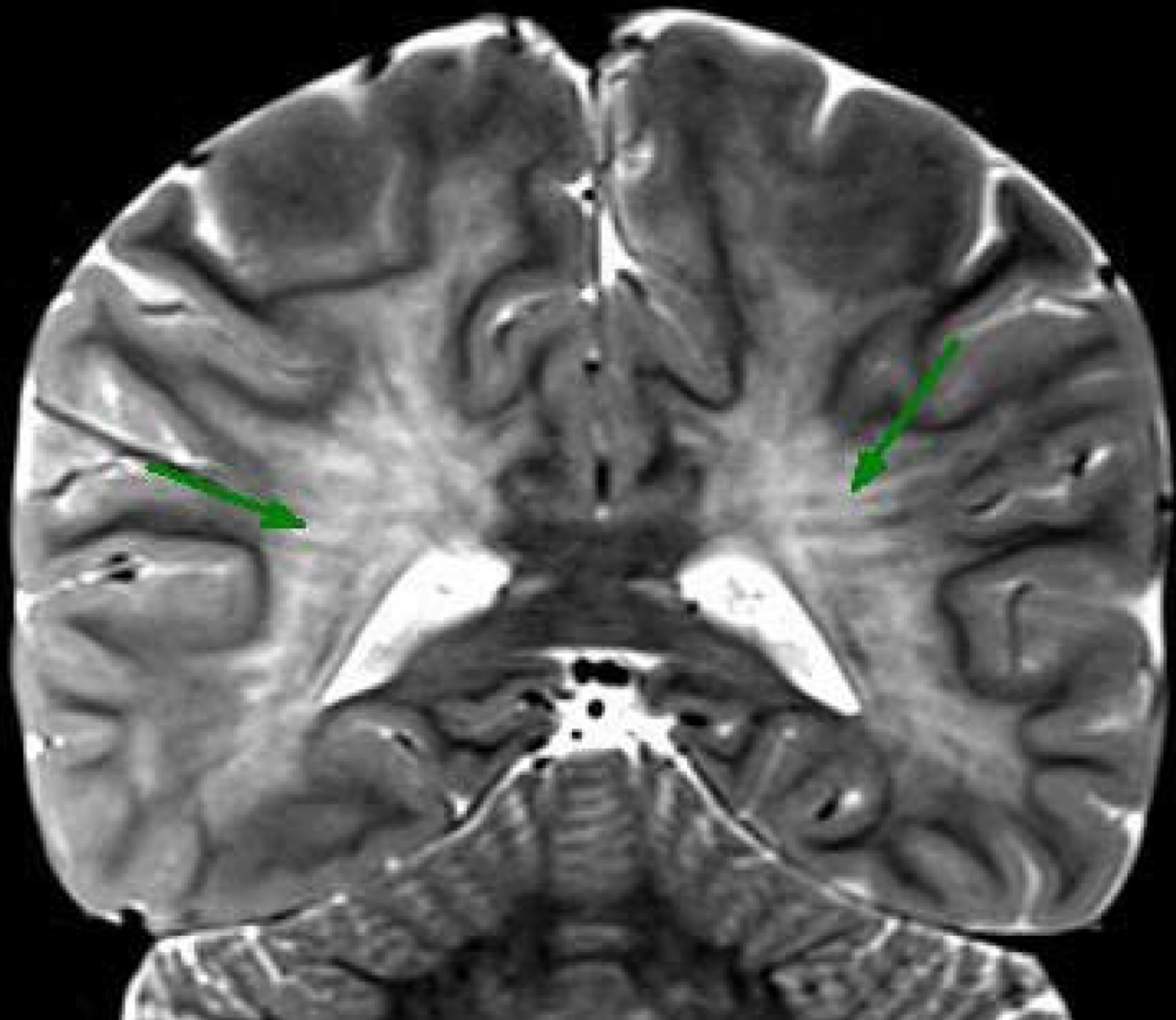
4 year old girl with history of metachromatic leukodystrophy presents from at outside hospital with hematemesis, melena and anemia requiring multiple transfusions.

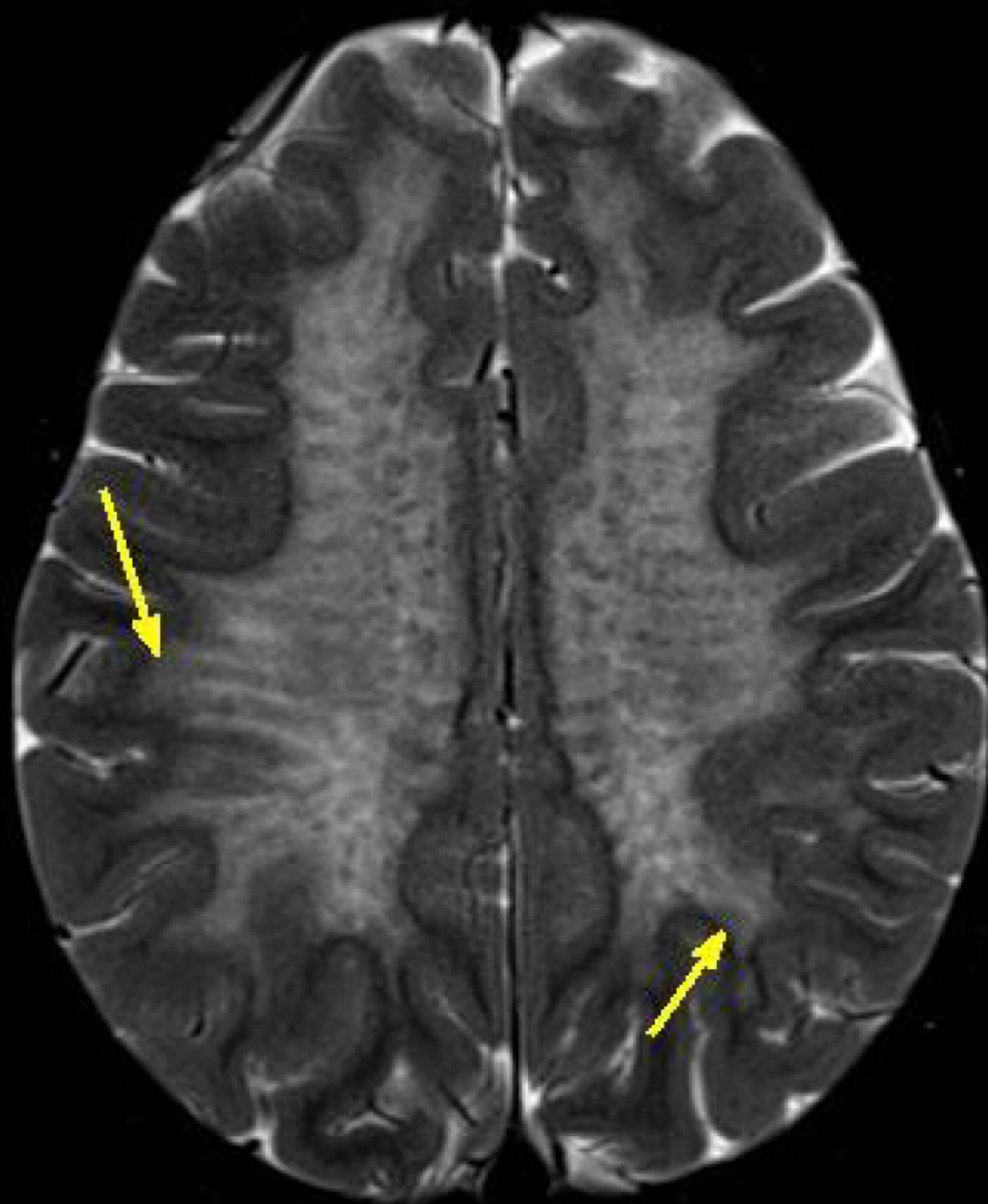








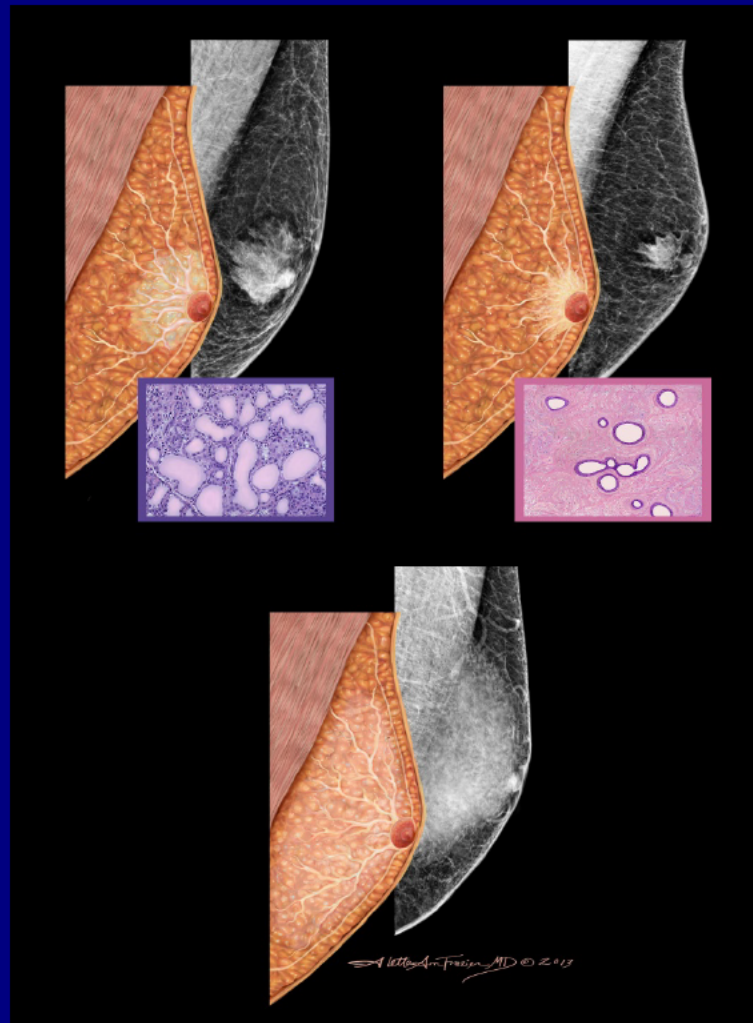




Papilloma of the Gallbladder associated with Metachromatic Leukodystrophy

Carolyn Herman, MD
Indiana University
Indianapolis, Indiana

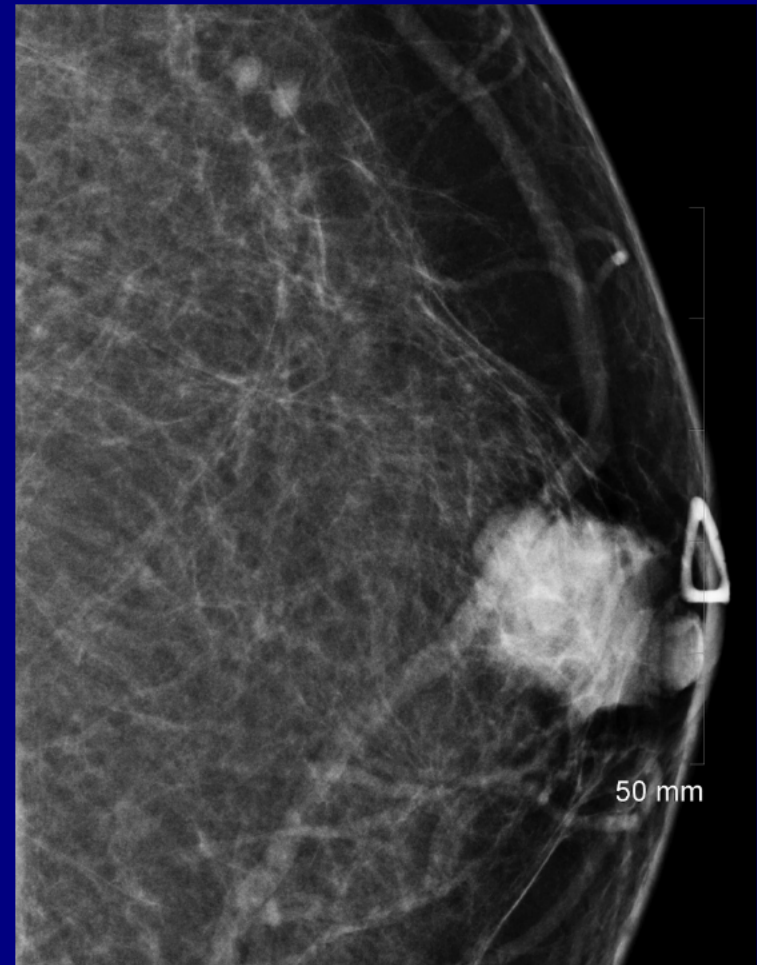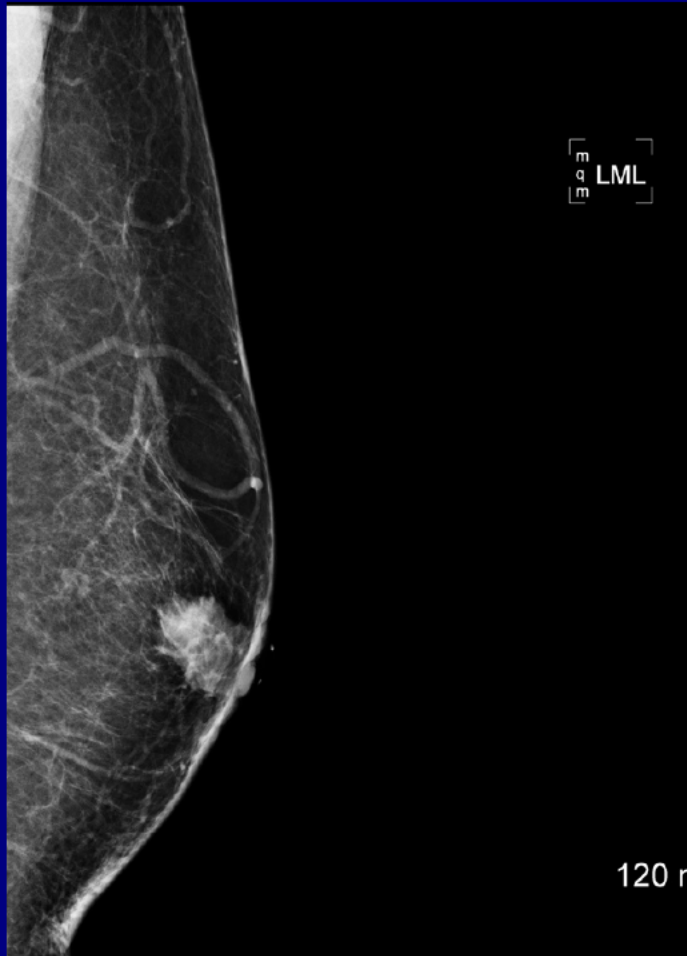Breast Best Case



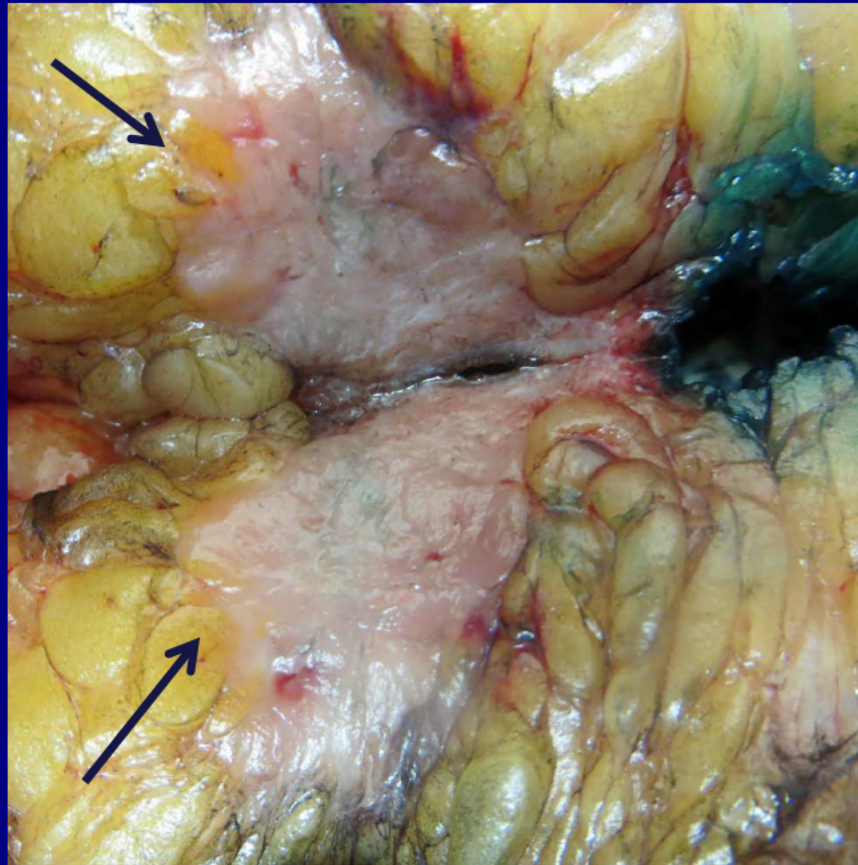
Clinical Information

Hispanic male with left nipple itching
and a palpable lump

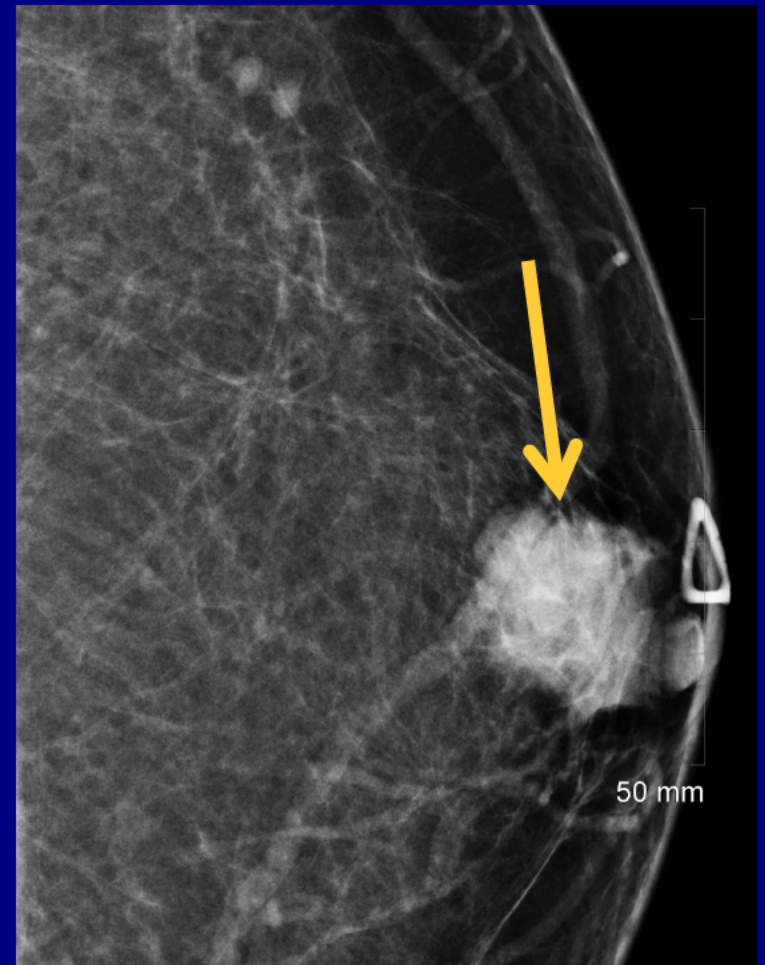
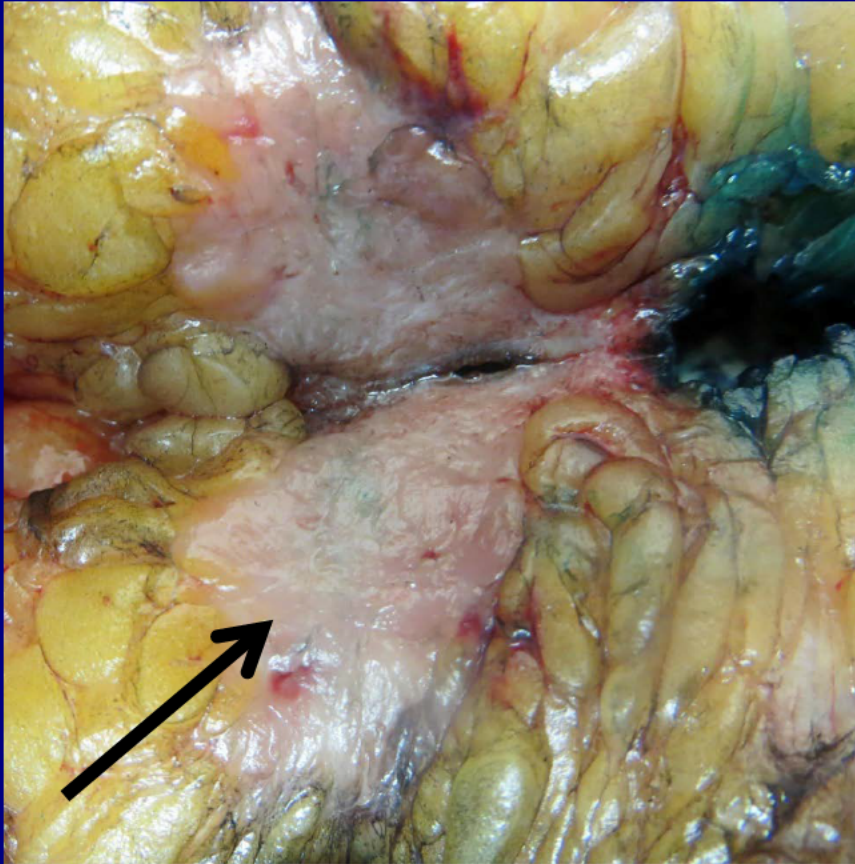
Left Mammogram



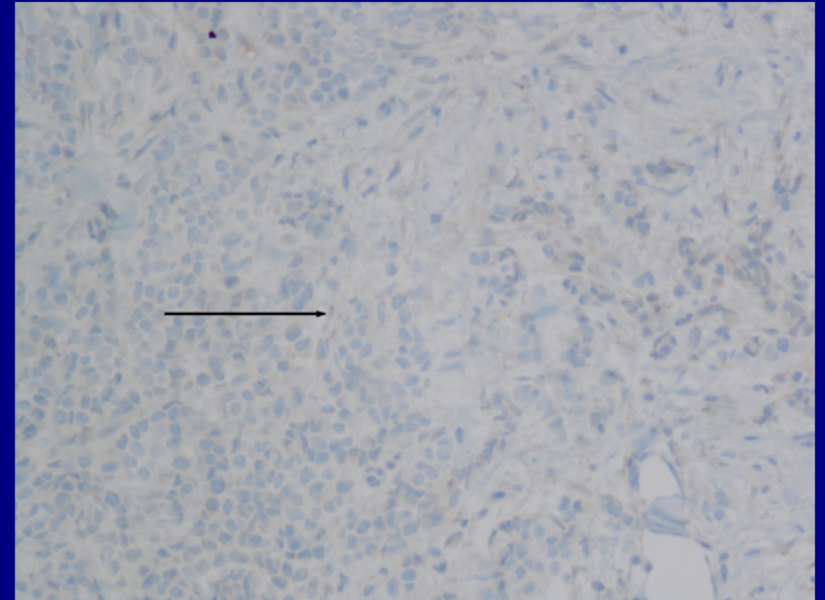
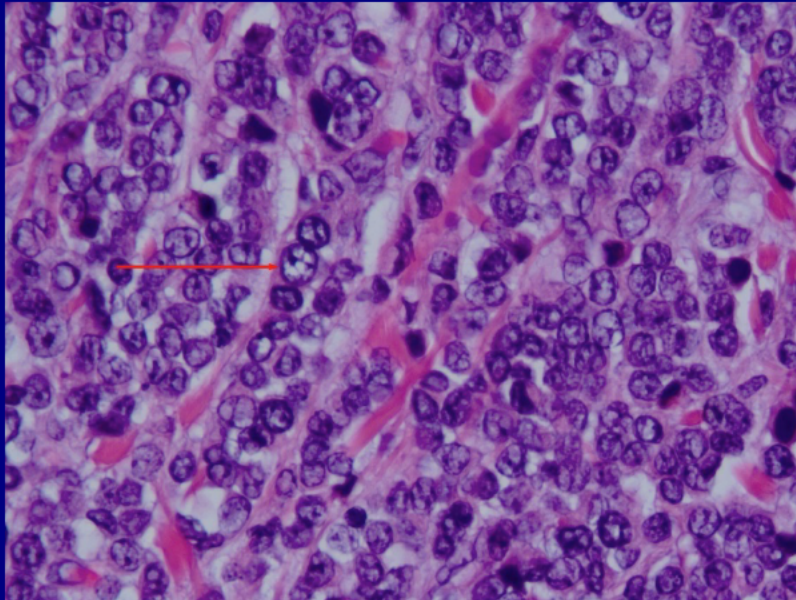
Gross Pathology



Gross Pathology

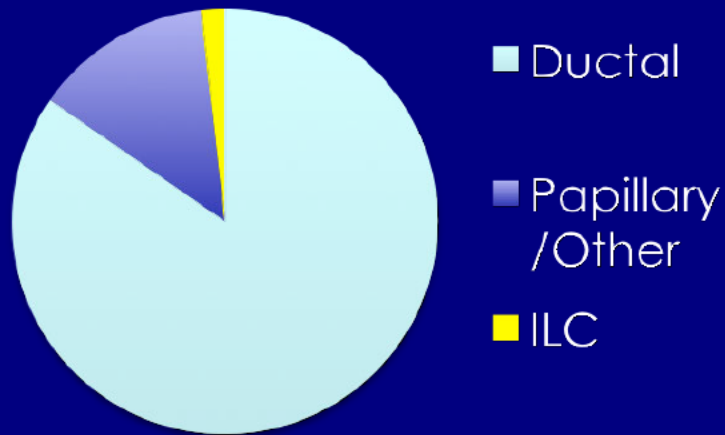


Histology

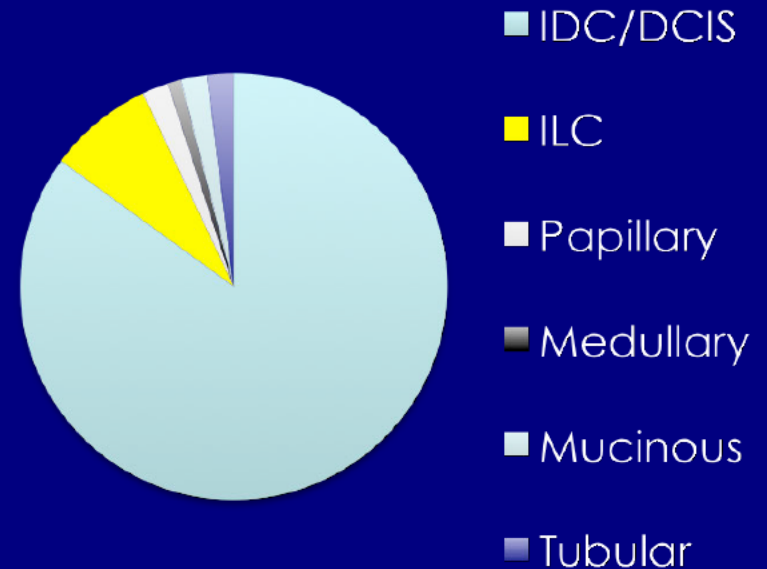


Breast Cancer Types by Gender

Males



Females



Invasive Lobular Carcinoma in a Male

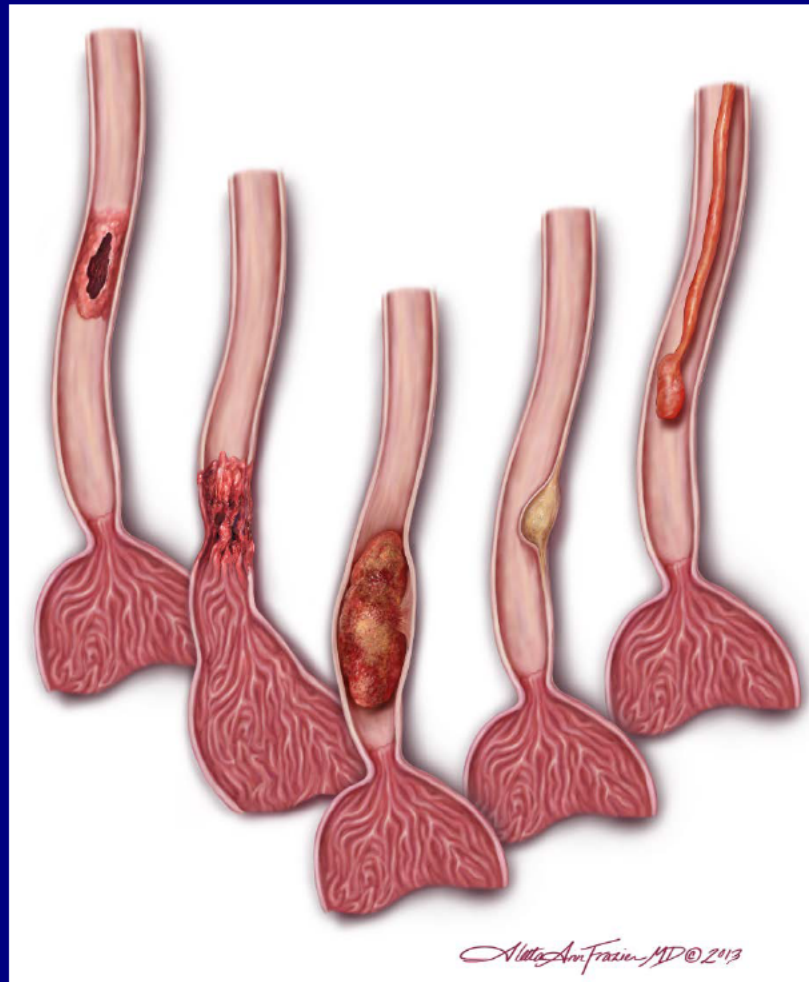Anita Ong

Mercy Hospital and Medical Center

University of Illinois at Chicago

Chicago, Illinois

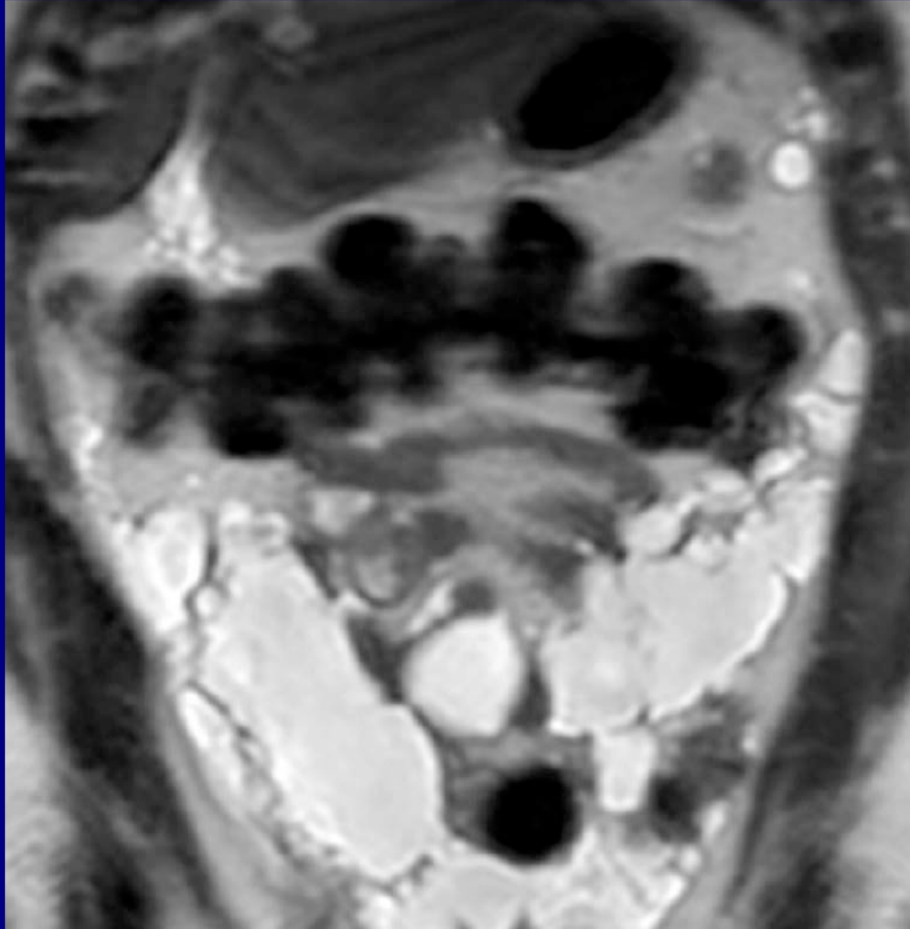
Gastrointestinal Best Case



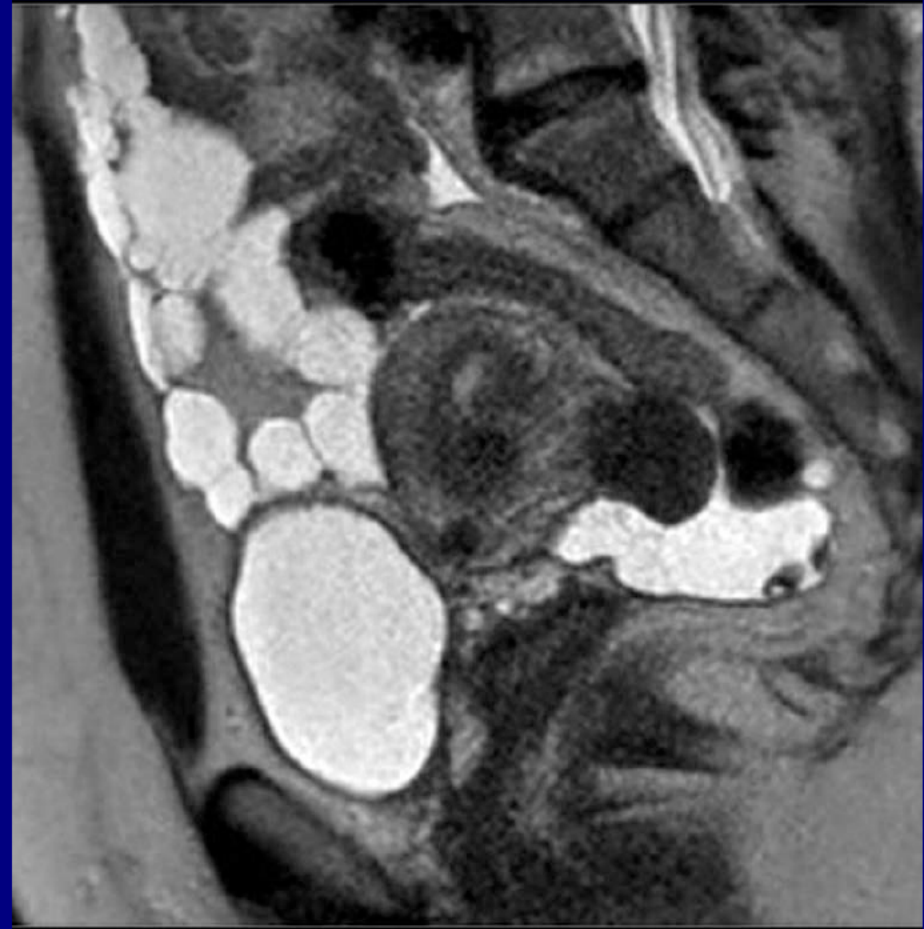
Clinical Information

47 year old female presents for work-up of abdominal masses found at an outside hospital.

MRI

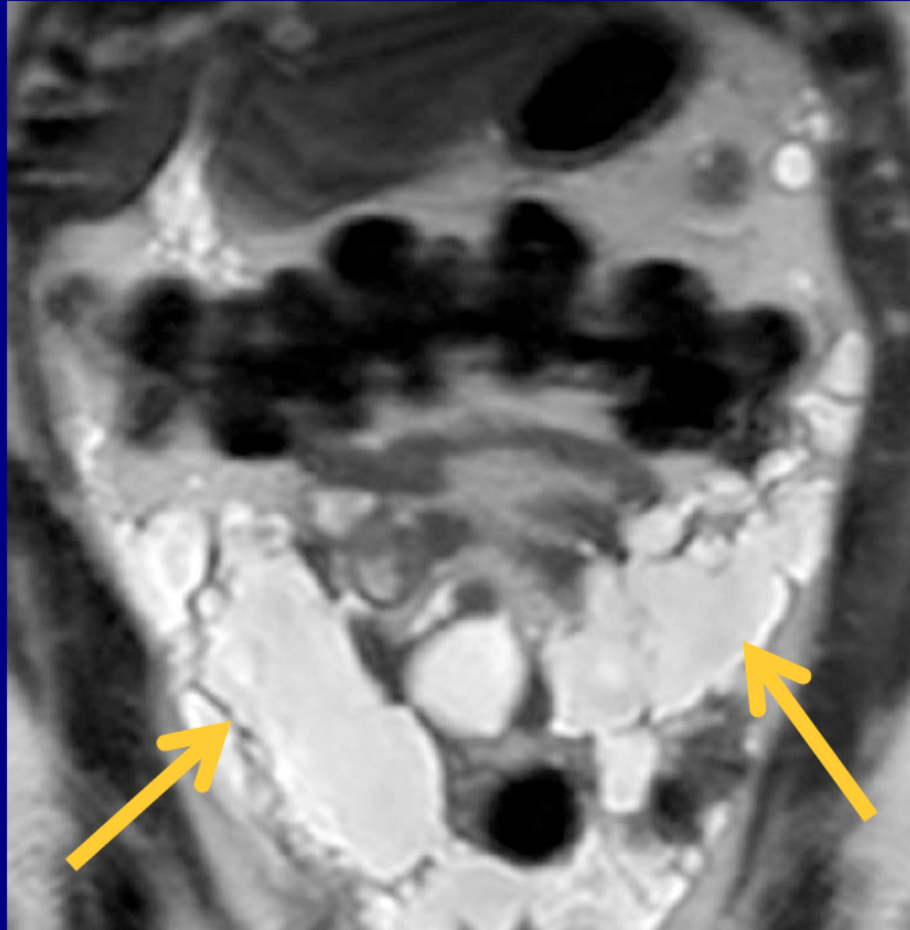


Coronal T2

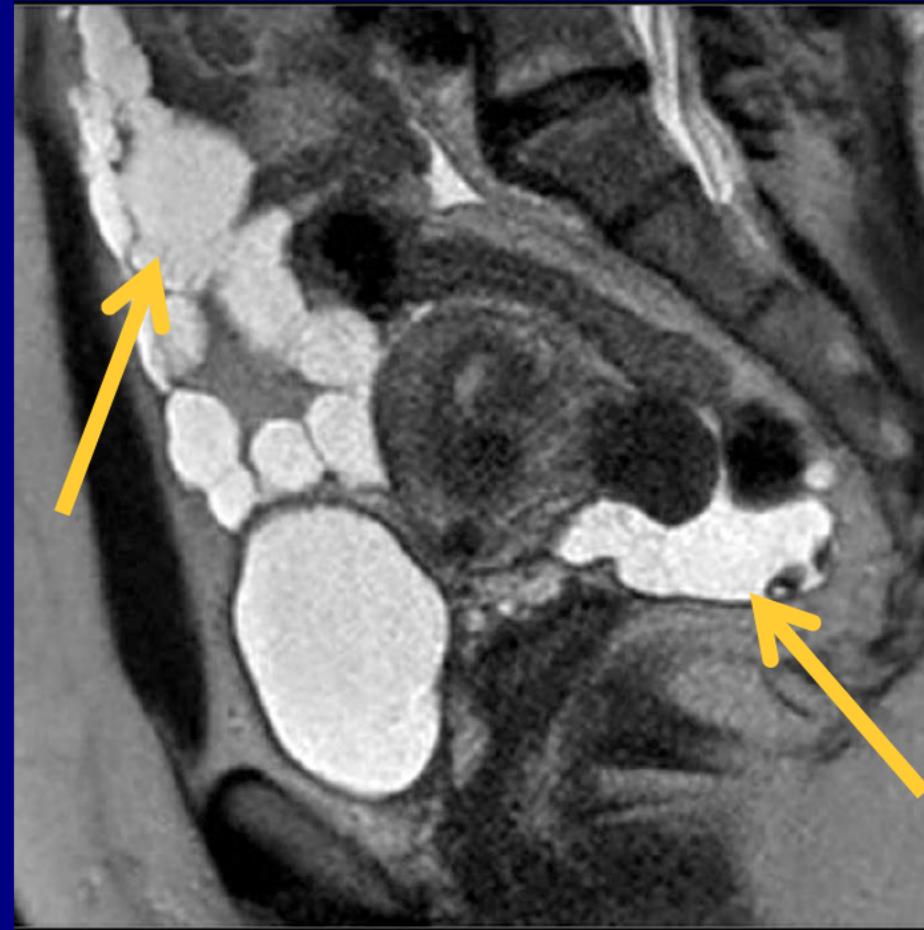


Sagittal T2

MRI

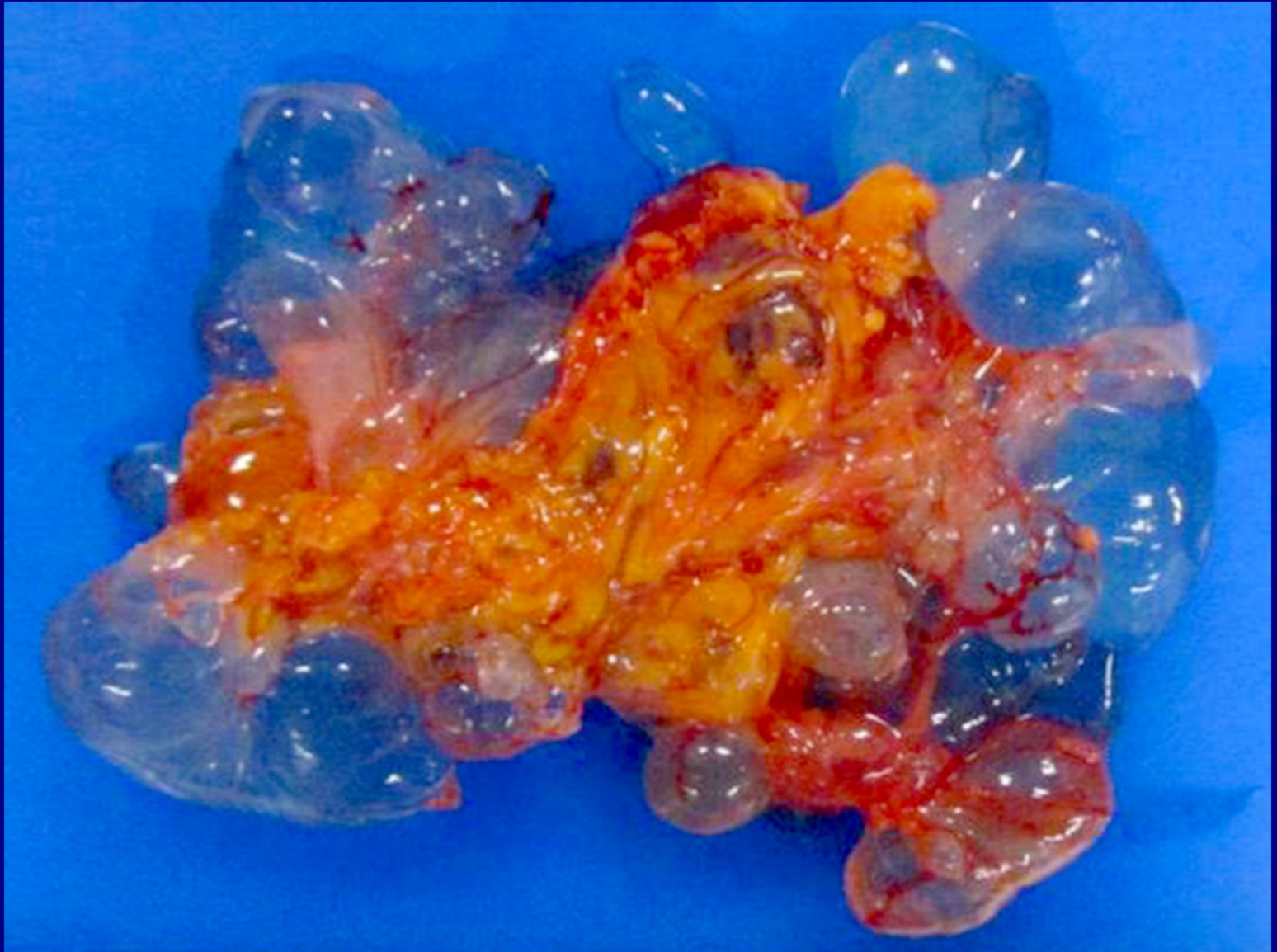


Coronal T2

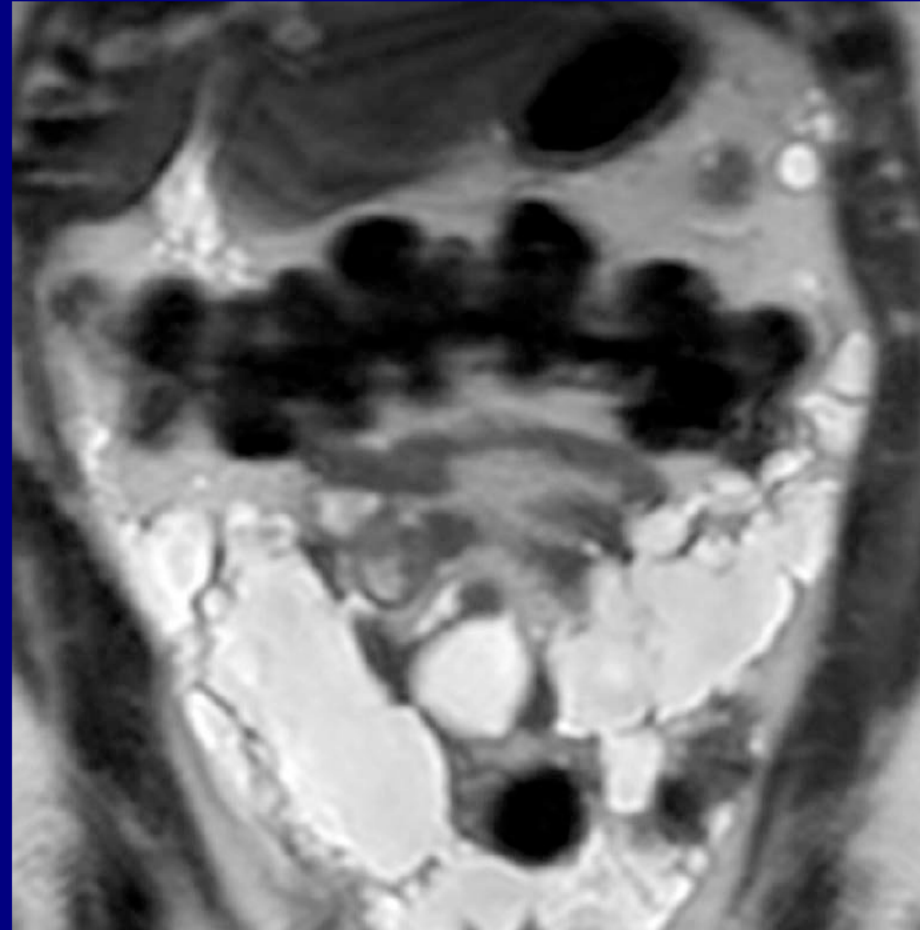
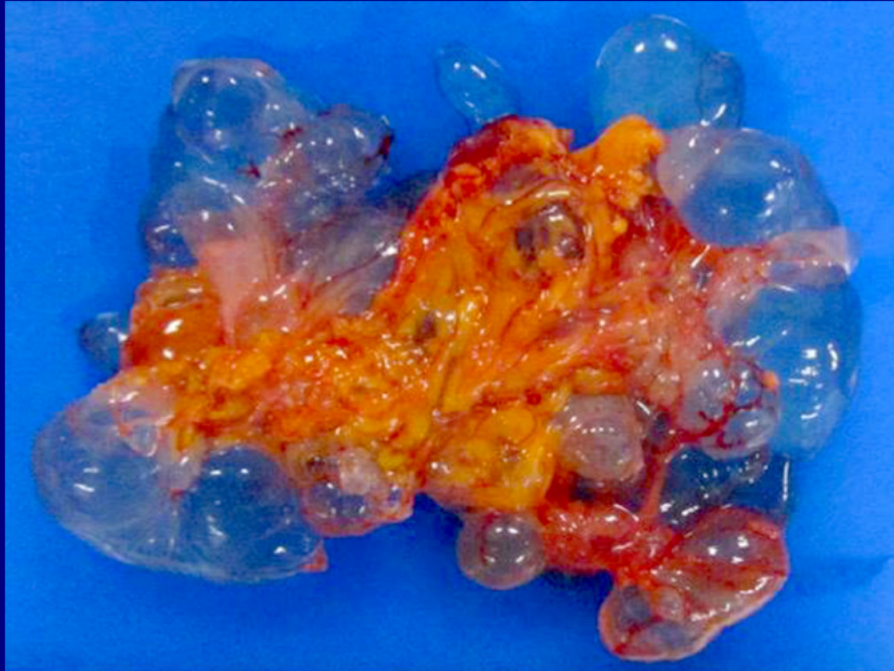


Sagittal T2

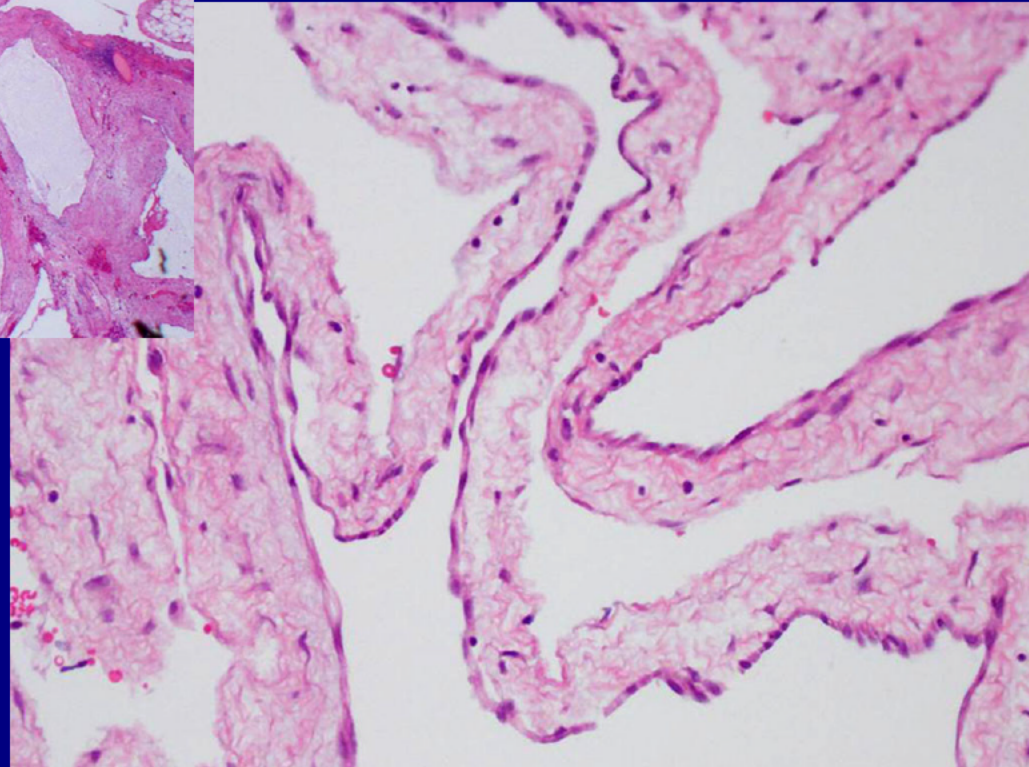
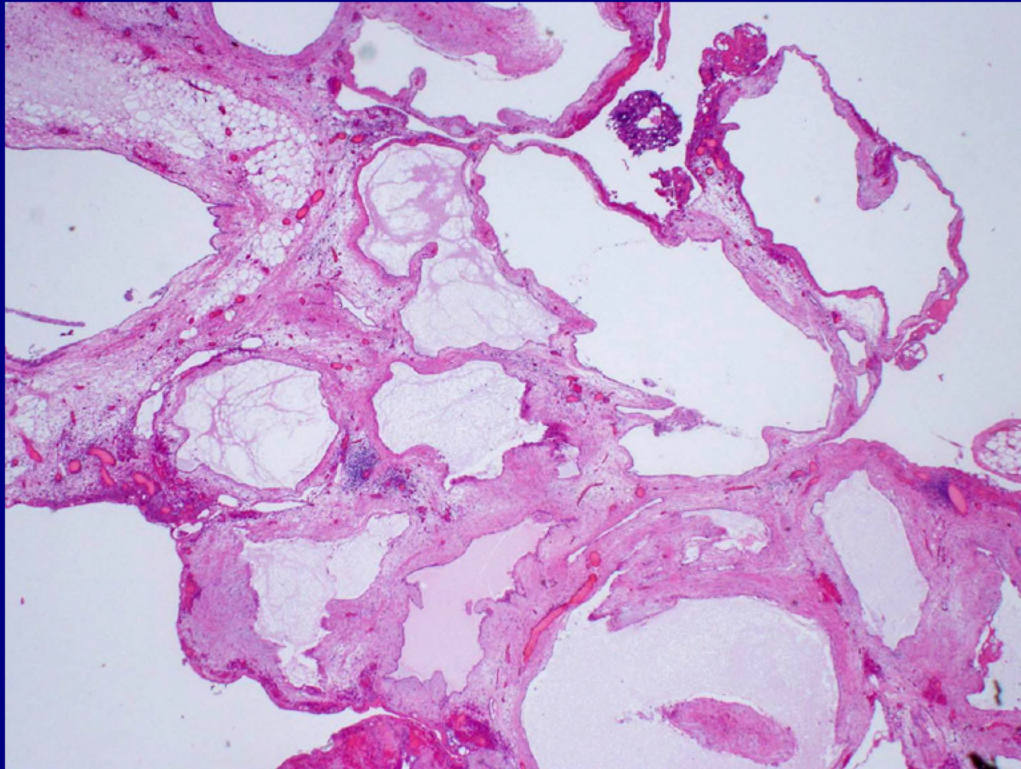
Gross

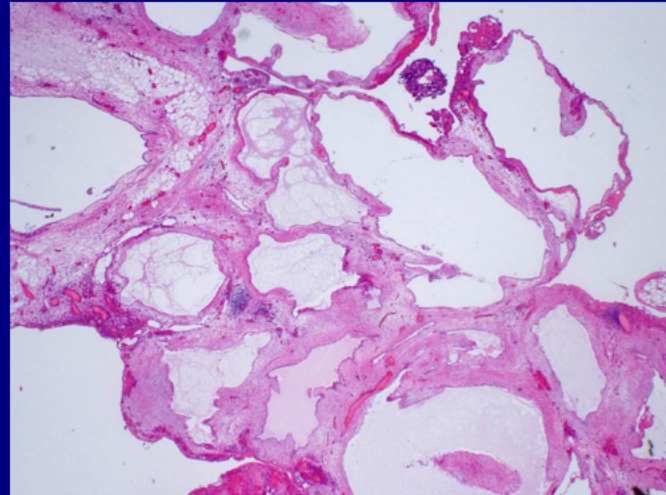
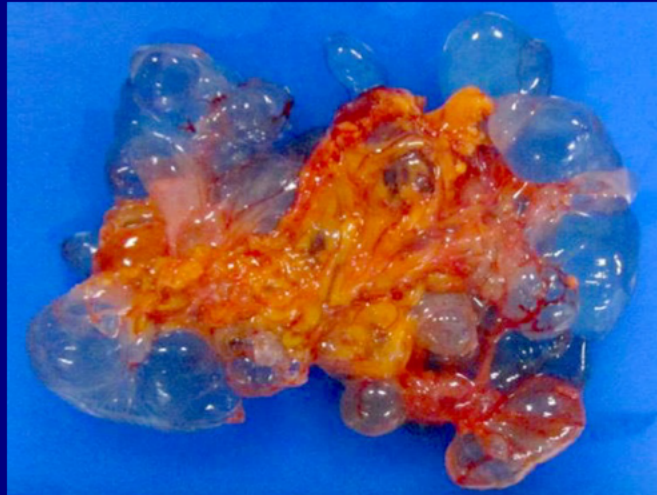
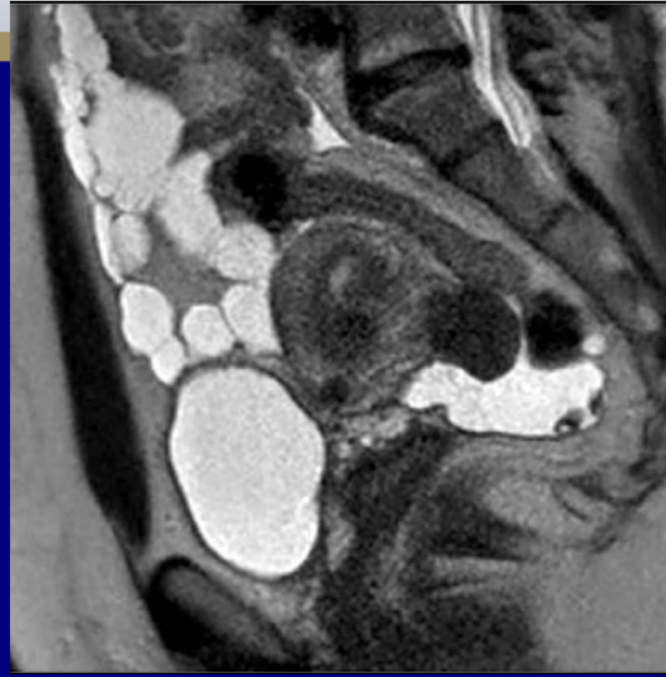
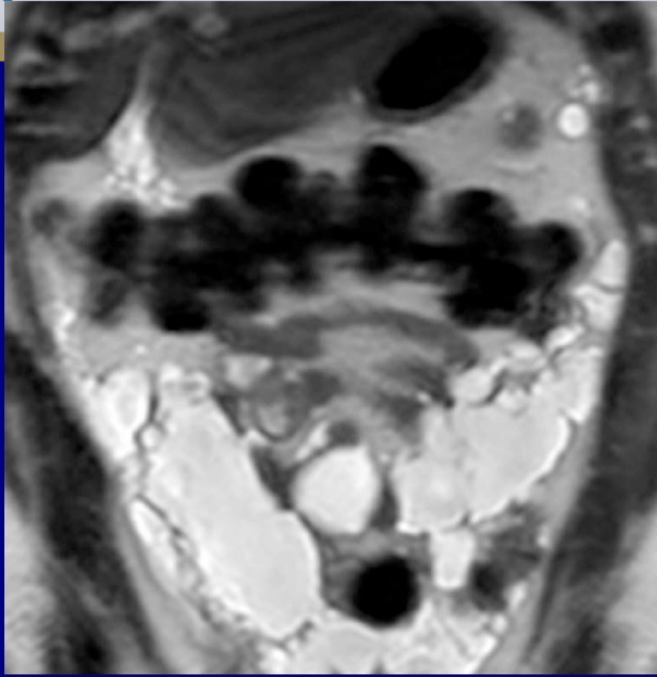


Gross



Histology





Benign Multicystic Peritoneal Mesothelioma

Ruri Lee, M.D.

**New York Medical College
Westchester Medical Center
Valhalla, NY**

**Many thanks to all of you for
submitting such great cases!
Have a safe trip home**

**From the staff of the
American Institute for Radiologic Pathology**