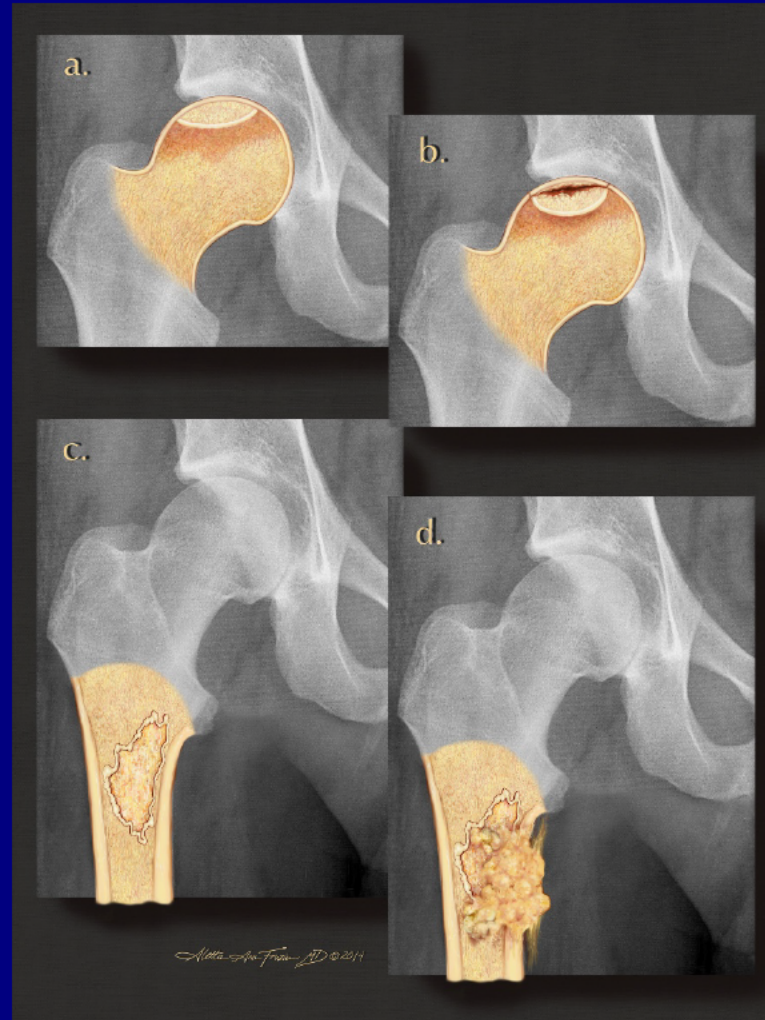


# Best Cases of the AIRP

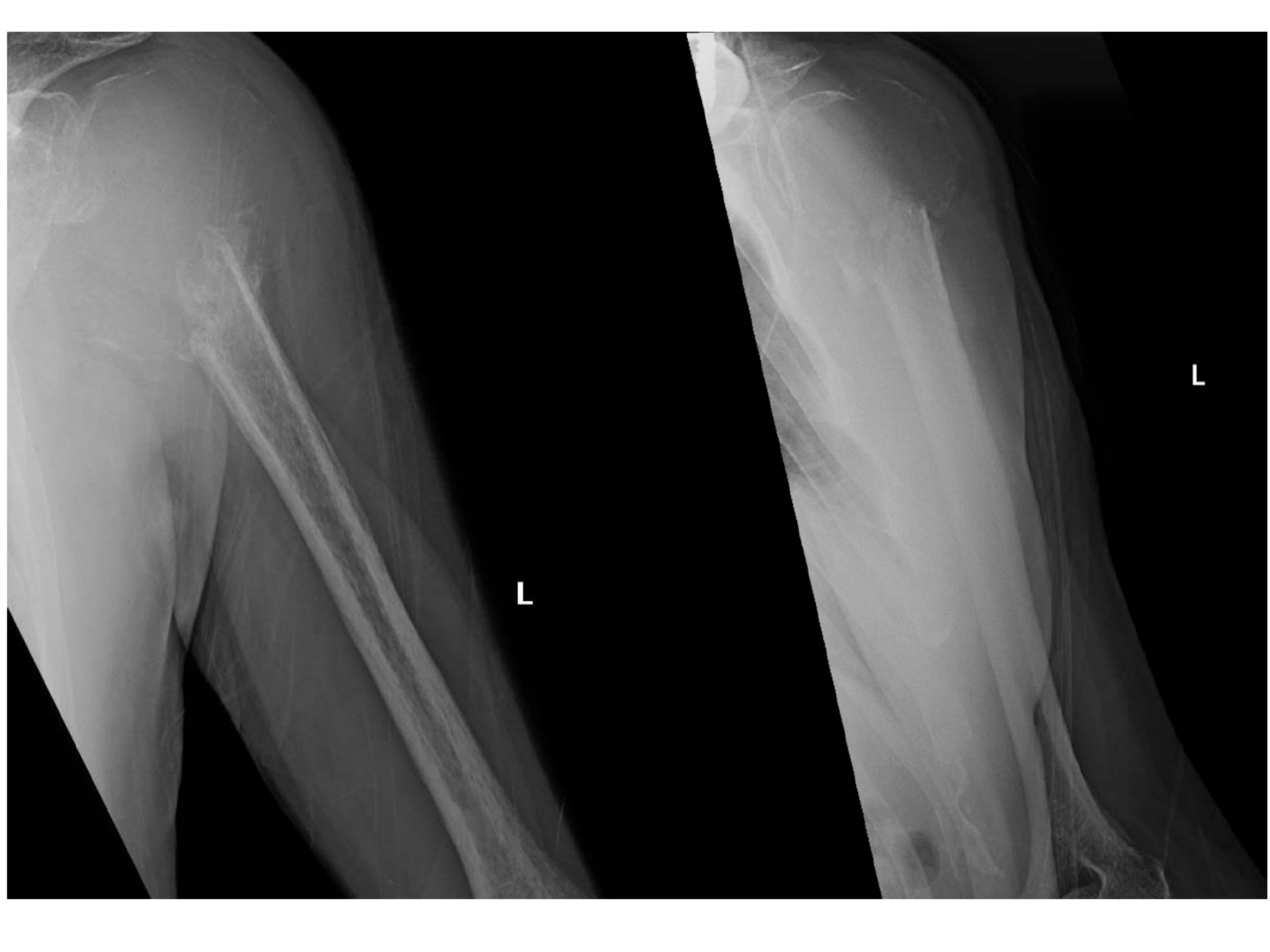**April-May, 2015**

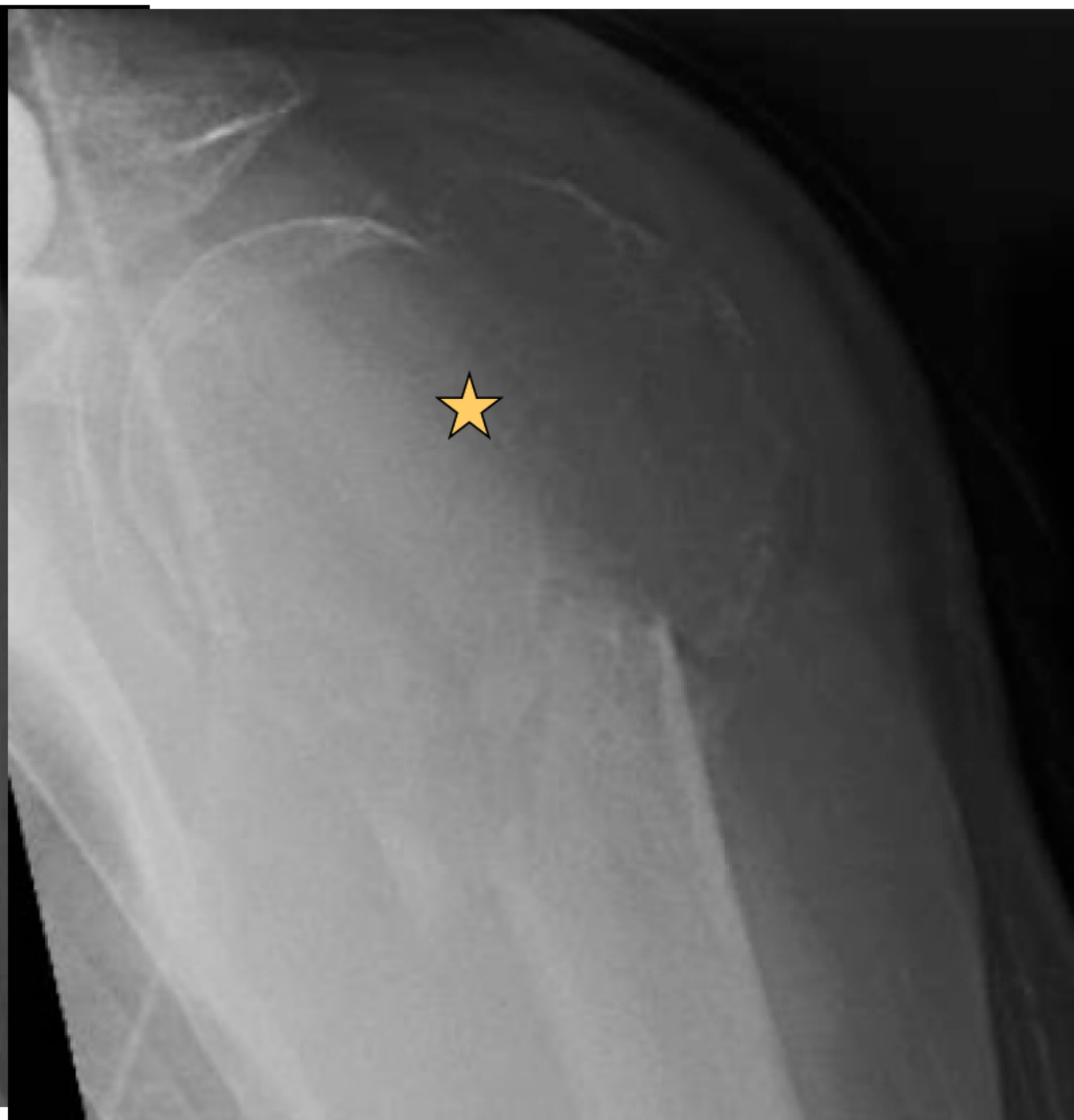
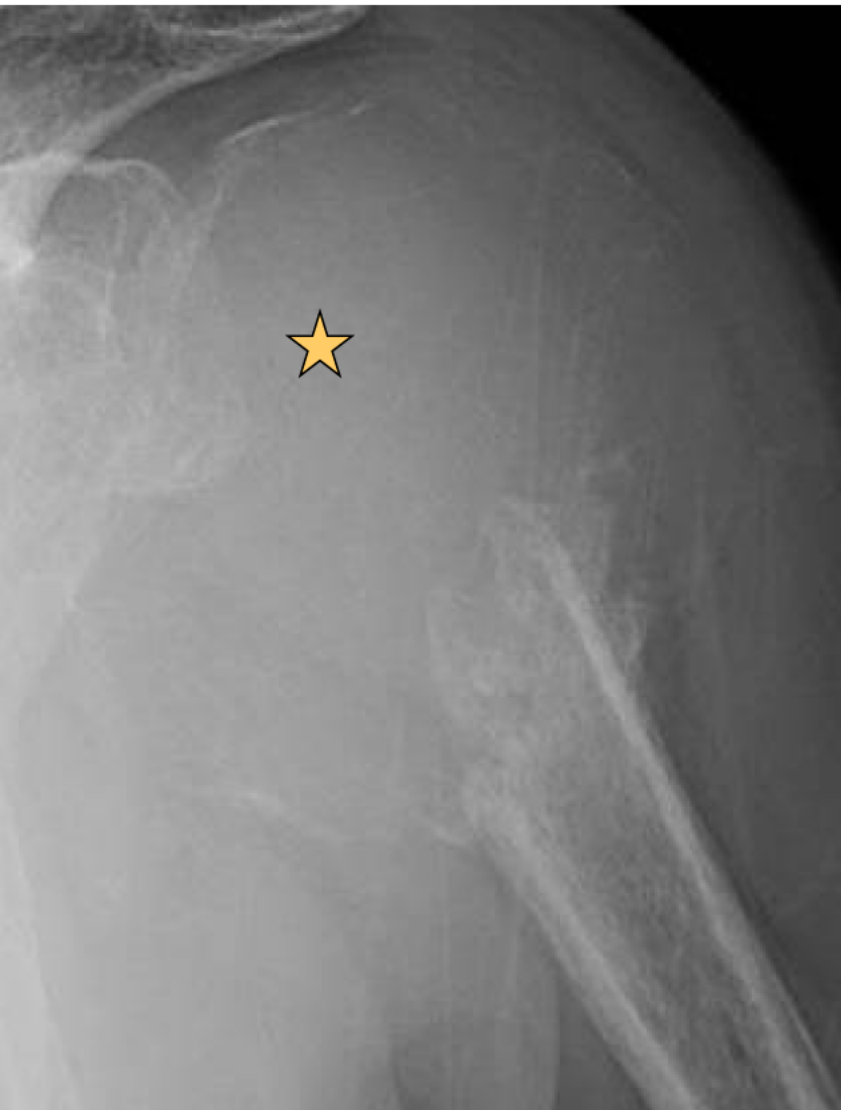
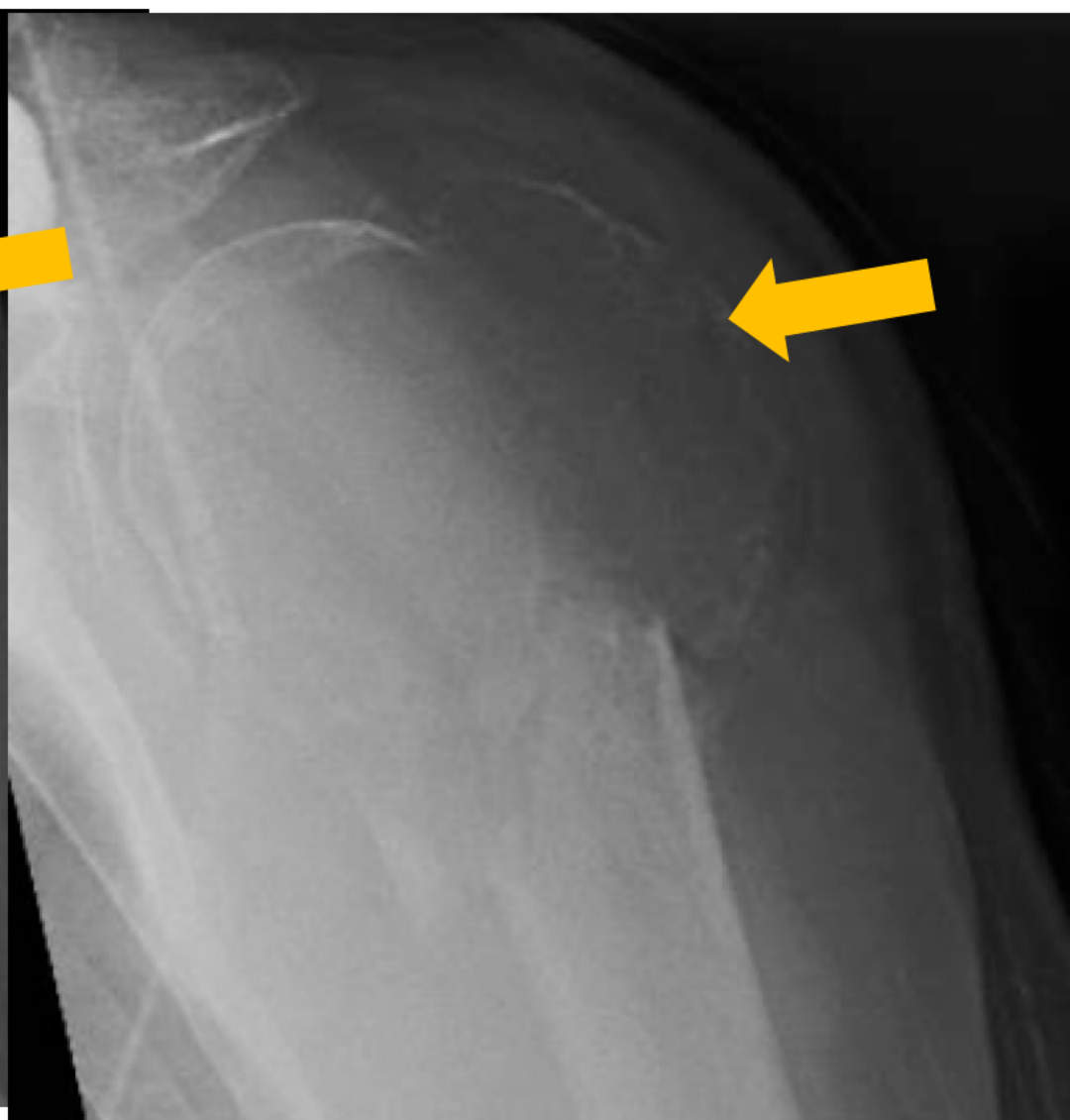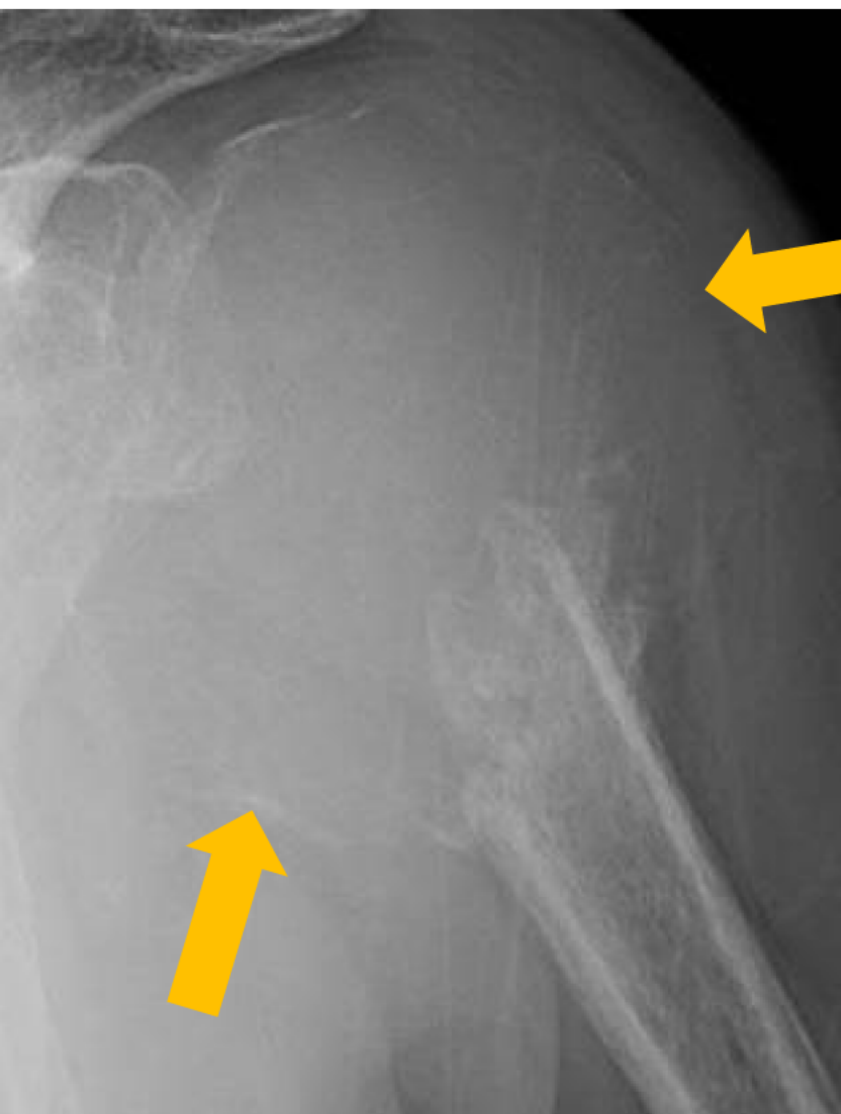
# Musculoskeletal Best Case

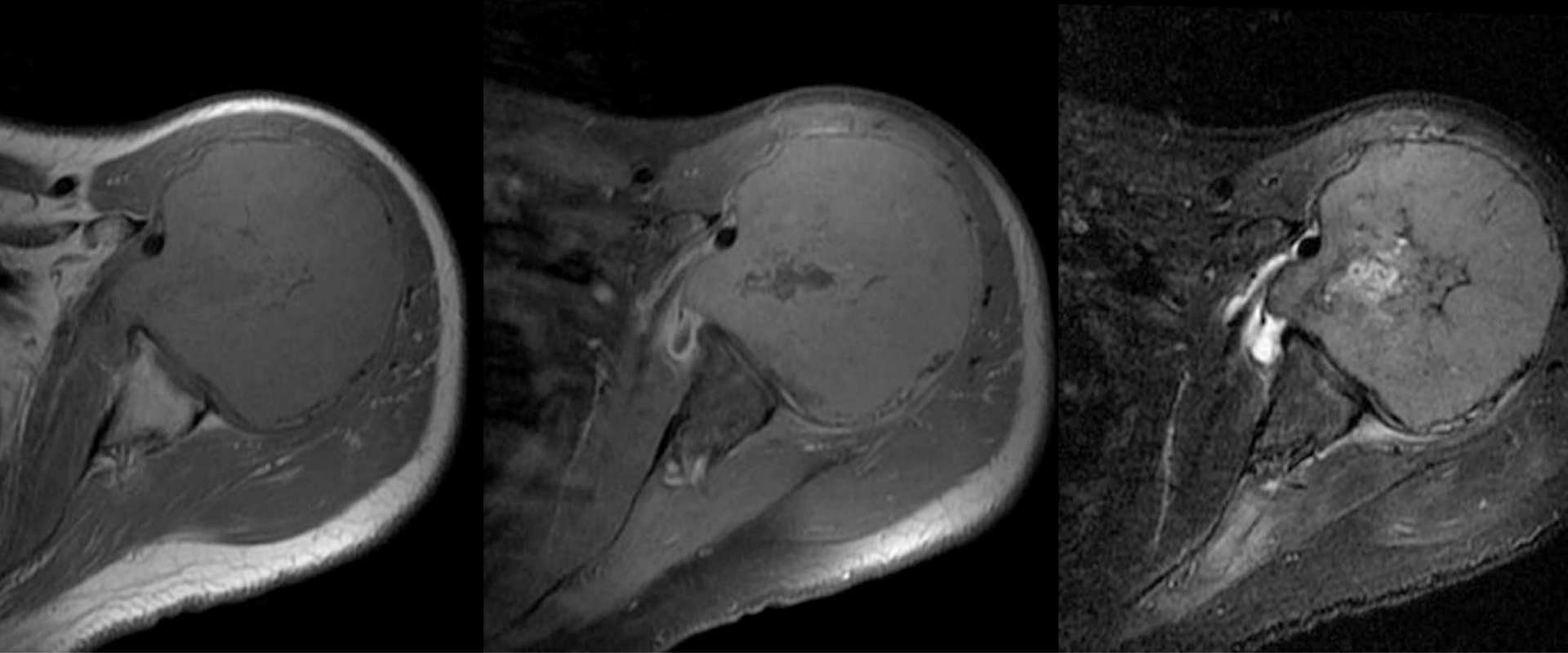


55 year old male with fall on left  
shoulder.





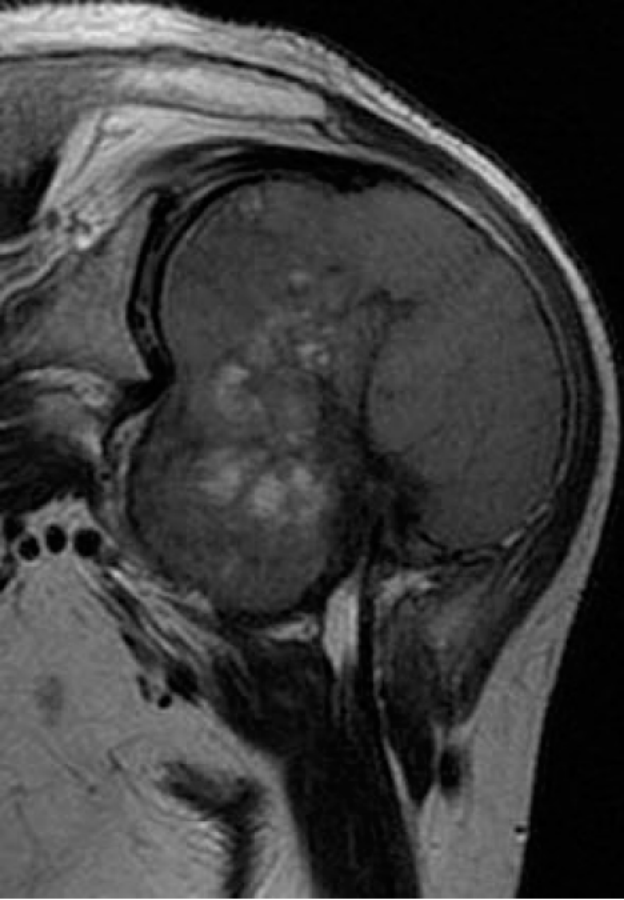




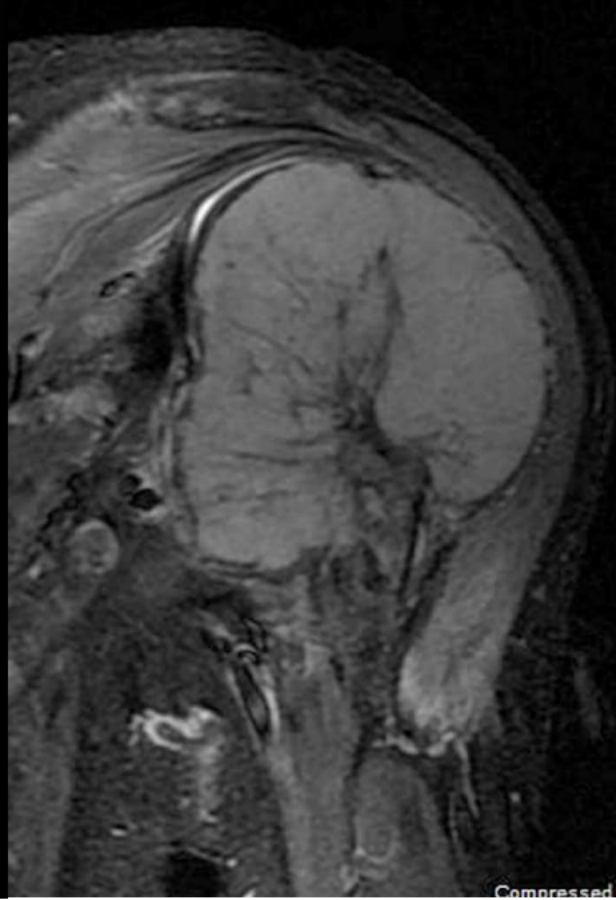
T1

T1+C

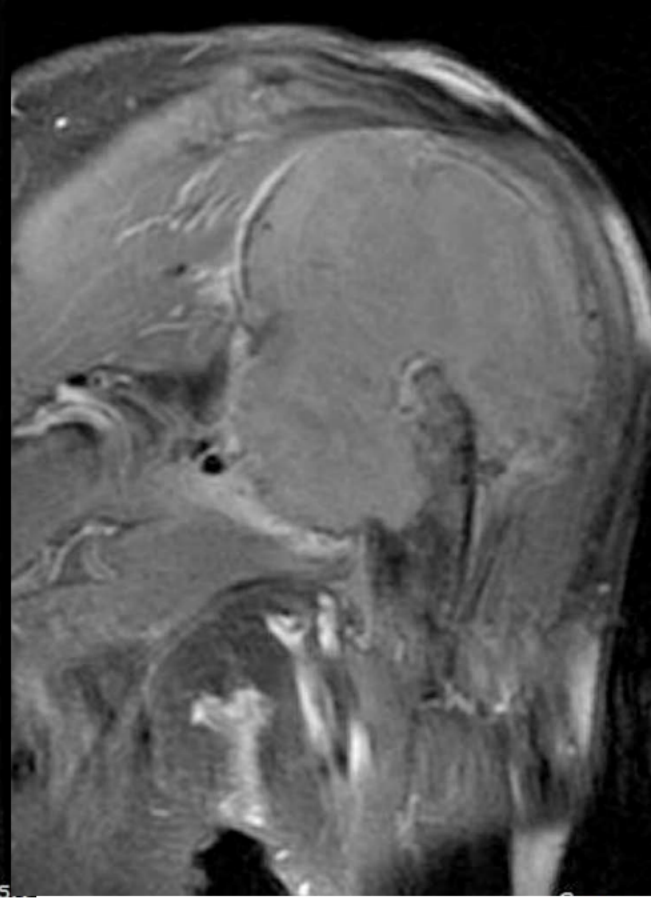
STIR



T2

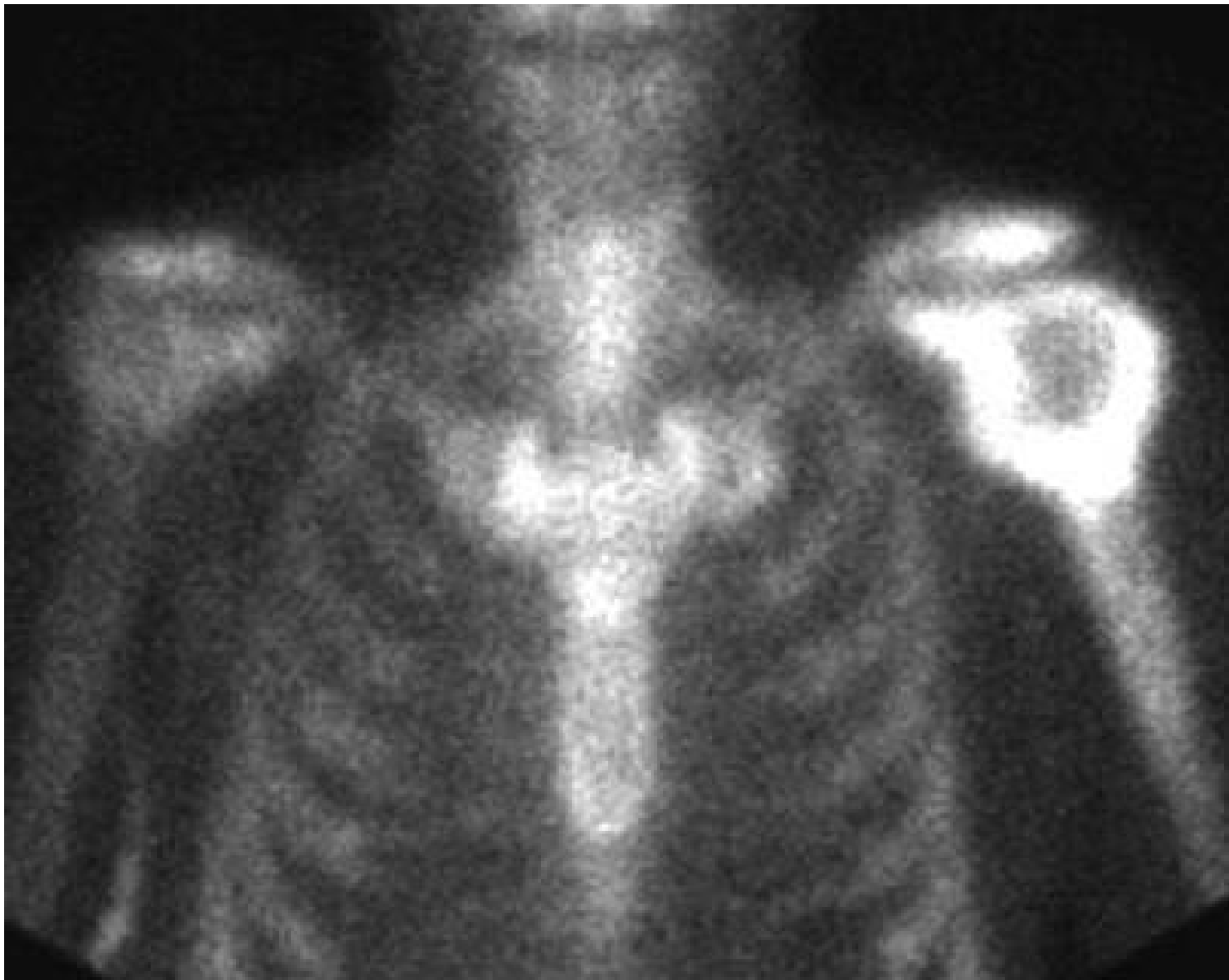


STIR

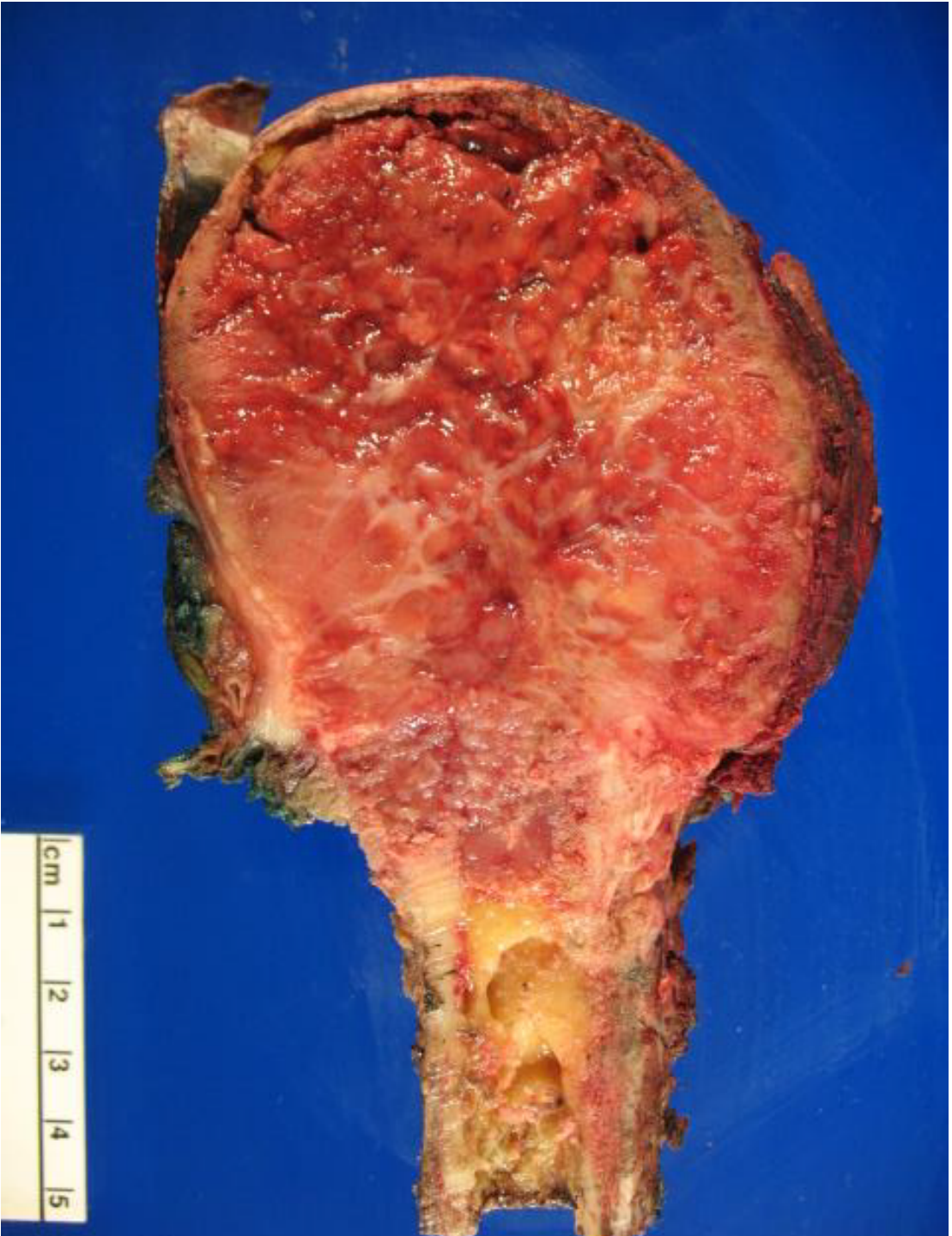


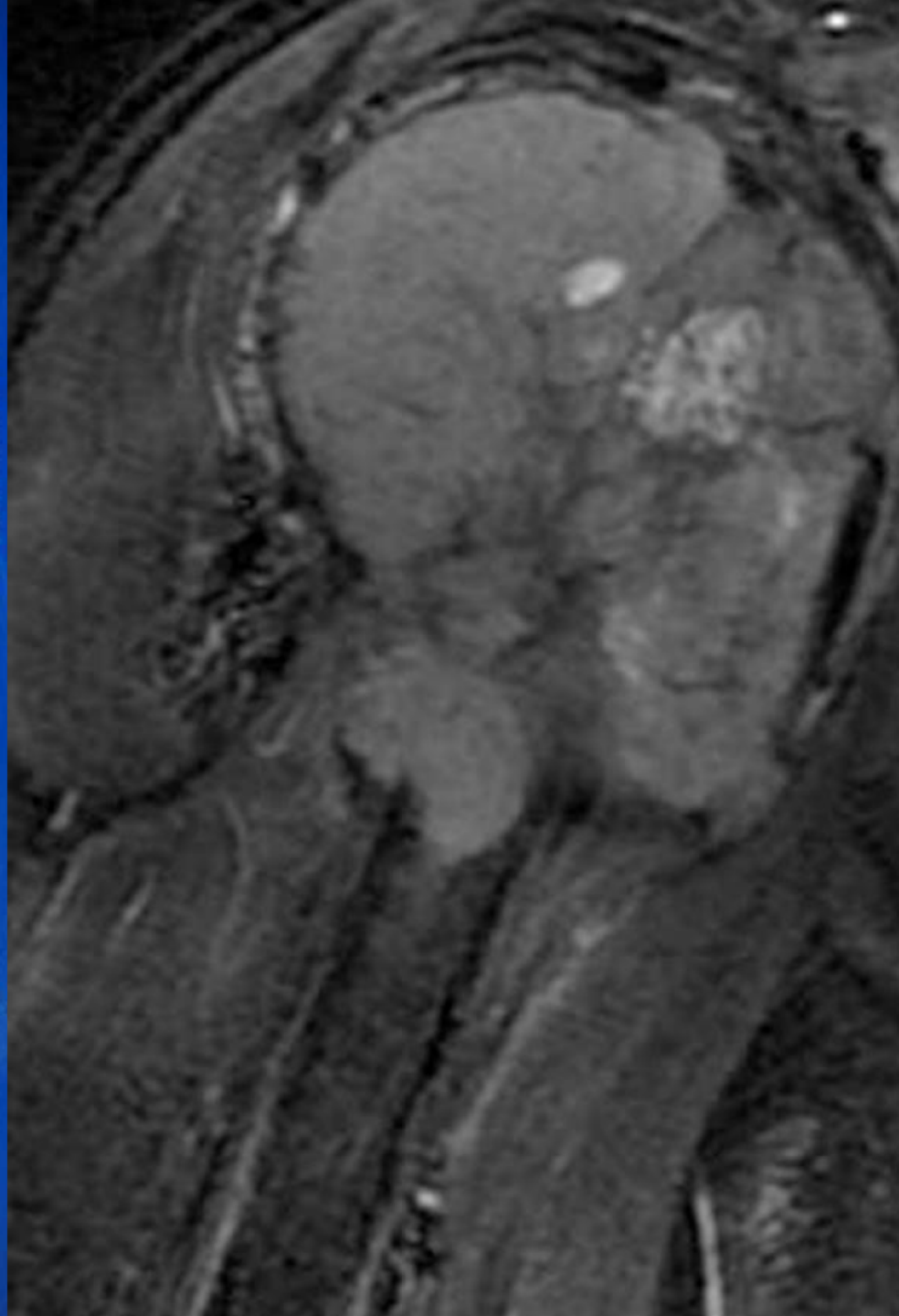
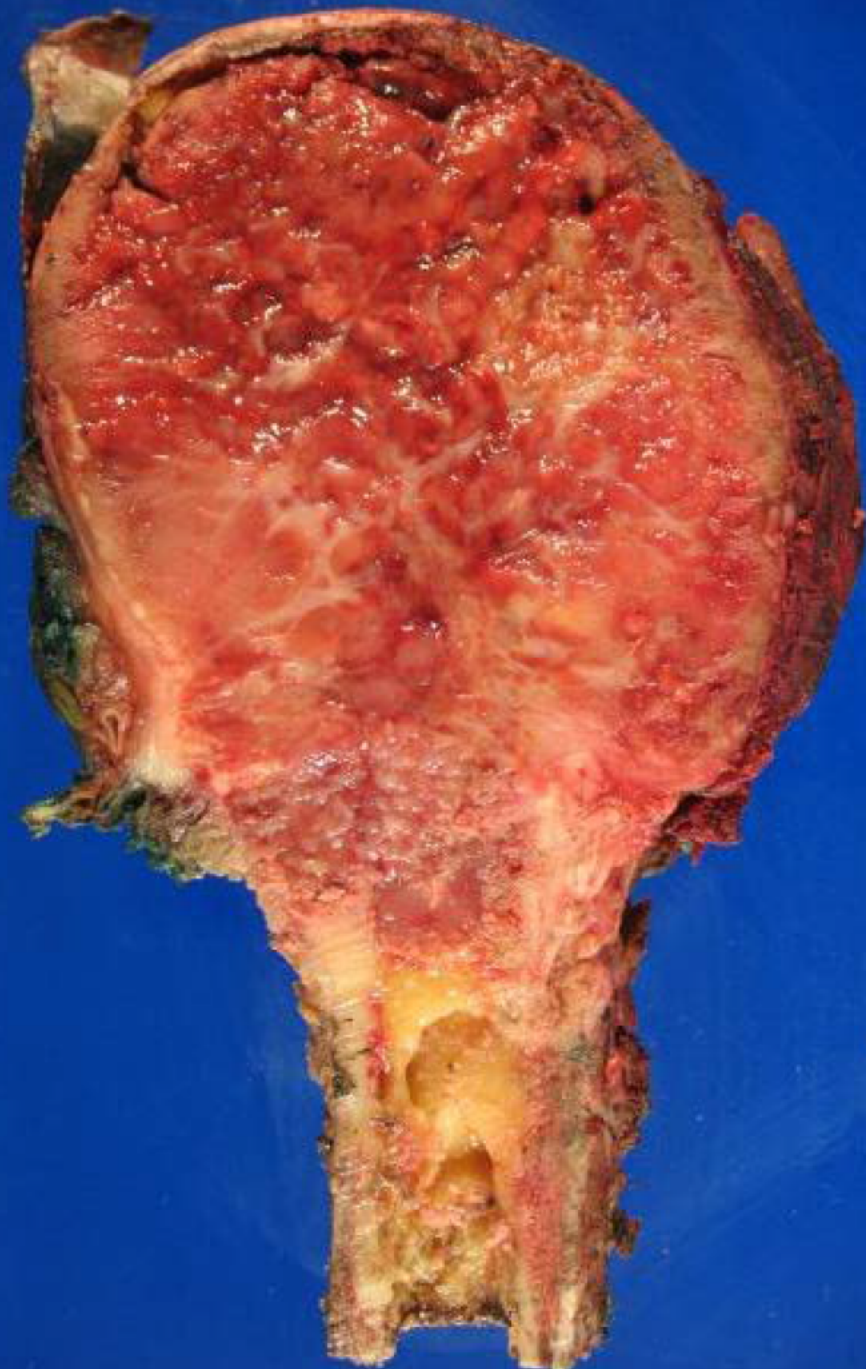T1+C



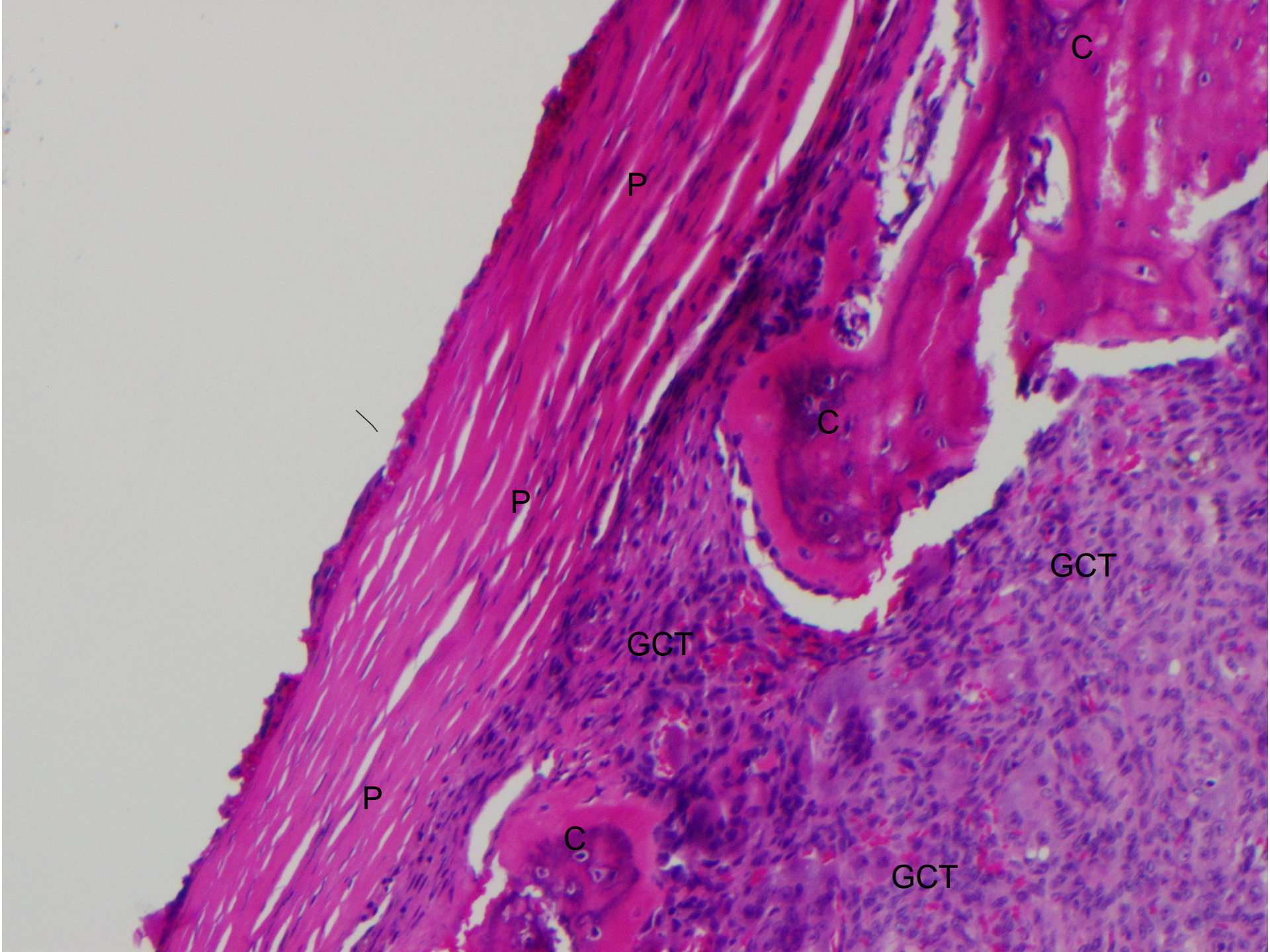




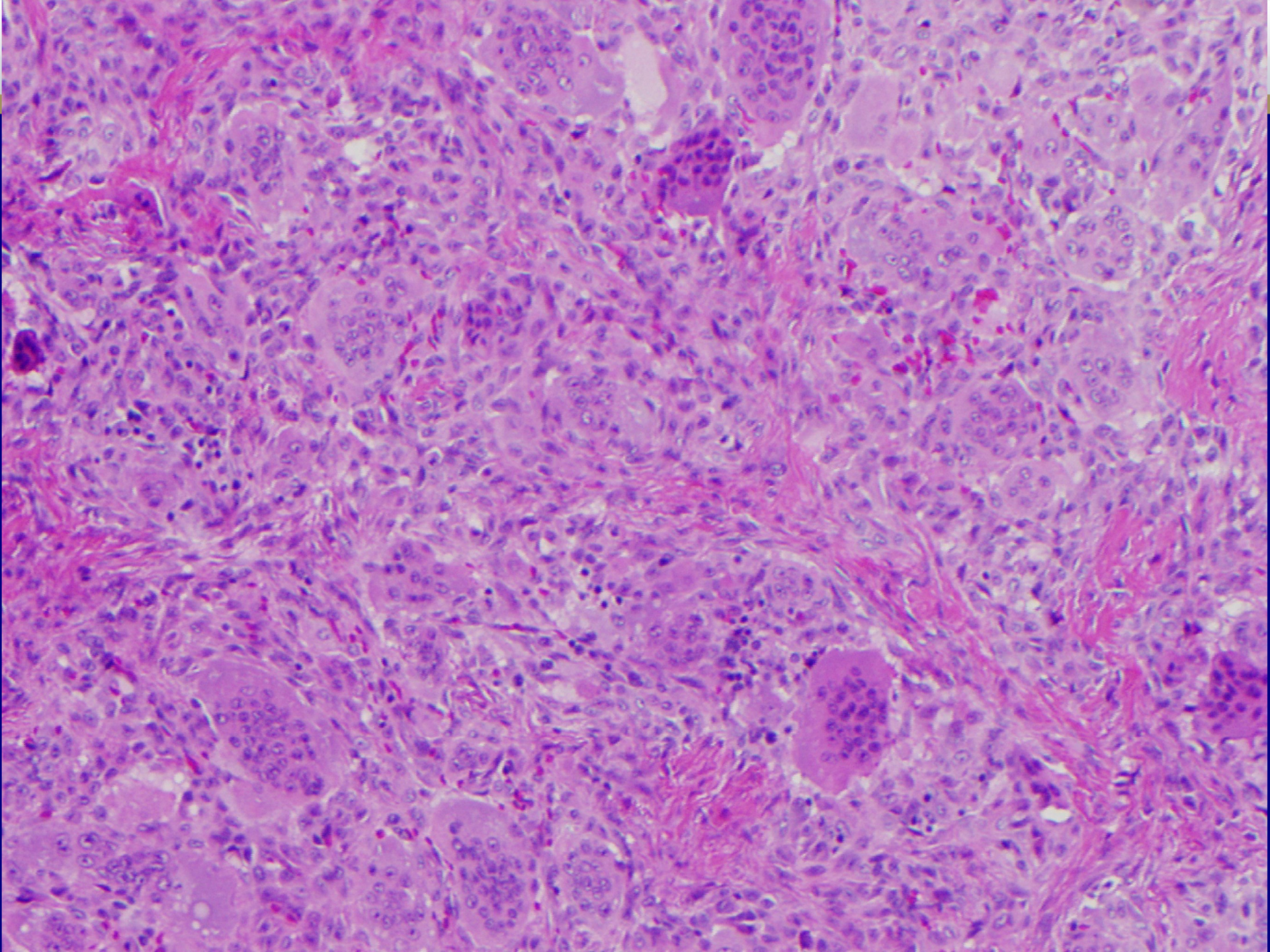




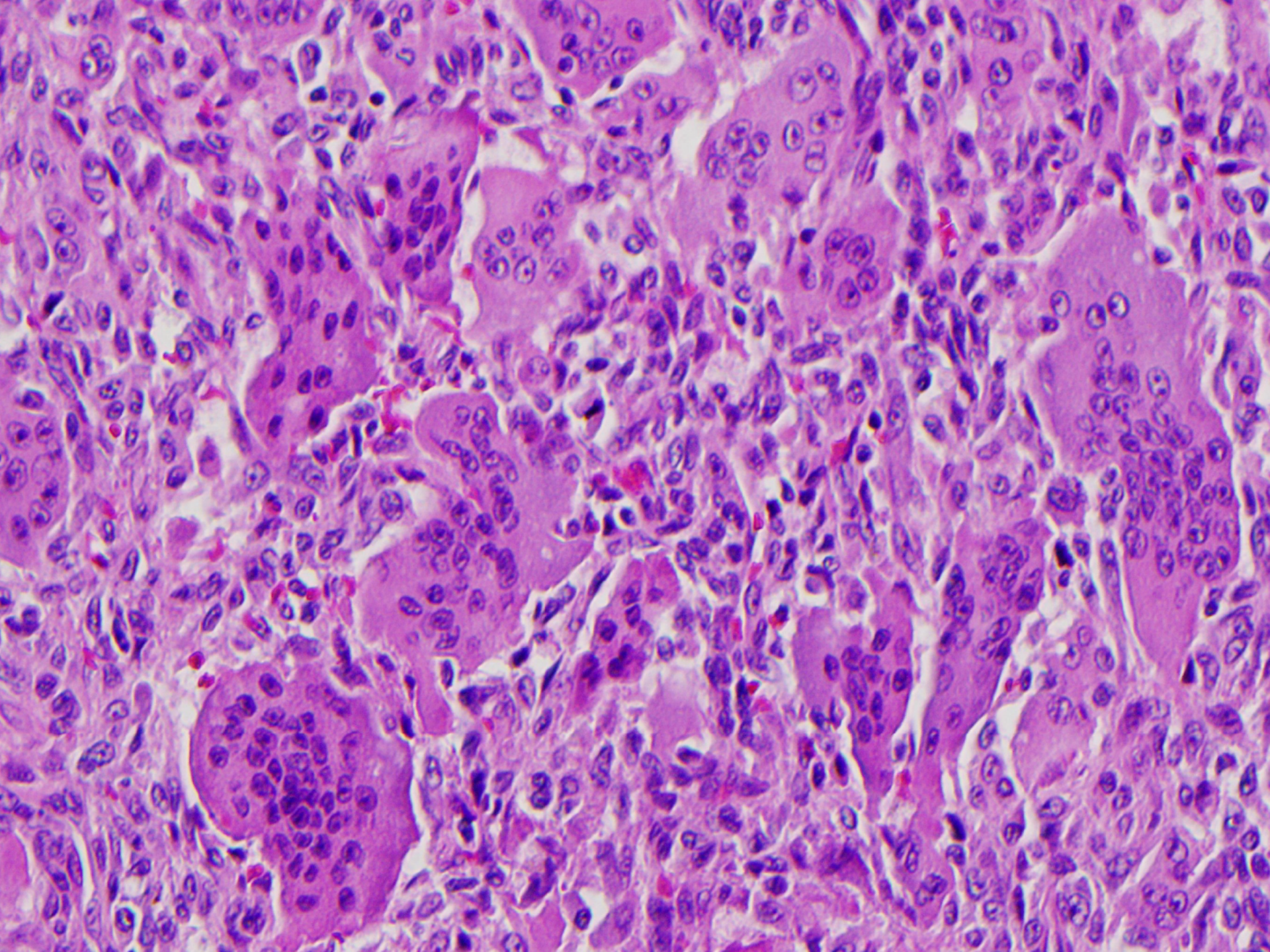












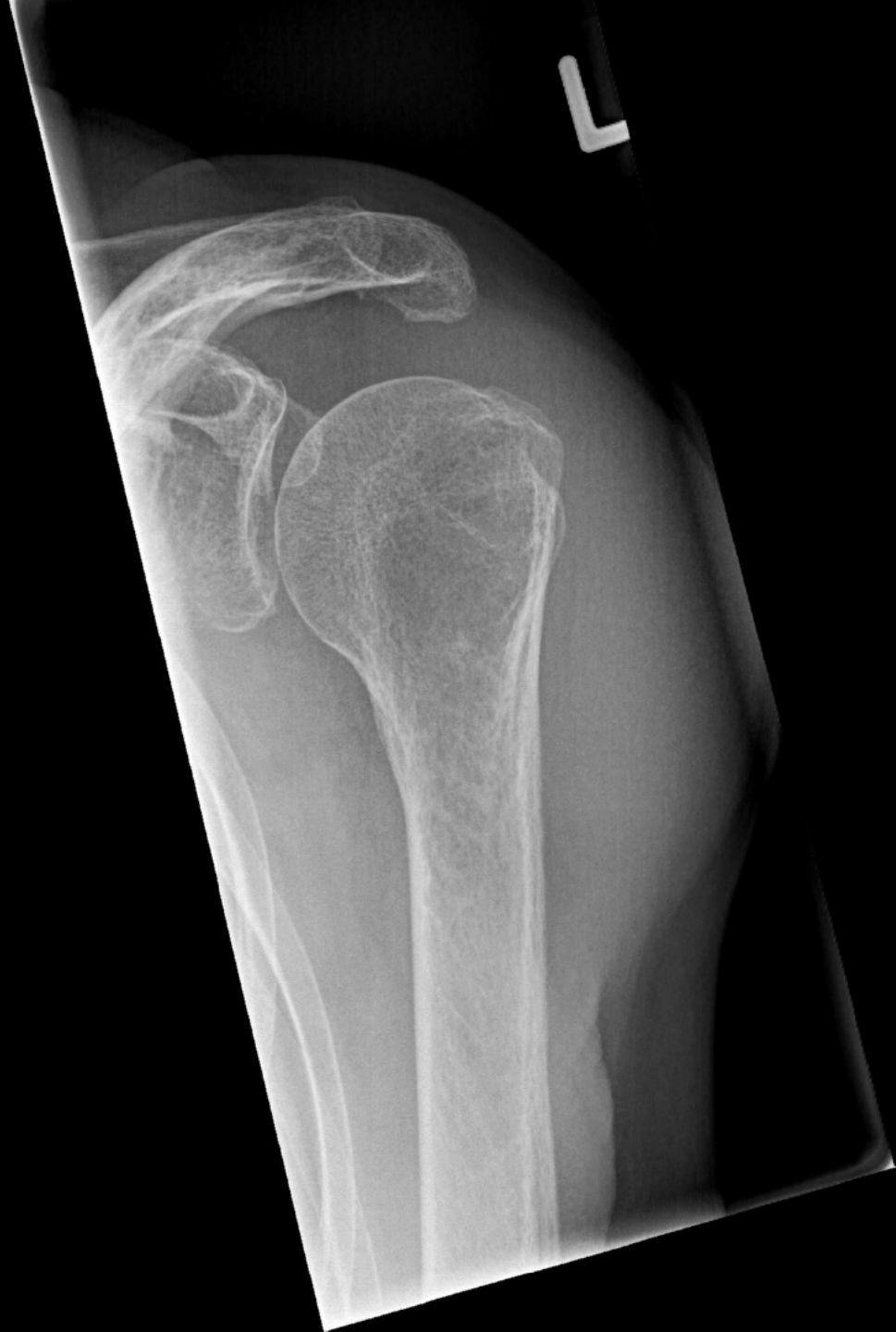# Giant Cell Tumor

Dr. Dushyant Thakur  
SUNY Upstate Medical Center  
Syracuse, New York

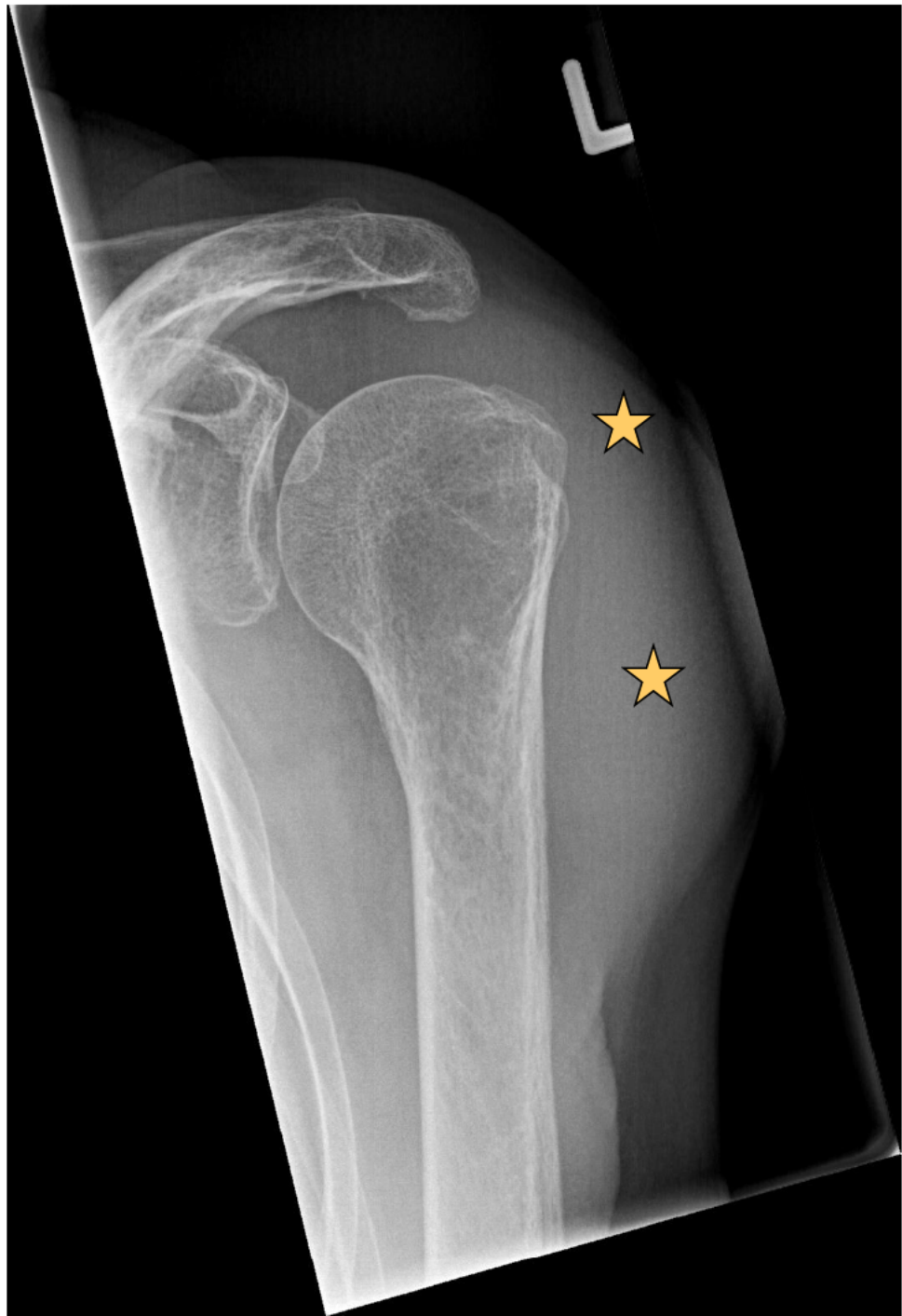

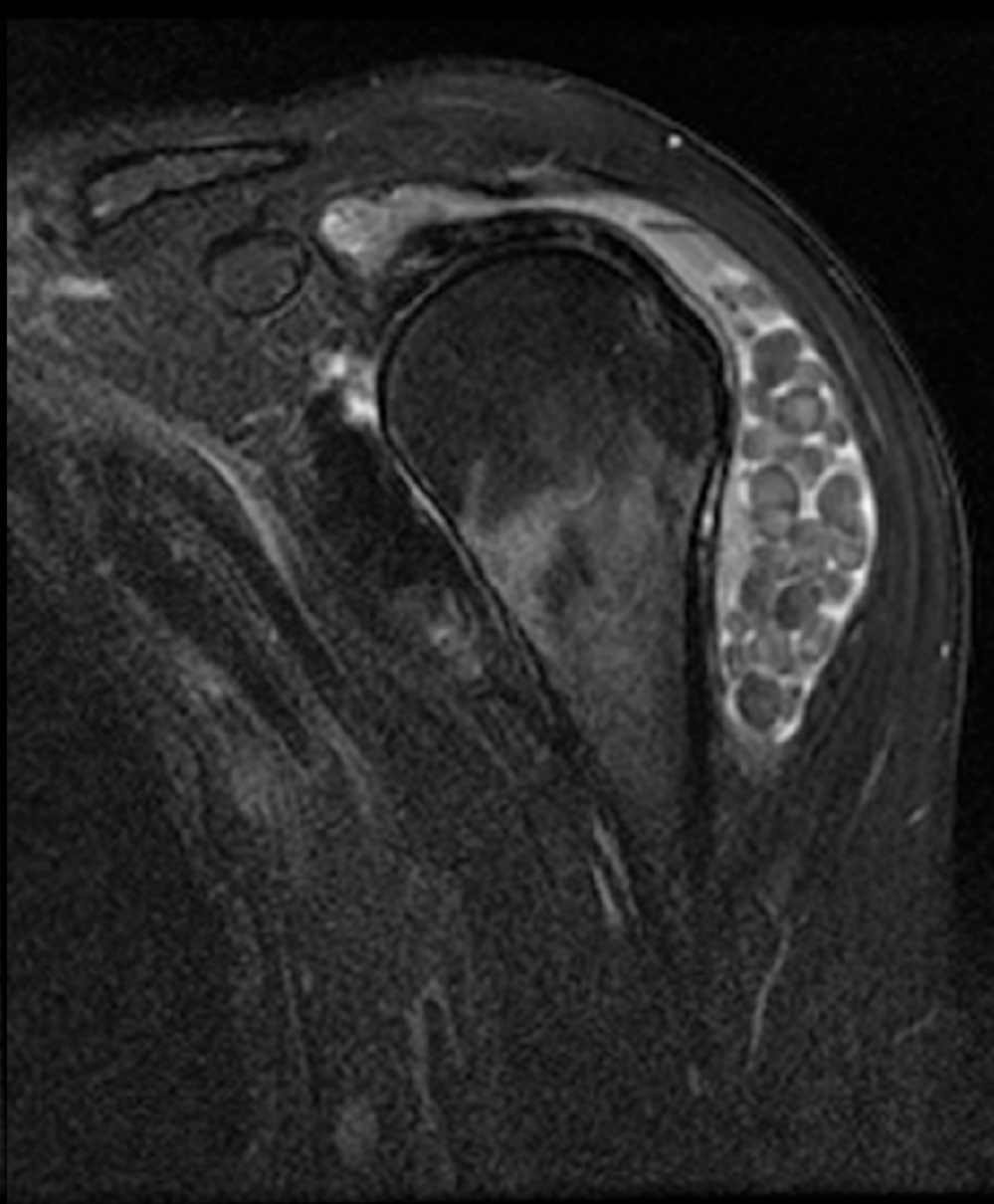
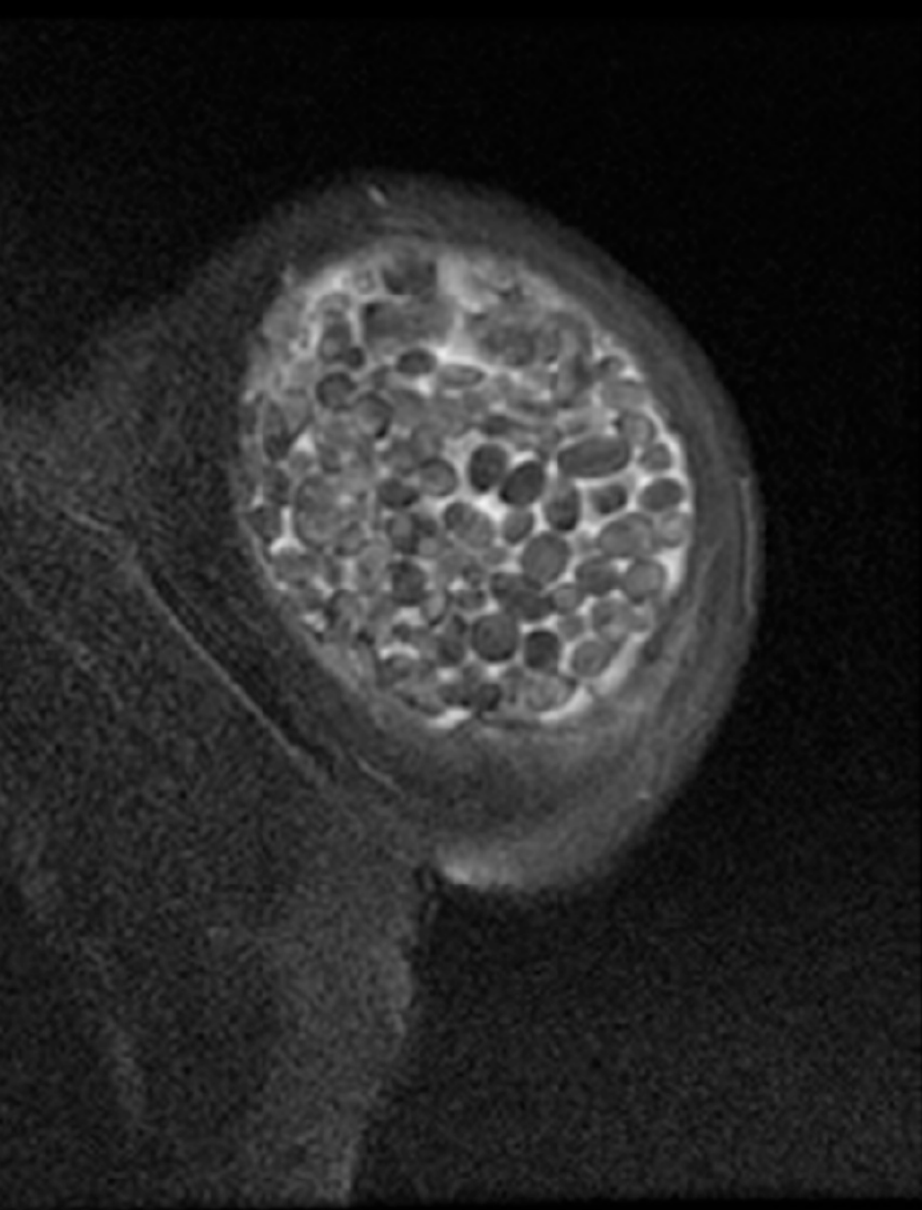
## HONORABLE MENTION!

65 year old female with worsening left shoulder pain. PMH withheld.

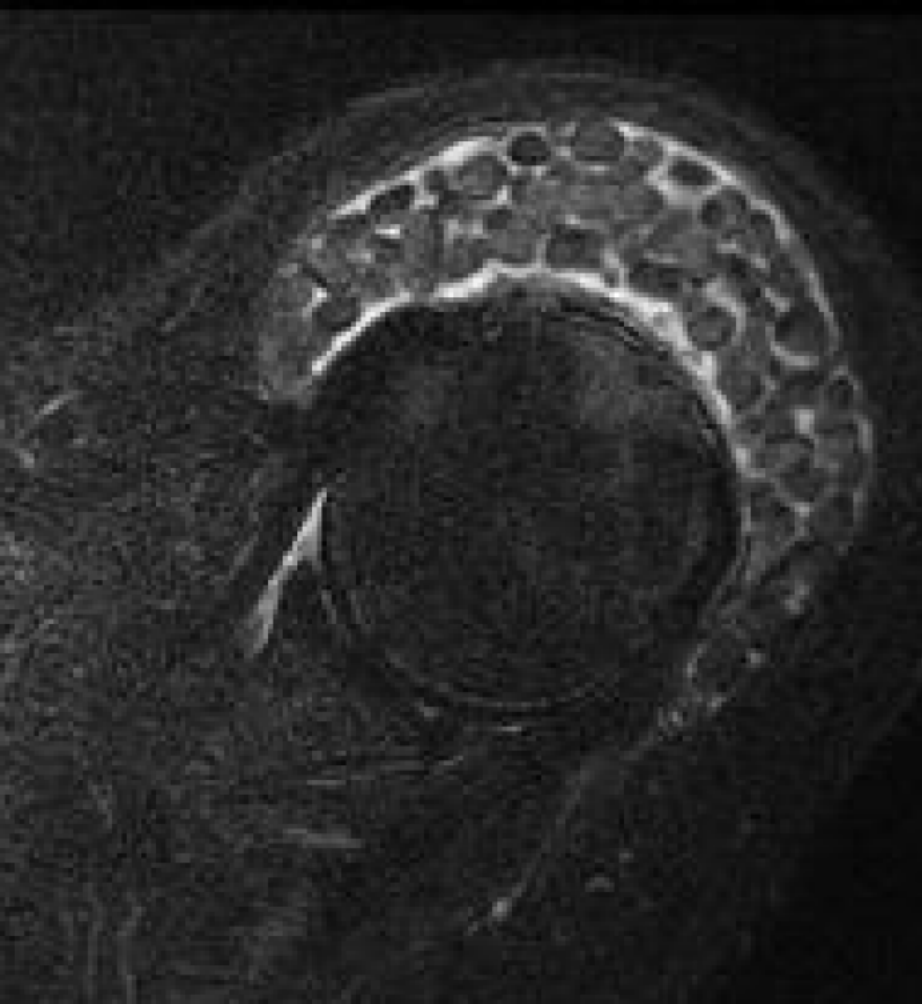




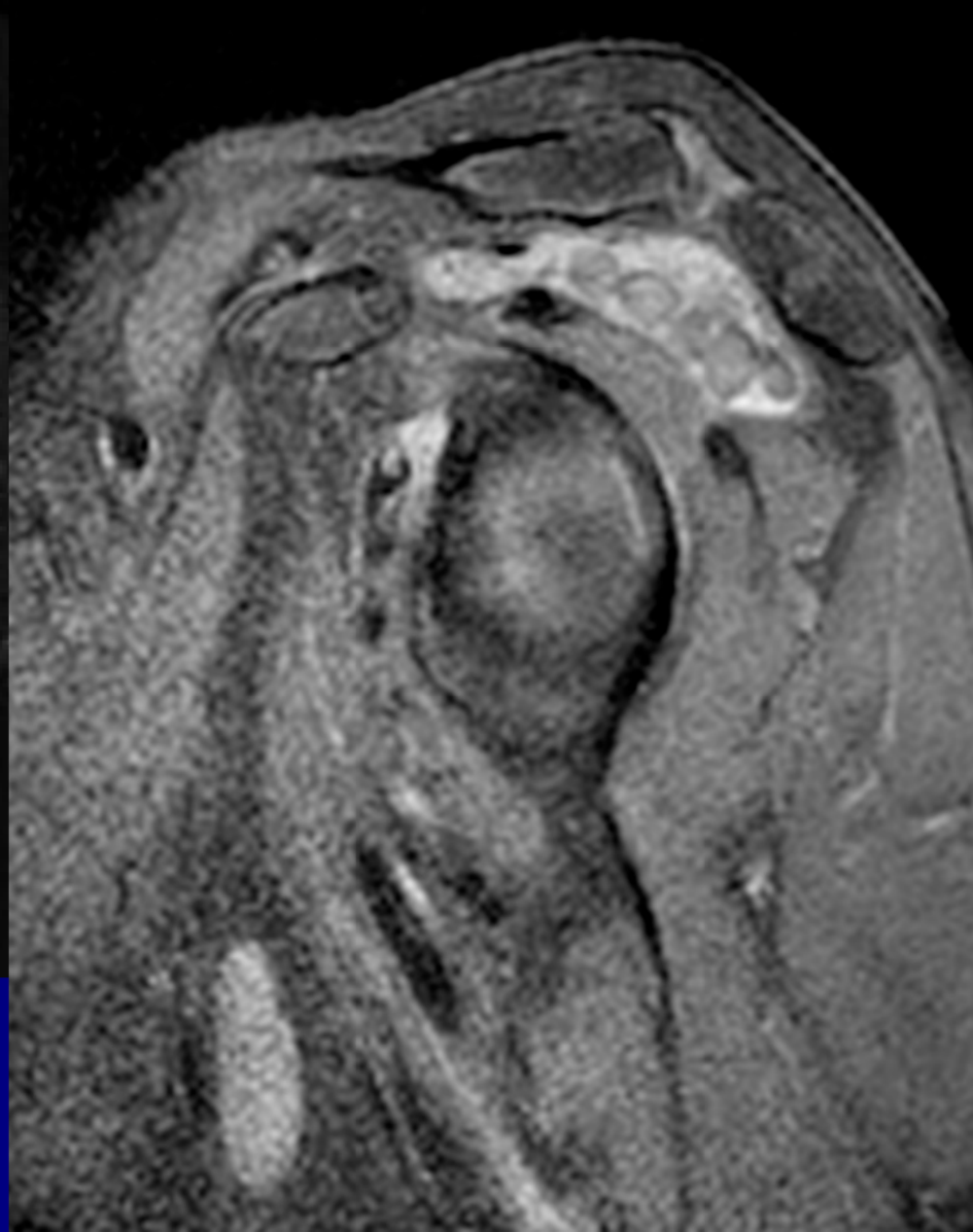


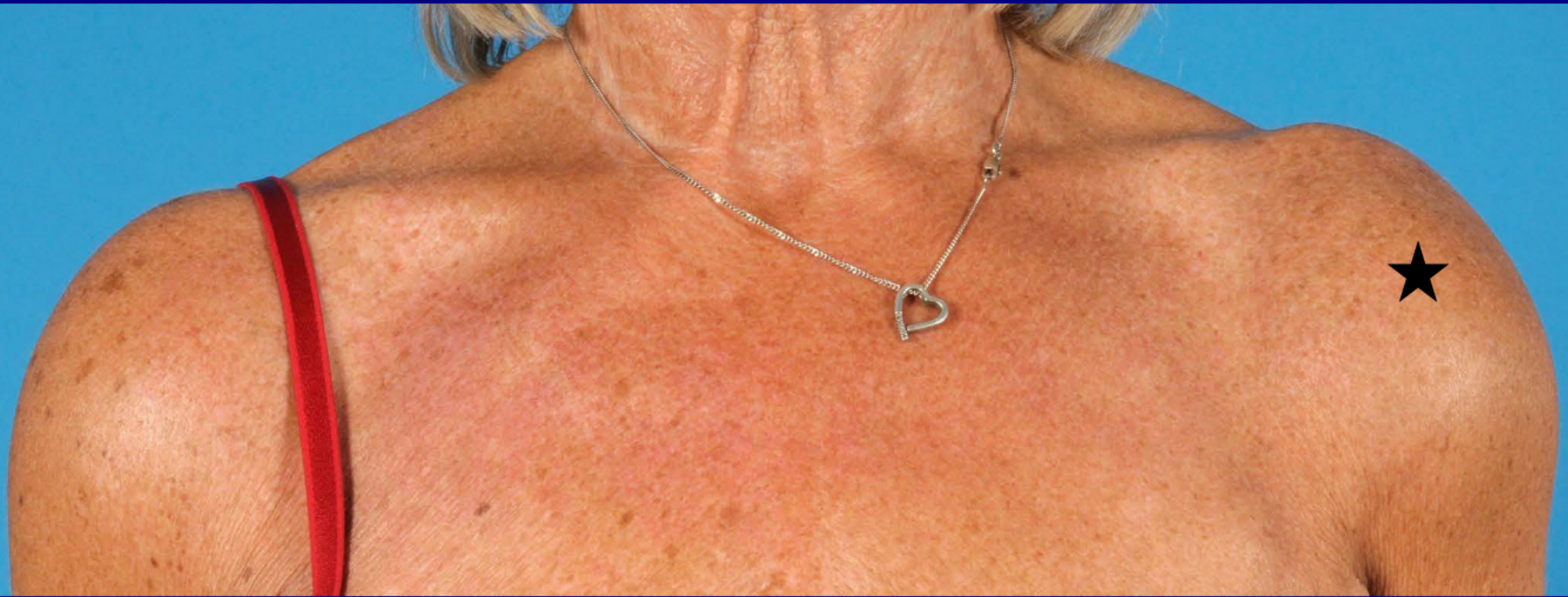

T2FS

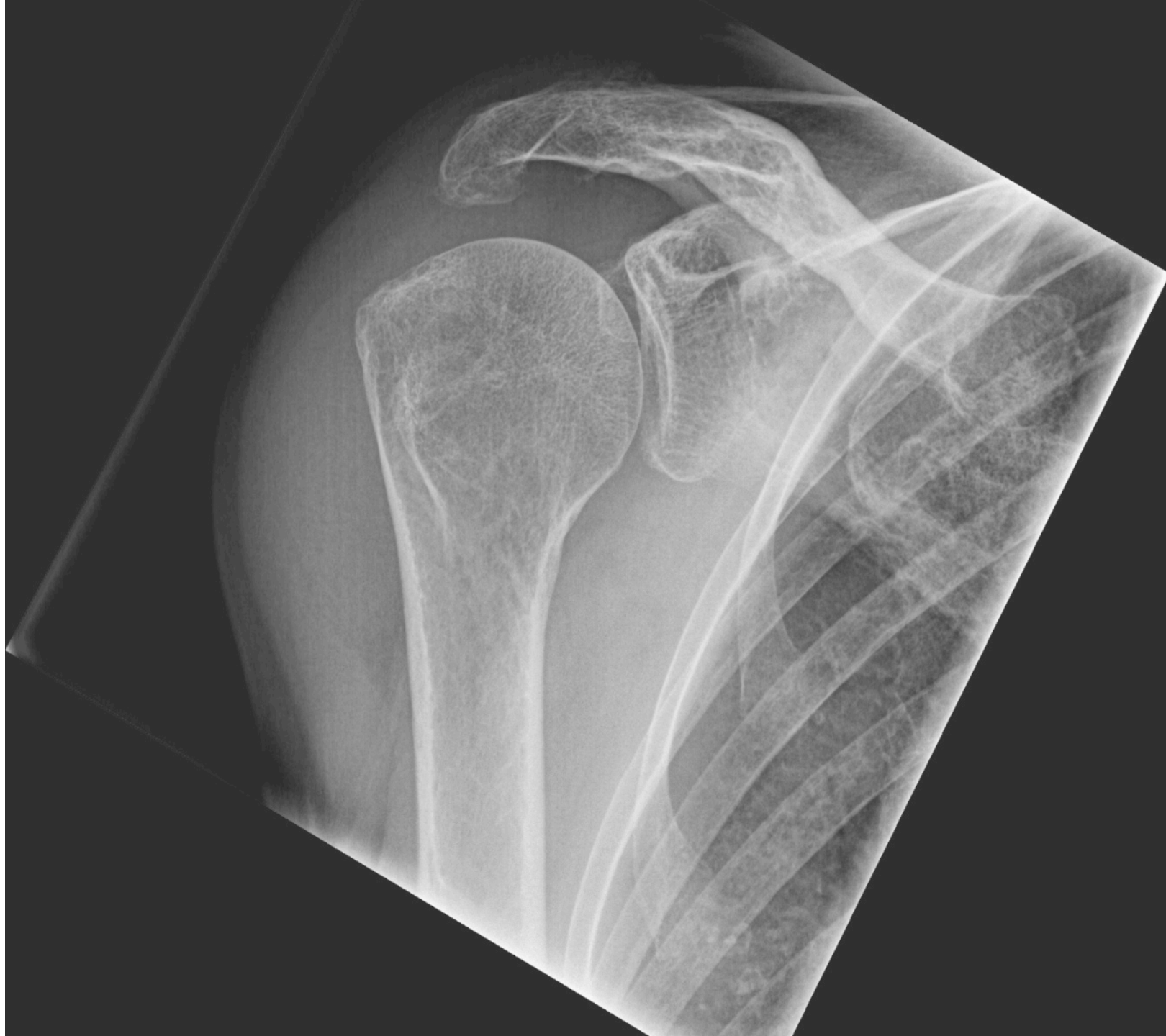

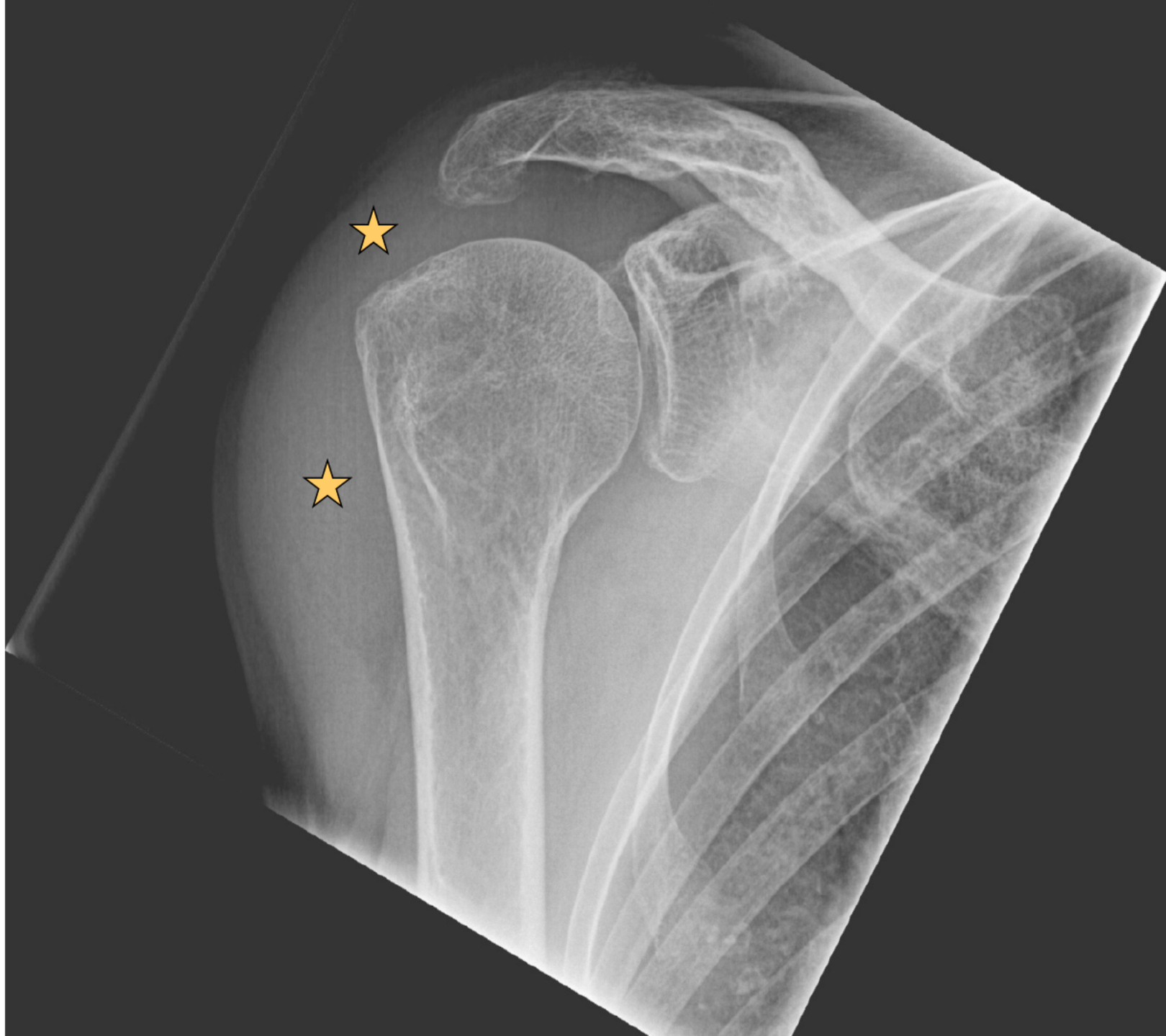
T2FS

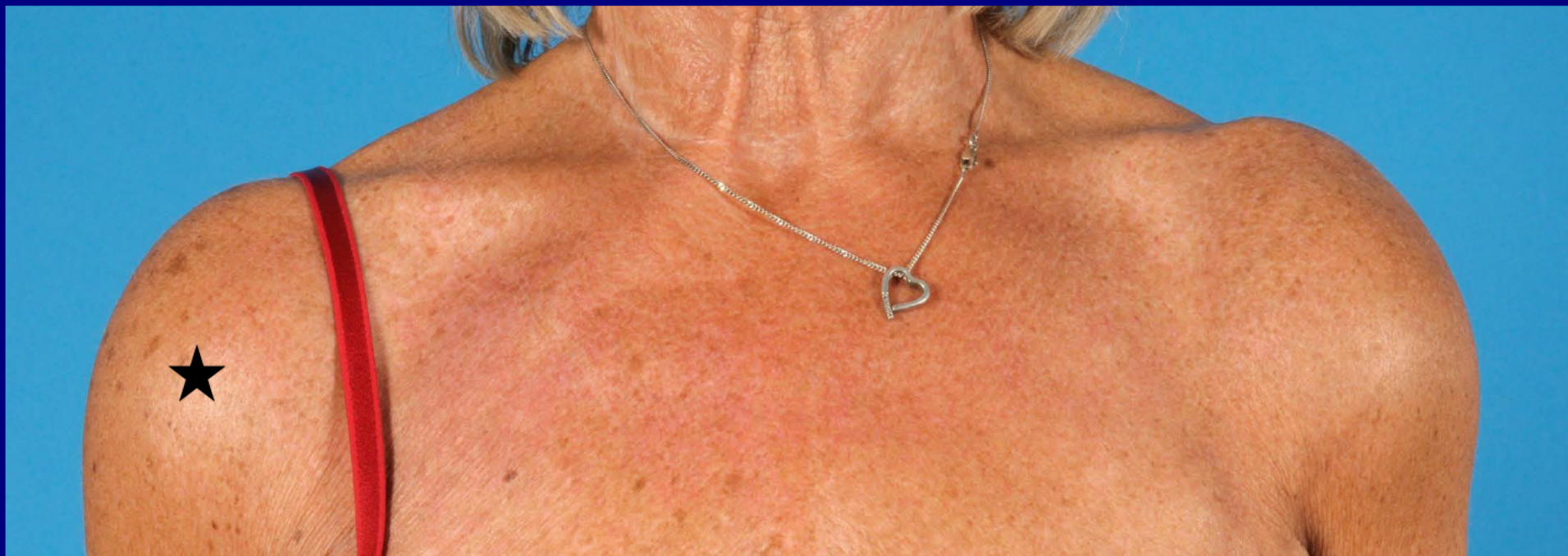



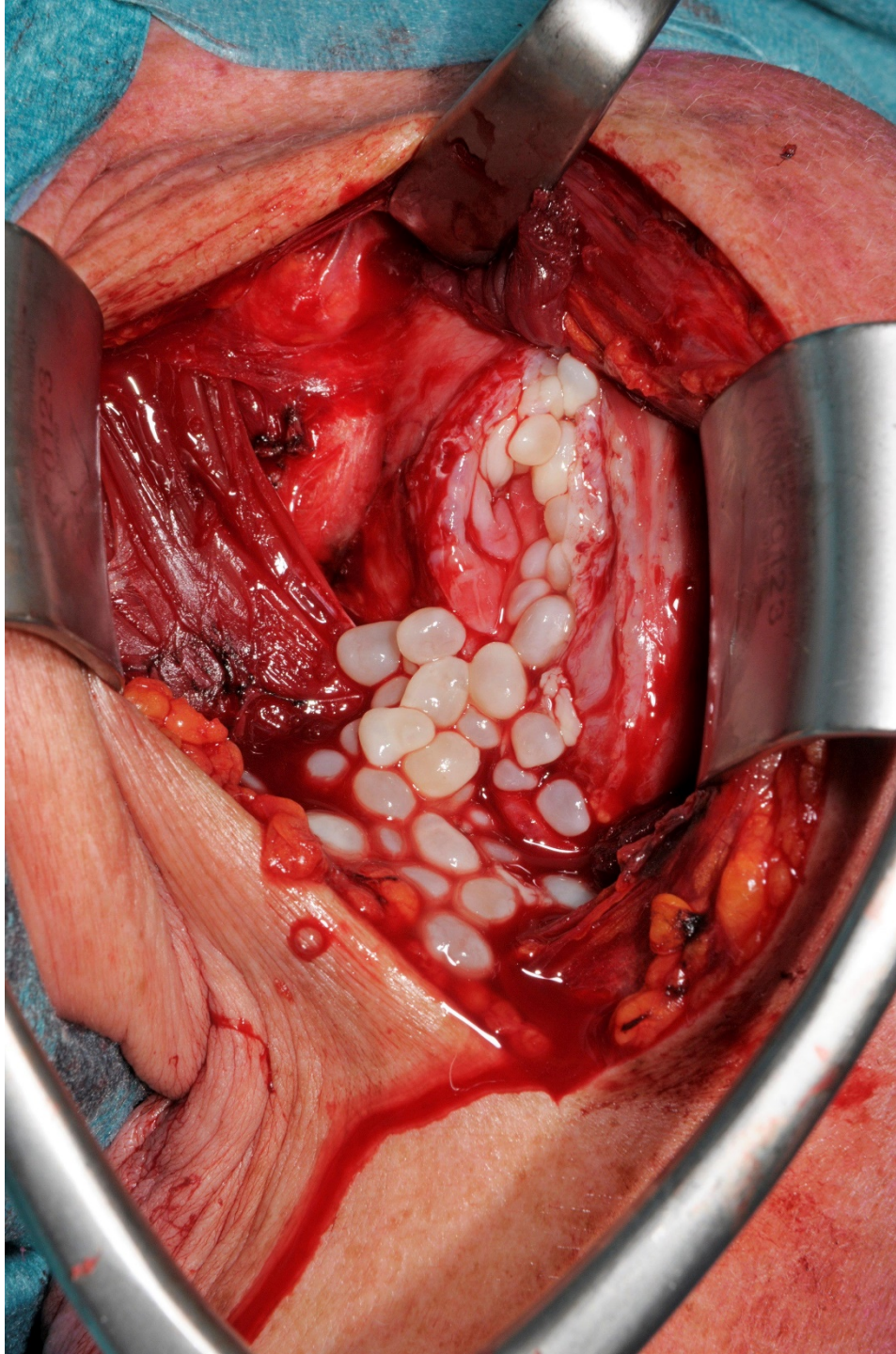





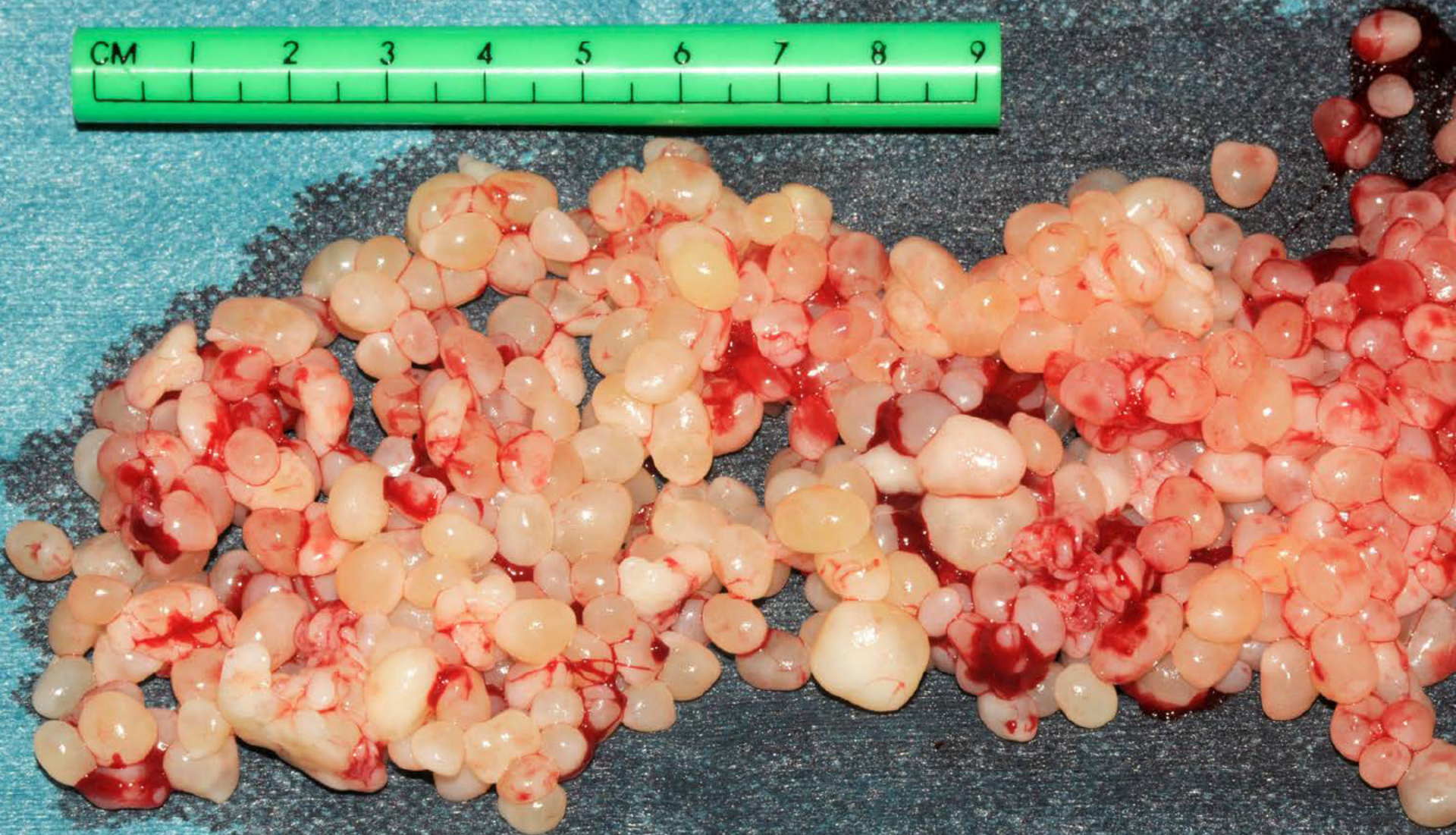




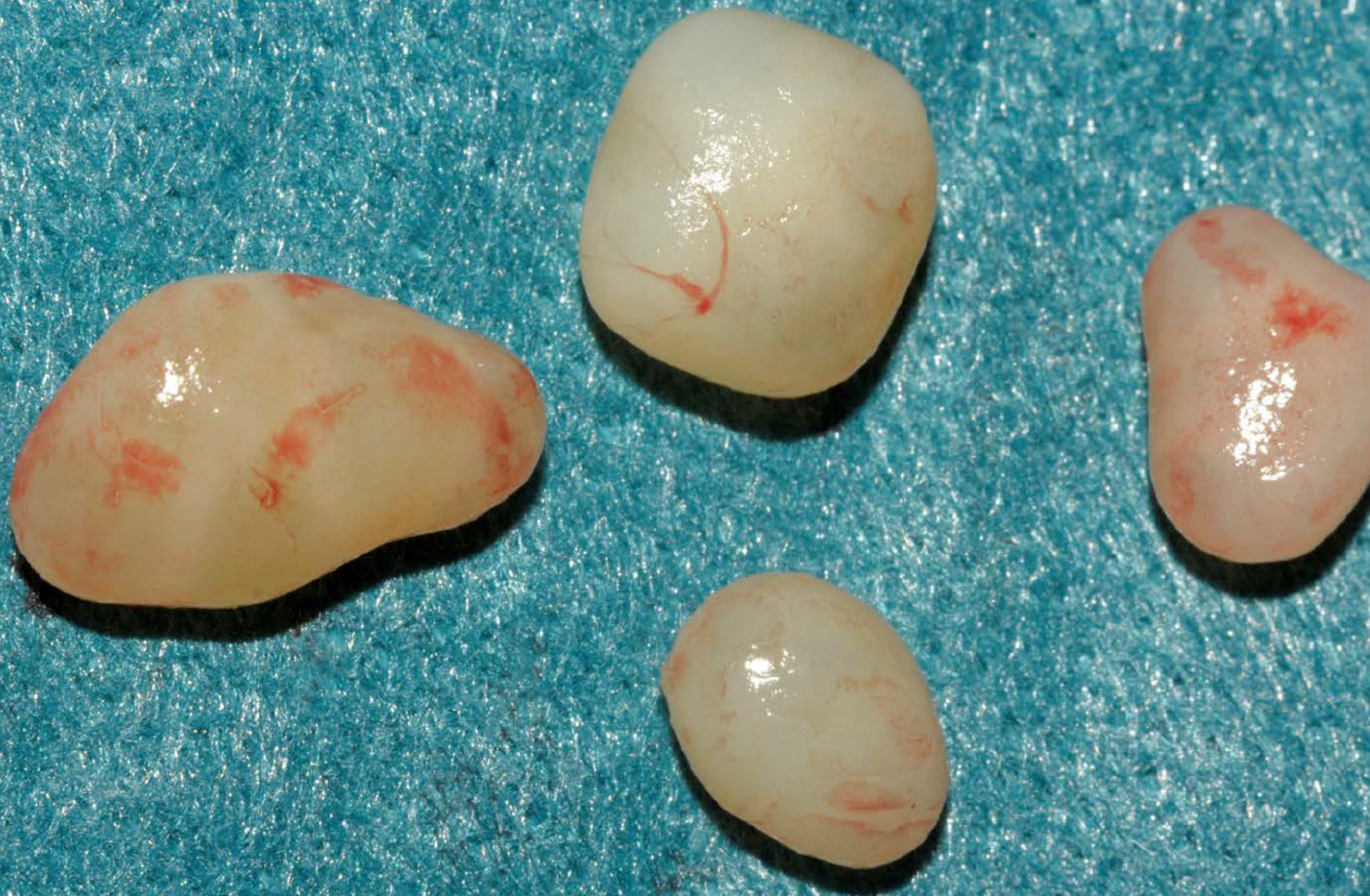




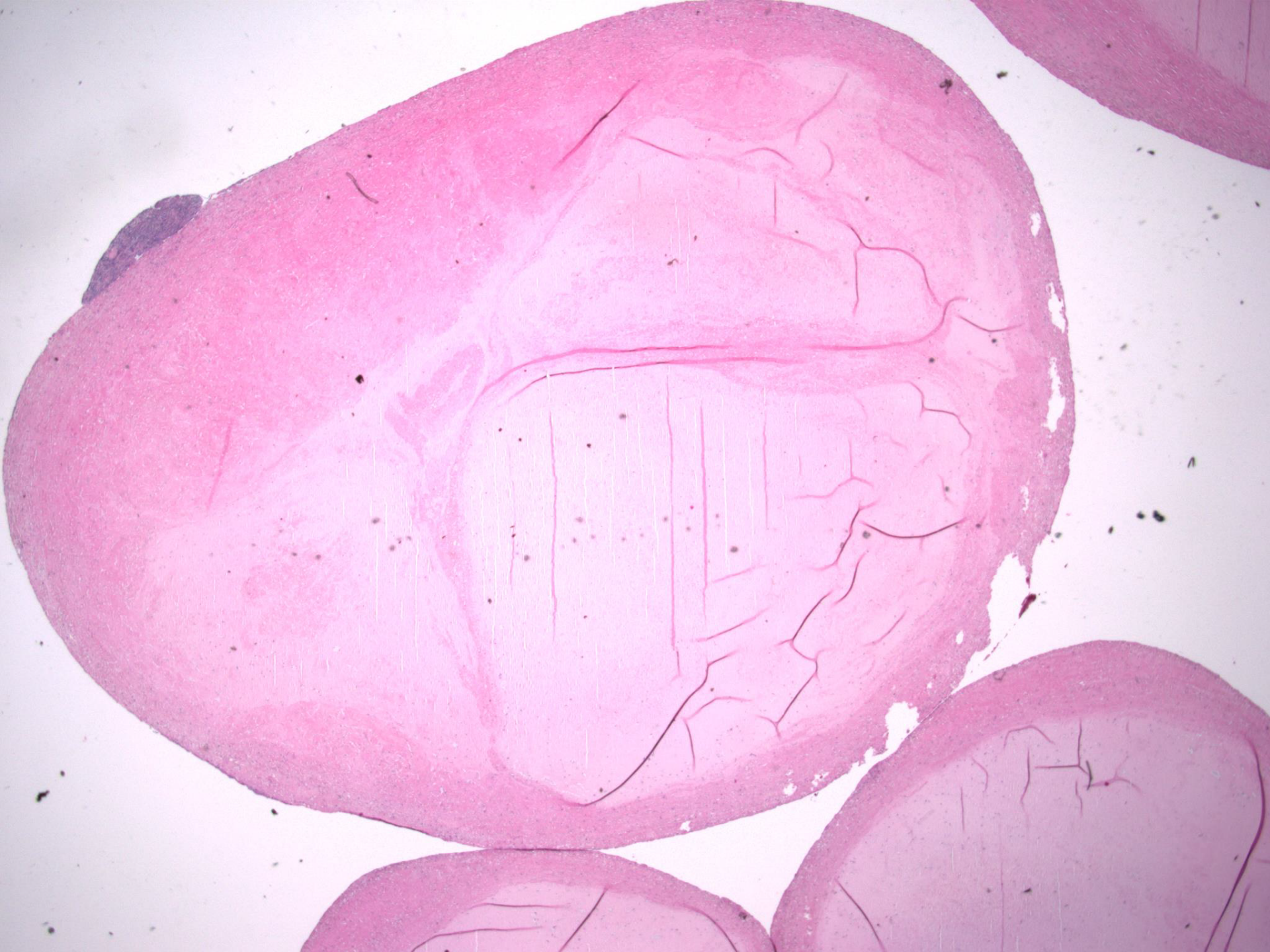


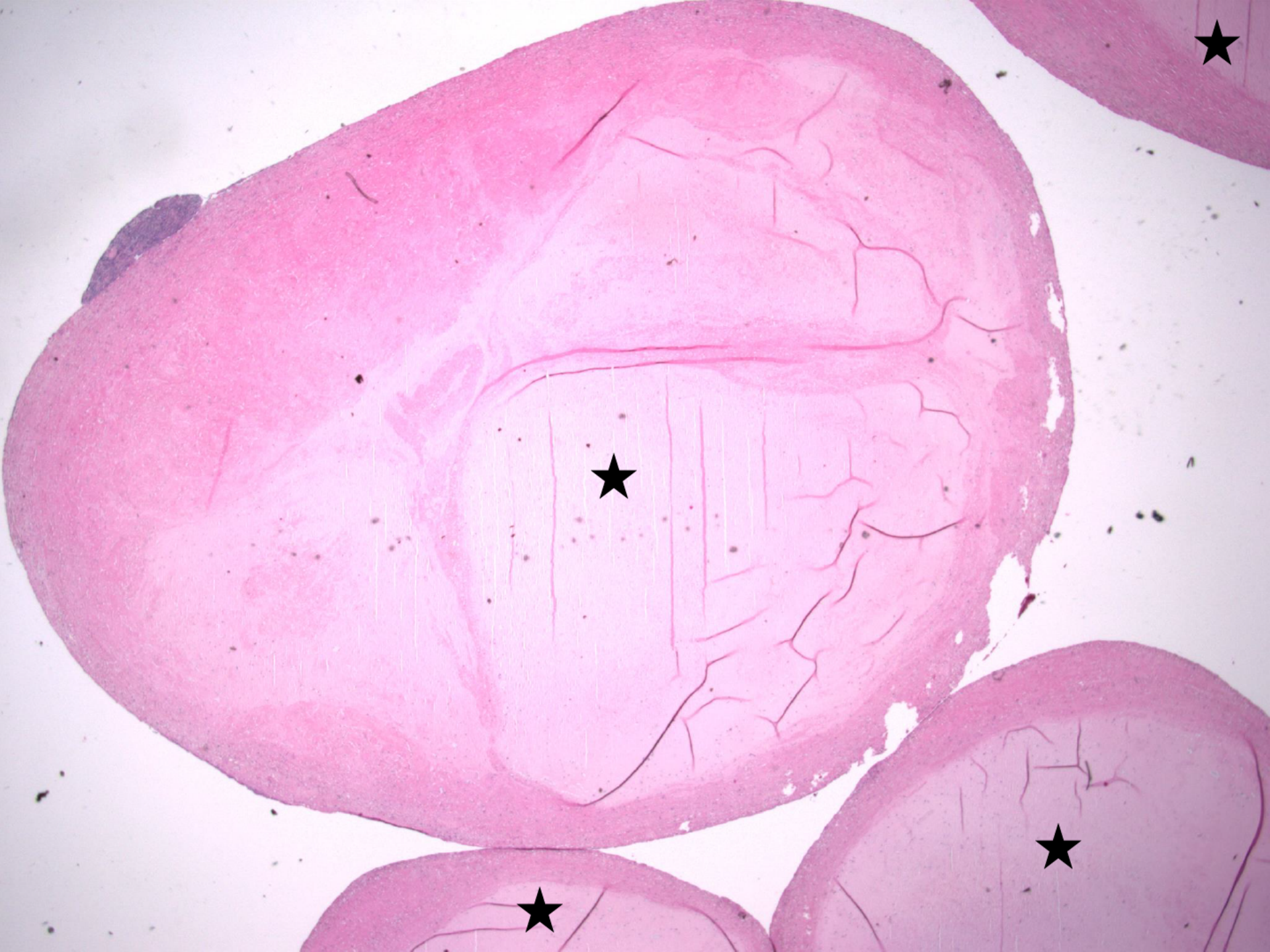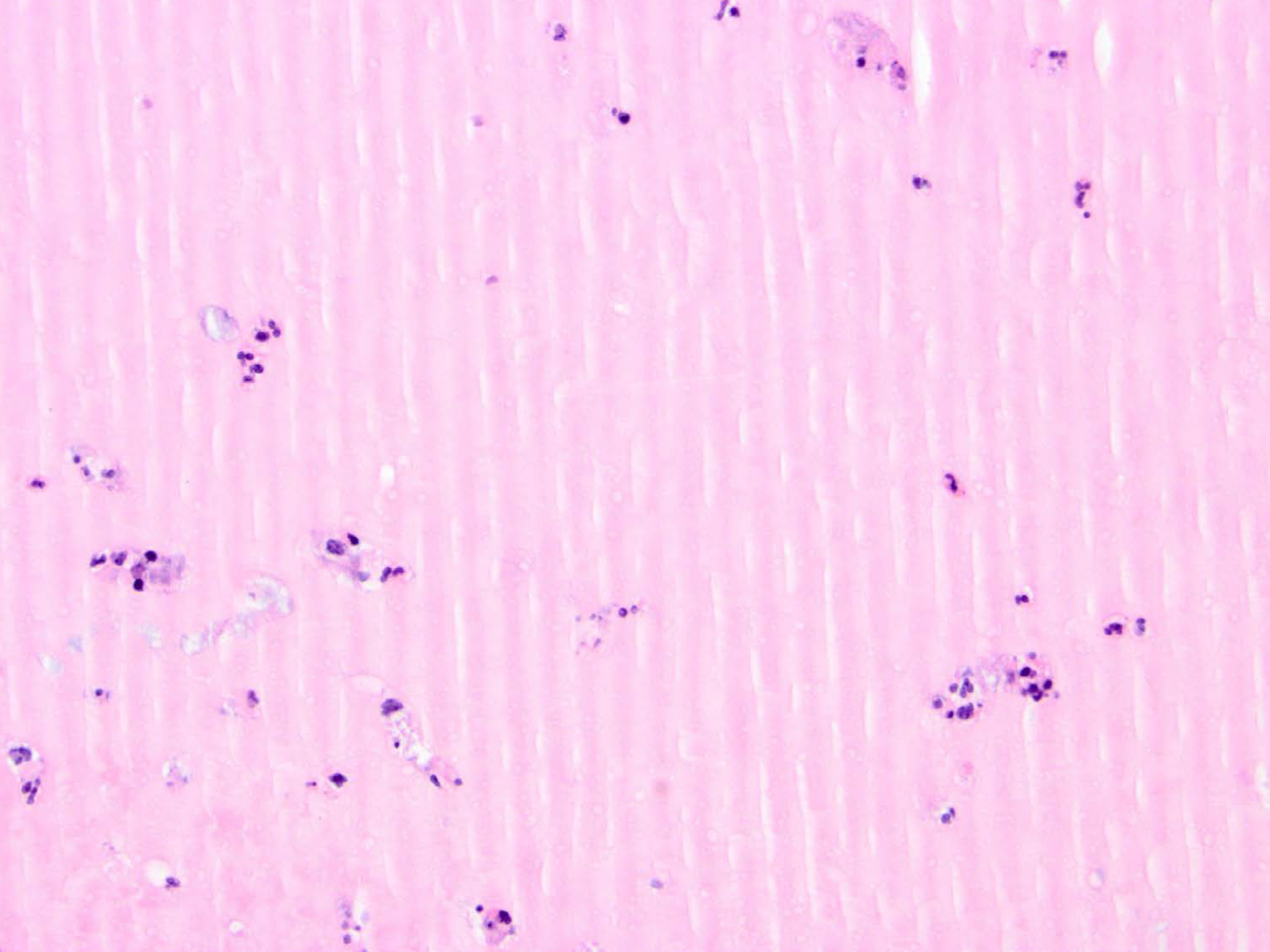




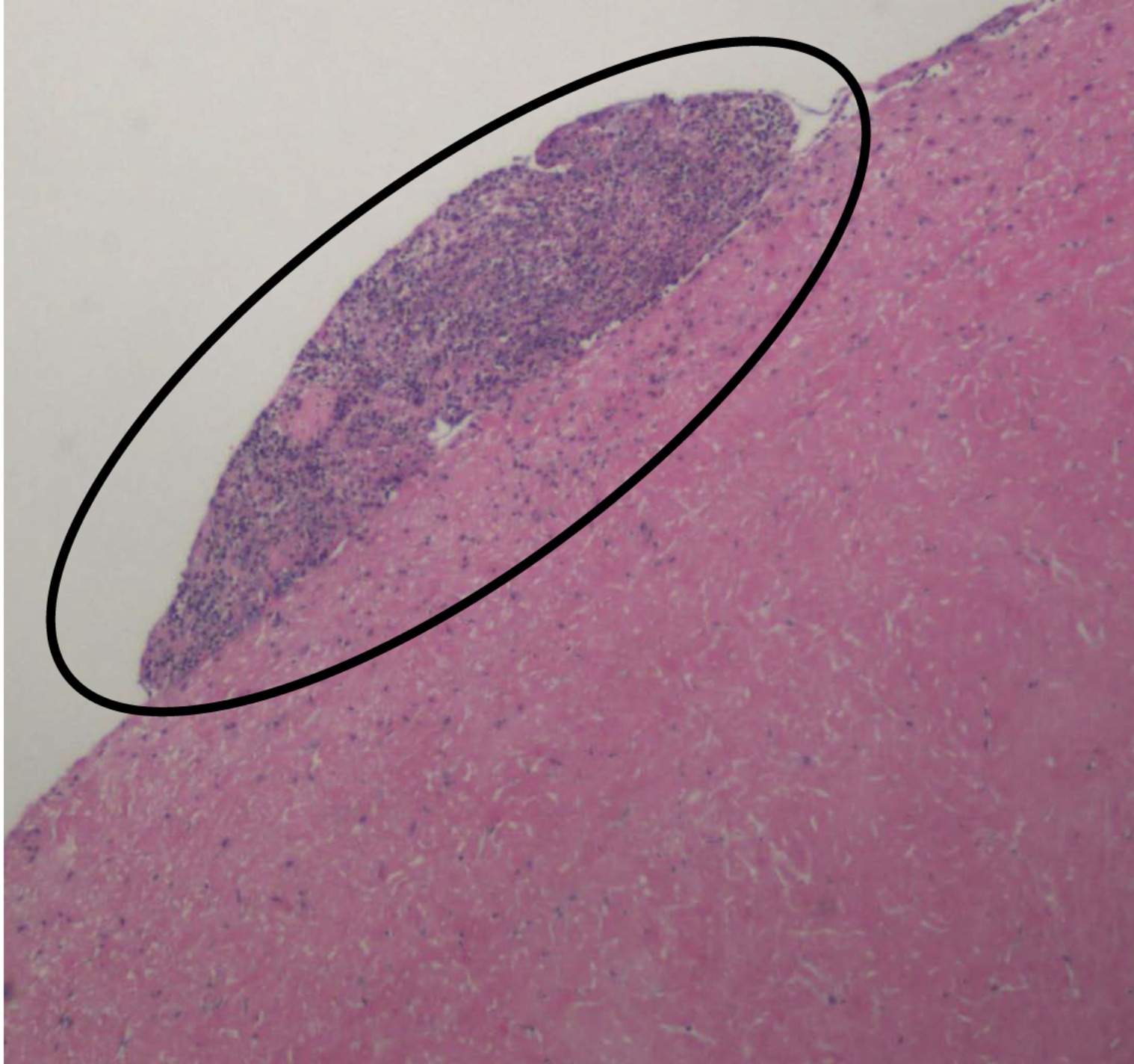












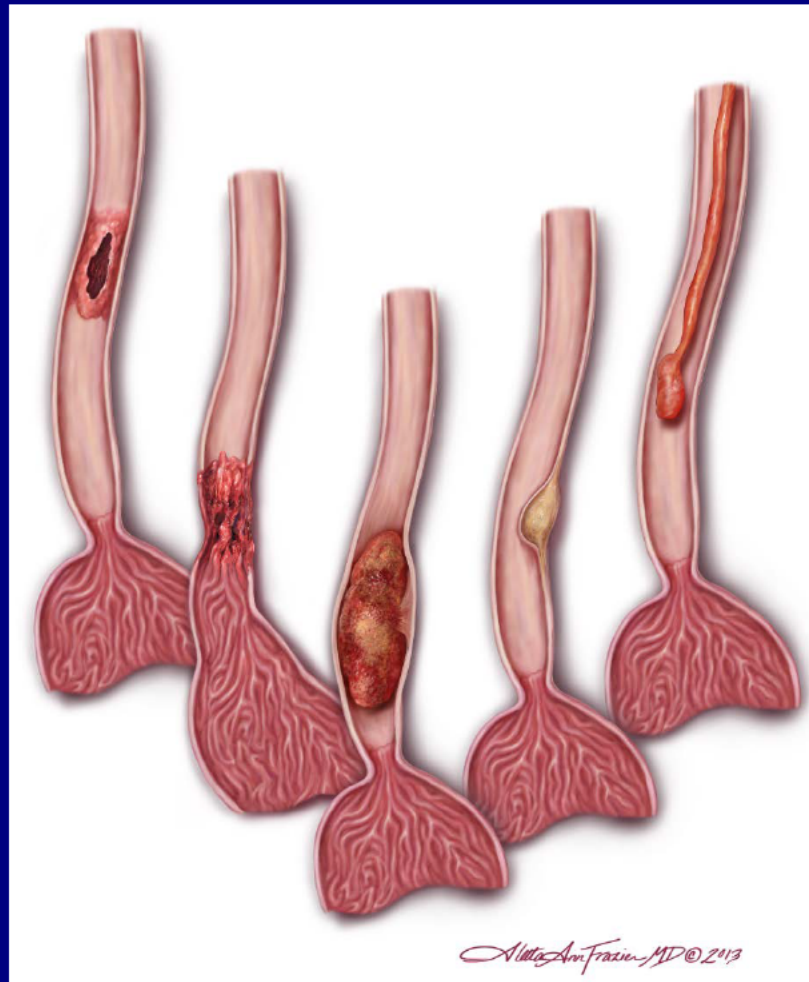# Rice Bodies in Rheumatoid Arthritis

Dr. Inge Vanhooymissen  
Erasmus Medical Center  
Rotterdam, Netherlands

# Gastrointestinal Best Case

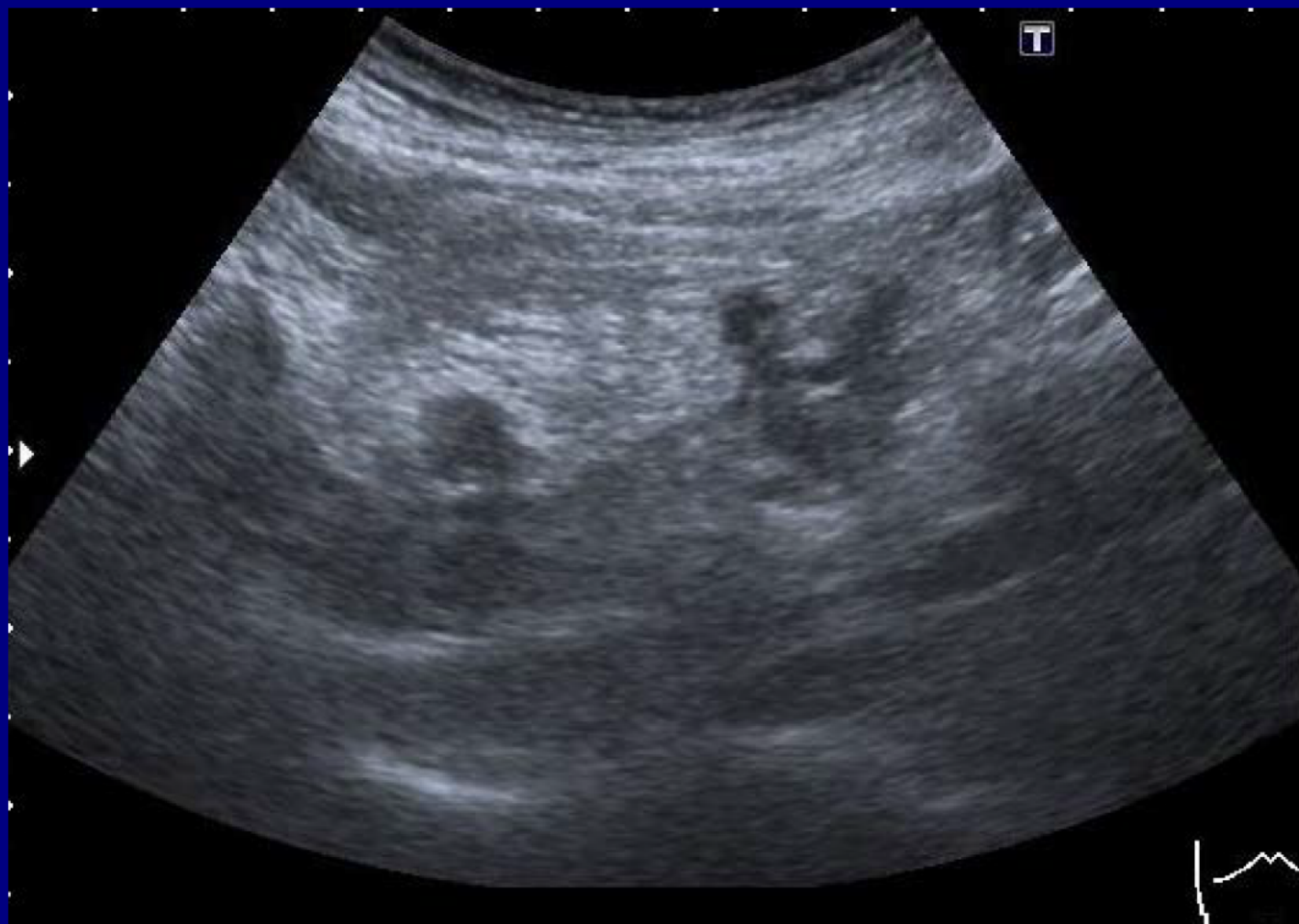


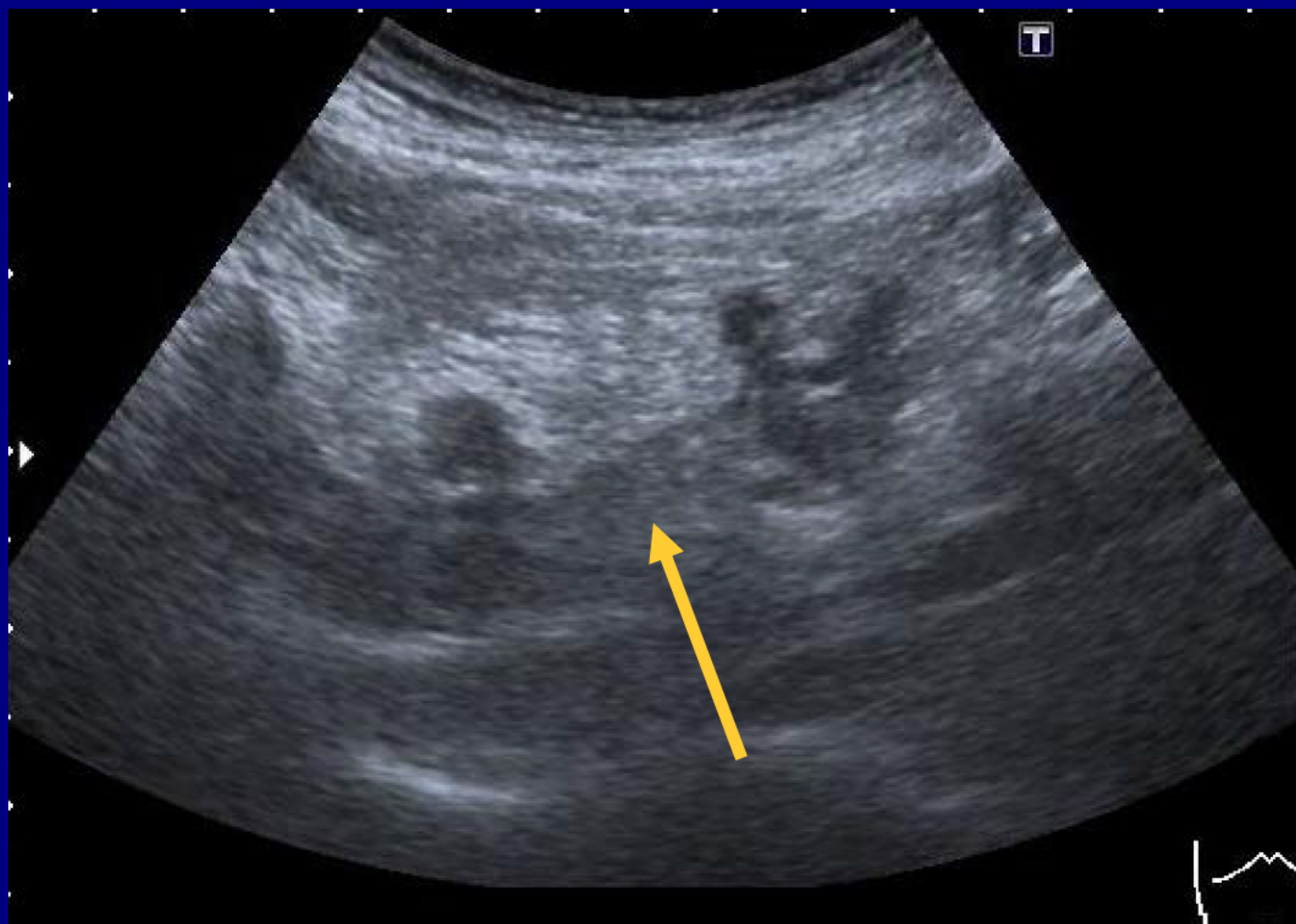


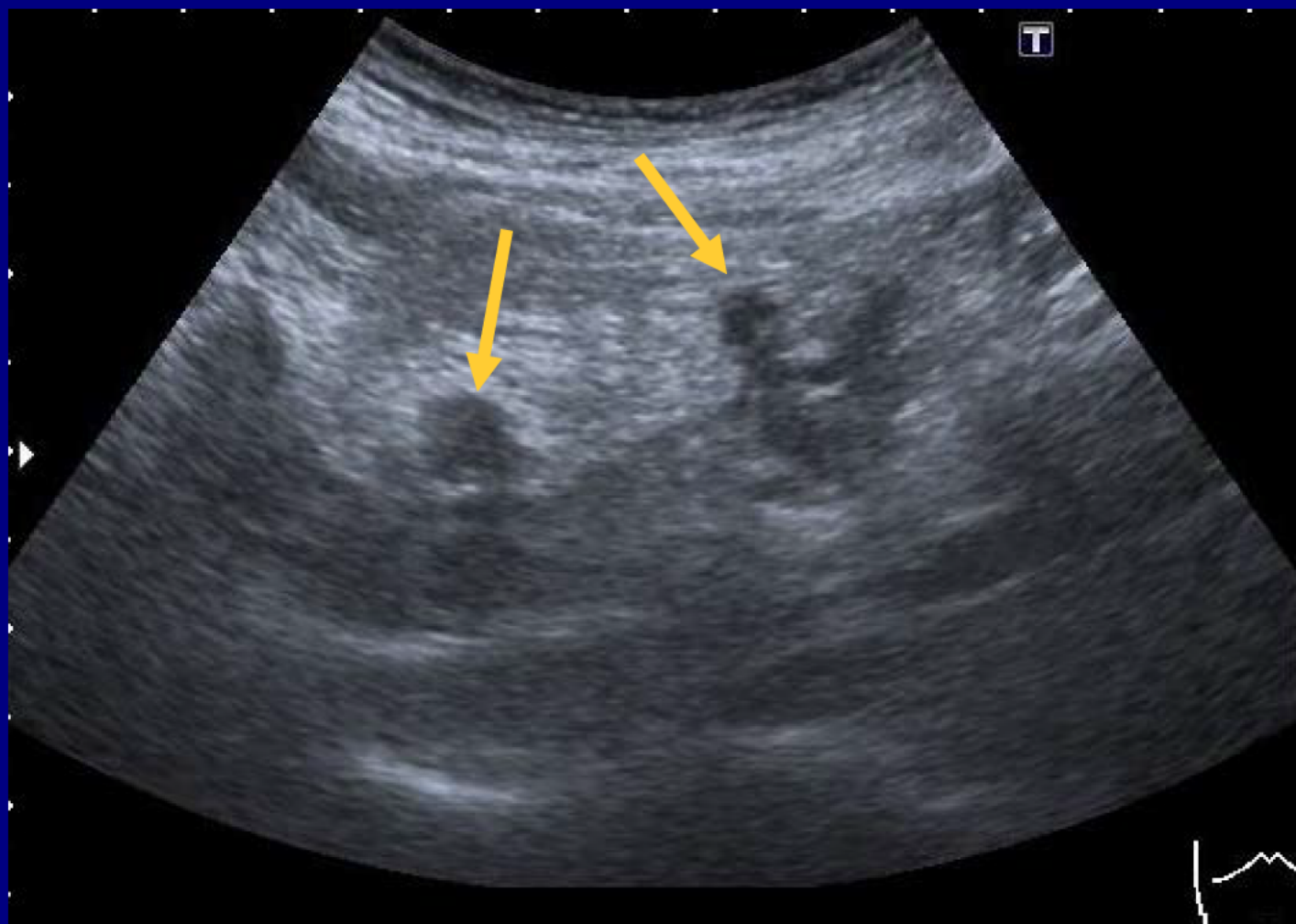
**48 year old male with 3 days of  
intermittent diffuse abdominal pain.**

**(-) fever**

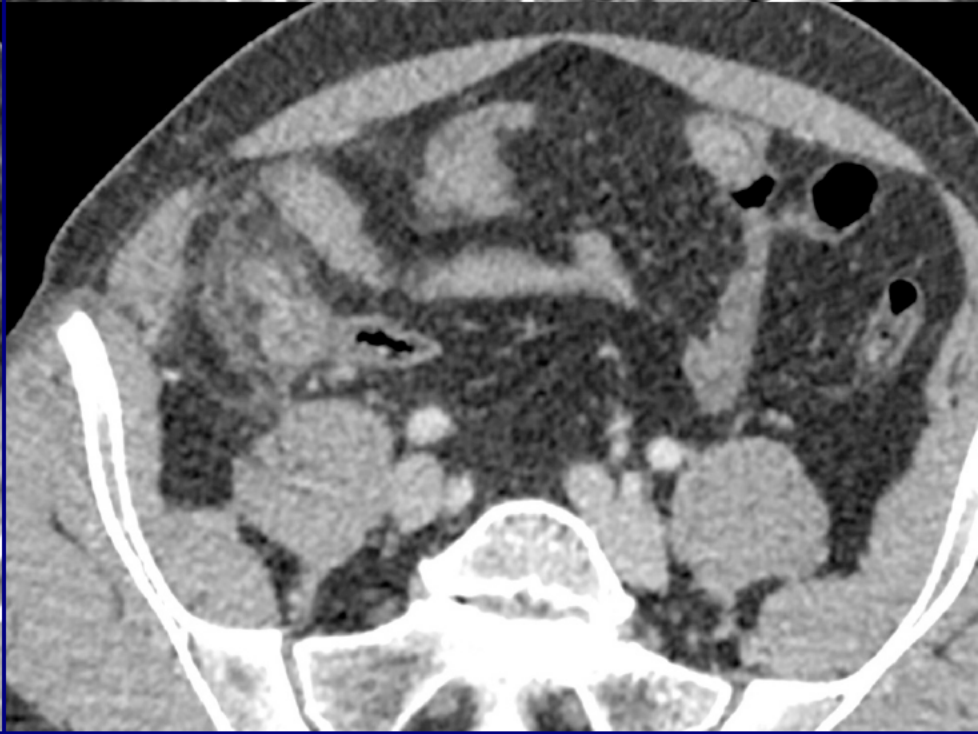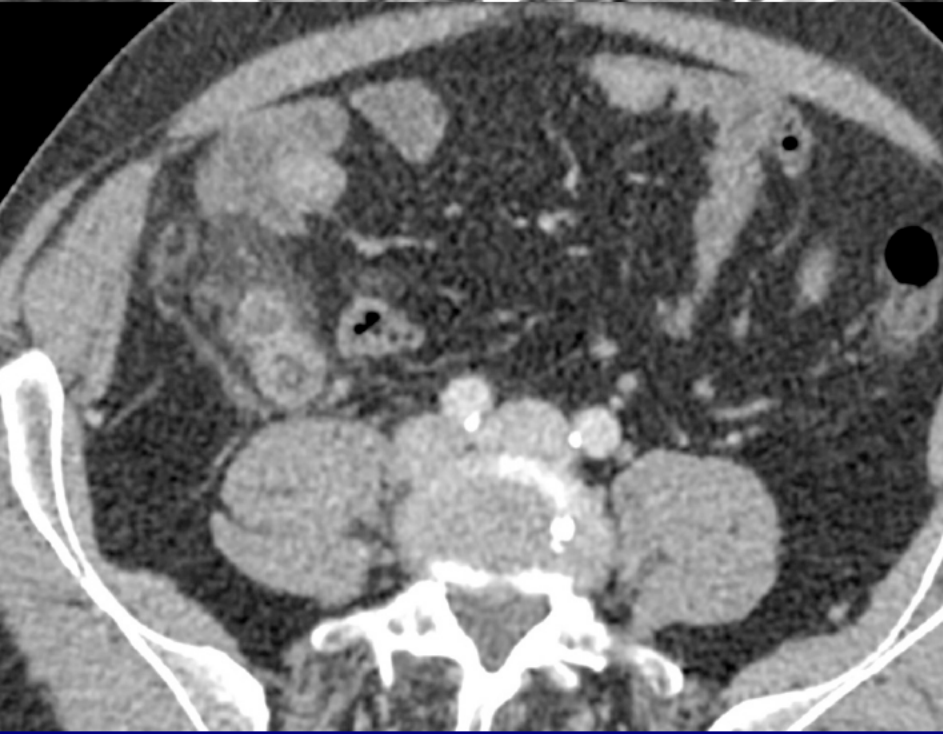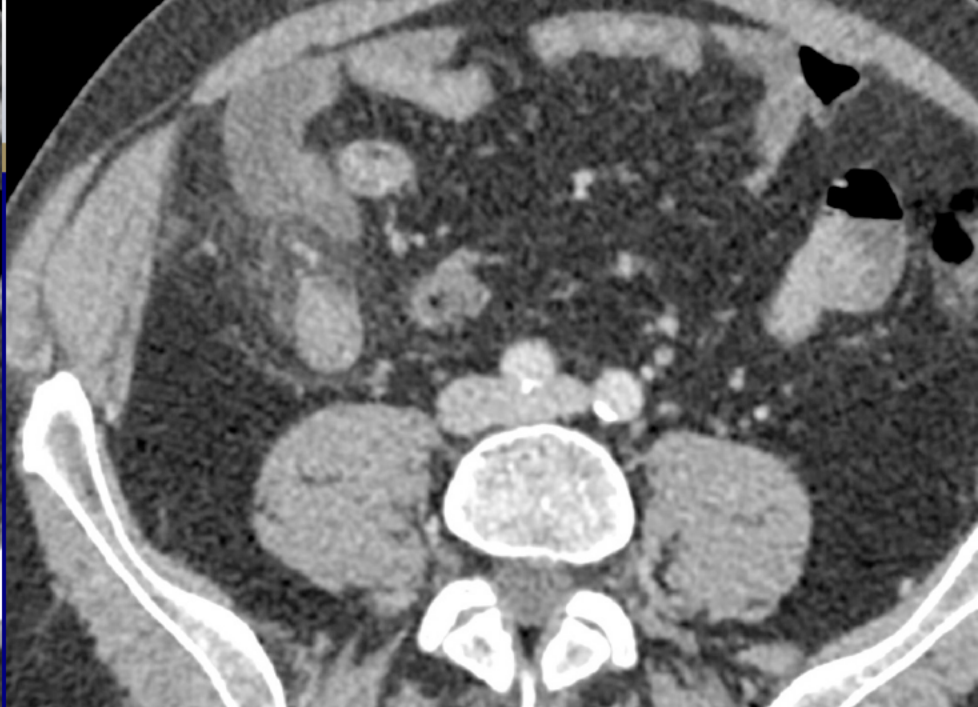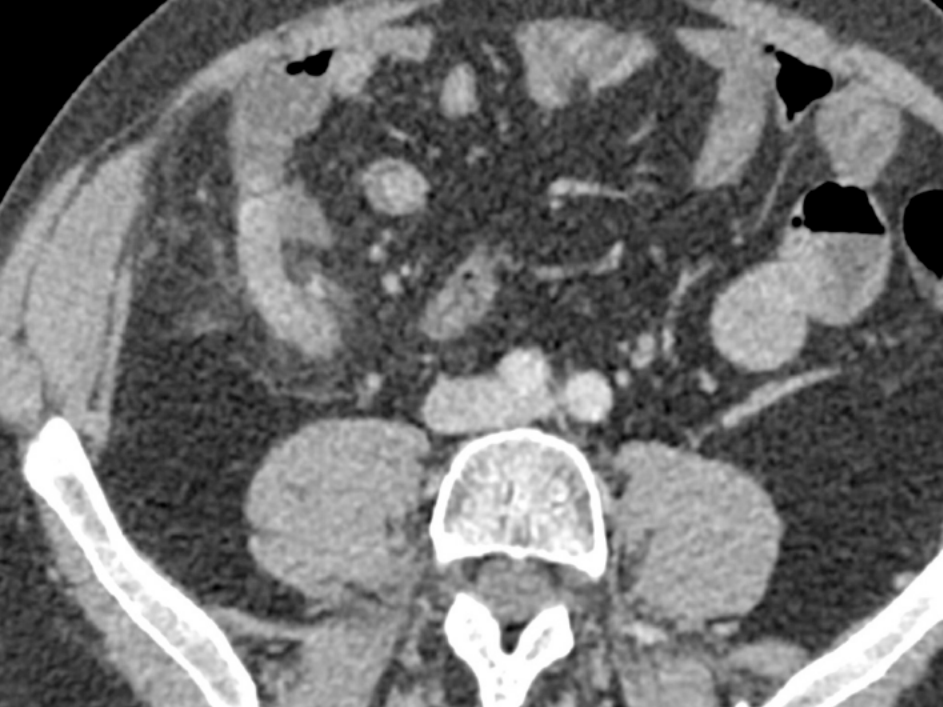**(+) nausea, anorexia**




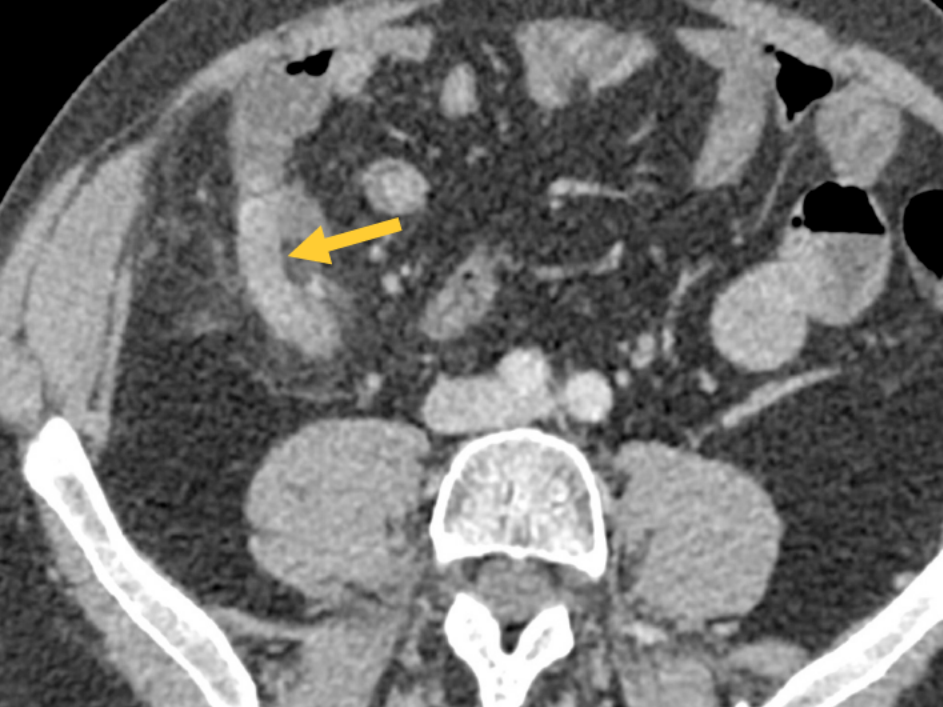


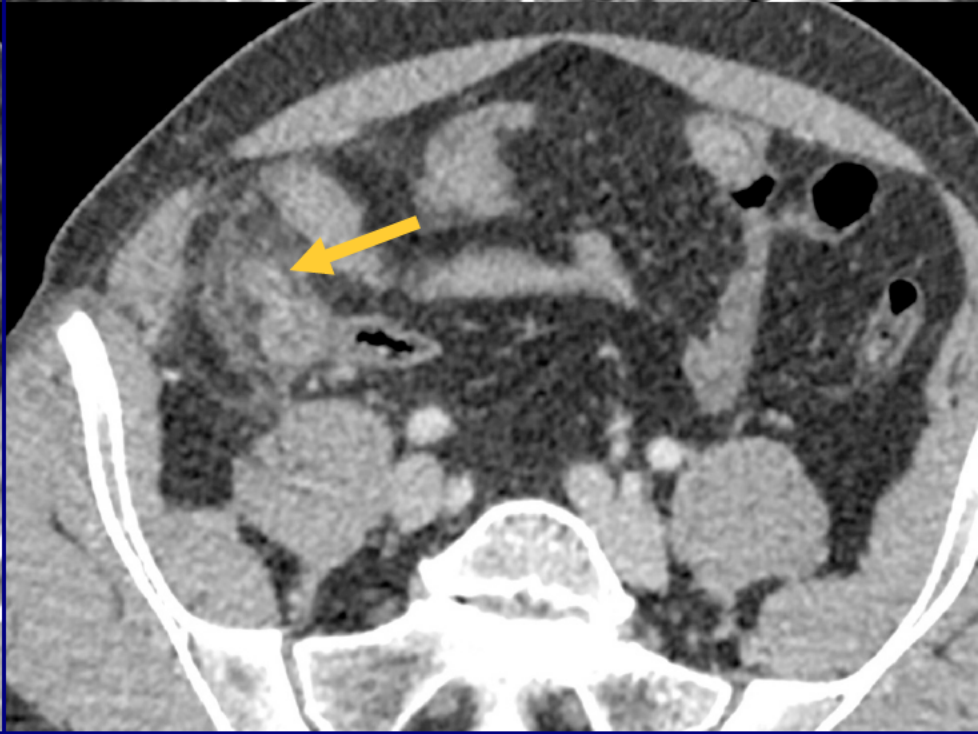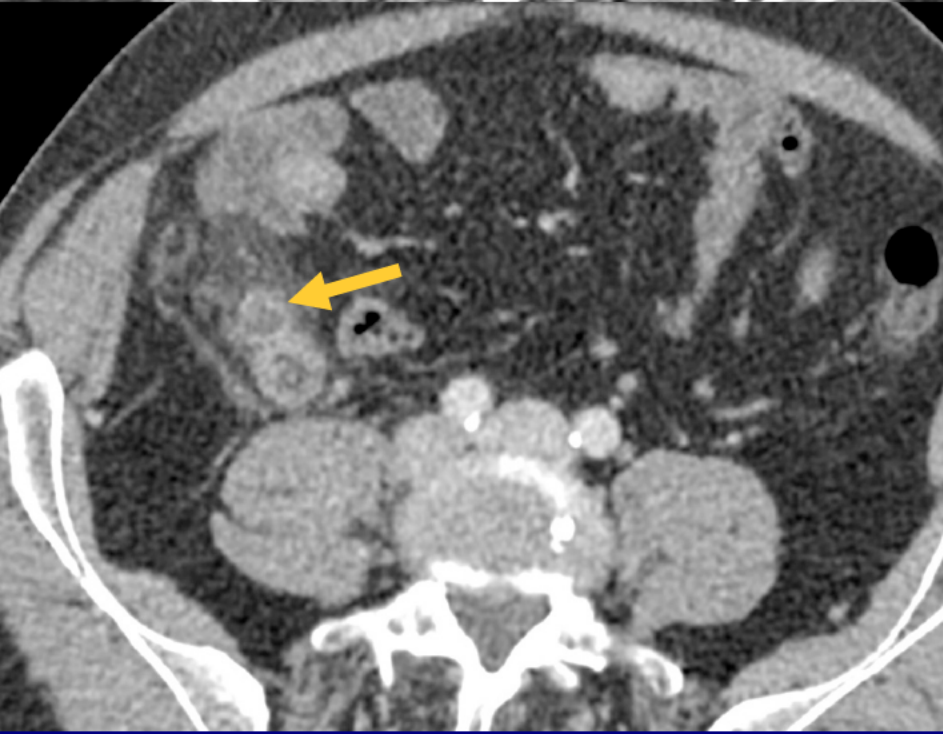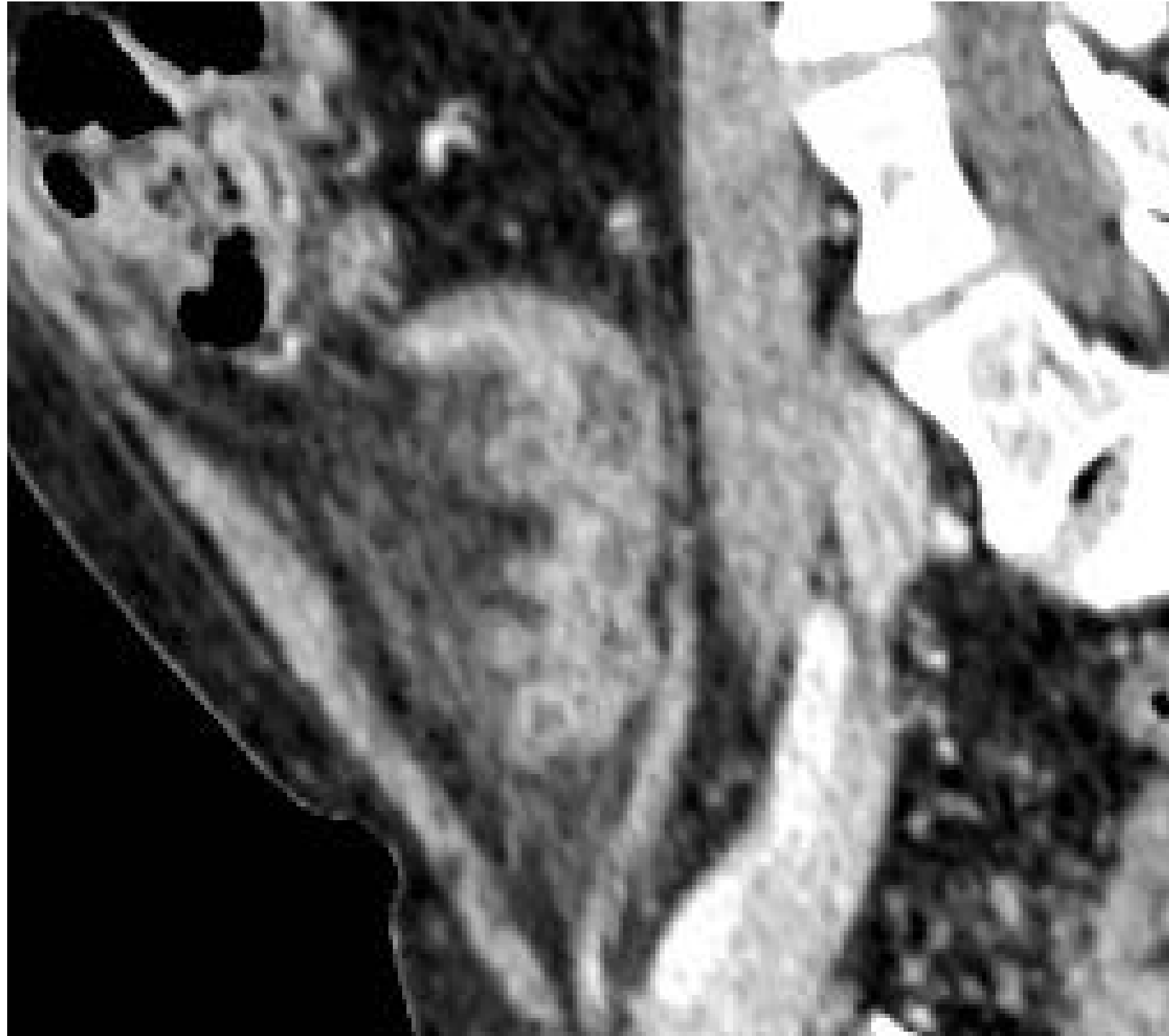




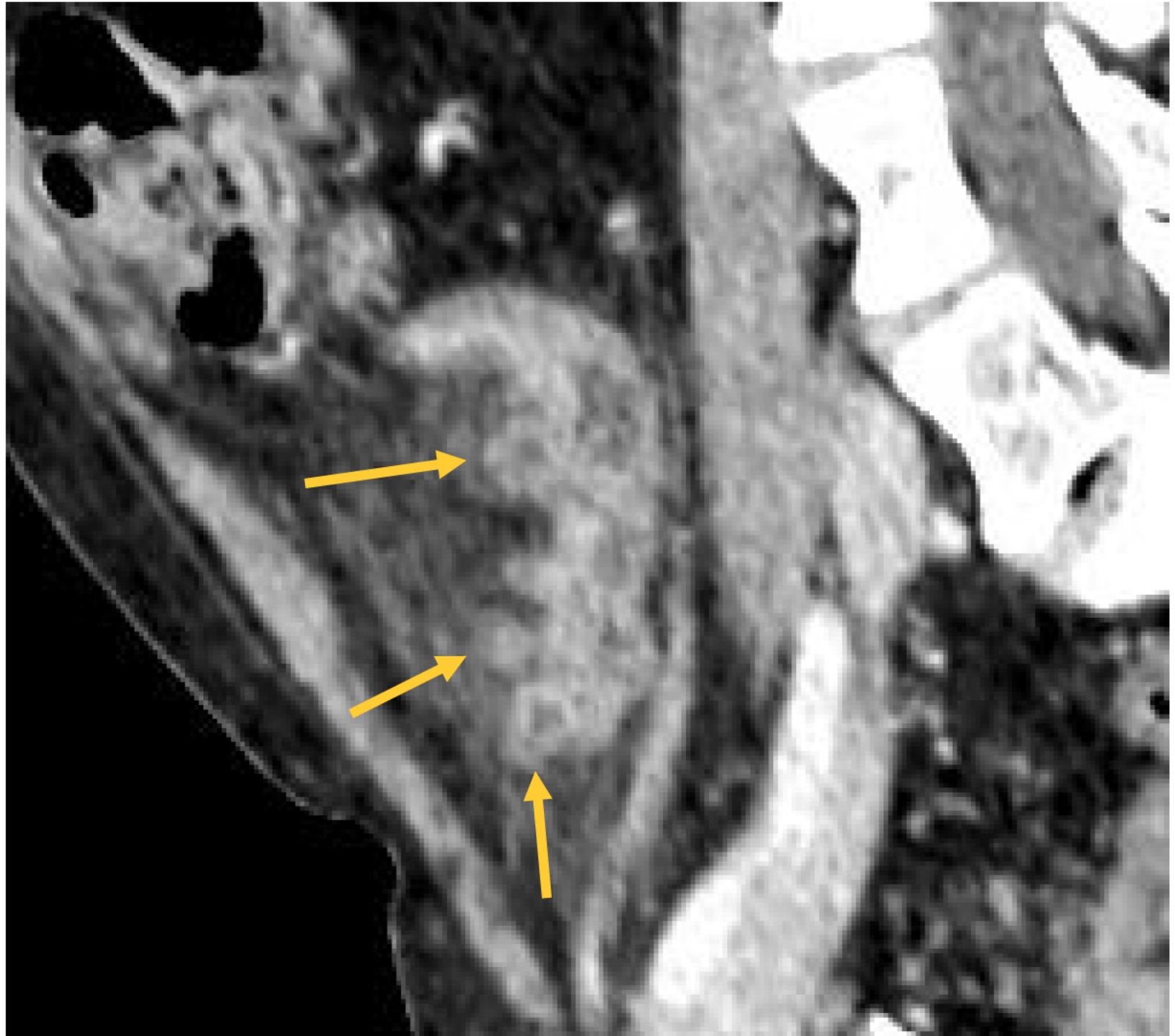


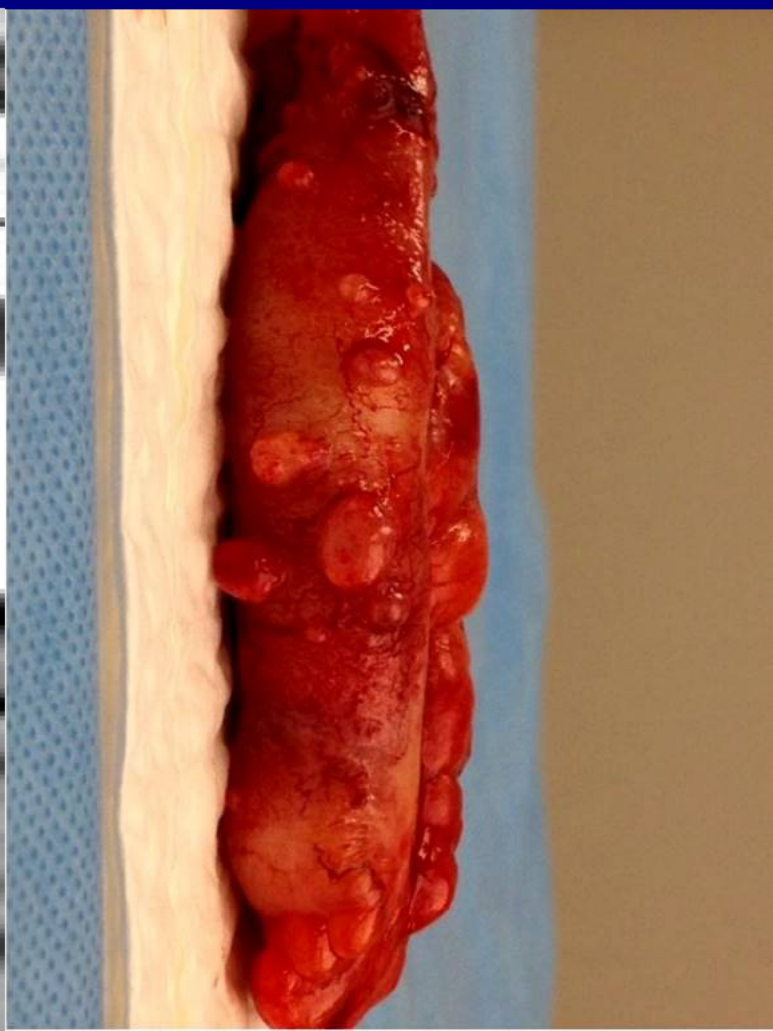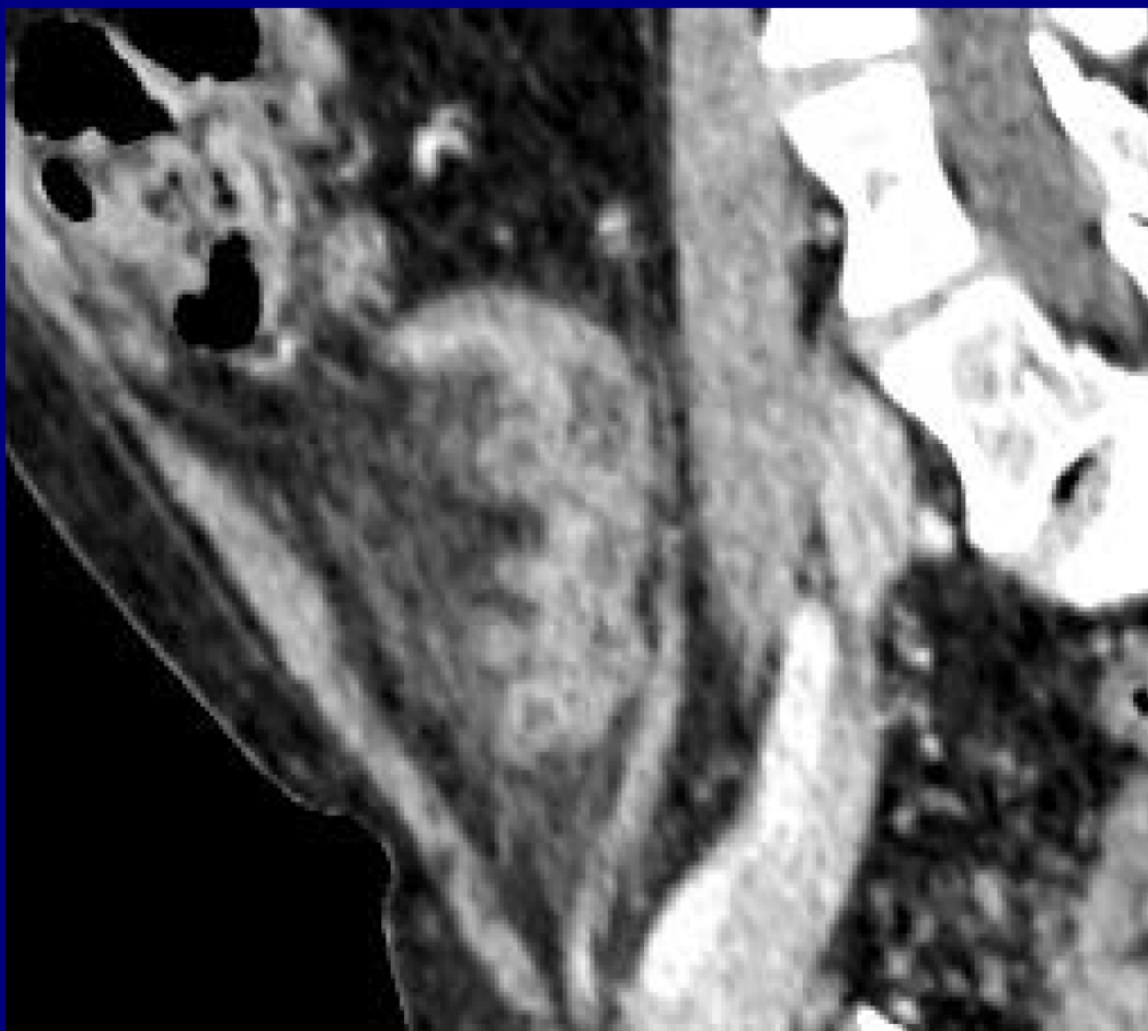


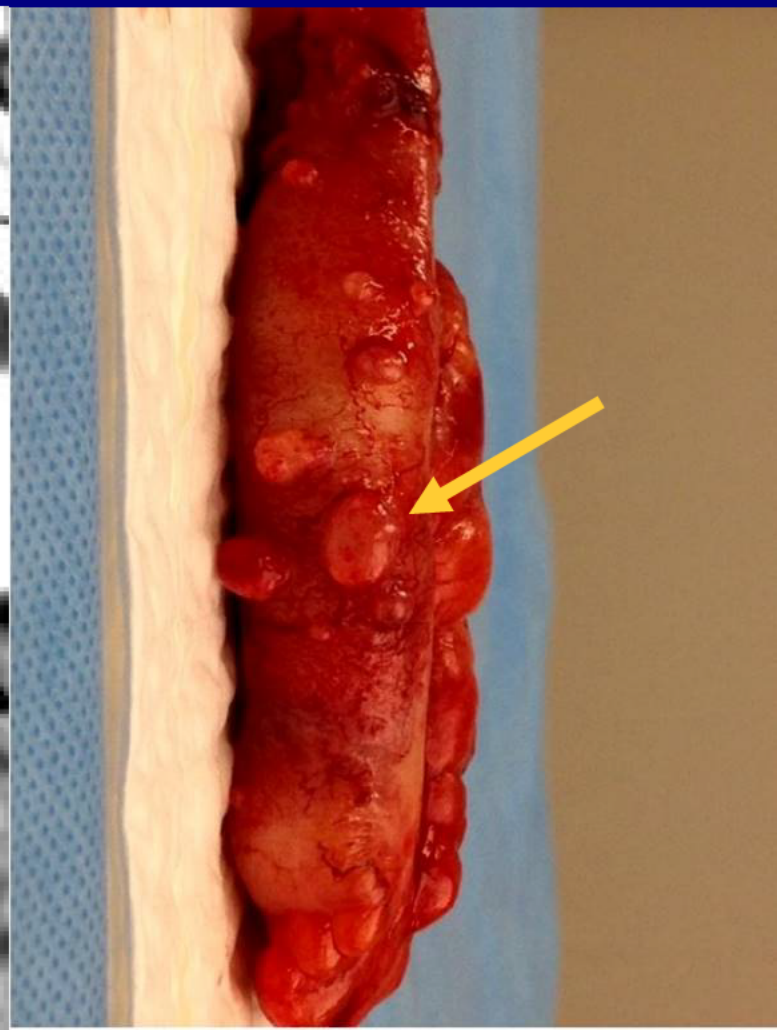
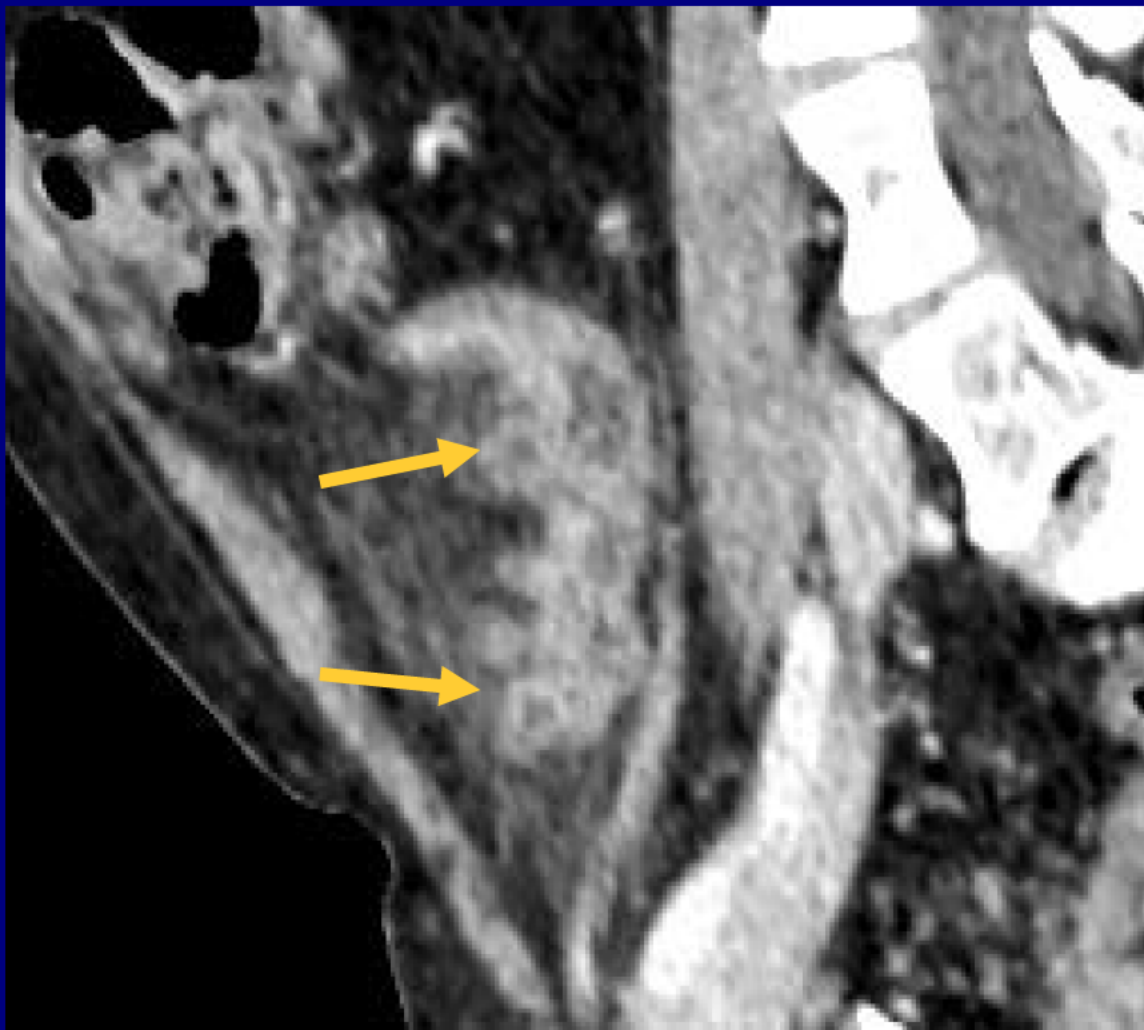




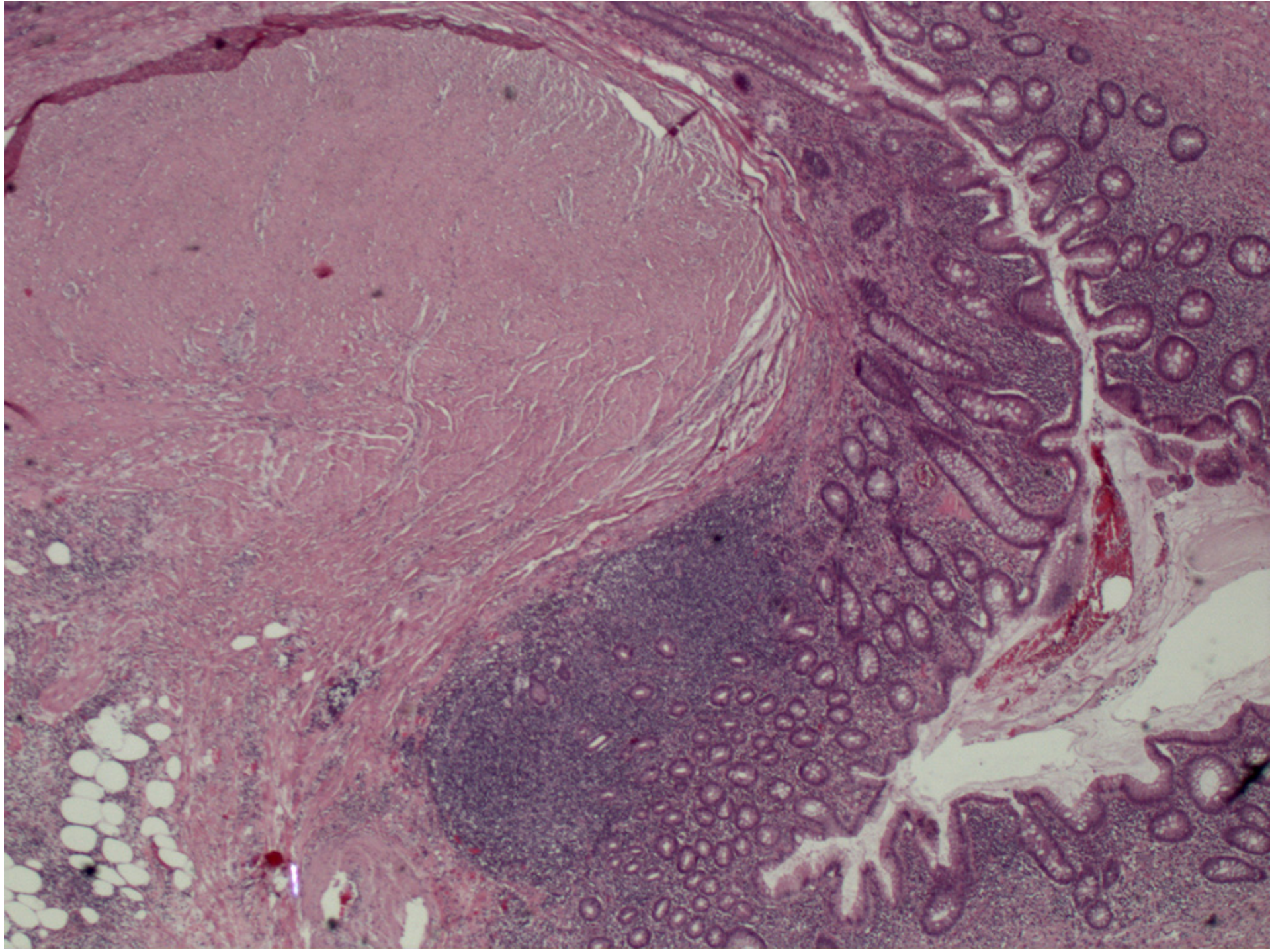




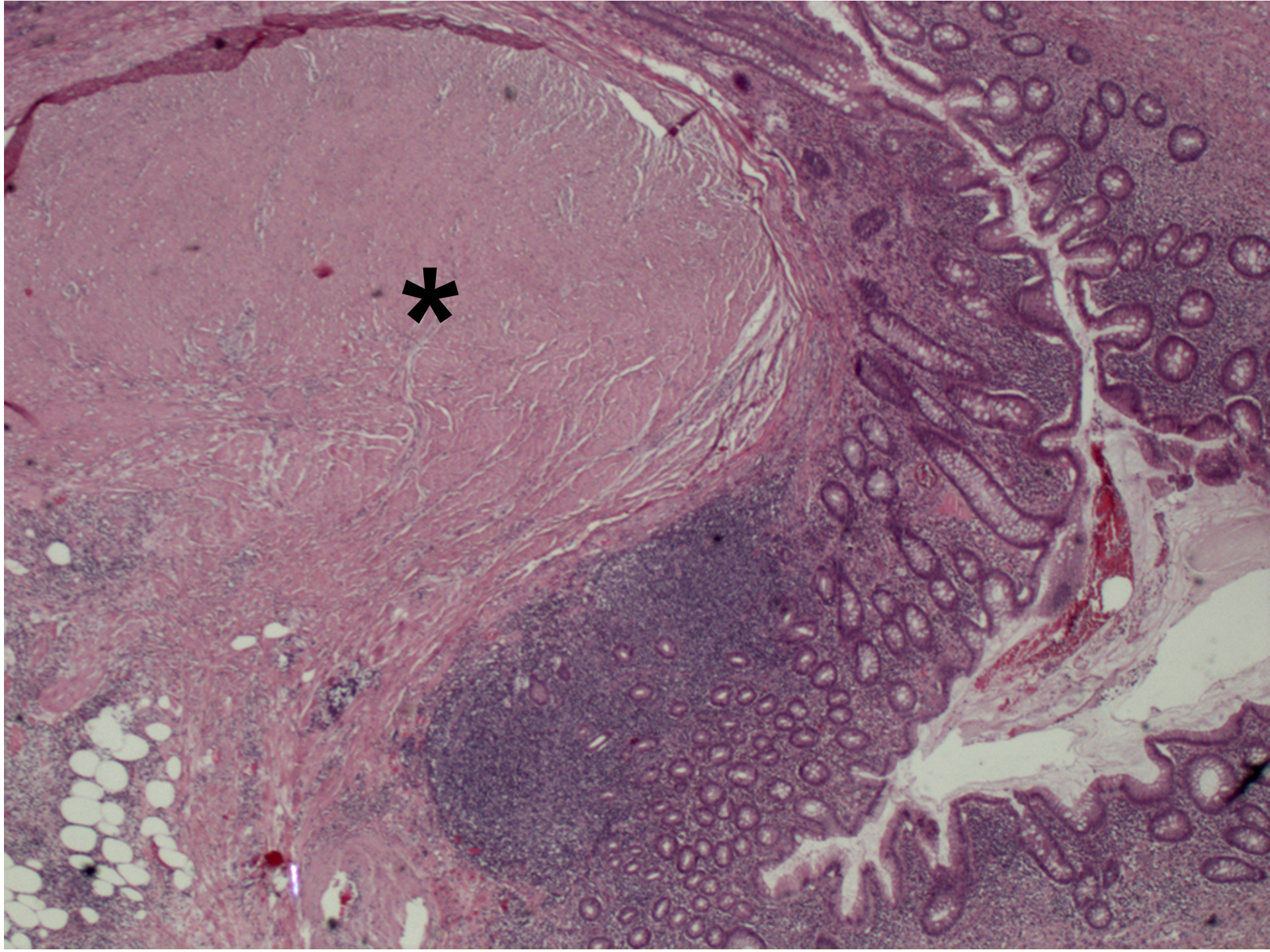




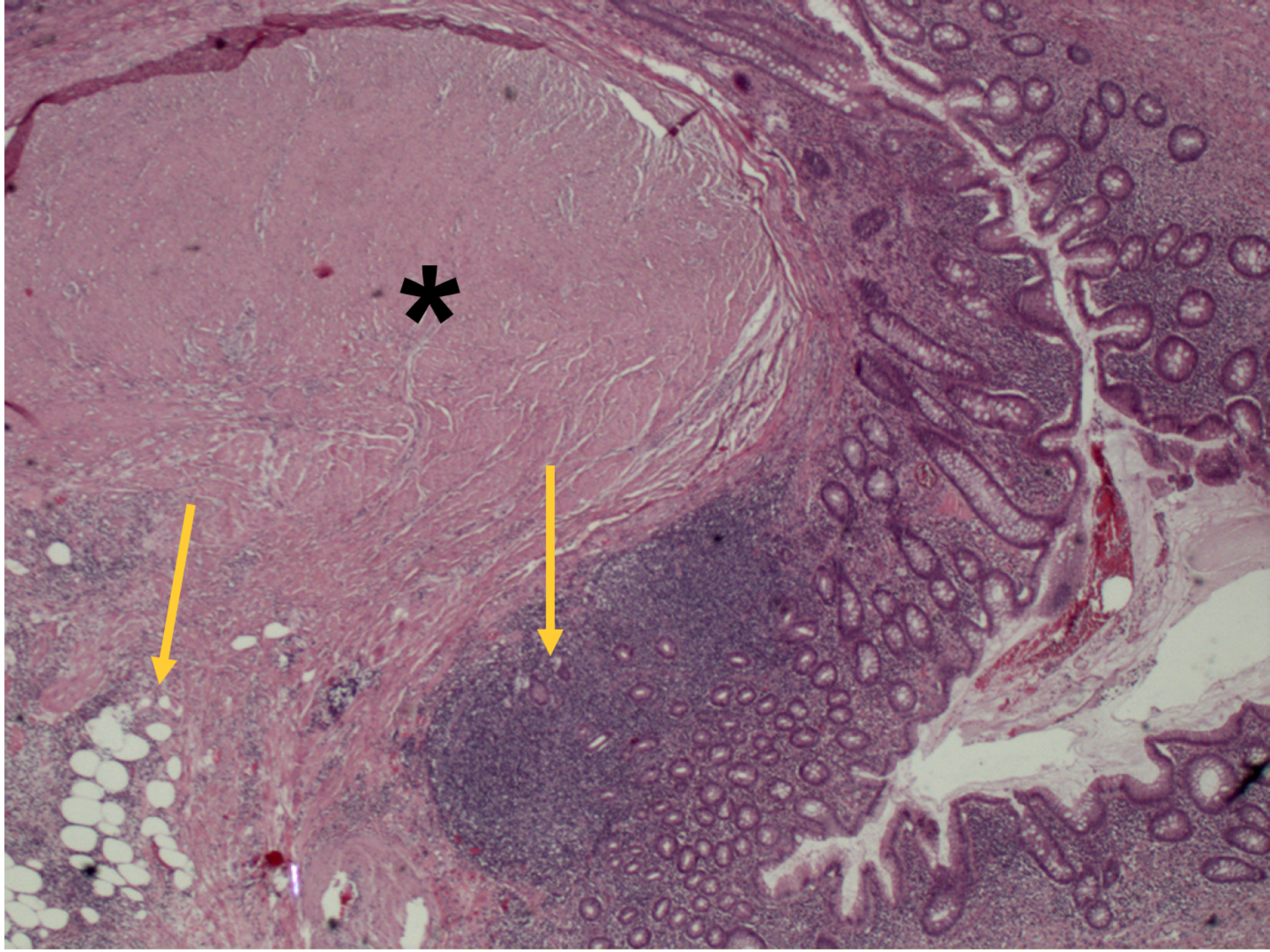












# Appendiceal Diverticulitis

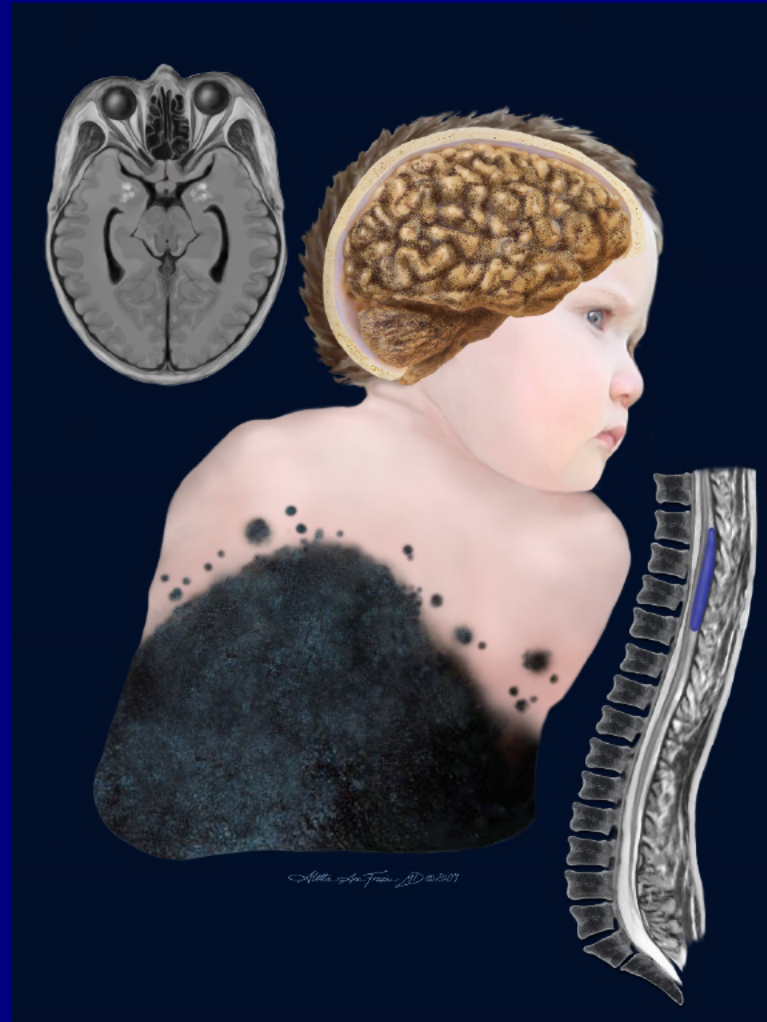**Marielle Kuijper, M.D.**

**Kennemer Gasthuis**

**Haarlem, Noord-Holland, Netherlands**



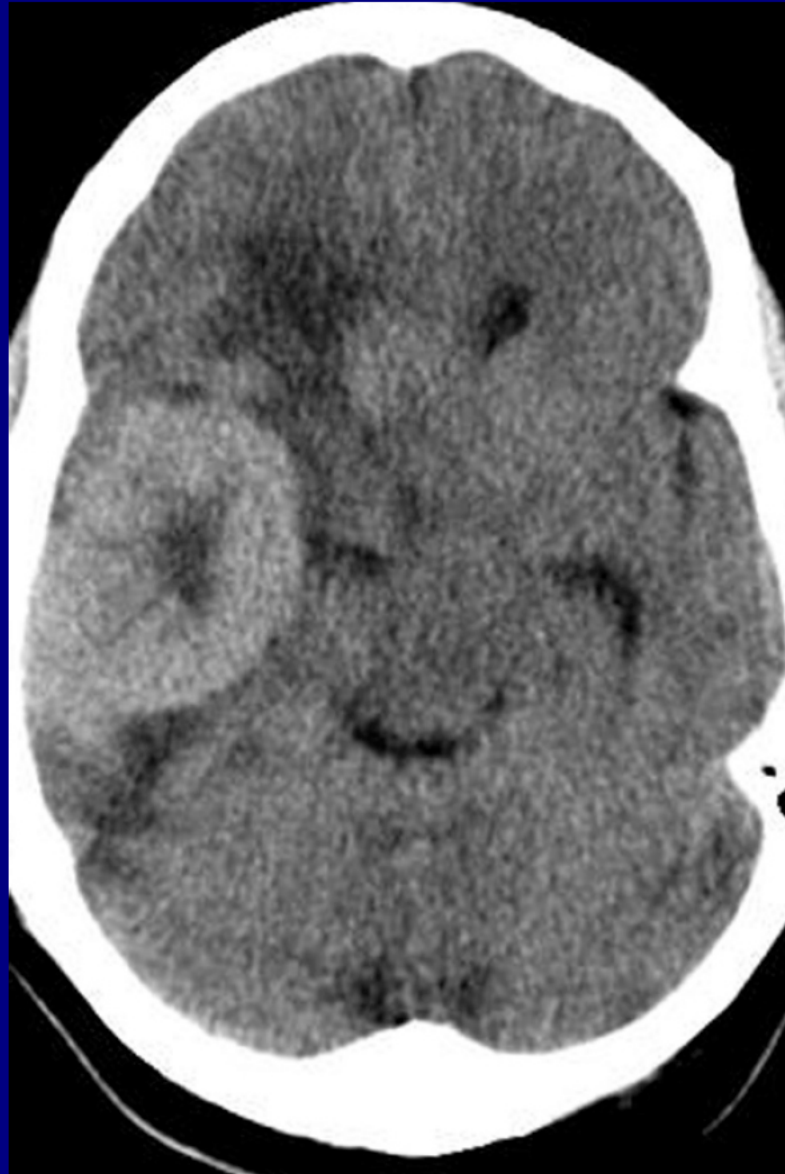
# Neuroradiology Best Case

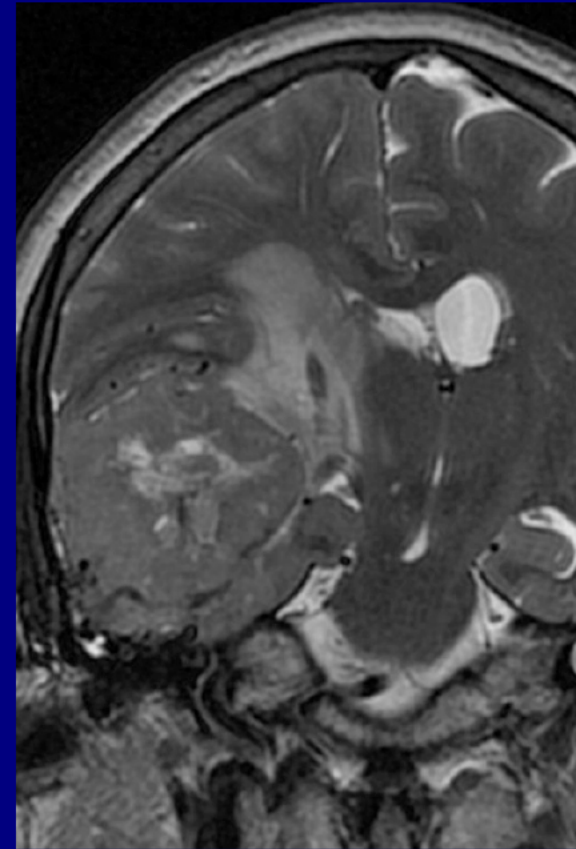
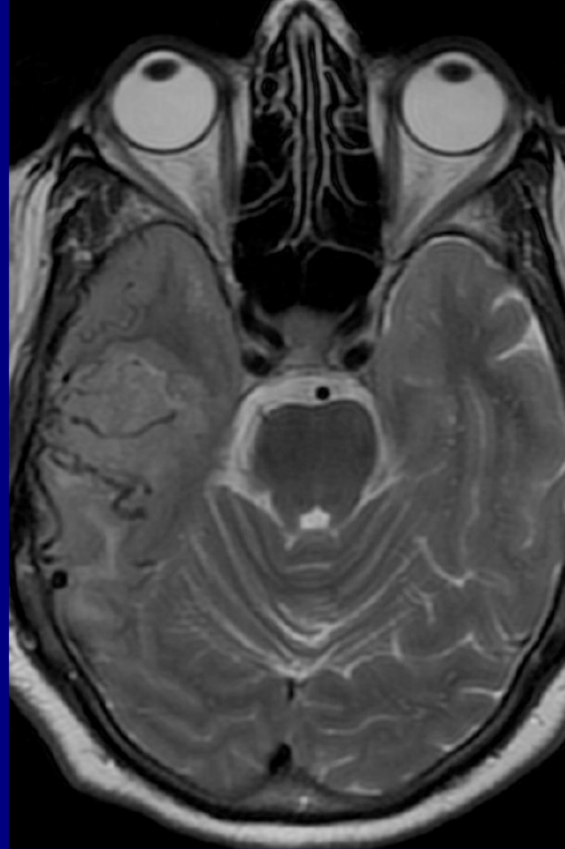
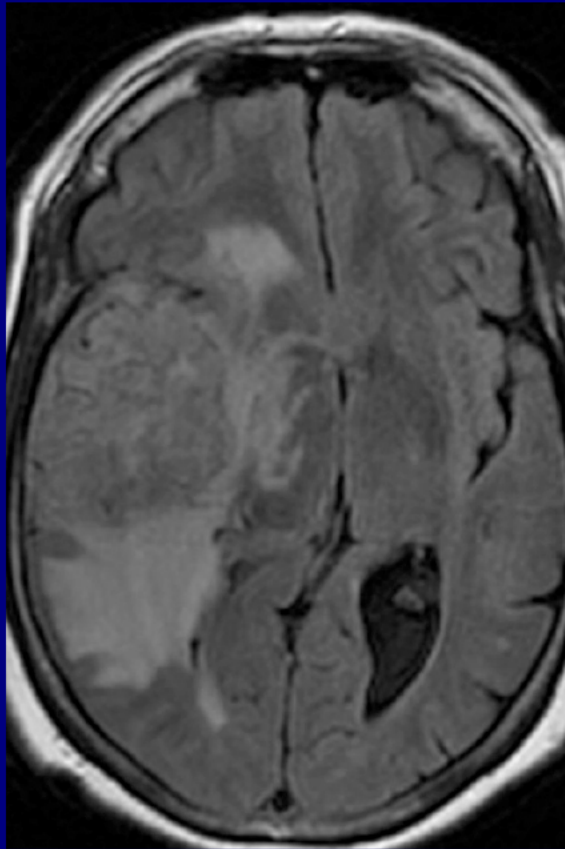




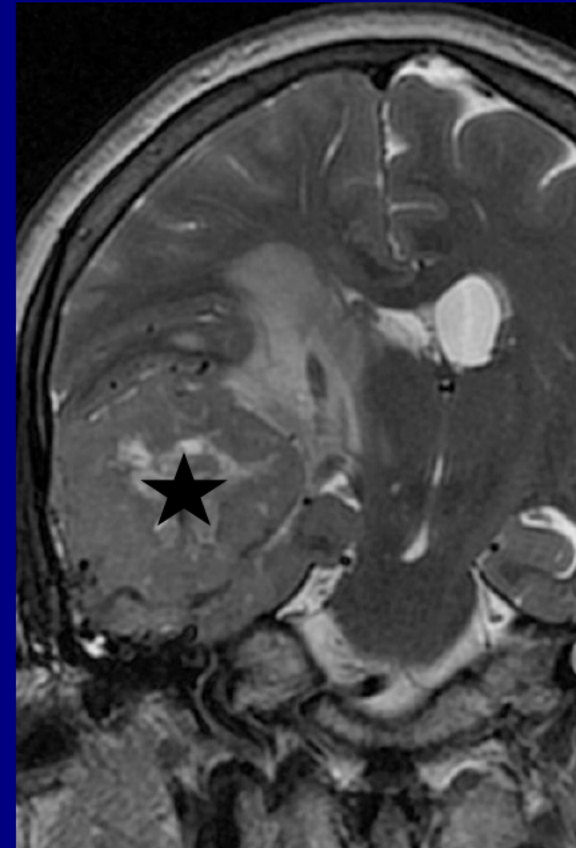
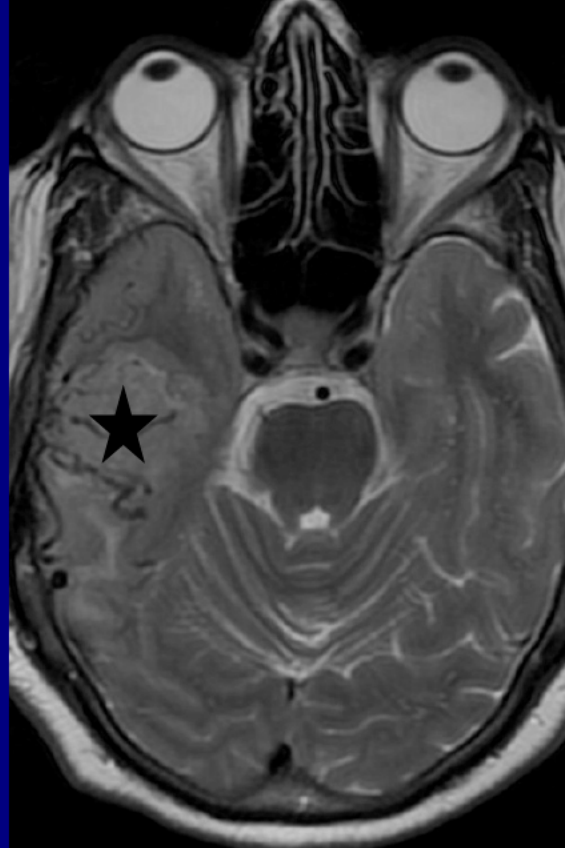
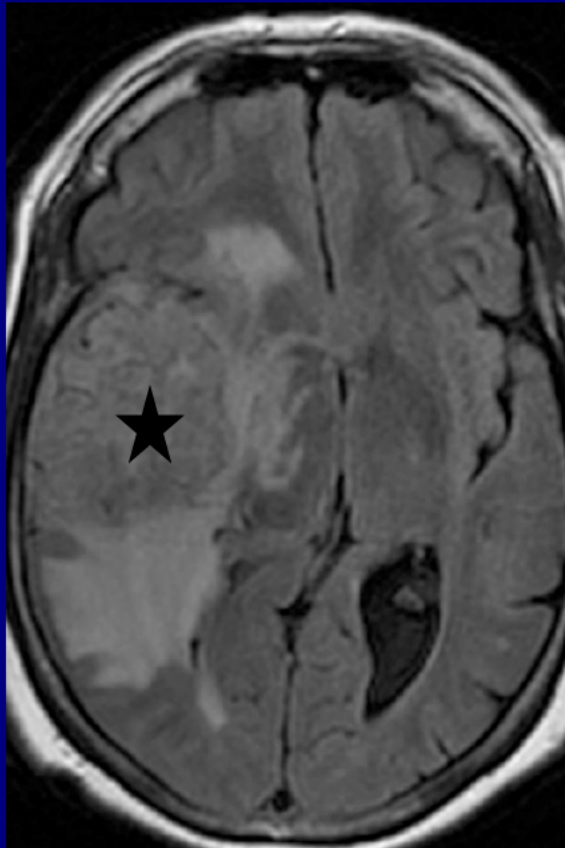
# **65-year-old female with hemi-cranial headache and progressive forgetfulness**

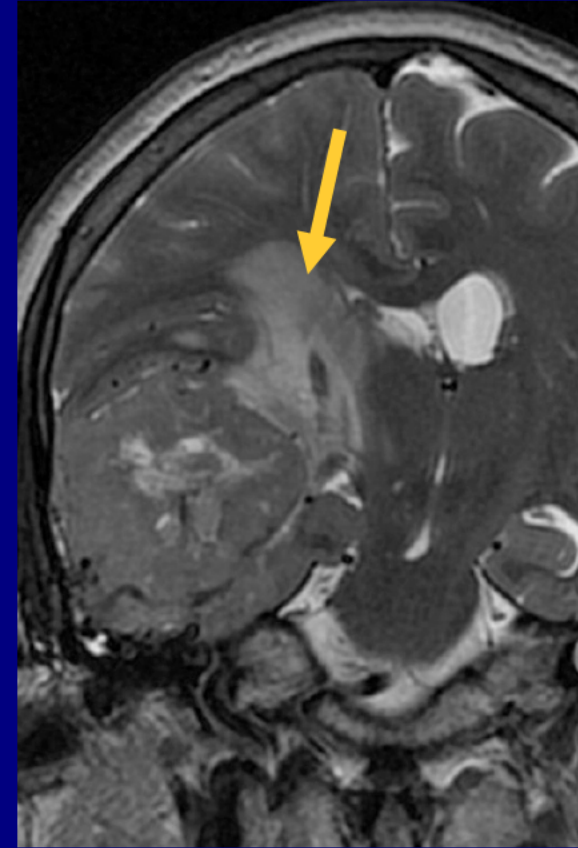
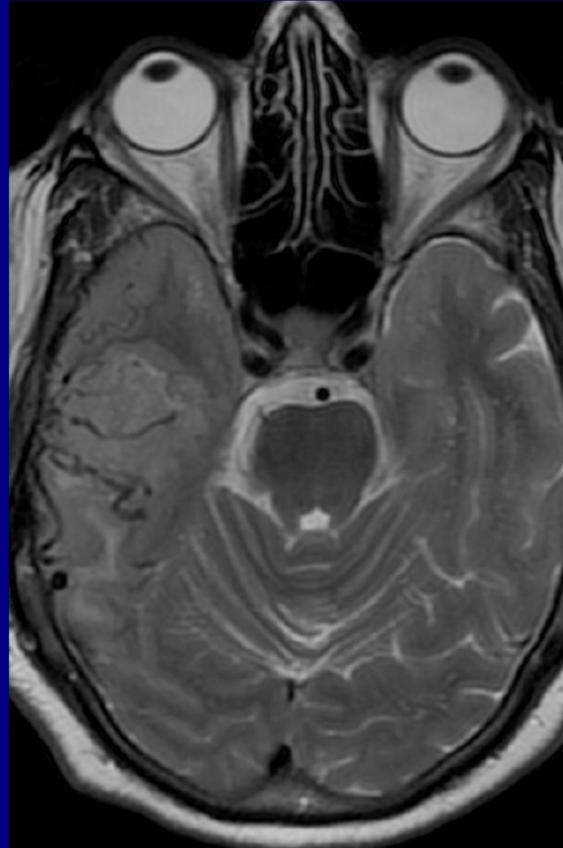
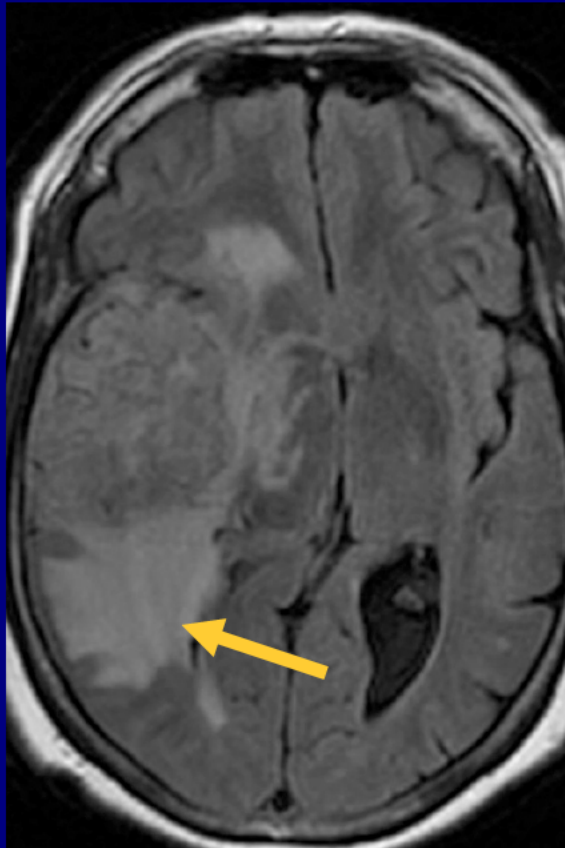
# Noncontrast CT

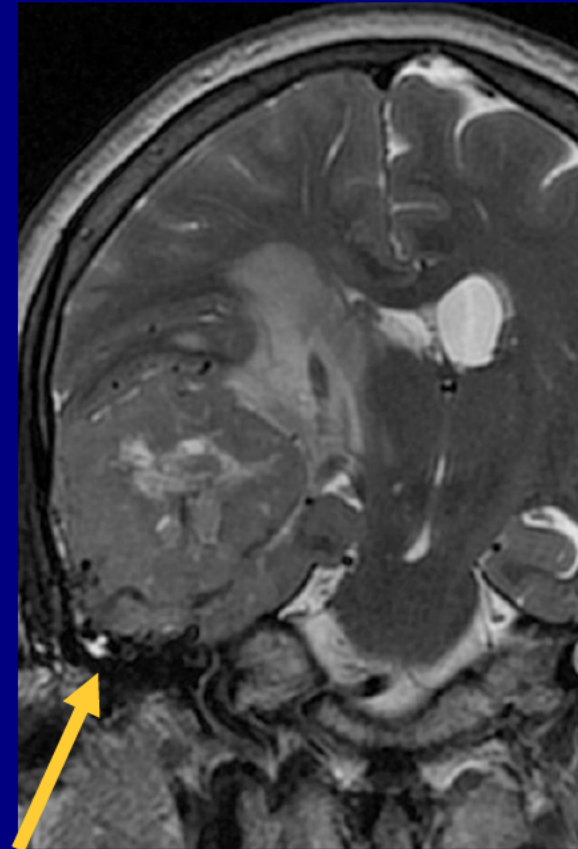
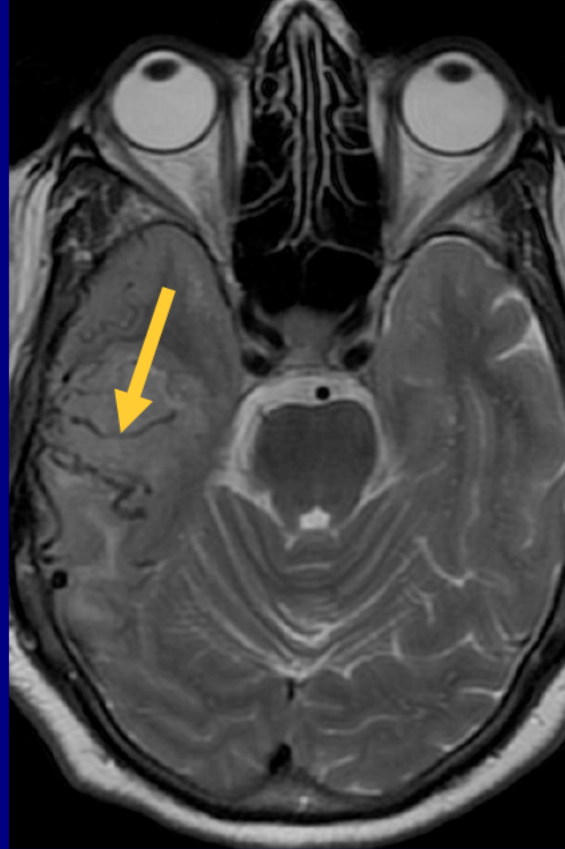
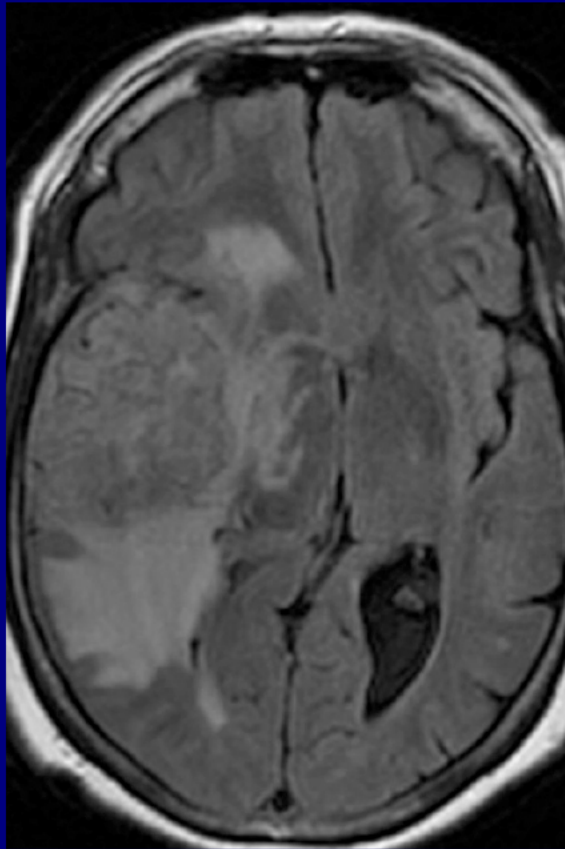




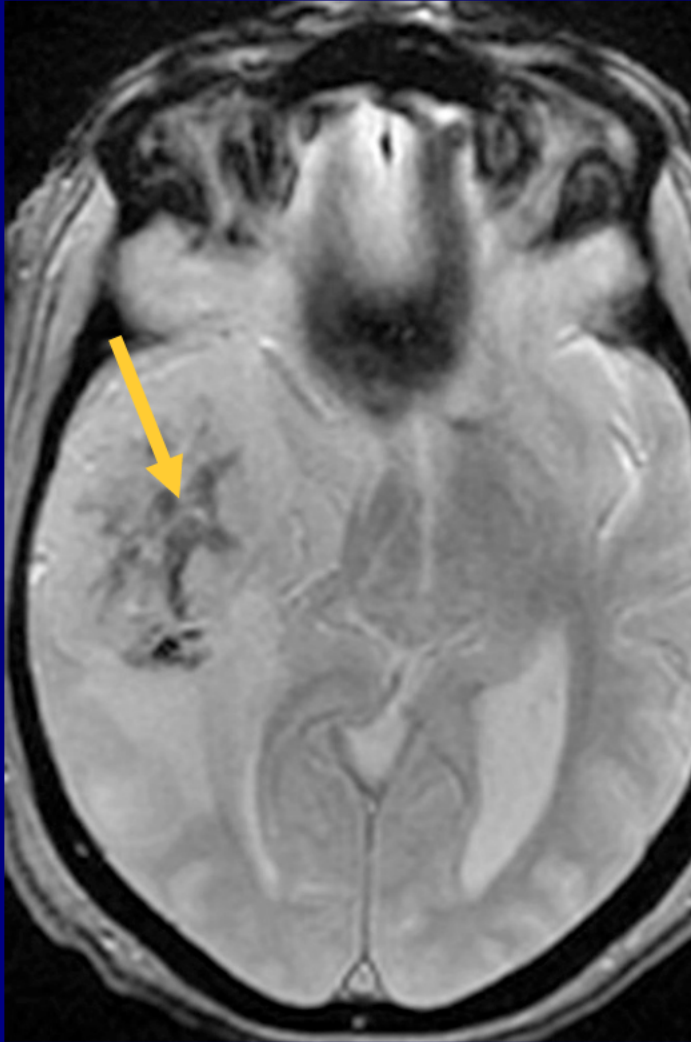




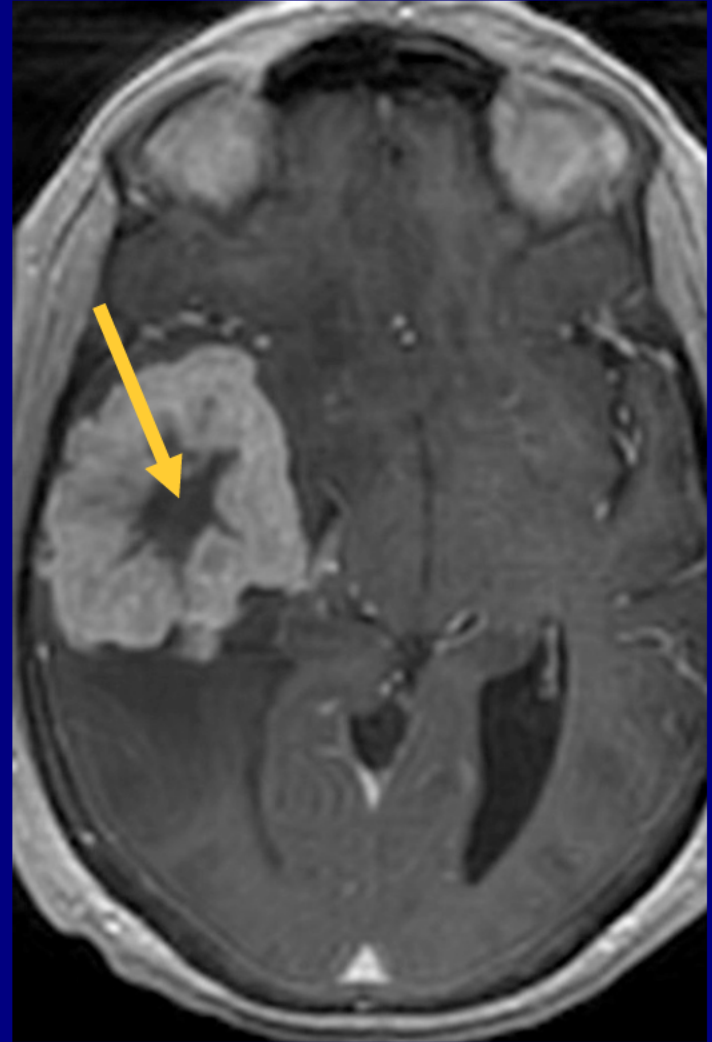




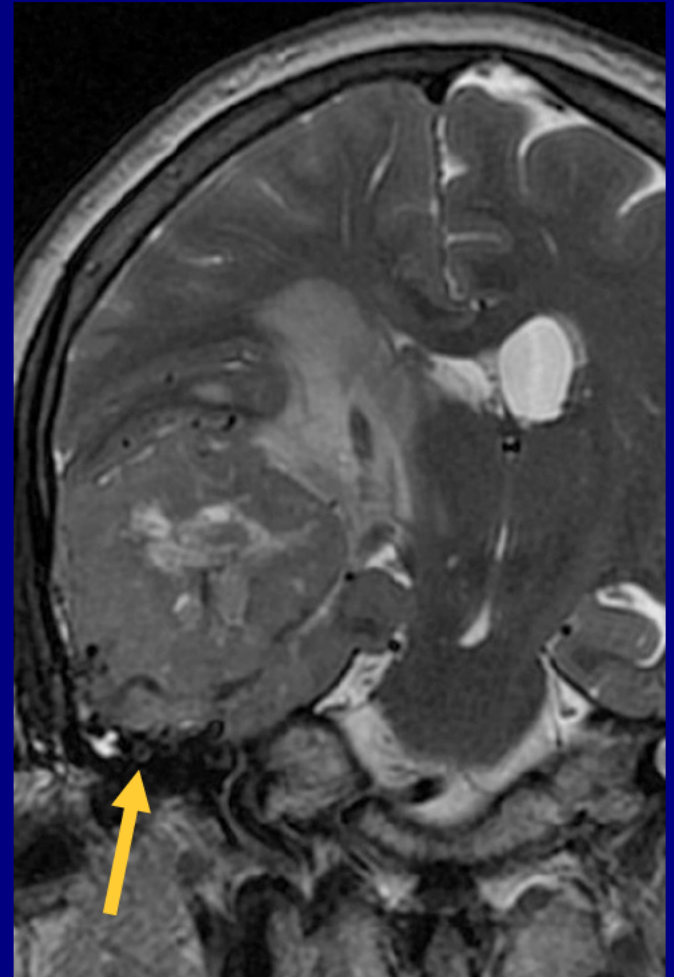
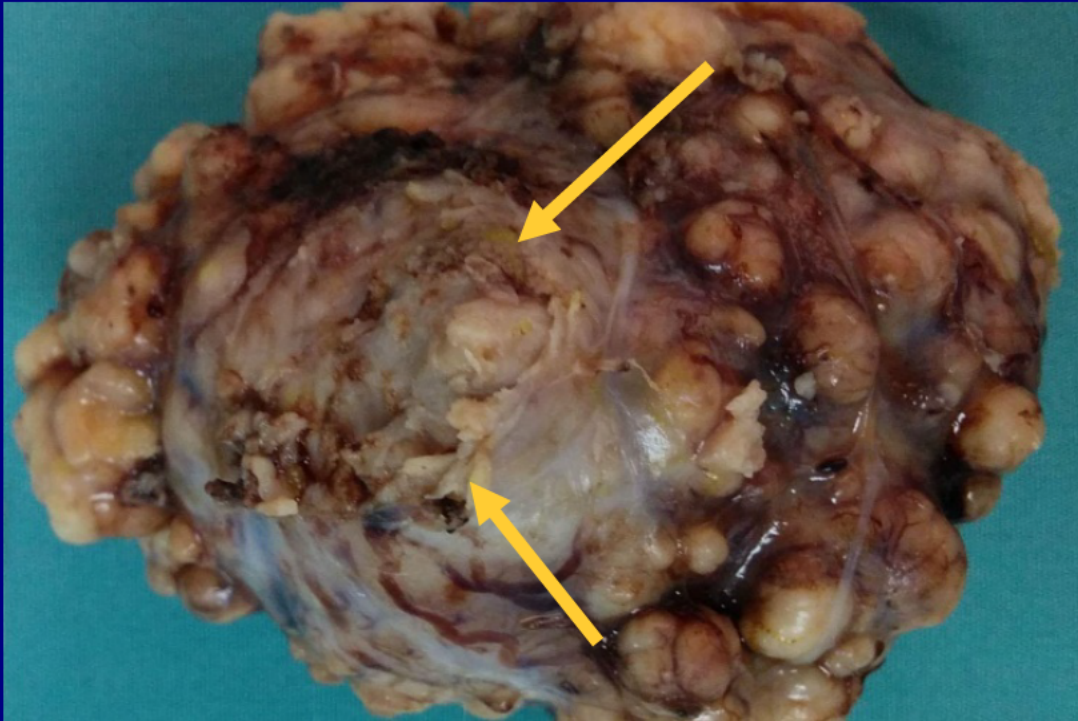


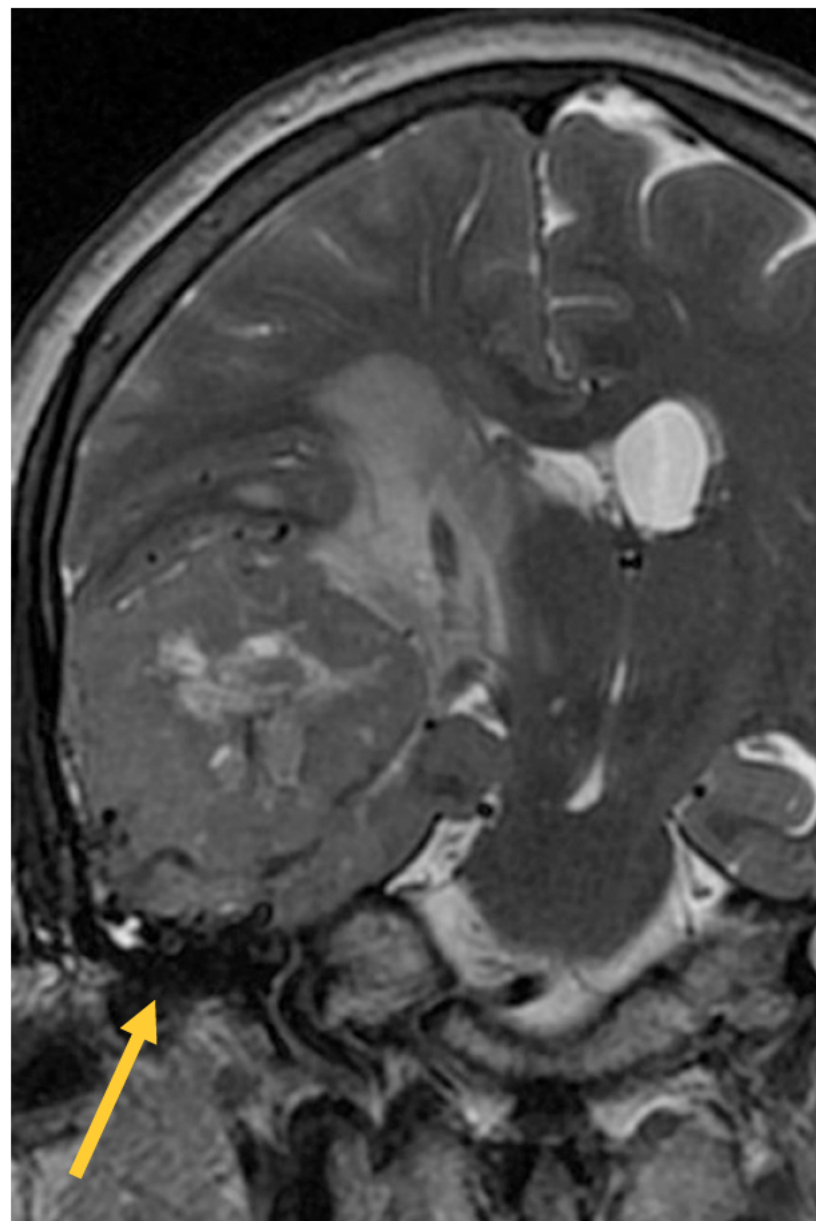
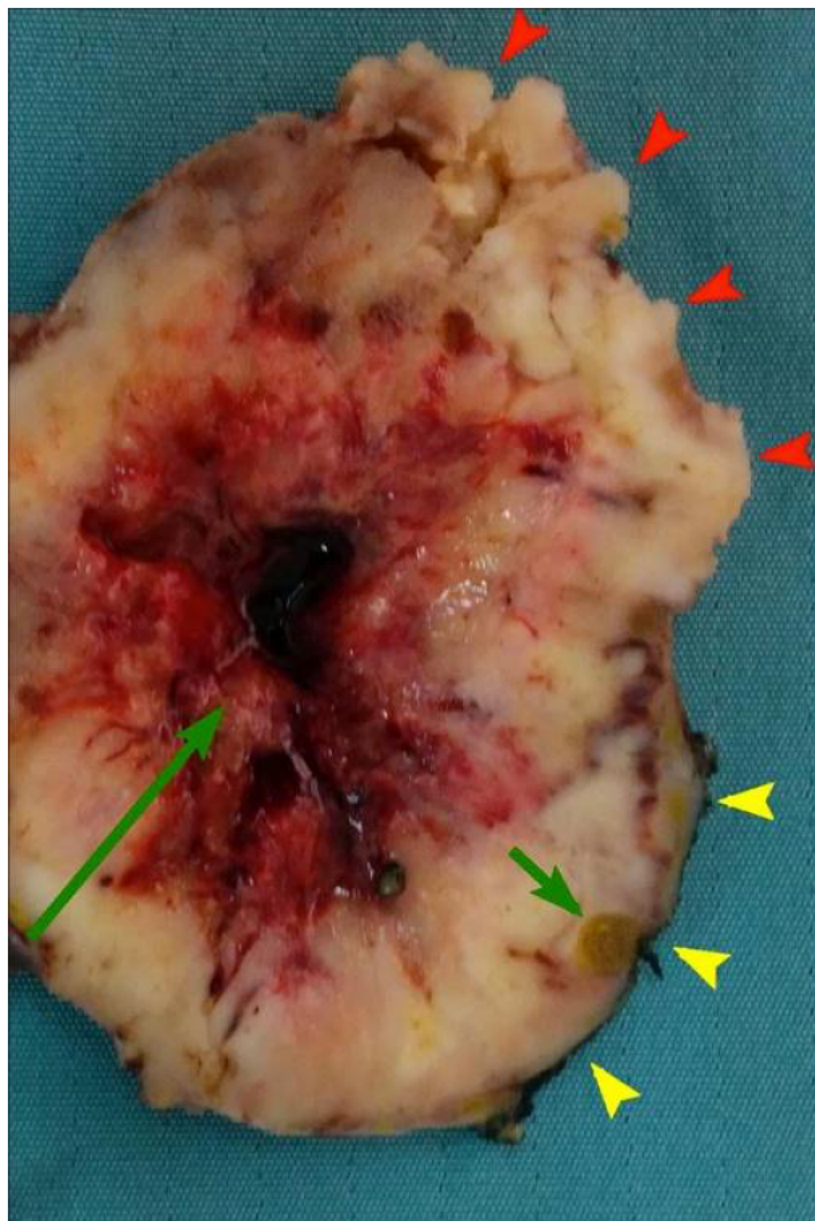


**GRE**

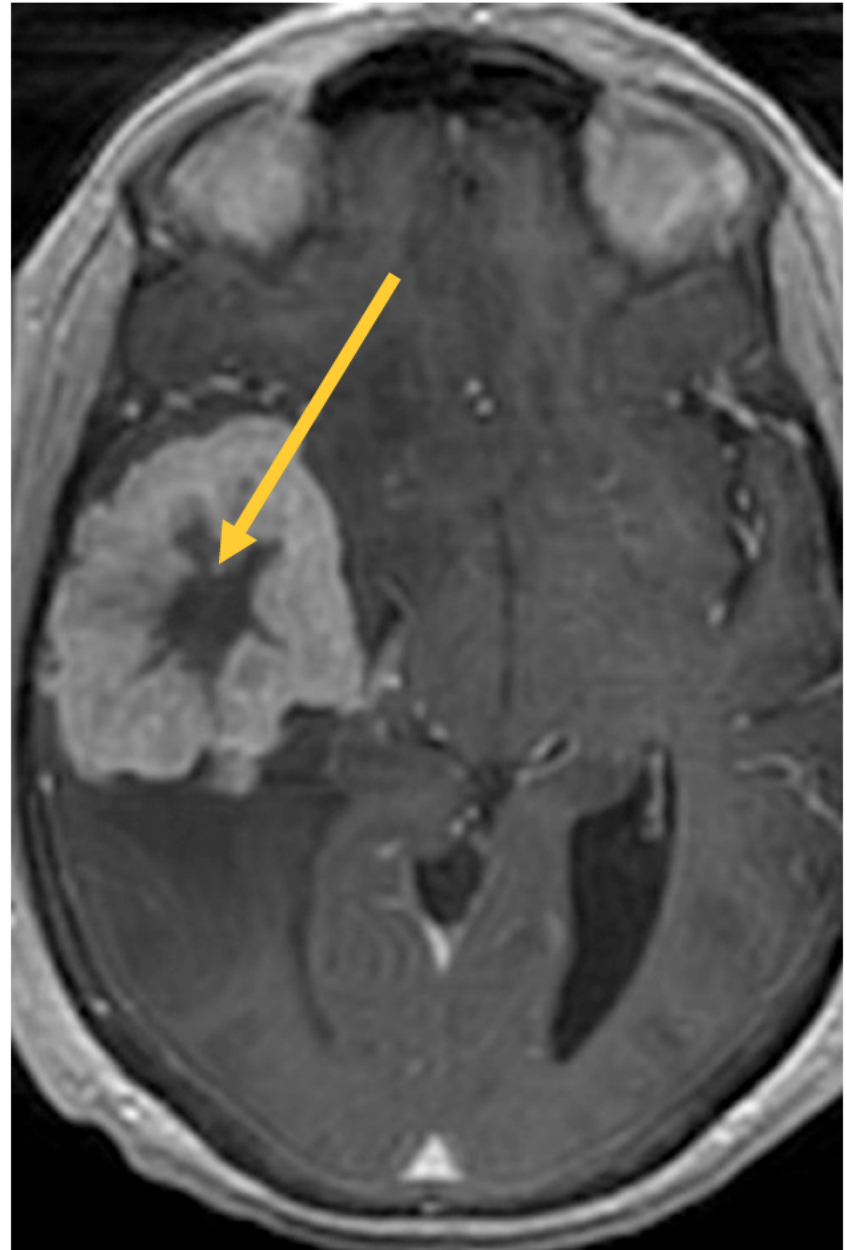
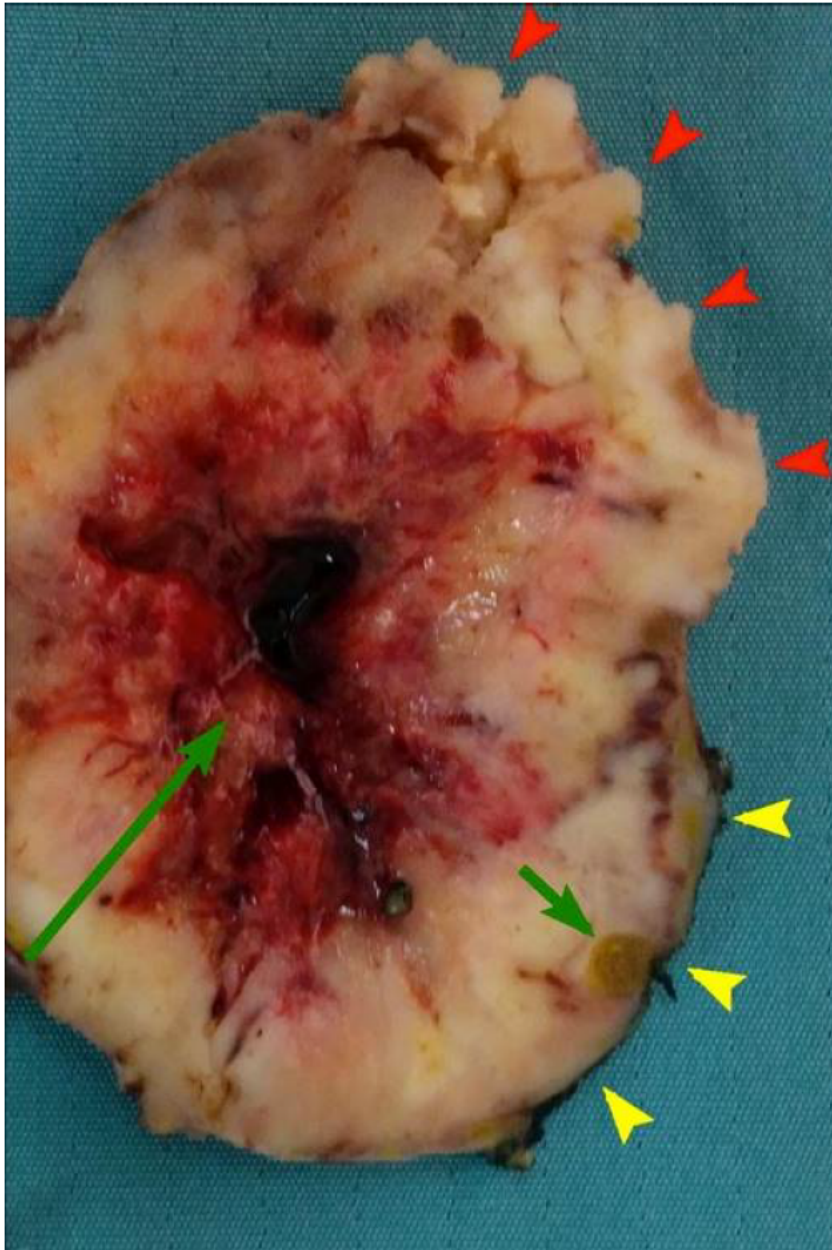


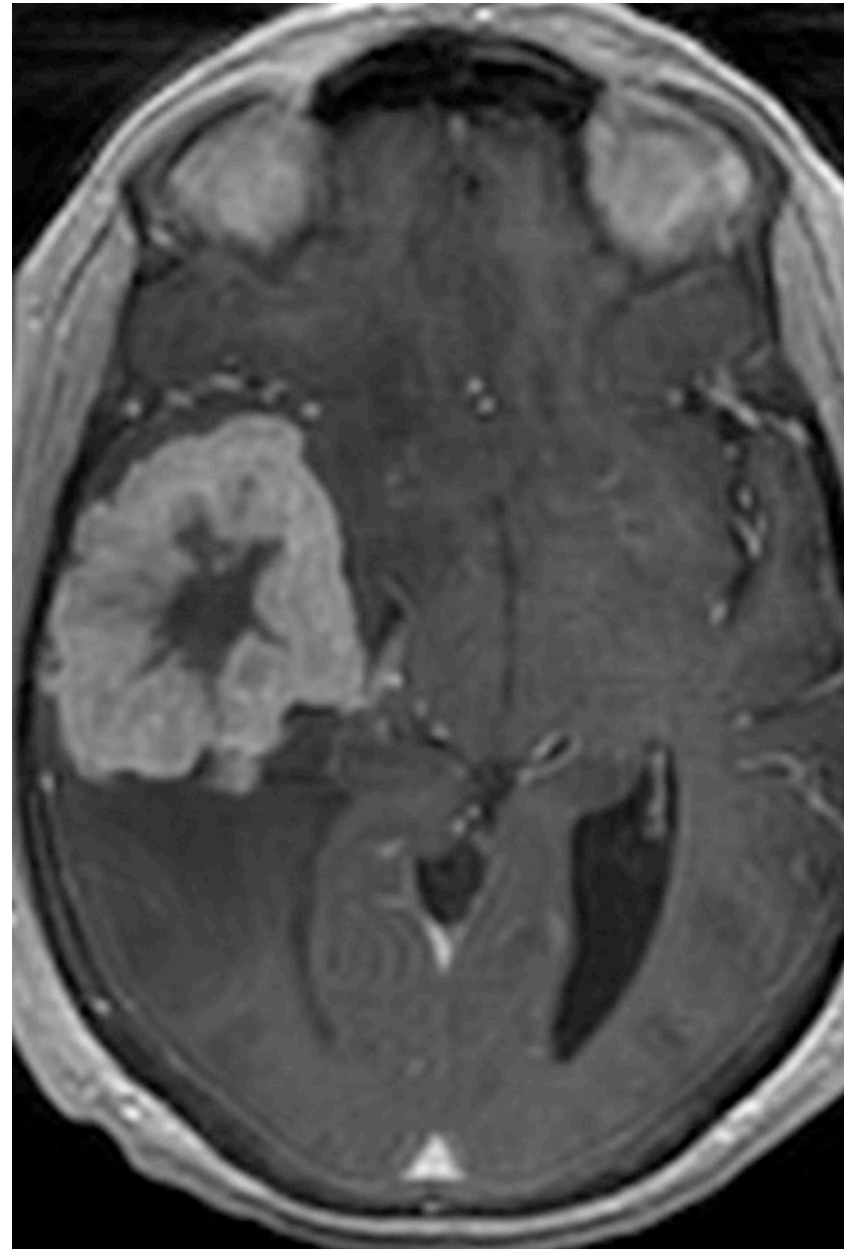
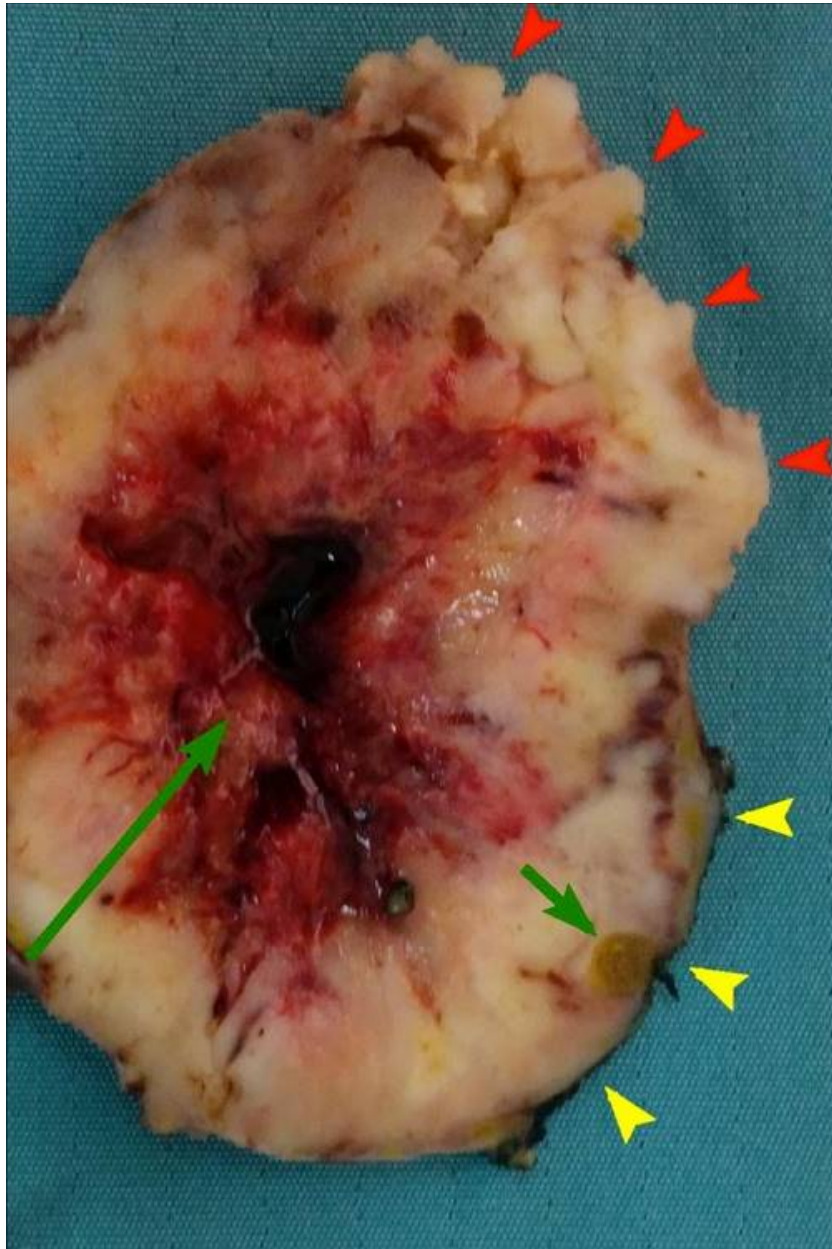
**Post contrast**











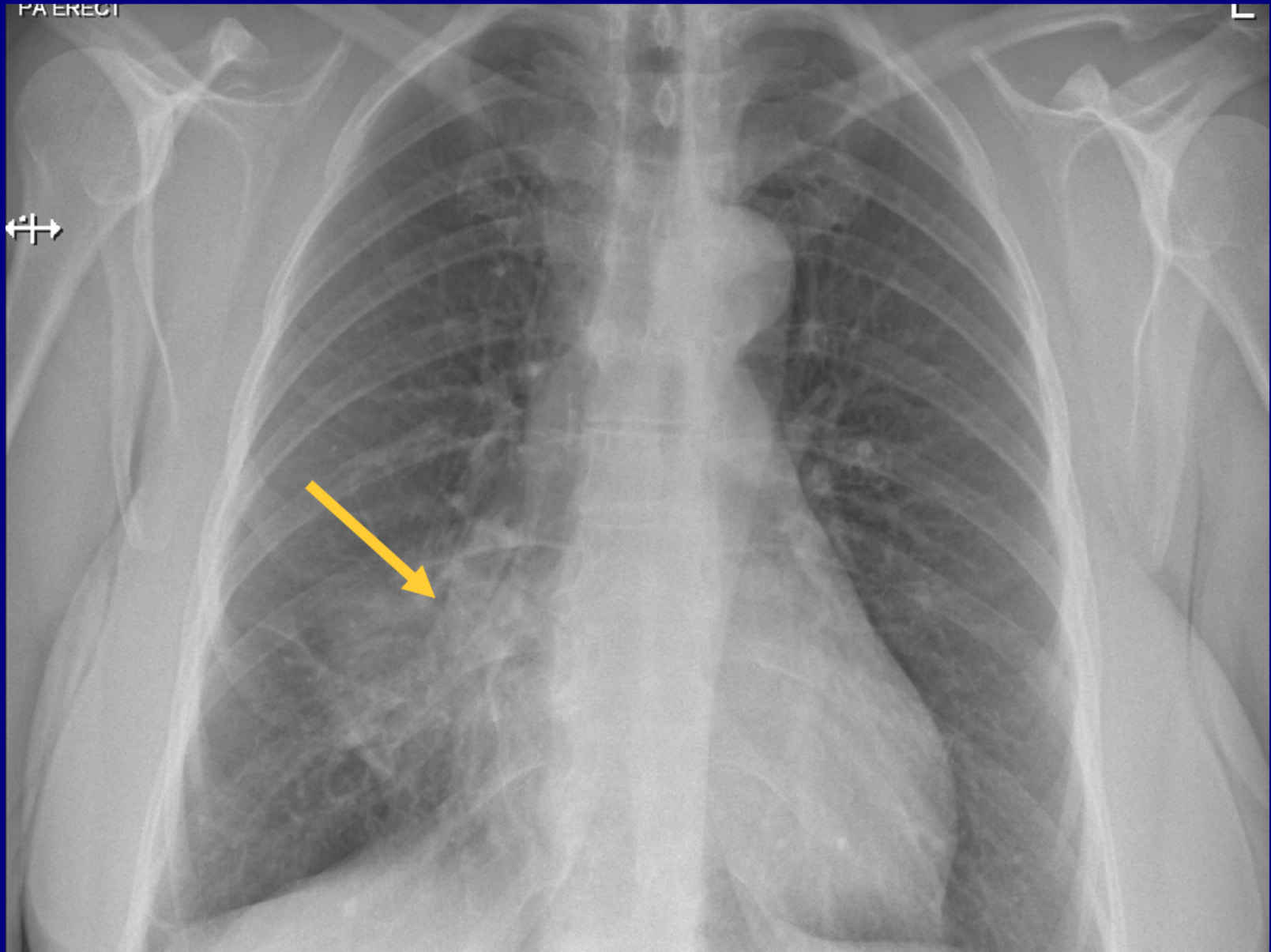
# Hemangiopericytoma

**Antonio Lorenzo Gorriz , M.D.**  
**Hospital General Universitario de**  
**Castellon**  
**Castellon, Spain**



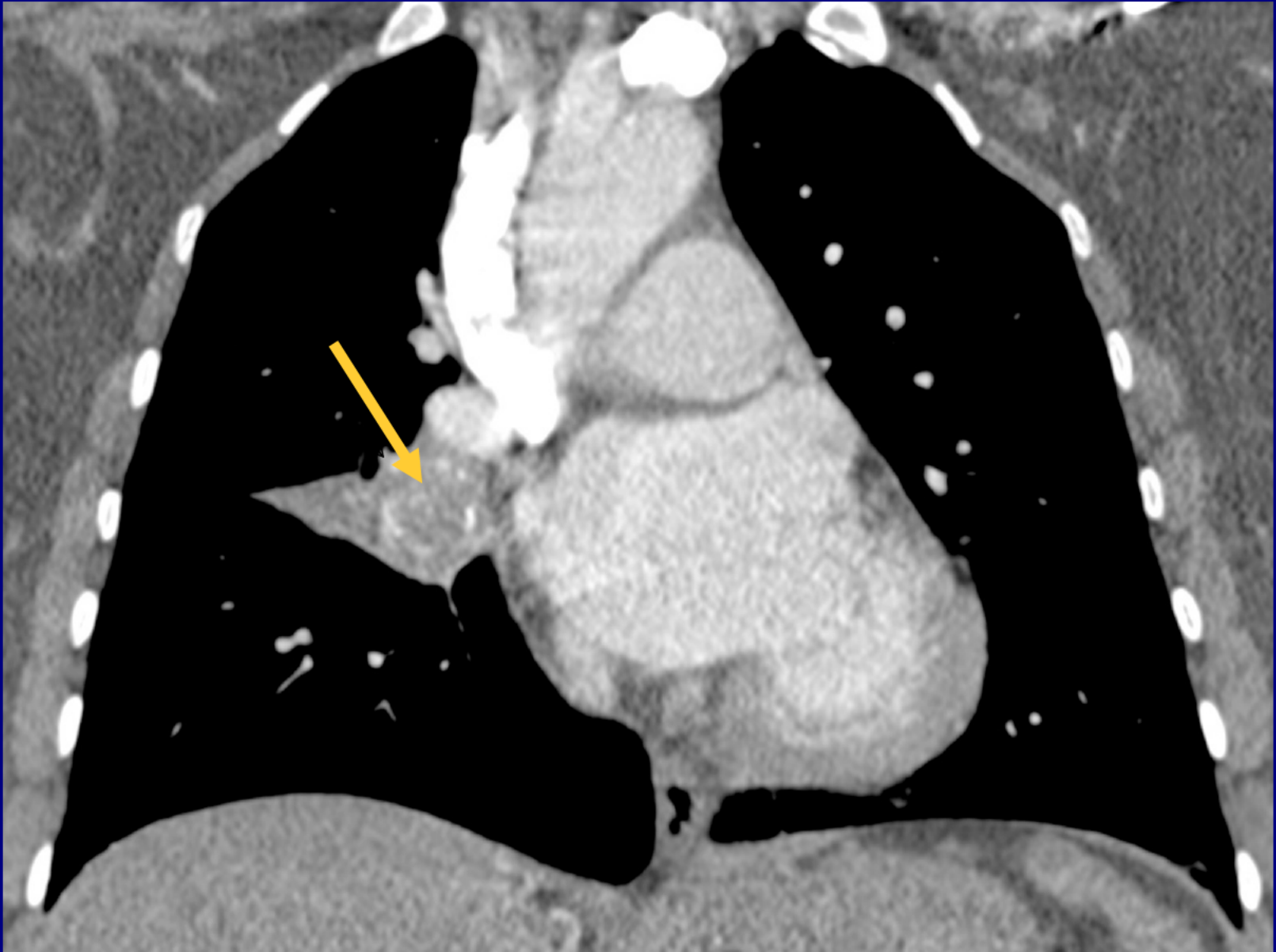


**78 year old female non smoker  
with a history of a cough**

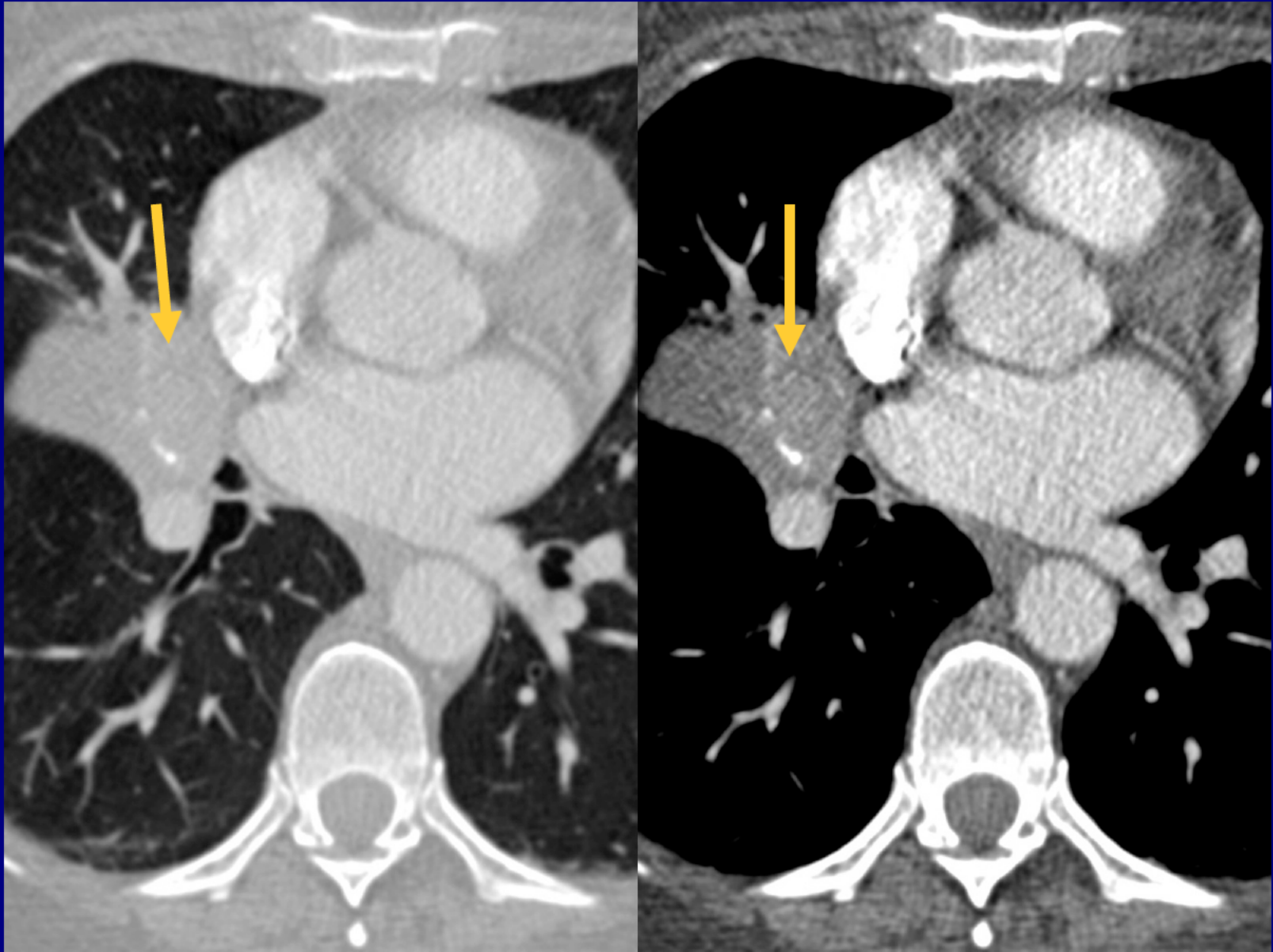


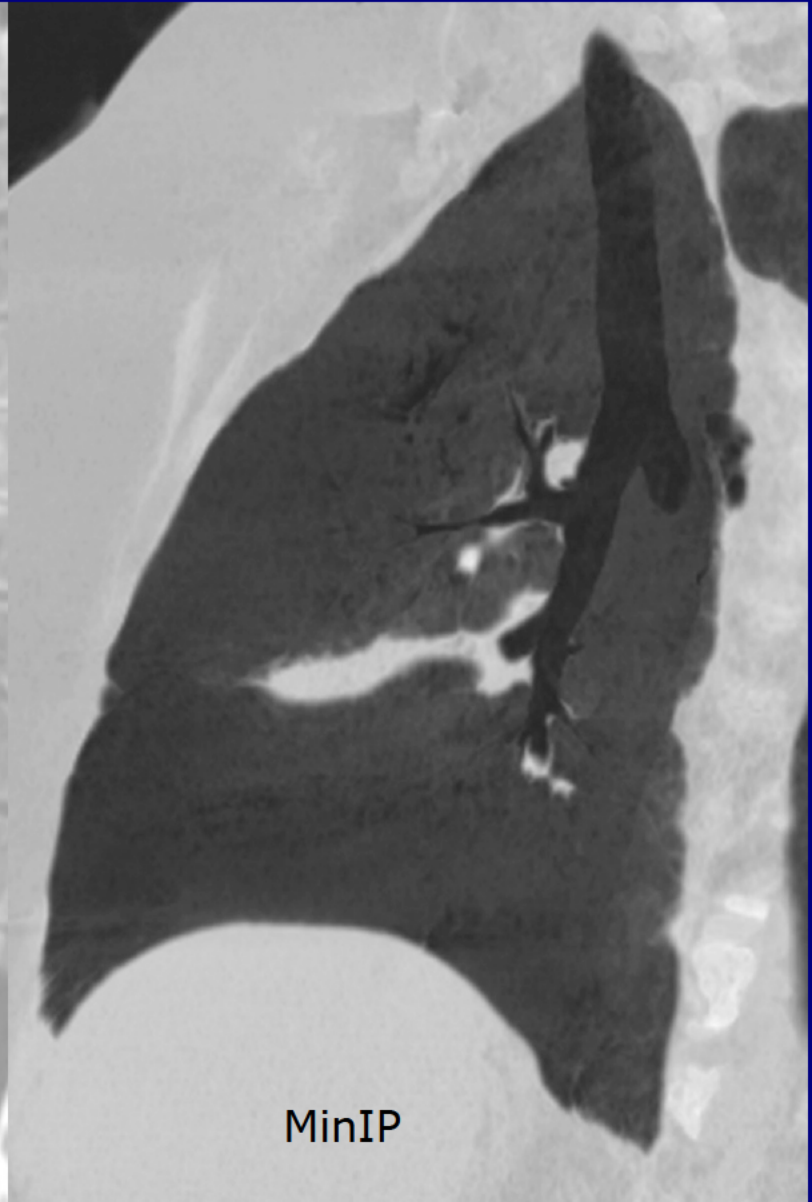
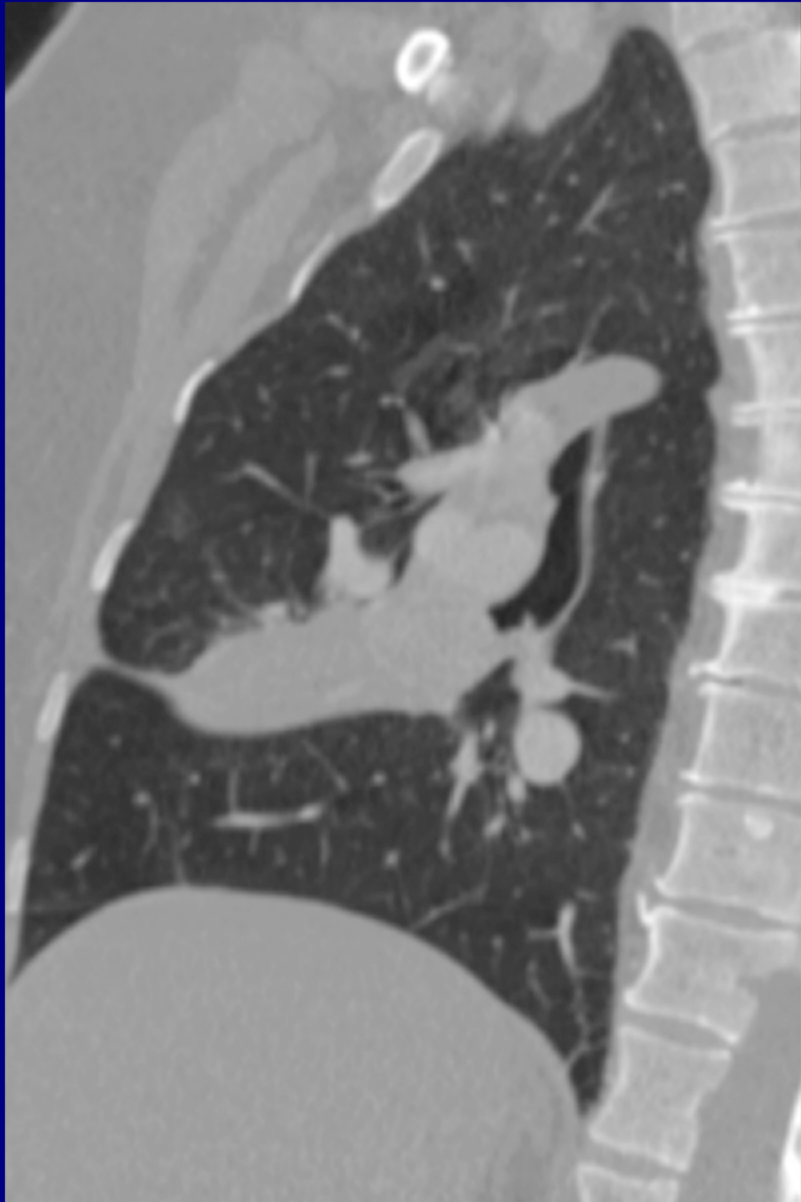

# Mass in the right hilum

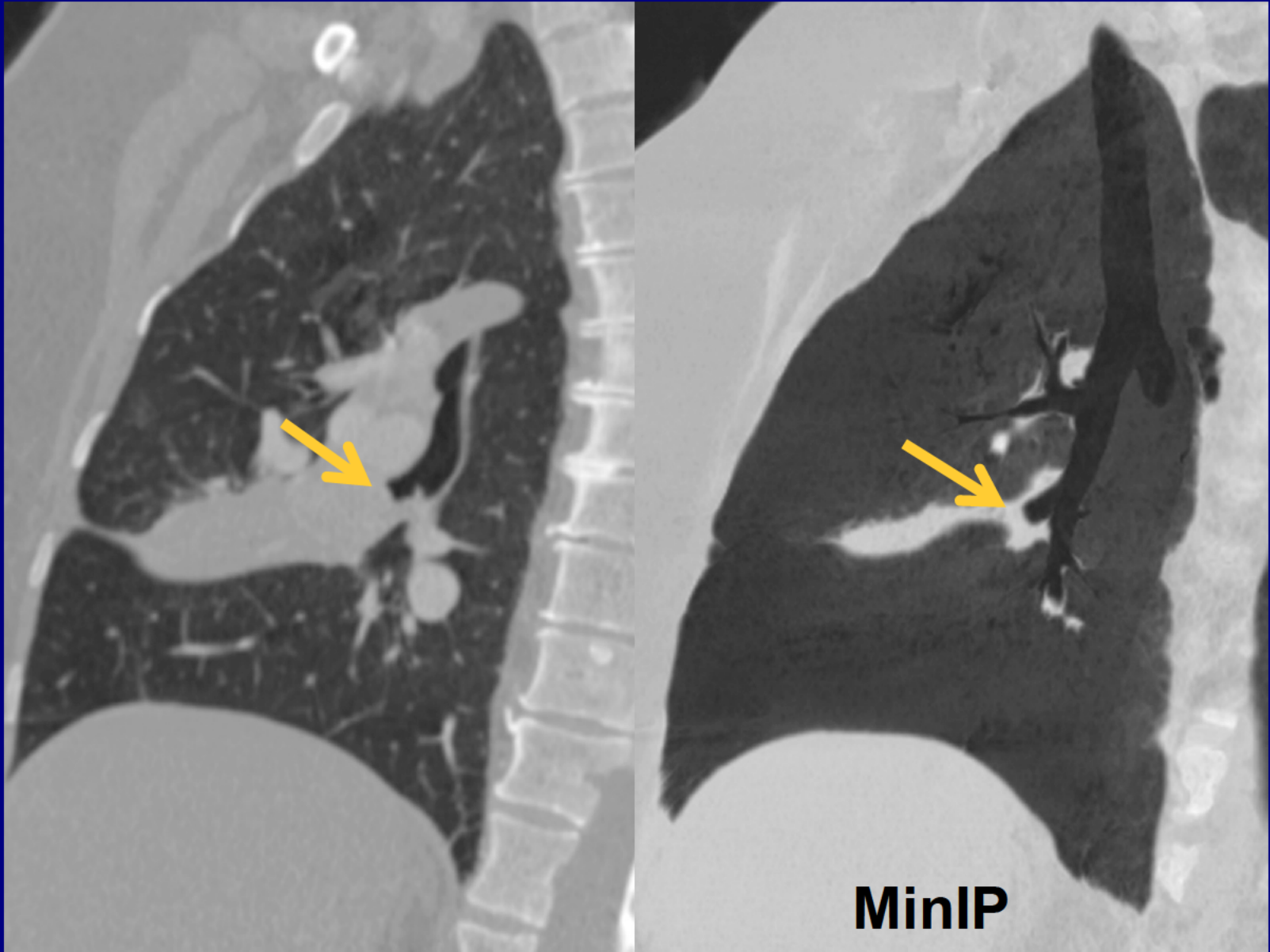


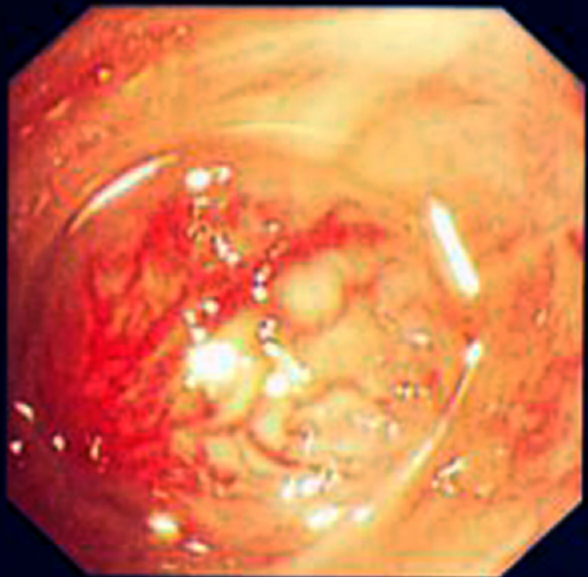
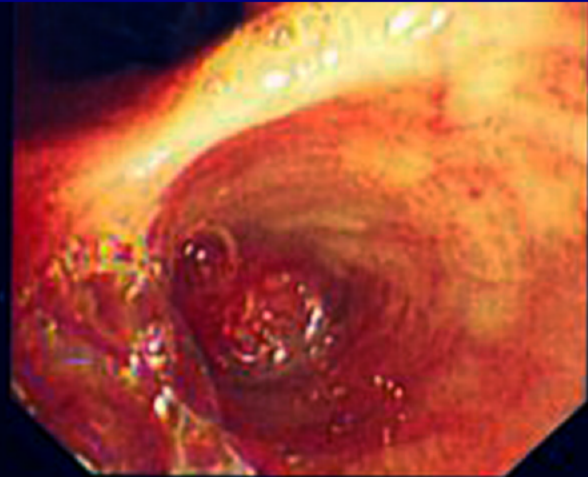
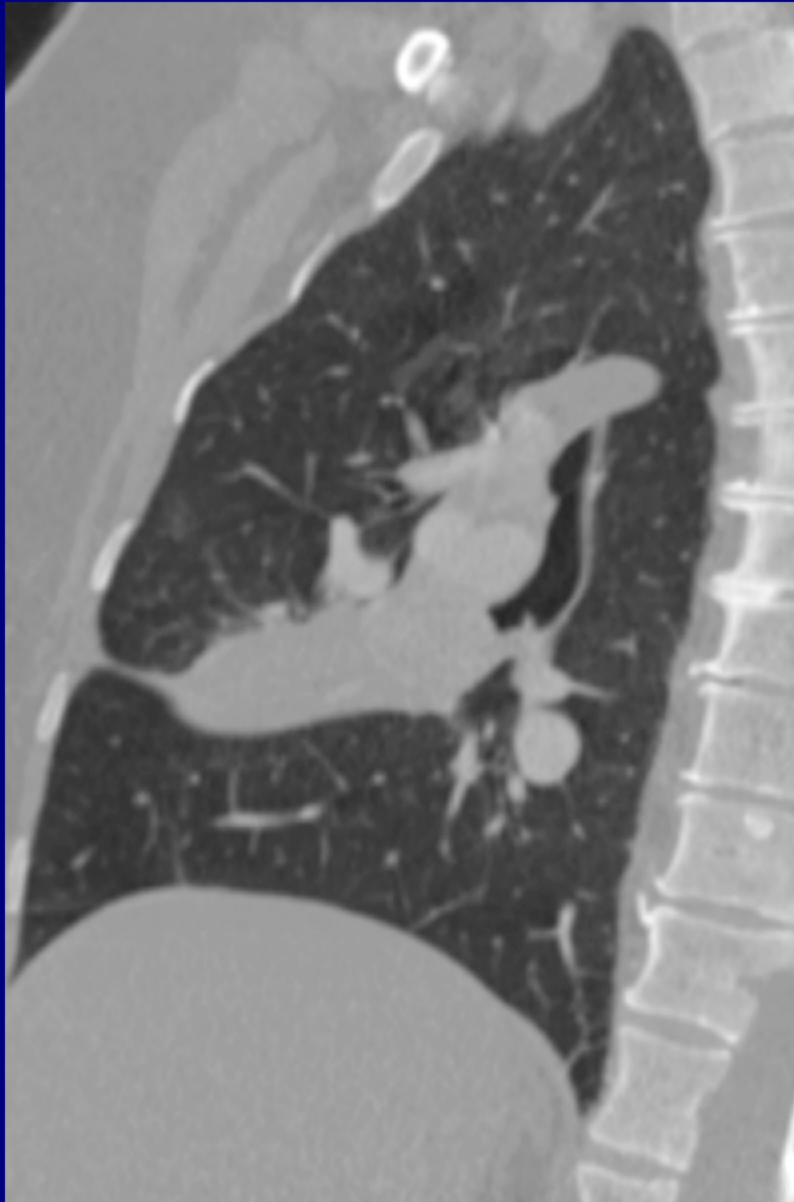# Mass with middle lobe collapse

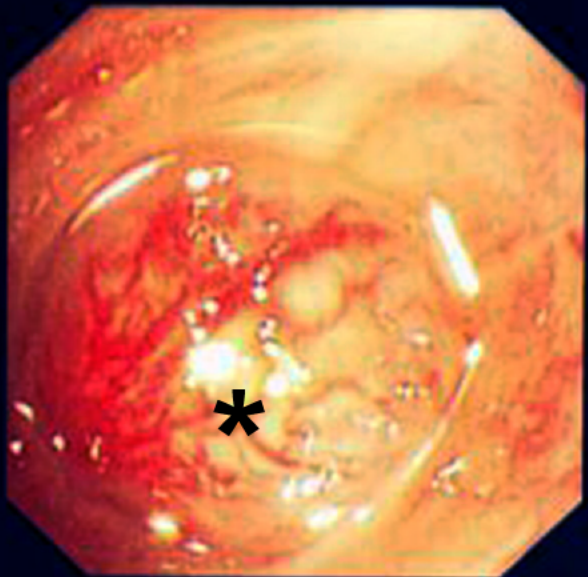
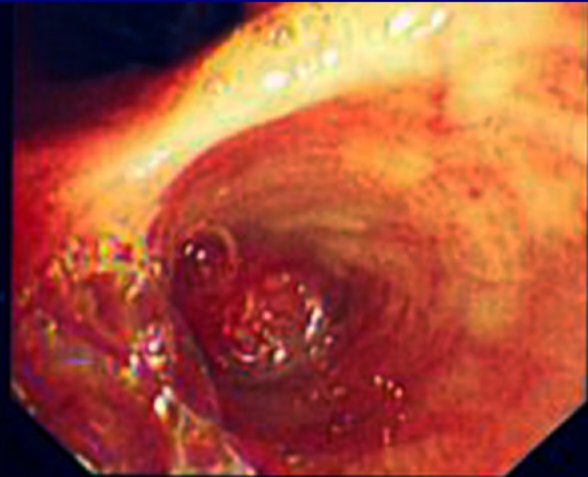
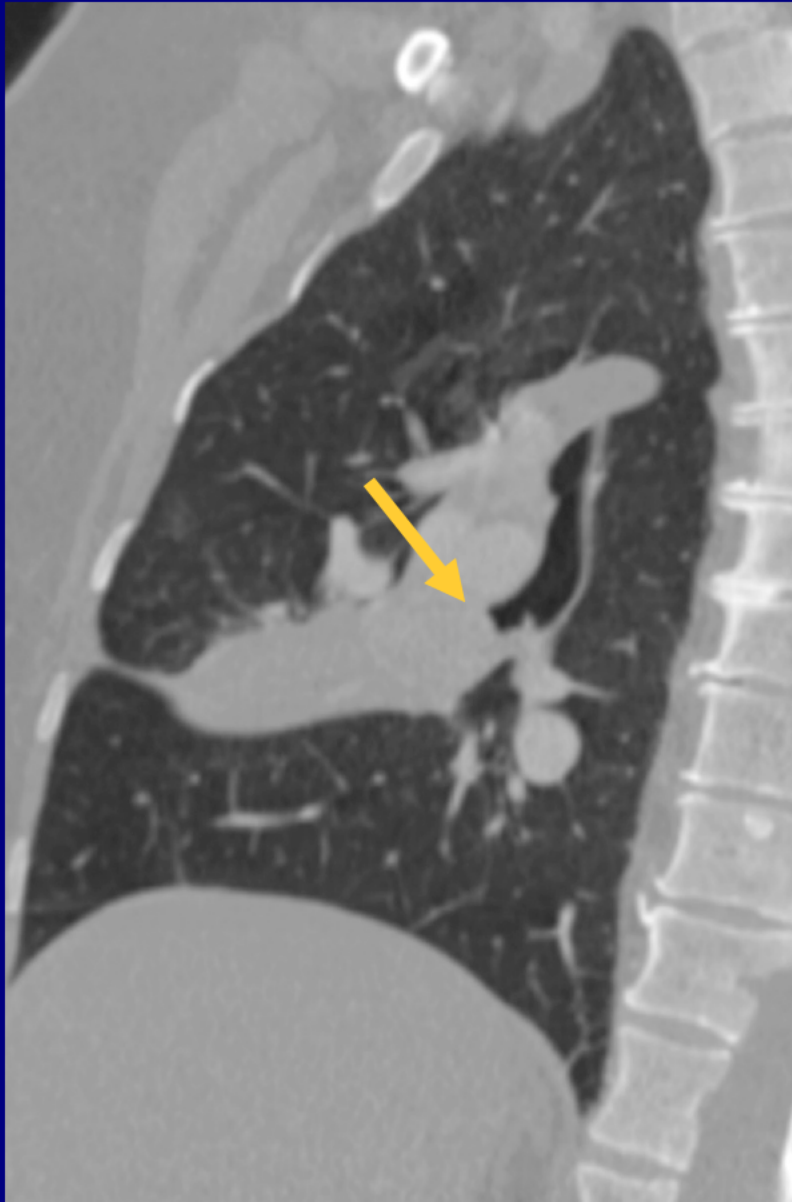





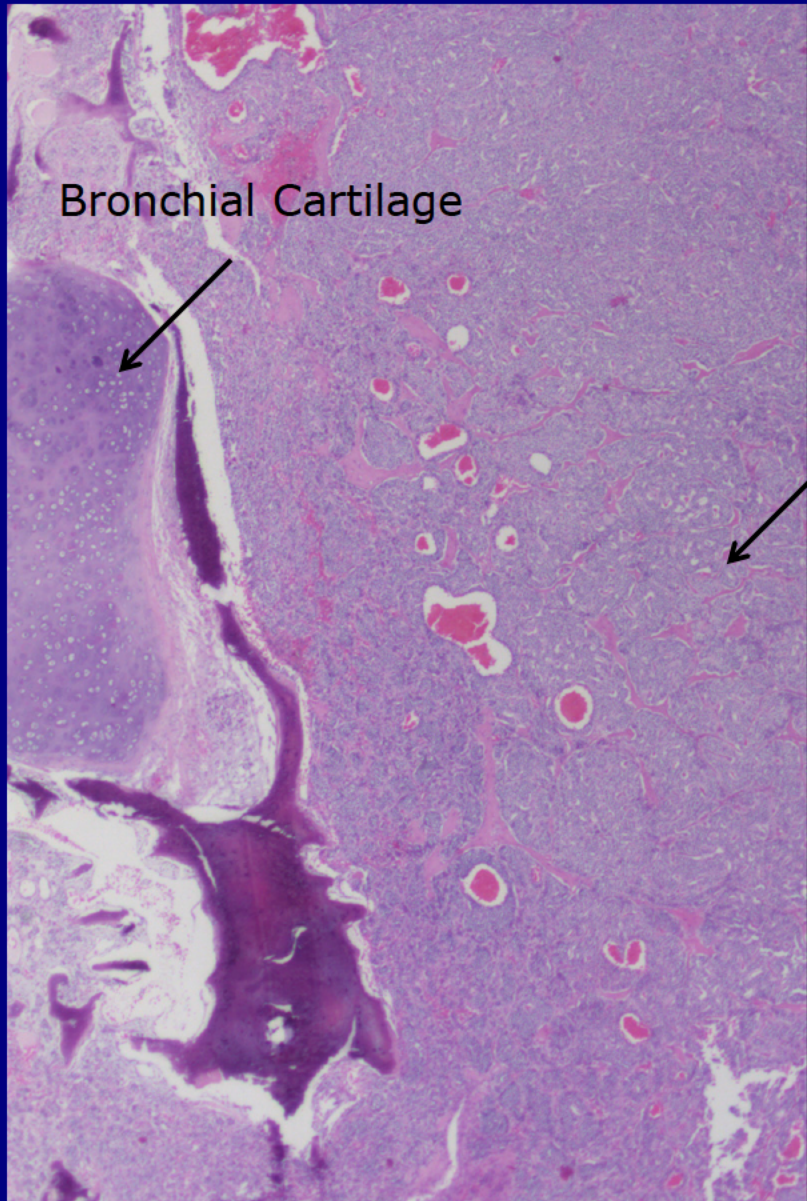




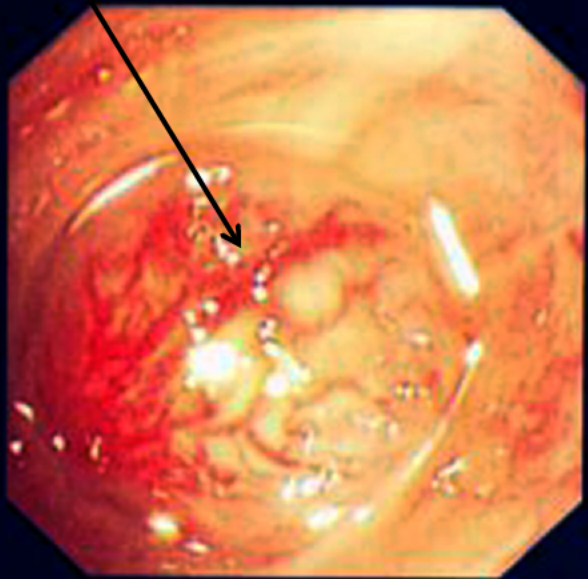
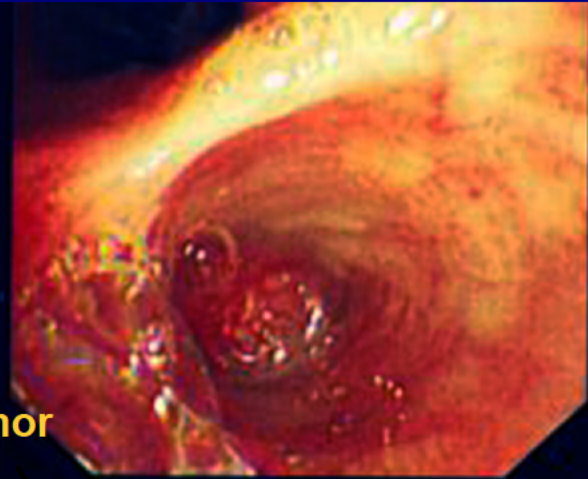




# Endobronchial tumor



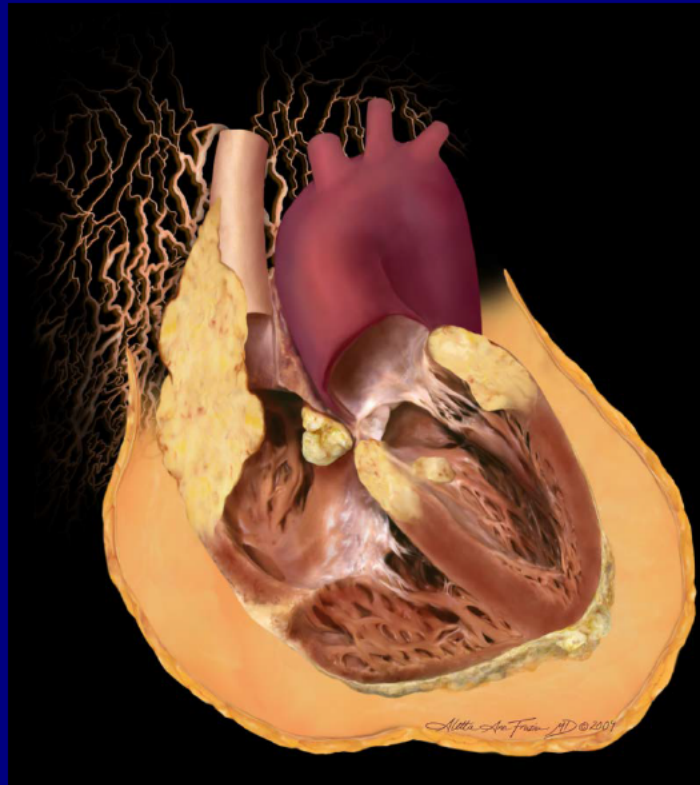**Tumor**



# Bronchial Carcinoid

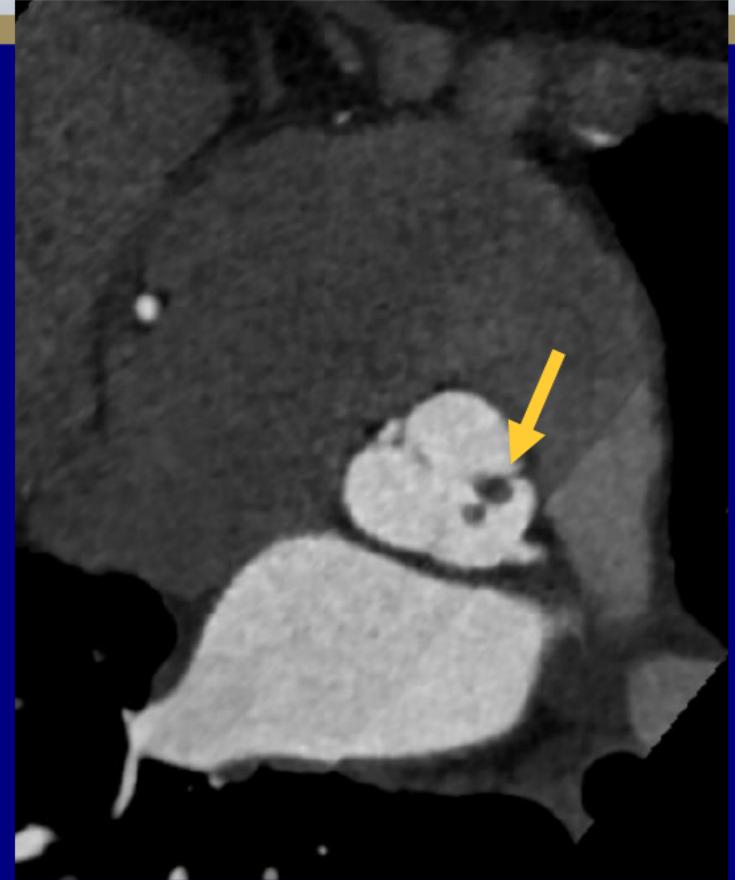
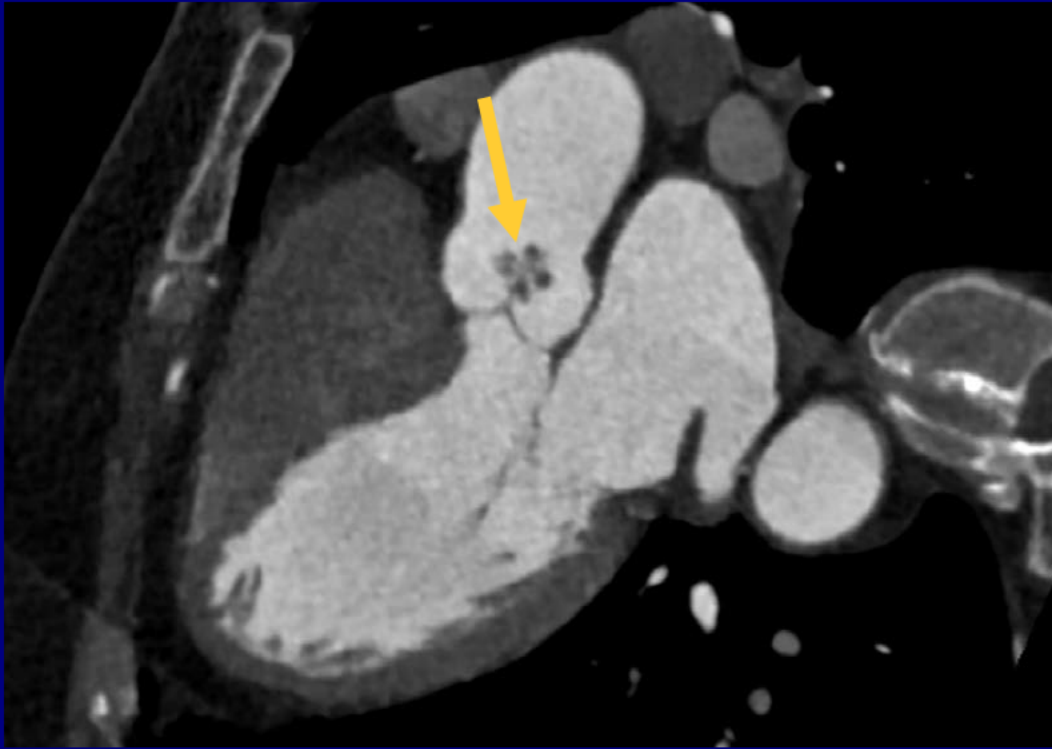
**Hyeladzira Thahal, MD**  
**Bristol Royal Infirmary**  
**Bristol, United Kingdom**

# Cardiovascular Best Case

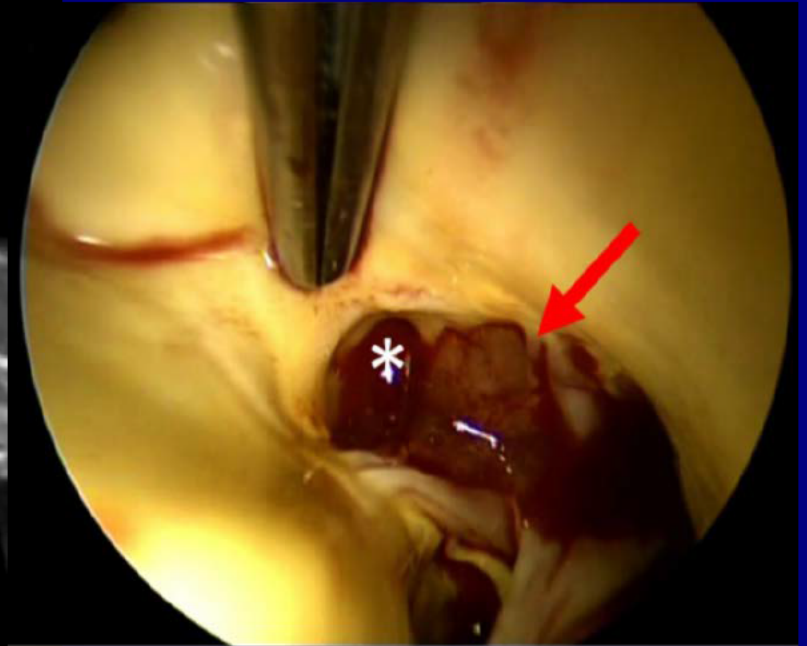
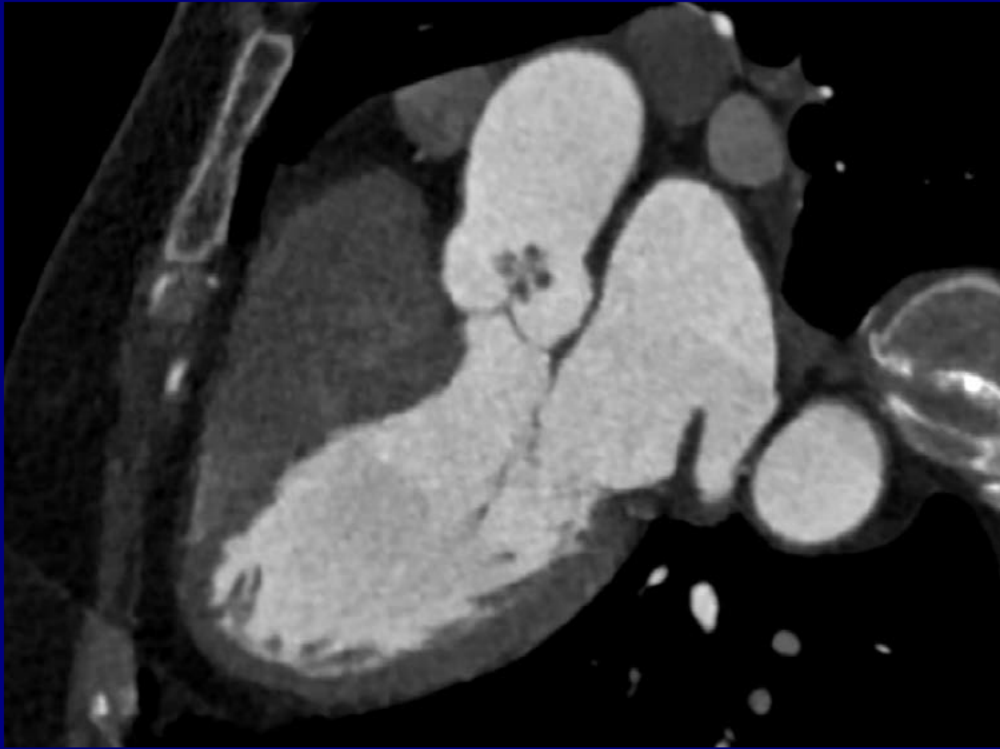




Adult female presents with one episode of retrosternal chest pain during swimming and a remote history of melanoma. EKG and blood pressure normal.

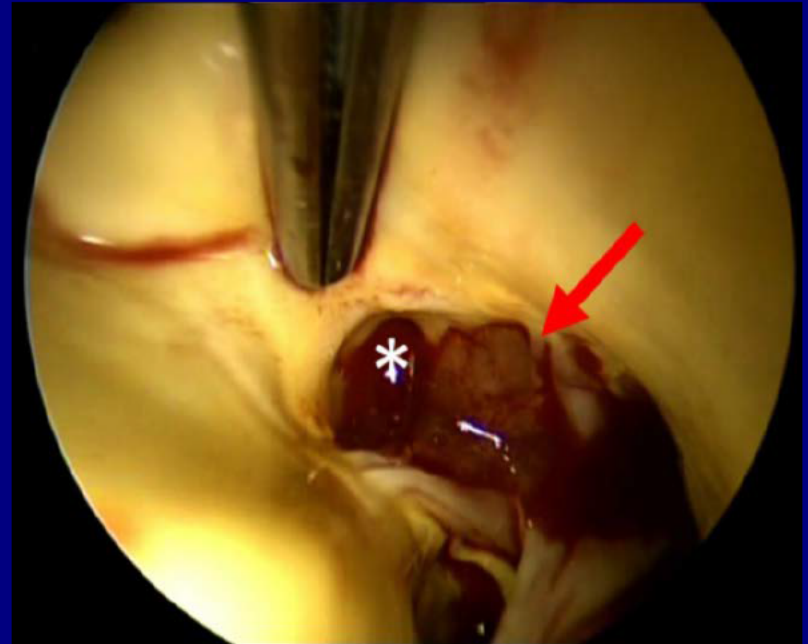
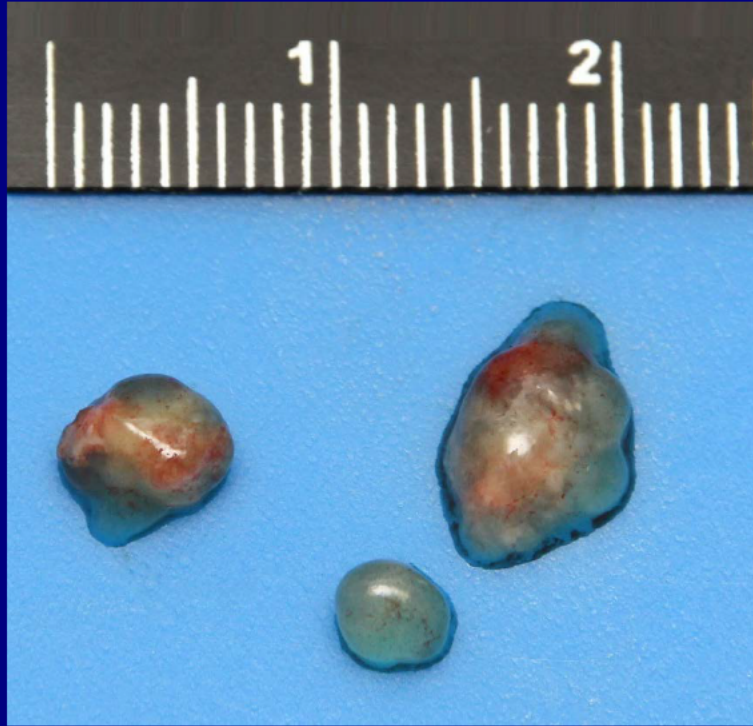

**ECG-gated contrast-enhanced CT images centered on the aortic valve show a tiny branching filling defect (measuring 12 x 10 x 9 mm) associated with the left coronary leaflet.**

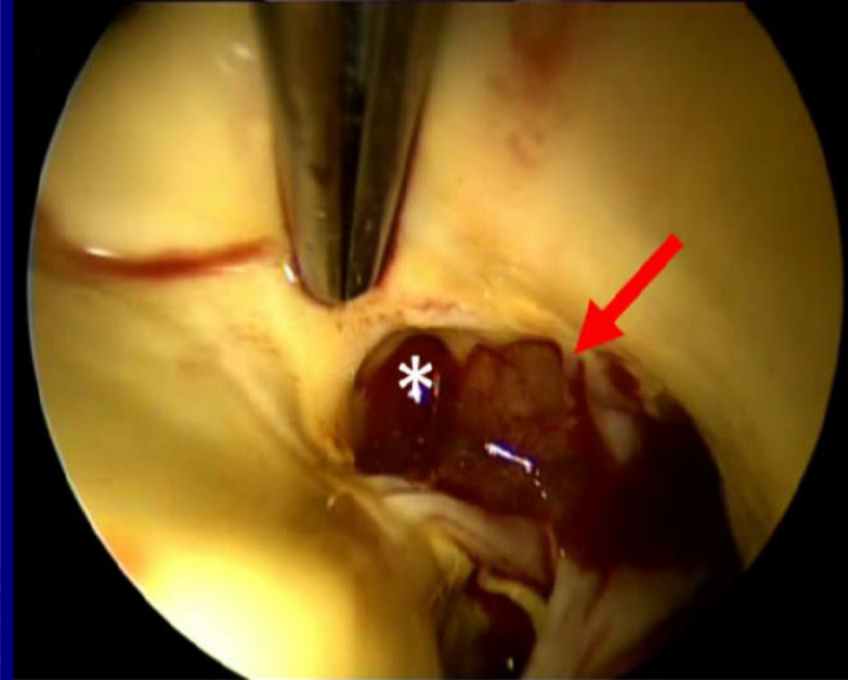
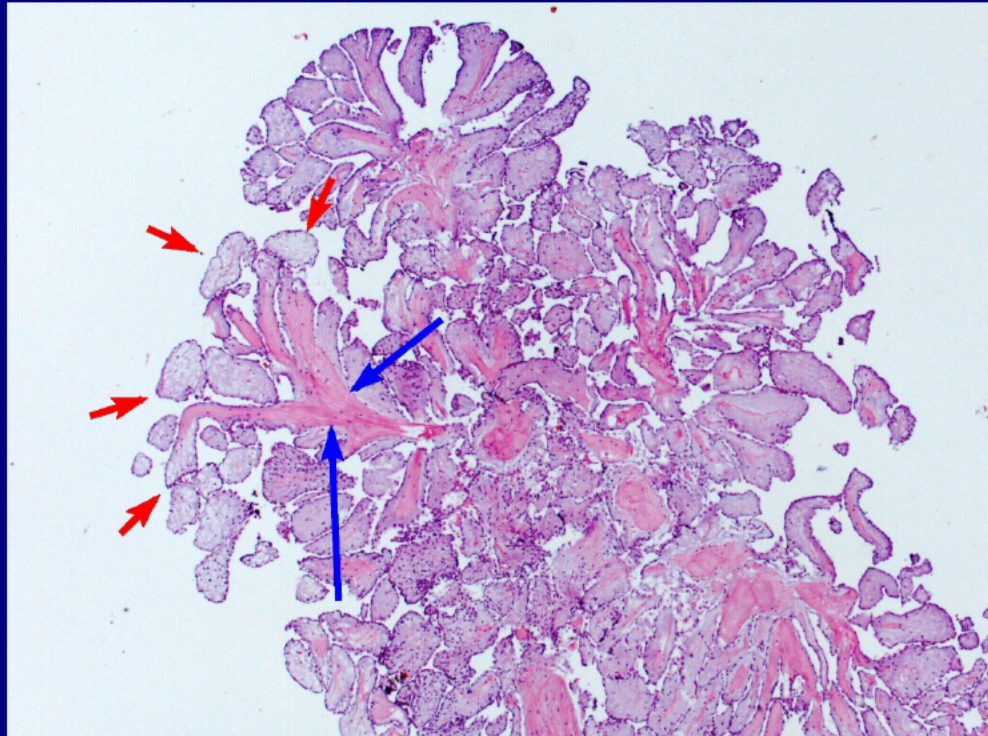


**Intraoperative view shows a multi-lobulated lesion attached to the left coronary aortic valve leaflet.**





**The resected lesion shows irregular gelatinous tissue fragments measuring up to 1.3 cm.**



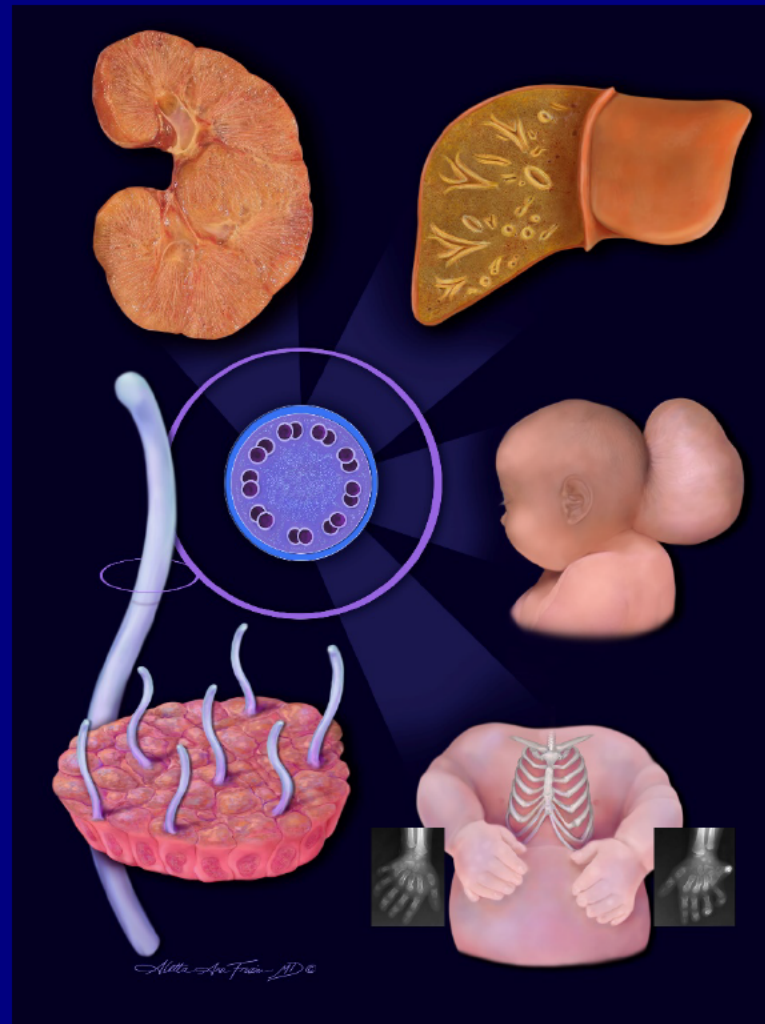
**Histologic examination shows this lesion is comprised of papillary fronds with central fibrous stroma. The fronds are lined by a single layer of endothelial cells. No melanoma cells.**

**Fibroelastoma of the left coronary  
cusp of the aortic valve with  
intermittent occlusion of the left  
coronary artery**

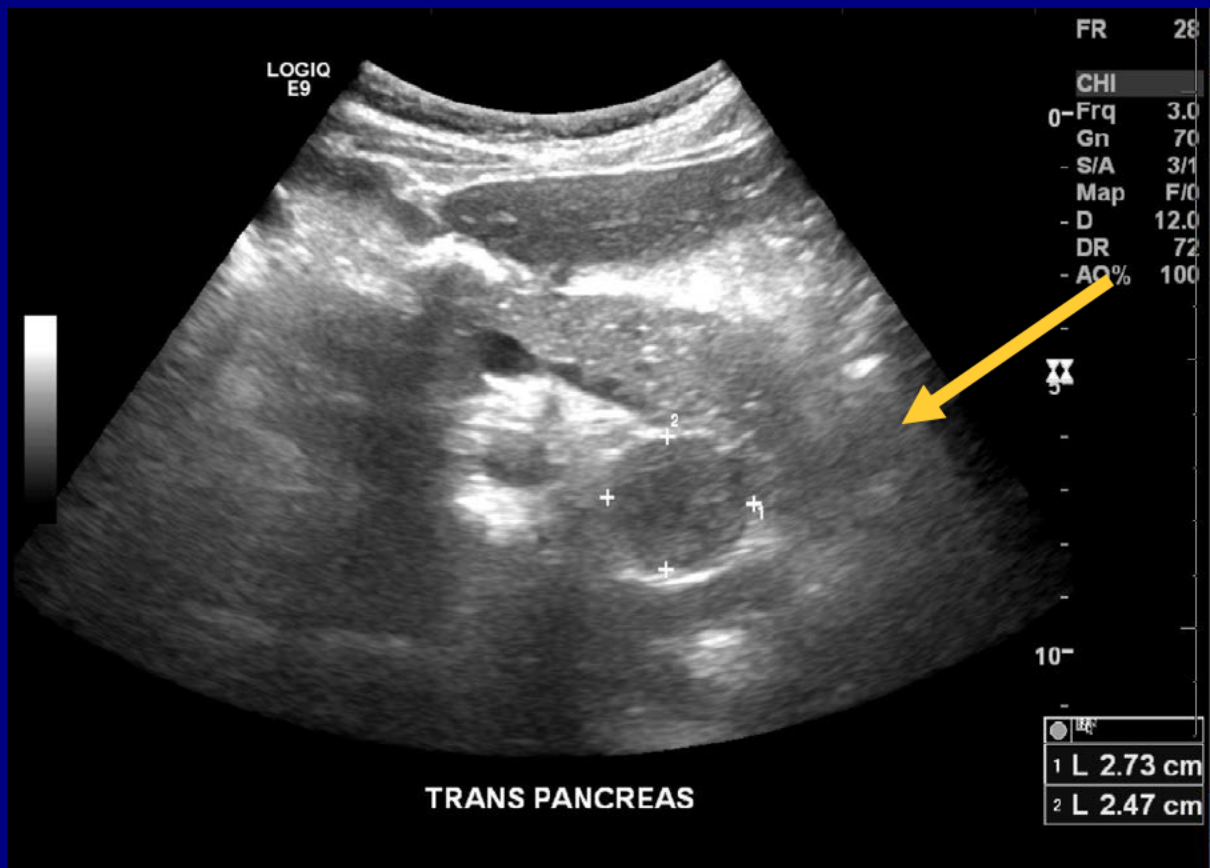
**Dr. Arthur du Mee  
Catharina Hospital  
Eindhoven, Netherlands**



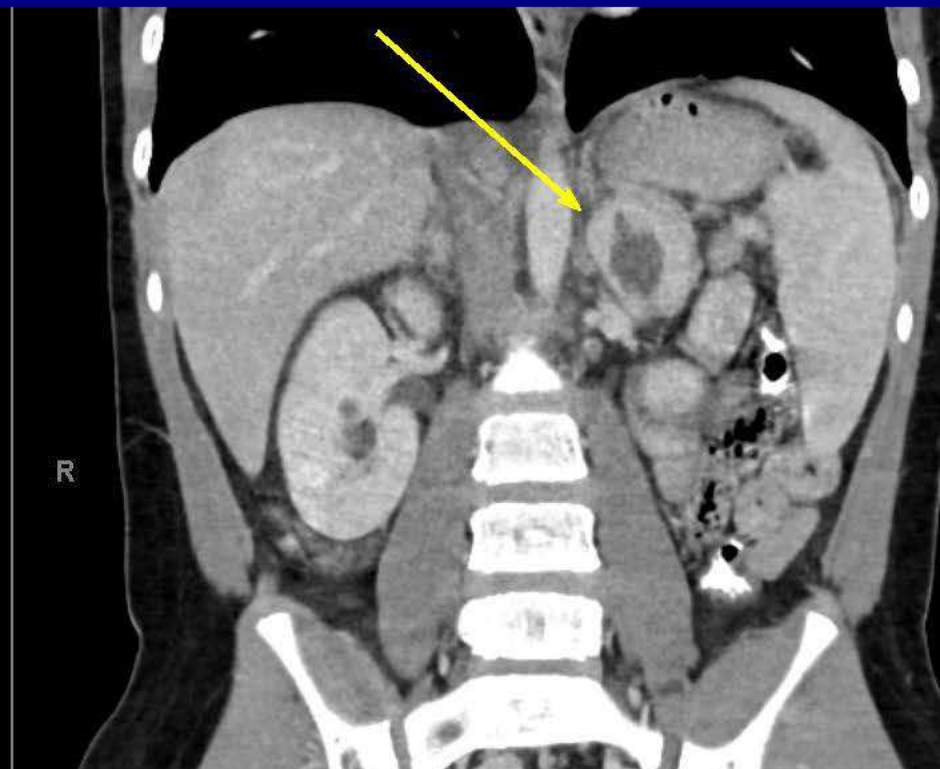
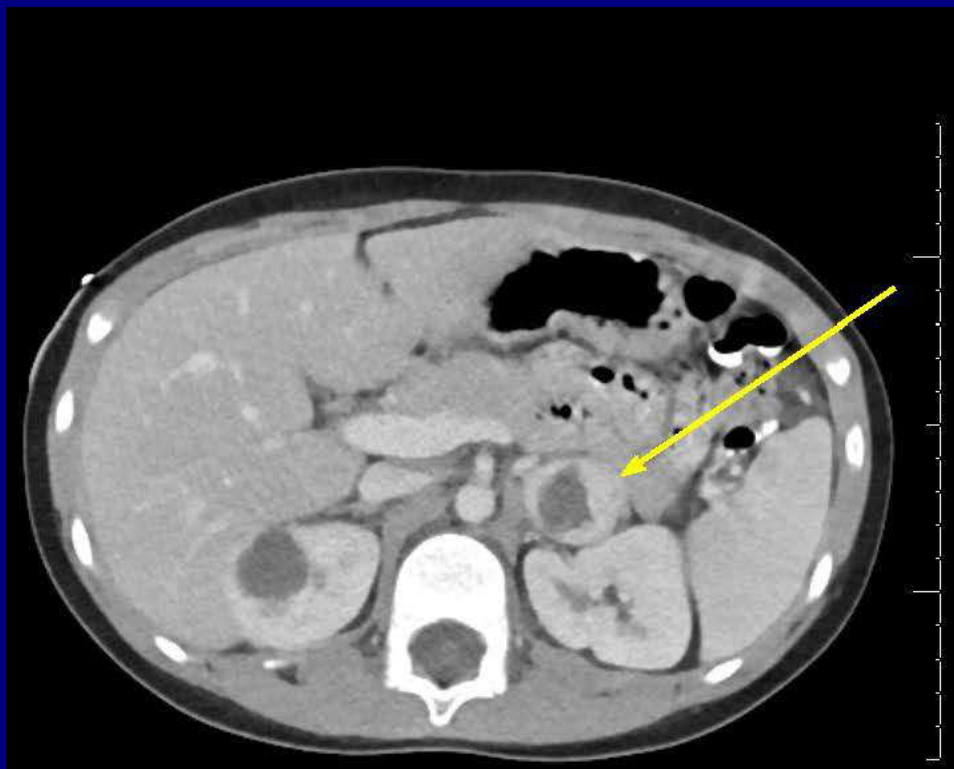
# Pediatric Best Case

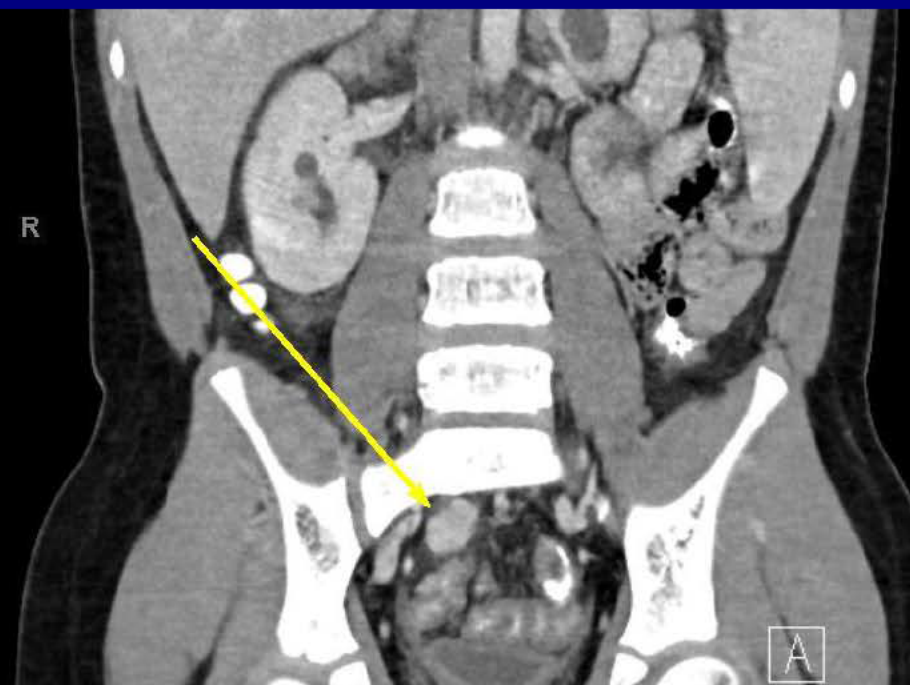
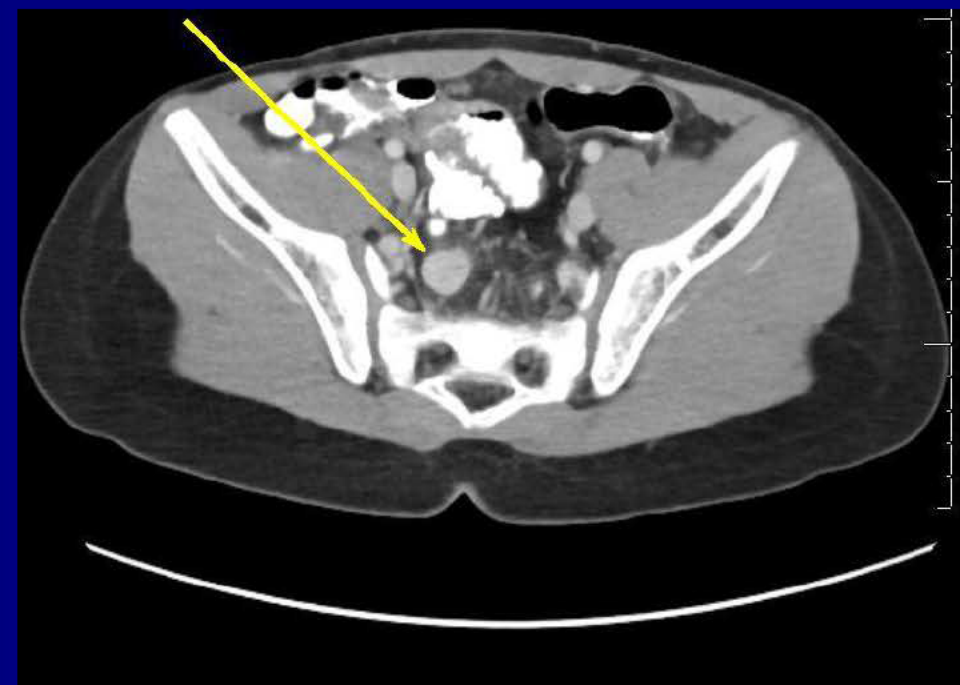


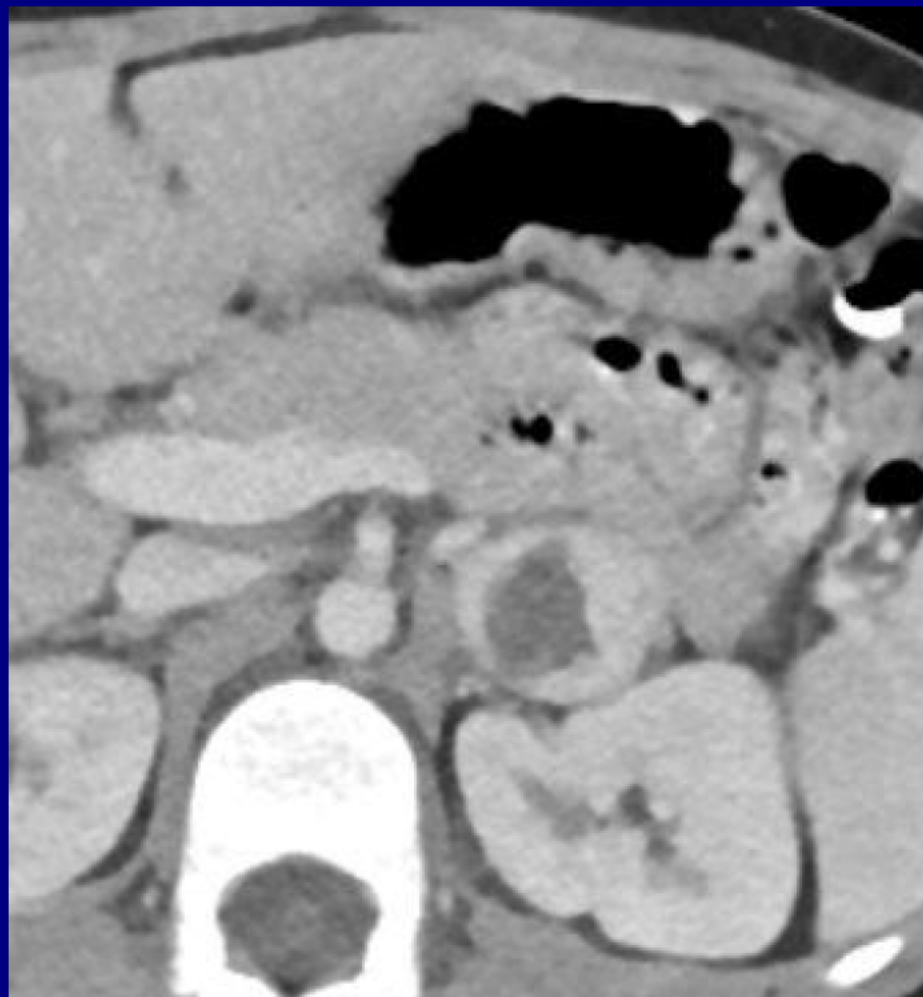
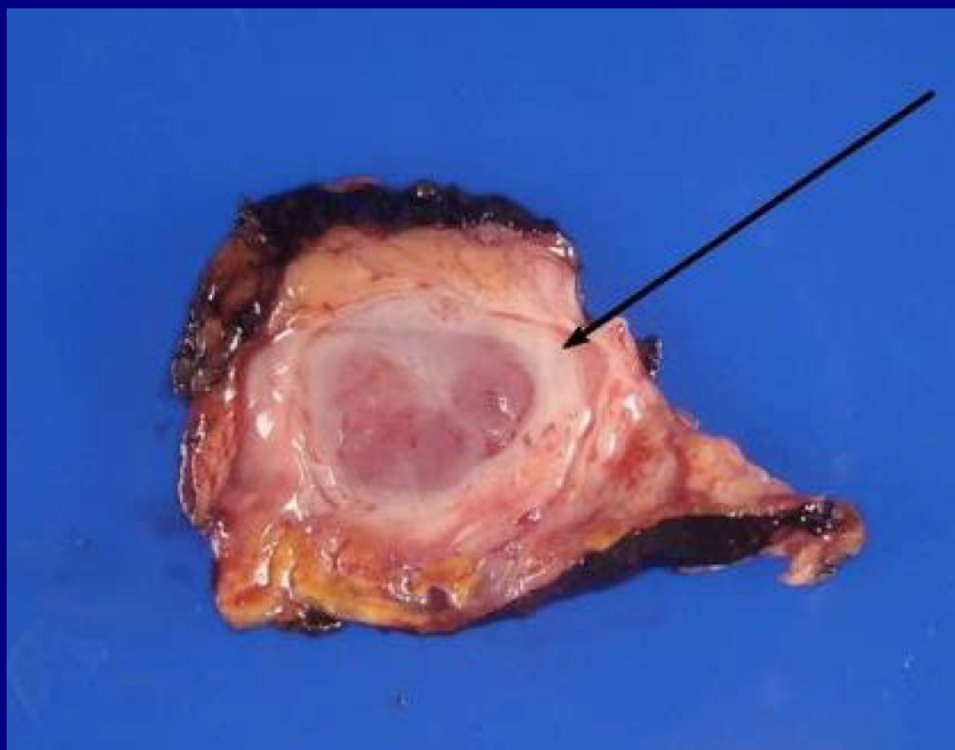
**10-year-old boy with episodes of  
“feeling hot” and tachycardia**



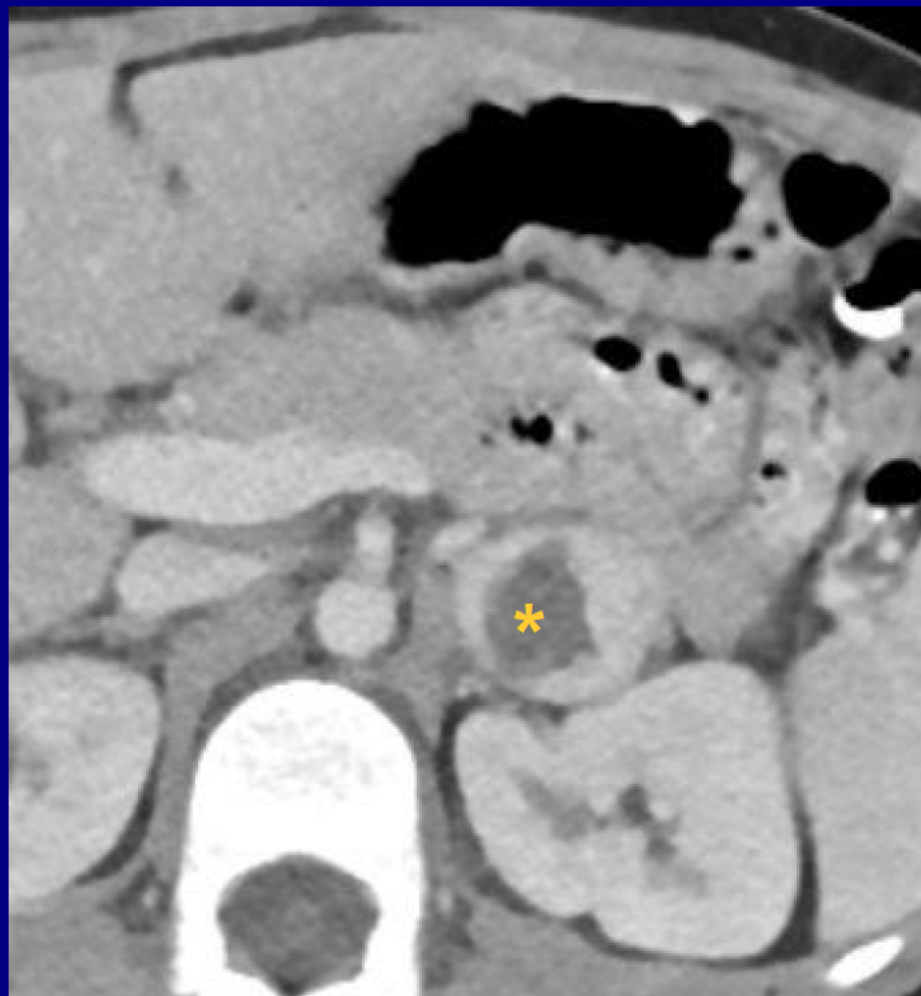
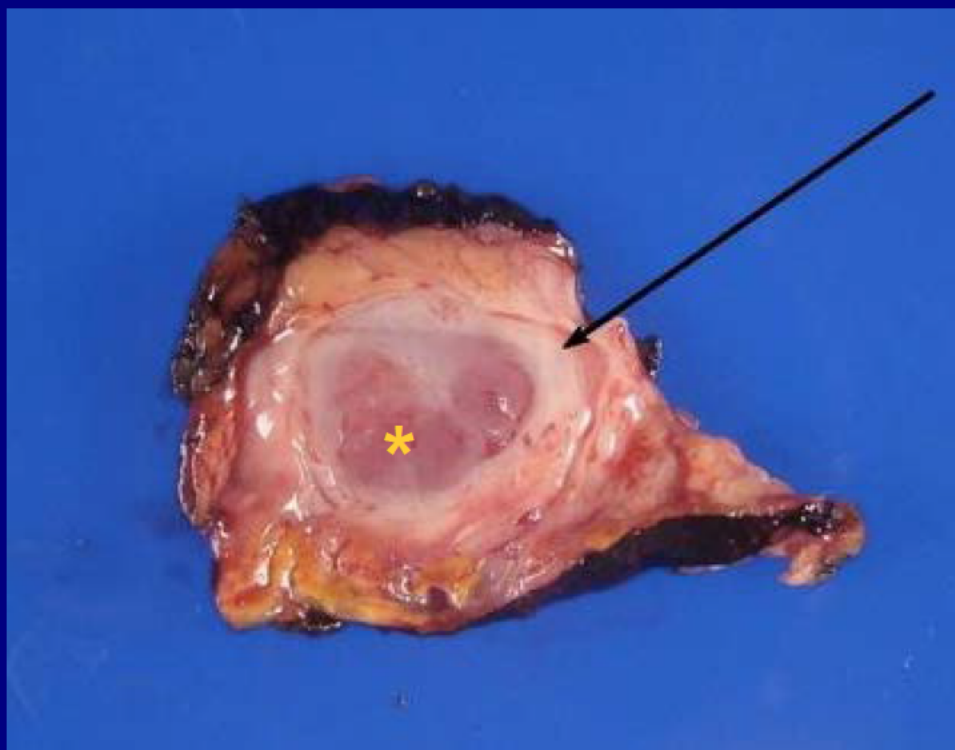


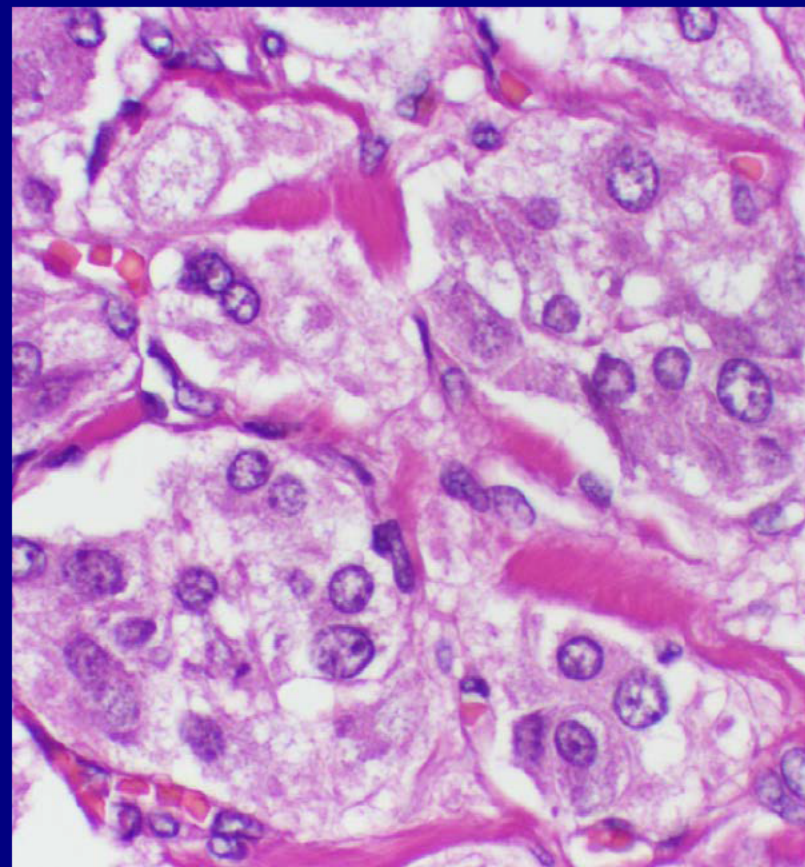
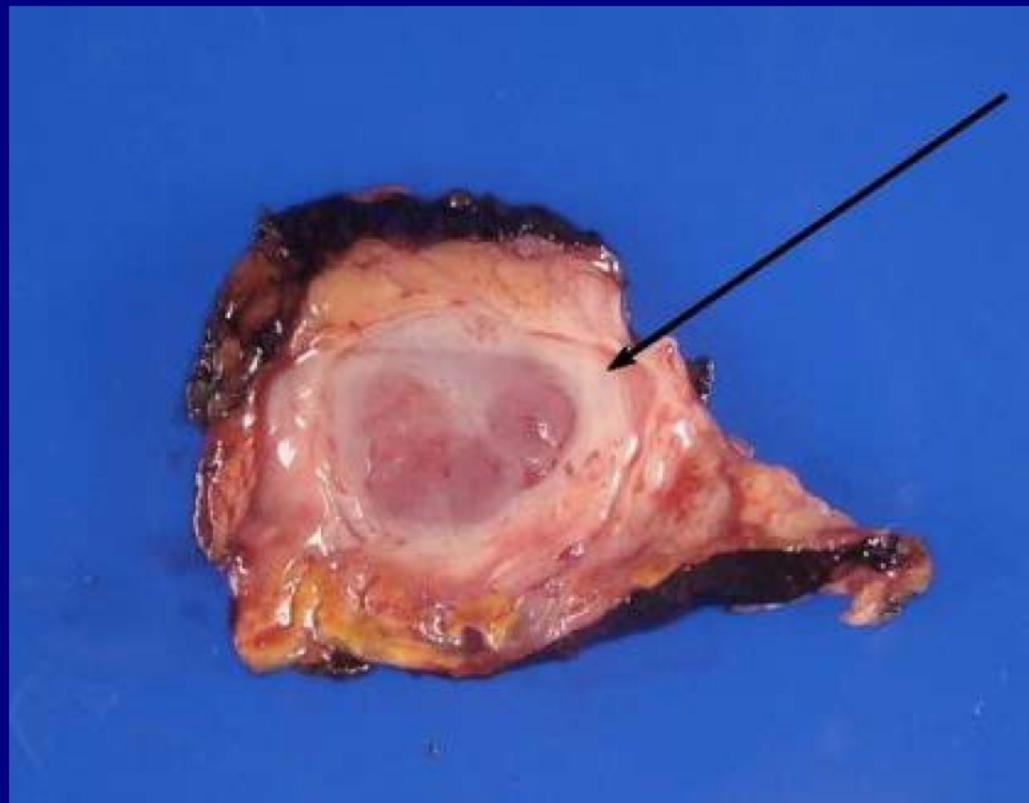












# Pheochromocytoma and Paraganglioma in von Hippel-Lindau Disease

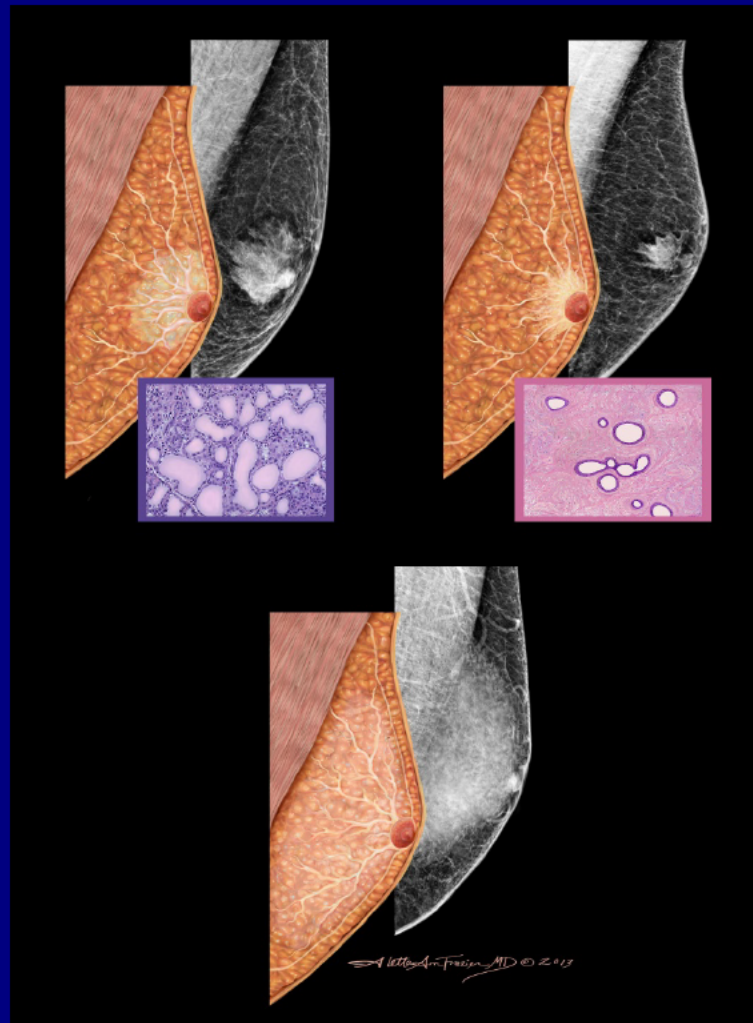
**Elaina Zabak, MD**

**University of Texas Southwestern Medical  
Center**

**Dallas, Texas**

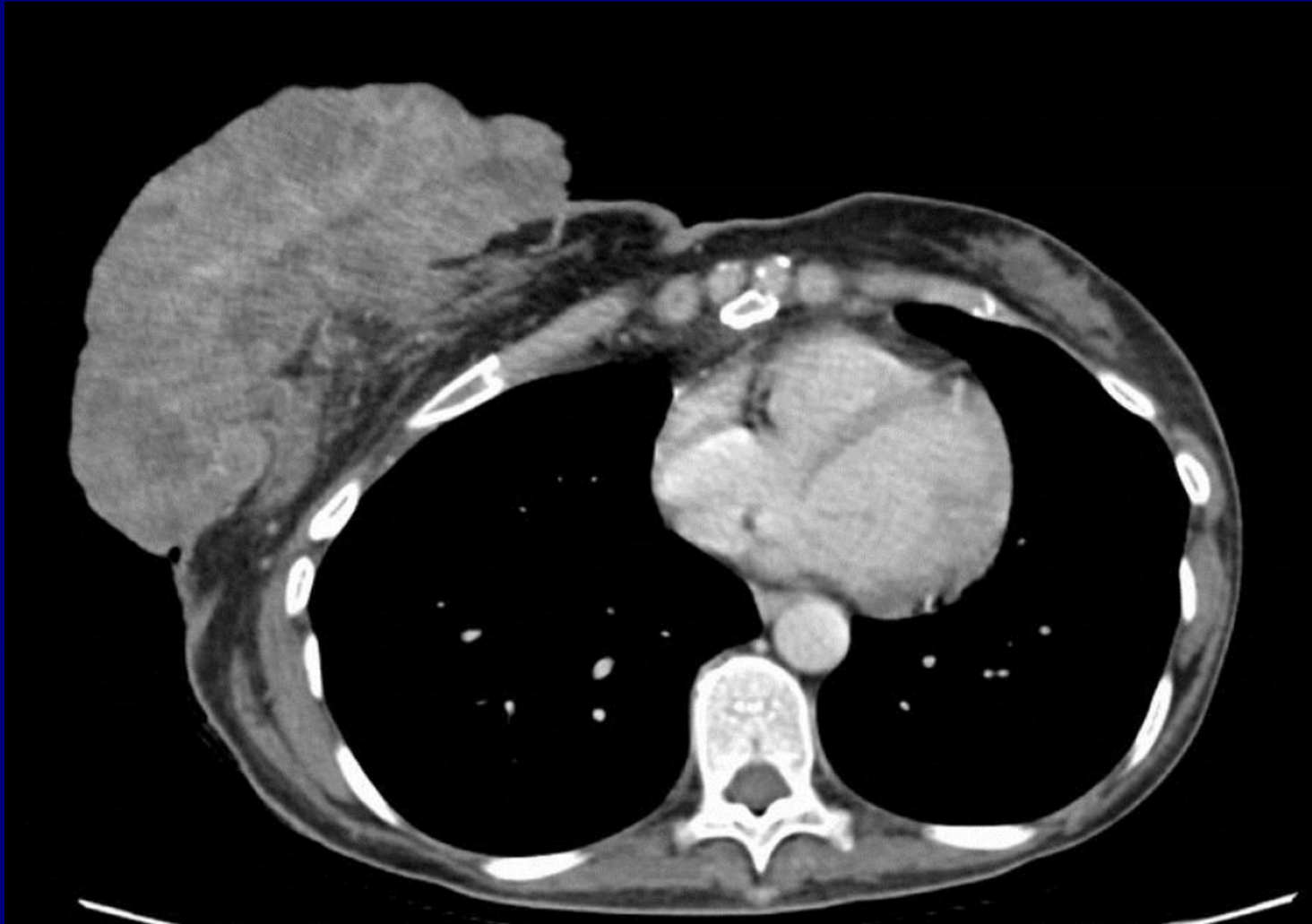

# Breast Best Case



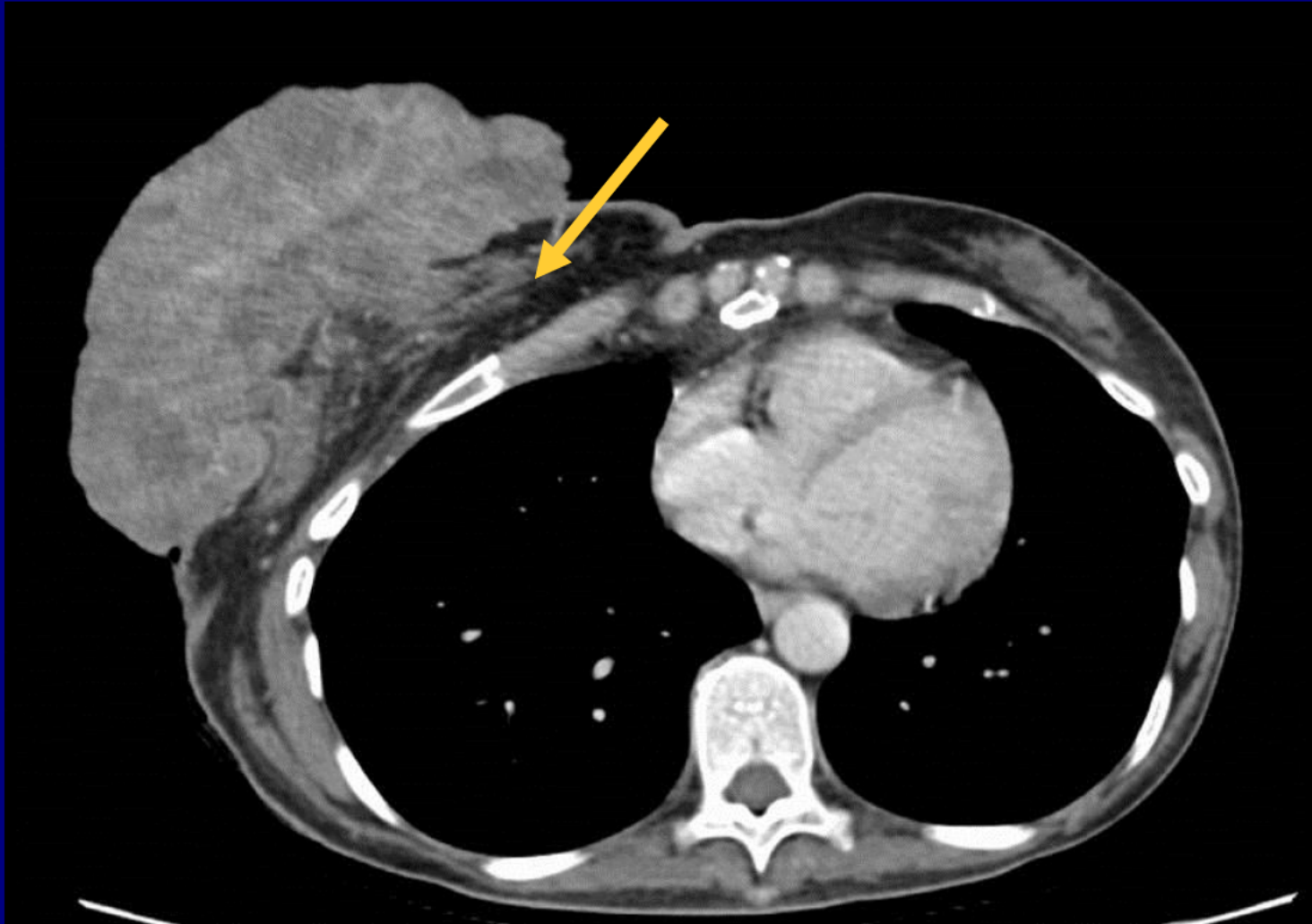
**51 yo female presented to the ER with  
a long-standing, but now rapidly  
enlarging breast mass.**

# Axial Chest CT

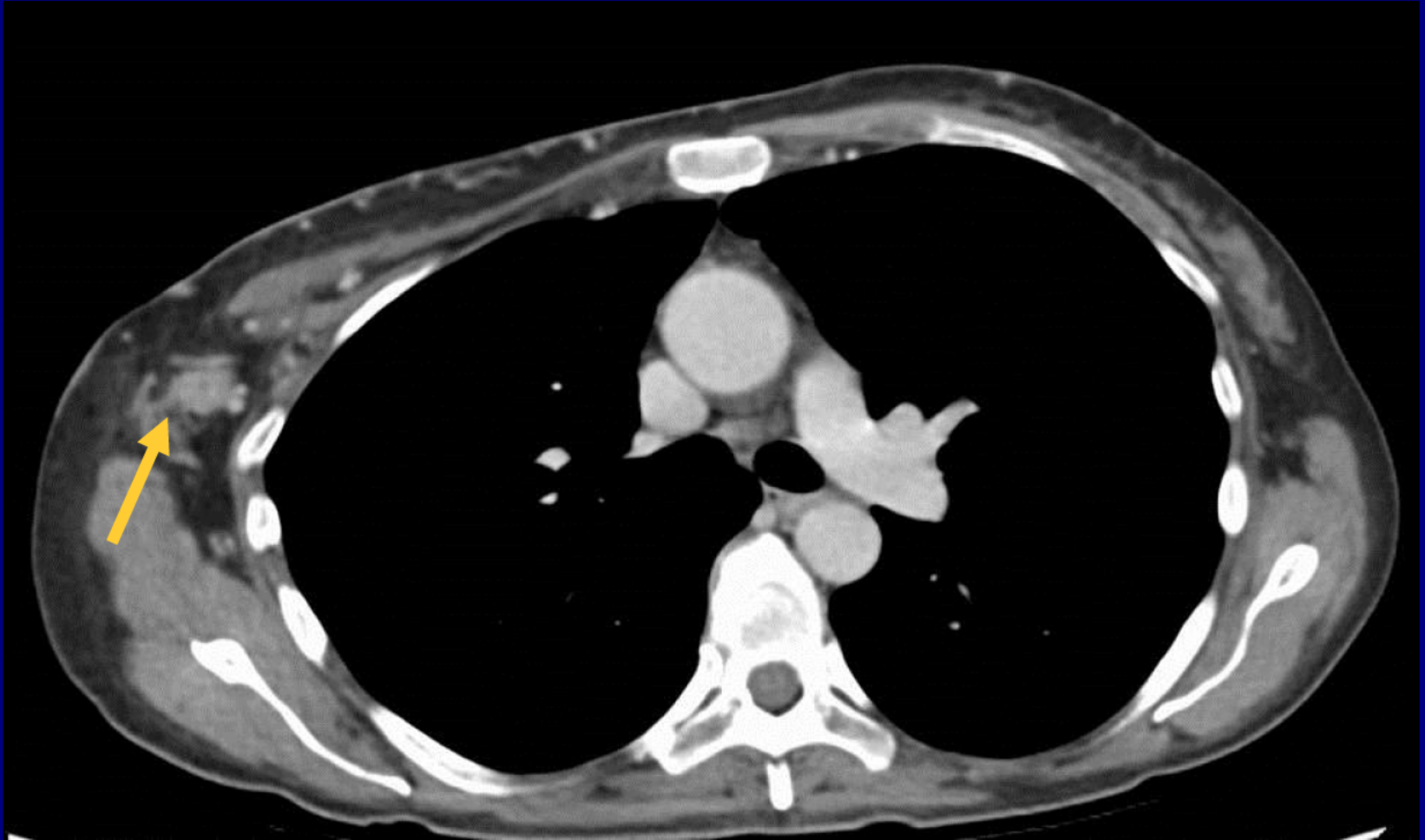




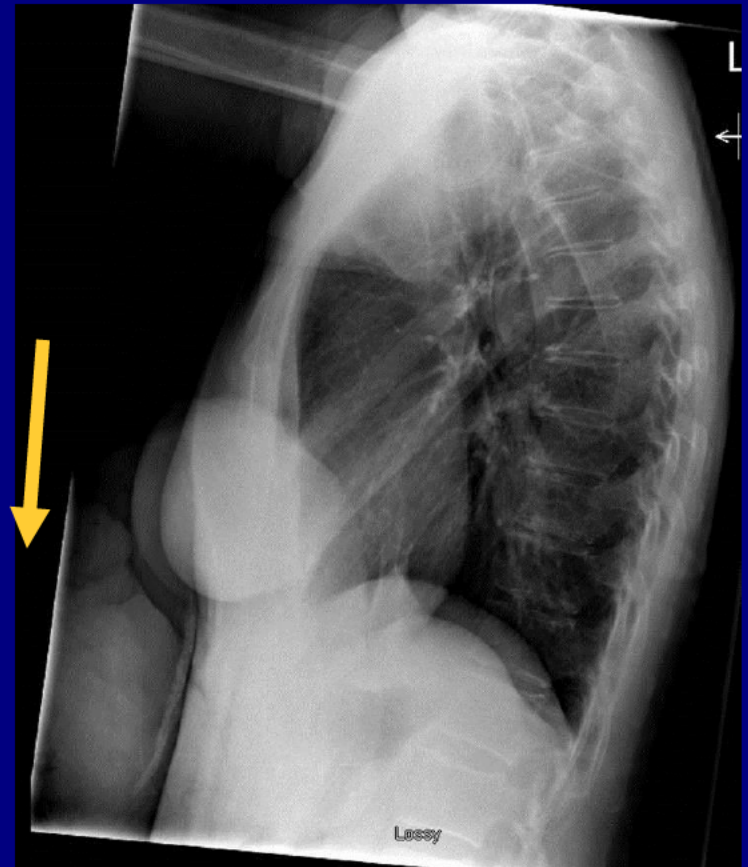
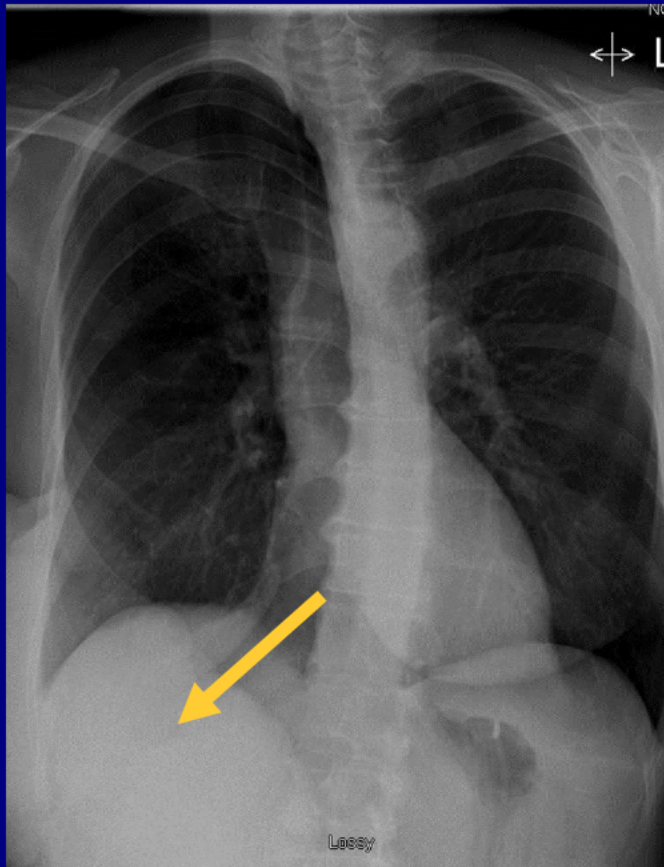
## Axial Chest CT



## Axial Chest CT

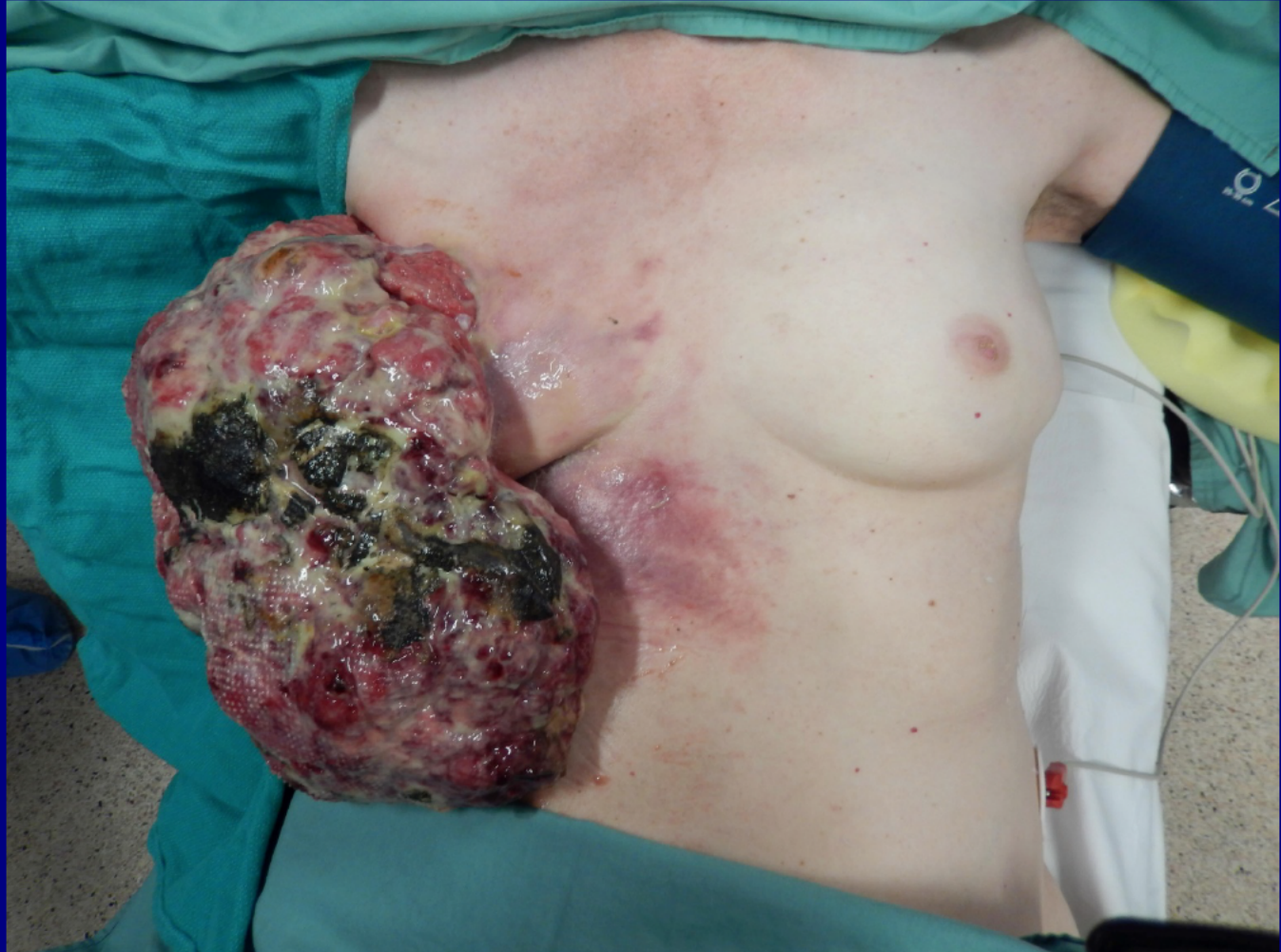

# CXR

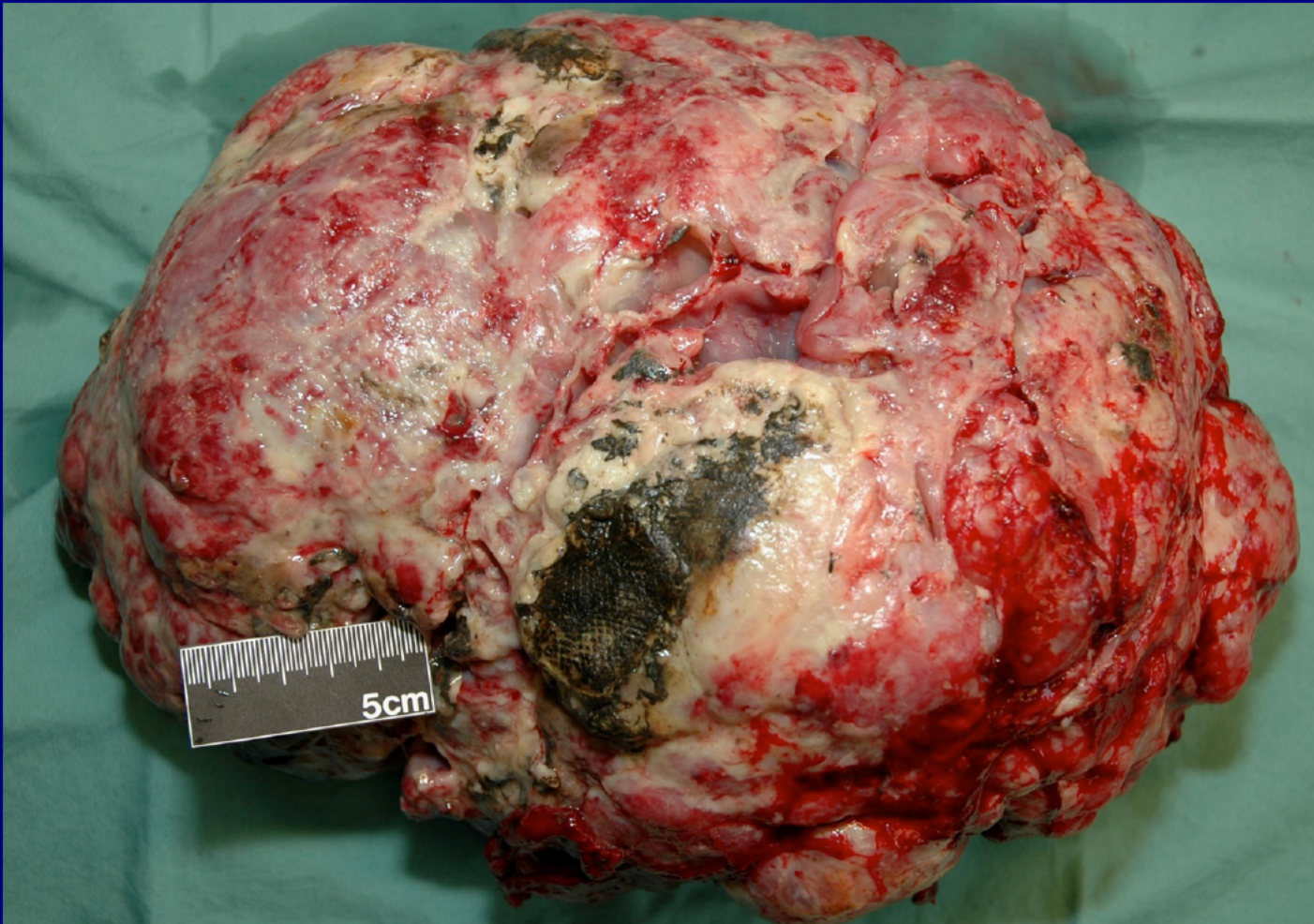




# Pre-Operative Clinical Image

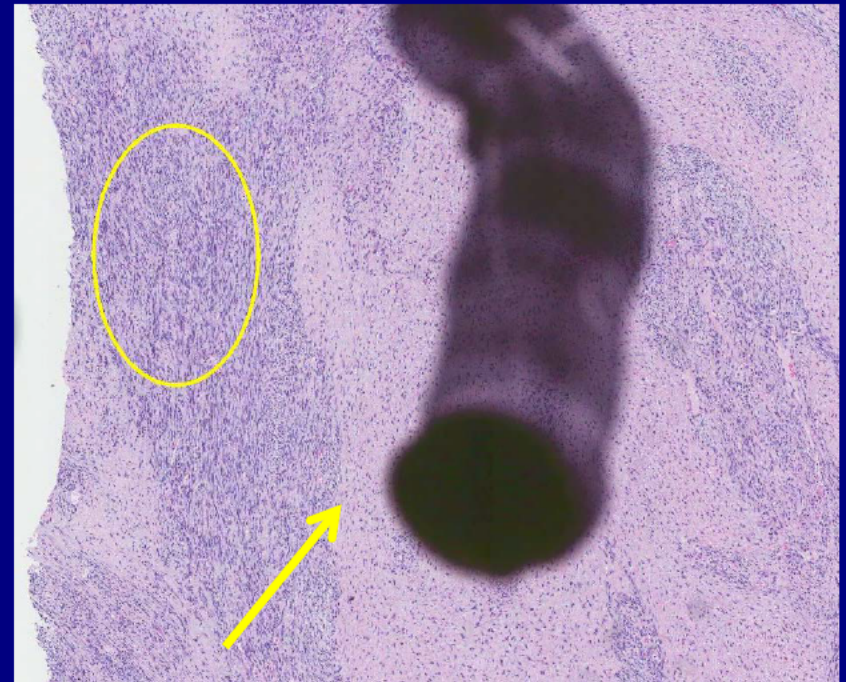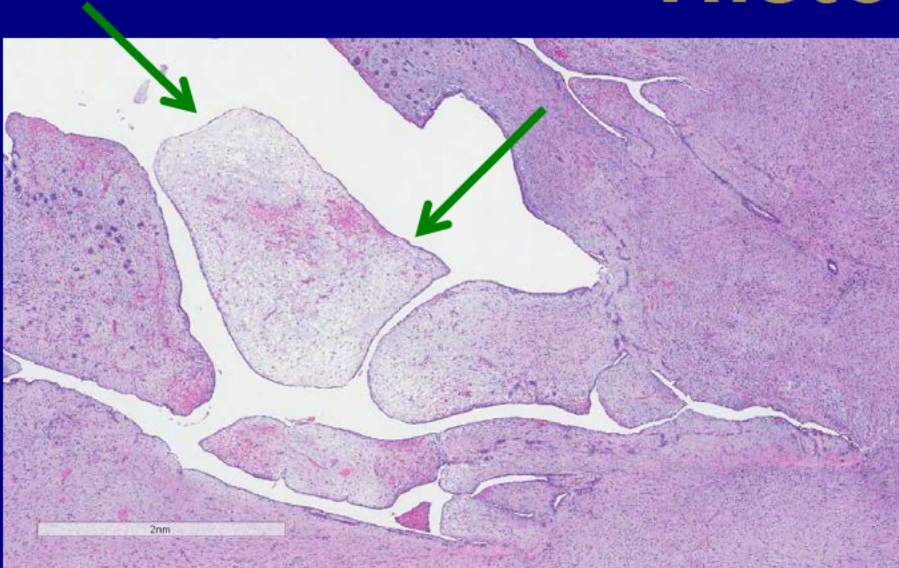


# Resected Tumor





# Histology

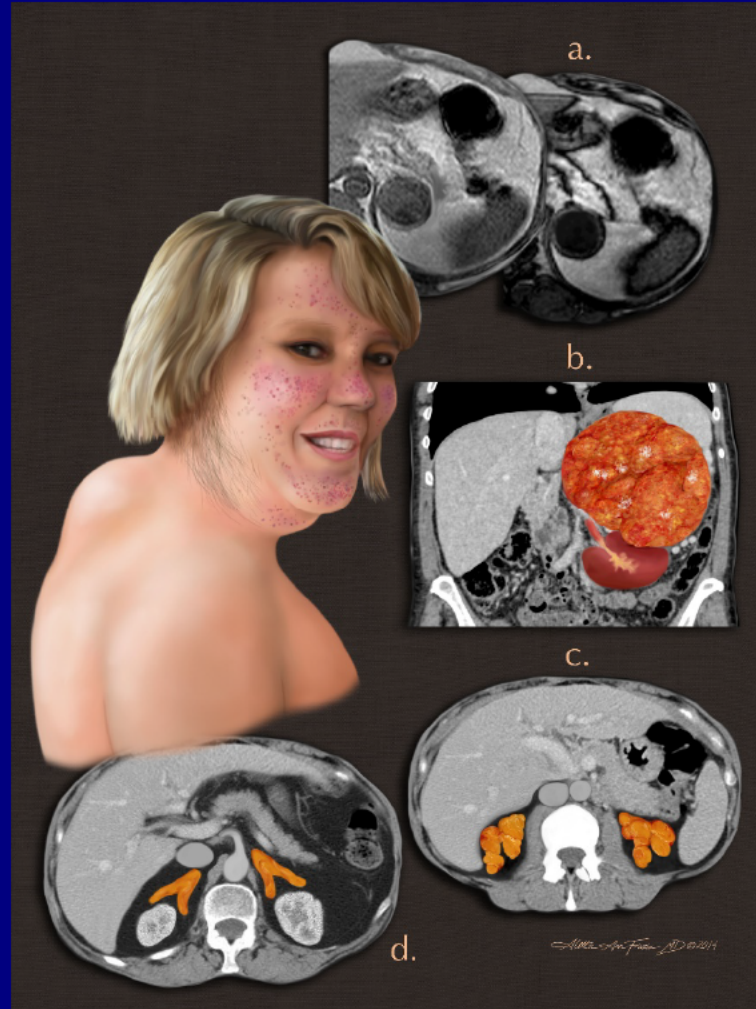




# **Malignant Phyllodes Tumor**

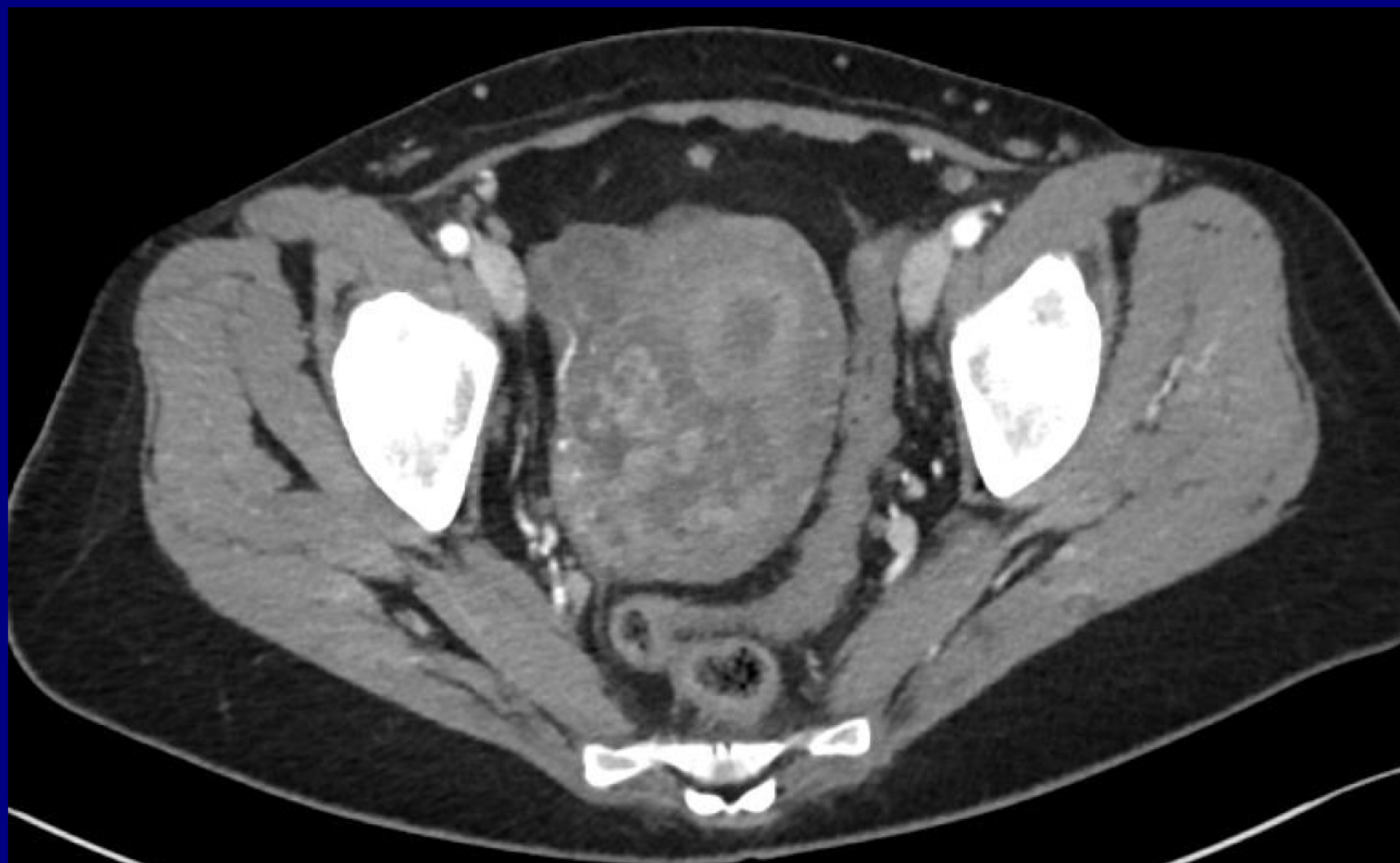**Jeffrey Quon, MD**  
**The Ottawa Hospital**  
**Ottawa, Ontario, Canada**

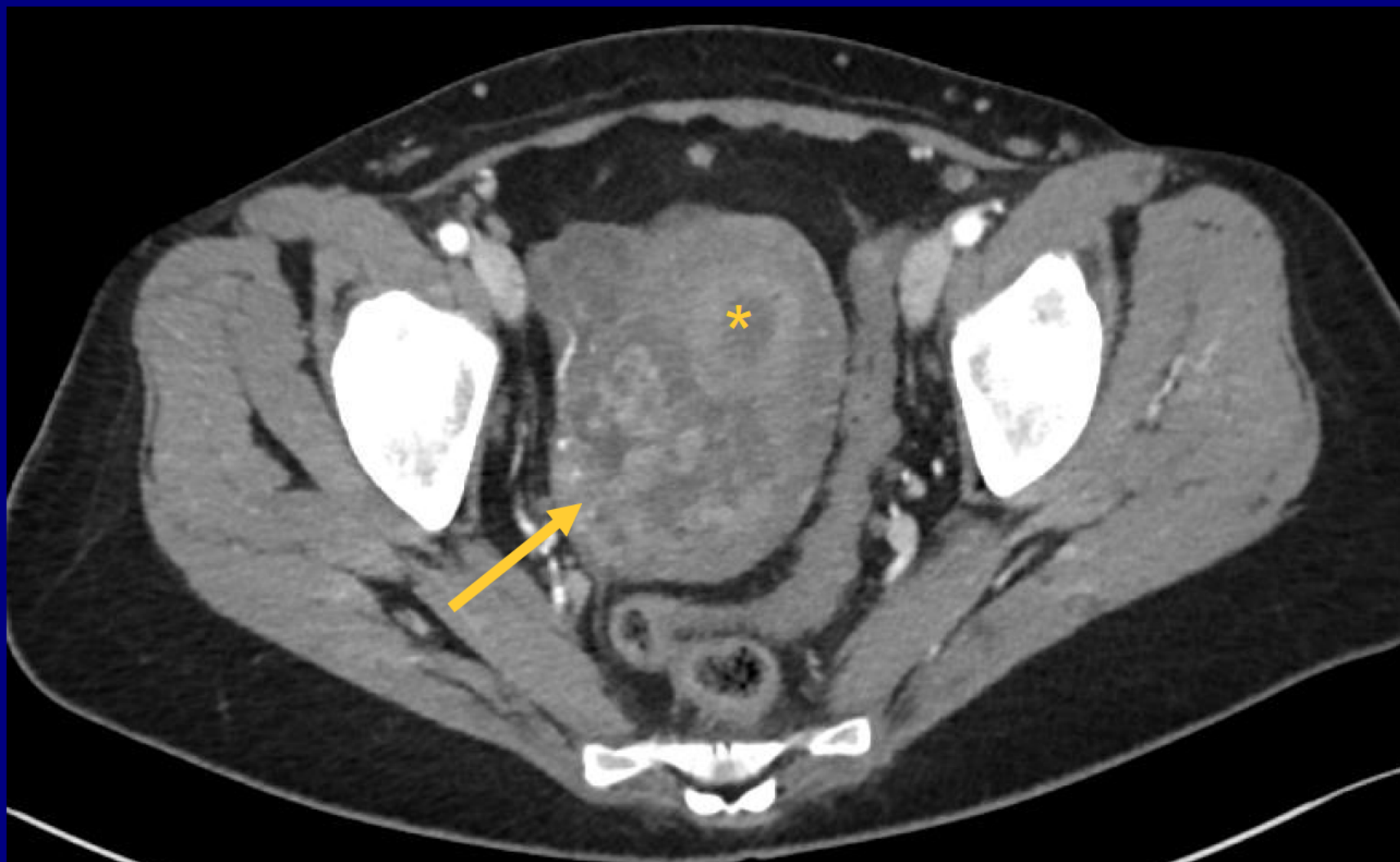
# Genitourinary Best Case

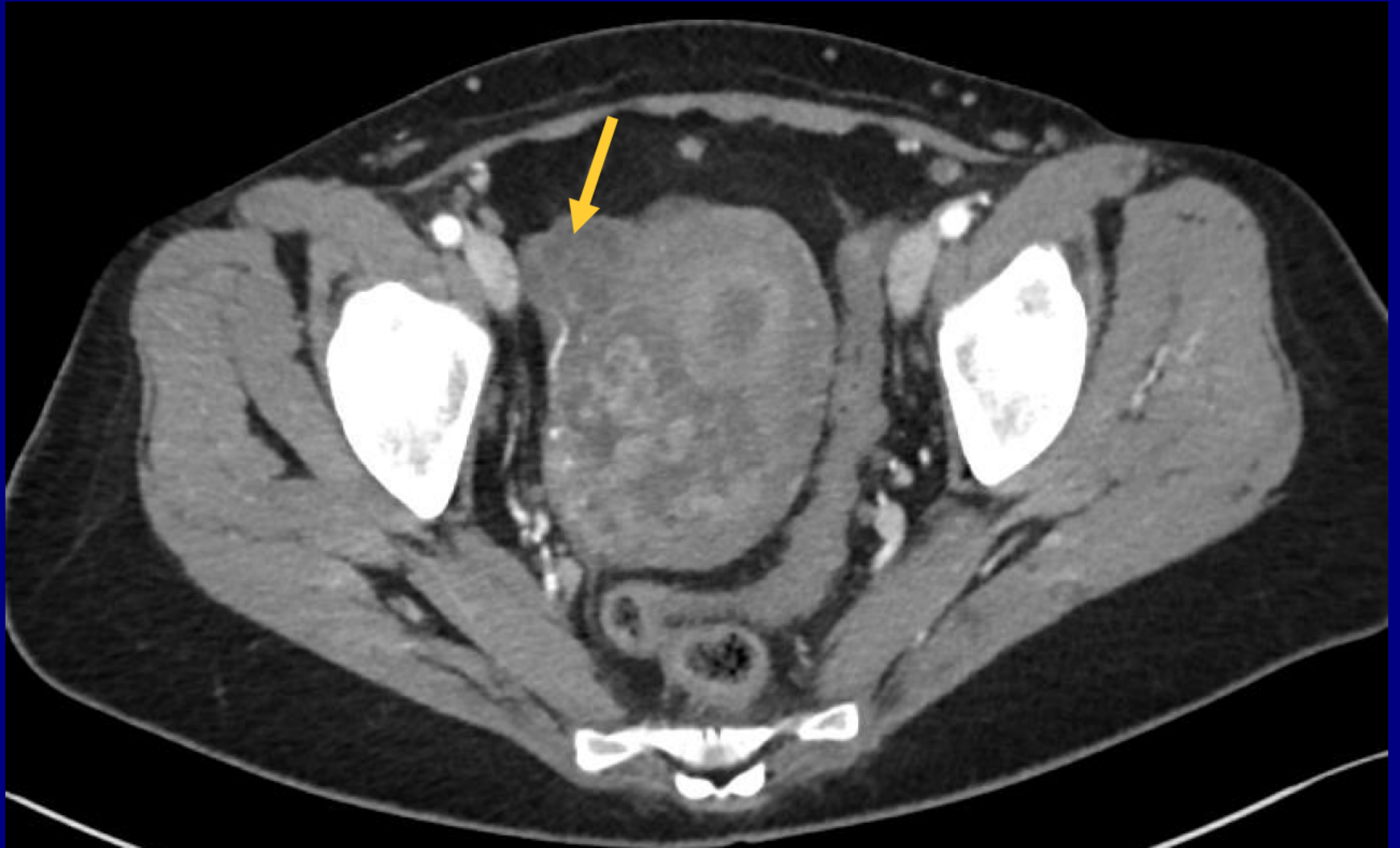

**53 yo female with shortness of breath  
and weight loss.**

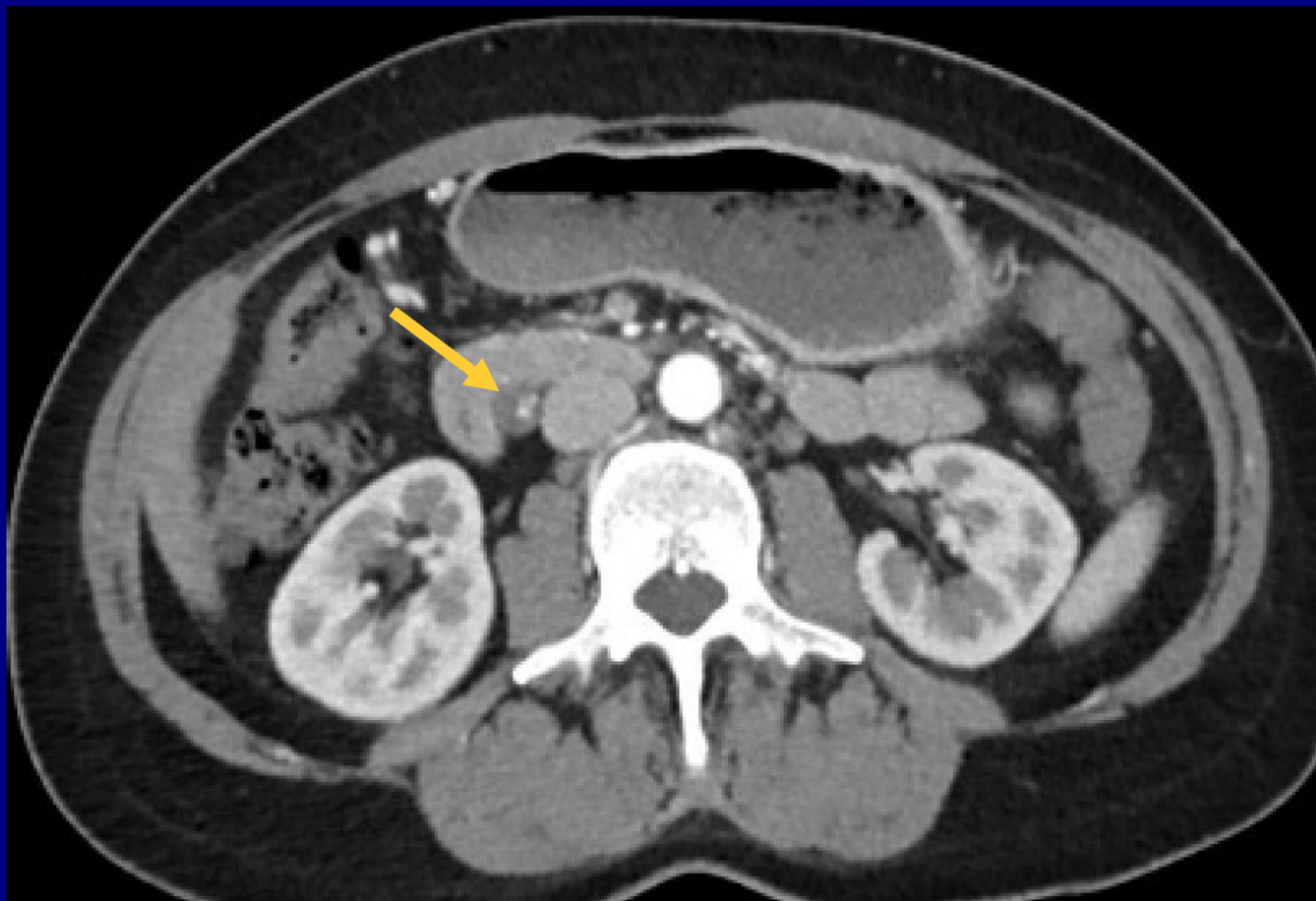


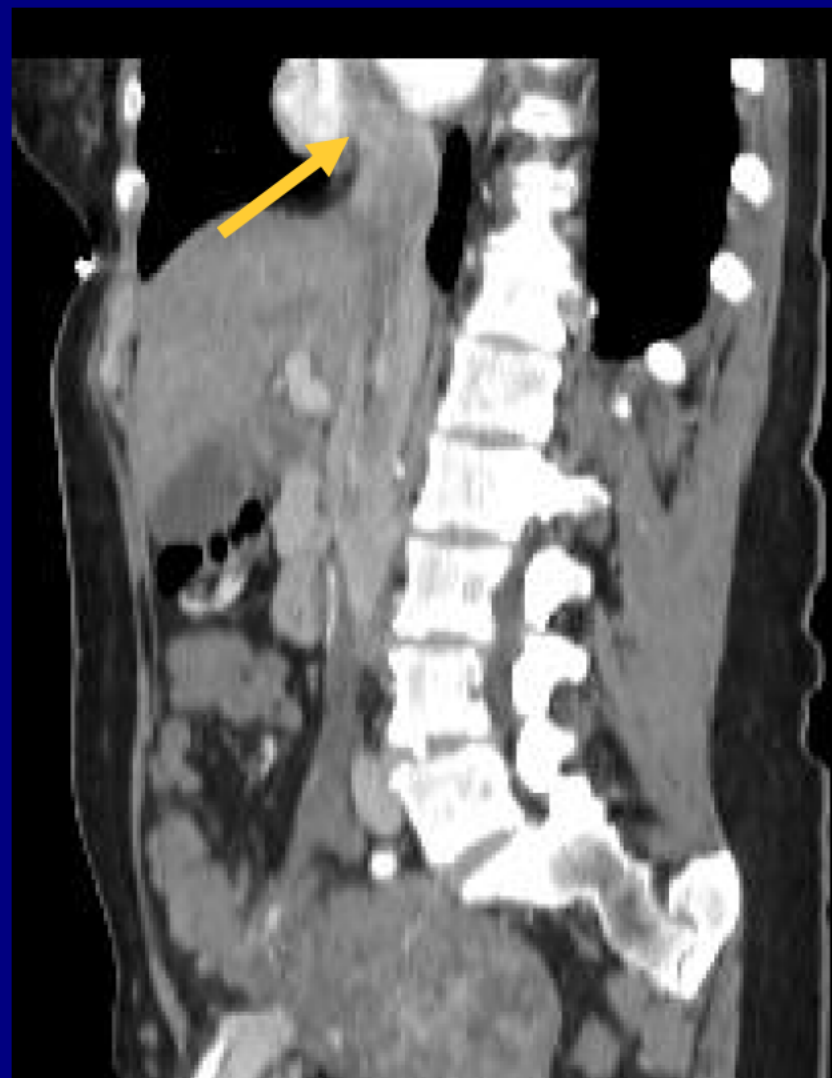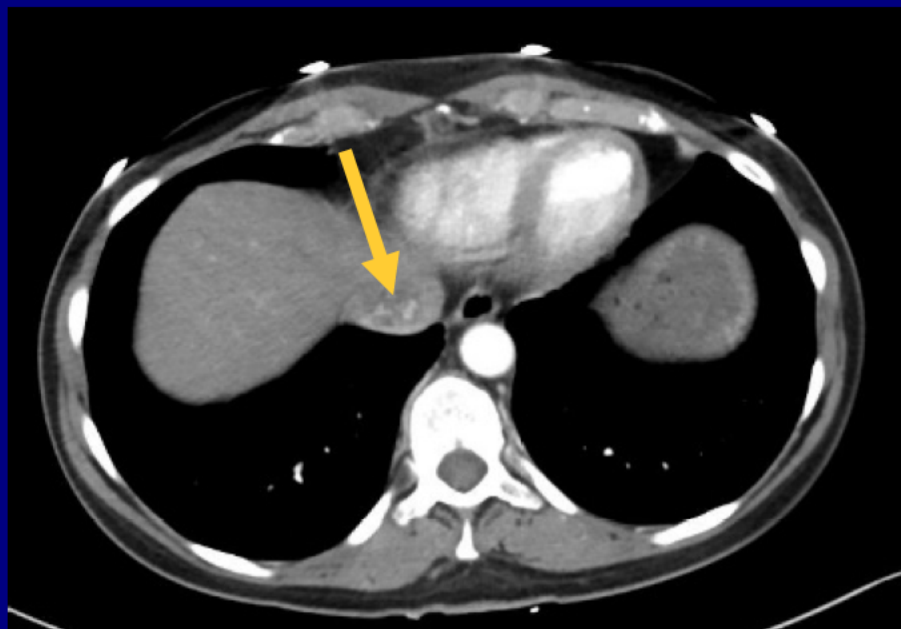



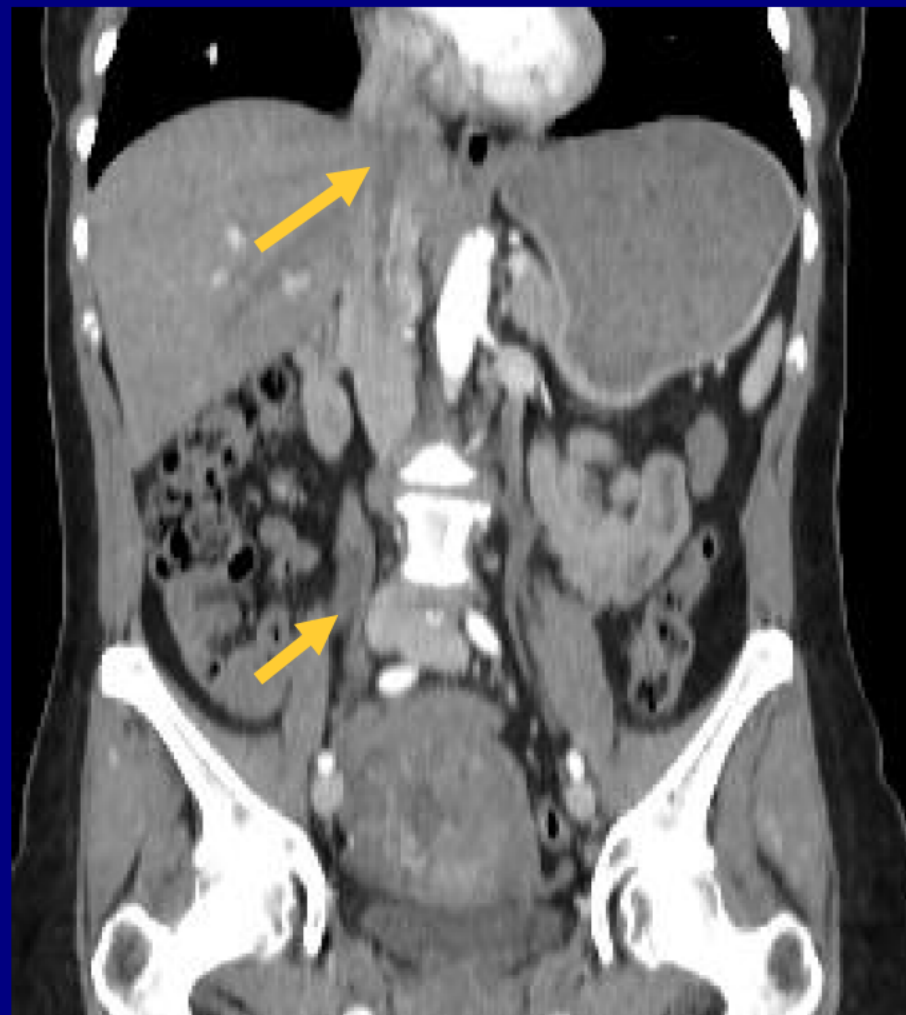
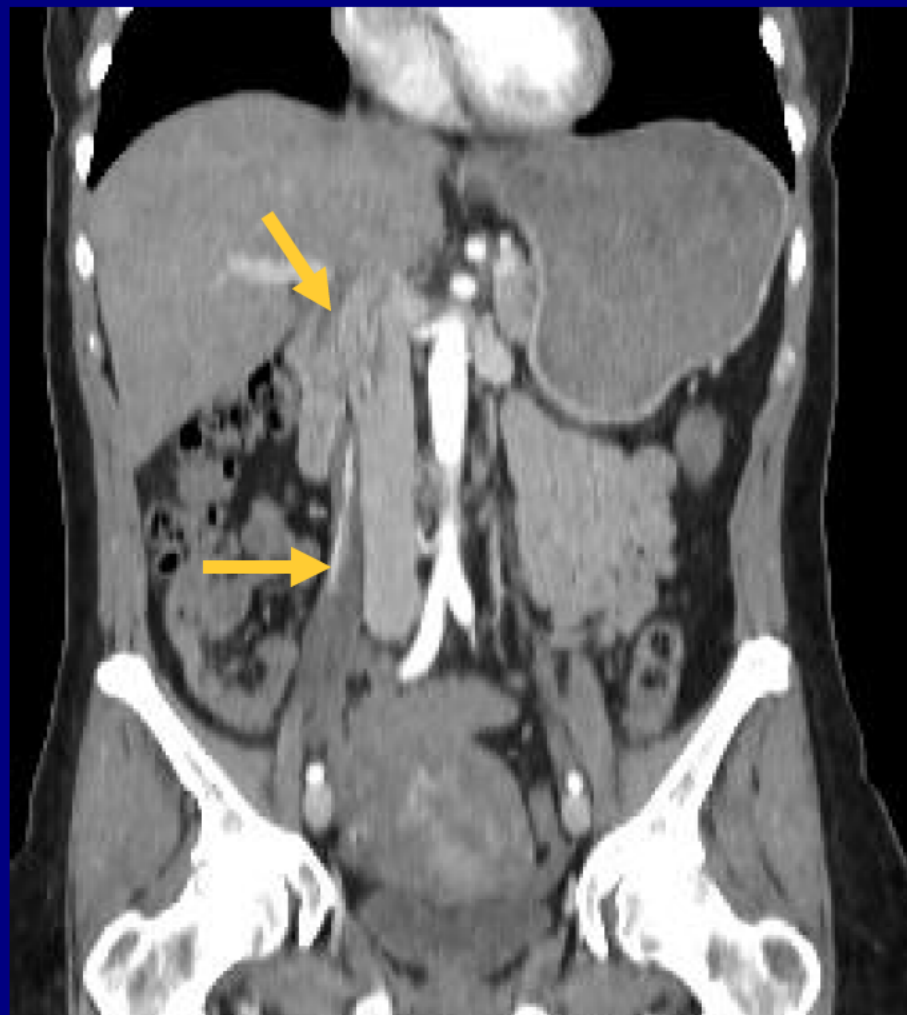



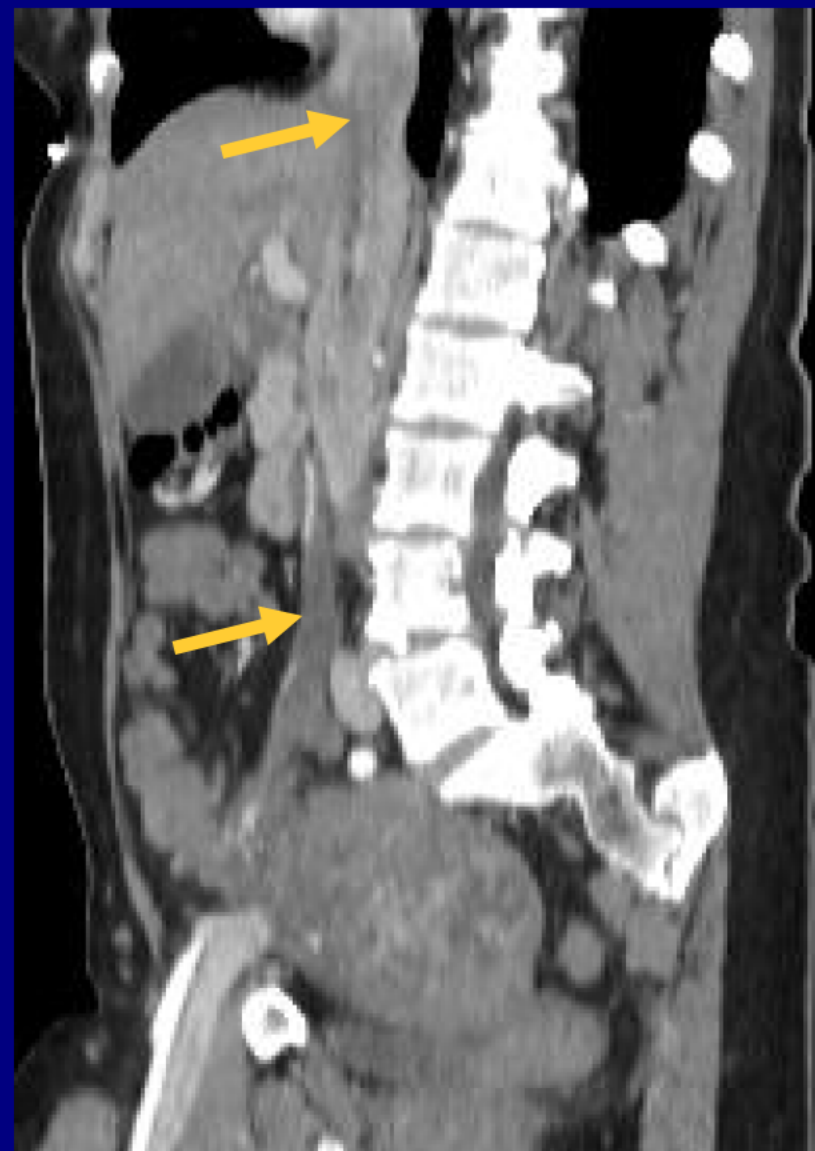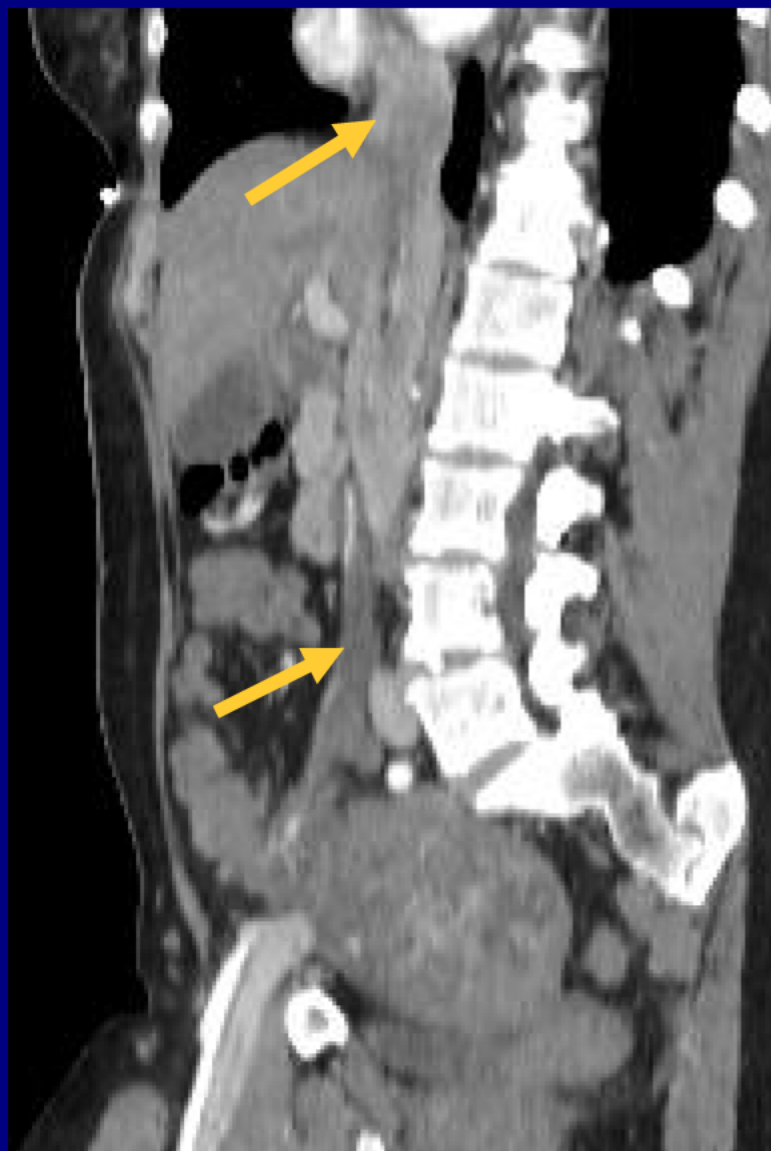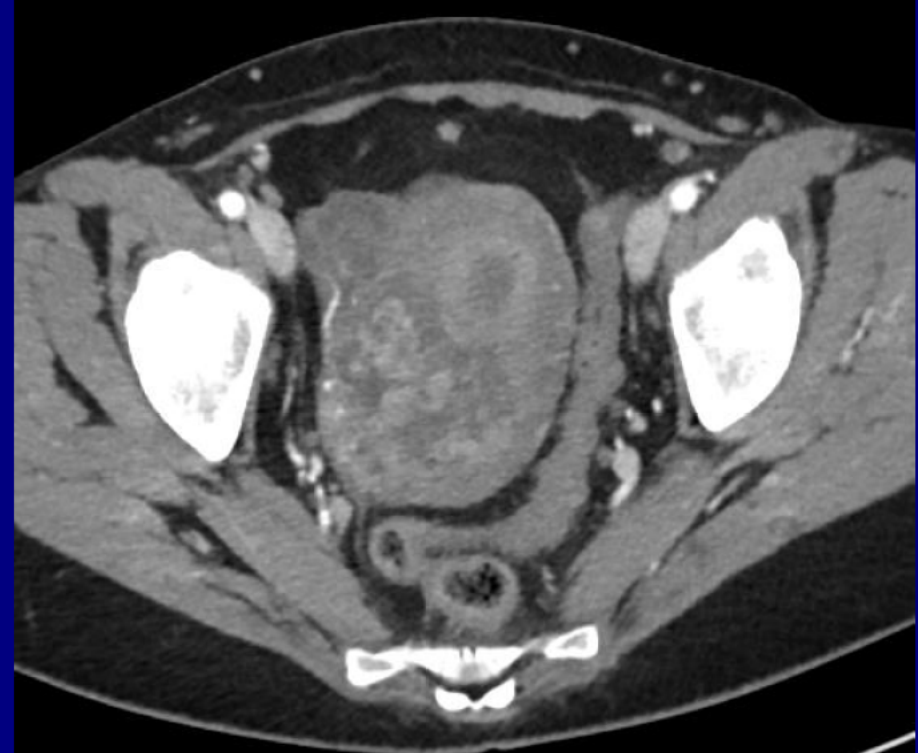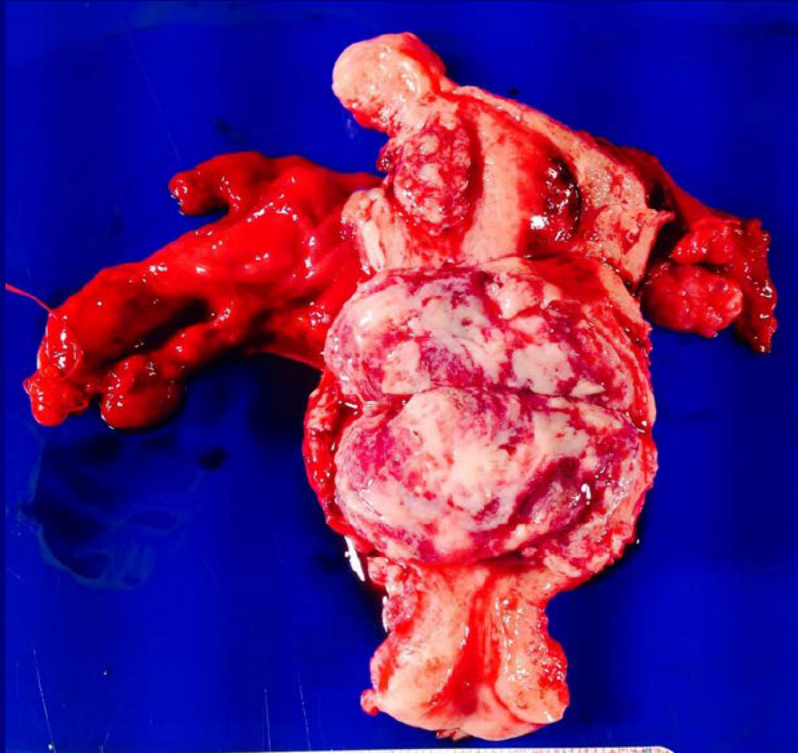


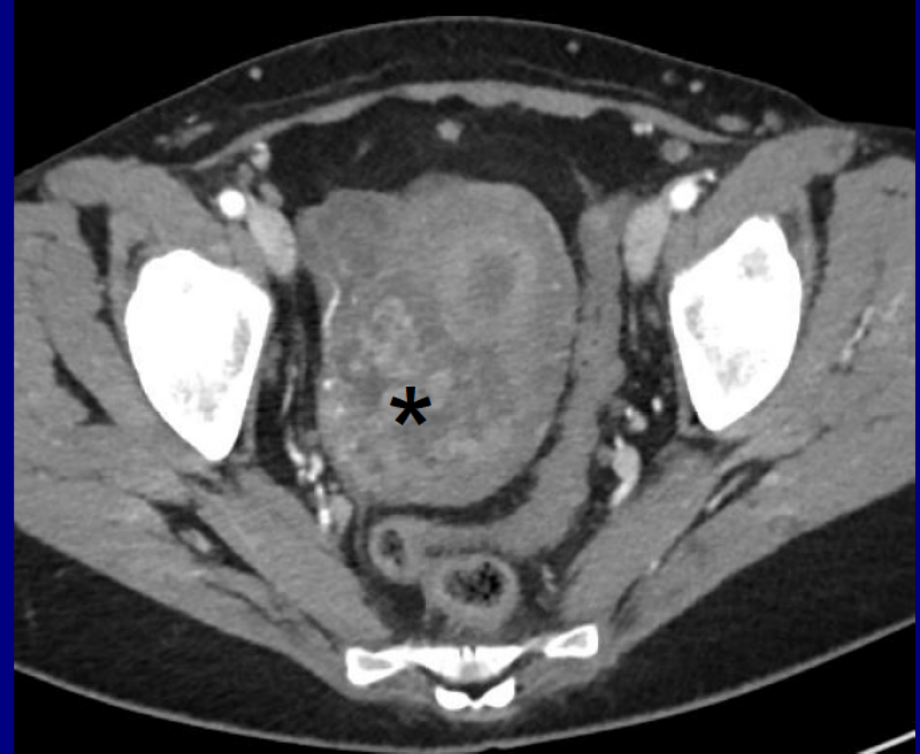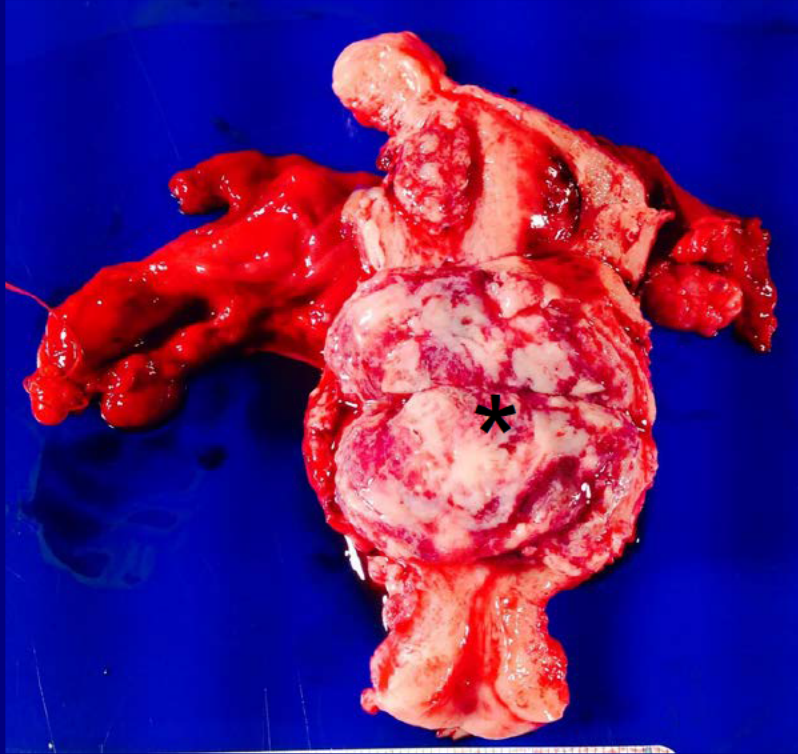




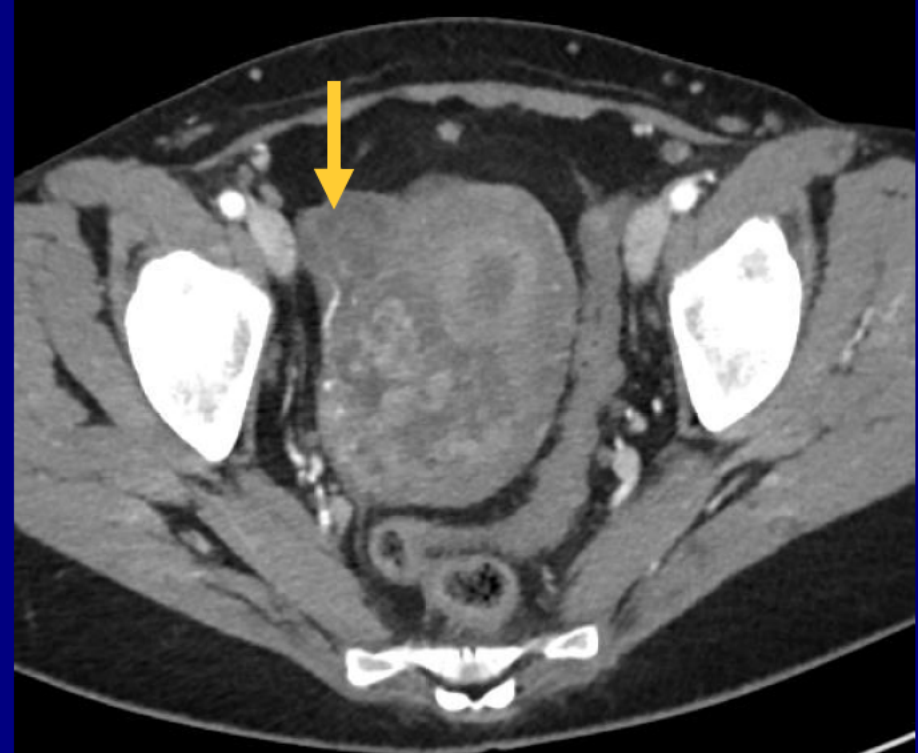
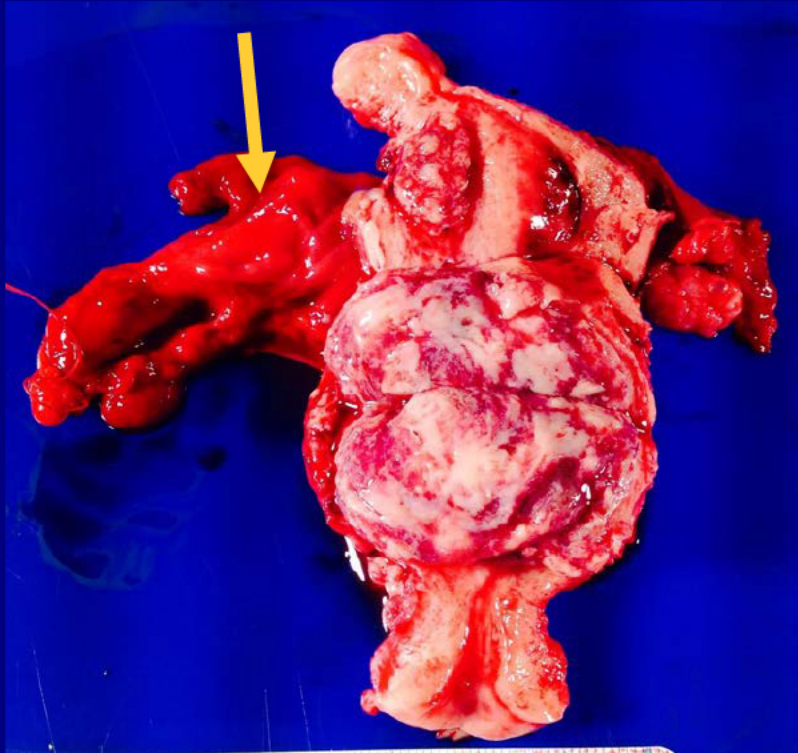




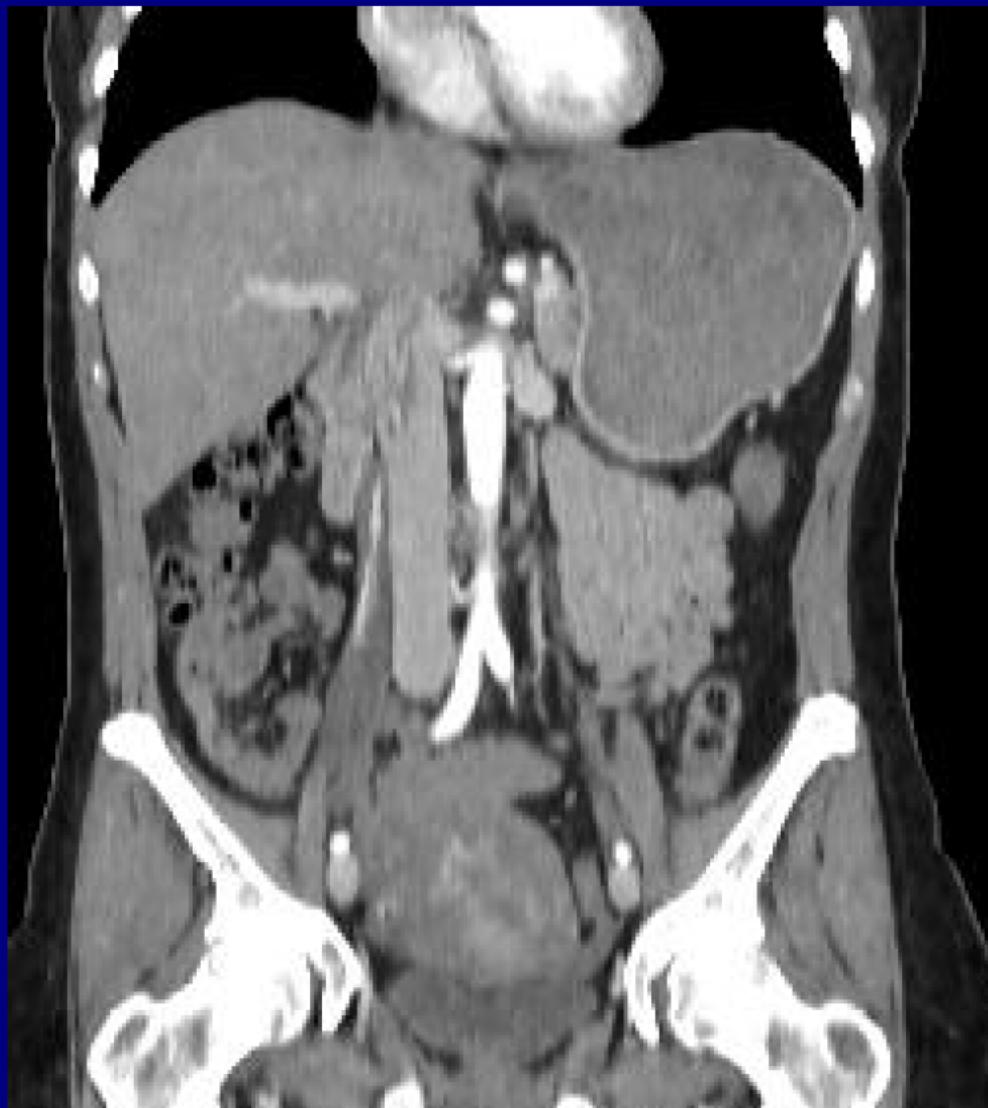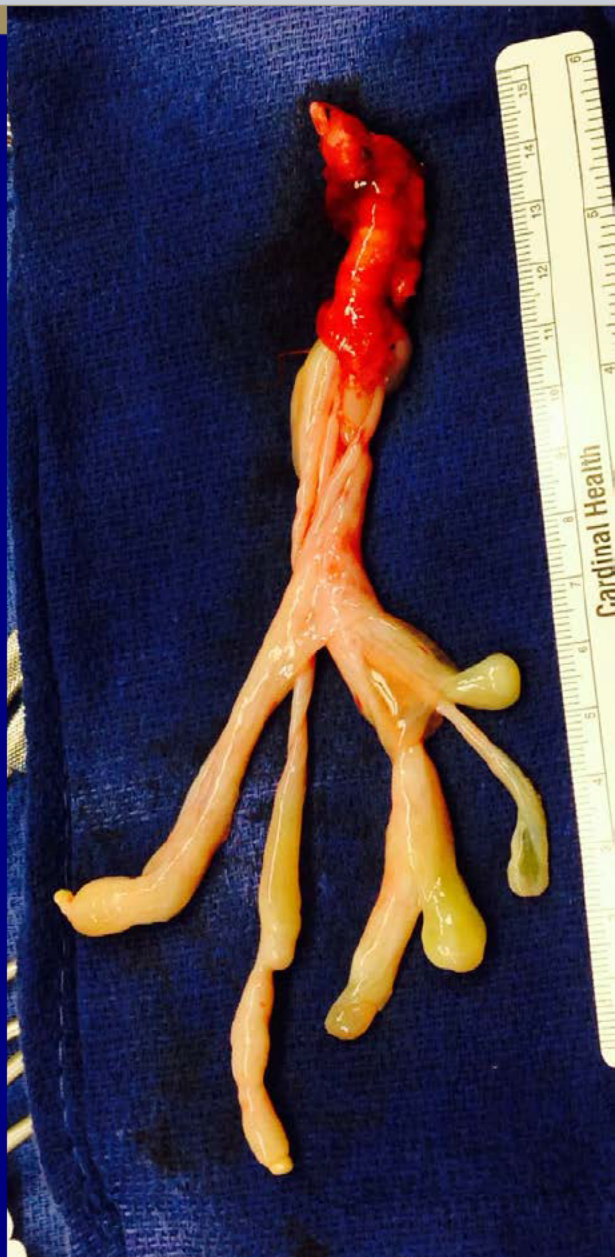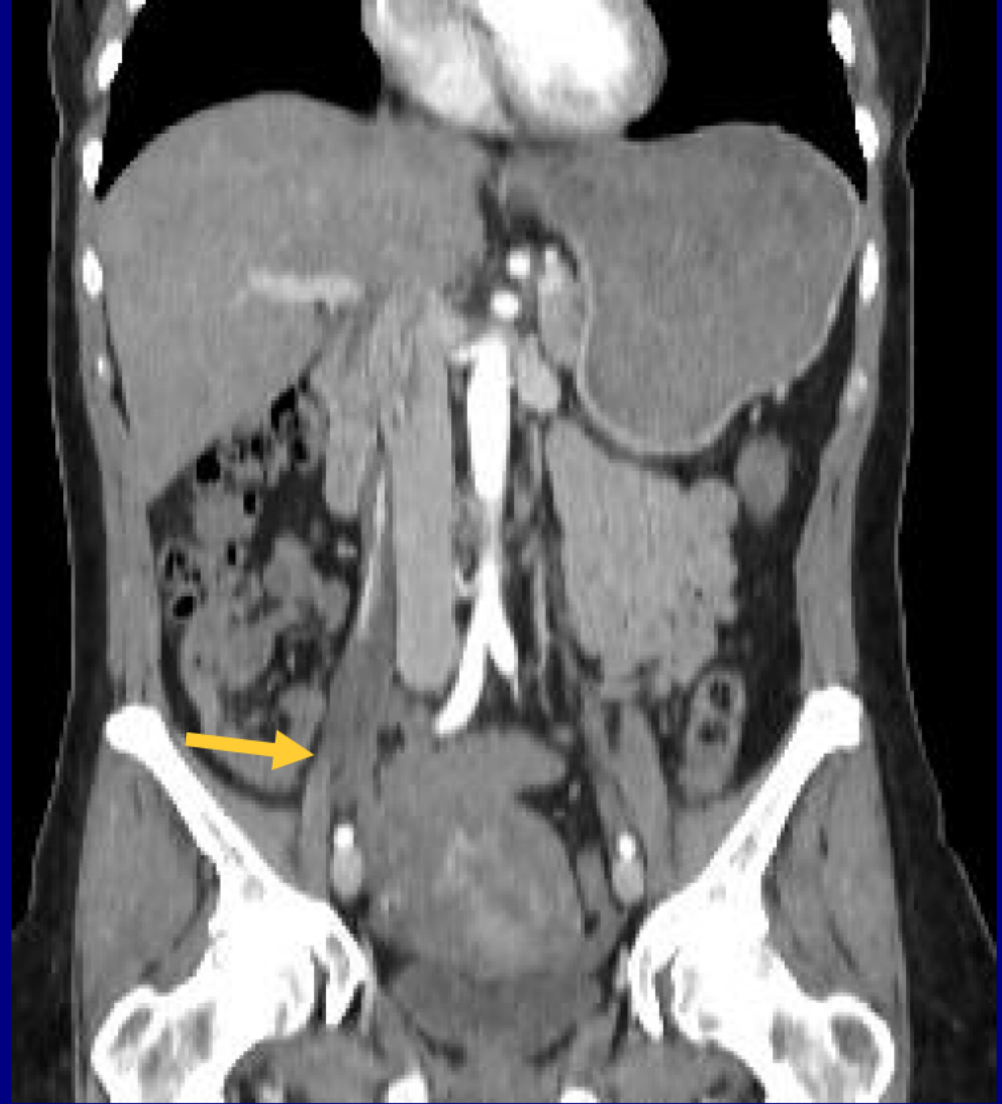
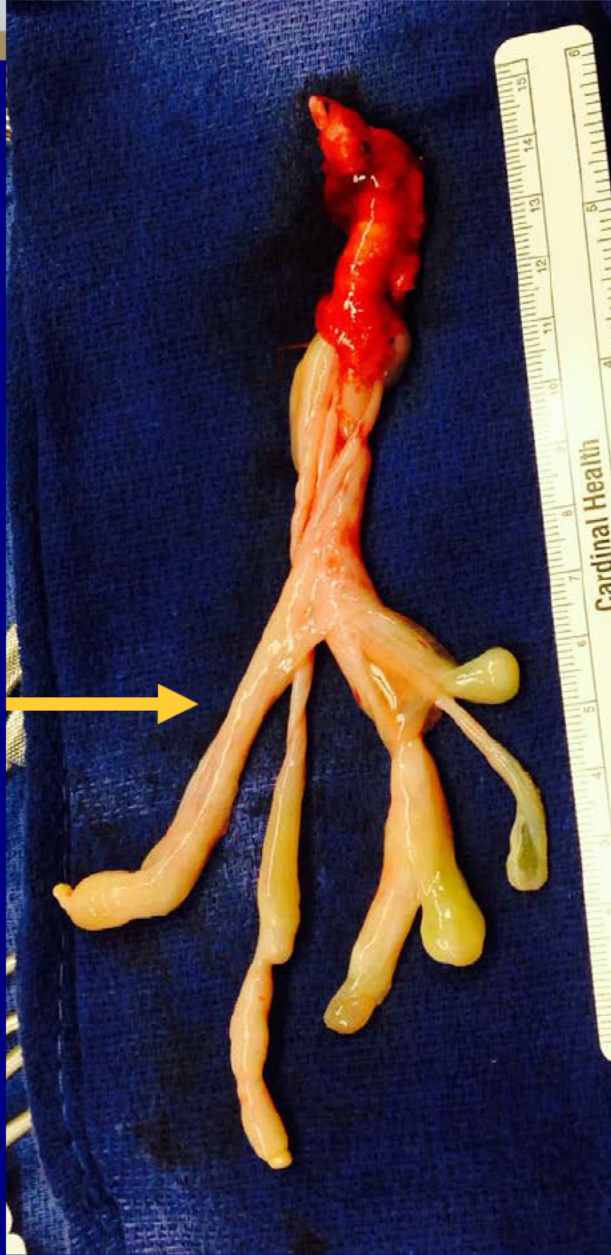




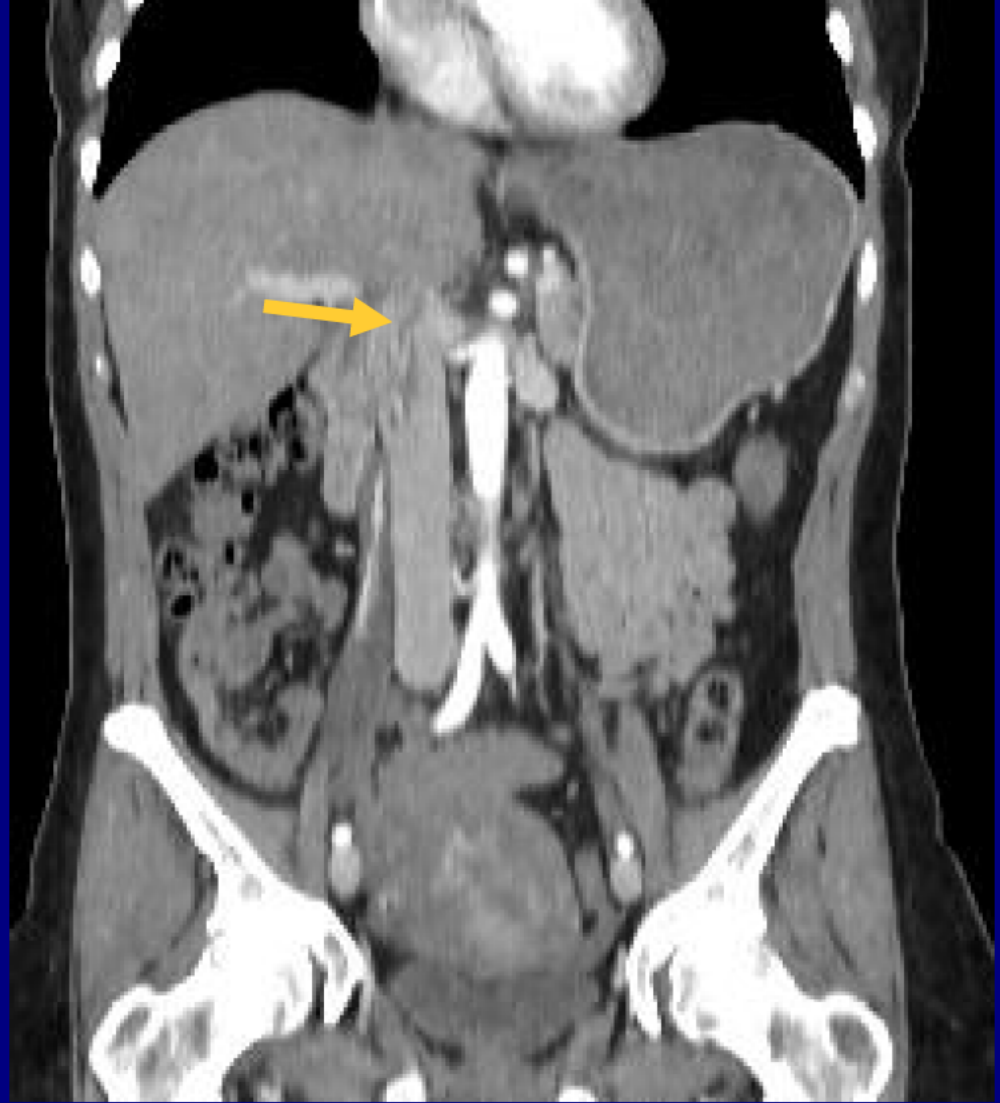


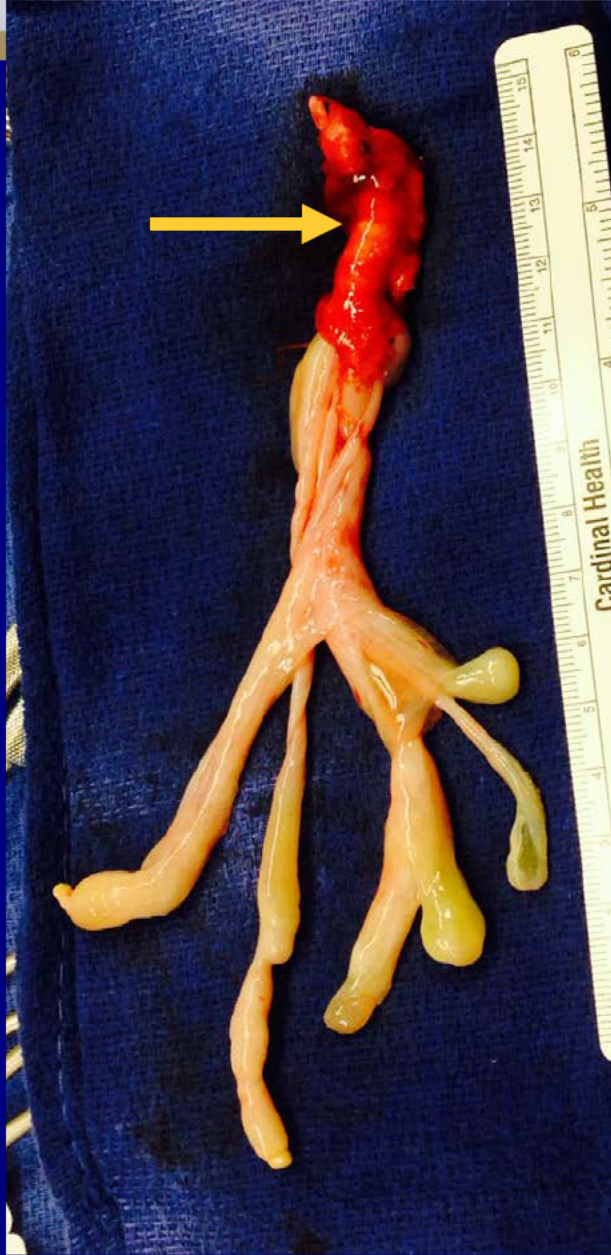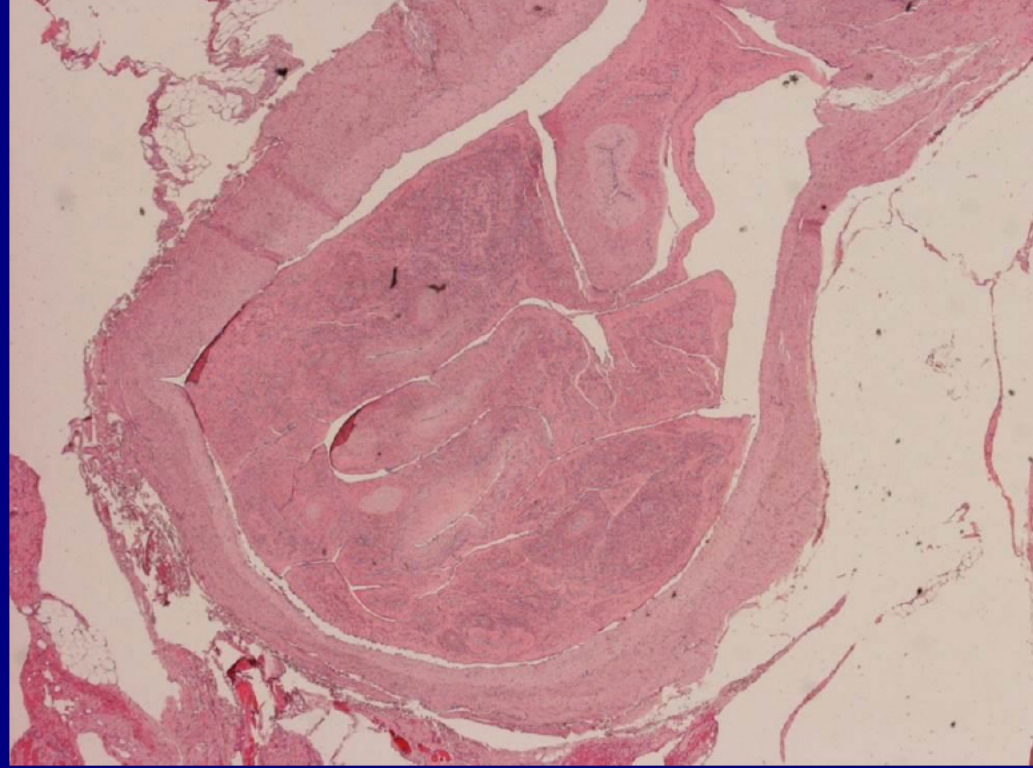




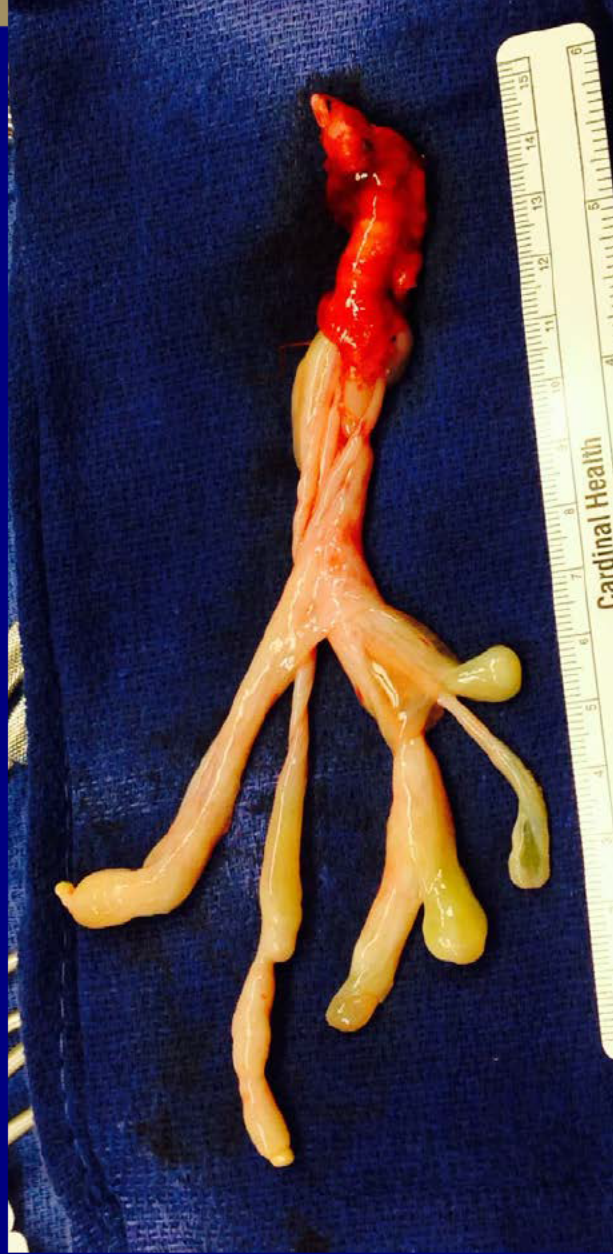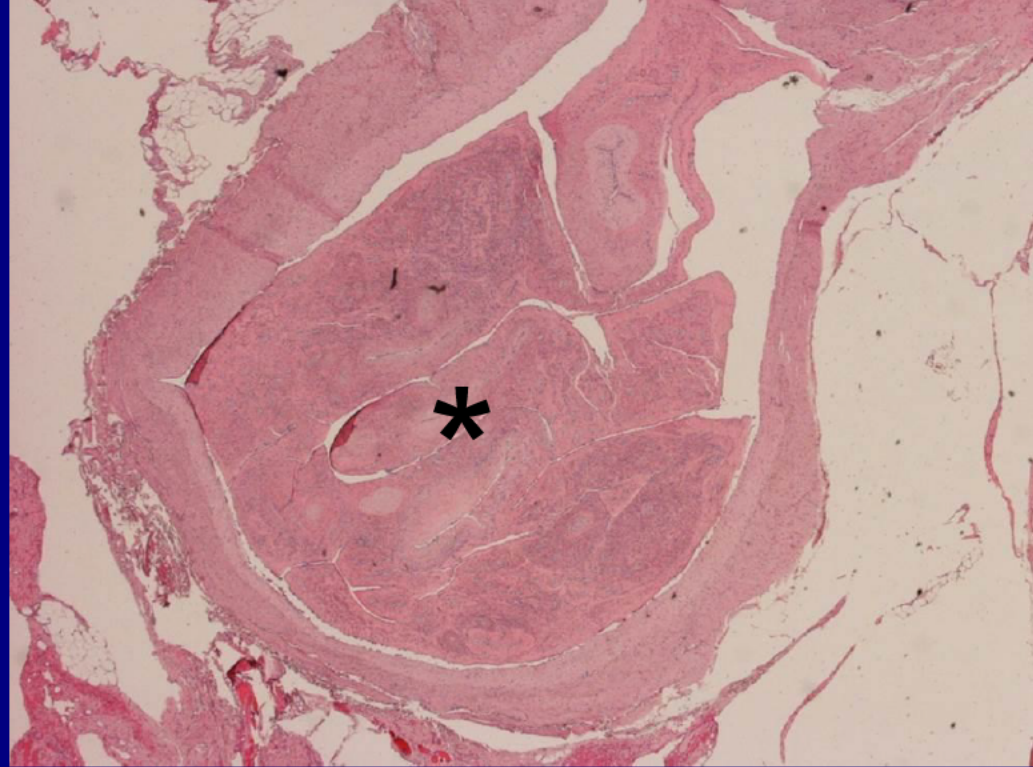




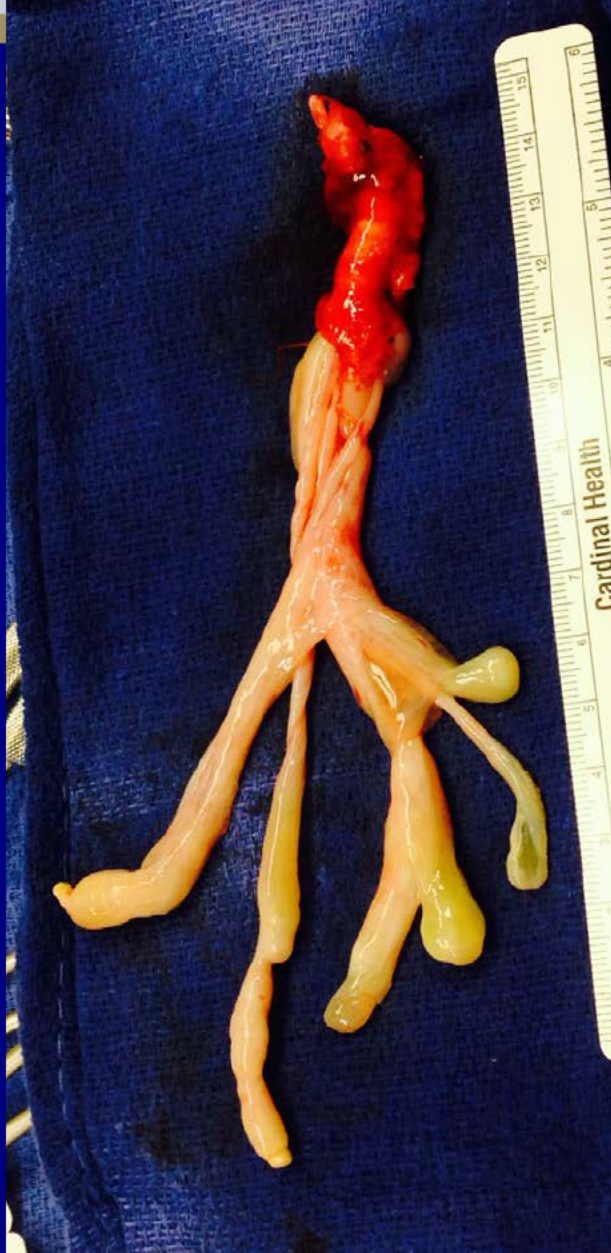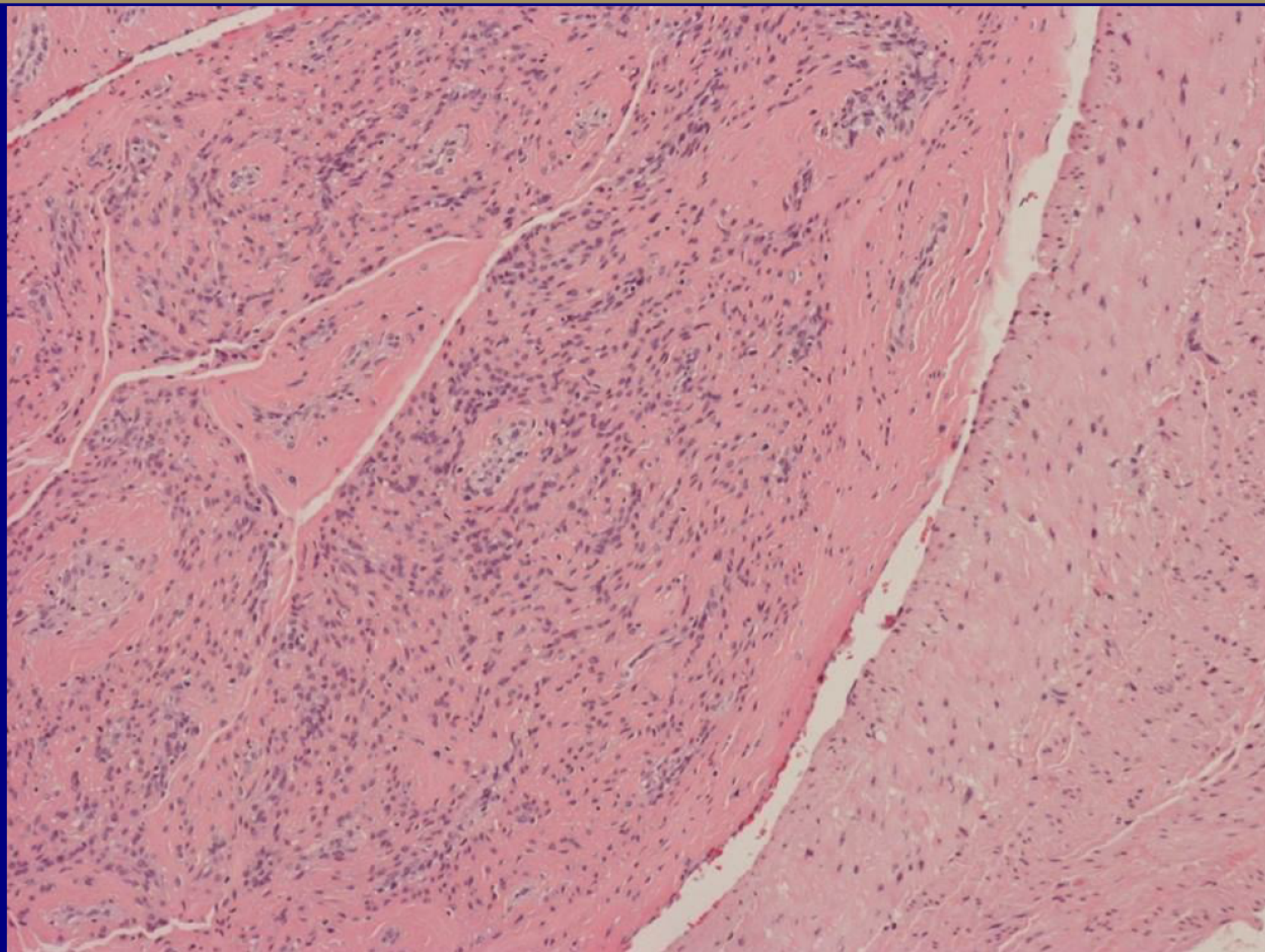




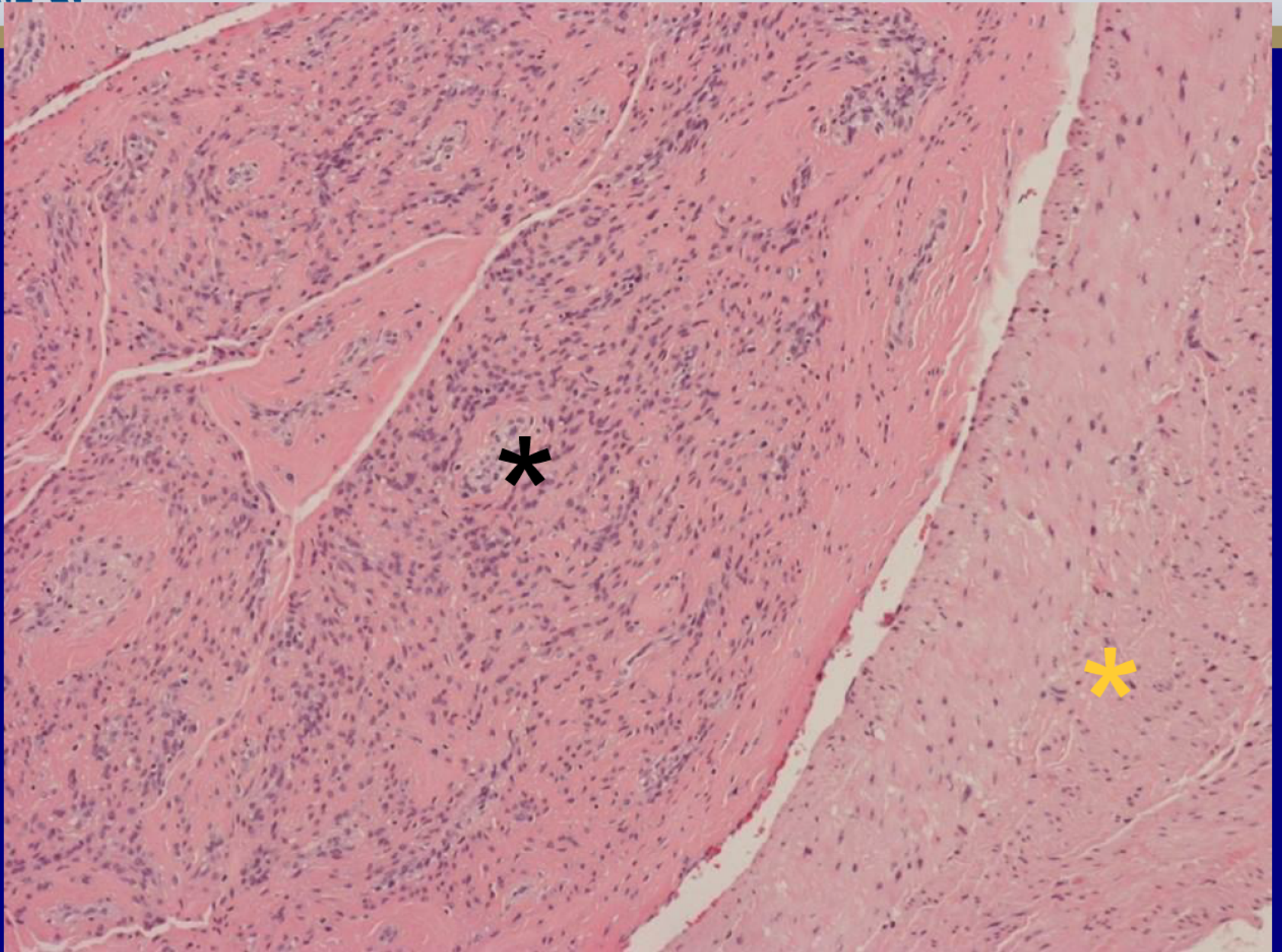




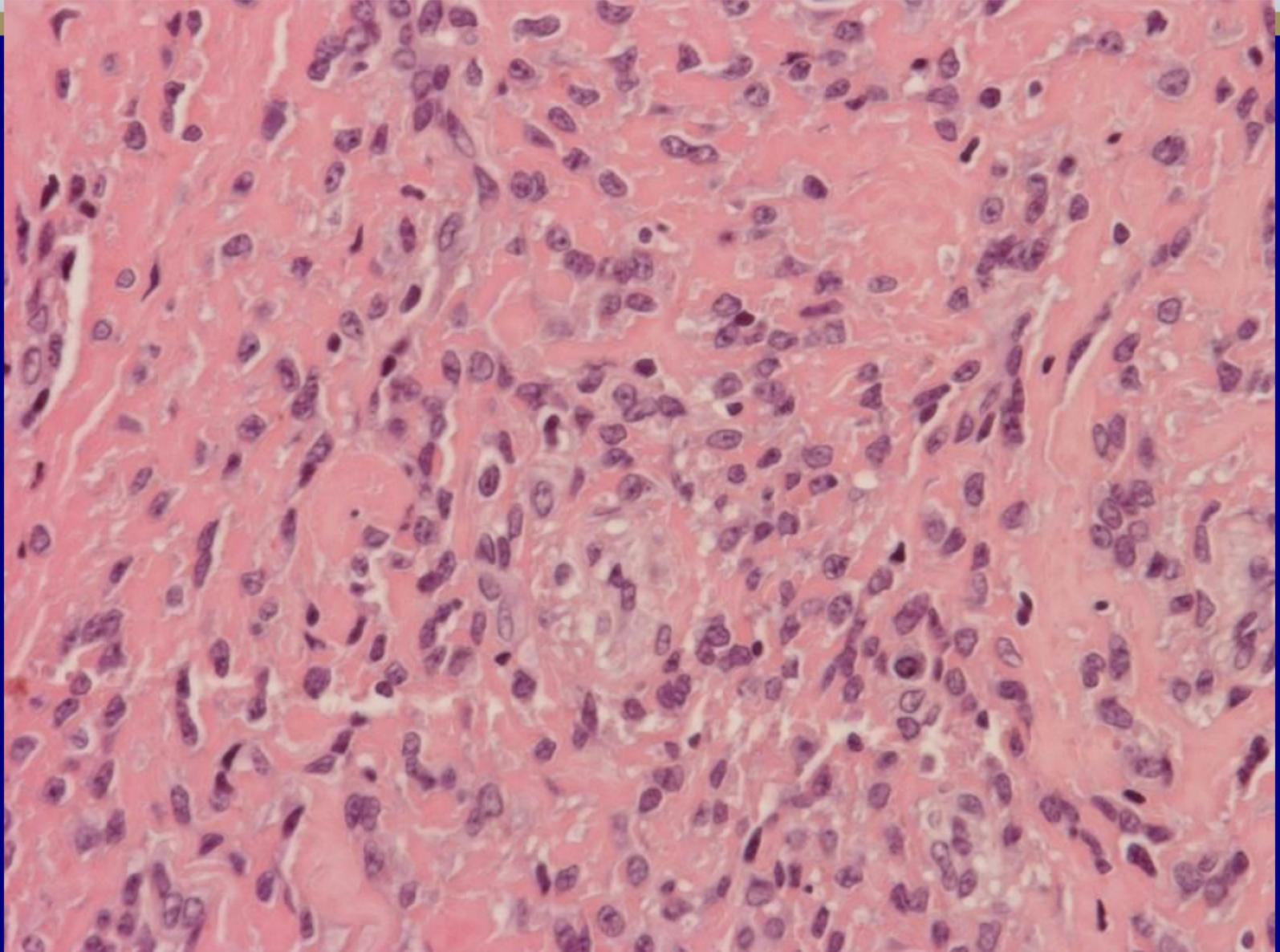














# **Intravenous Leiomyoma**

**Blake Parsons, MD**

**University of Oklahoma Medical Center  
Oklahoma City, Oklahoma**

**Many thanks to all of you for  
submitting such great cases!  
Have a safe trip home**

**From the staff of the  
American Institute for Radiologic Pathology**