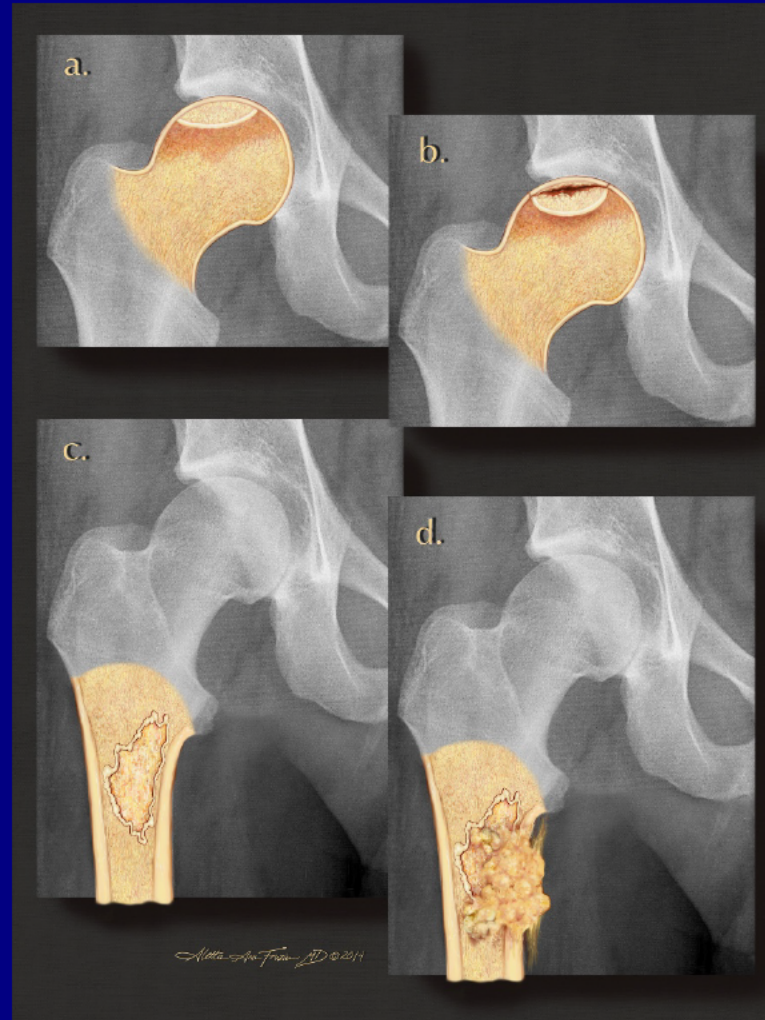


# Best Cases of the AIRP

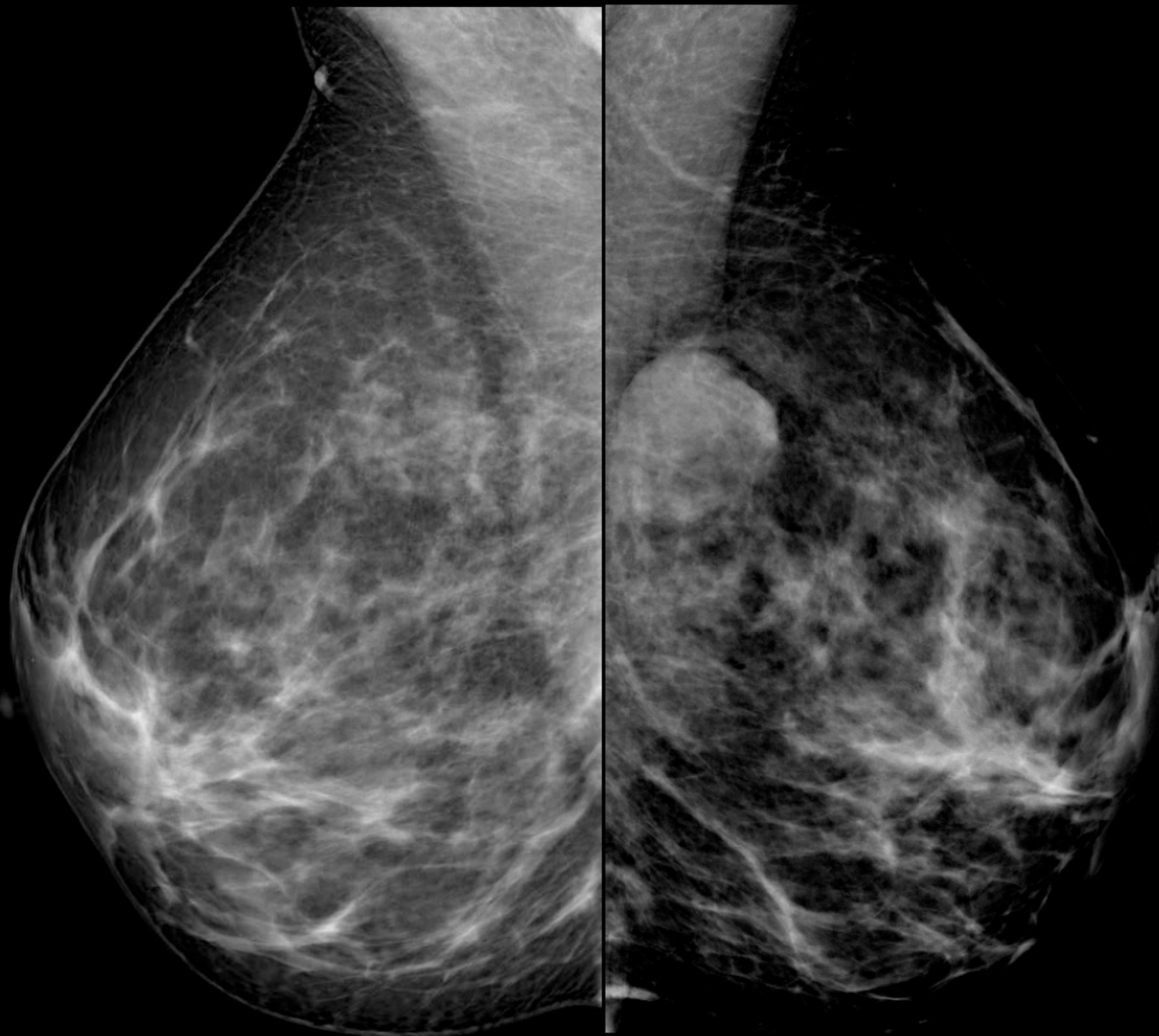
April-May, 2016



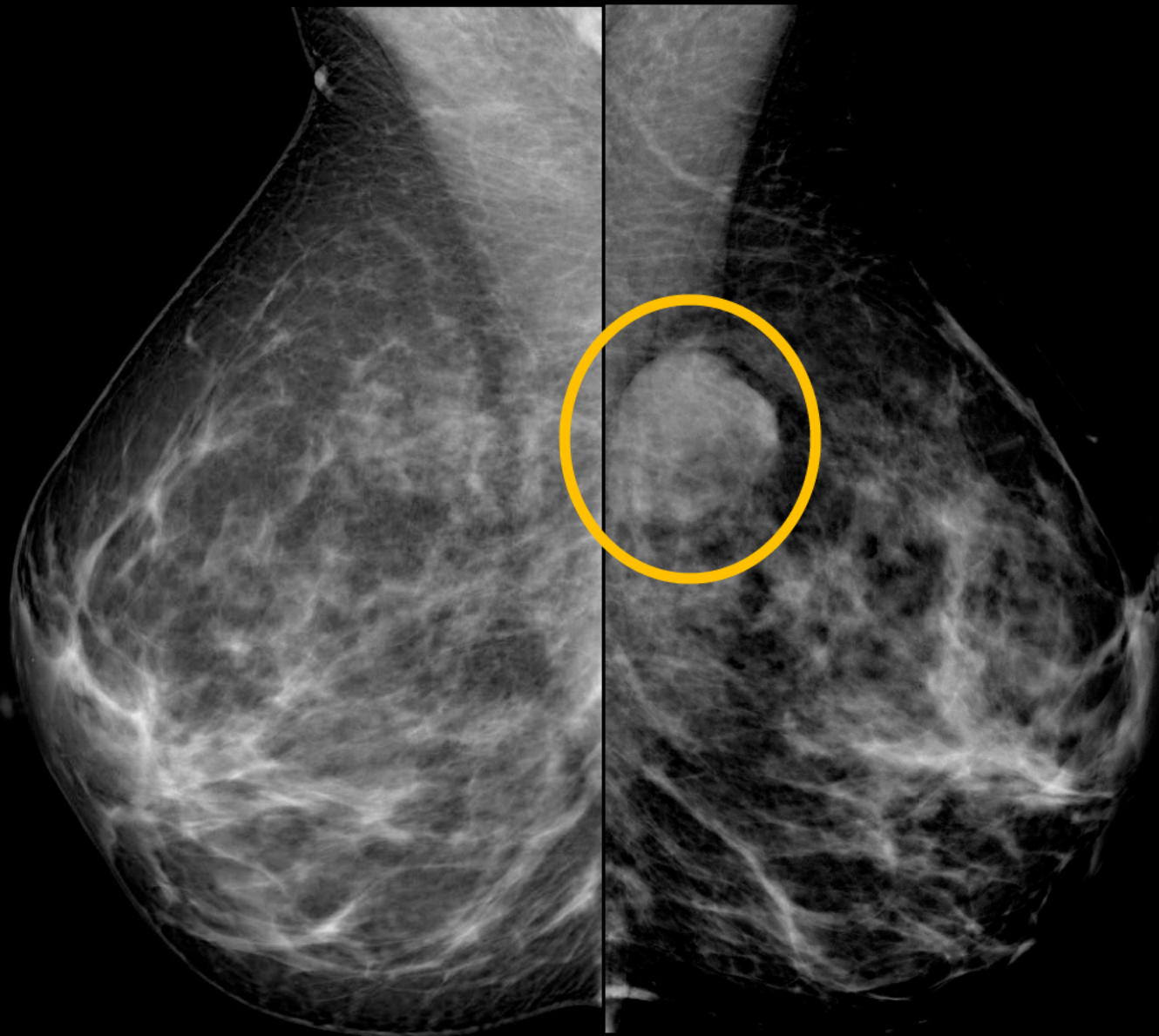
# Musculoskeletal Best Case



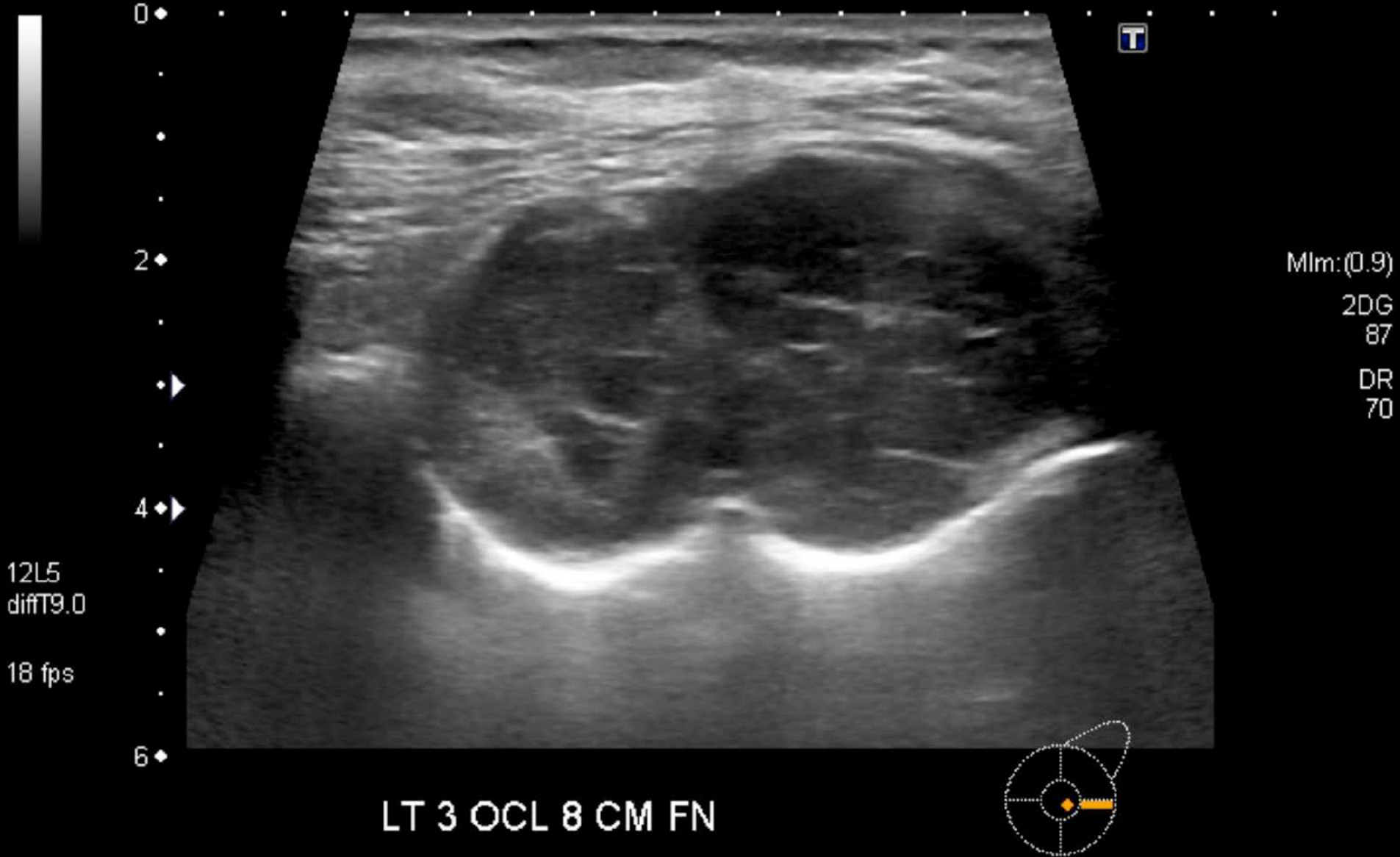
**51-year-old female presenting for  
diagnostic mammogram found to  
have an incidental chest wall  
mass**



**Mediolateral oblique view**

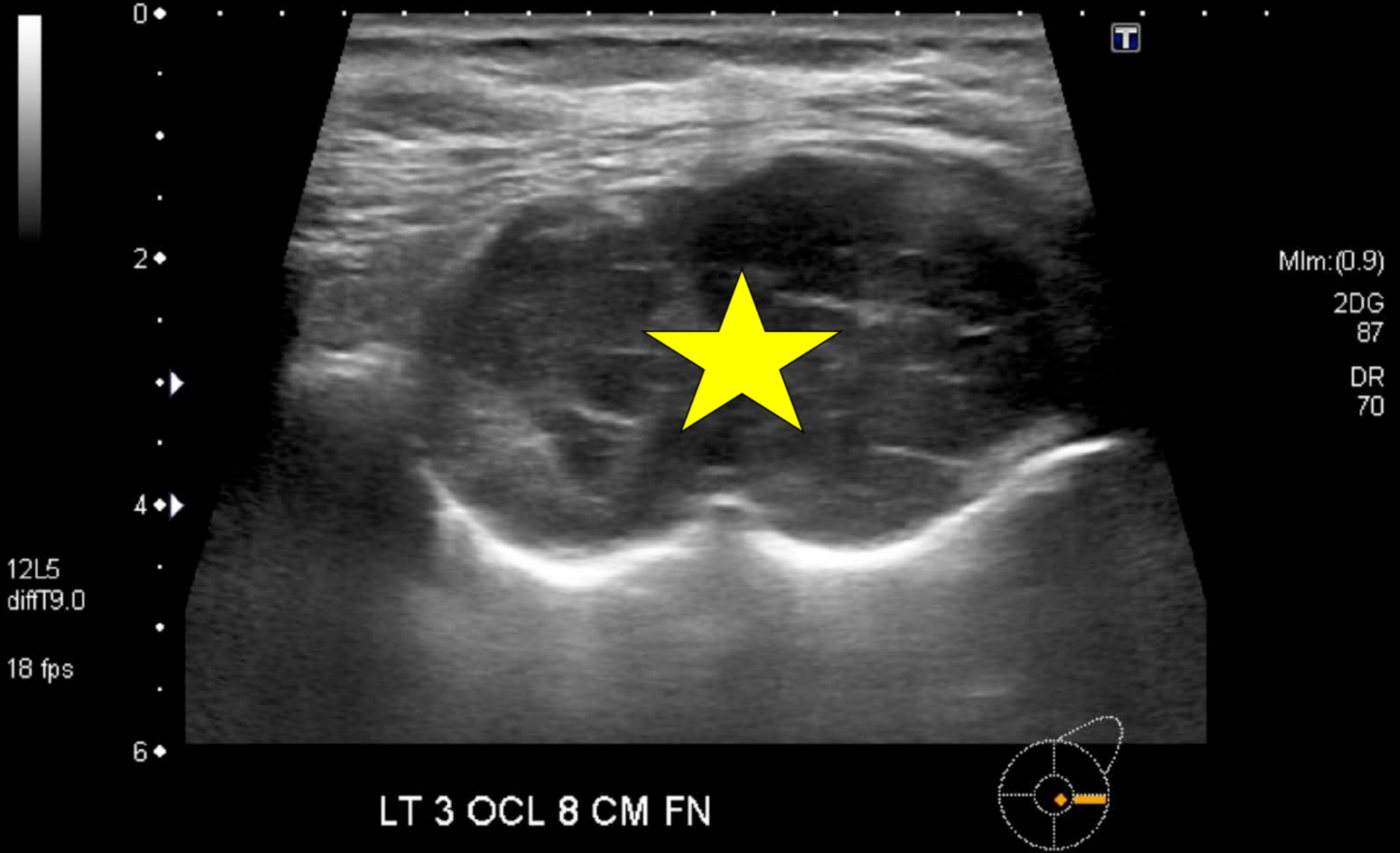


**Mediolateral oblique view**



**Breast US**



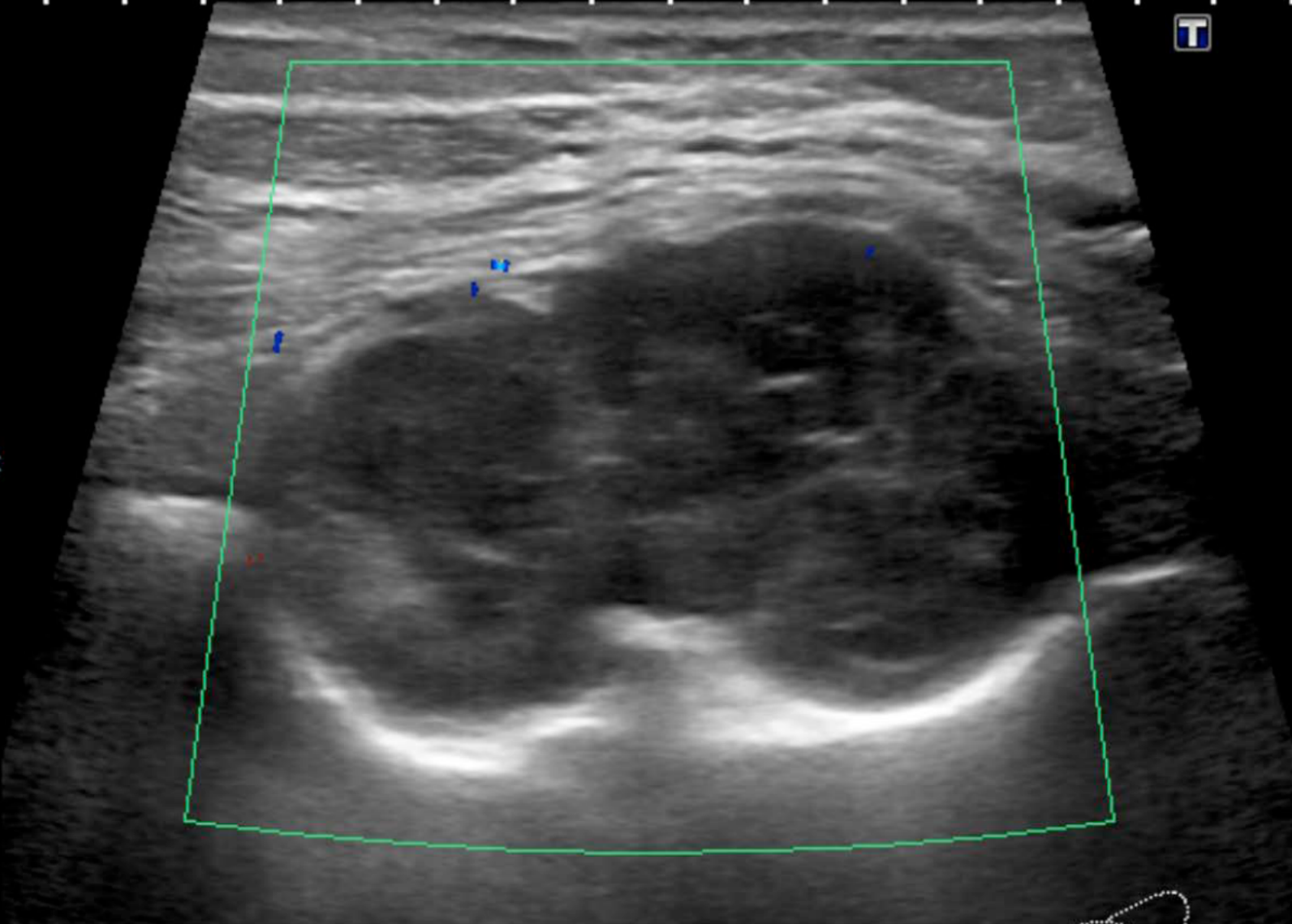


**Breast US**



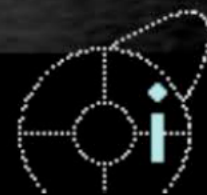3.8  
cm/s

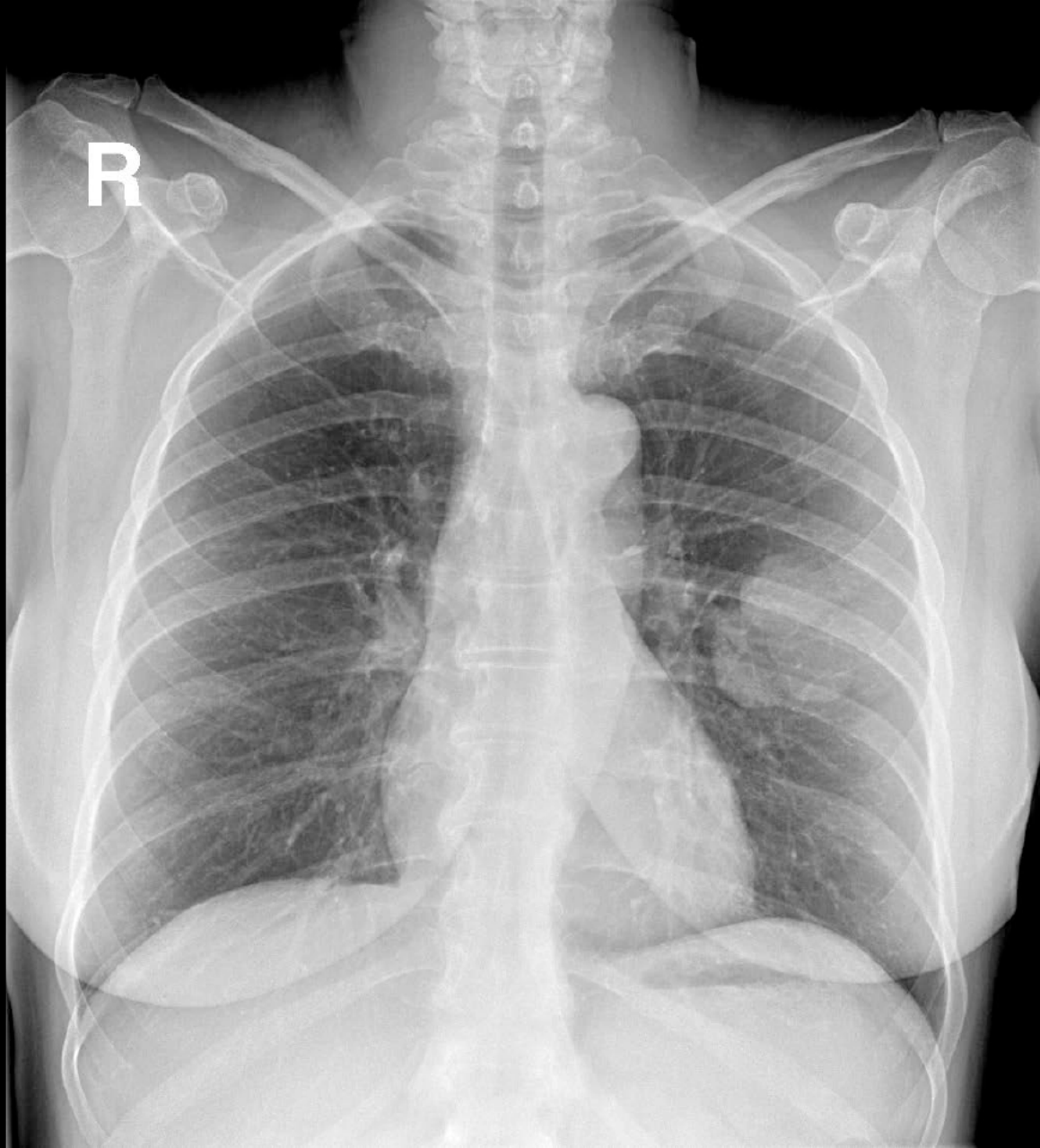
12L5  
diffT9.0  
CF 6.1  
5 fps



LT 3 OCL 8 CM FN

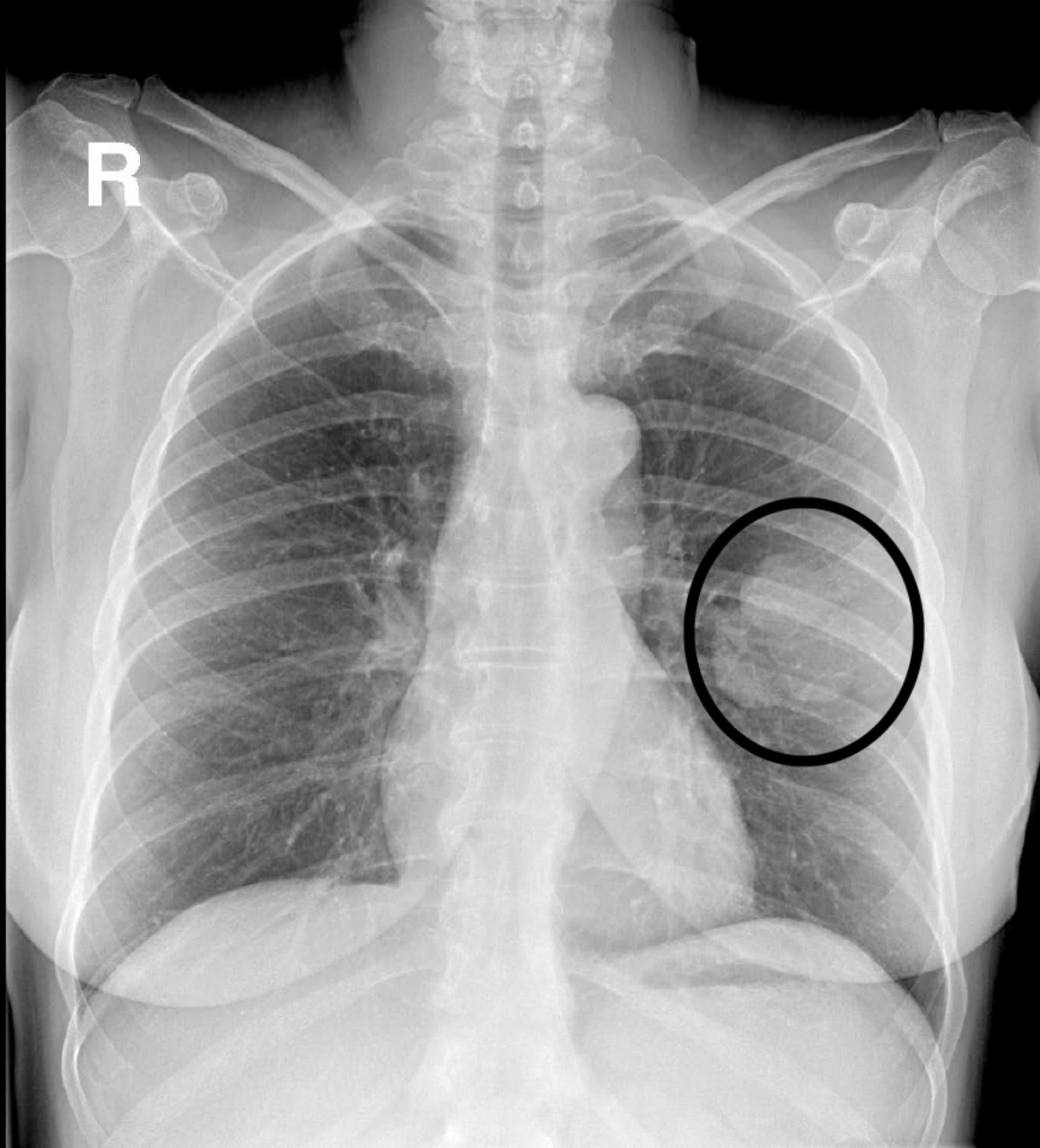
**Doppler US**



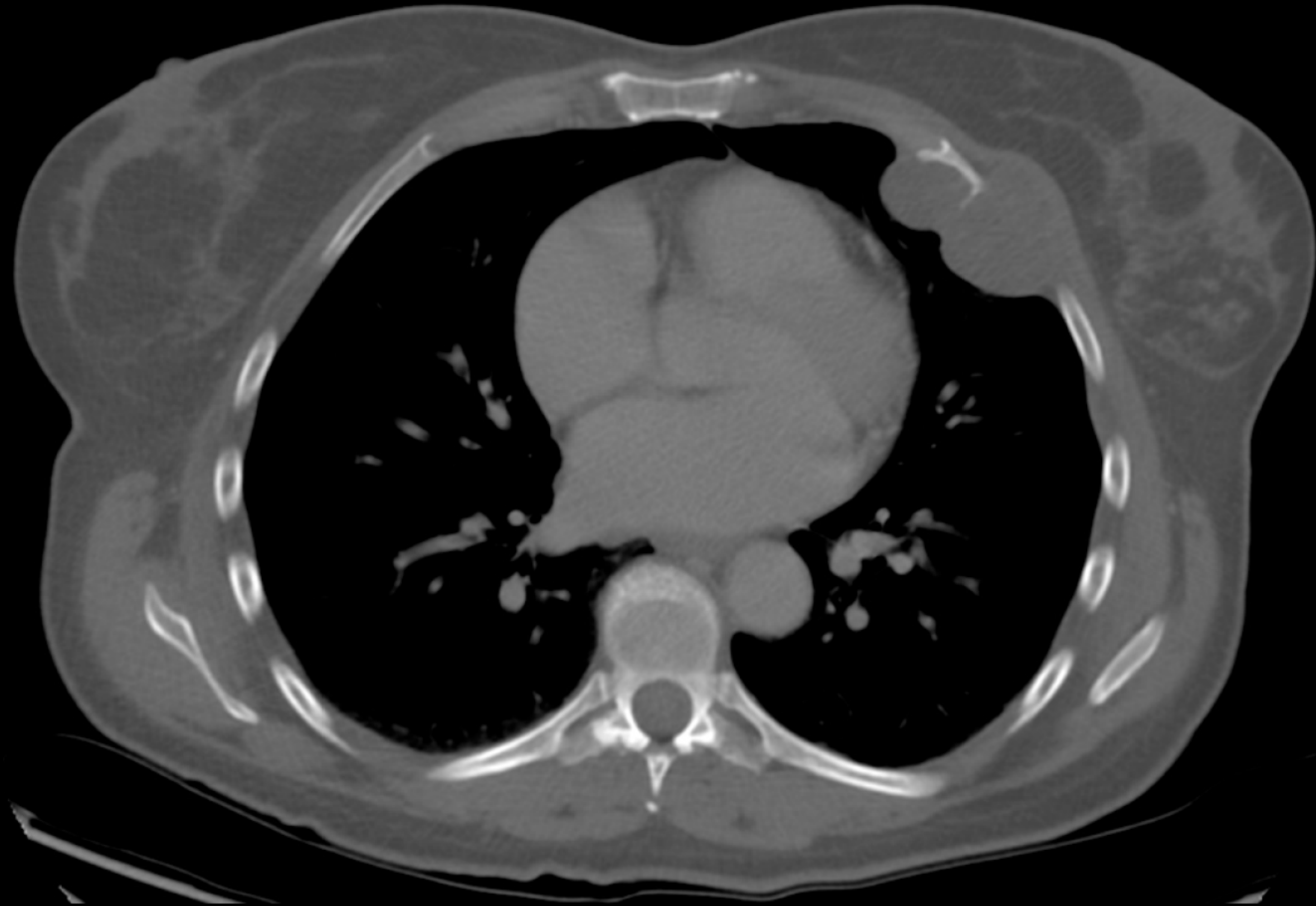


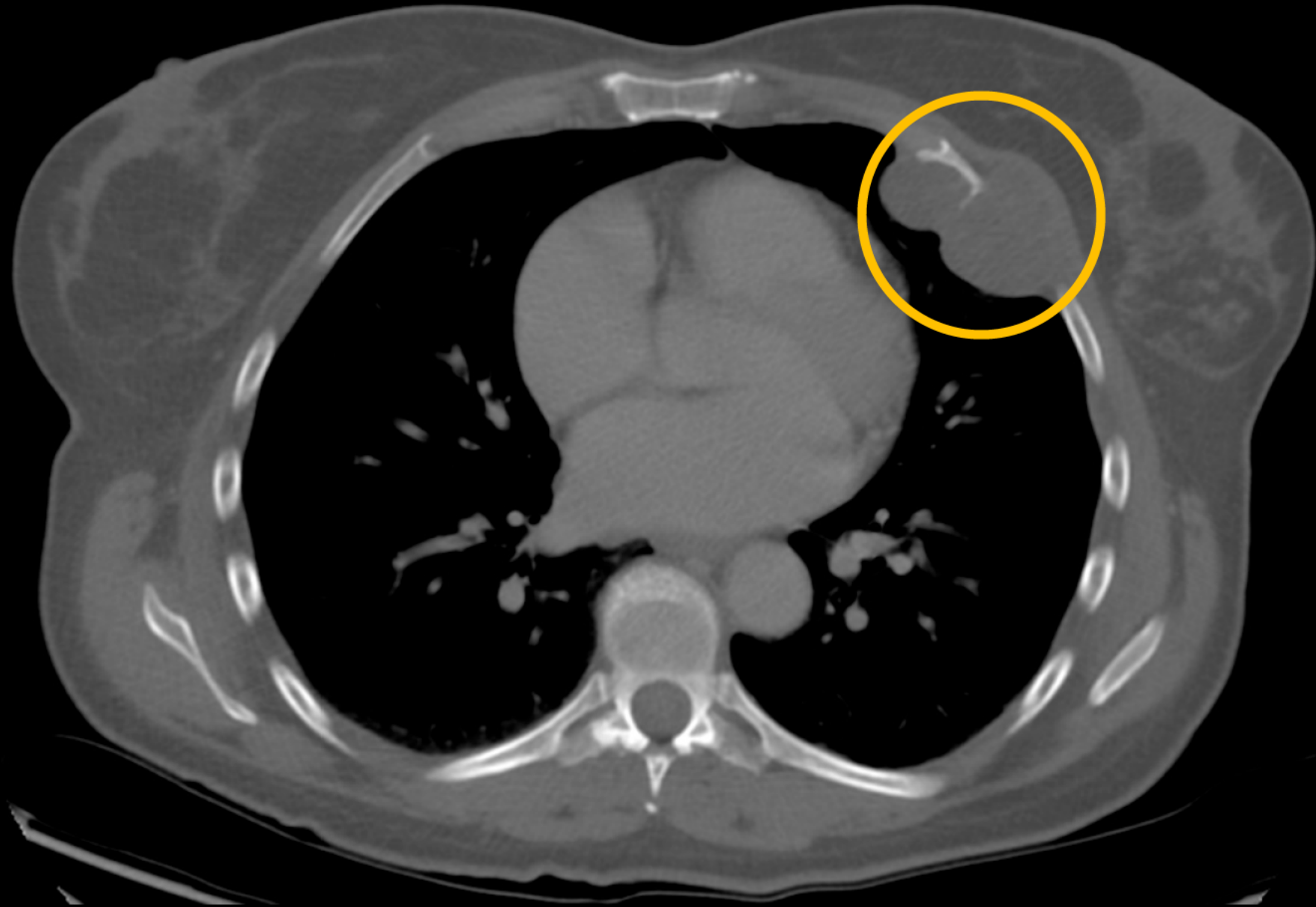
**Chest radiograph**

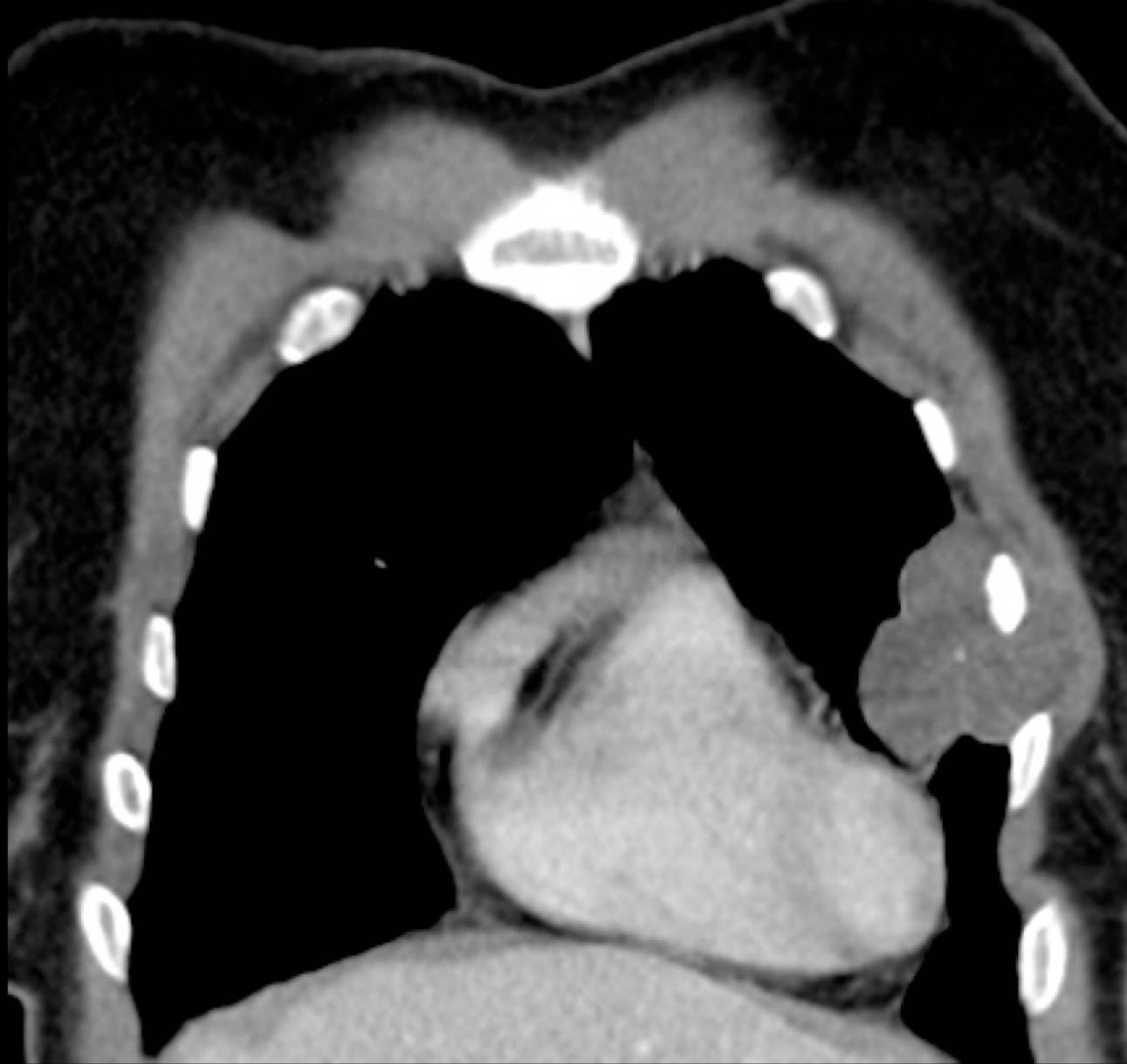

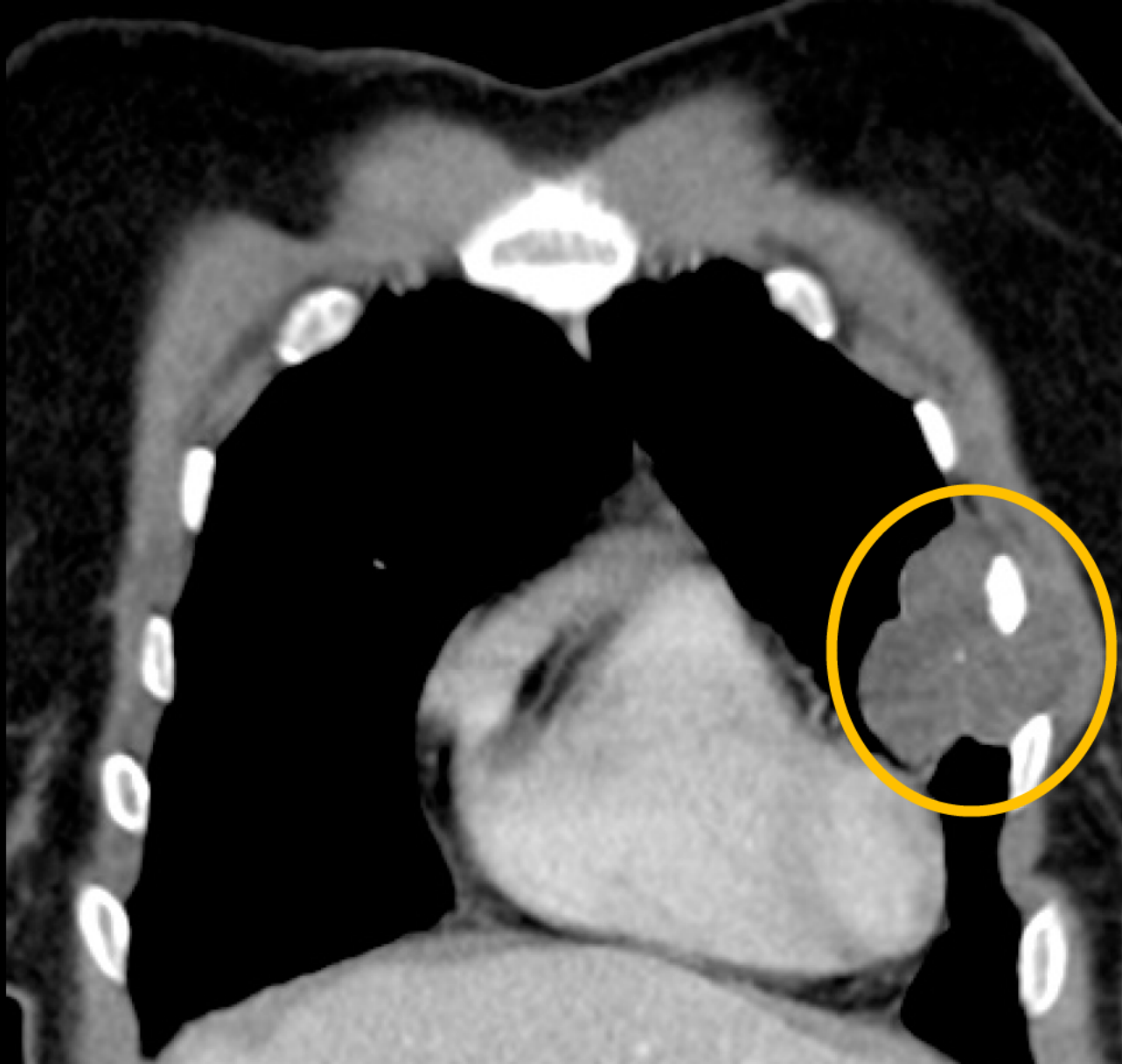


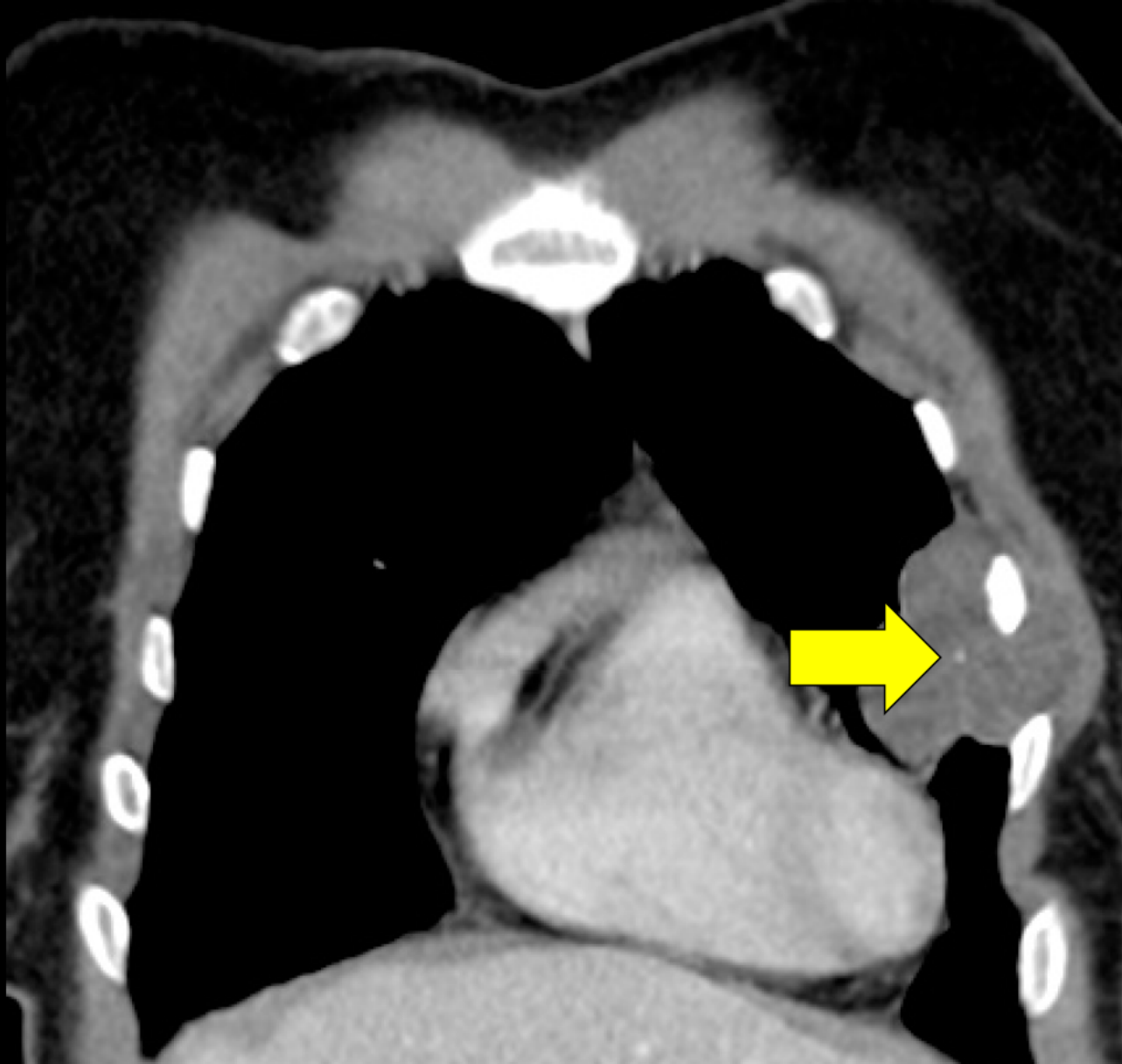
**Chest radiograph**

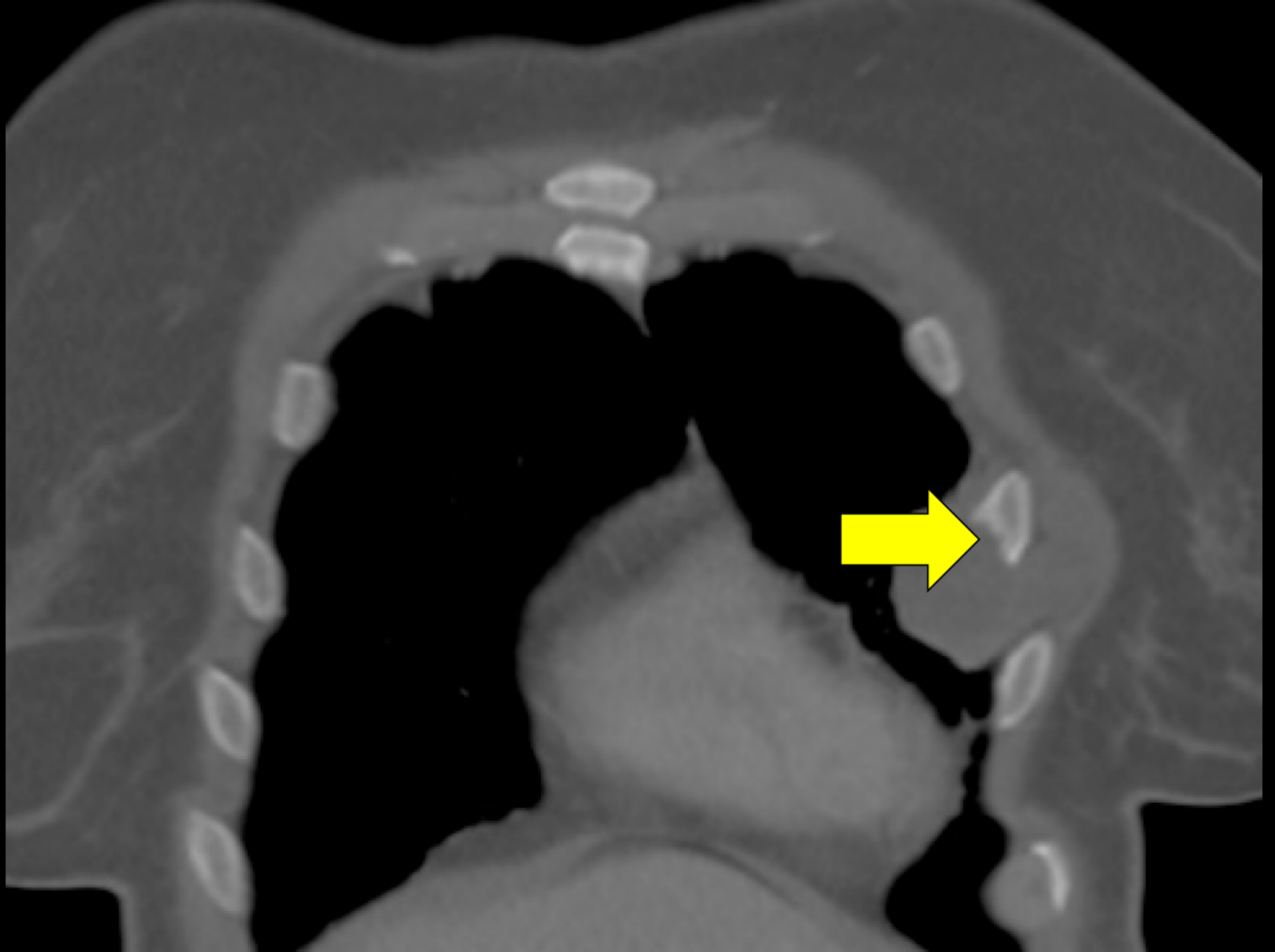




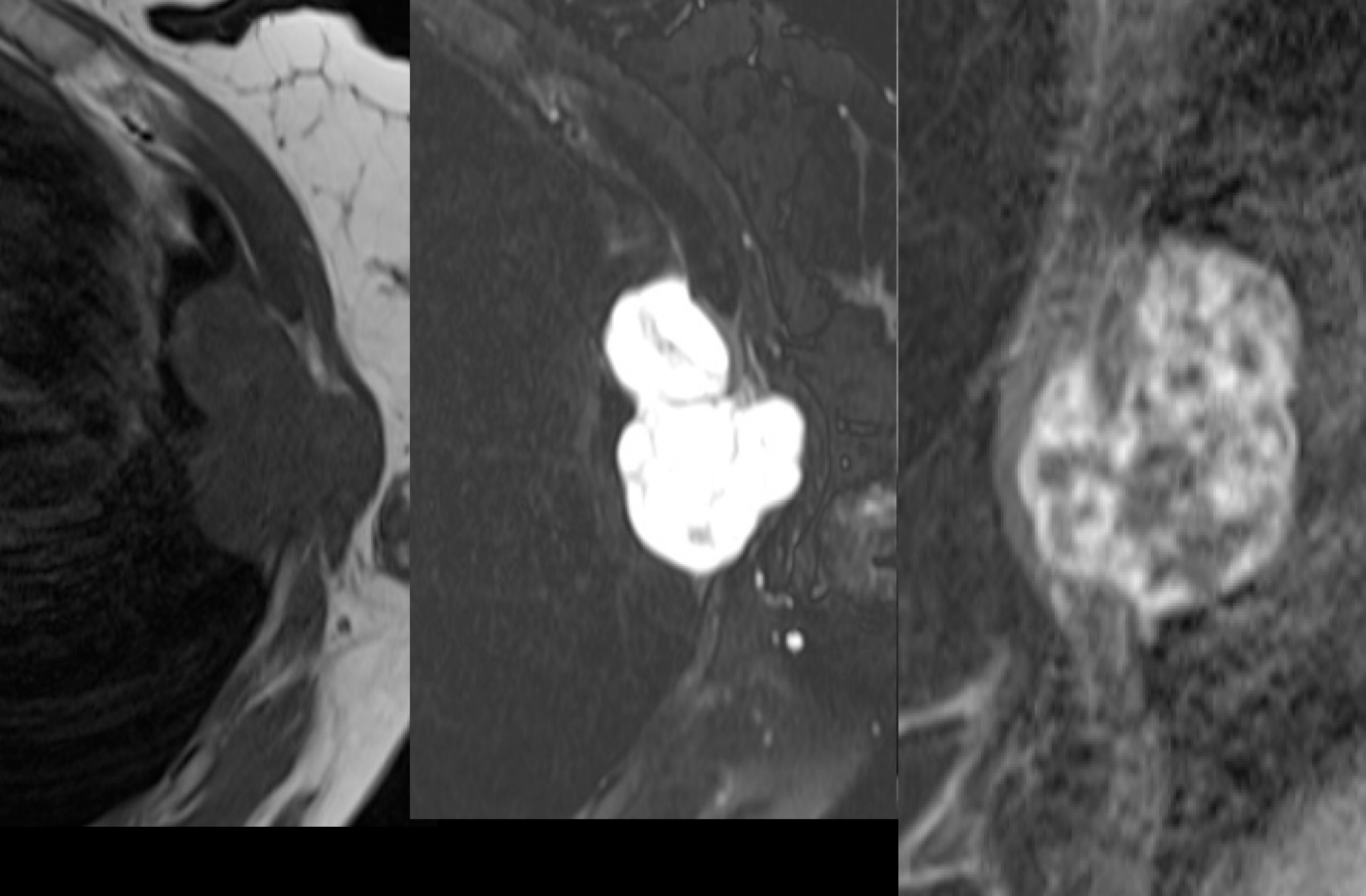






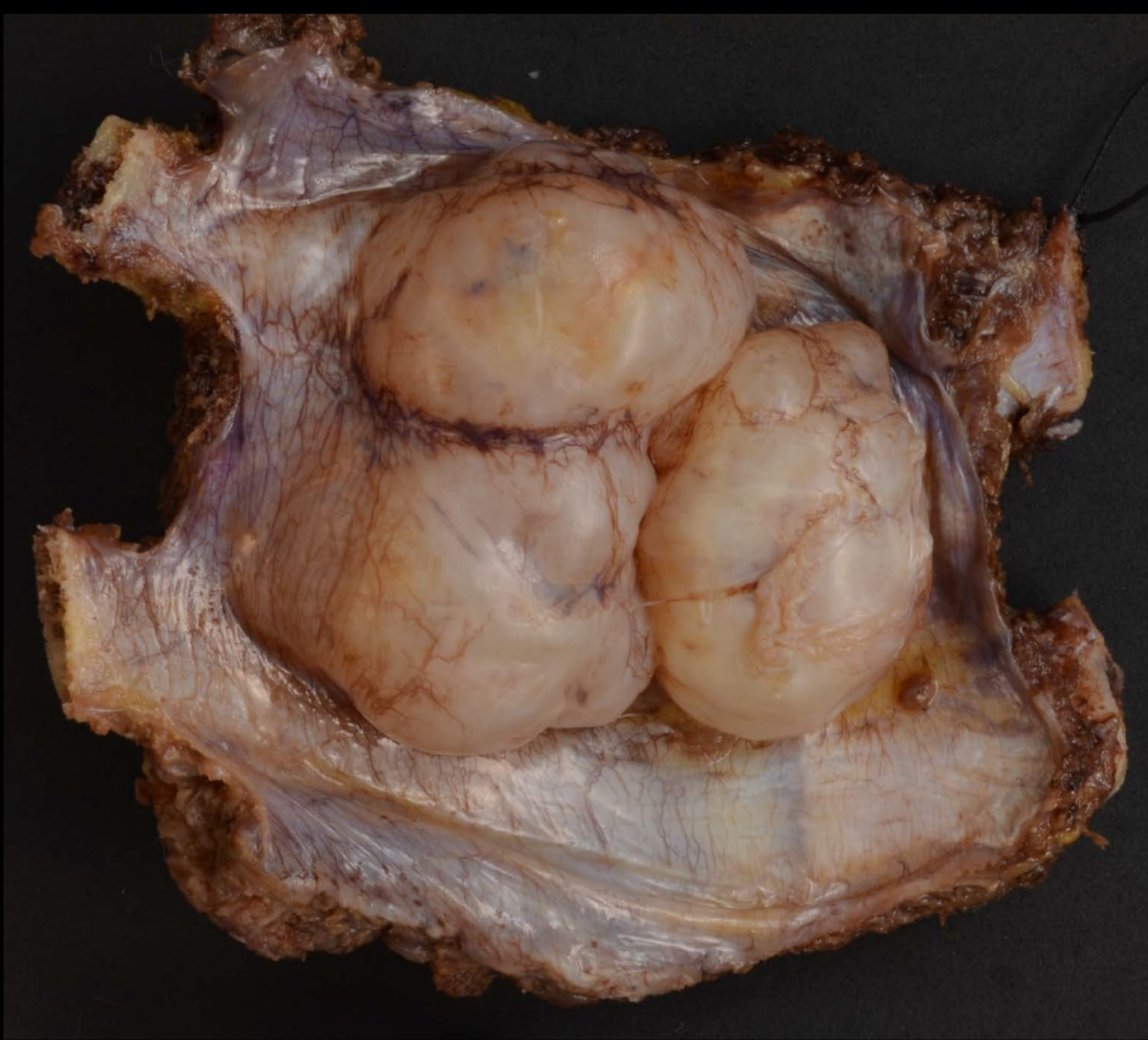


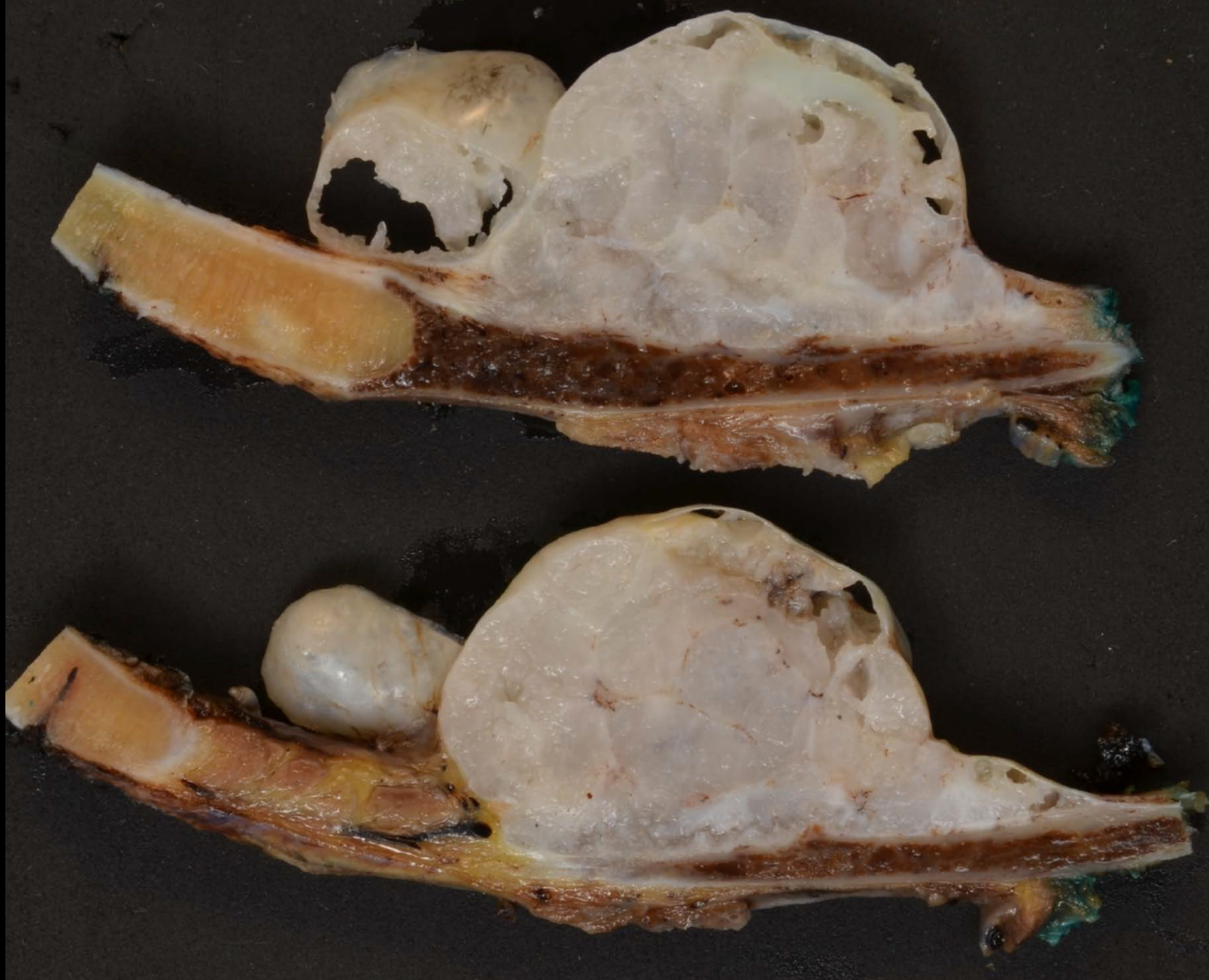



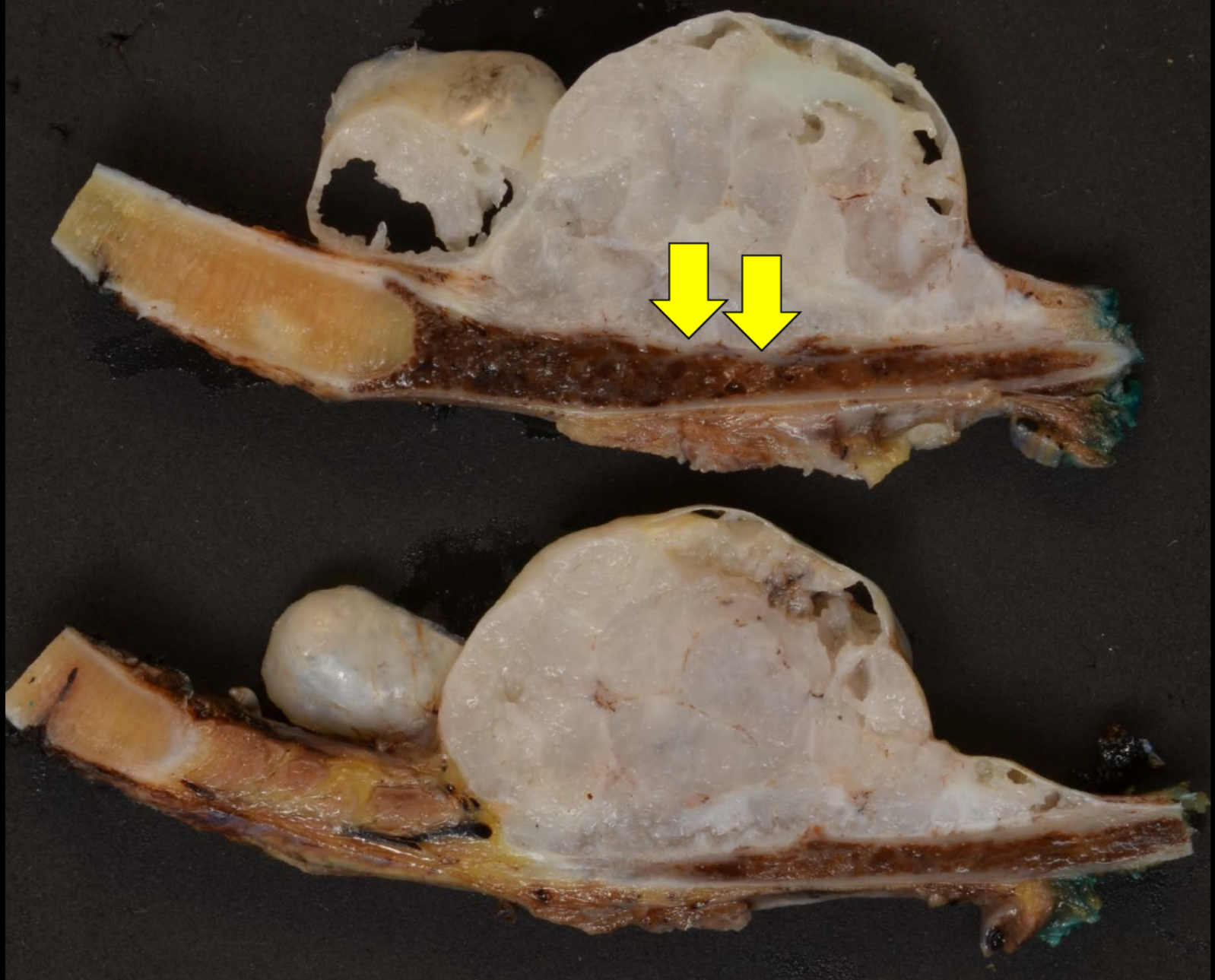**Axial T1, T2 FS and T1 FS post**

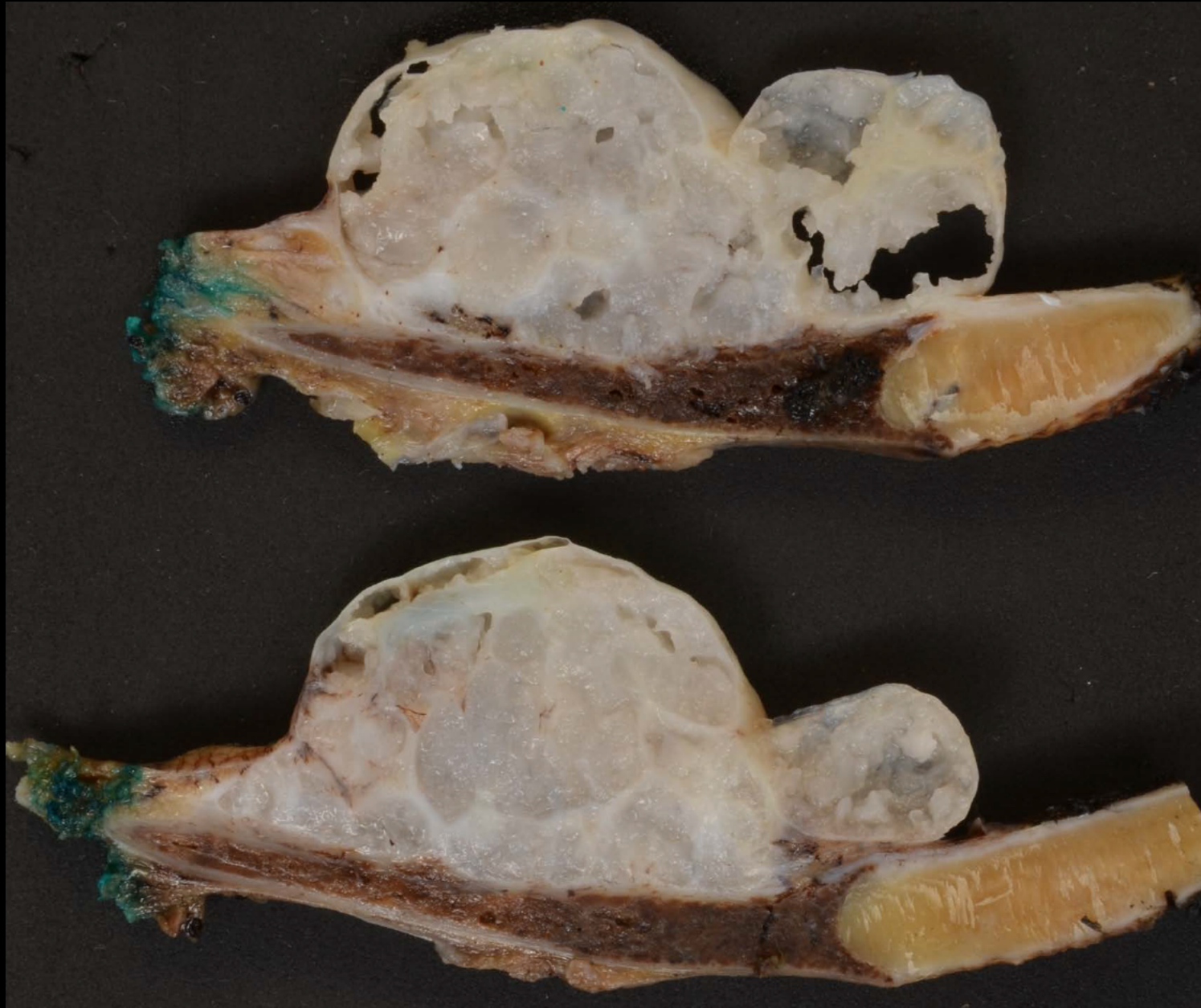




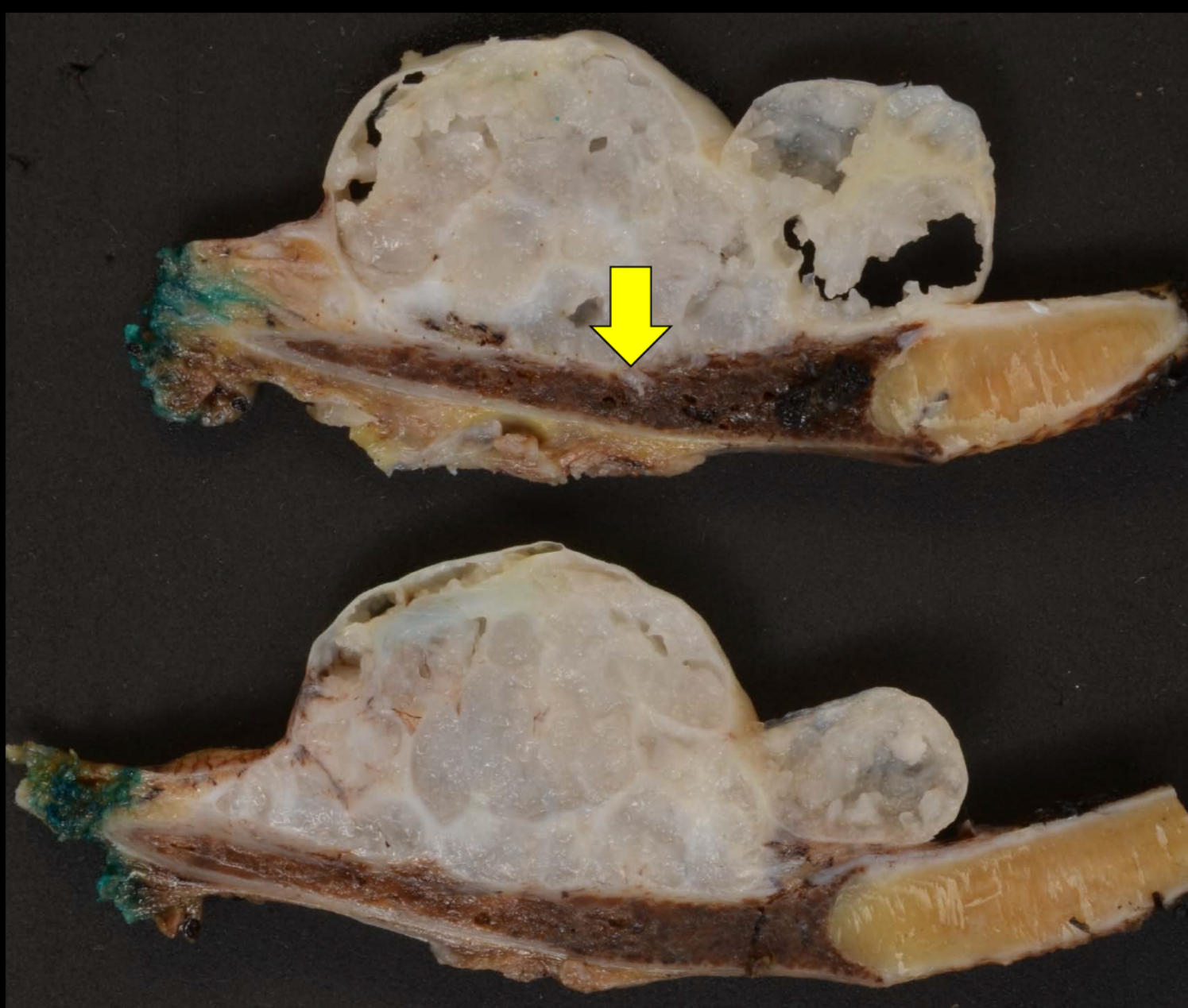


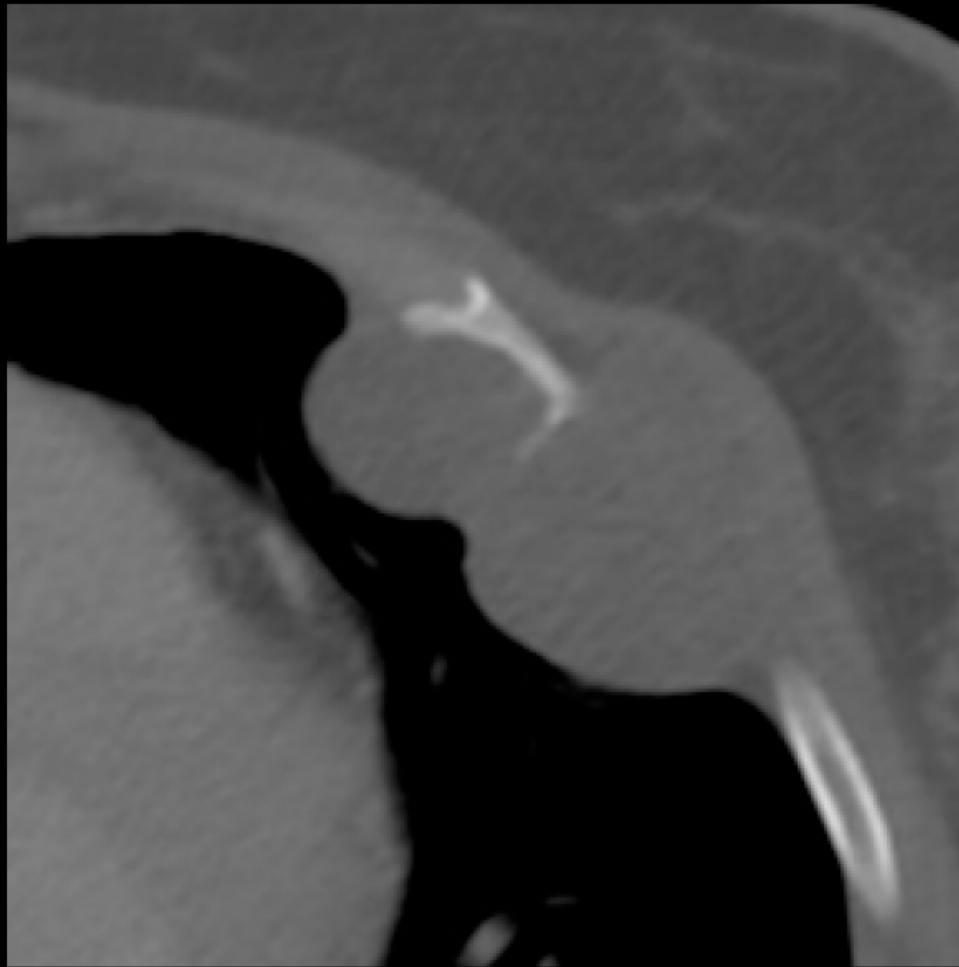

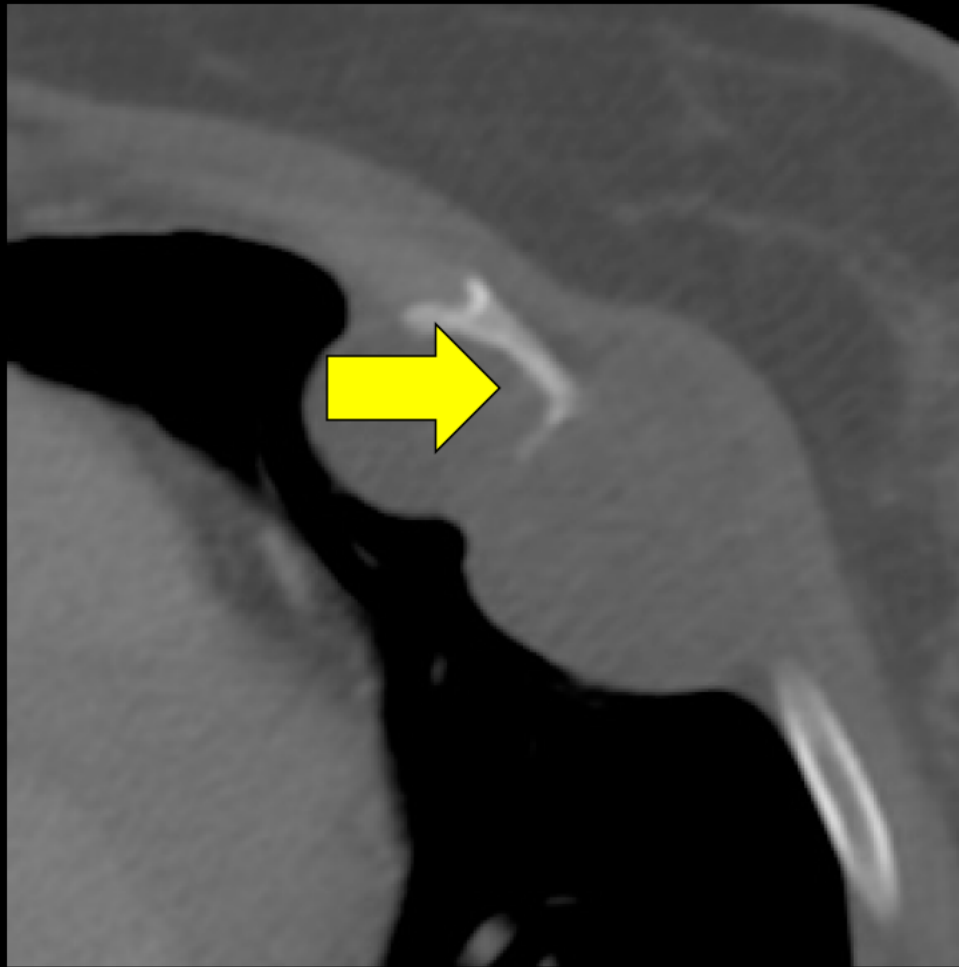






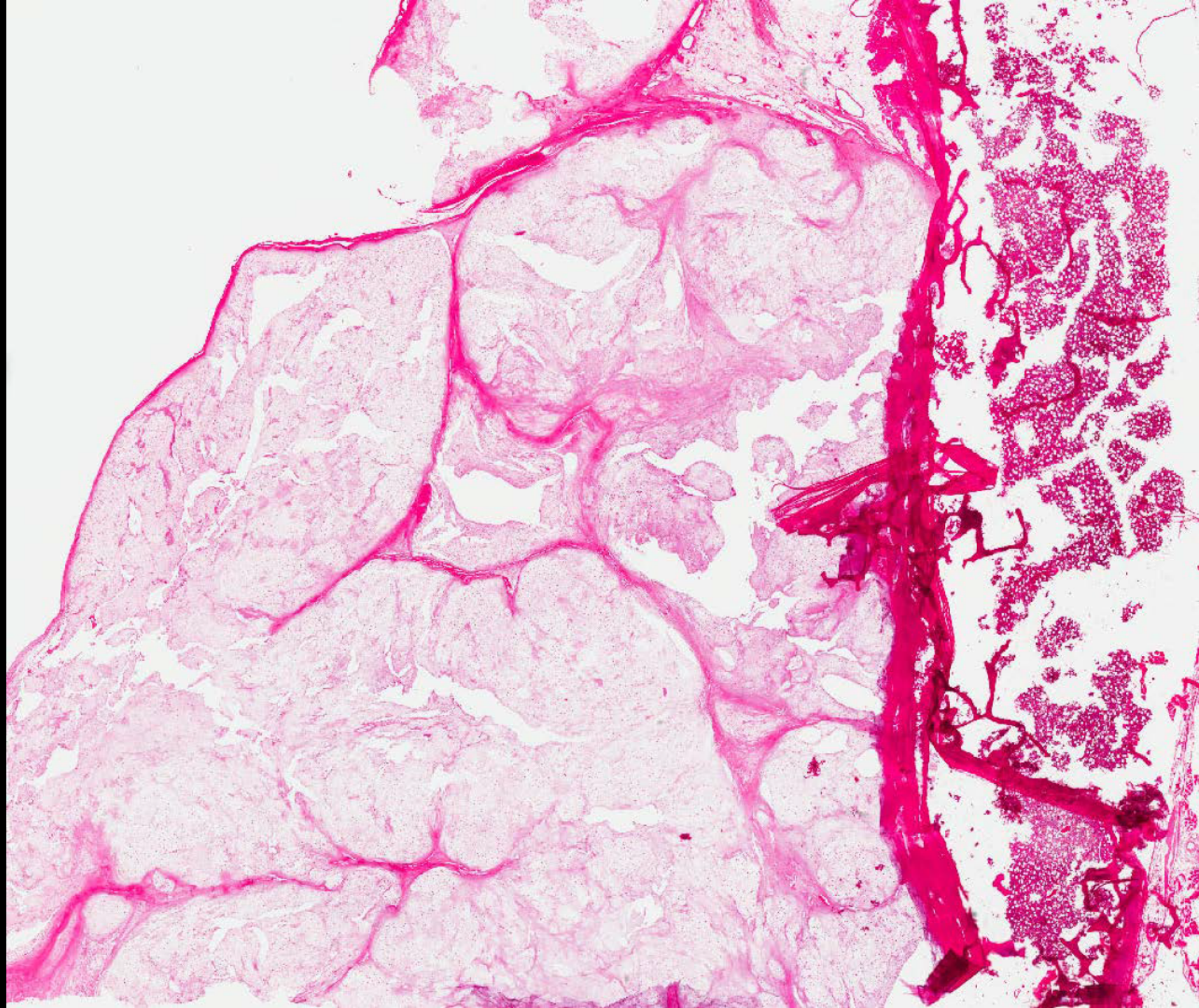


**Axial CT and matched gross photograph**

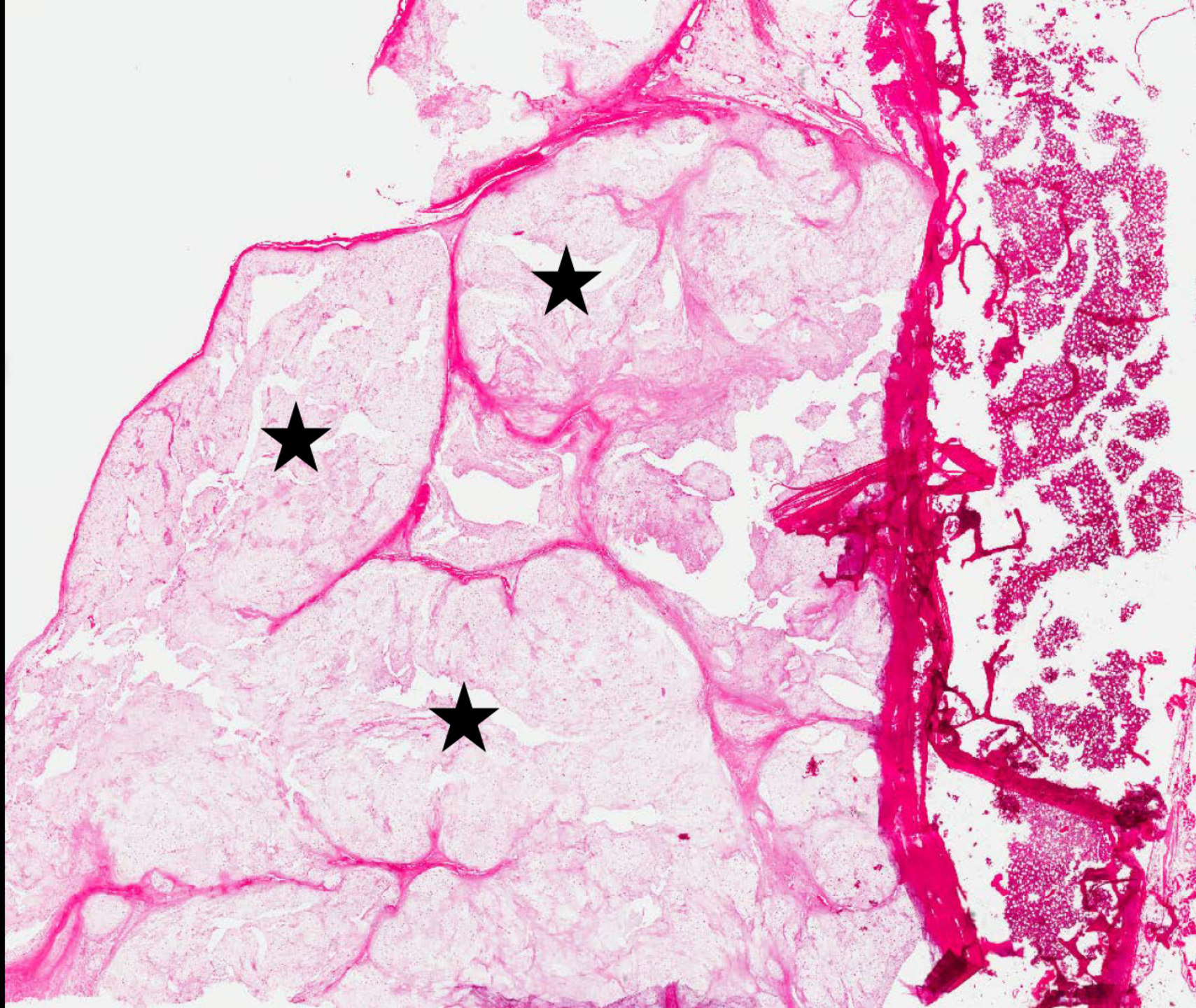


**Axial CT and matched gross photograph**

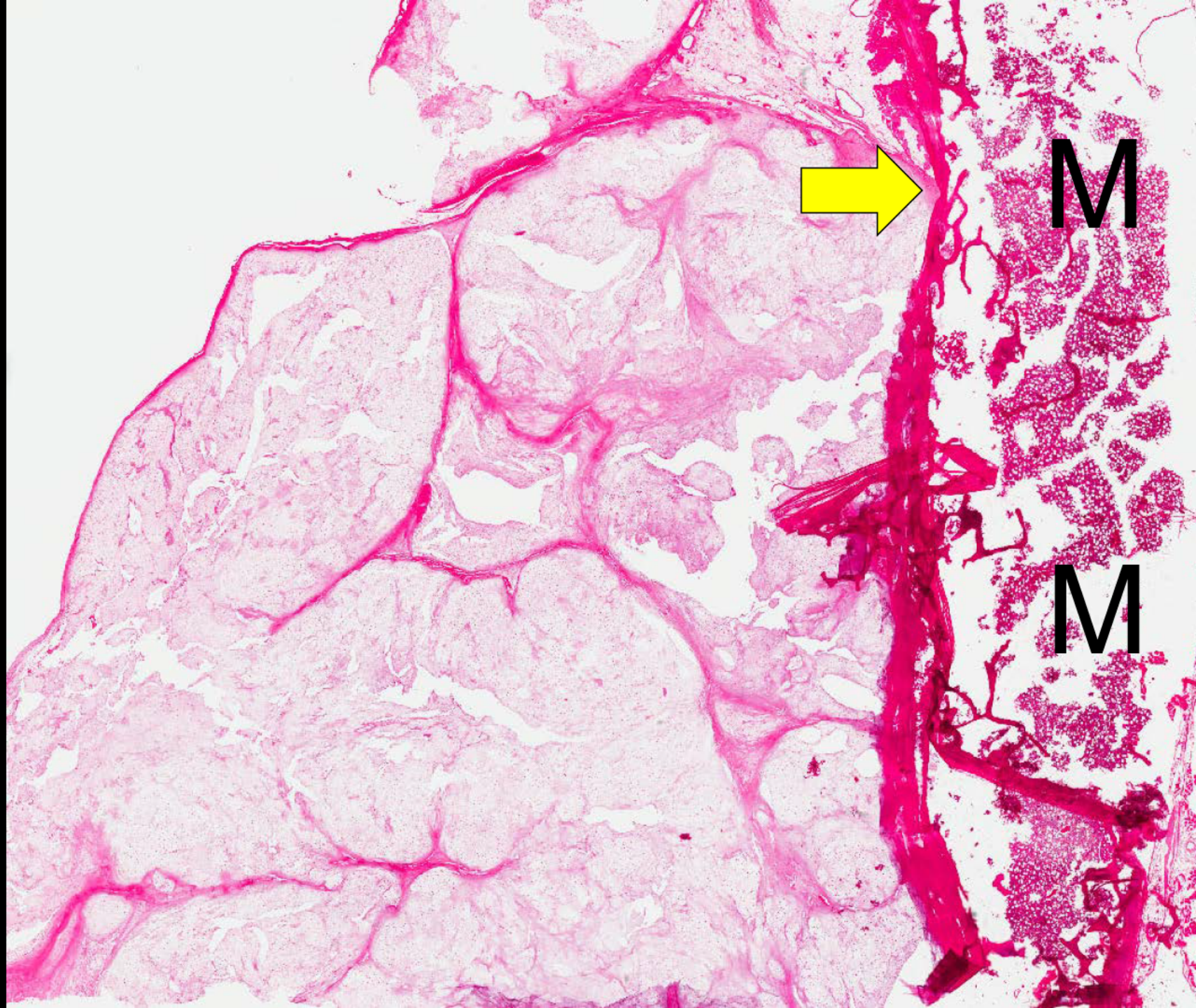




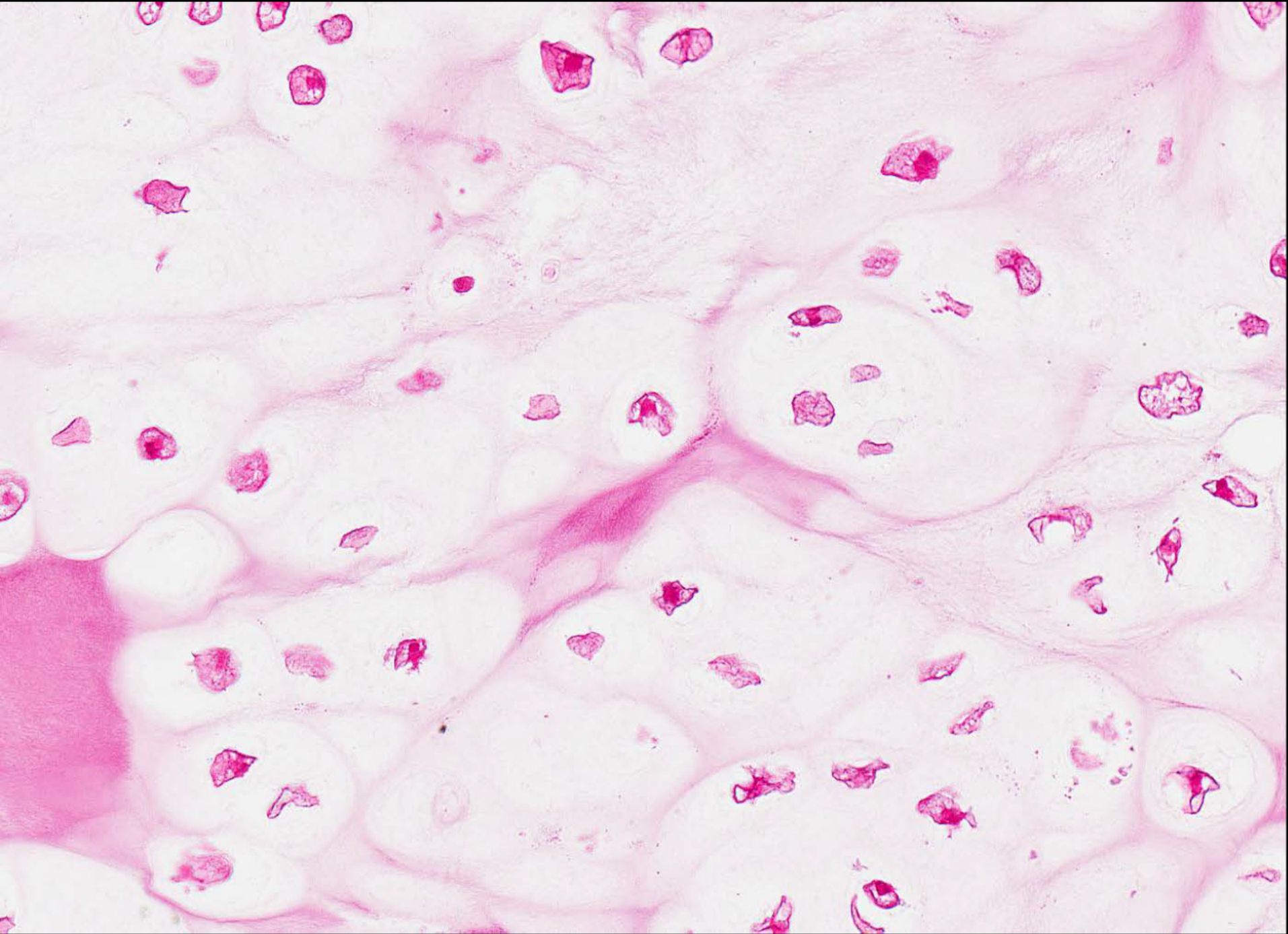










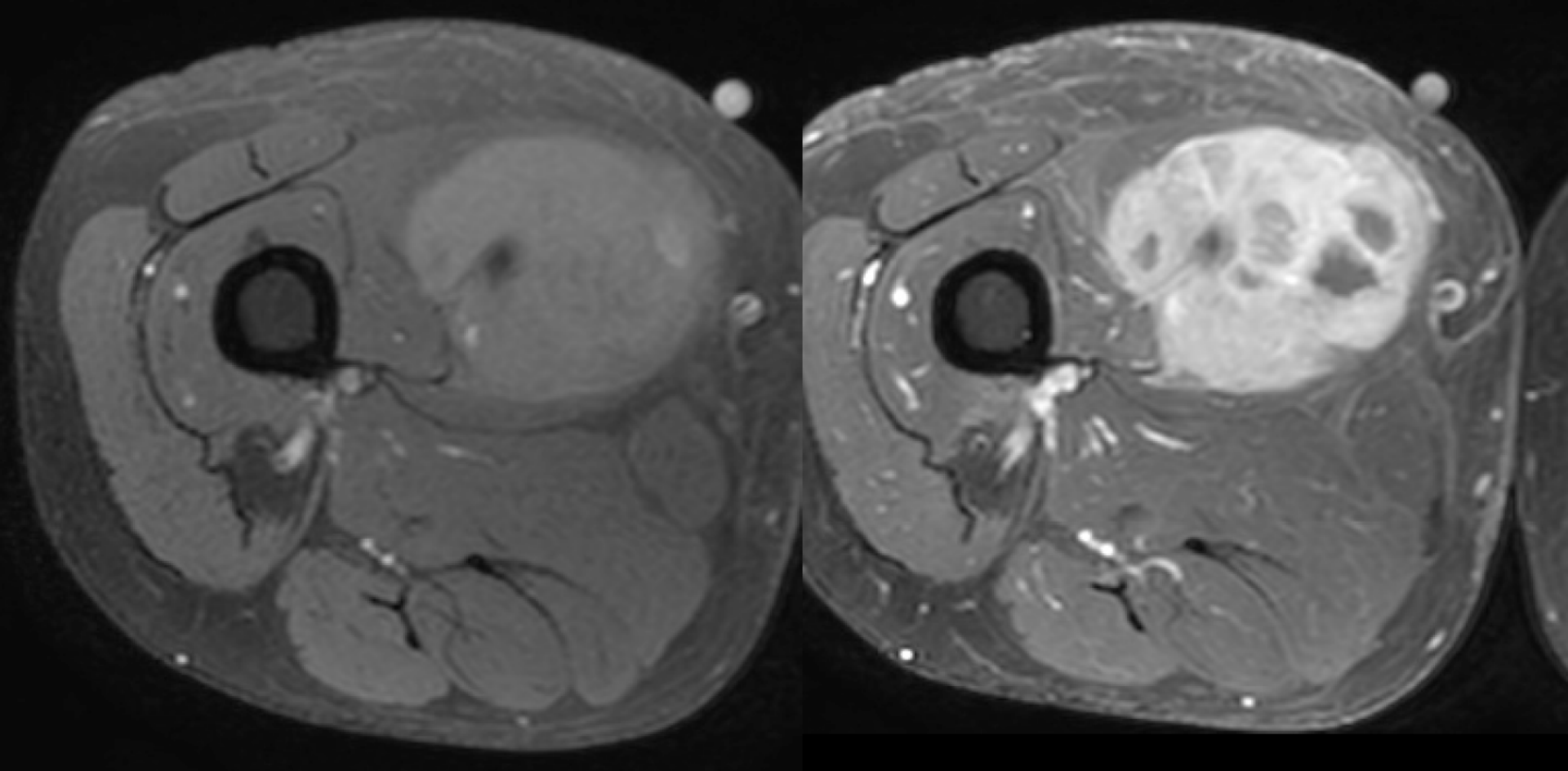


# Juxtacortical Chondrosarcoma

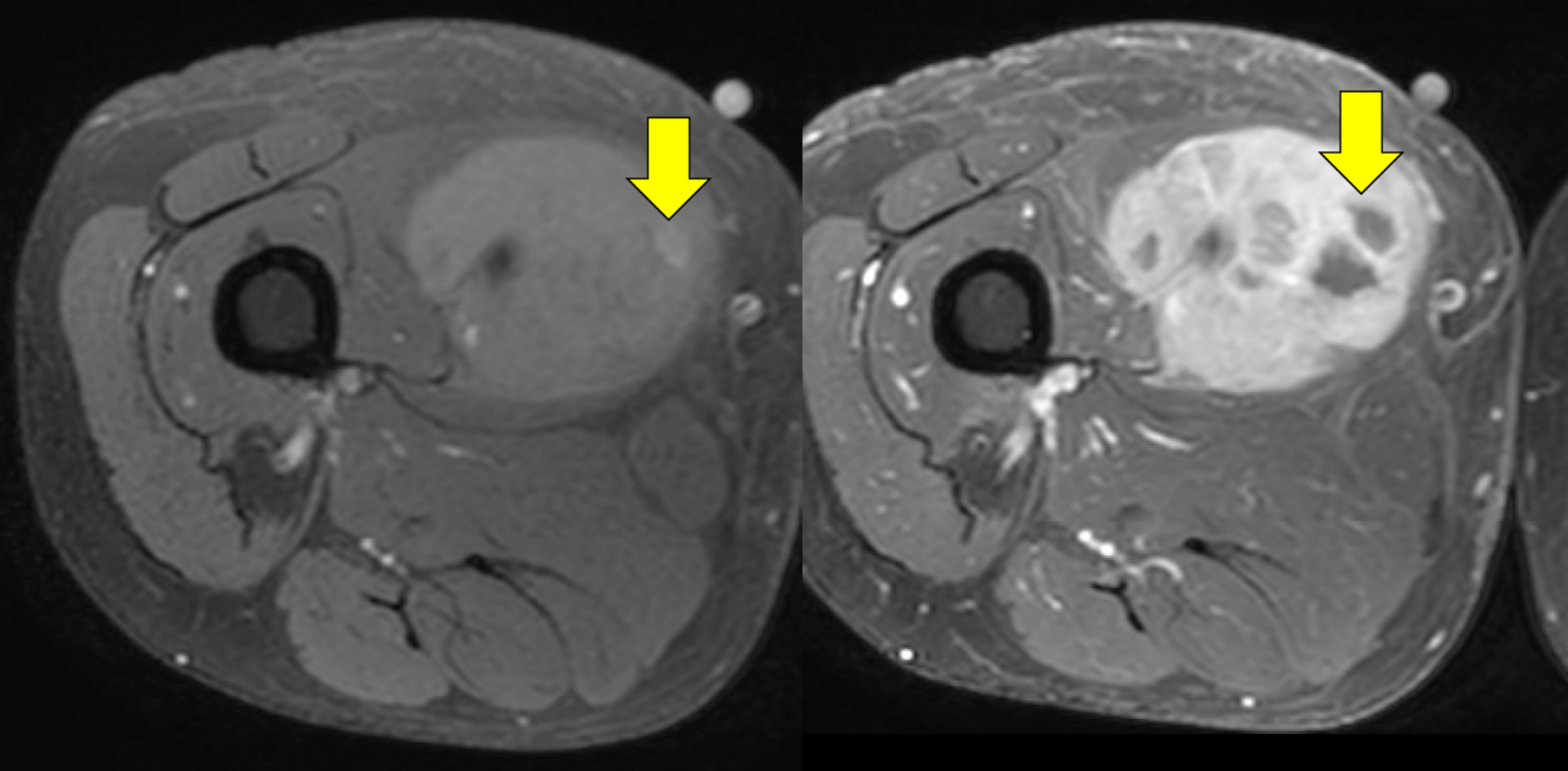
Dr. Kari Visscher  
London Health Science Center,  
Western University  
London, Ontario, Canada

# Honorable mention

**75-year-old male with  
gradually enlarging mass in  
right thigh and increasing  
lower limb swelling**

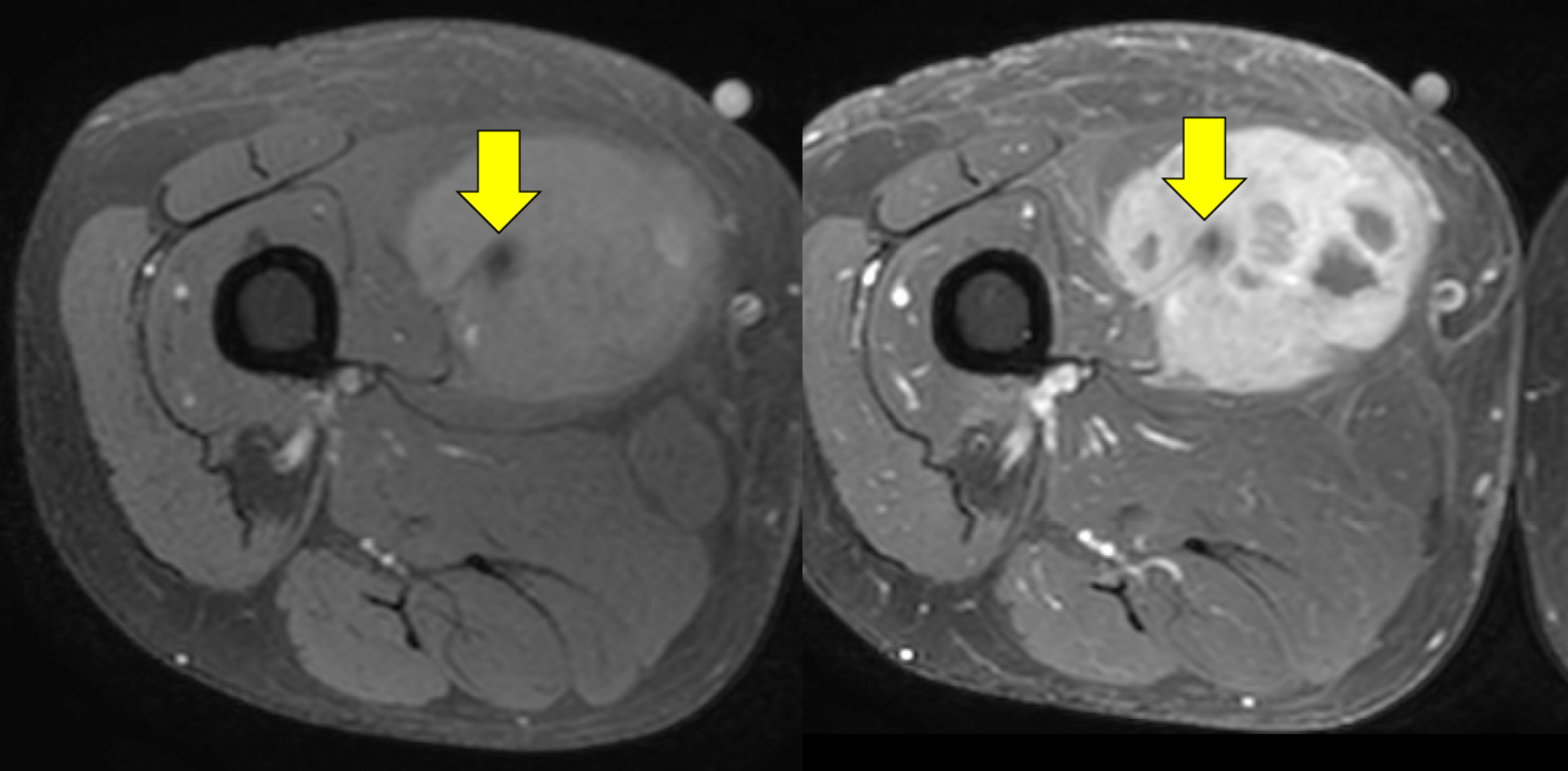


**Axial T1 FS Pre and Axial T1 FS Post**

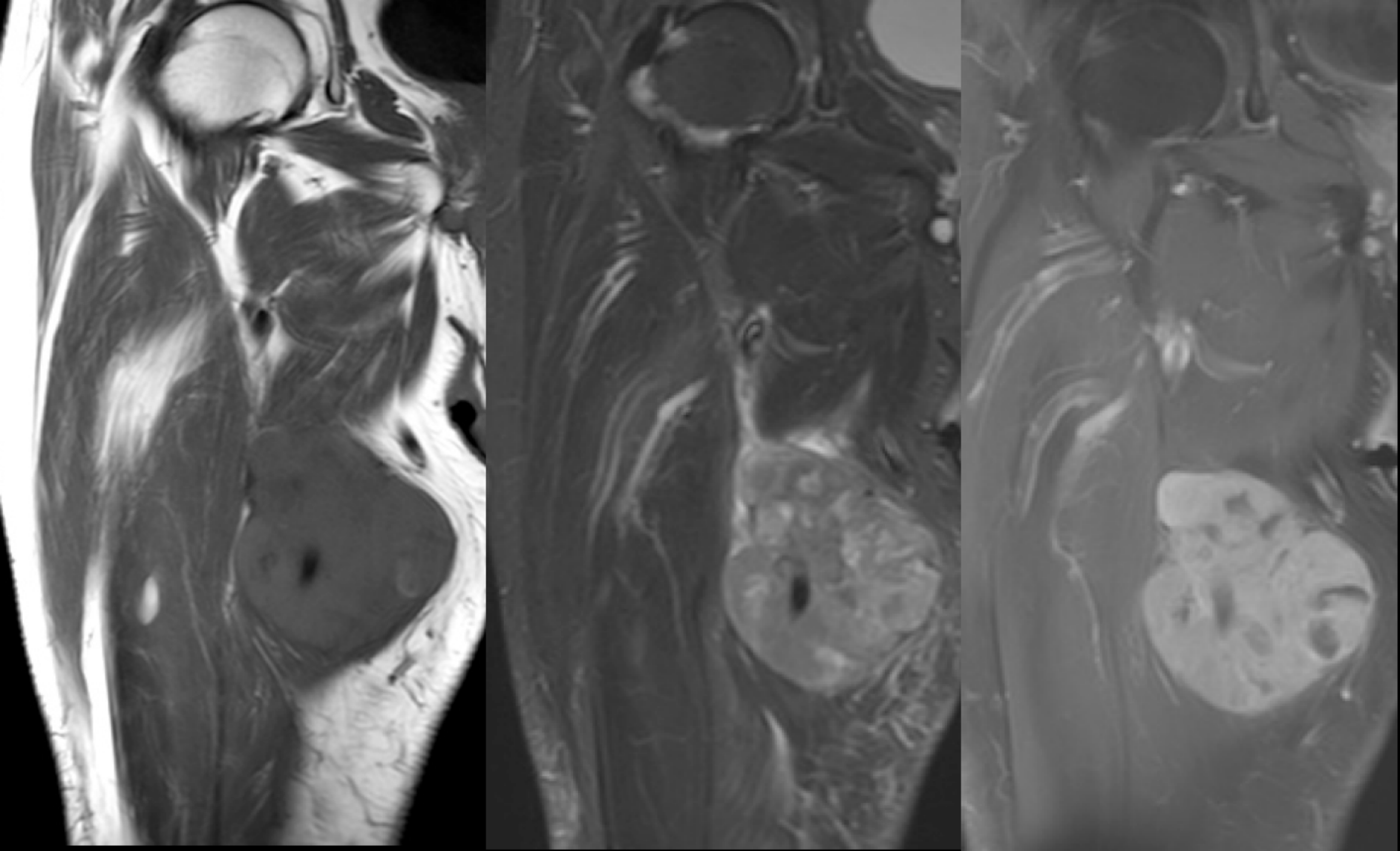


**Axial T1 FS Pre and Axial T1 FS Post  
showing hemorrhagic necrosis**

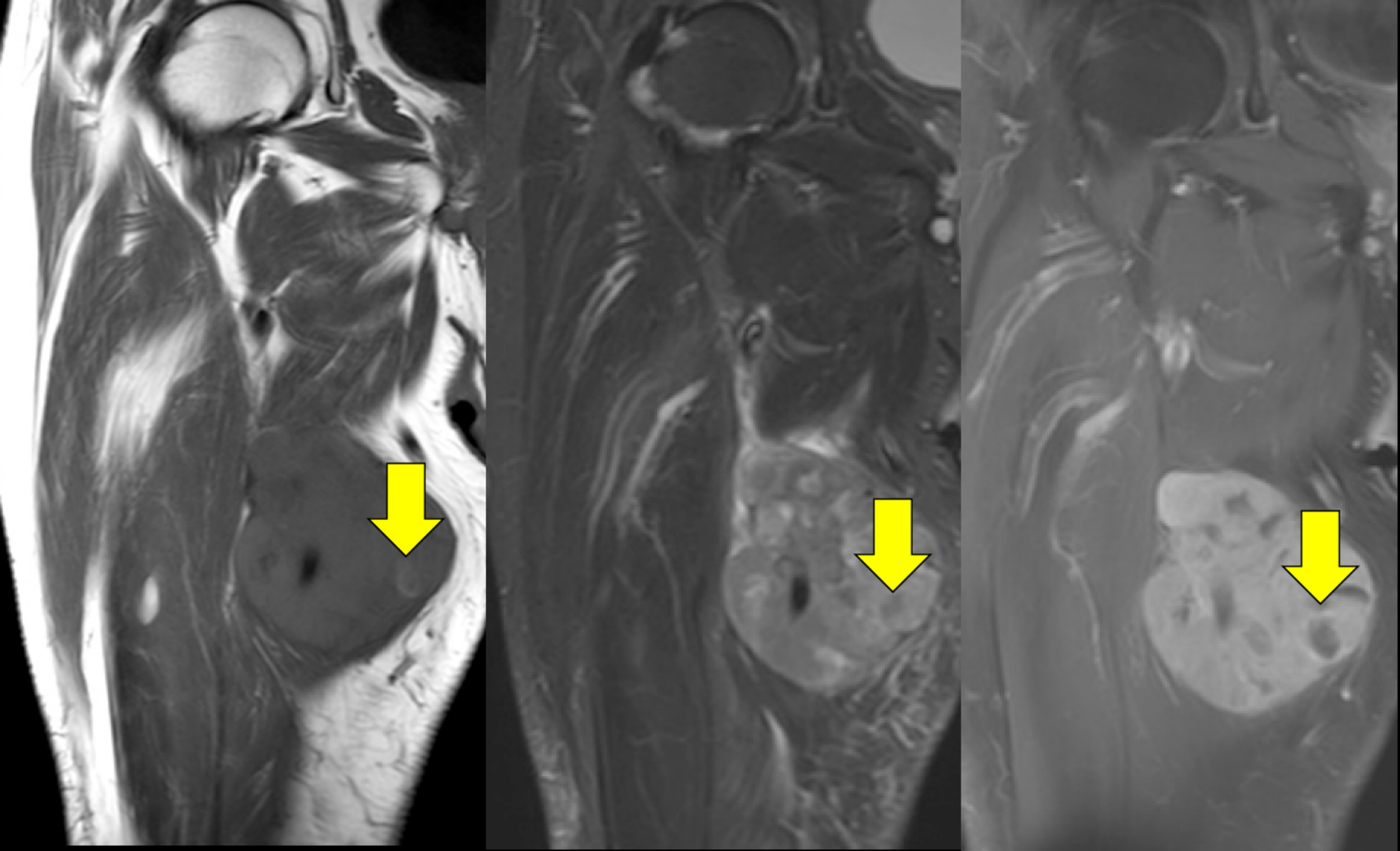




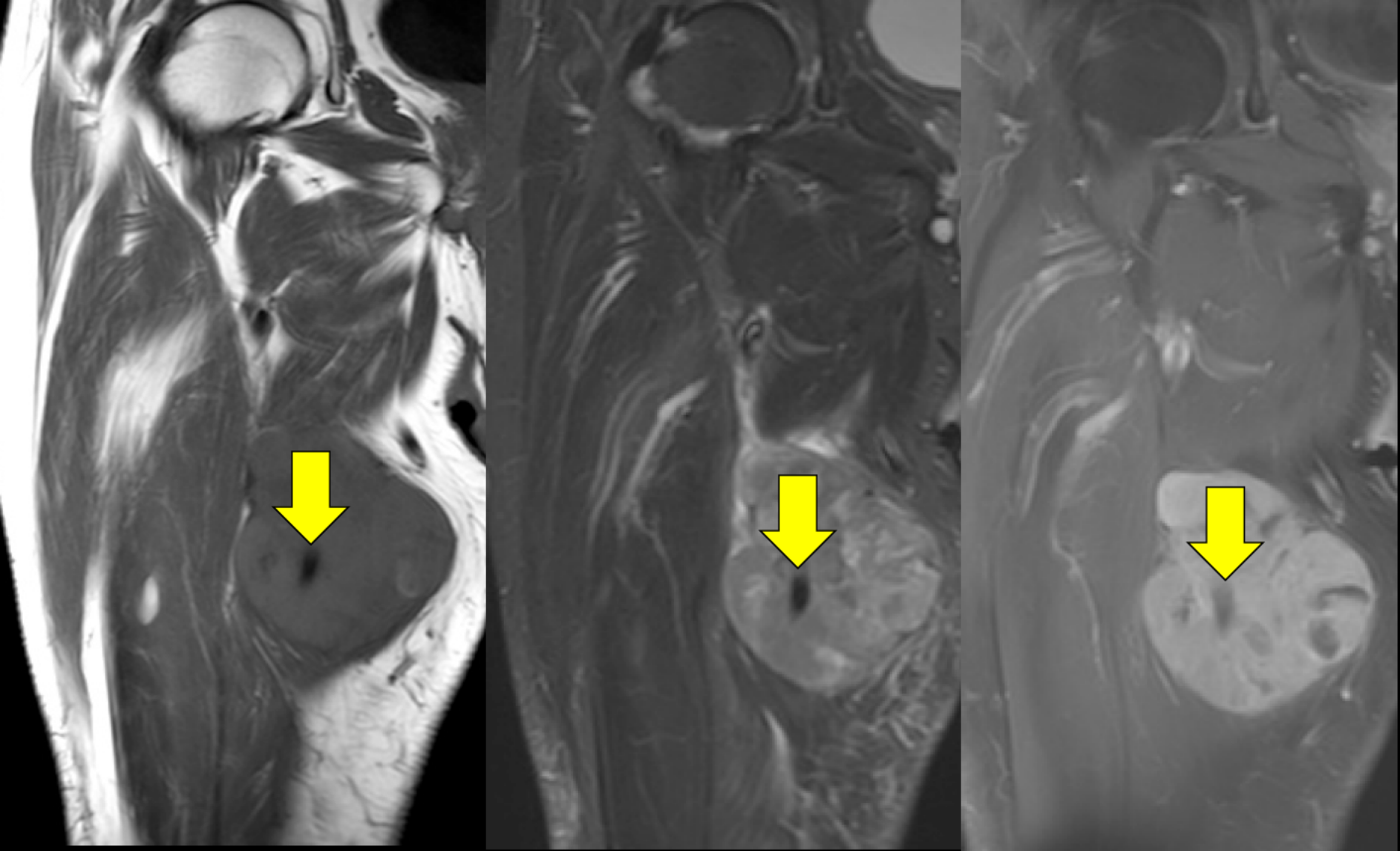
**Axial T1 FS Pre and Axial T1 FS Post  
showing SFA**



**Coronal T1, STIR and T1 FS post**

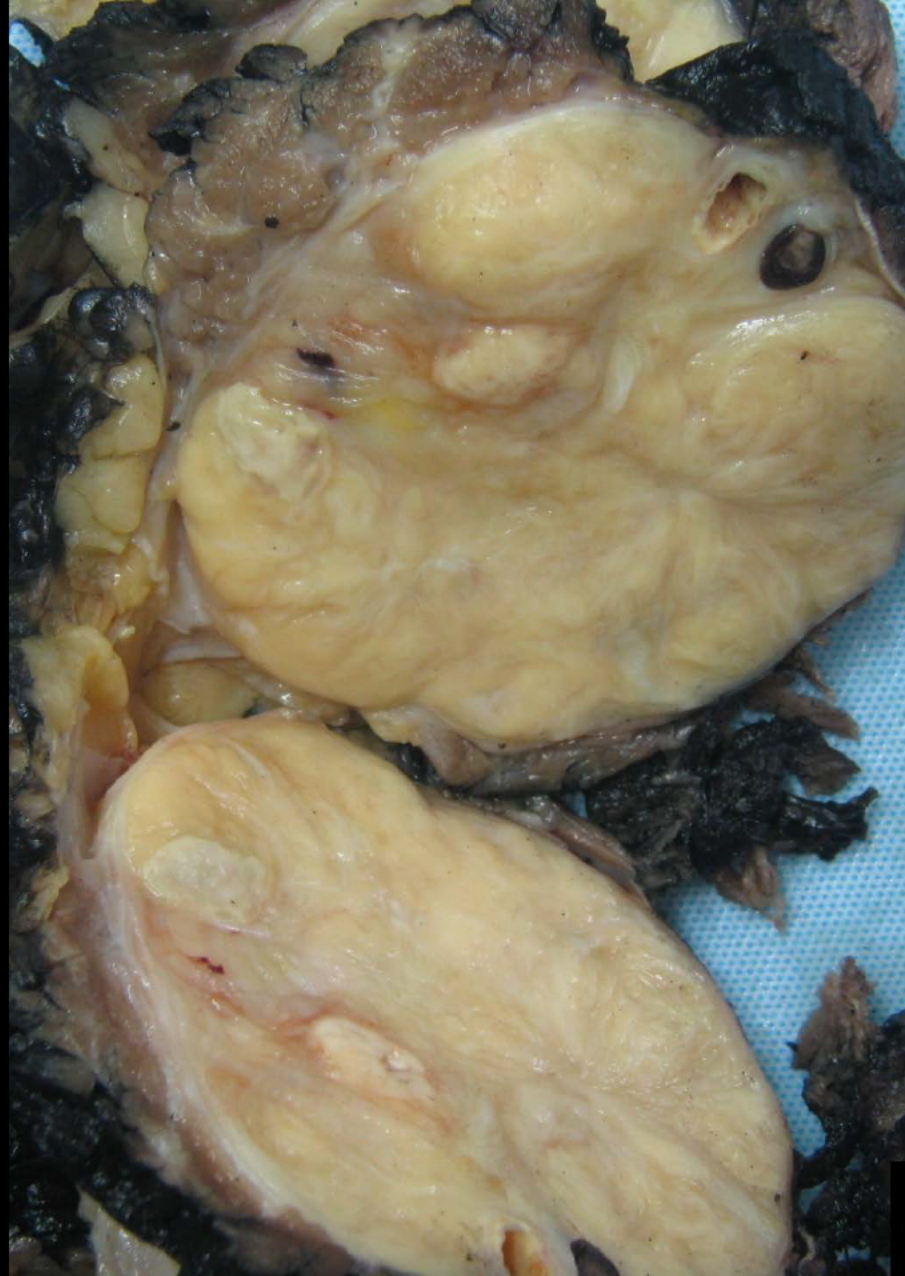

**Coronal T1, STIR and T1 FS post showing hemorrhage**

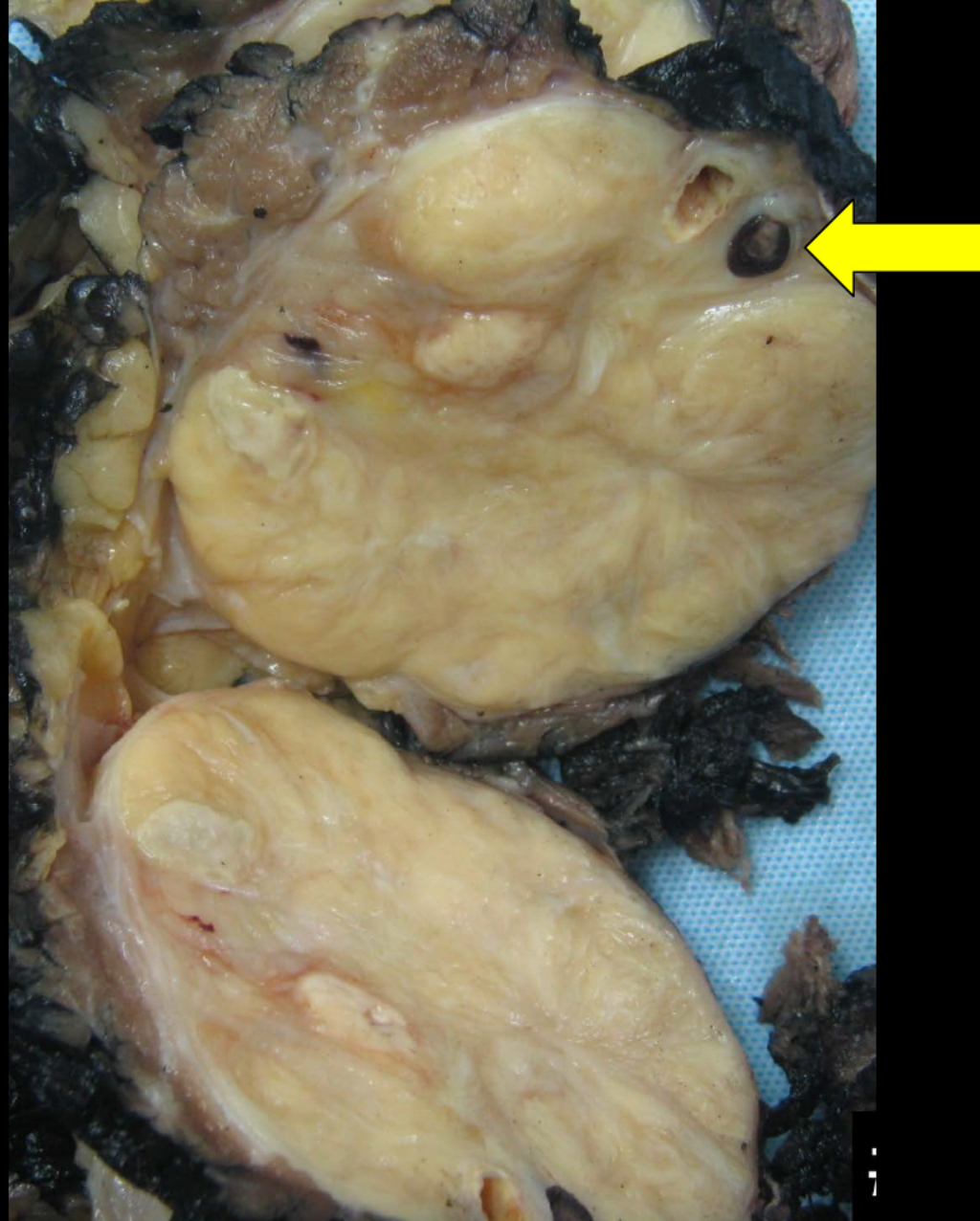


**Coronal T1, STIR and T1 FS post showing SFA**



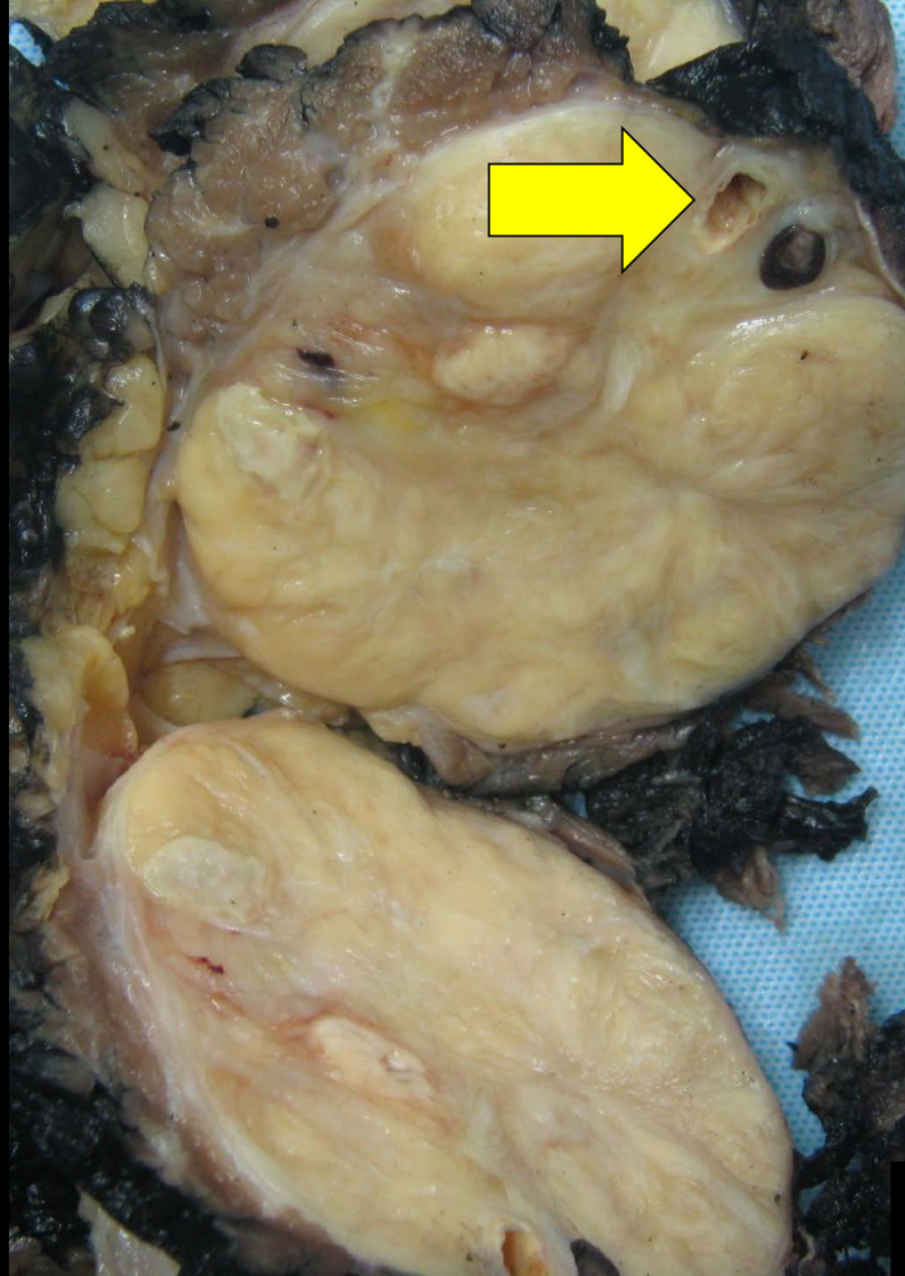

**Gross picture**

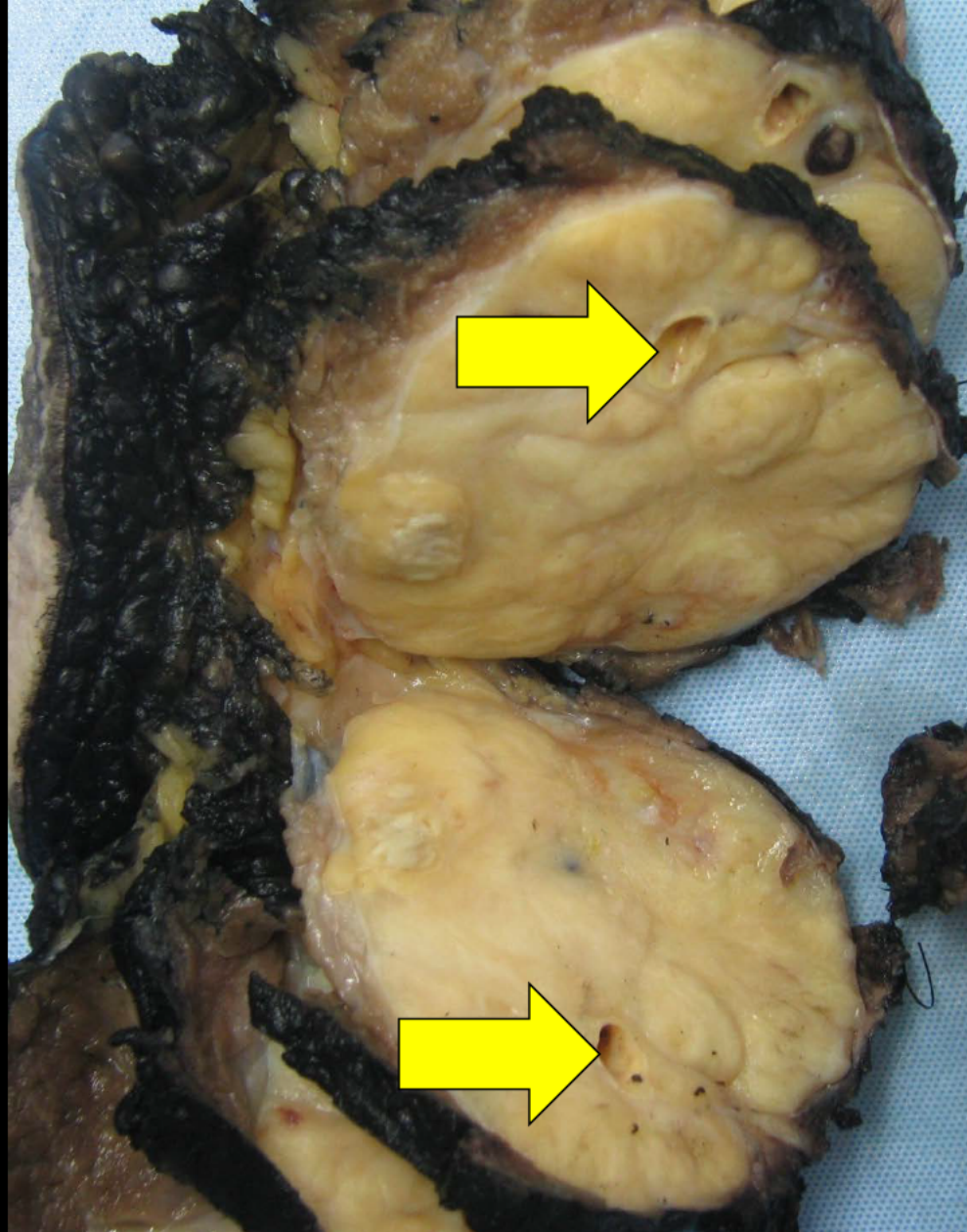


**Gross picture showing thrombus in SFV**

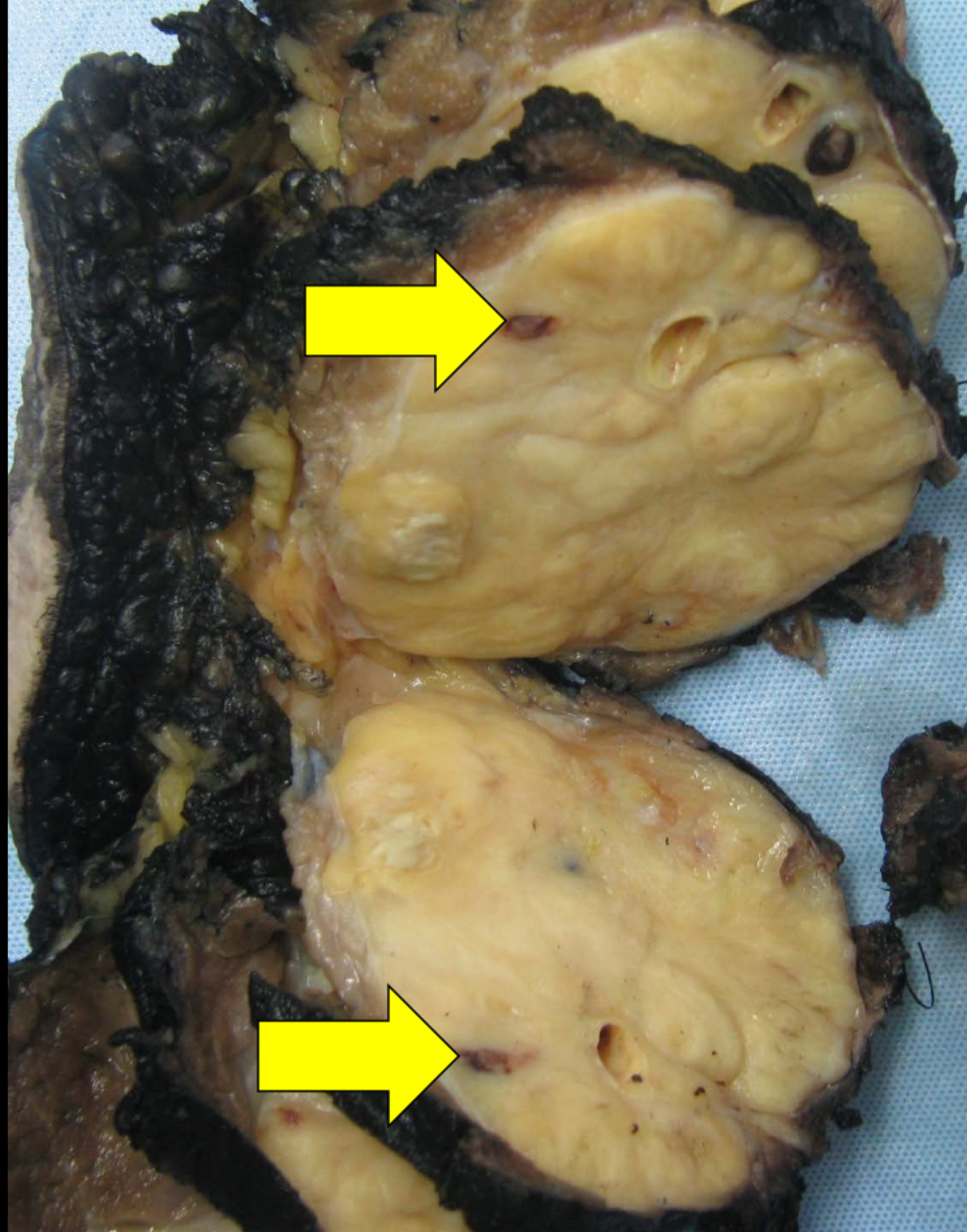




**Gross picture showing SFA**

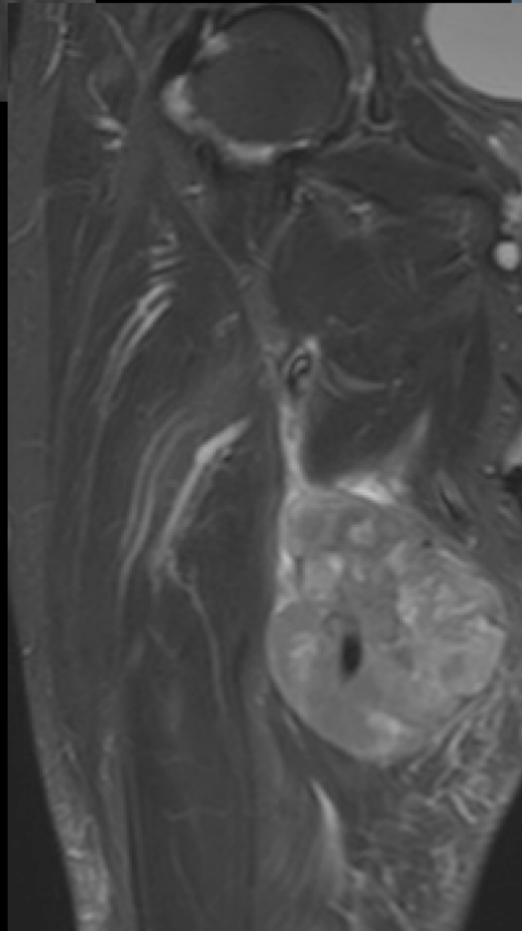
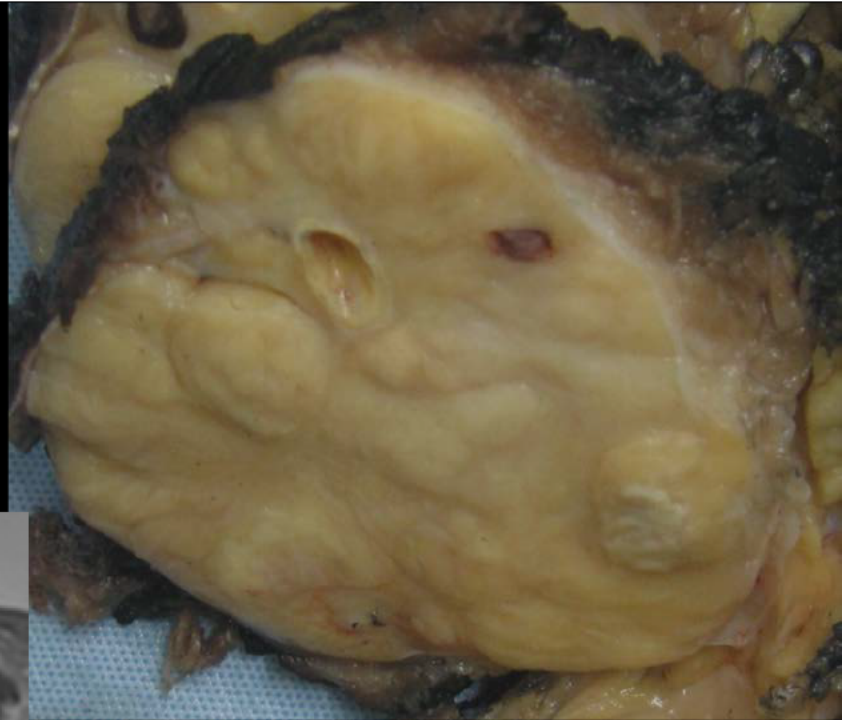
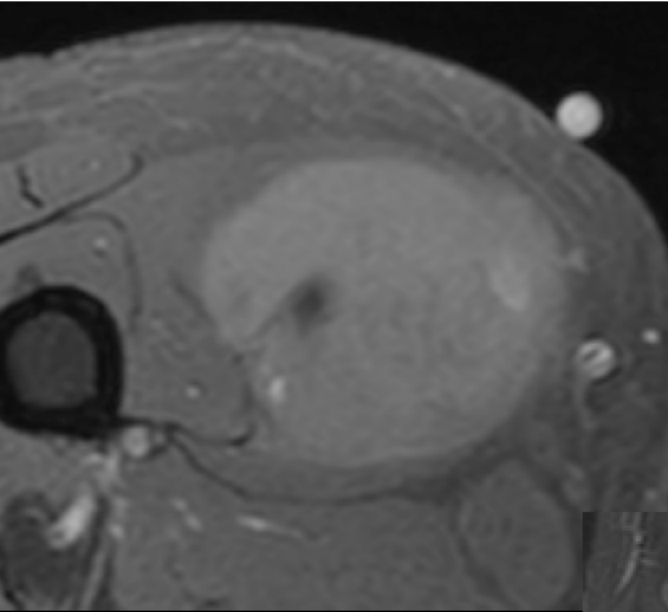


**Gross picture showing SFA**

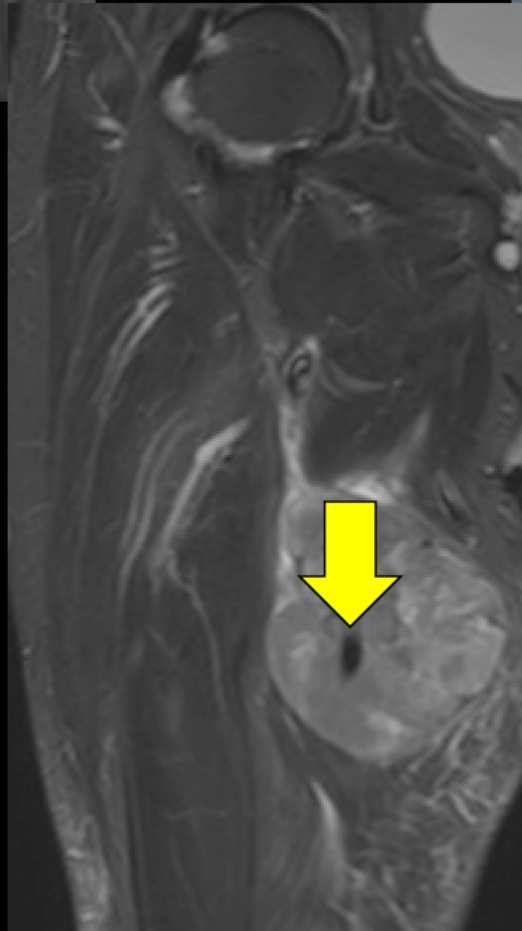
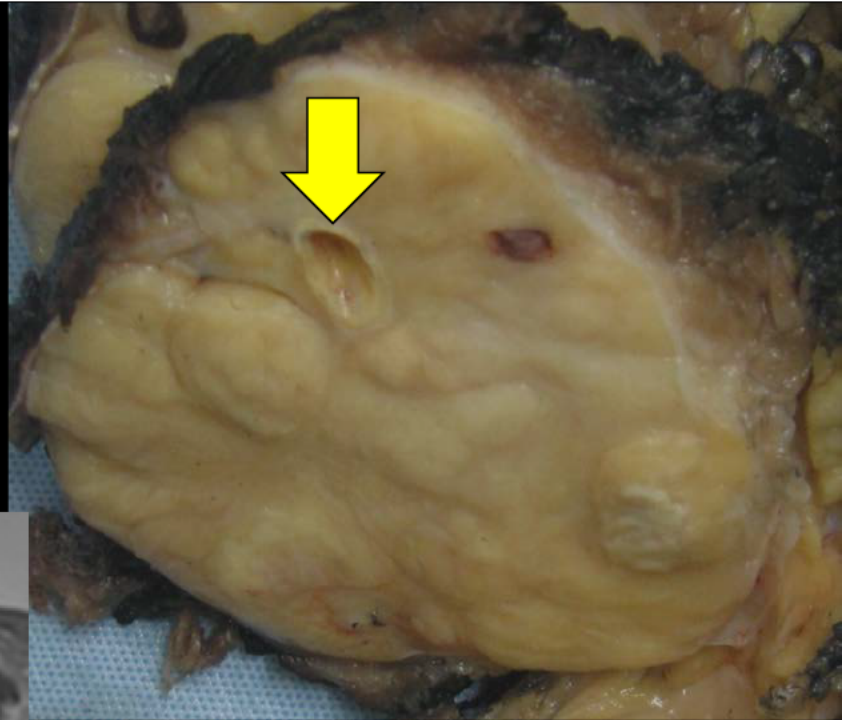

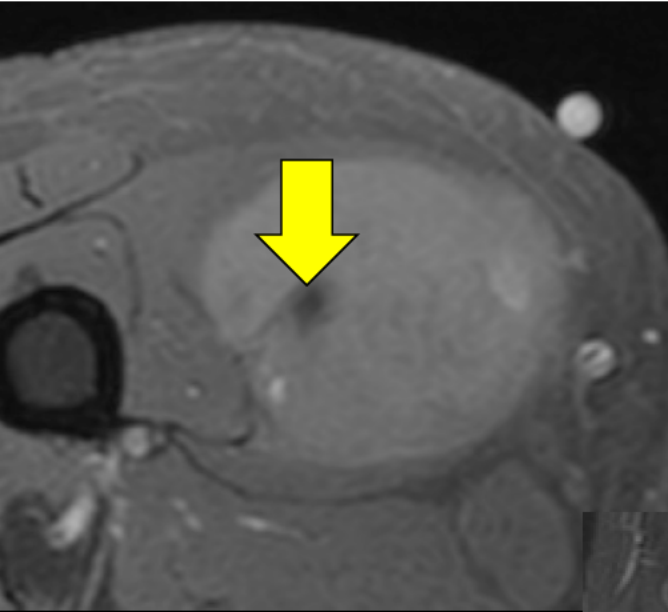


**Gross picture showing hemorrhage**



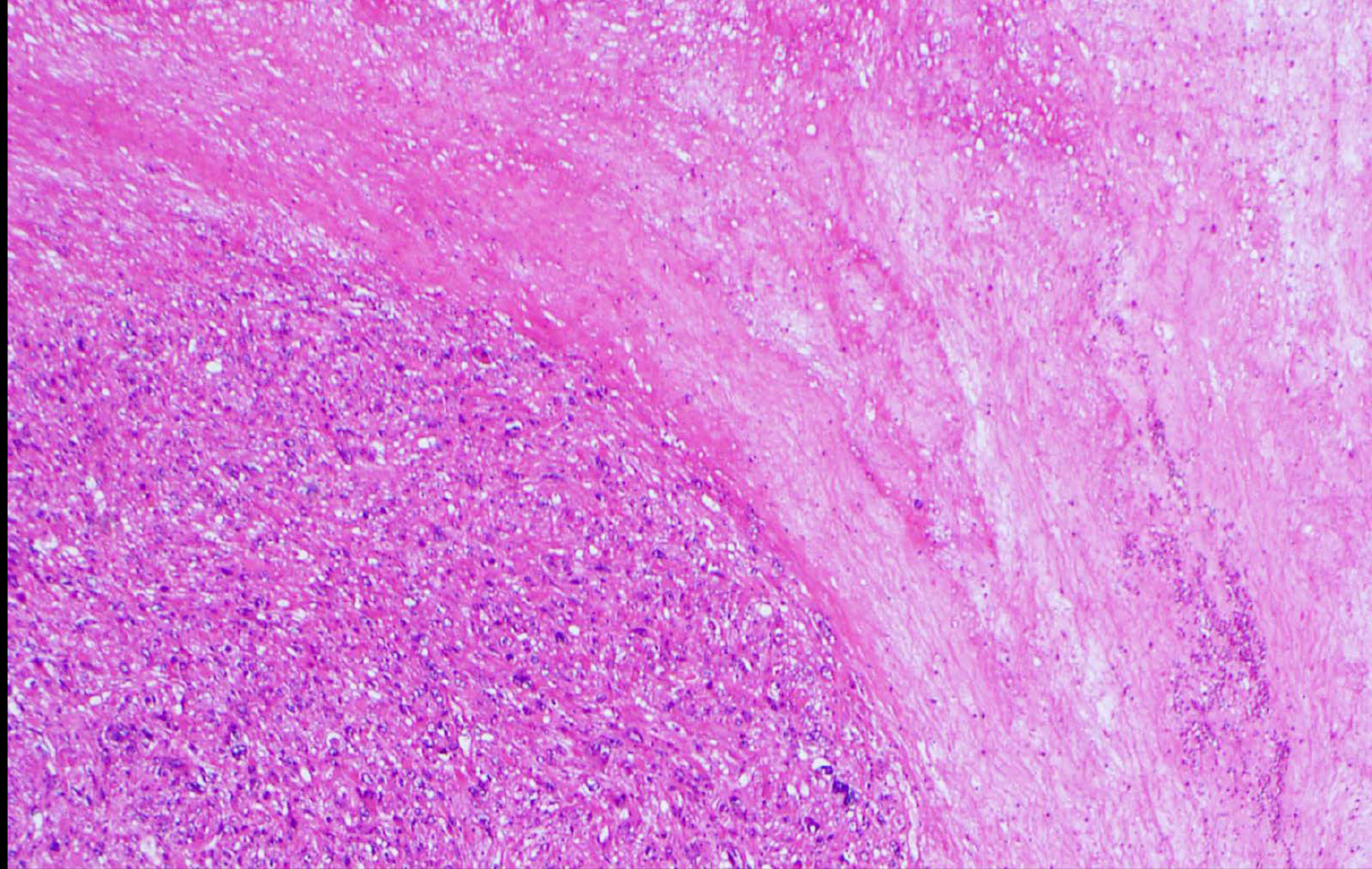


**Matched T1 FS  
pre and Gross  
picture**



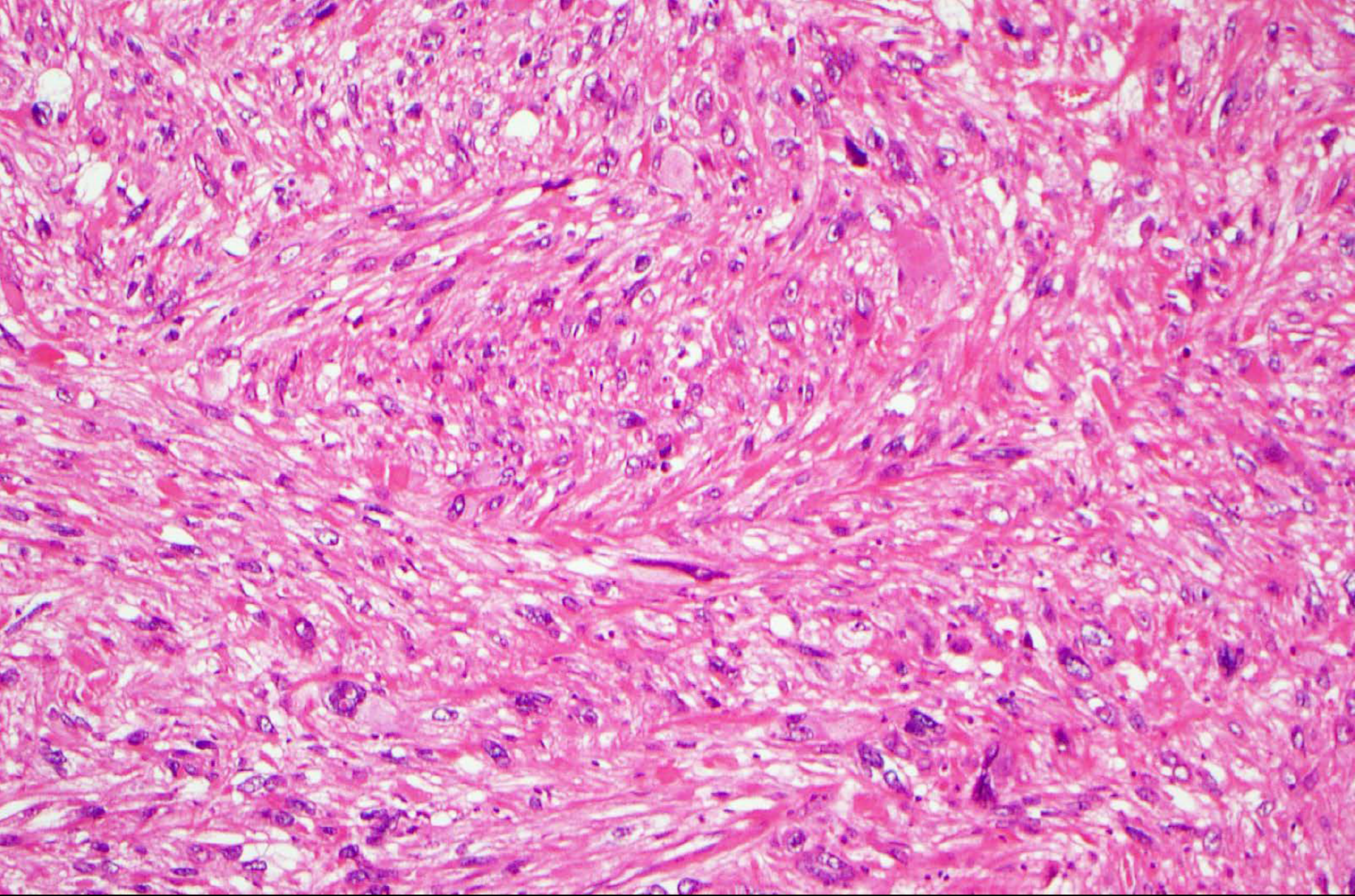
**Matched T1 FS  
pre and Gross  
picture showing  
encased SFA**





**Low power microscopy picture**





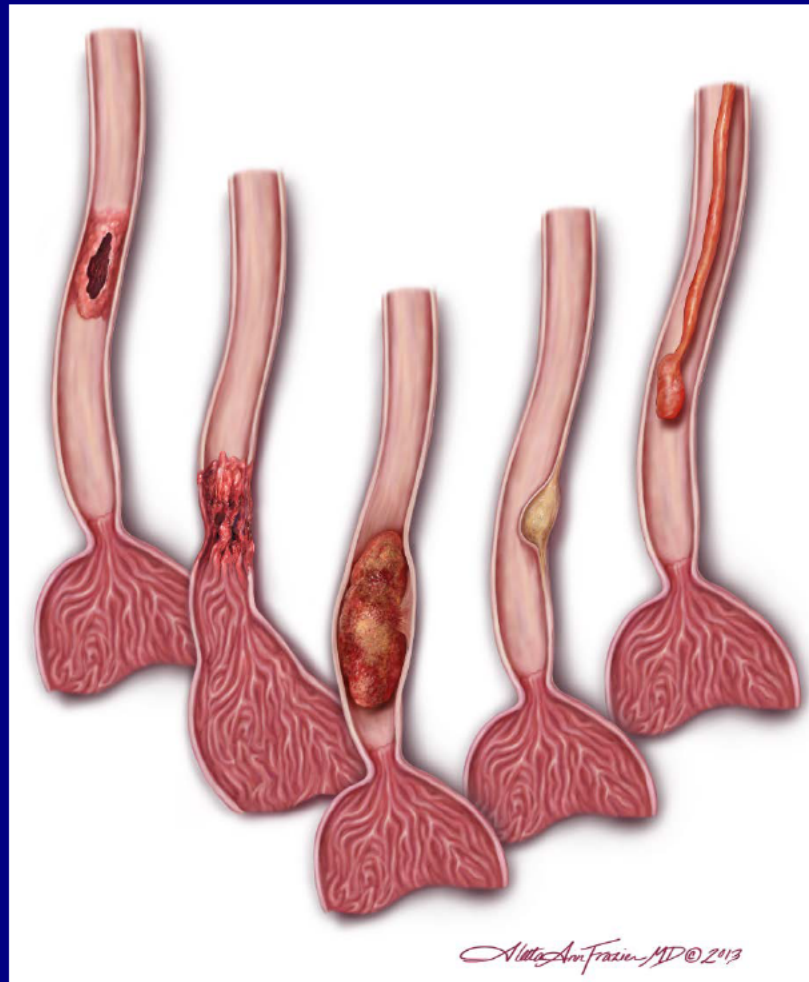**High power microscopy picture**

# Leiomyosarcoma arising from vein wall

Dr. David Woodlock  
University Hospital Galway  
Galway, Ireland



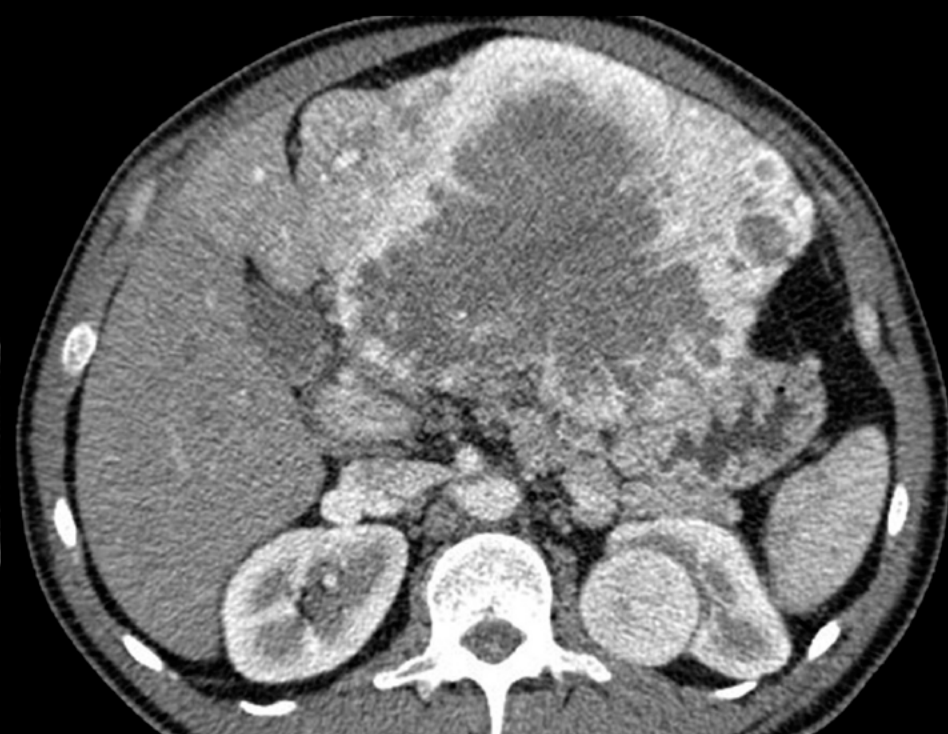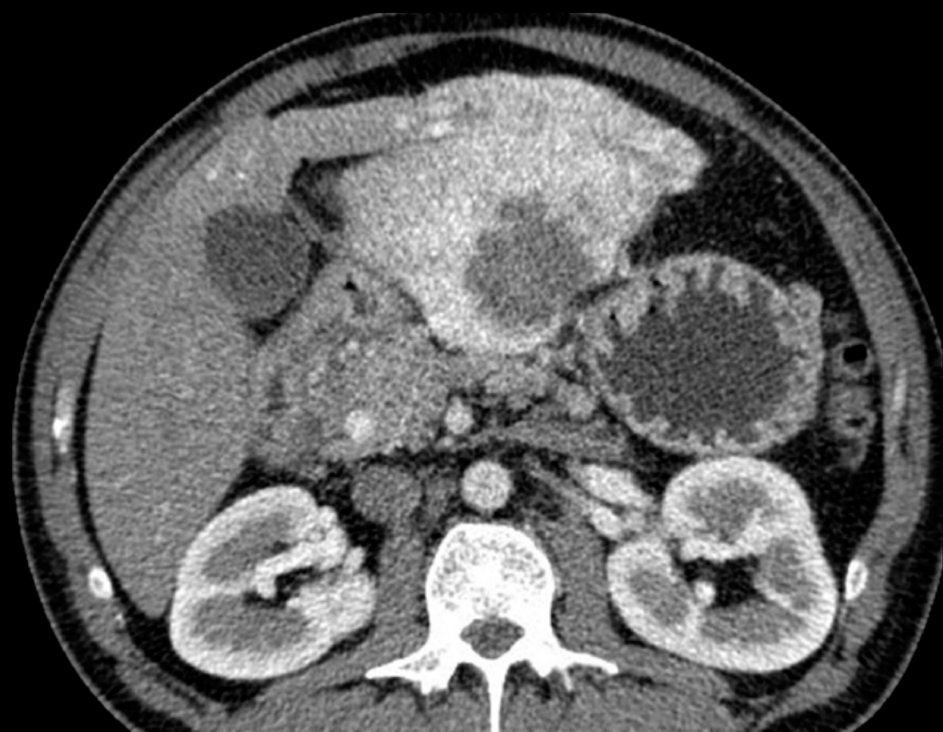
# Gastrointestinal Best Case

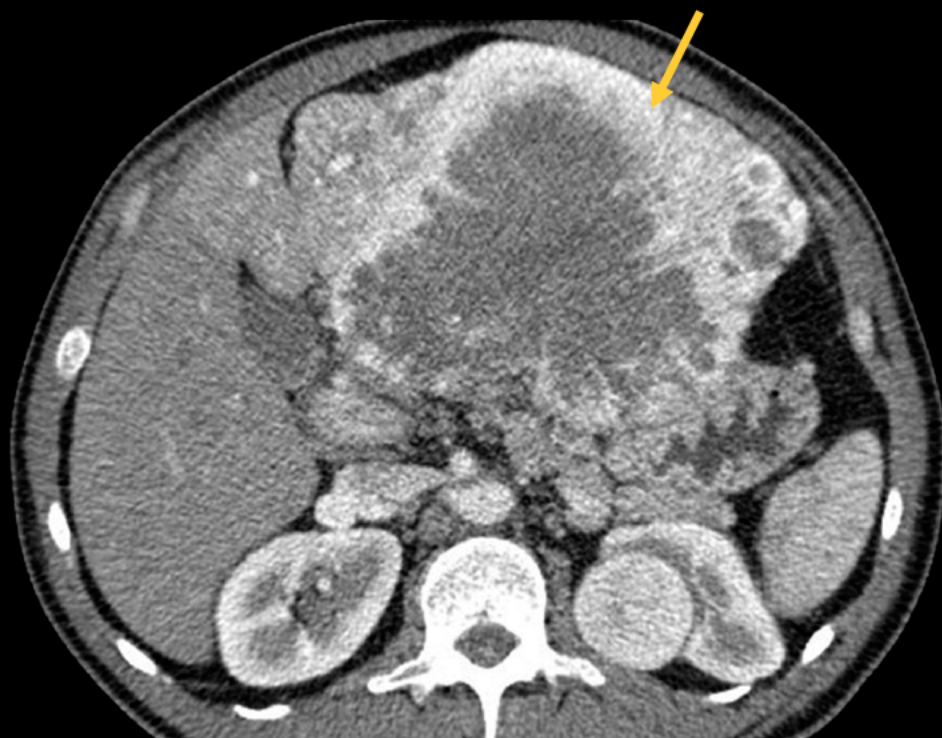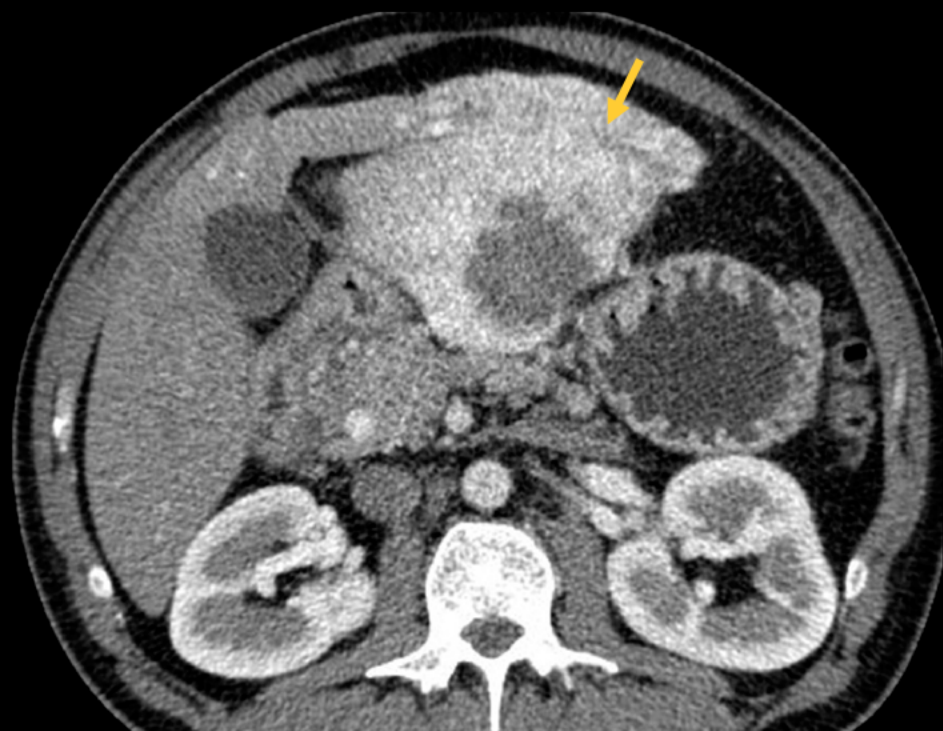




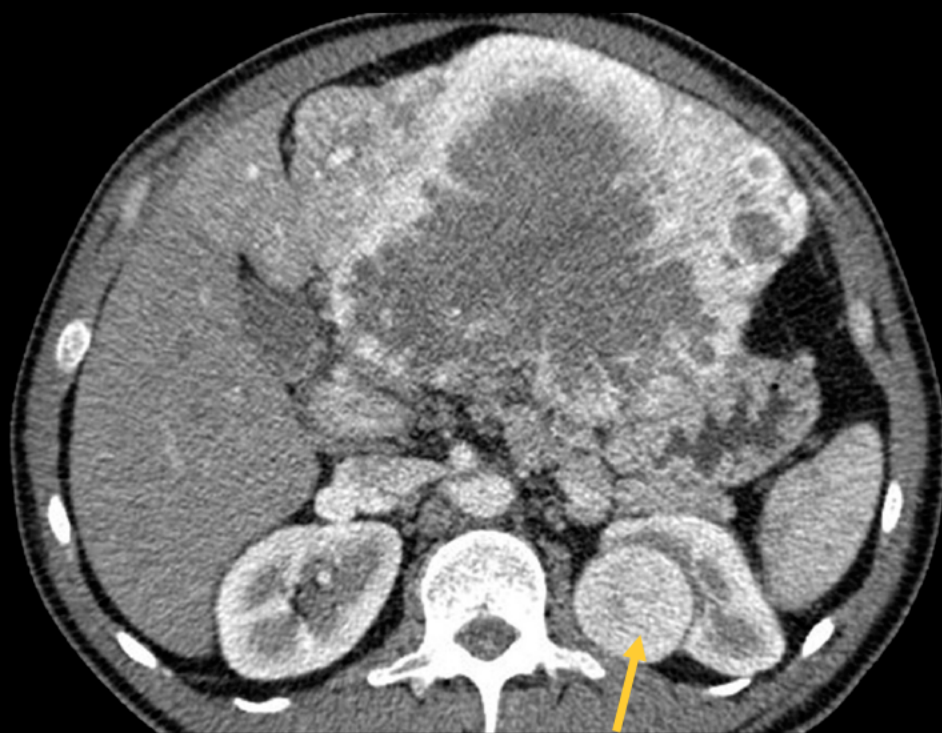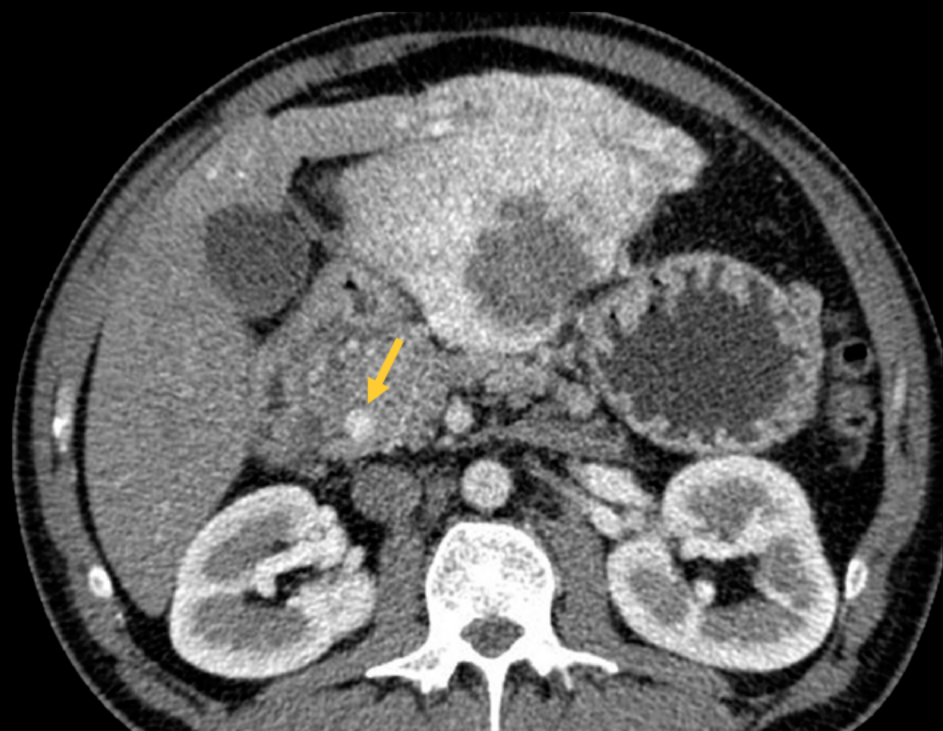
## Clinical information

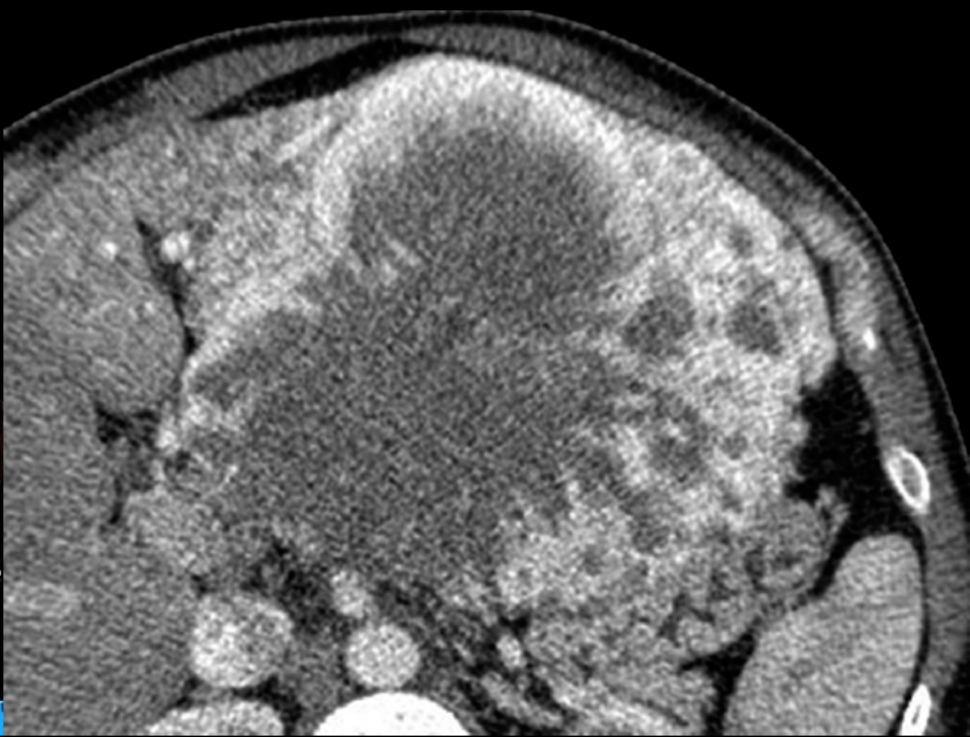
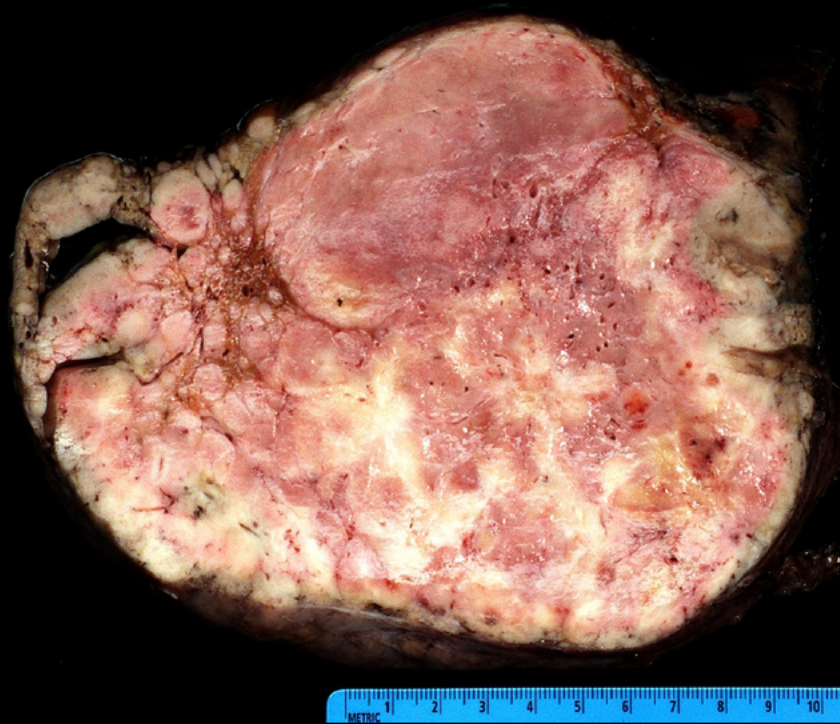
39 year old male with altered mental status  
due to profound hypoglycemia.

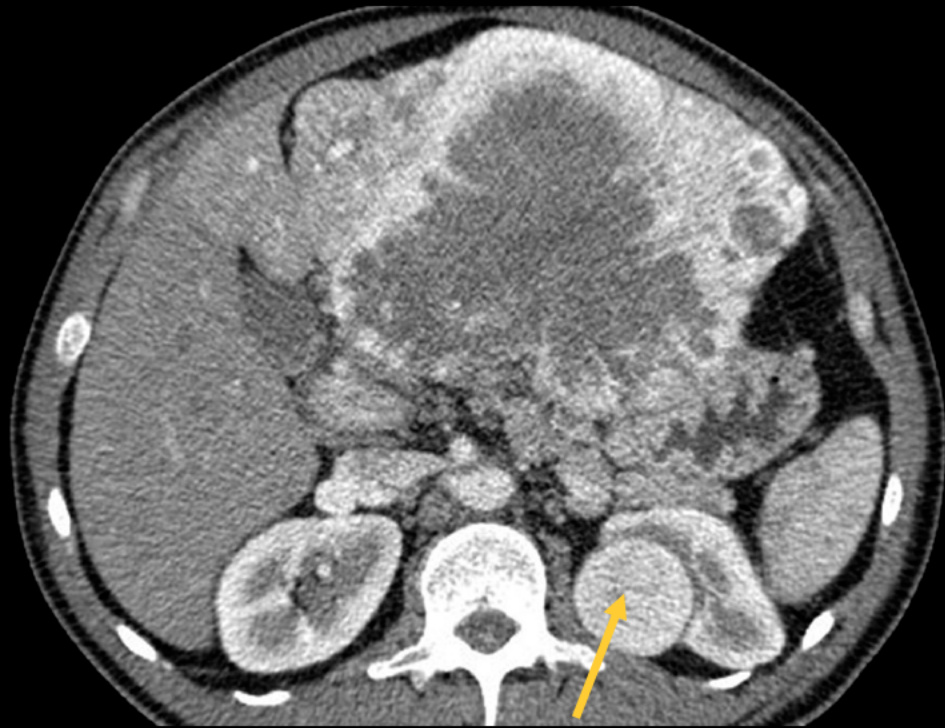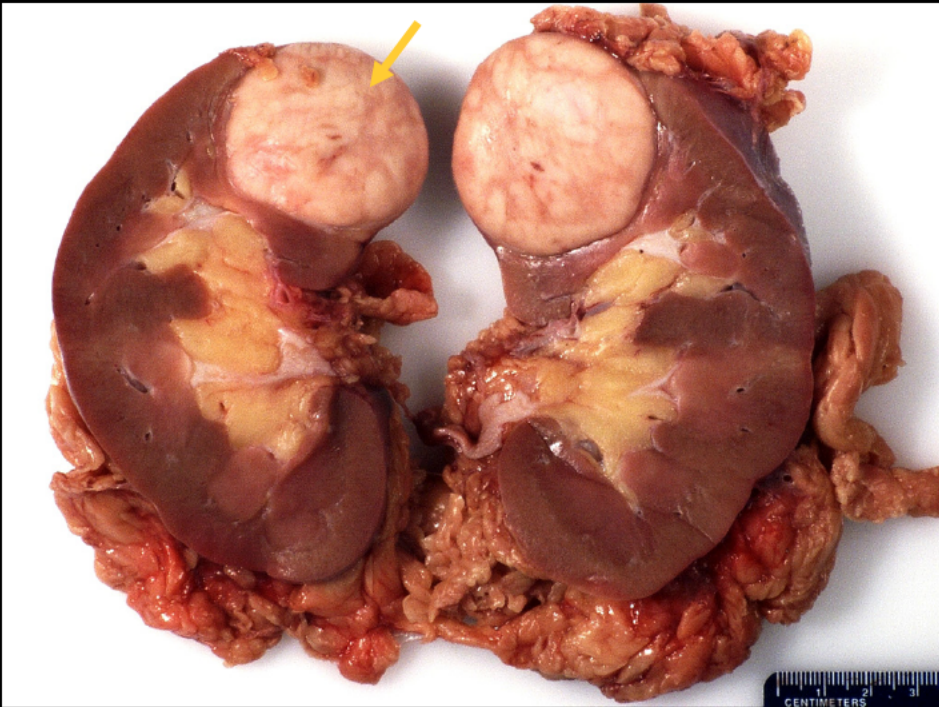




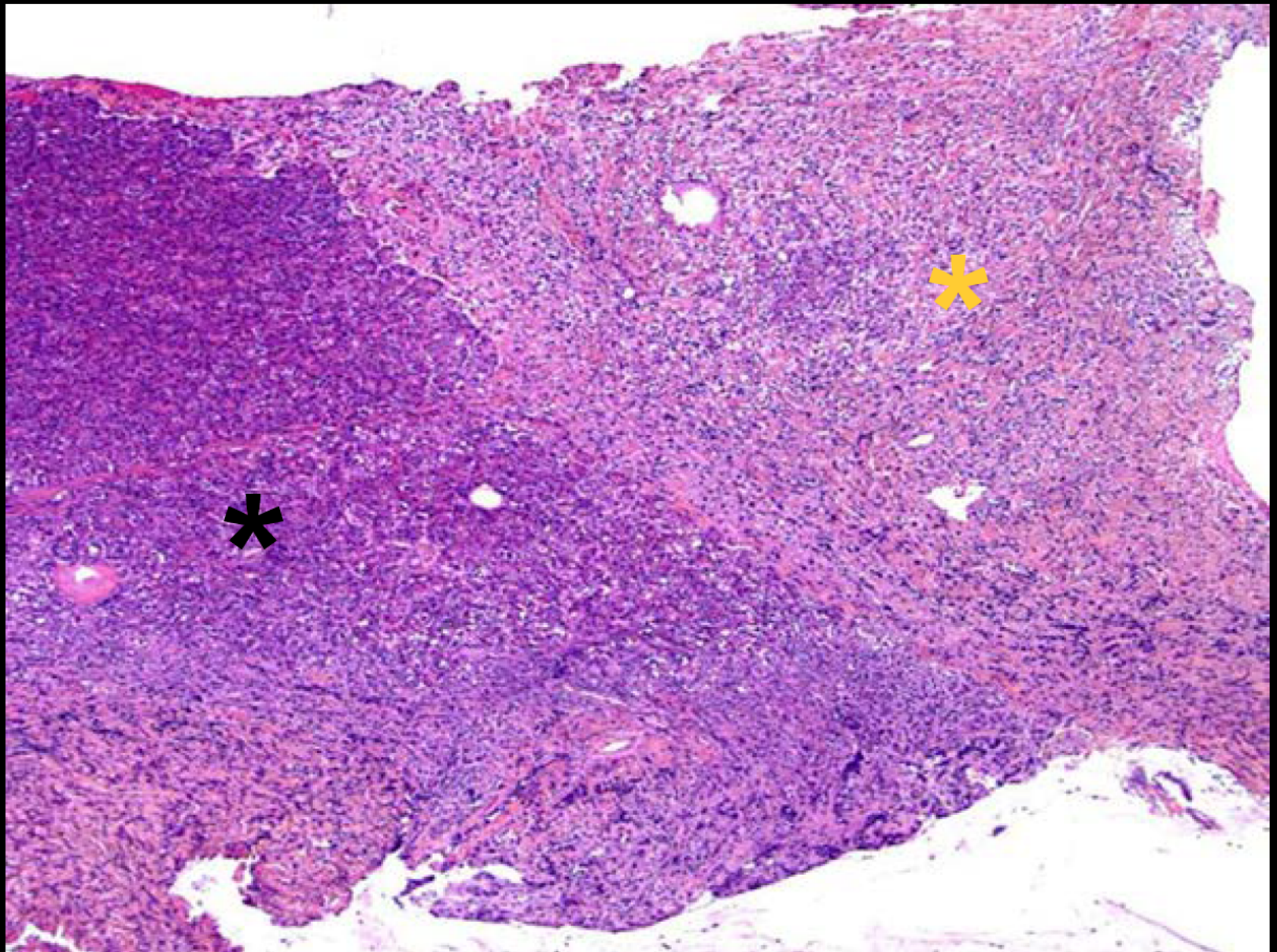




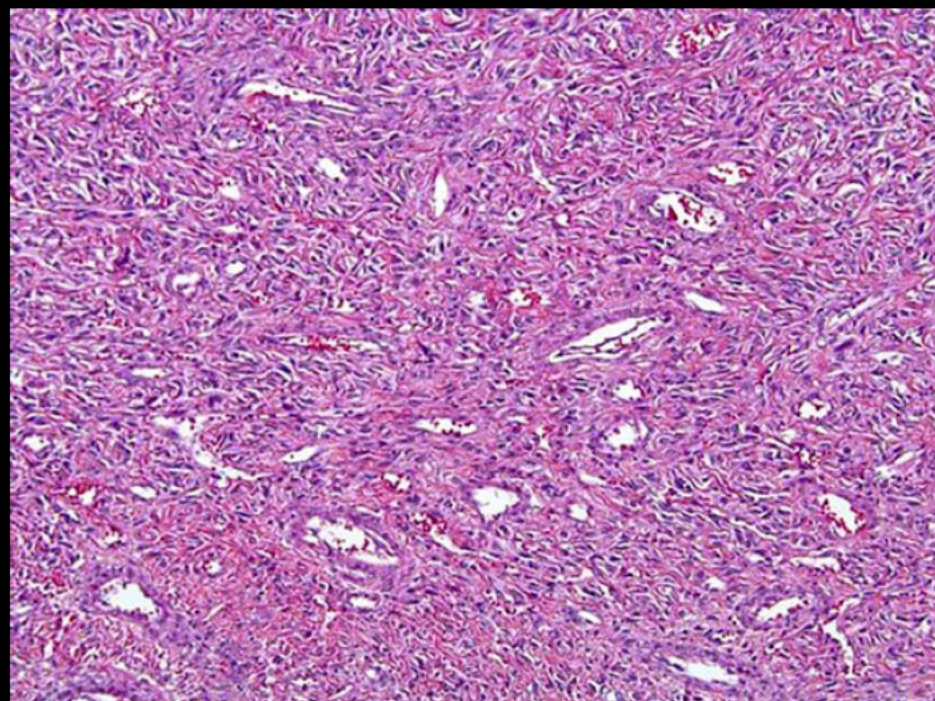
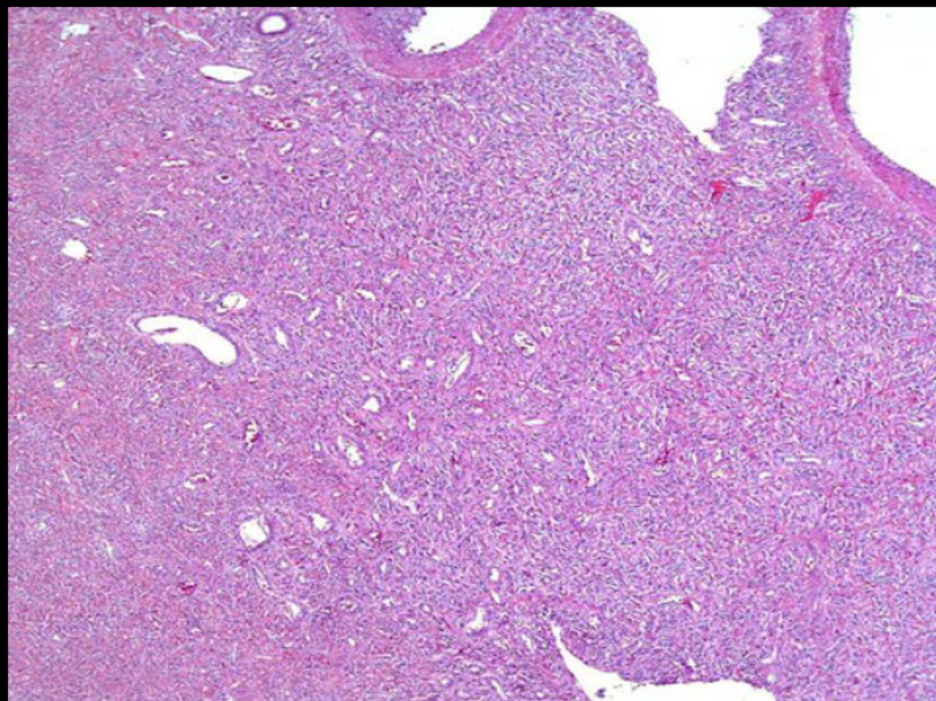









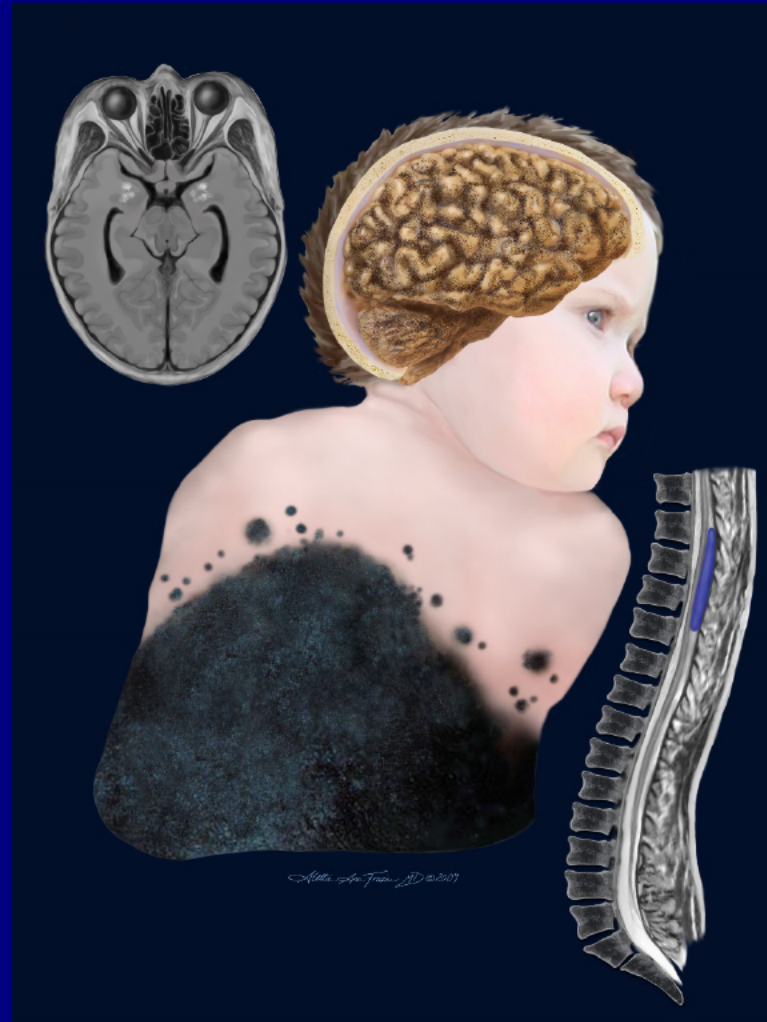


# Multifocal Solitary Fibrous Tumor

Andrew Degnan, M.D.  
University of Pittsburgh  
Pittsburgh, PA

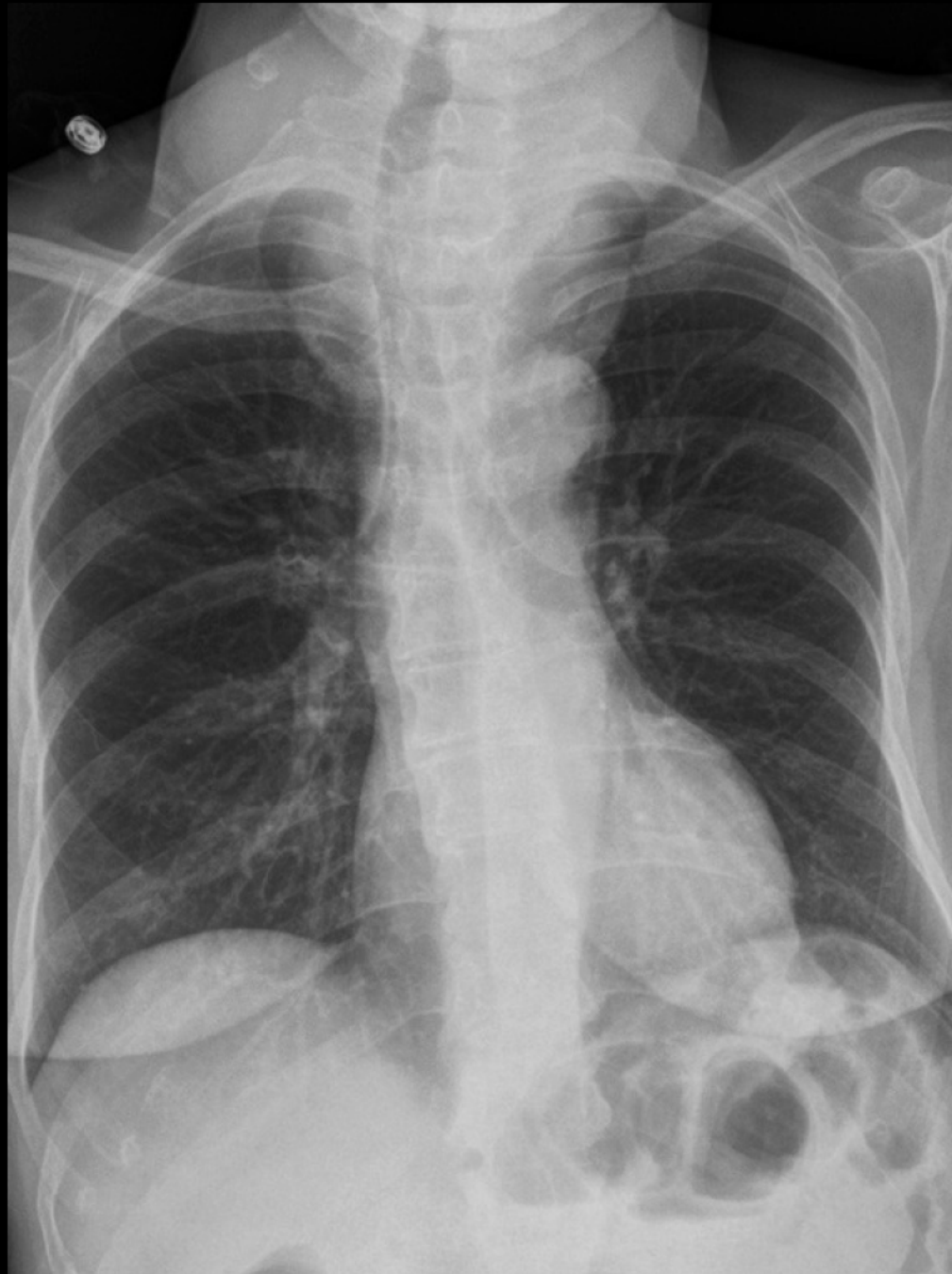
# Neuroradiology Best Case

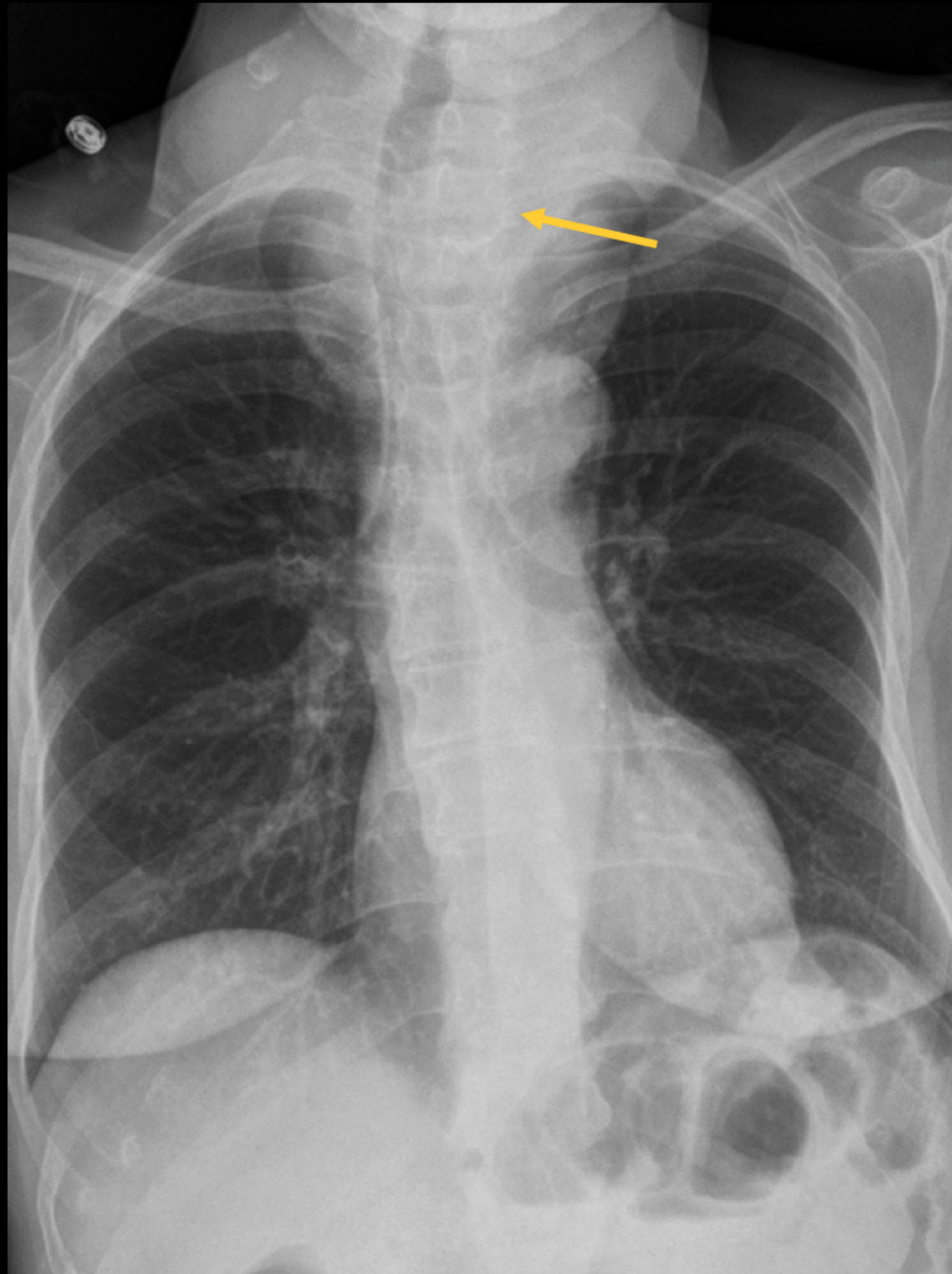




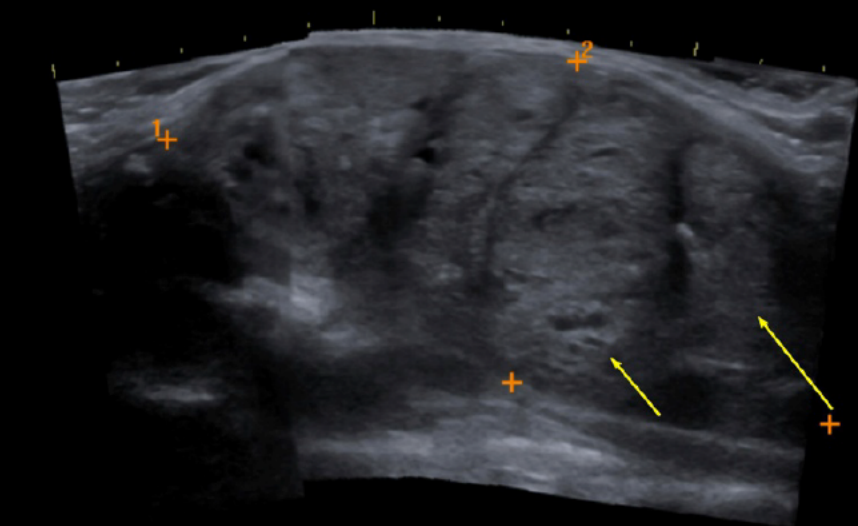
# Clinical Information

59-year-old euthyroid female with  
slowly enlarging neck mass for 12  
years



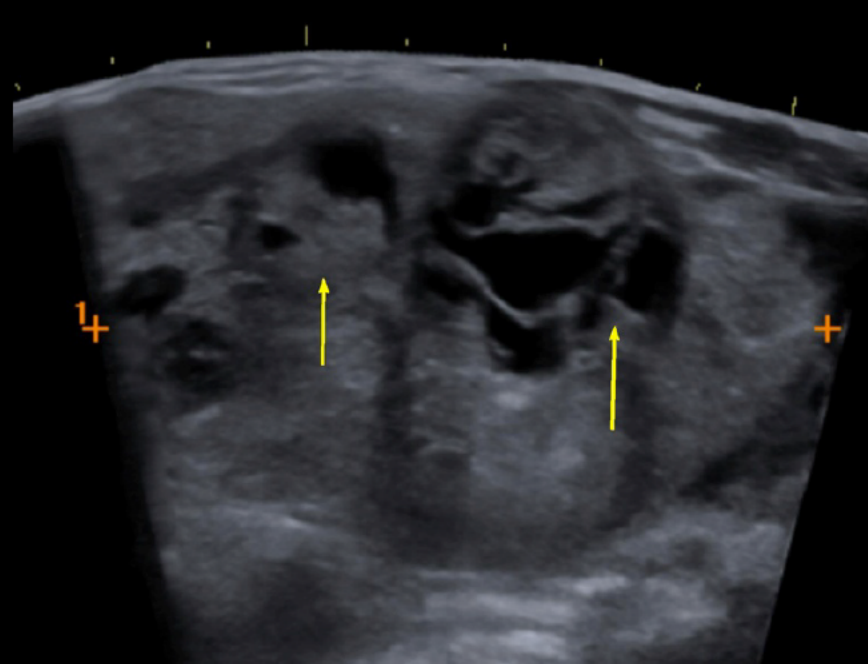
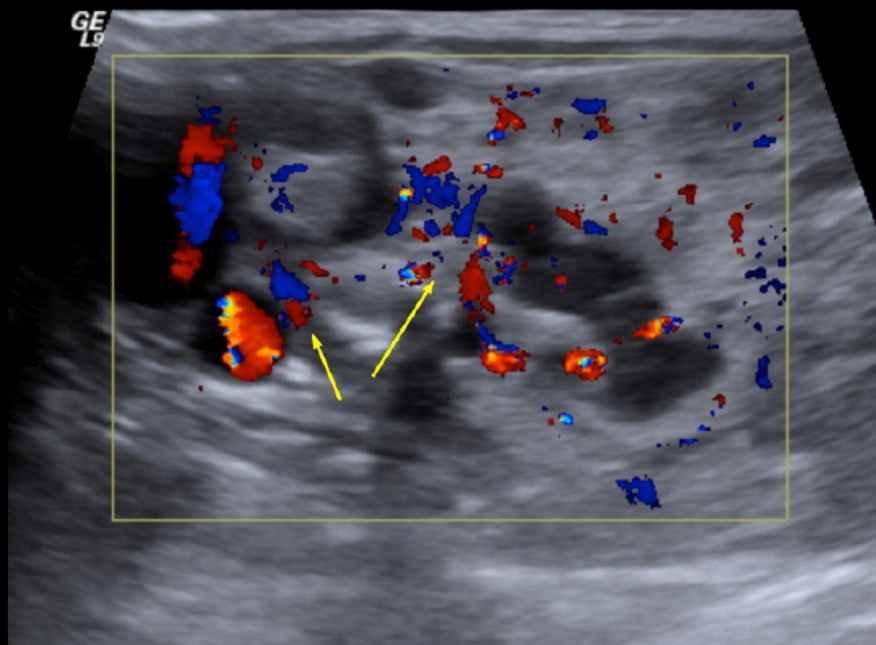
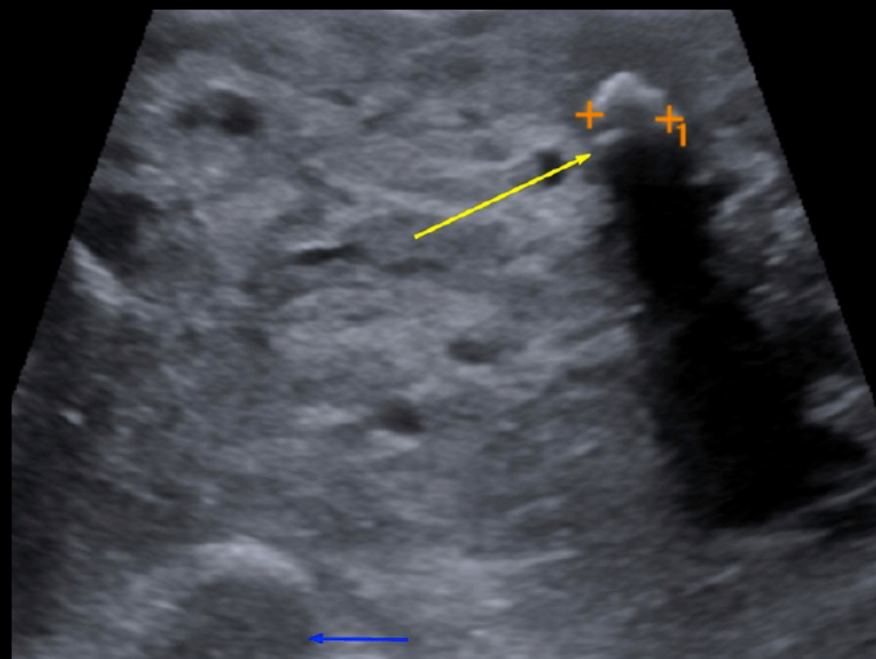


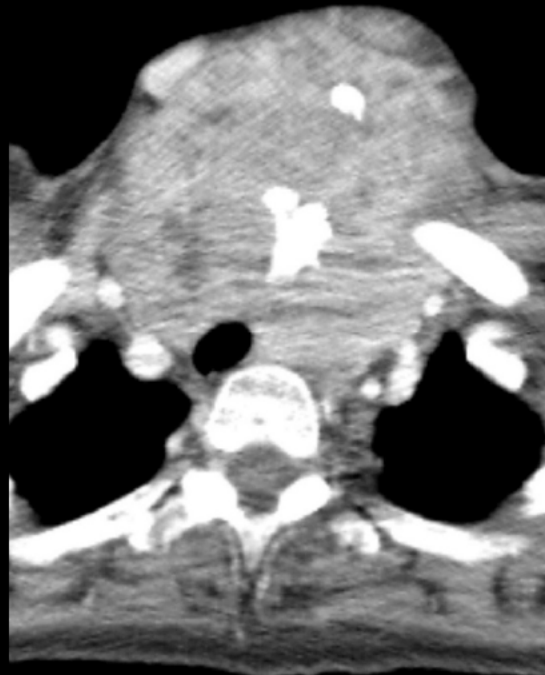
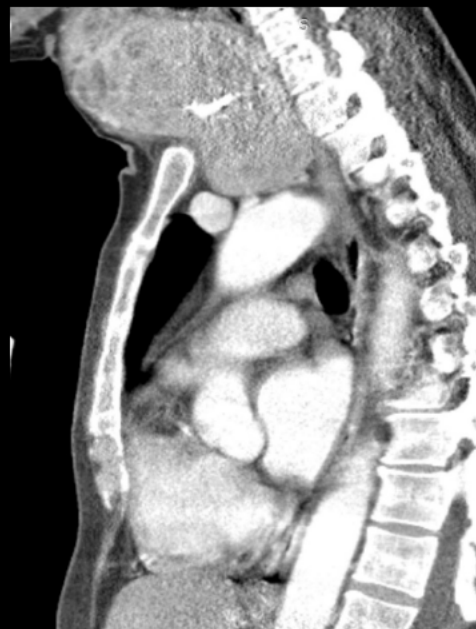
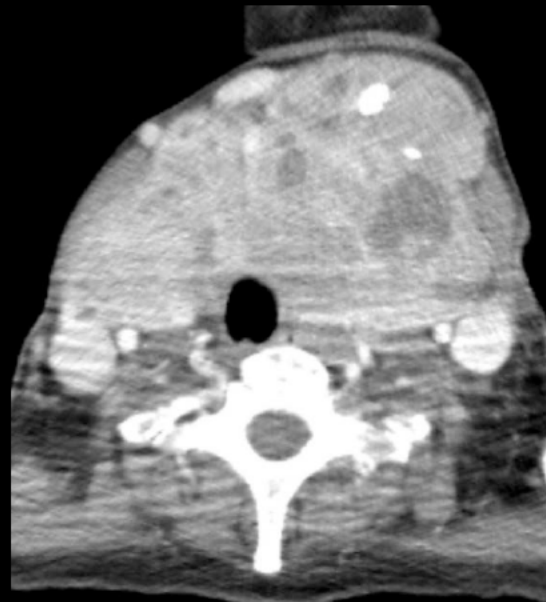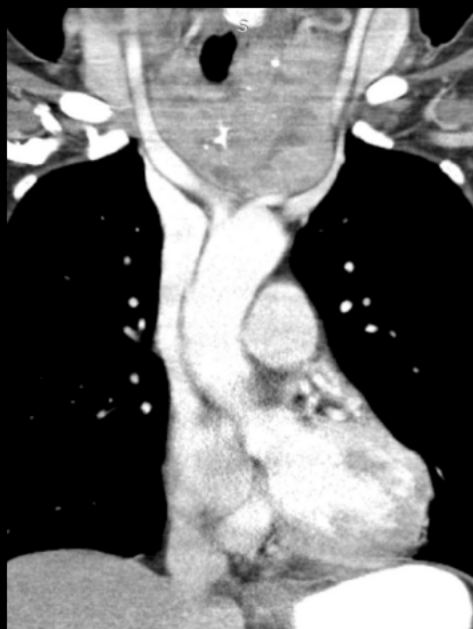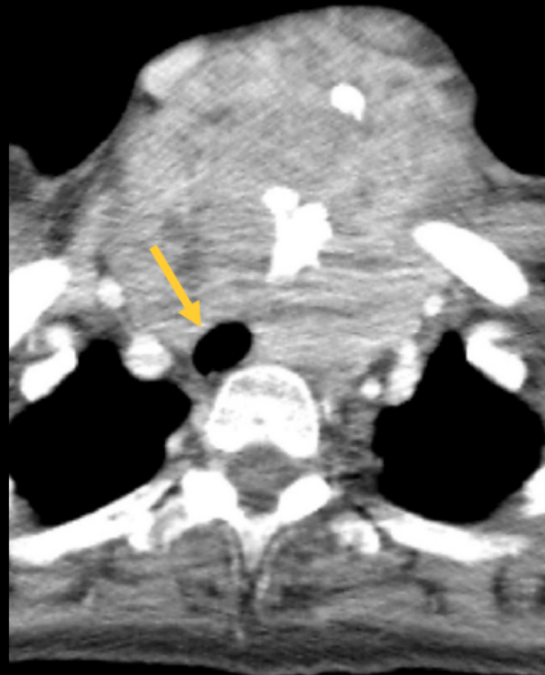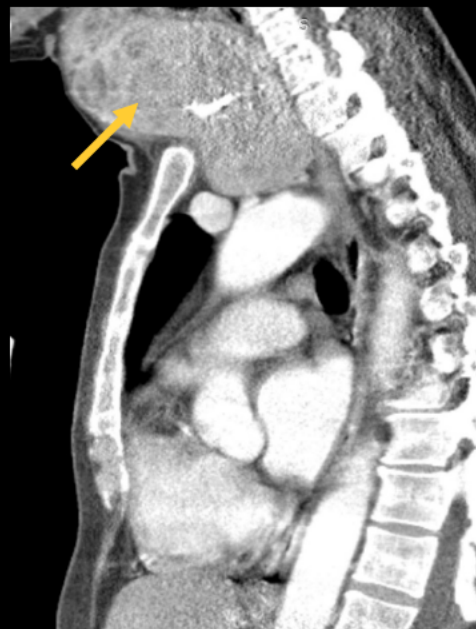


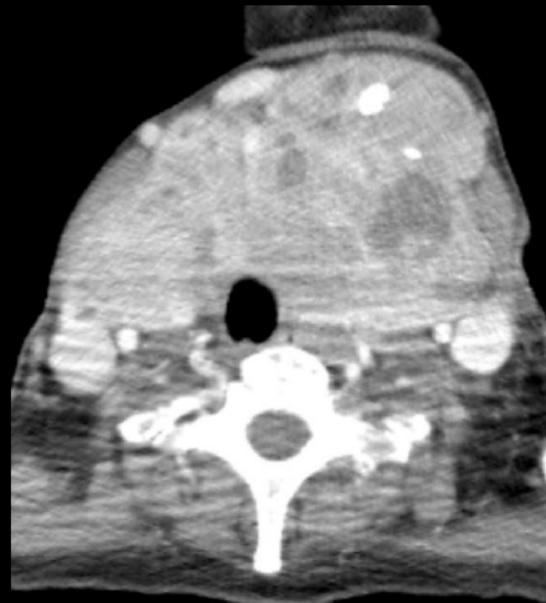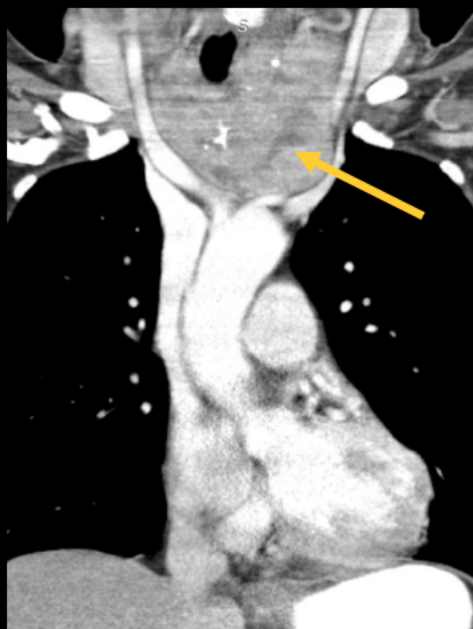1 L 11.11 cm  
 2 L 5.05 cm

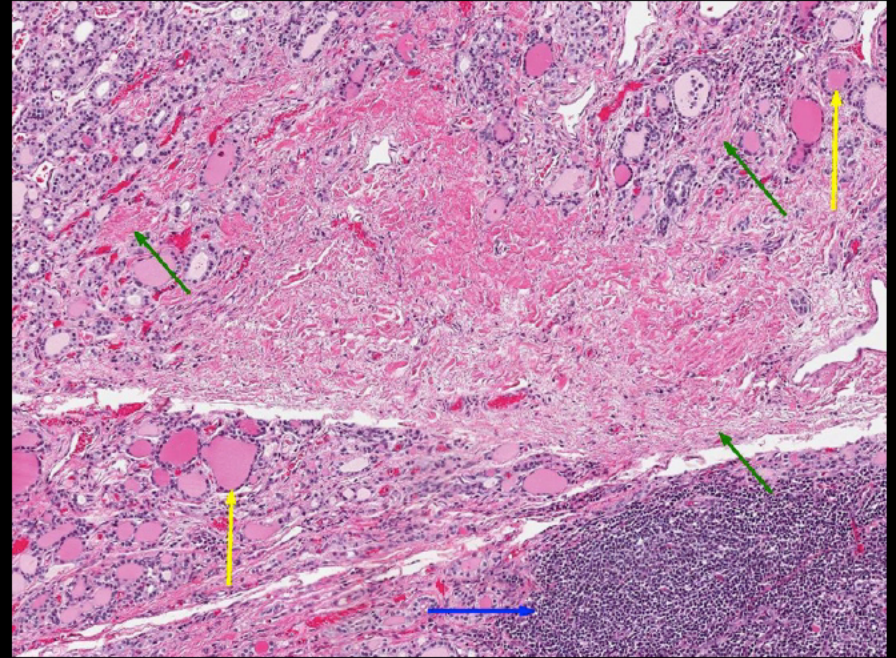
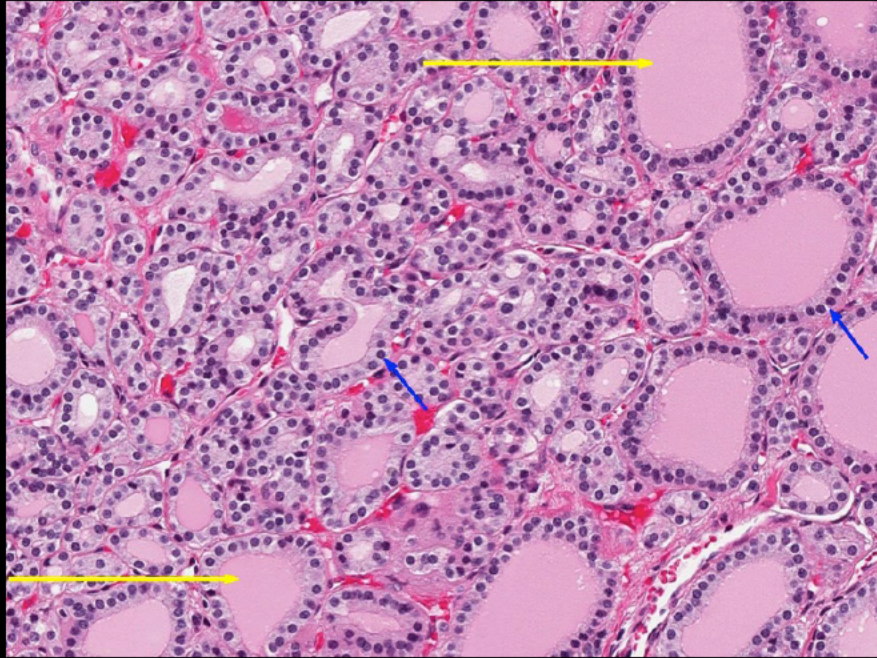
SAG LT LOBE

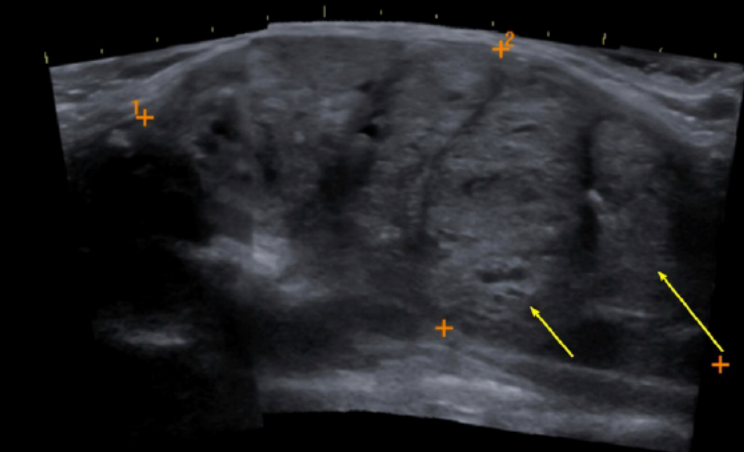





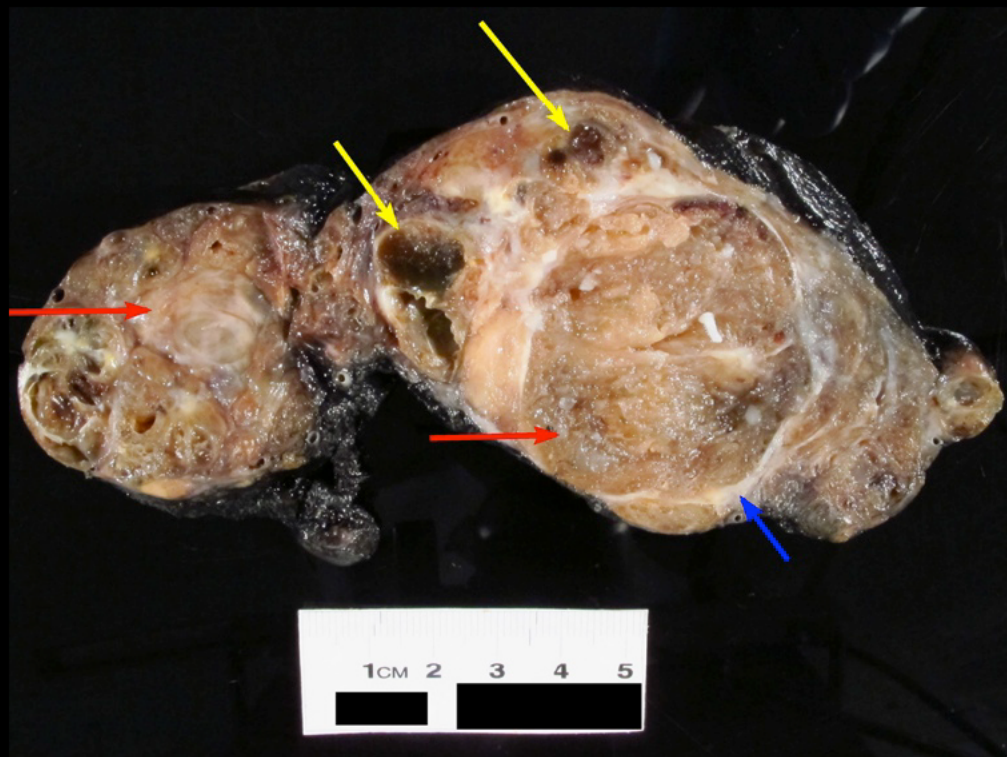
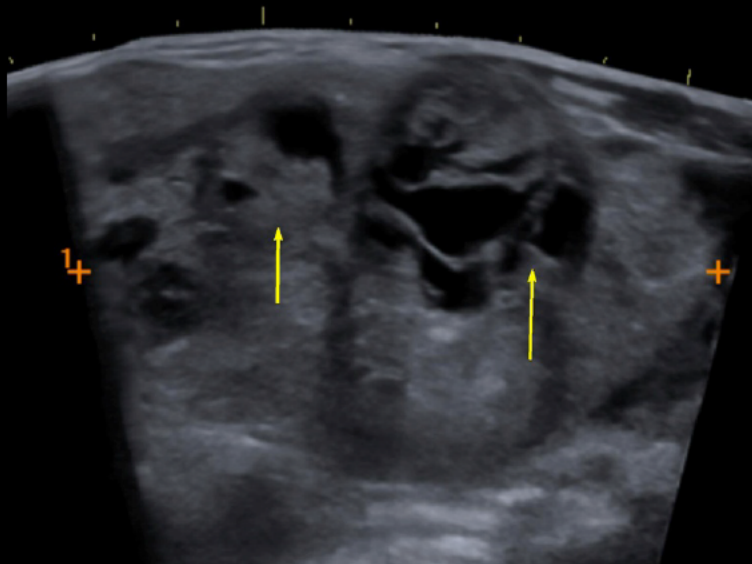




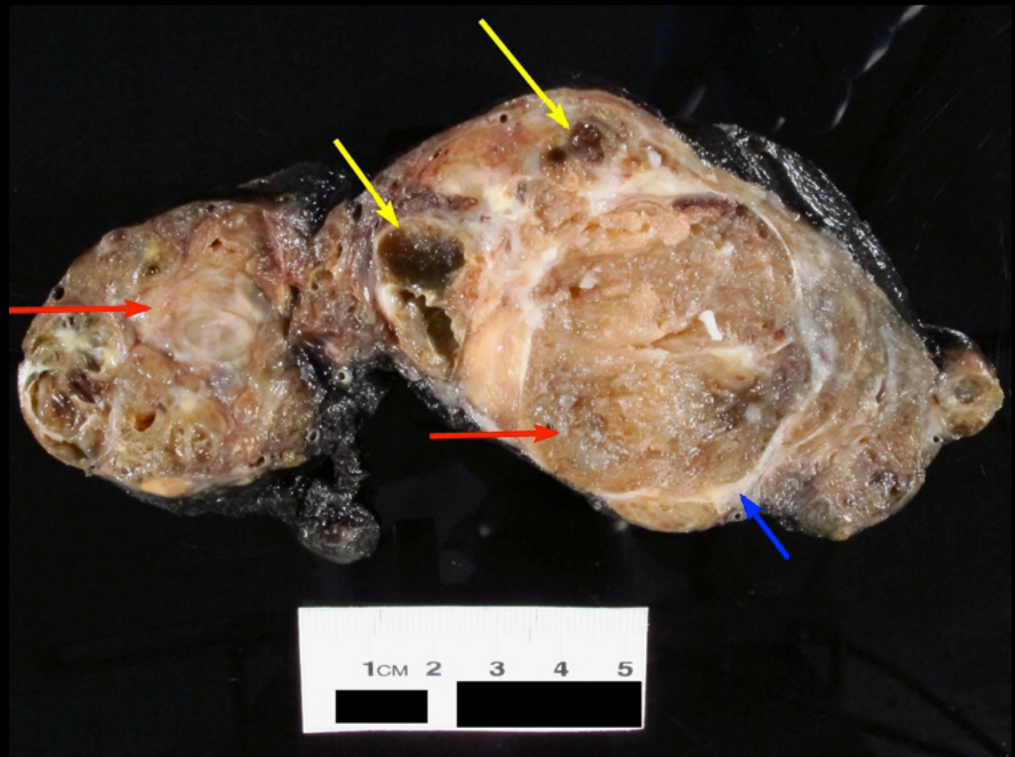
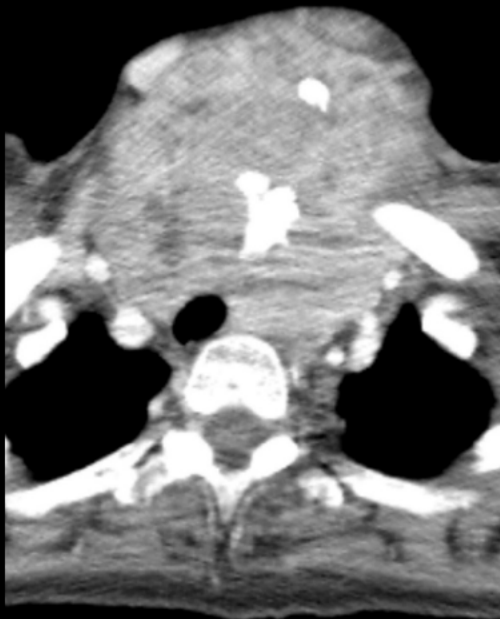

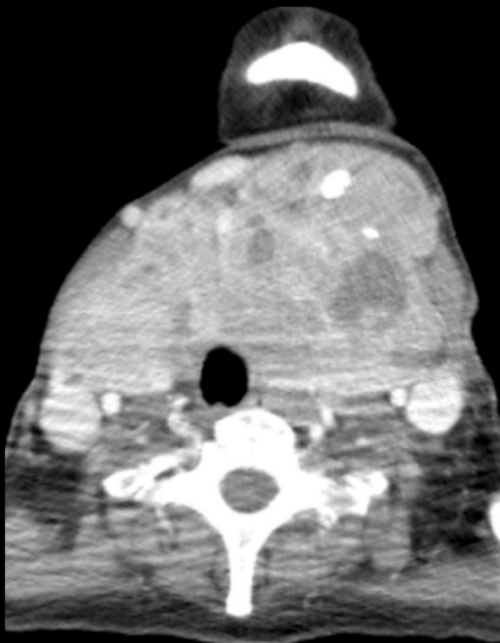
1 L 11.11 cm  
2 L 5.05 cm

SAG LT LOBE









# Goiter

Mathew Bligh, M.D.  
Queen Elizabeth II  
Health Sciences Centre  
Halifax, Nova Scotia, Canada

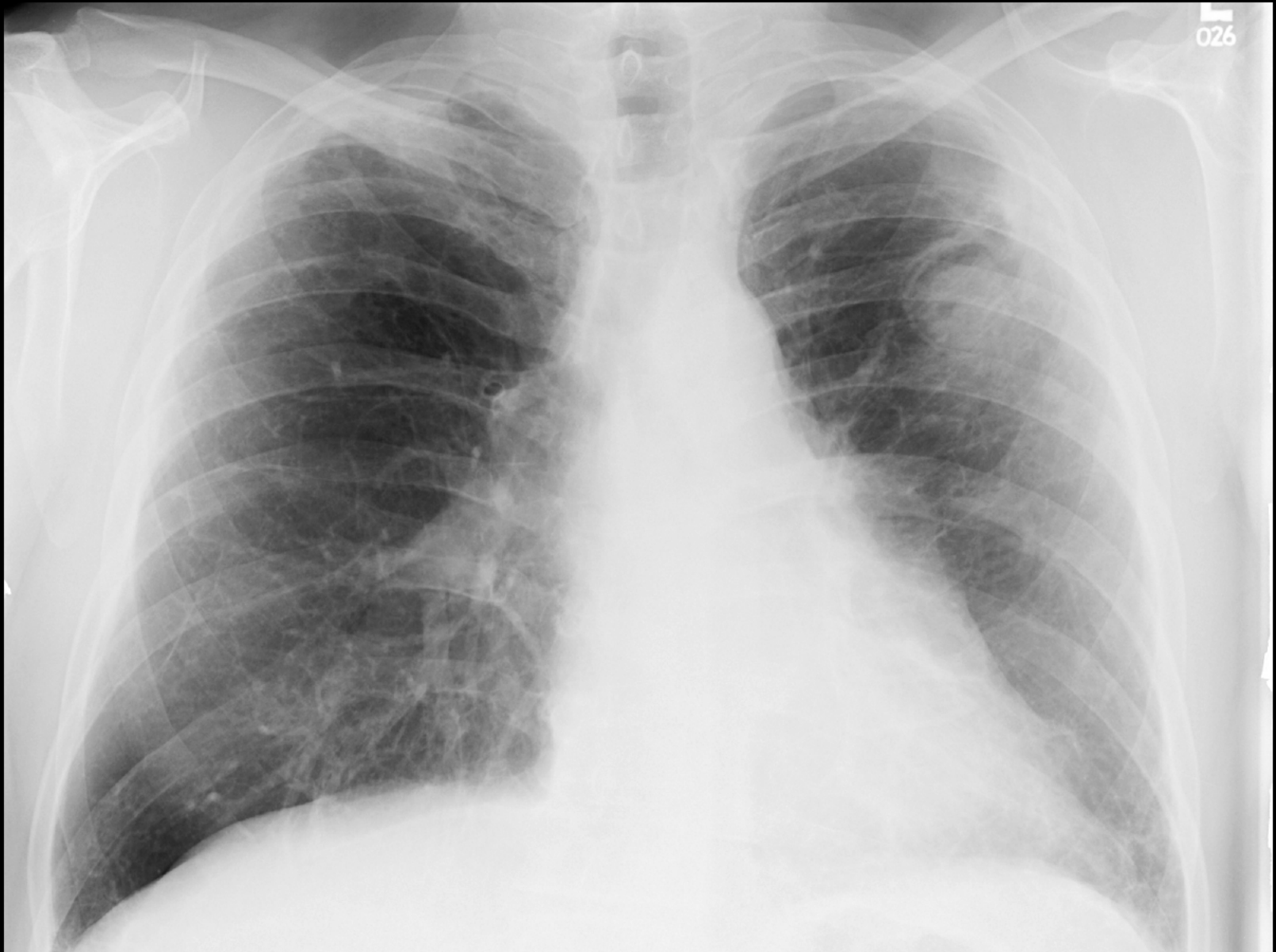


## Clinical Information

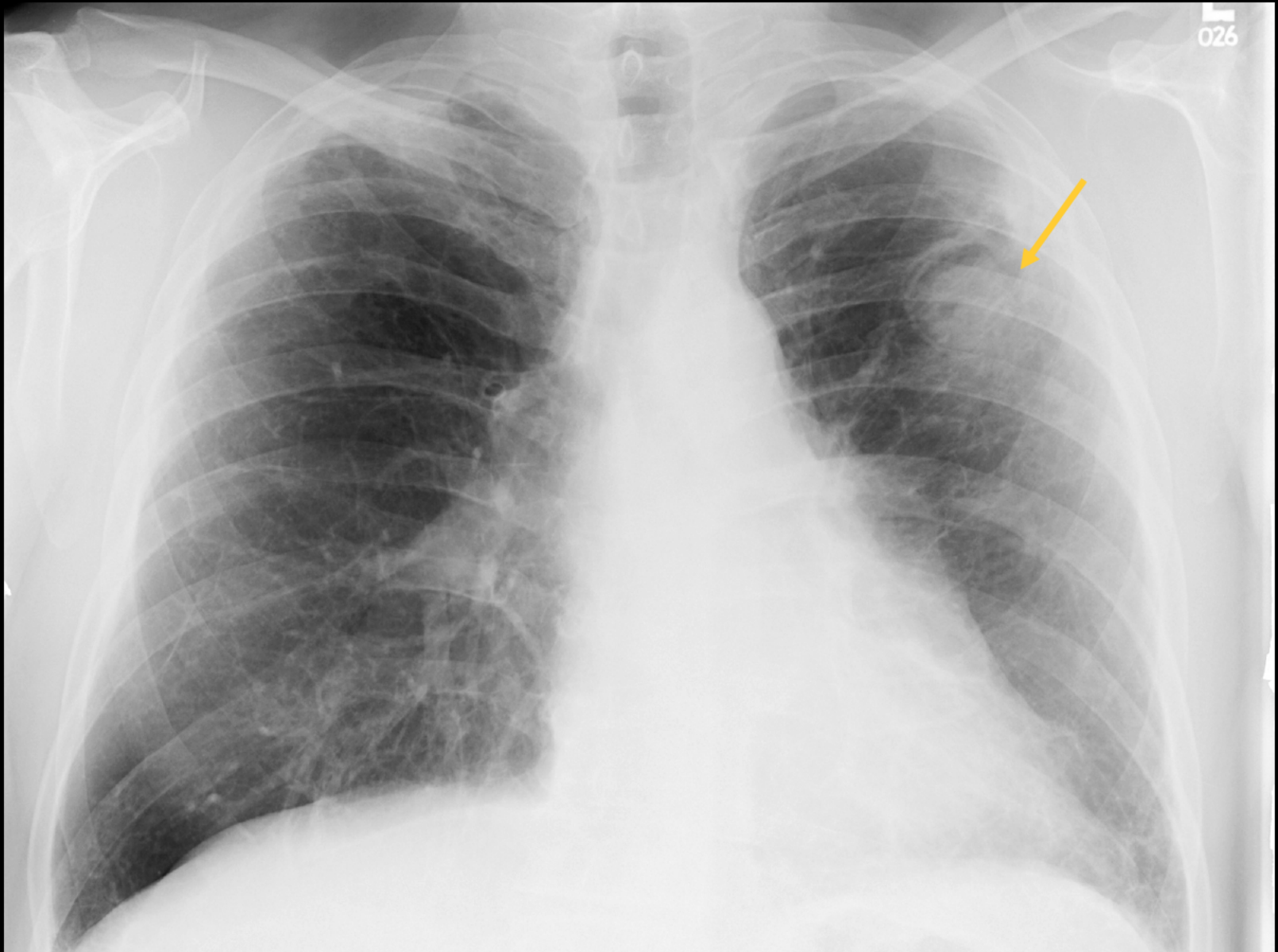
54 year old with 8 months of productive cough,  
prior weight loss and night sweats.  
Previously negative PPD



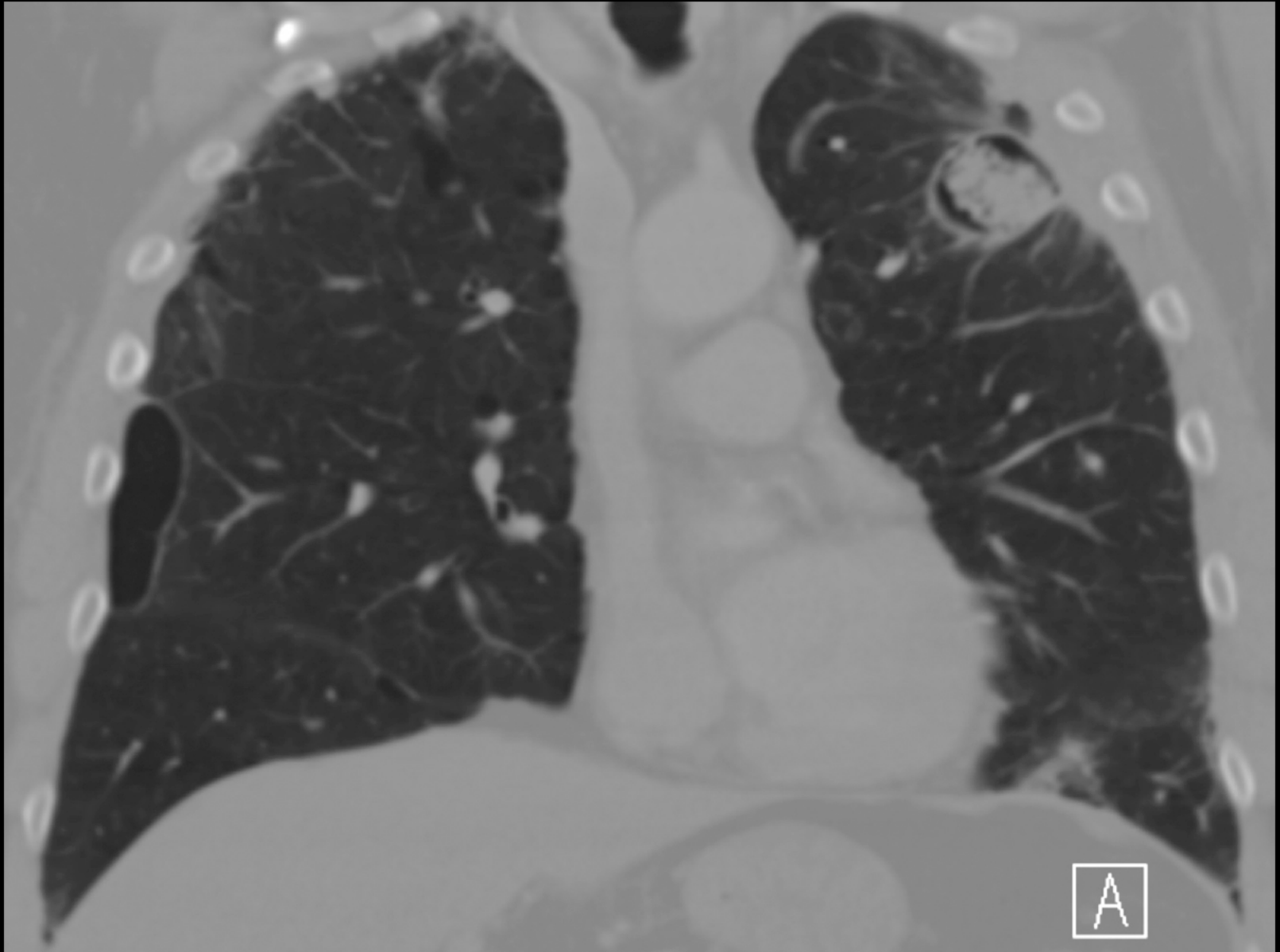
# Cavitary Mass



# Cavitary Mass

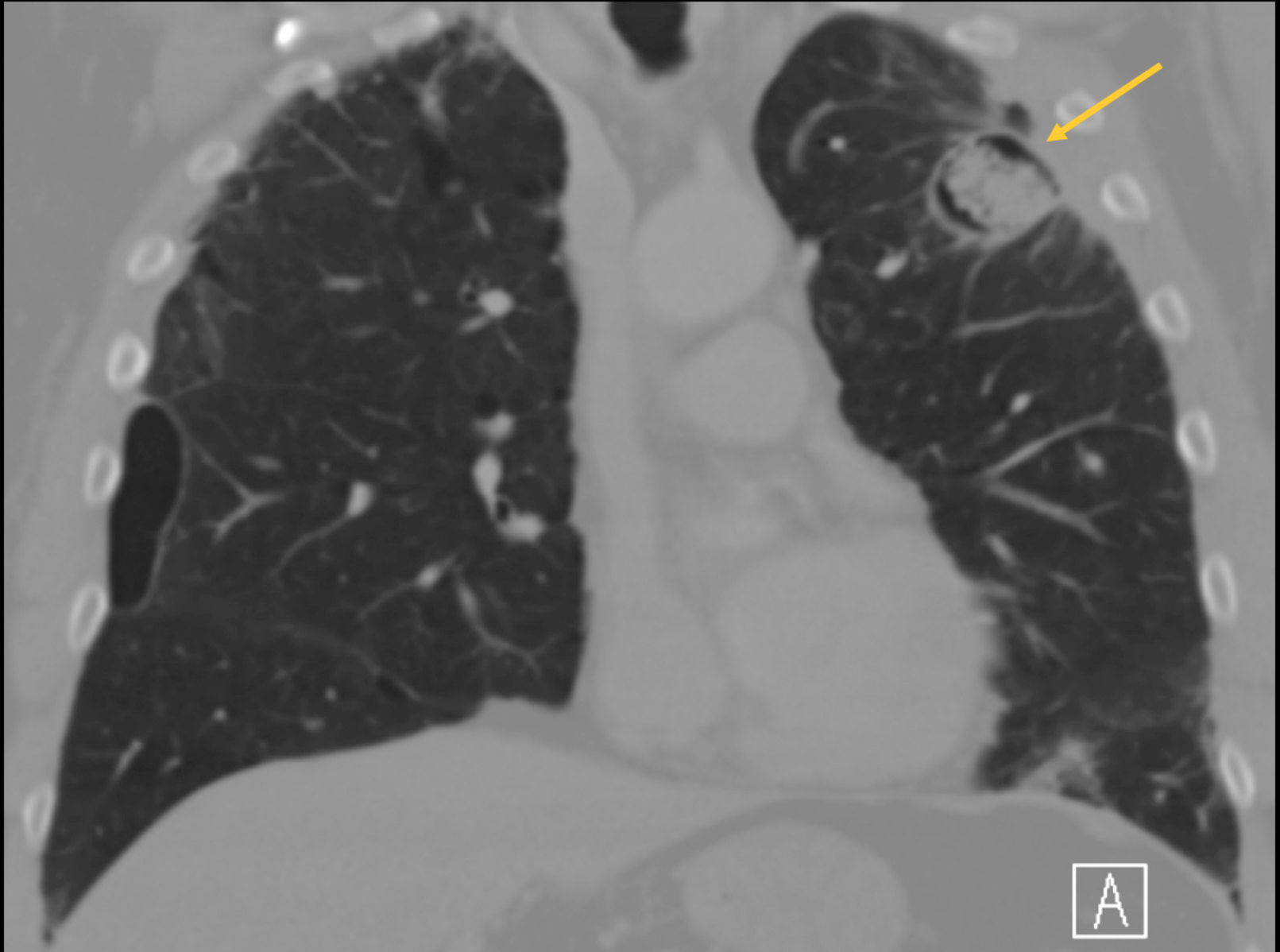


# Cavitary Mass

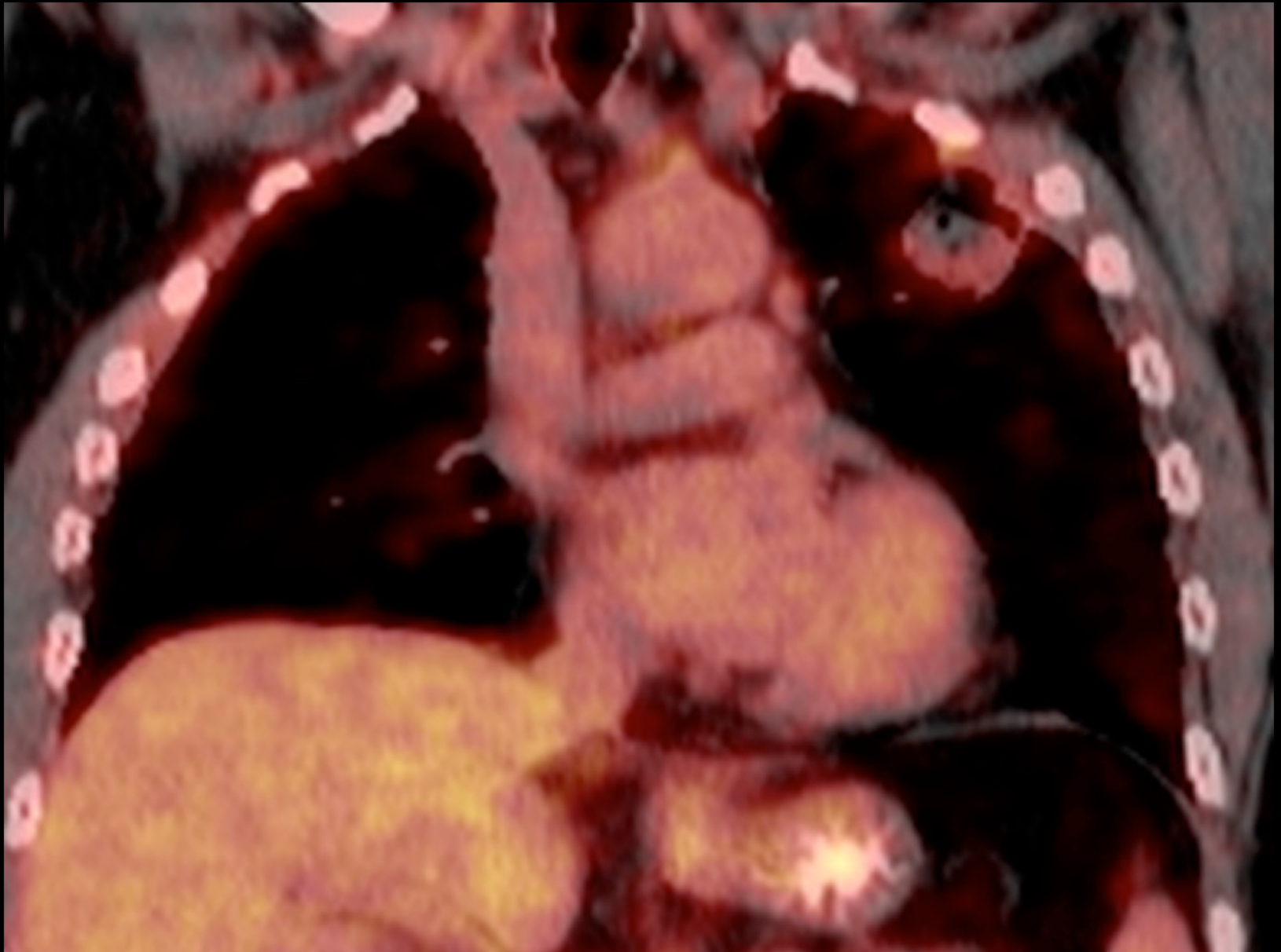




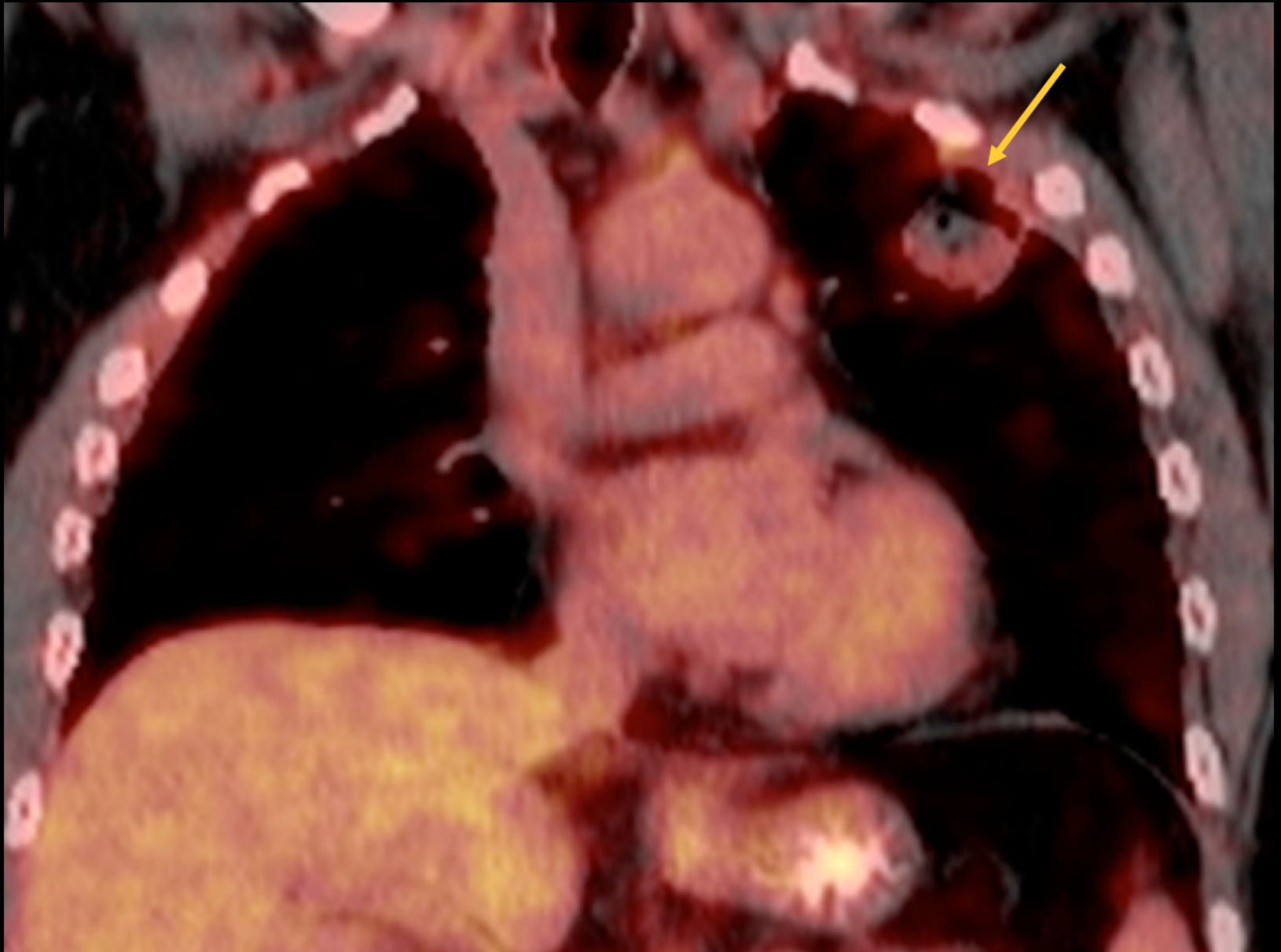
# Cavitary Mass



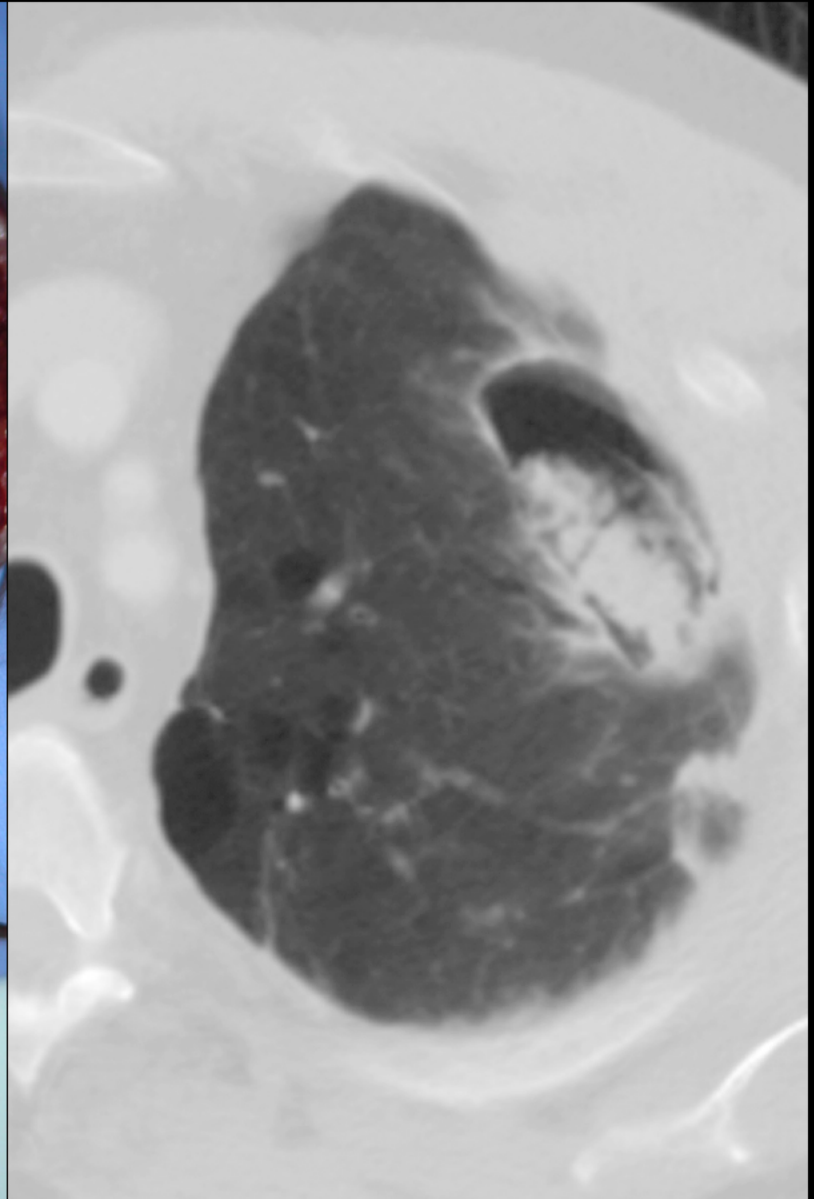
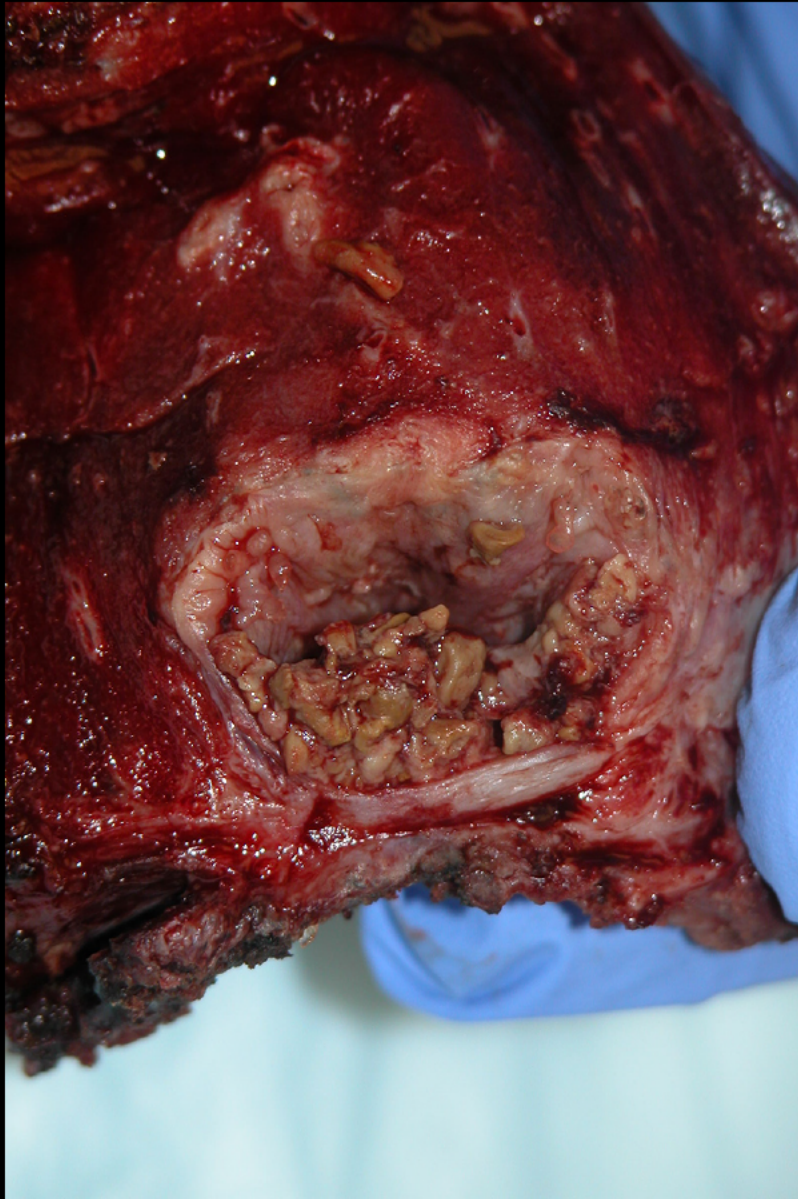# PET/CT

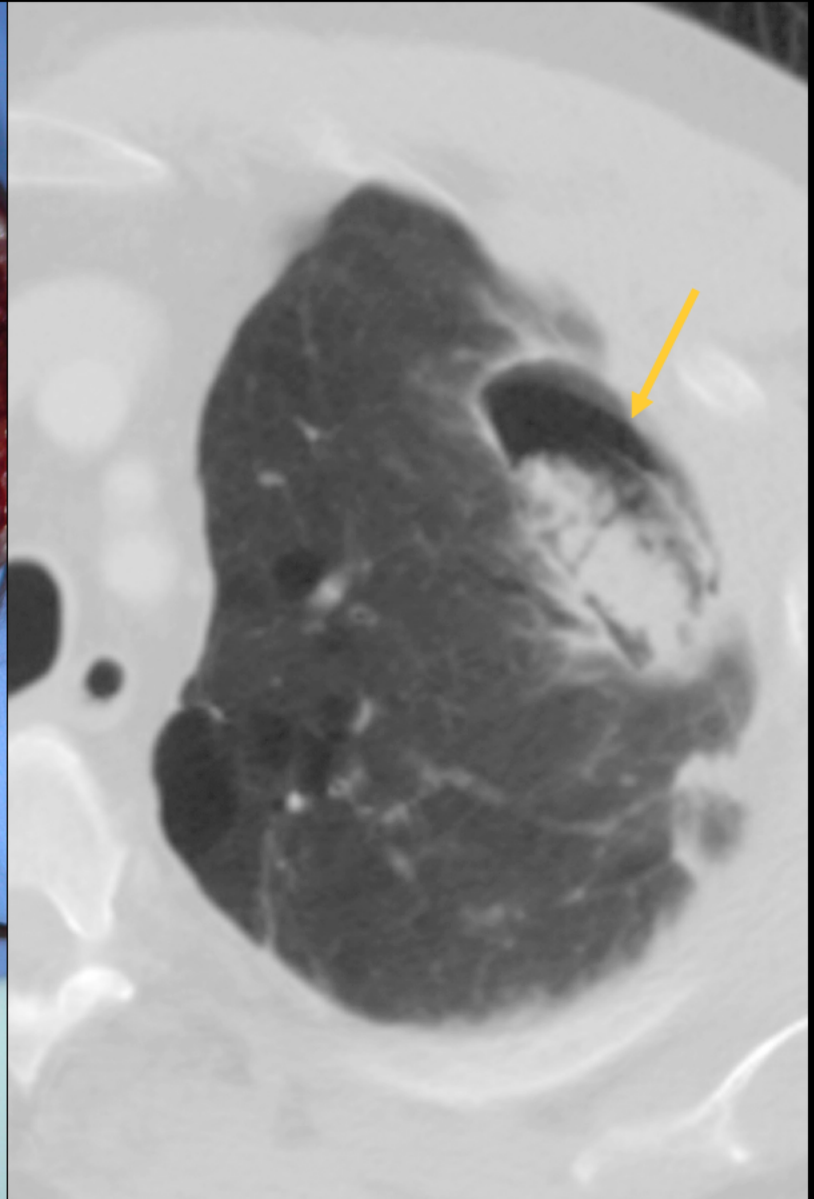
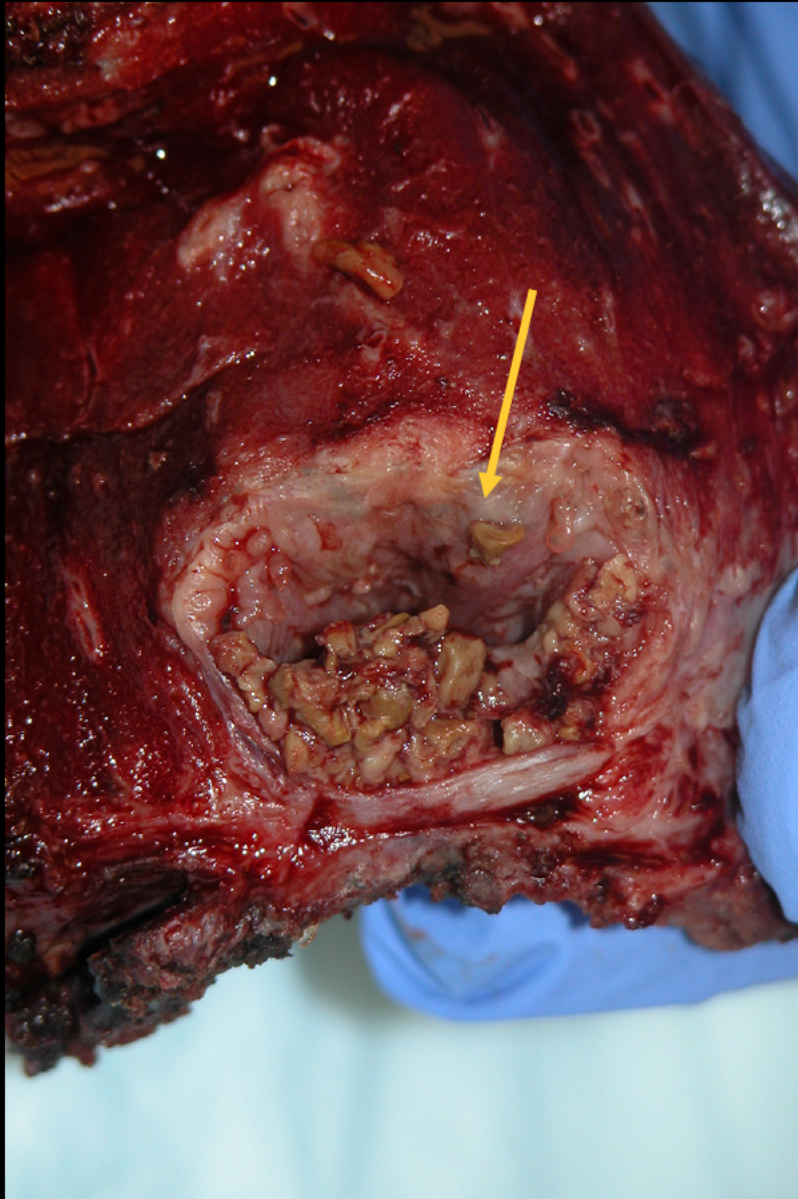


# PET/CT

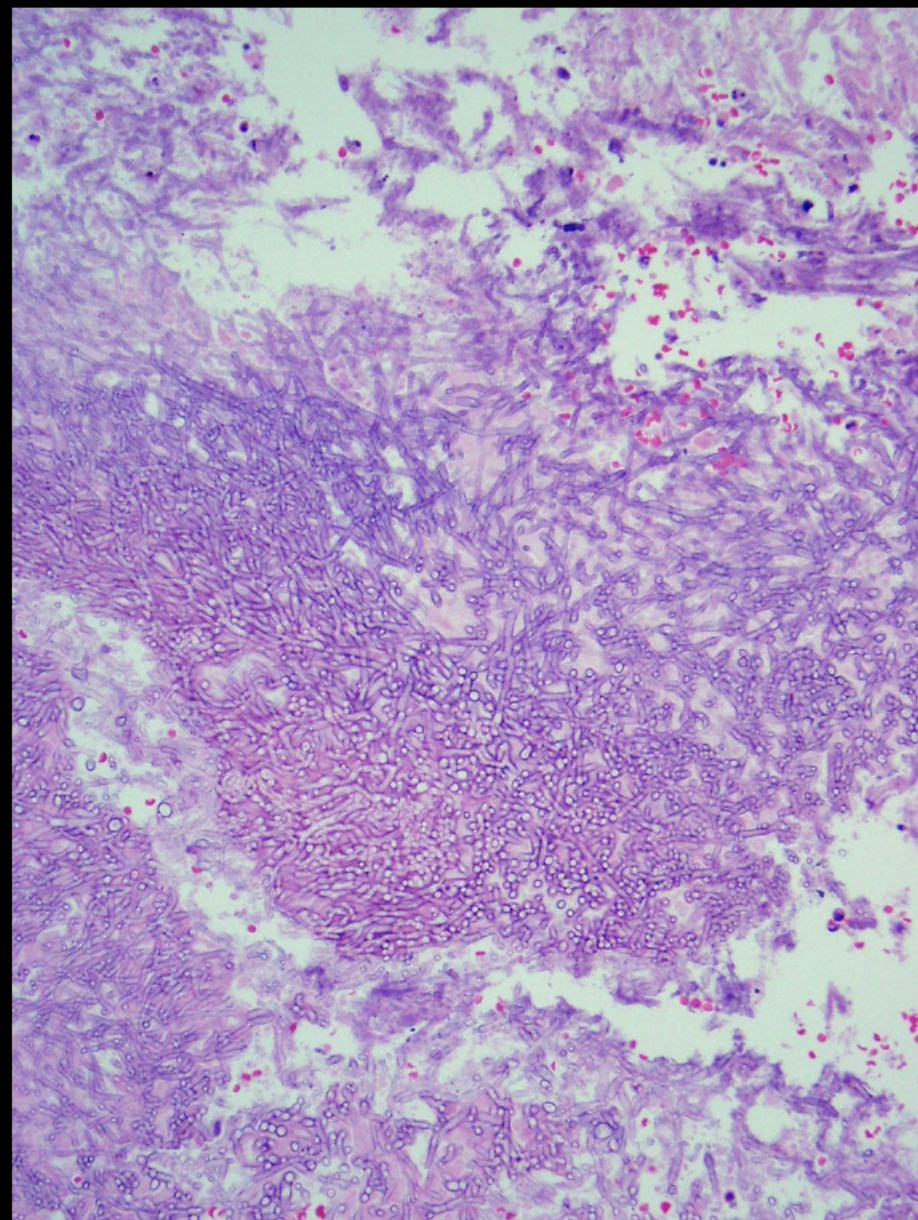
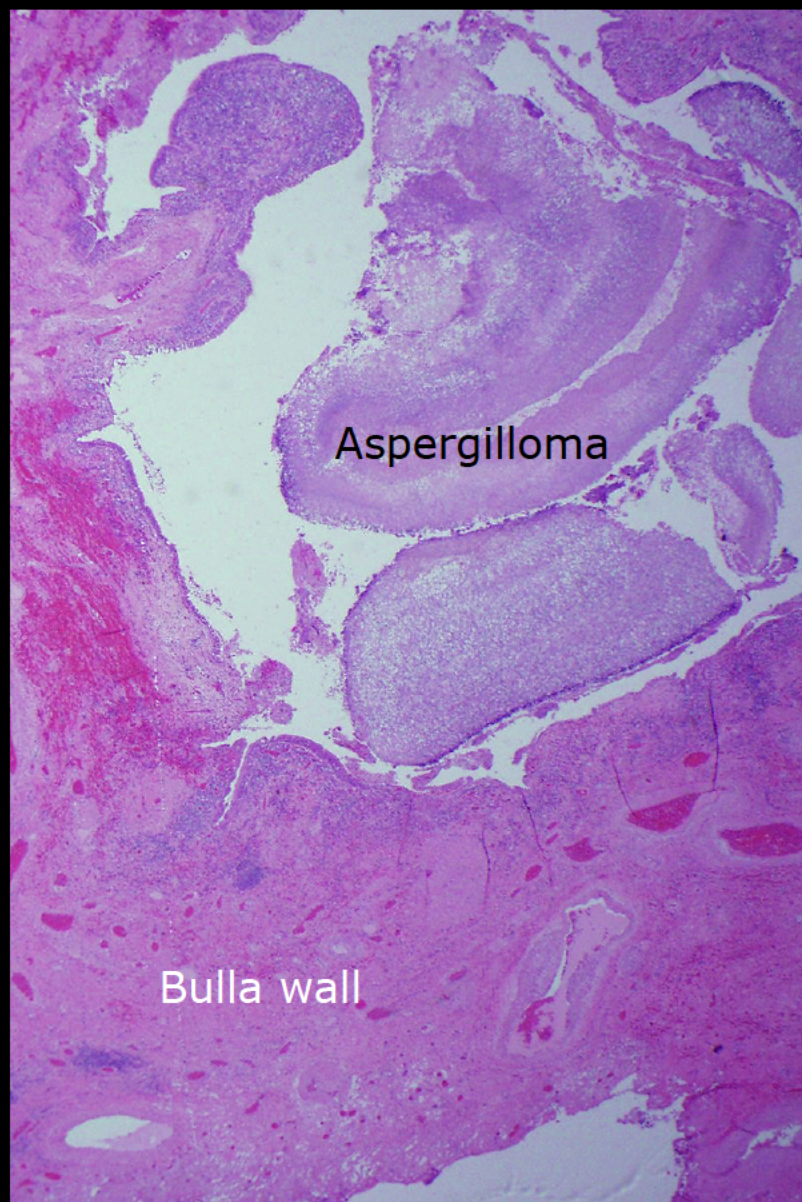




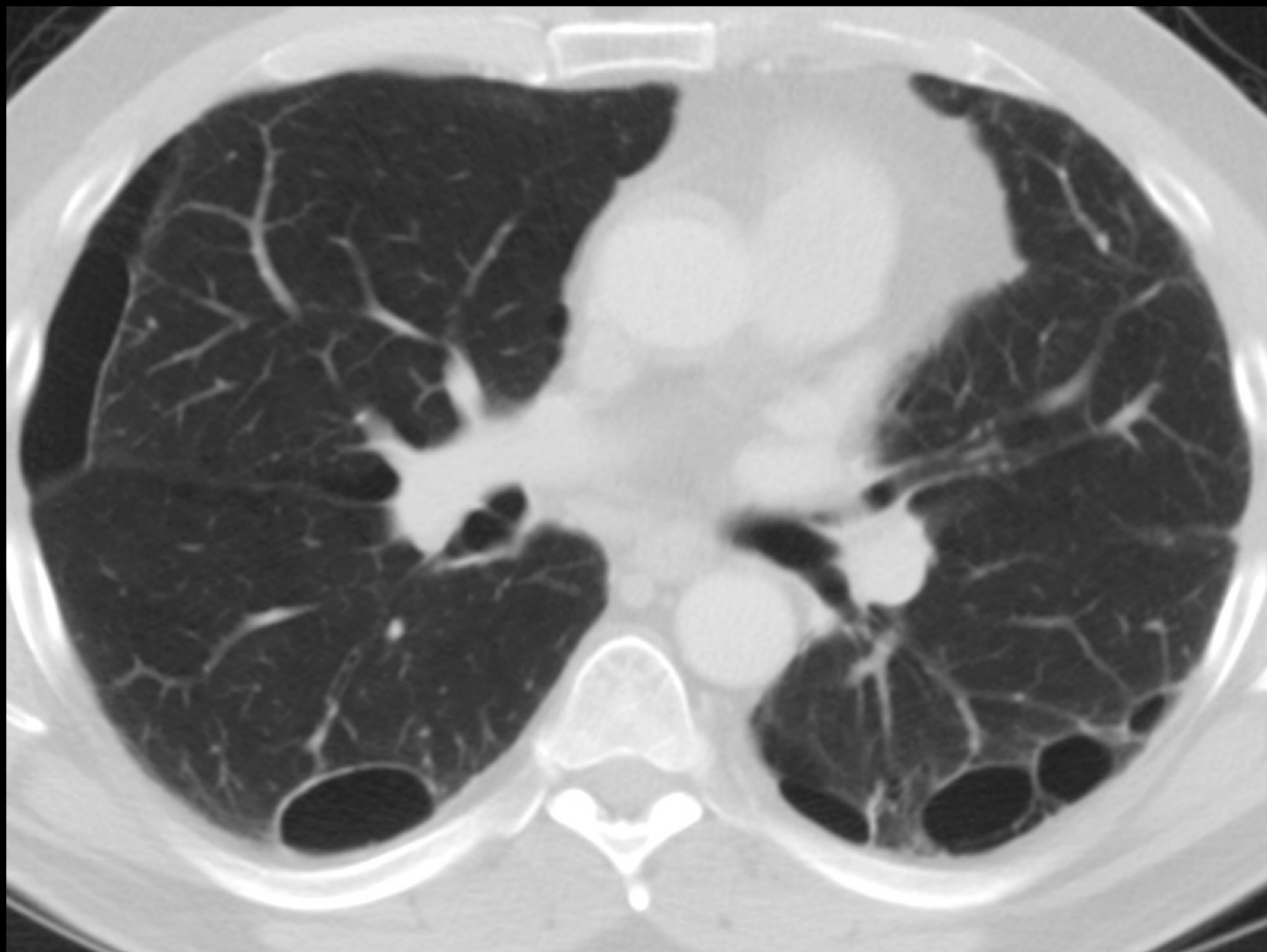













# Mycetoma (predisposing bullous lung disease)

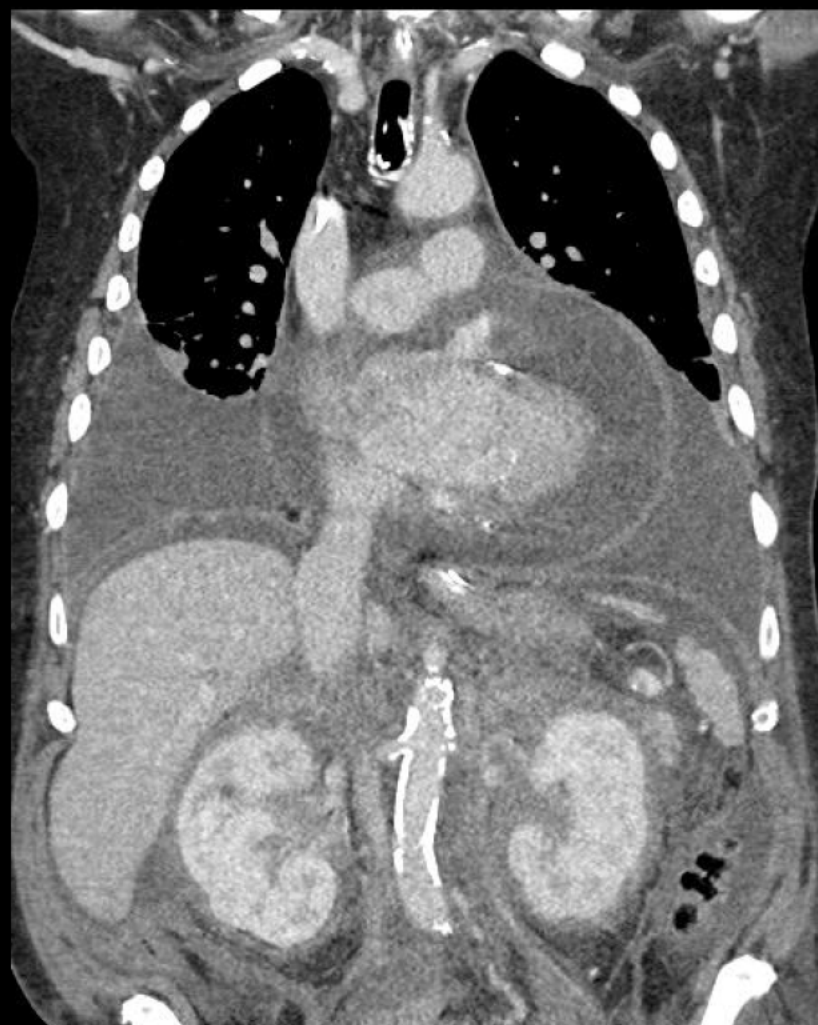
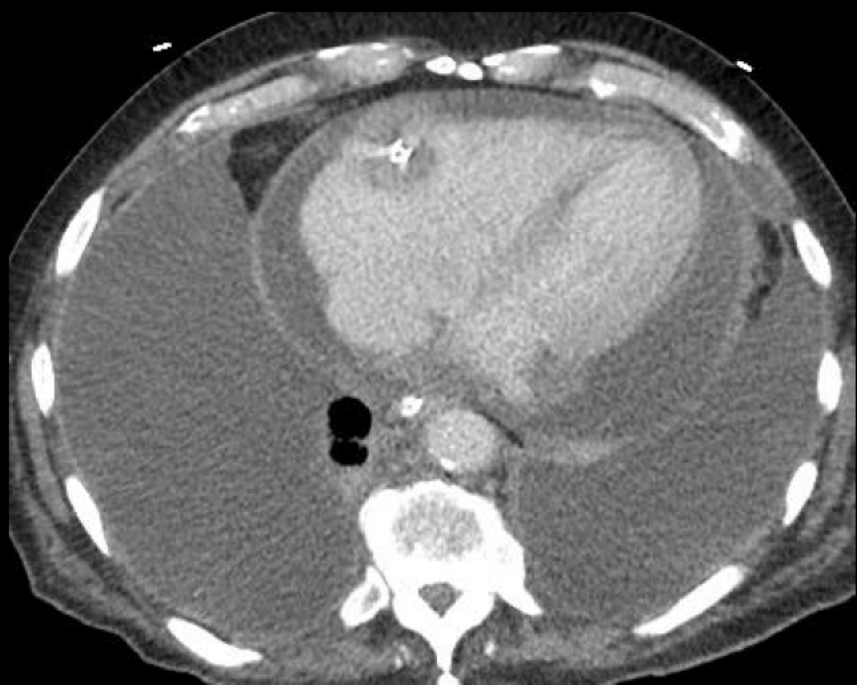Kelly Hastings, MD  
University of North Carolina  
Chapel Hill, NC

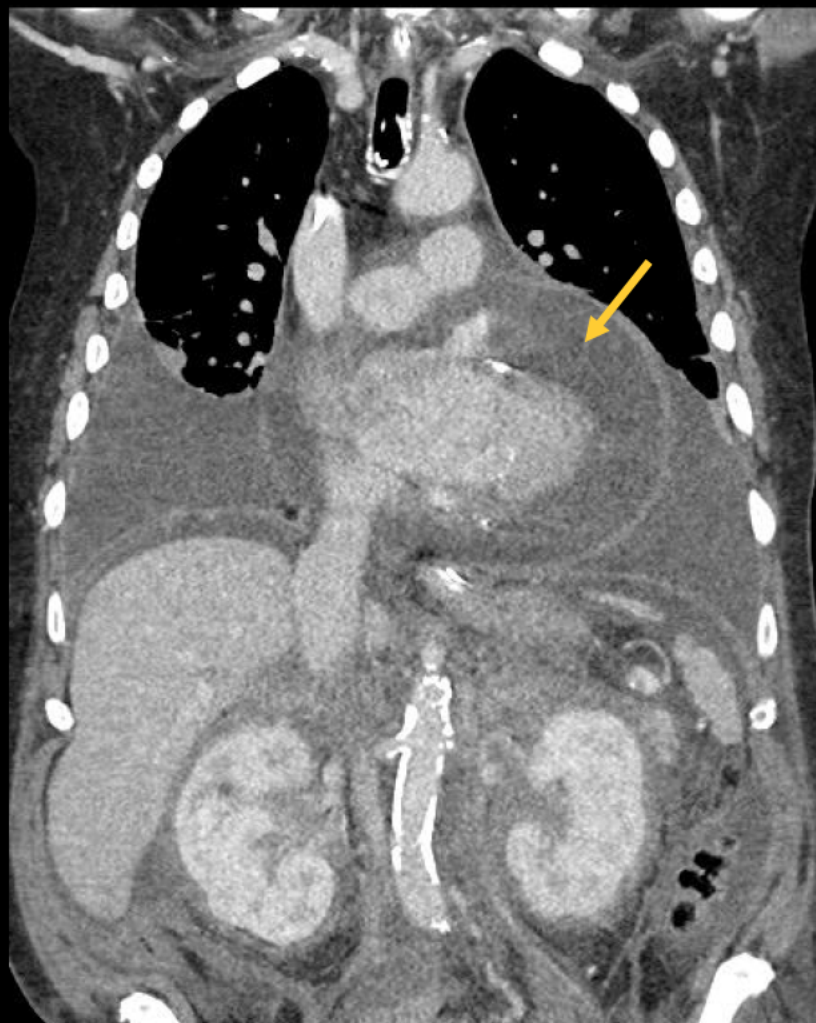
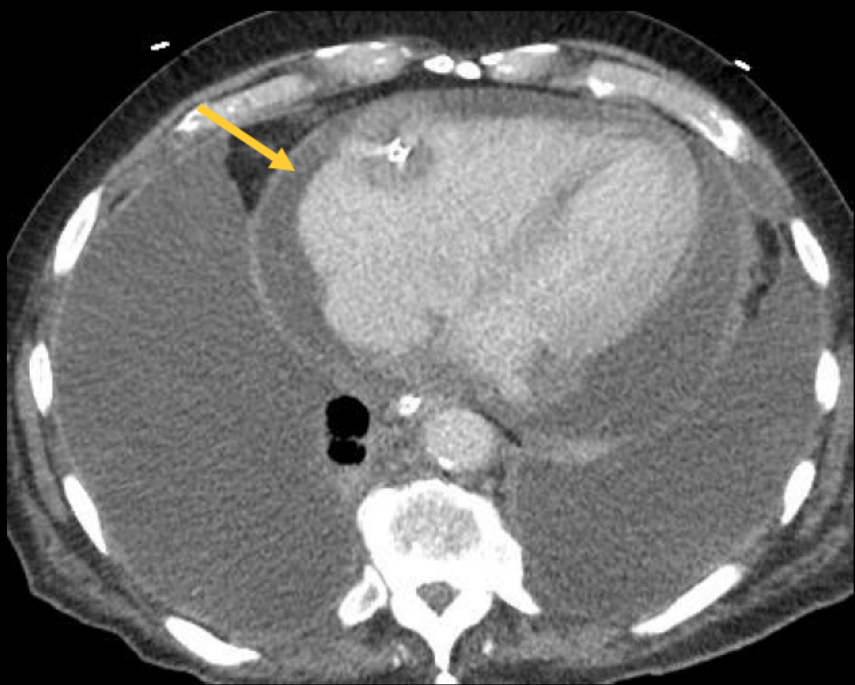




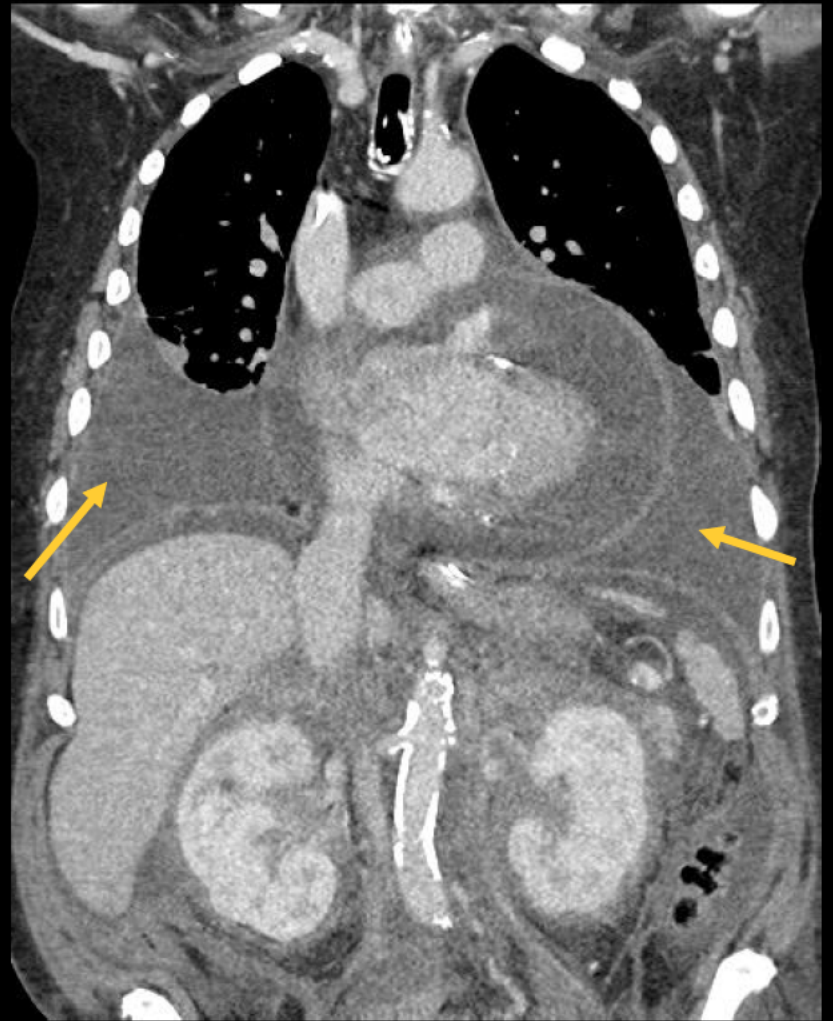
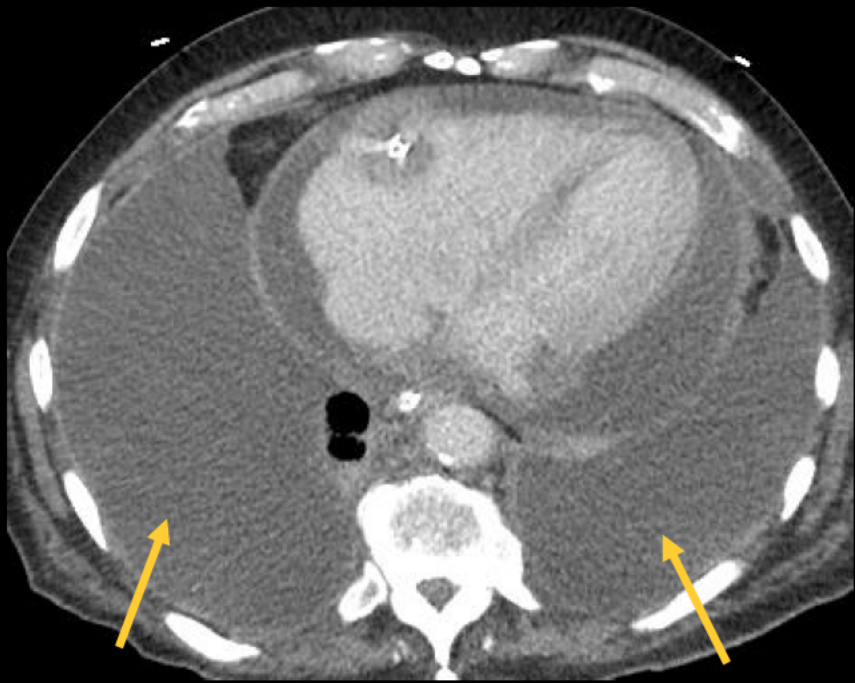
# Clinical Information

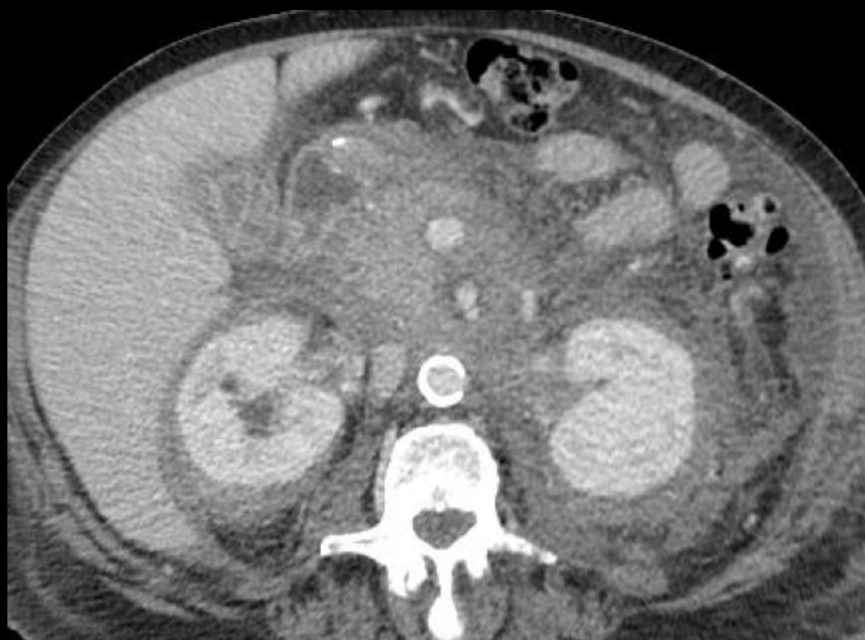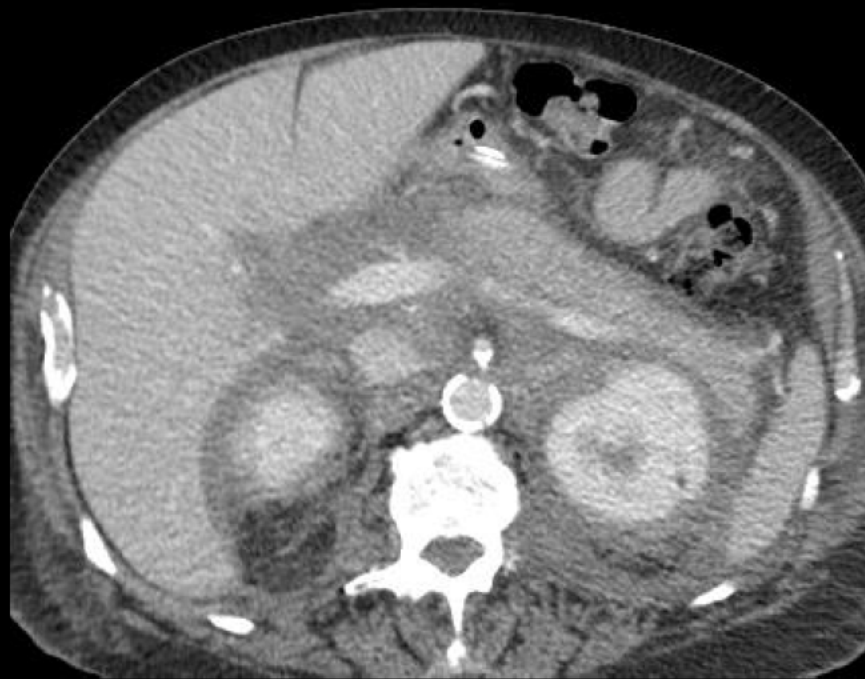**67 year old male with dyspnea, orthopnea  
and 2 liter oxygen requirement.**

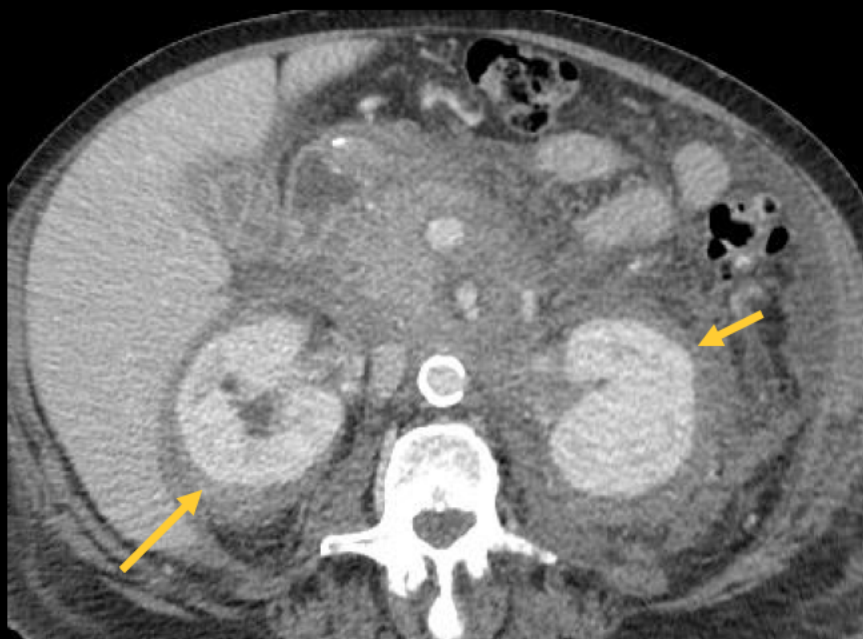
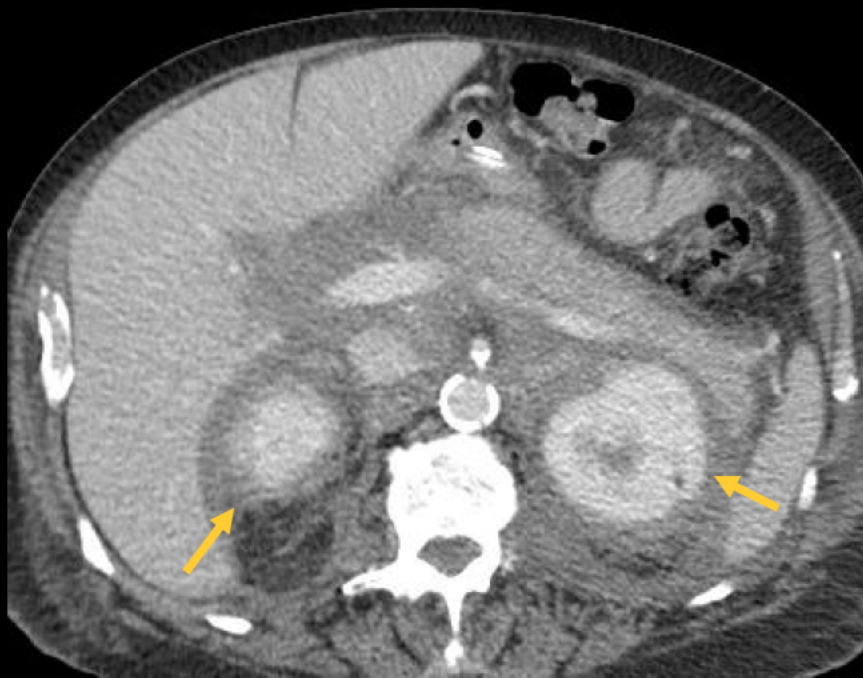






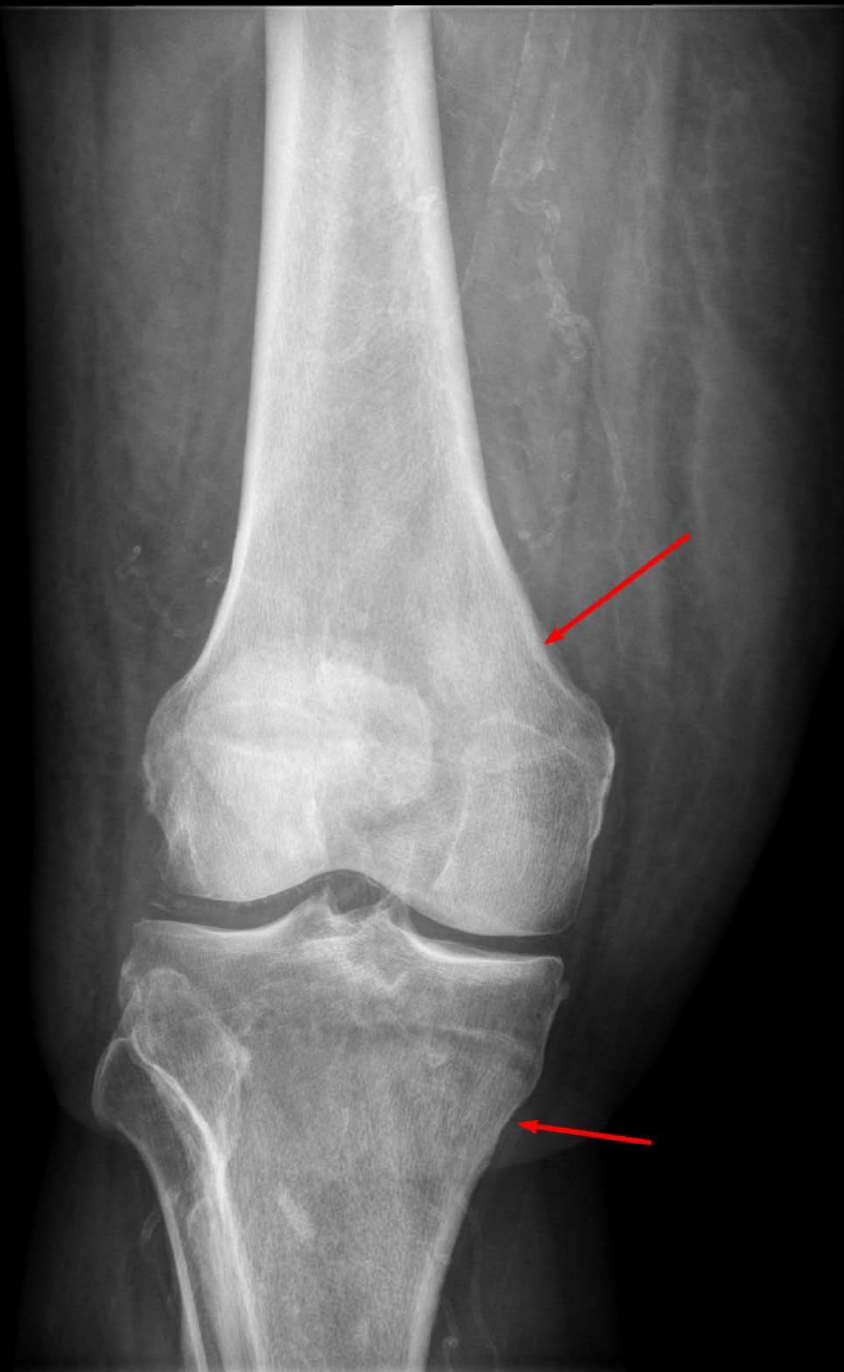







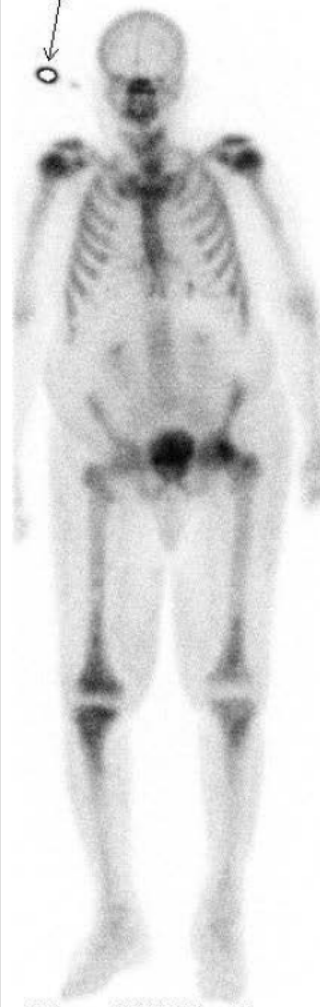R



ANTERIOR

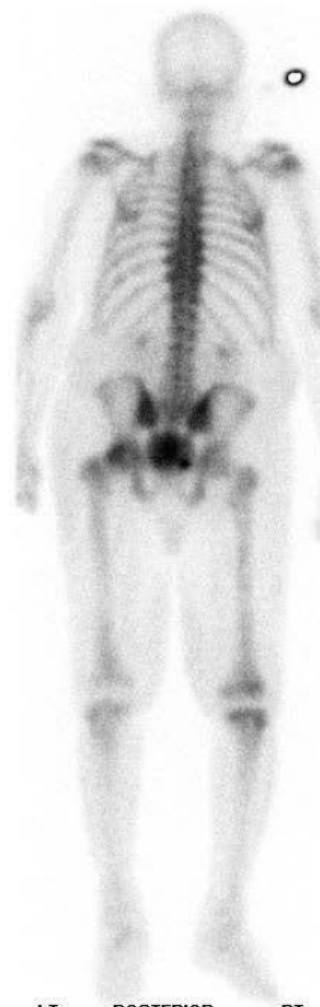27.4 MCi TC-MDP IV  
TECH DAA

INJ SITE



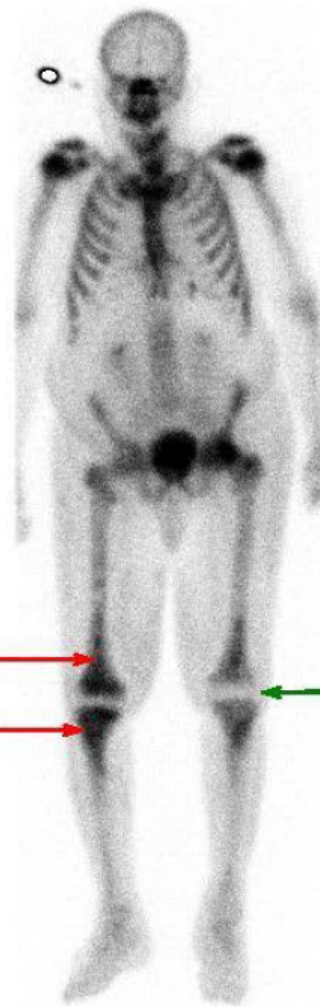RT ANTERIOR LT

POSTERIOR

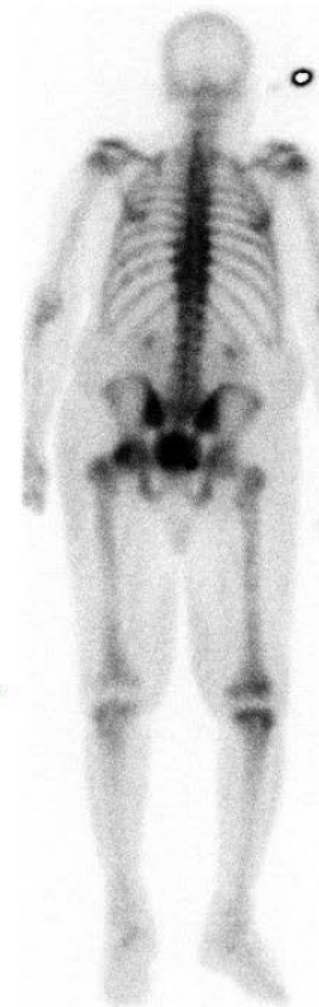

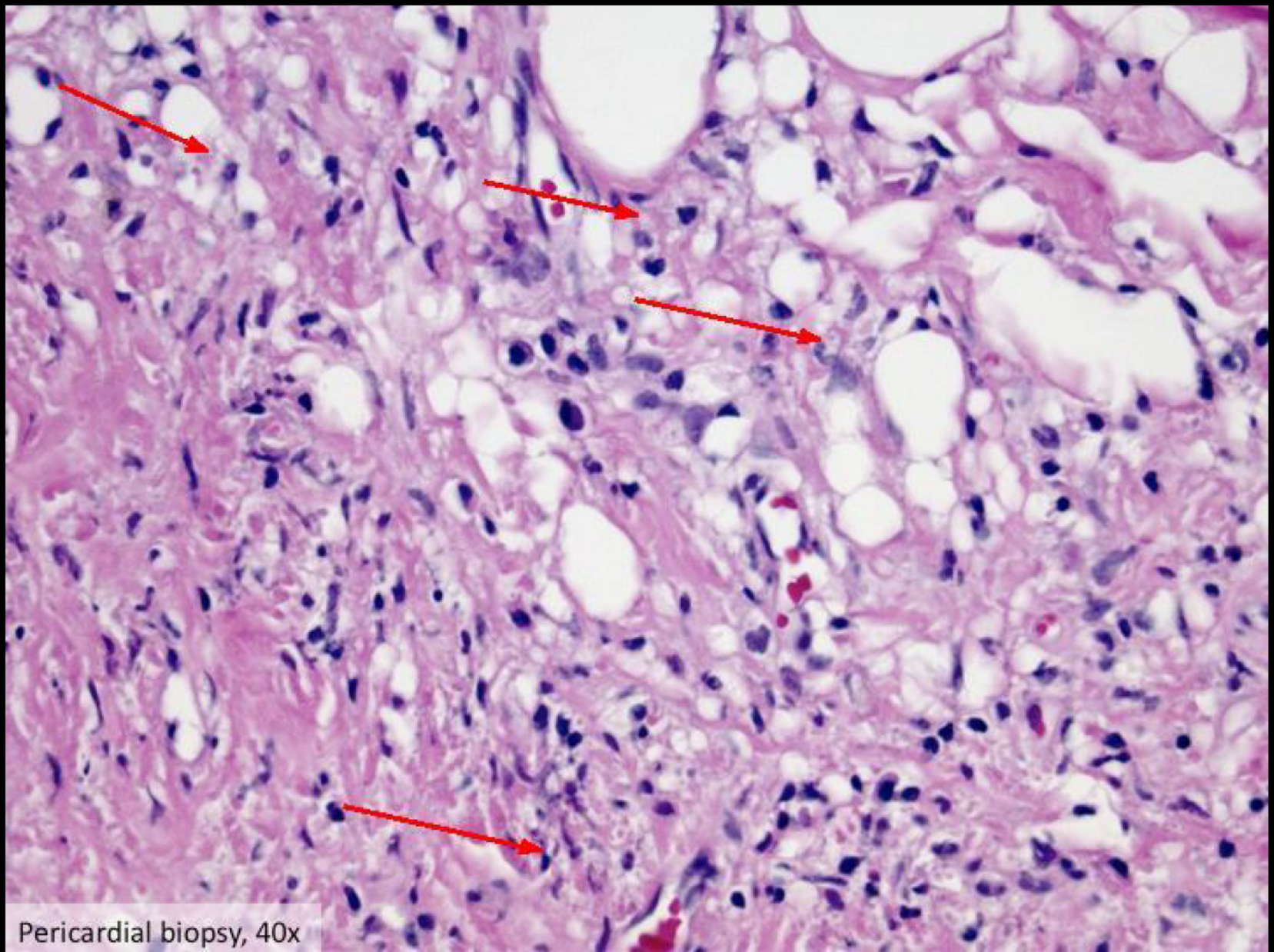
LT POSTERIOR RT

ANTERIOR



POSTERIOR





Pericardial biopsy, 40x



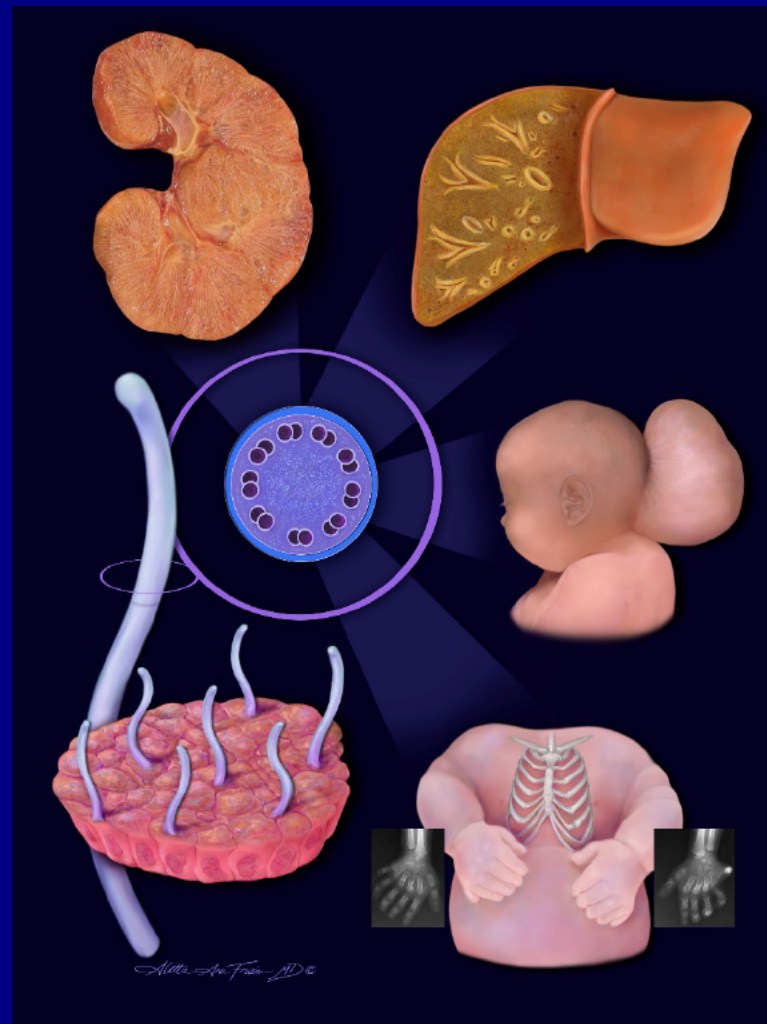
# Erdheim-Chester Disease

- **Non-Langerhans cell, non-familial multi systemic lipogranulomatous disorder**
- **Infiltration by lipid laden macrophages, giant cells and fibrosis**
- **Systemic manifestations:**
  - **Bone**
  - **Lung**
  - **Kidney**
  - **Retroperitoneal**
  - **Skin**
  - **Vascular**

# **Erdheim-Chester Disease**

**Philip Dougherty, MD**  
**University of Washington Medical Center**  
**Seattle, WA**

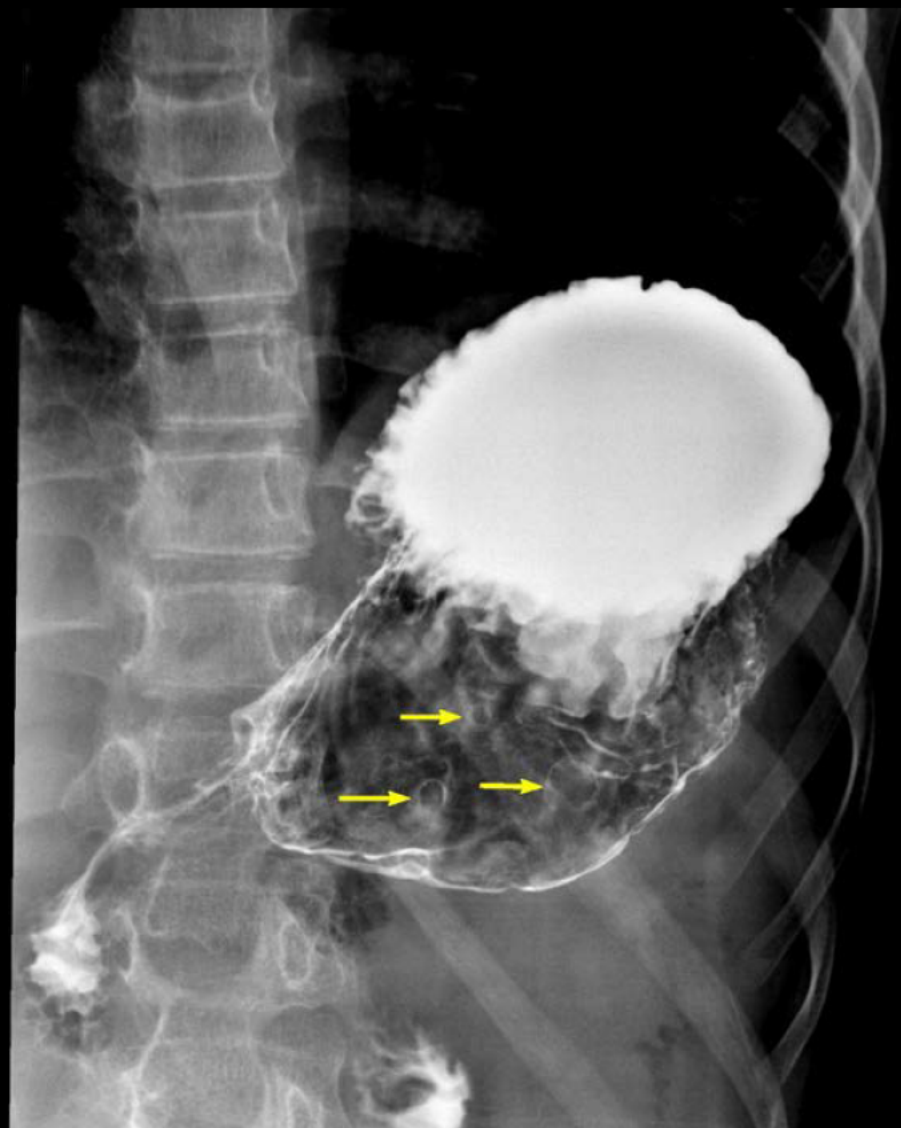
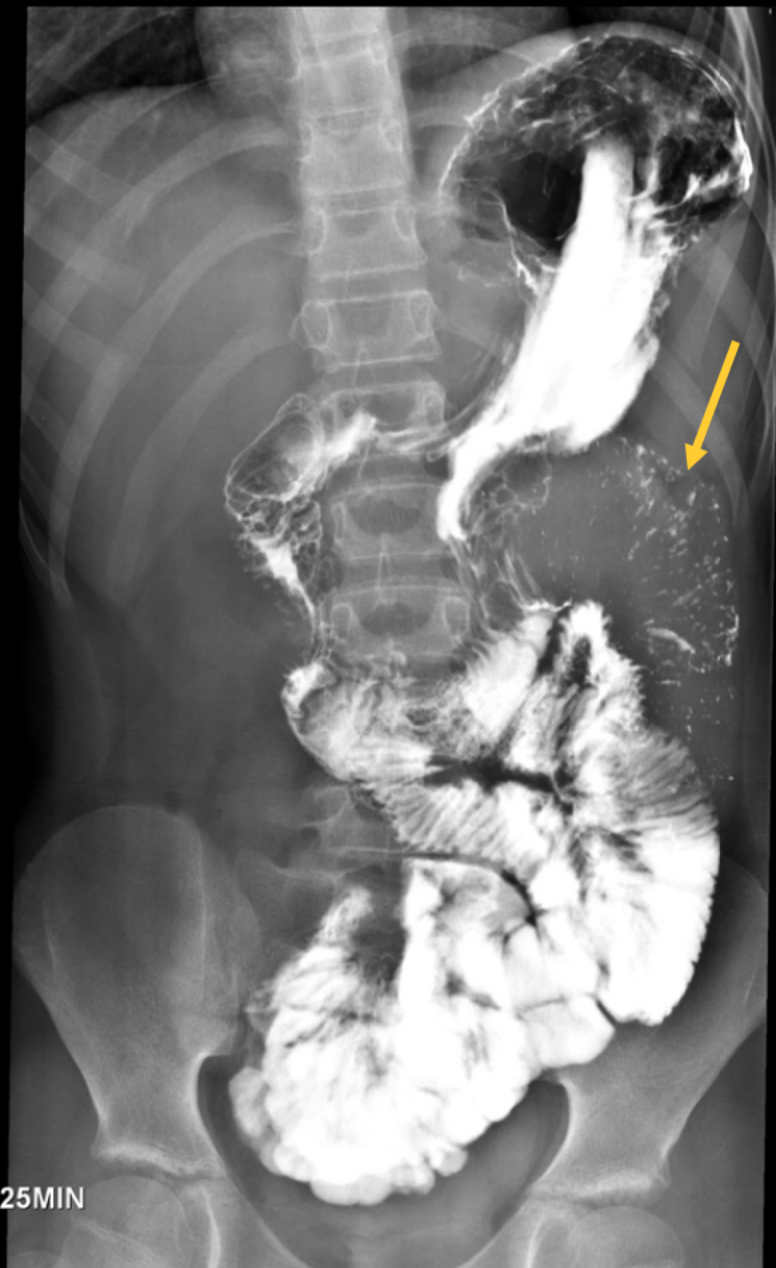# Pediatric Best Case

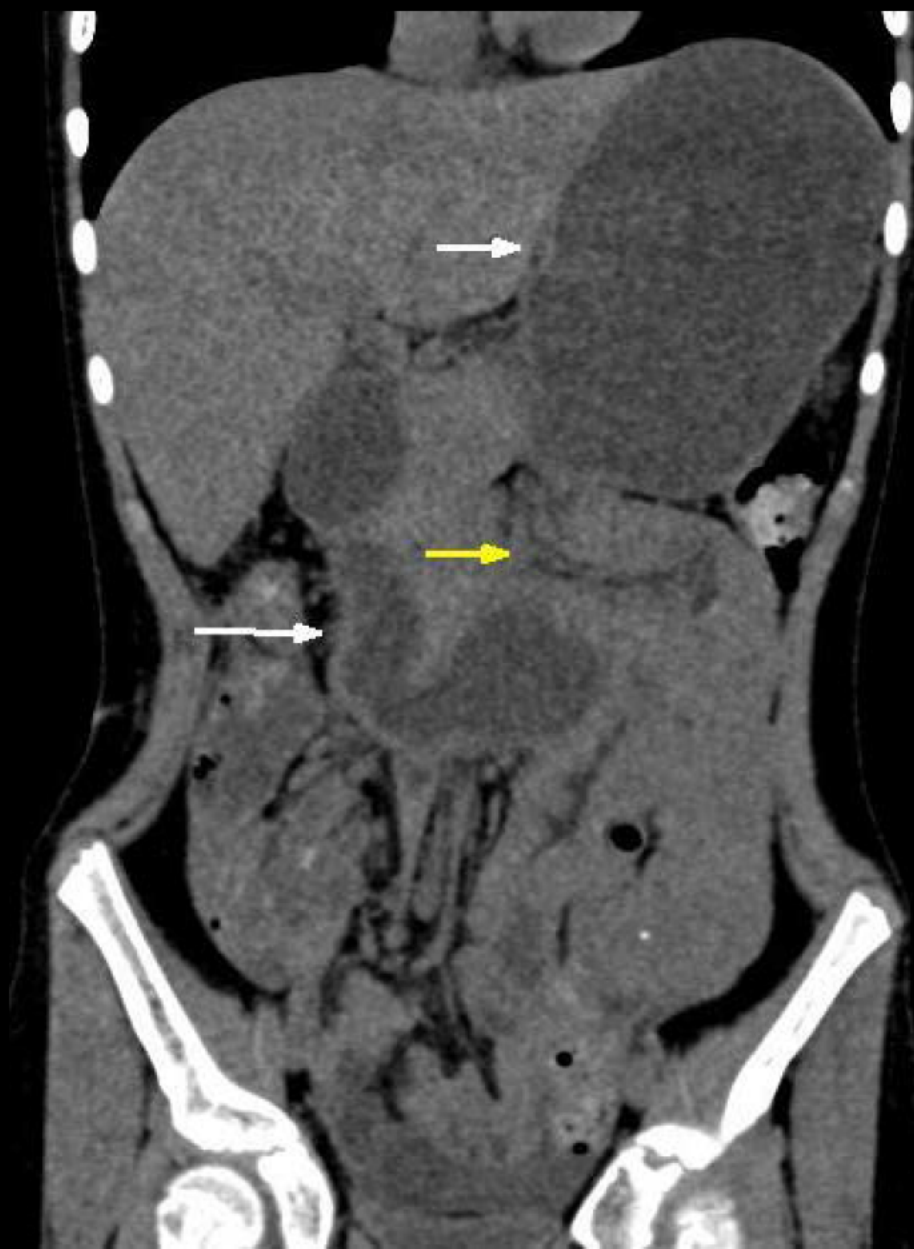
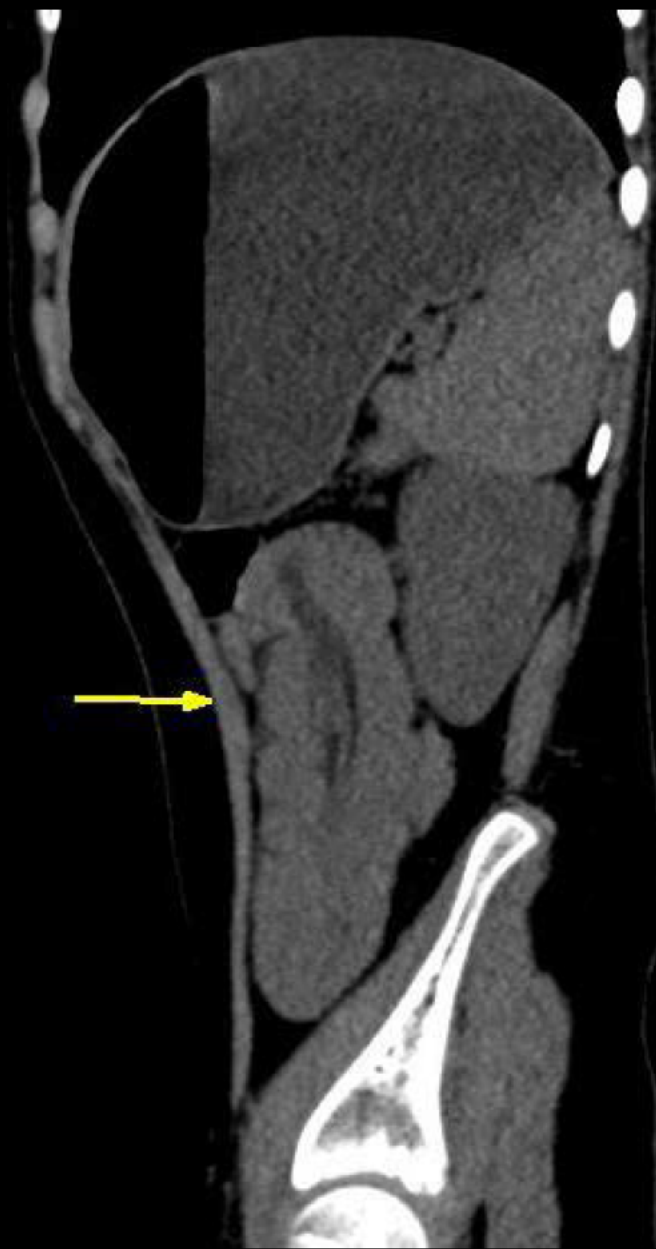


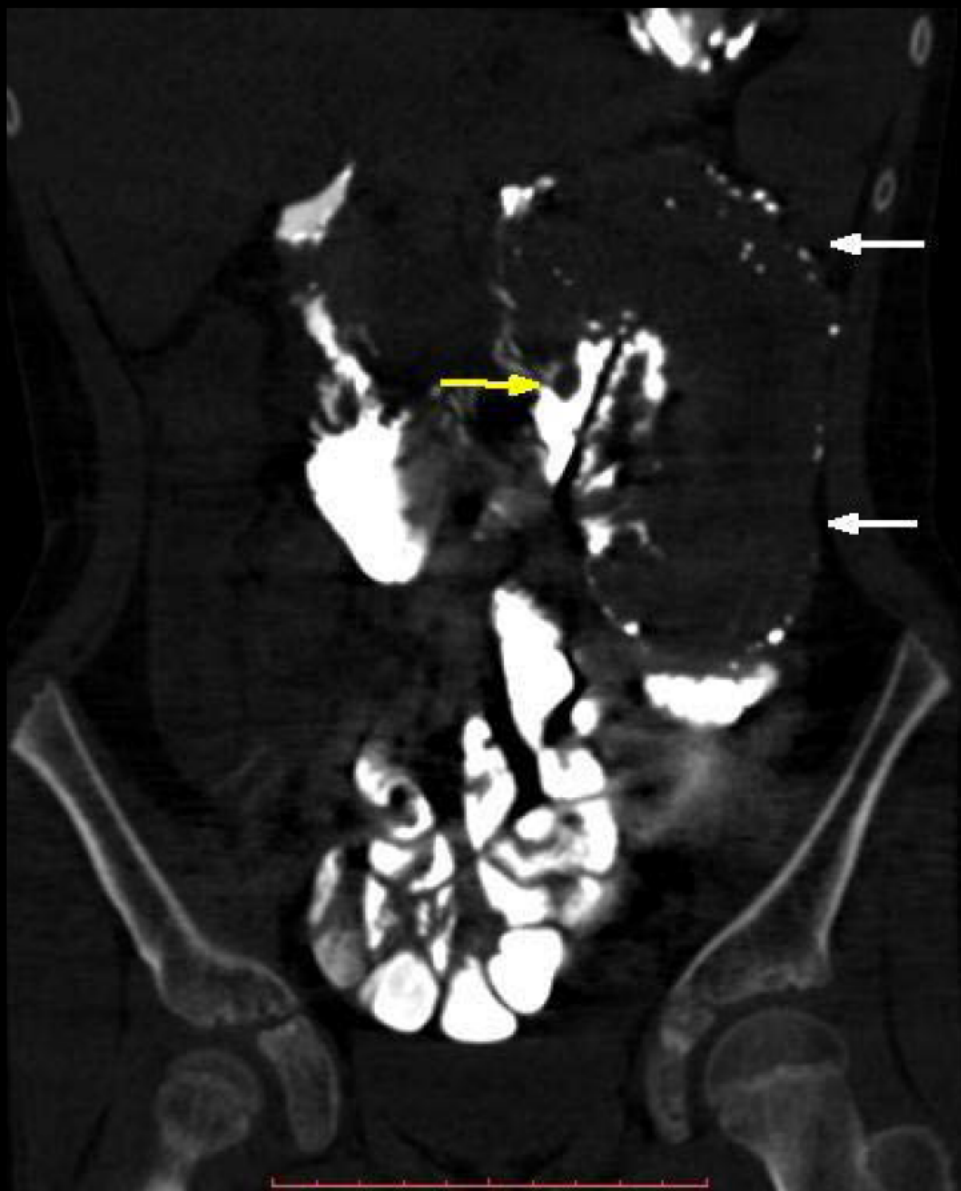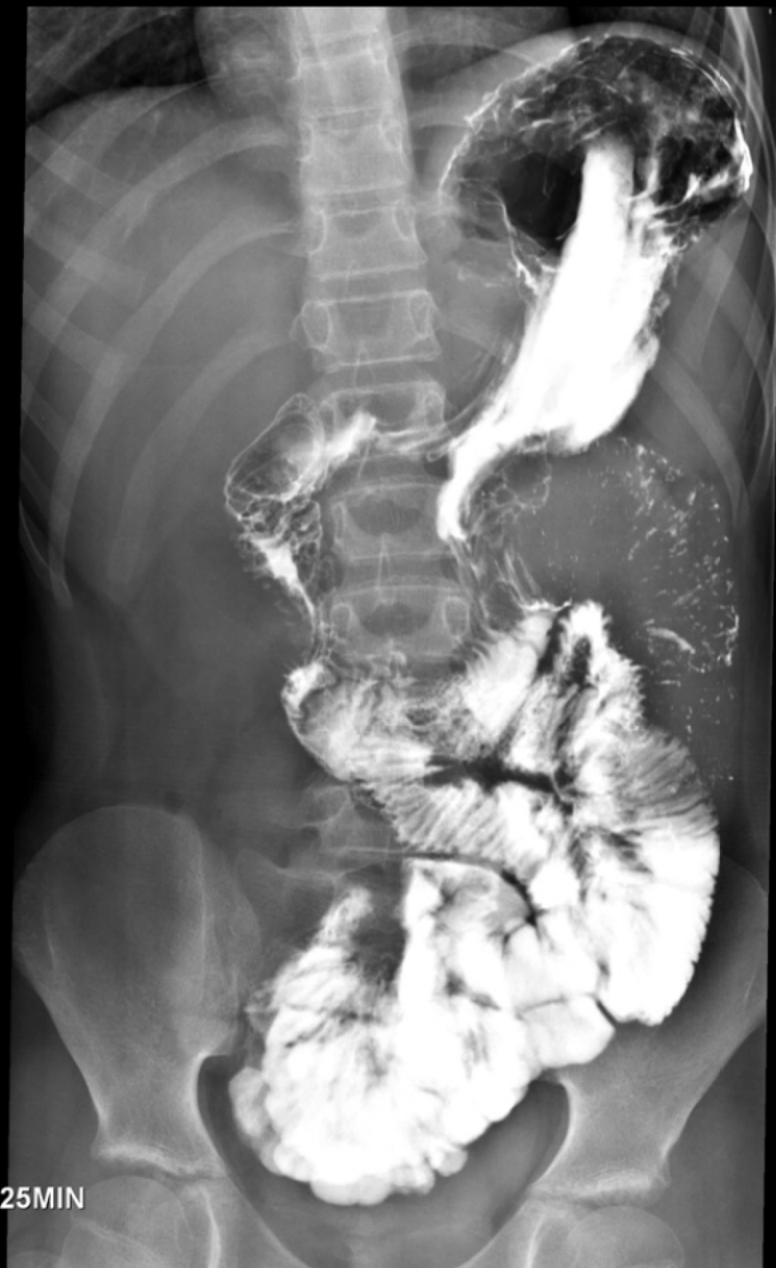## Clinical Information

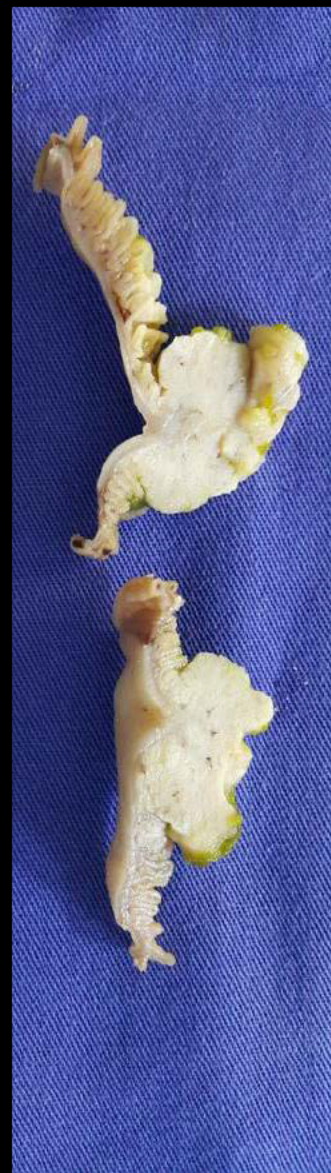9-year-old patient presented to the Emergency Room with recurrent episodes of upper abdominal pain, nausea and vomiting.

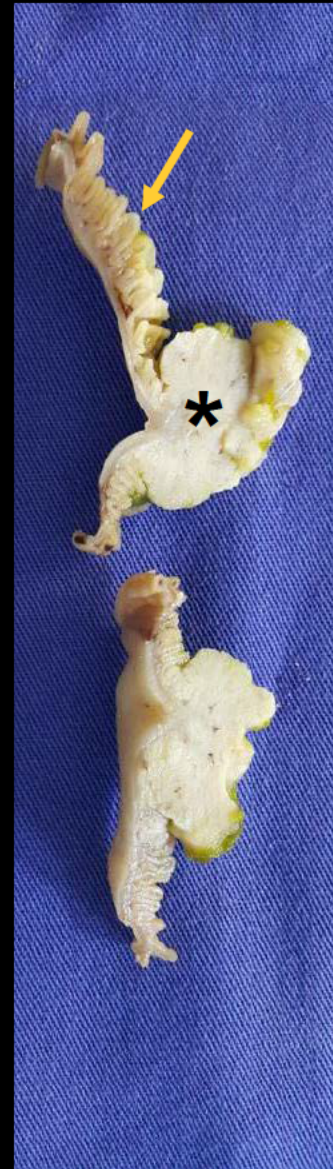
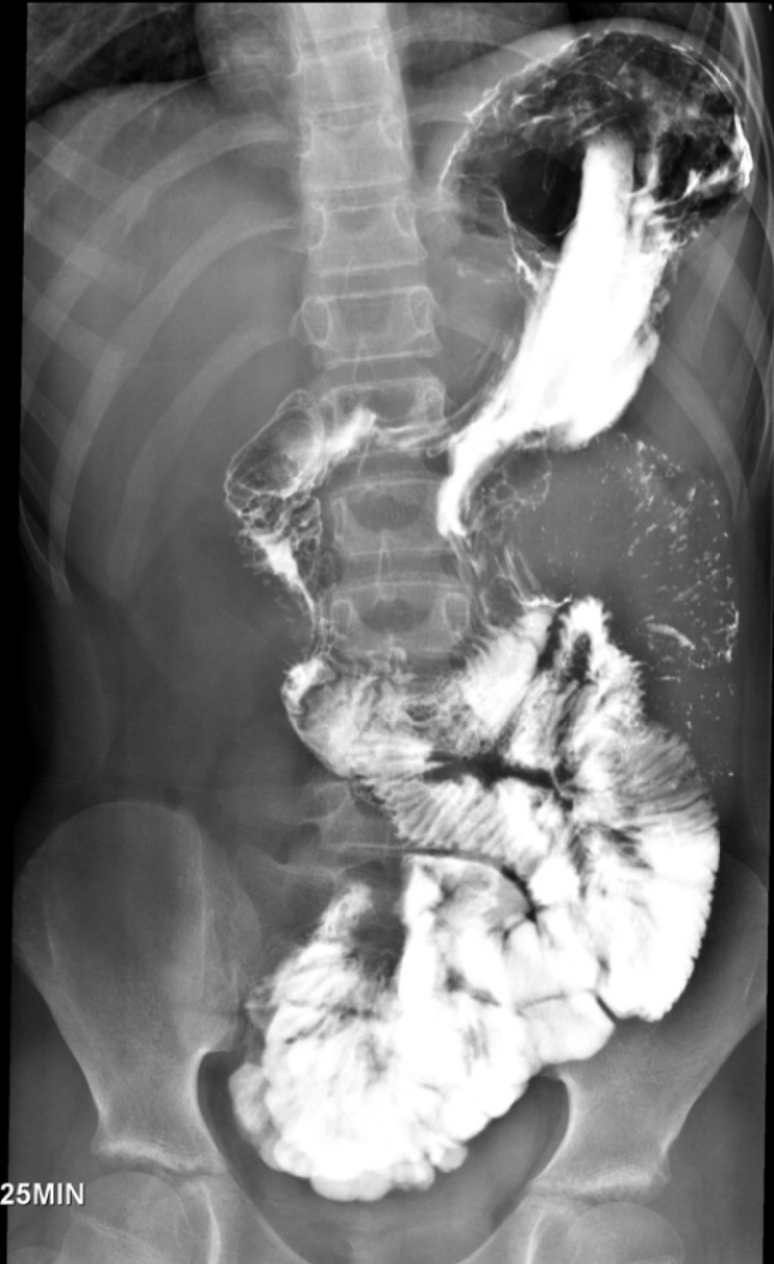




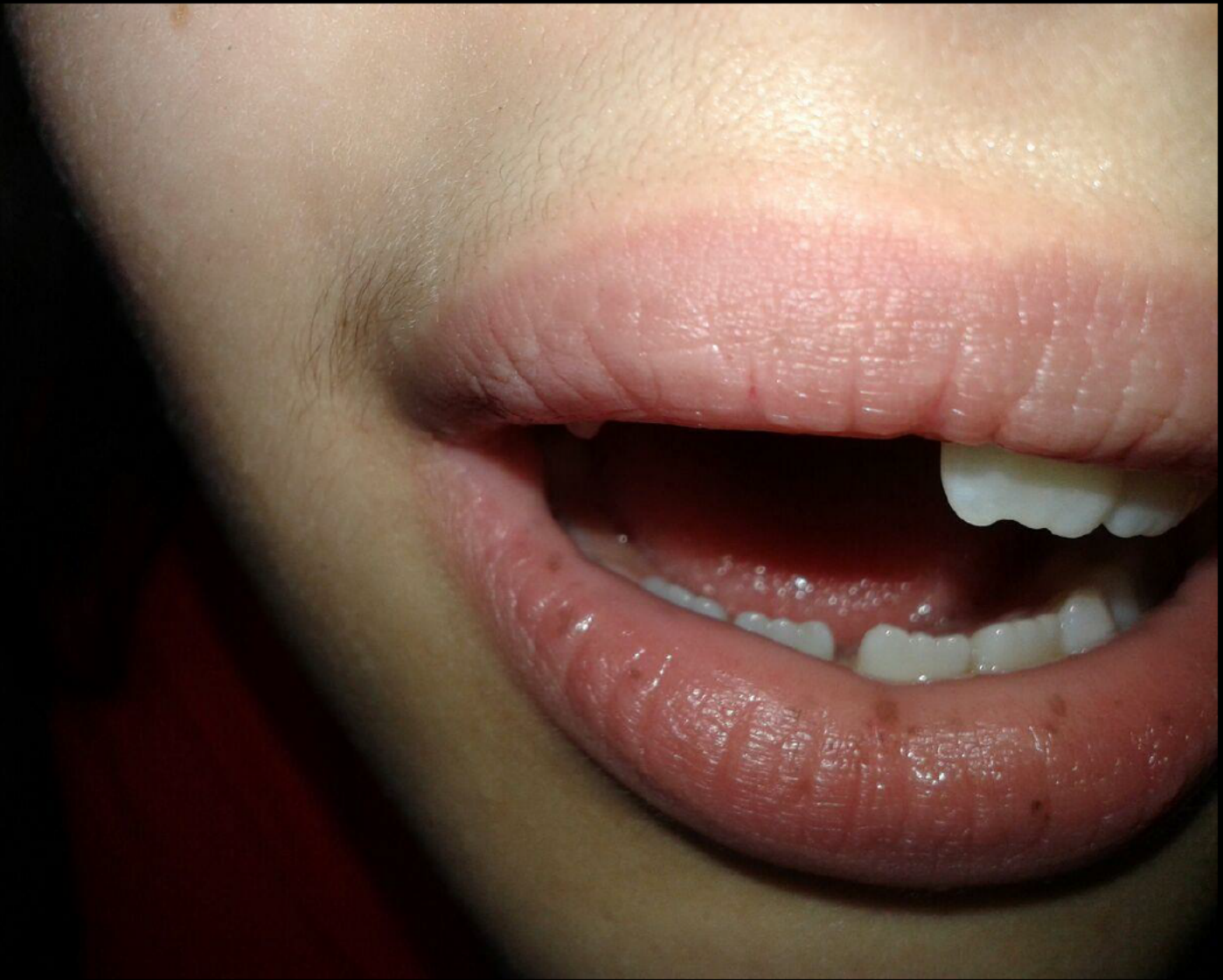









## Peutz-Jegher Syndrome/Intussusception

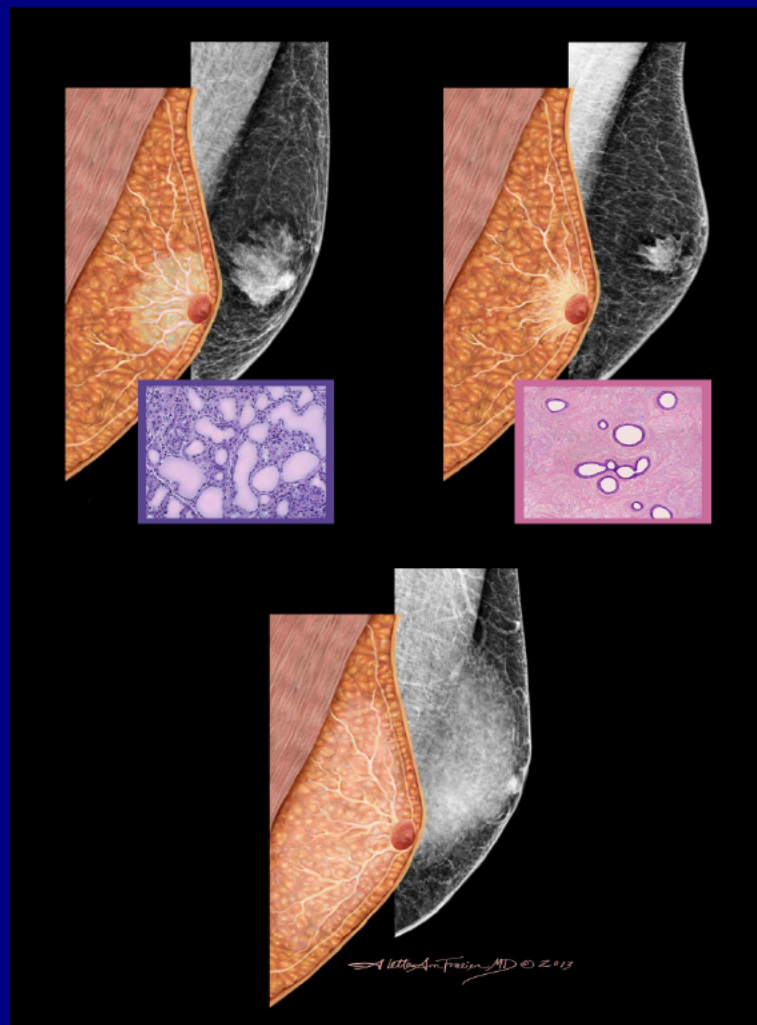
- Autosomal dominant
- Multiple hamartomatous polyps
  - Most common in small intestine
- Mucocutaneous melanin pigmentation involving the mouth, fingers and toes

# Peutz-Jegher Syndrome/Intussusception

Daniel Furlanetto, MD  
Hospital São Vicente de Paulo  
Passo Fundo, Brasil



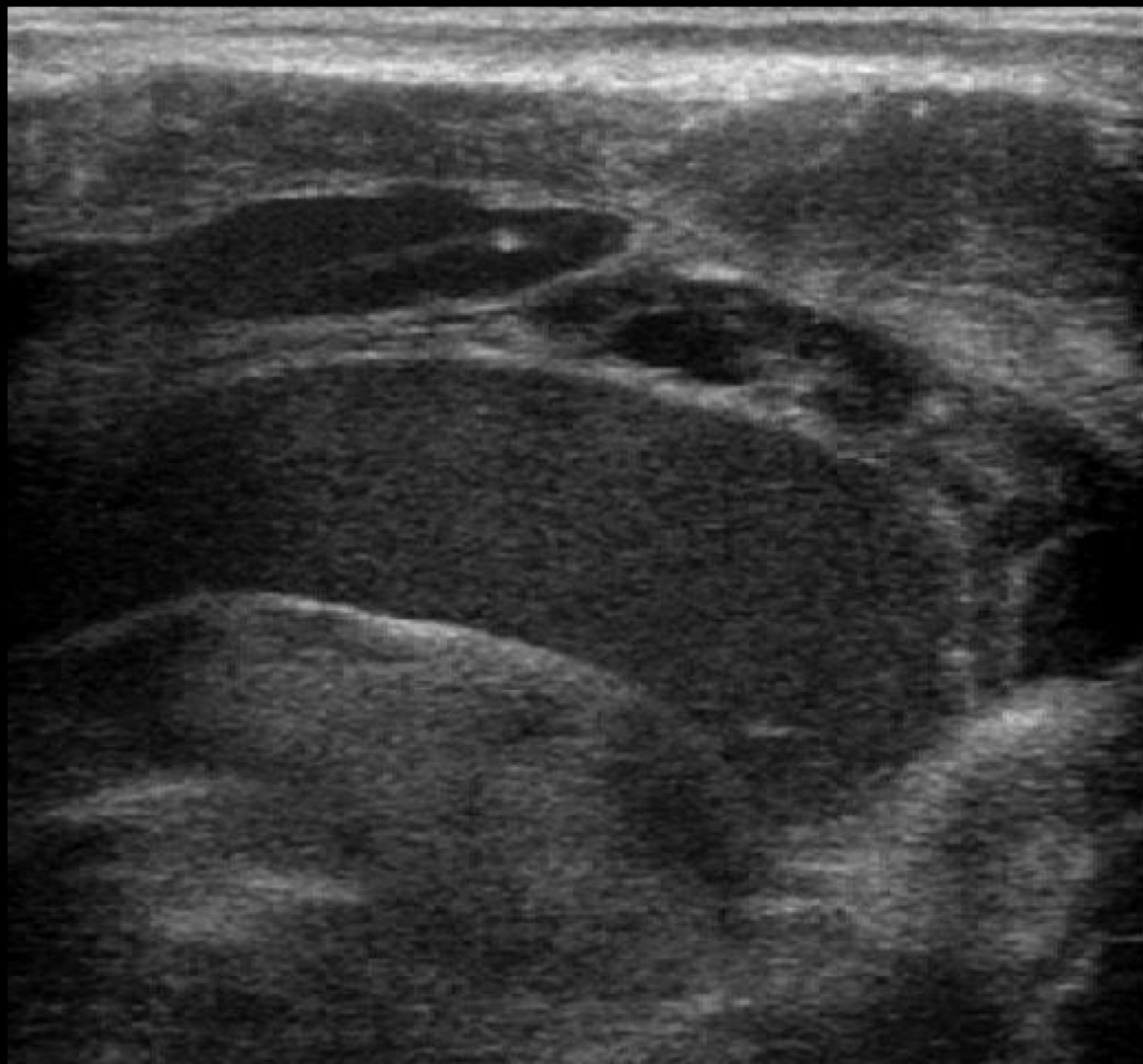
# Breast Best Case



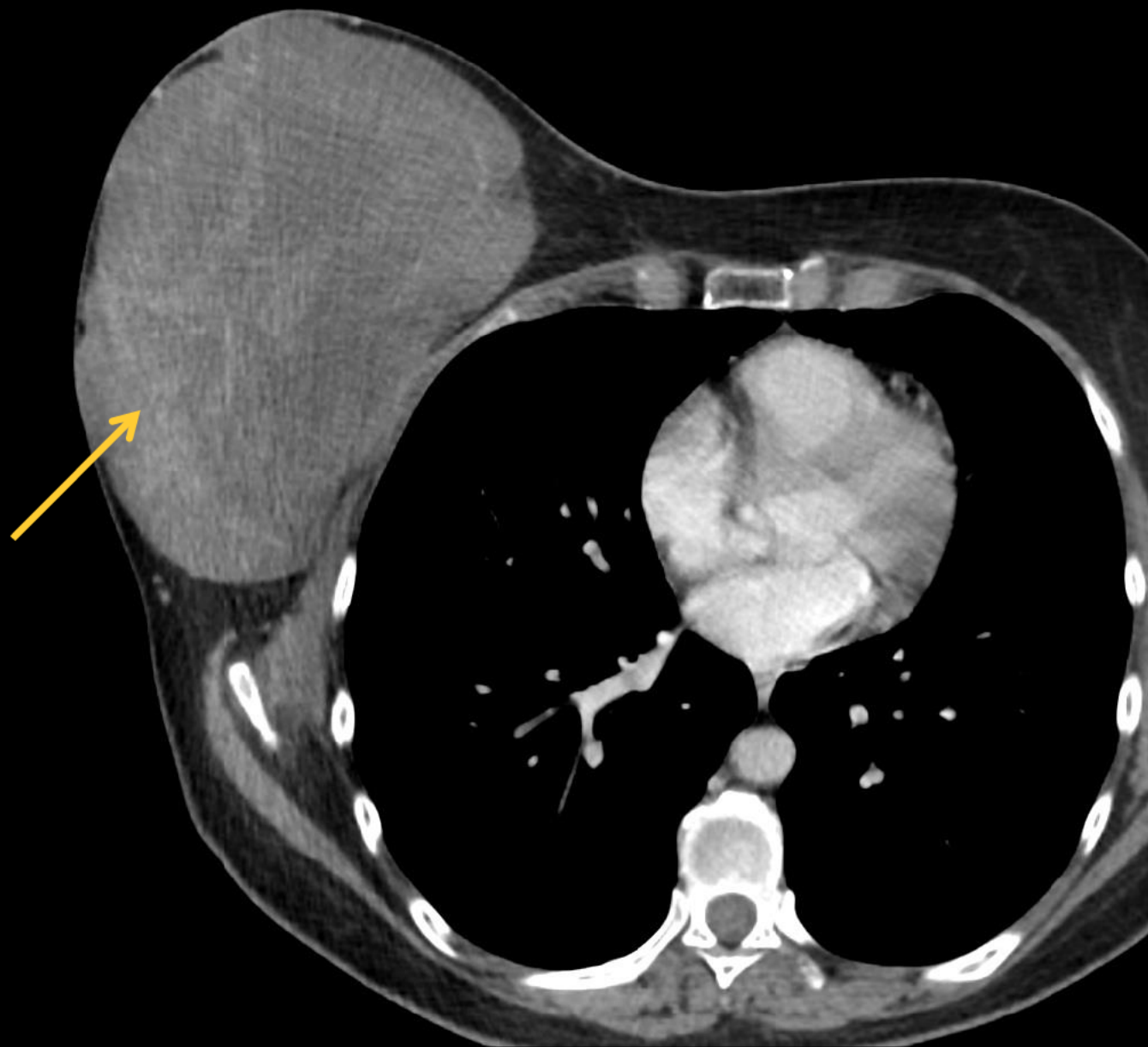
## Clinical Information

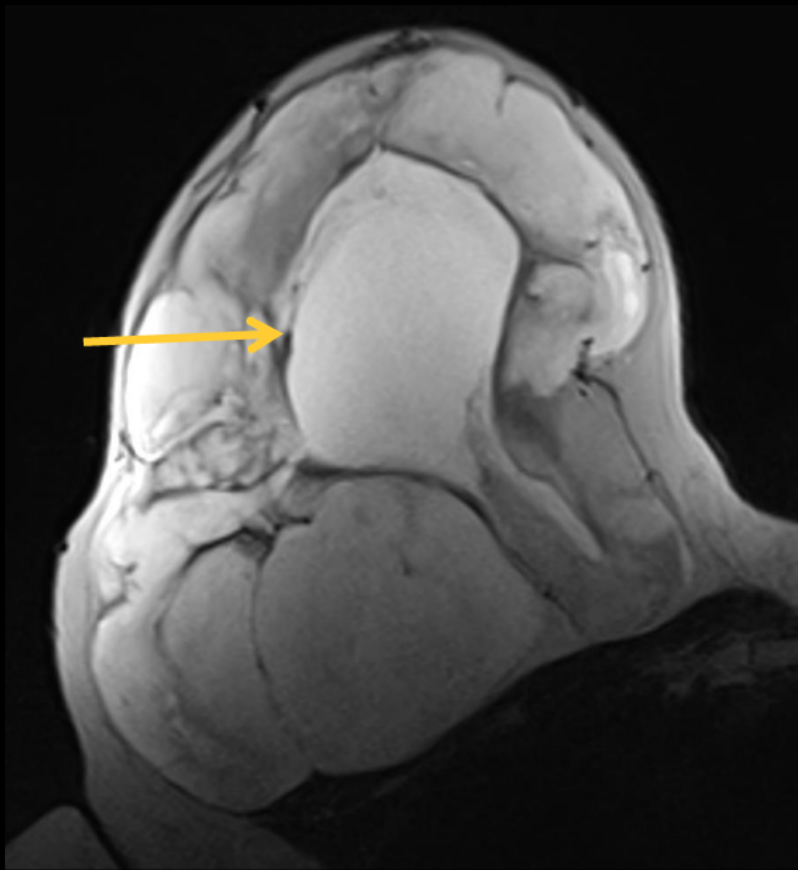**53-year-old woman with enlarging mass in  
the right breast for 3 months**

**On exam, there is a firm mass occupying  
the entire right breast**

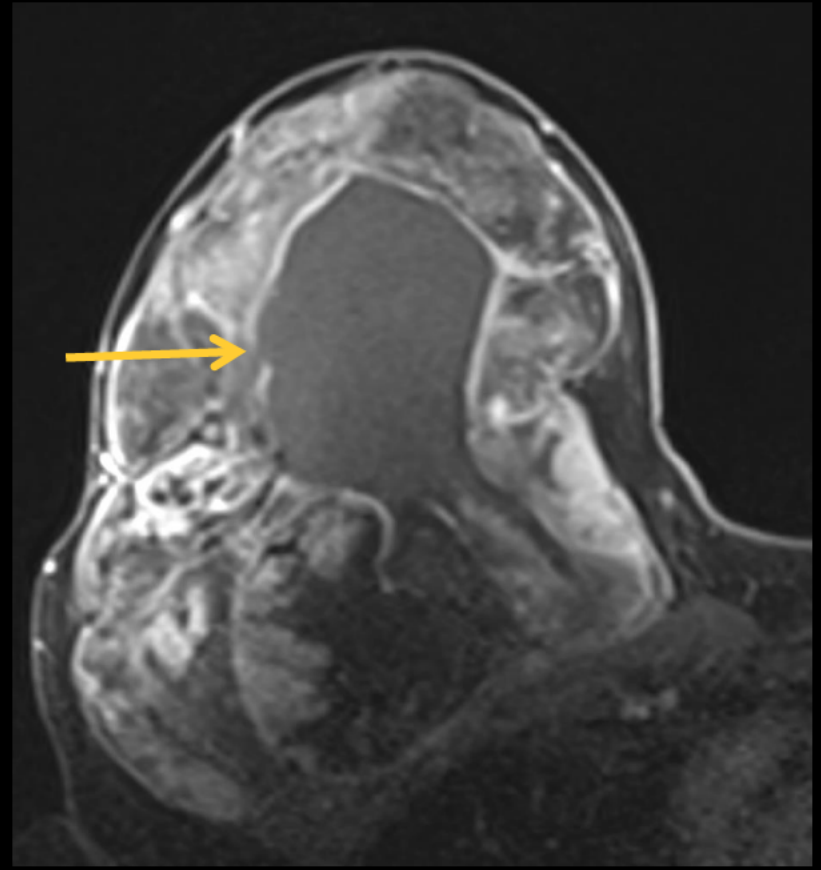




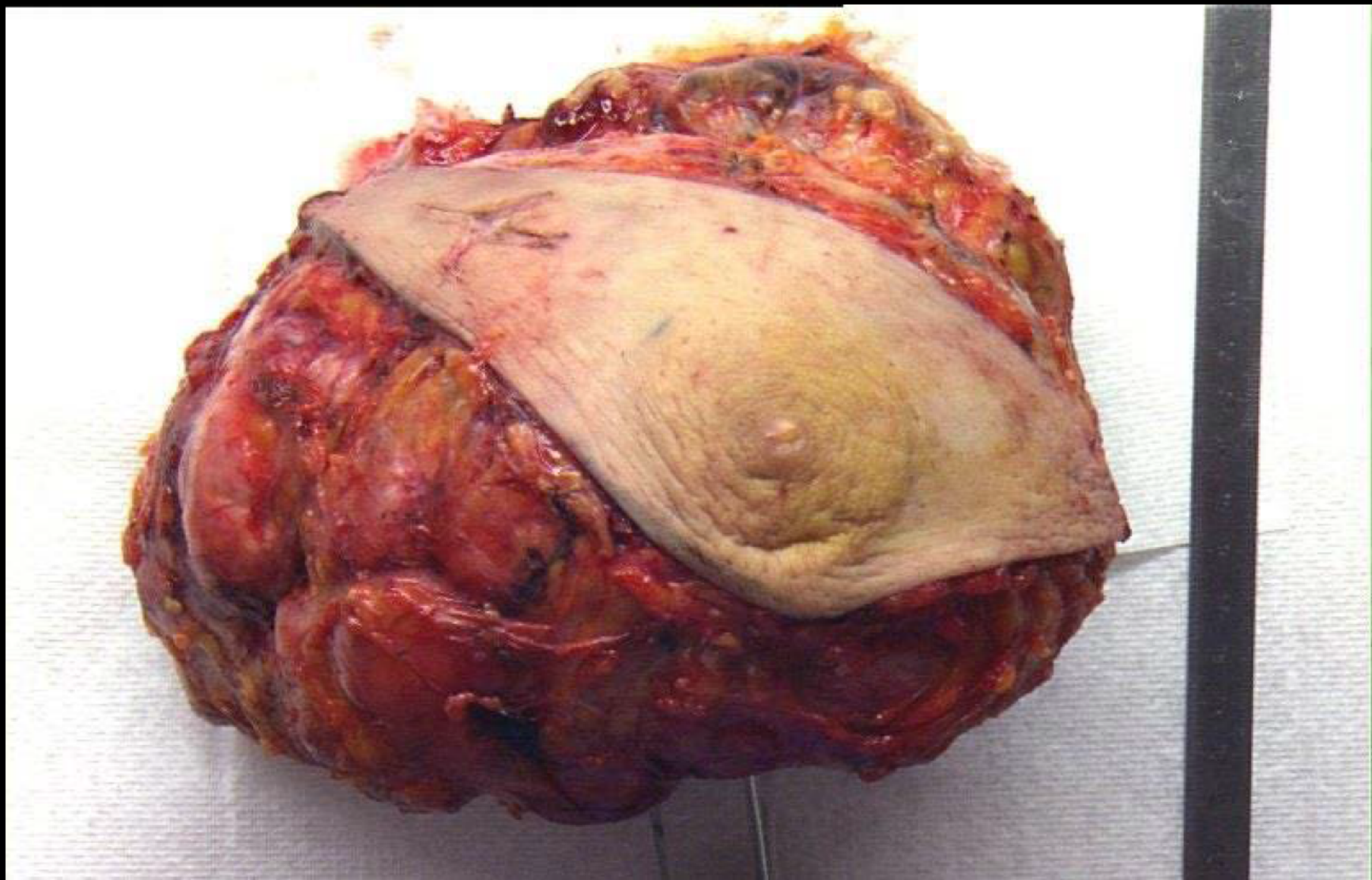




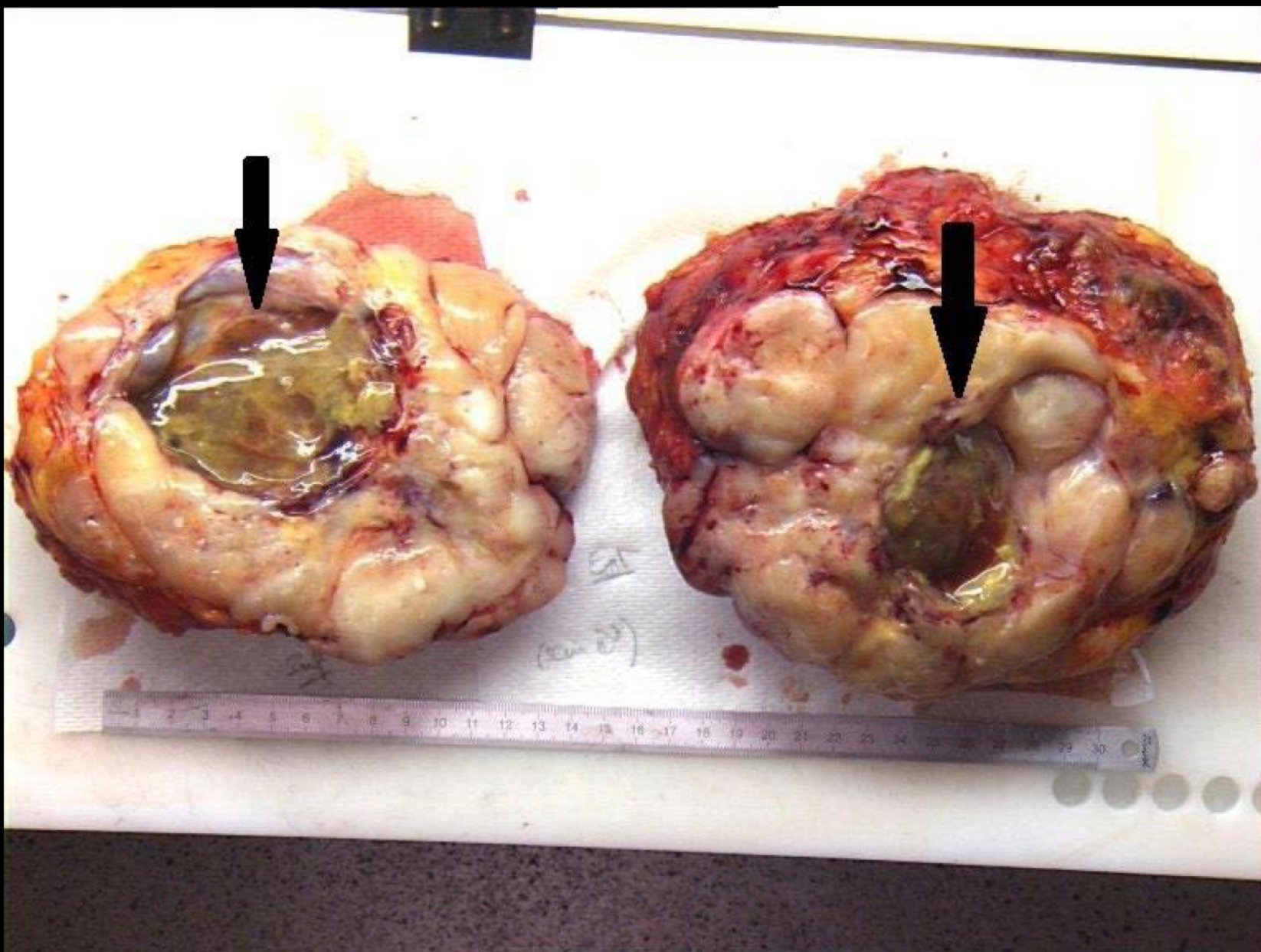
**T2**

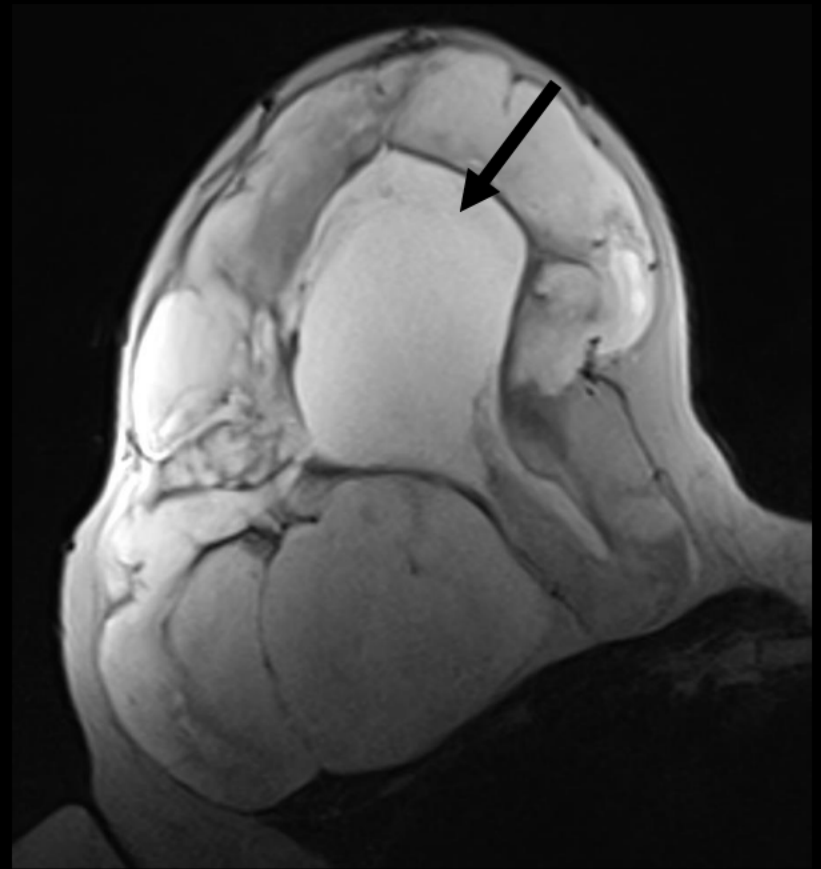
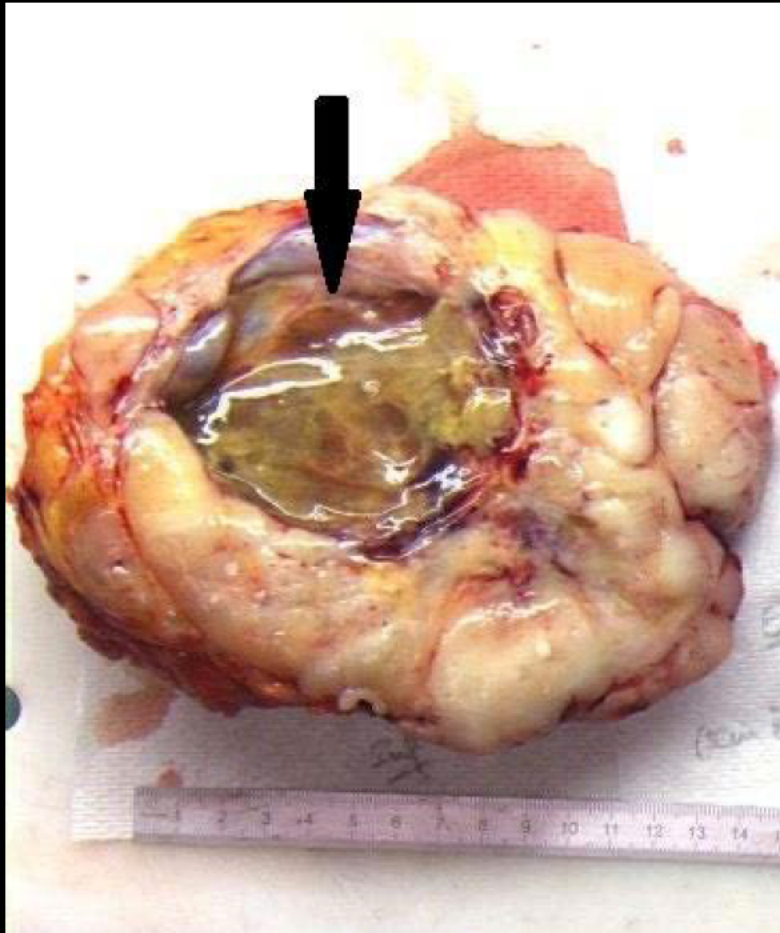


**T1 post**

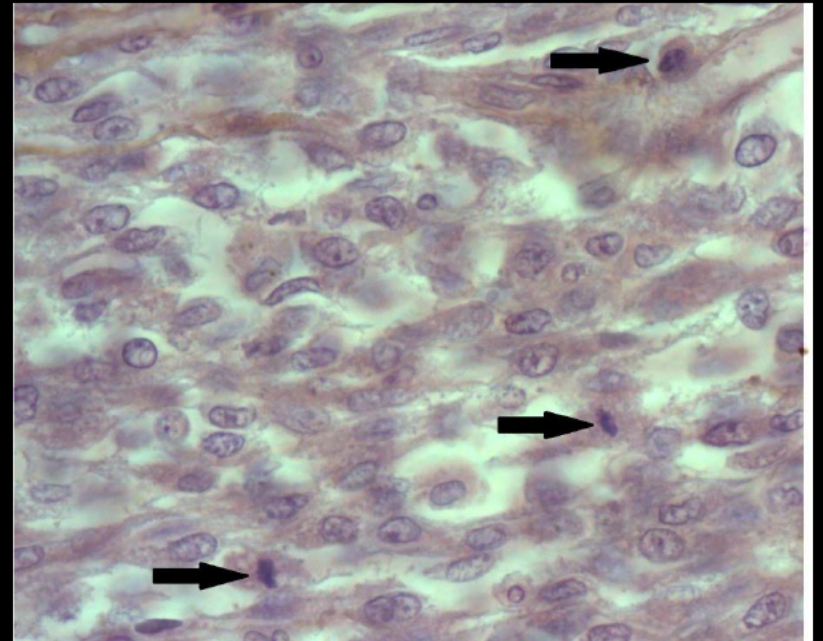
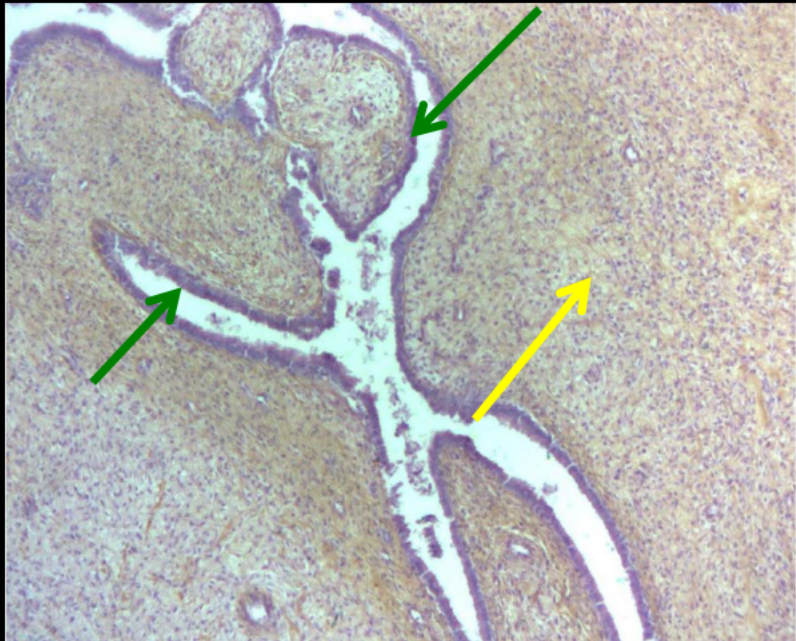












# Malignant Phyllodes Tumor

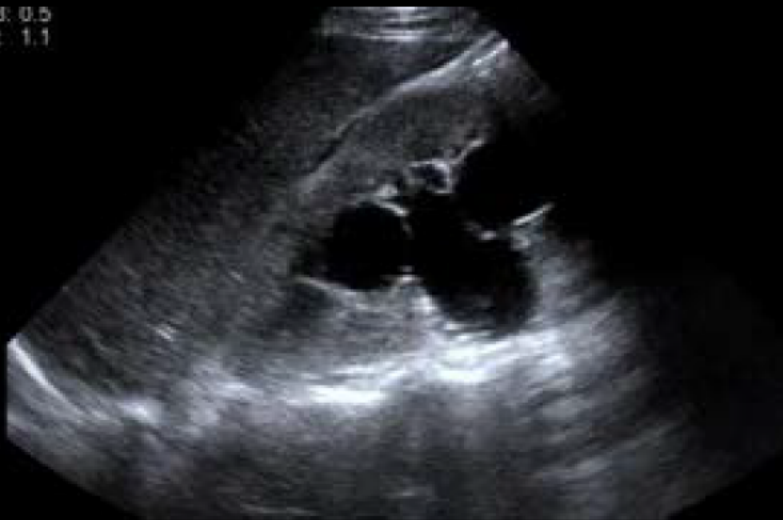Mathieu Schertz, MD  
Institut Curie  
Paris, France



## Clinical Information

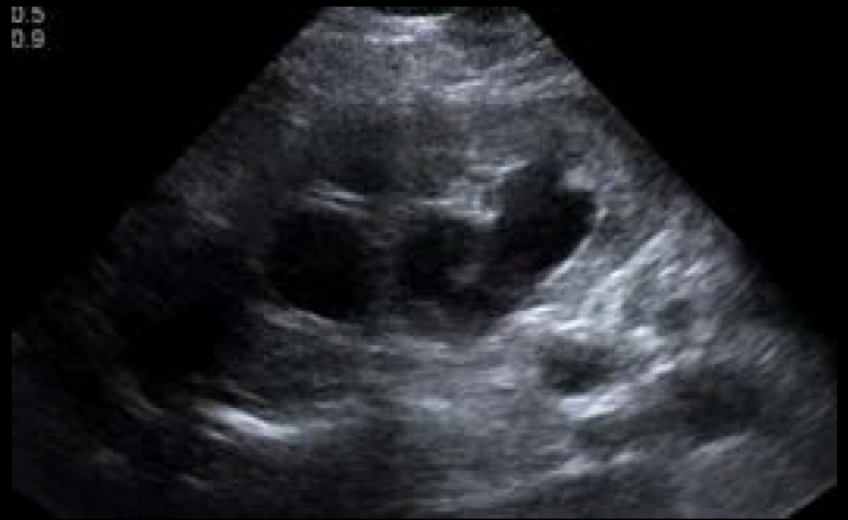39 year-old female of Somali origin presents with periumbilical and left lower quadrant abdominal pain and vaginal bleeding.

IB: 0.5  
BL: 1.1

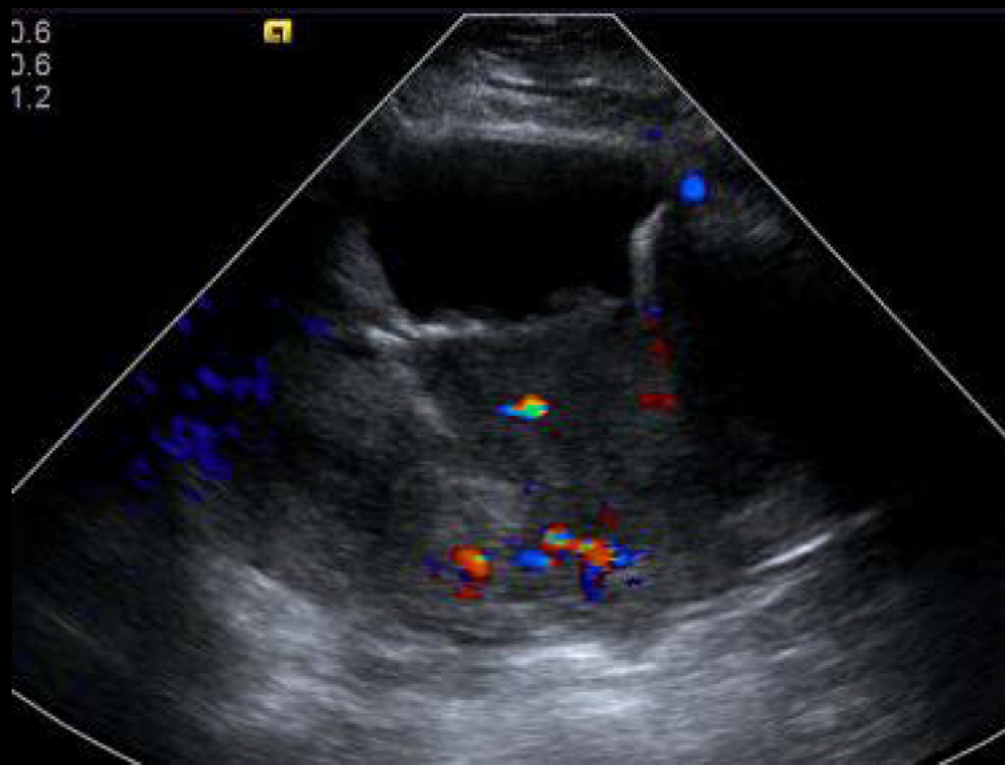
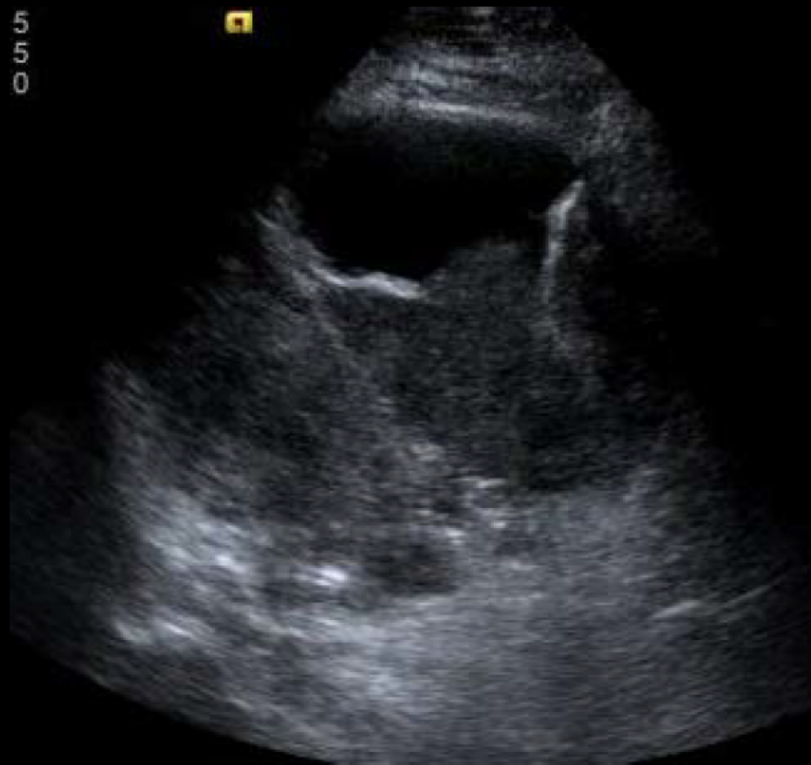

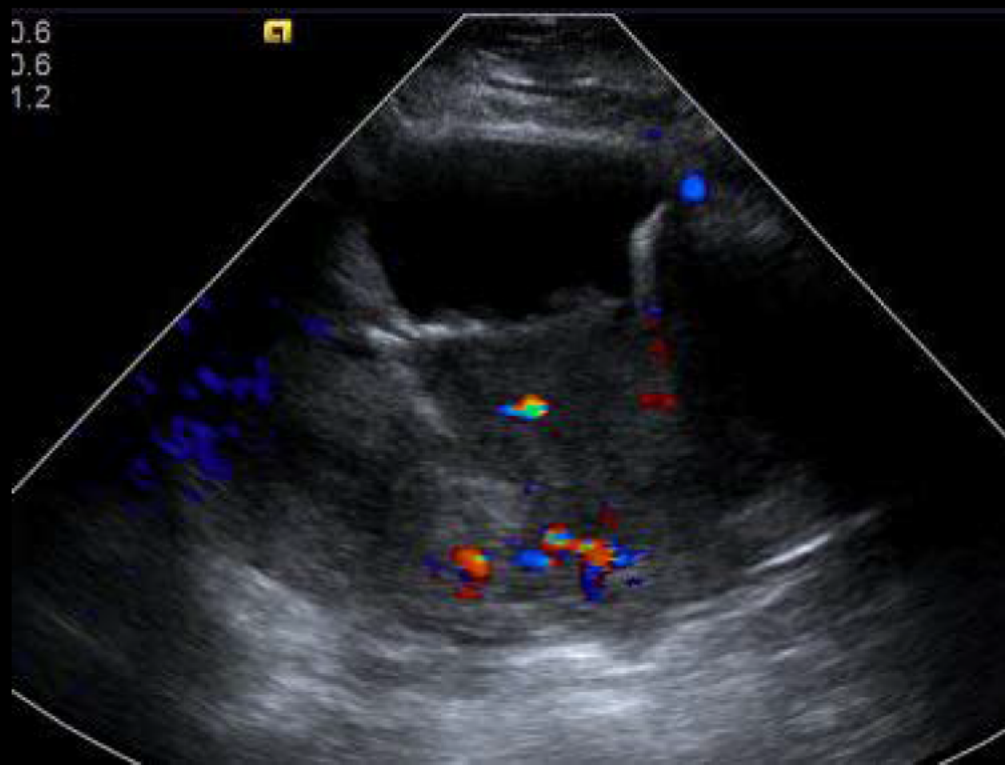
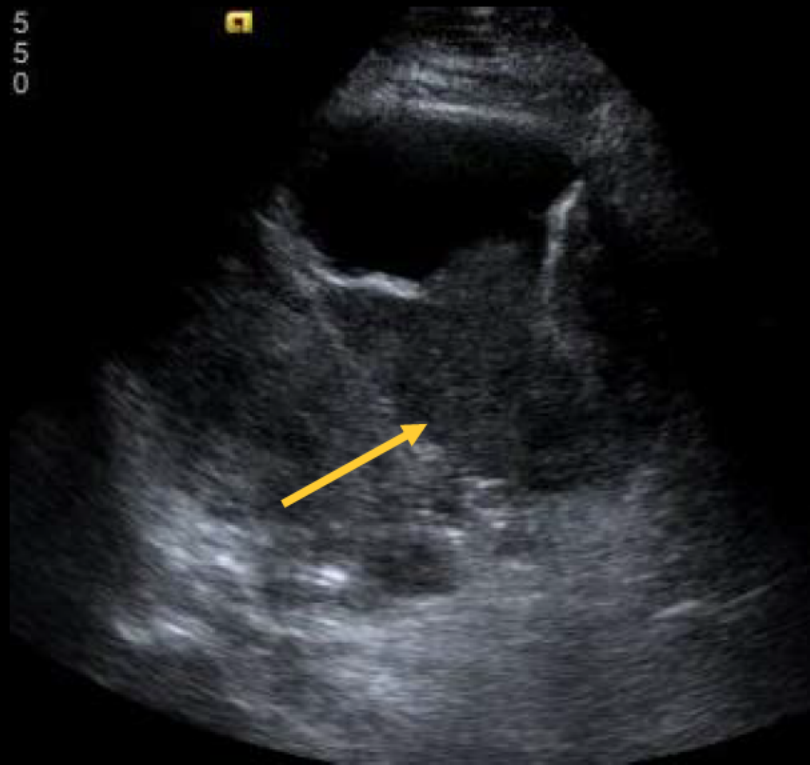
**Right**

IB: 0.5  
BL: 0.9

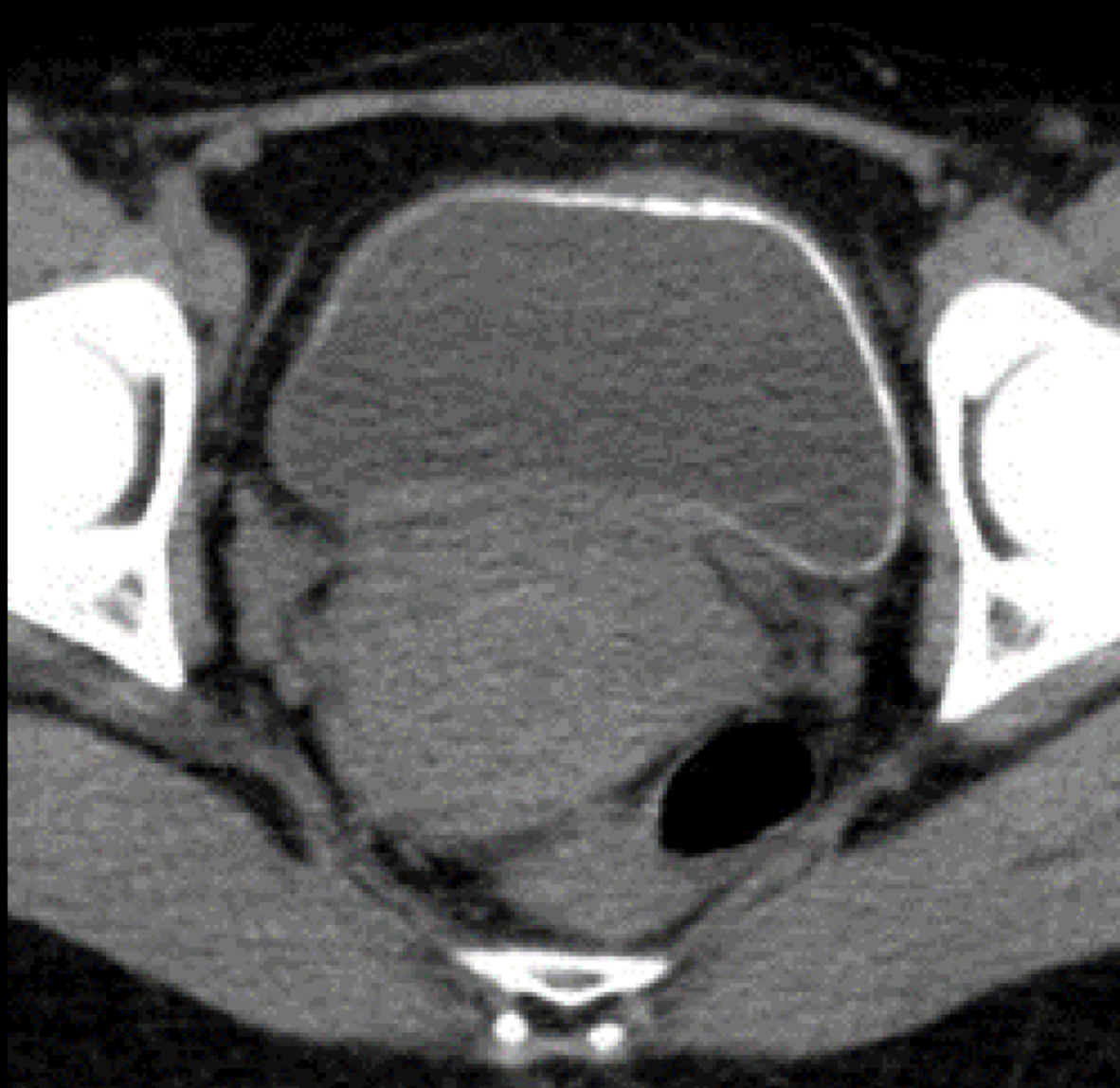


**Left**

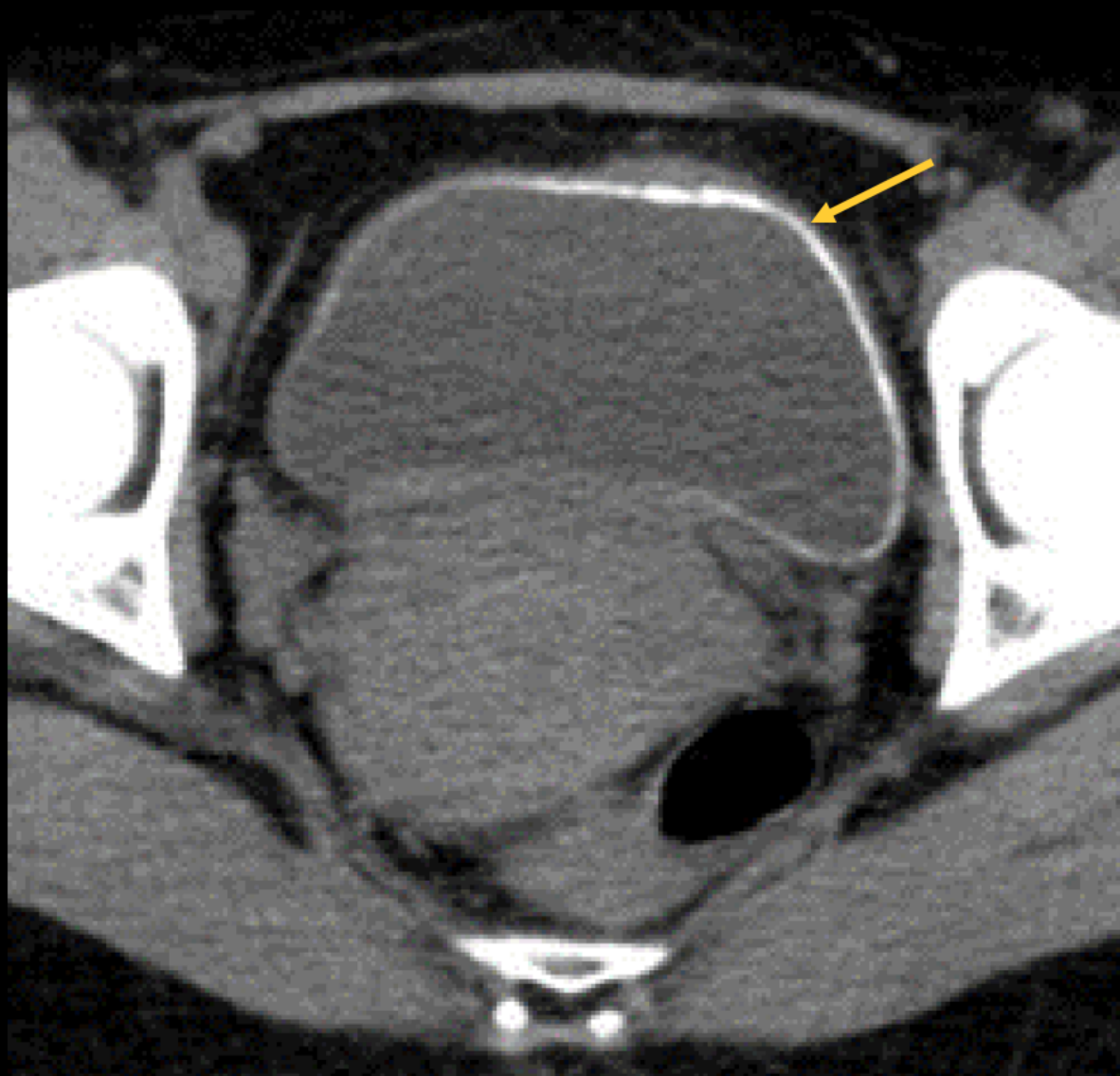




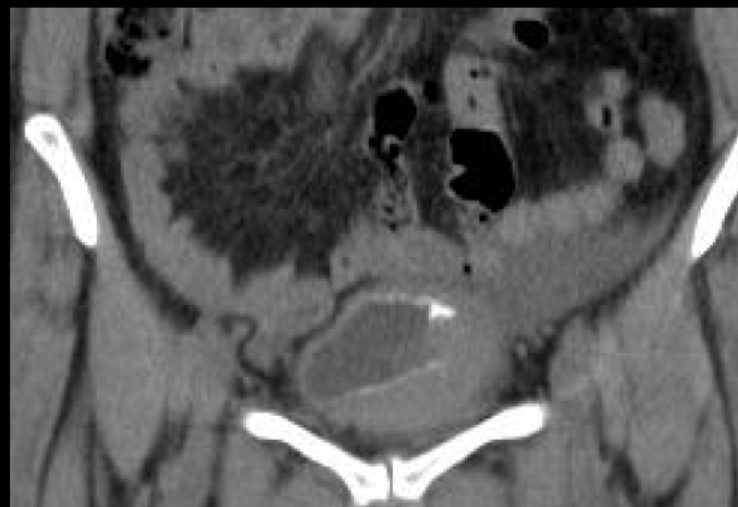
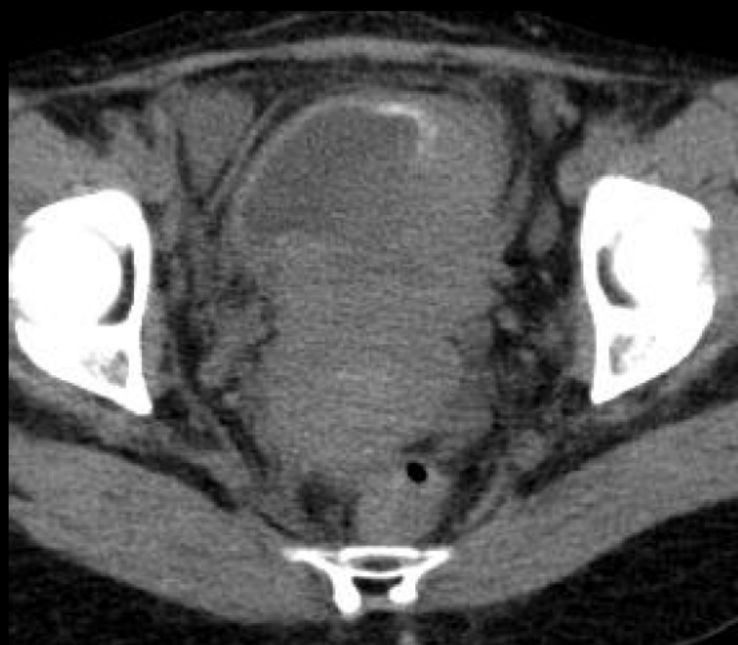
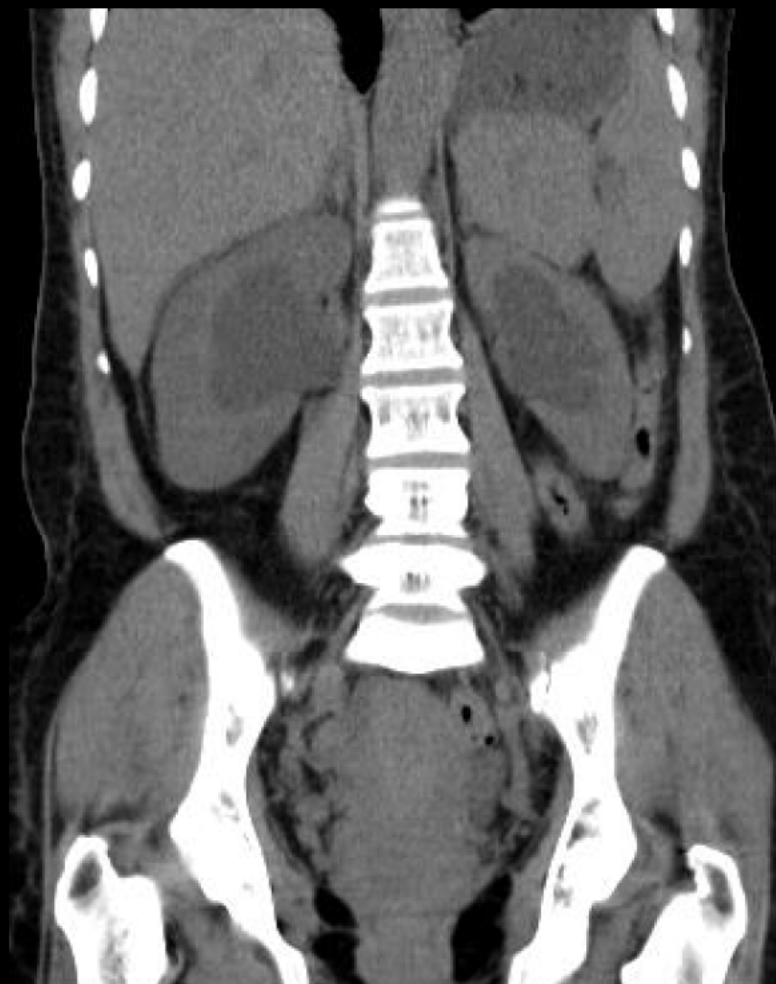

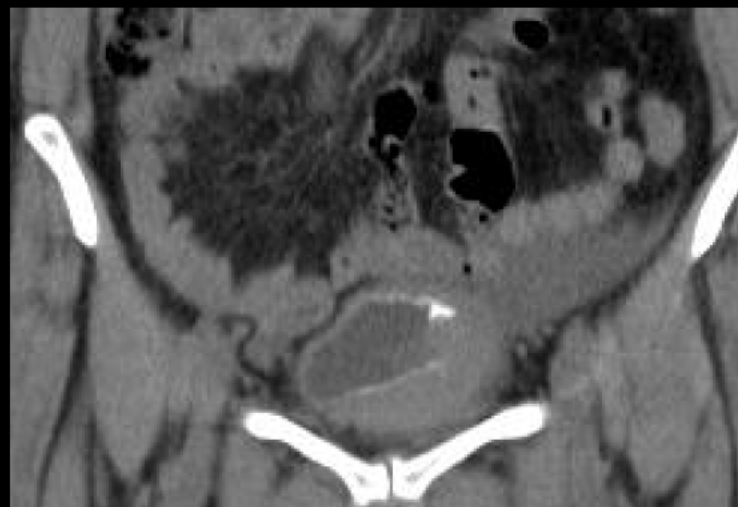

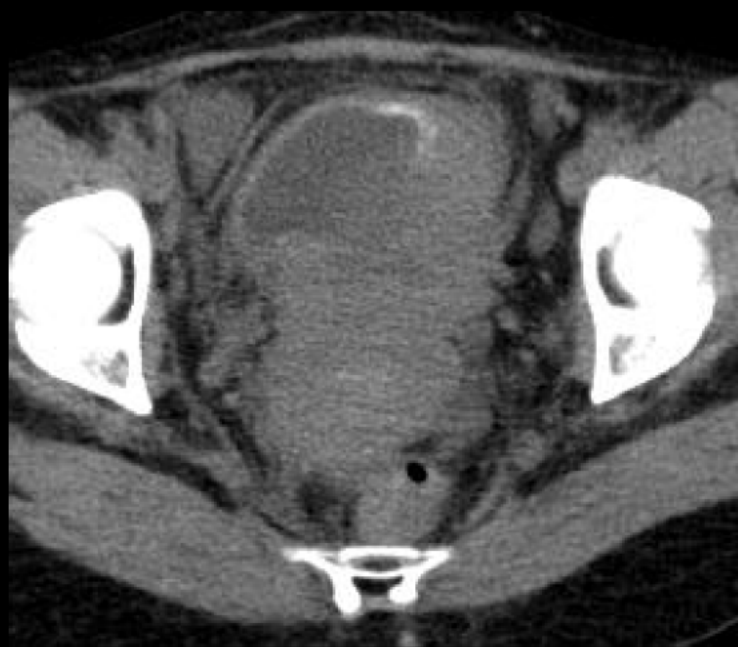
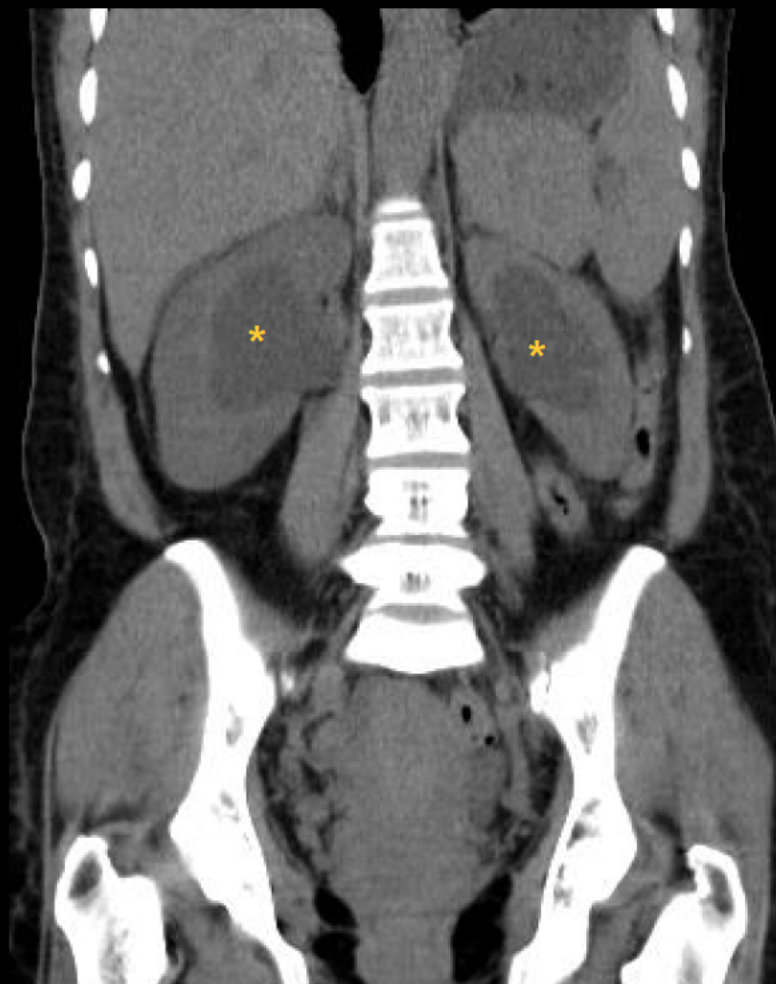**Several years prior**

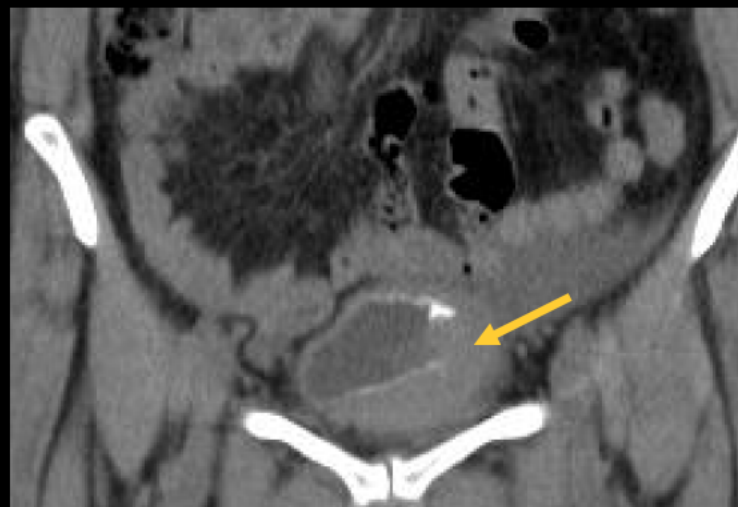
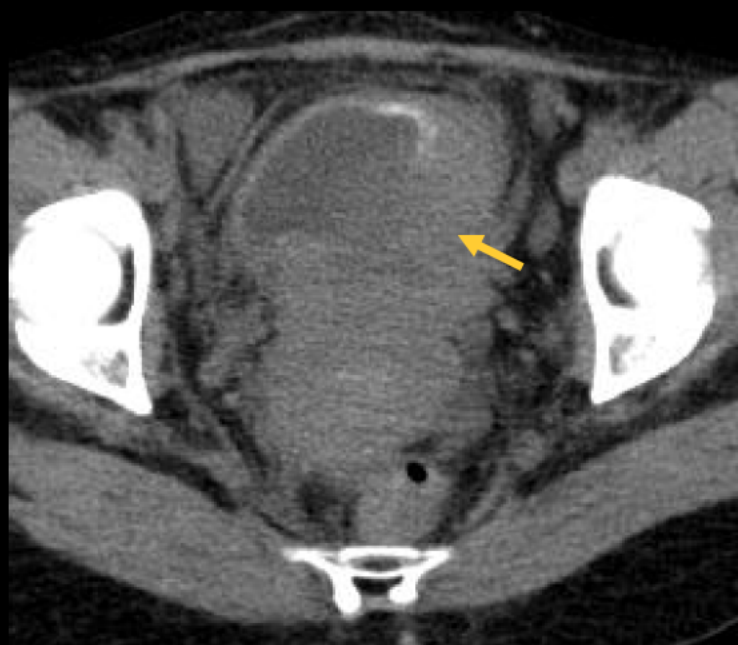

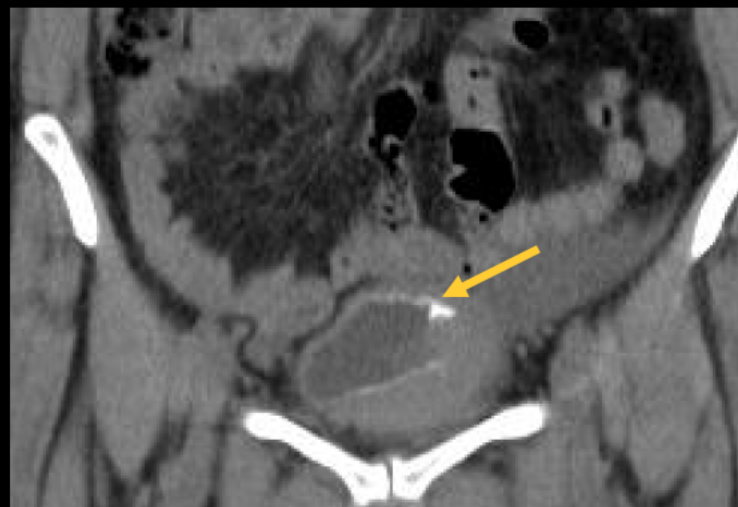
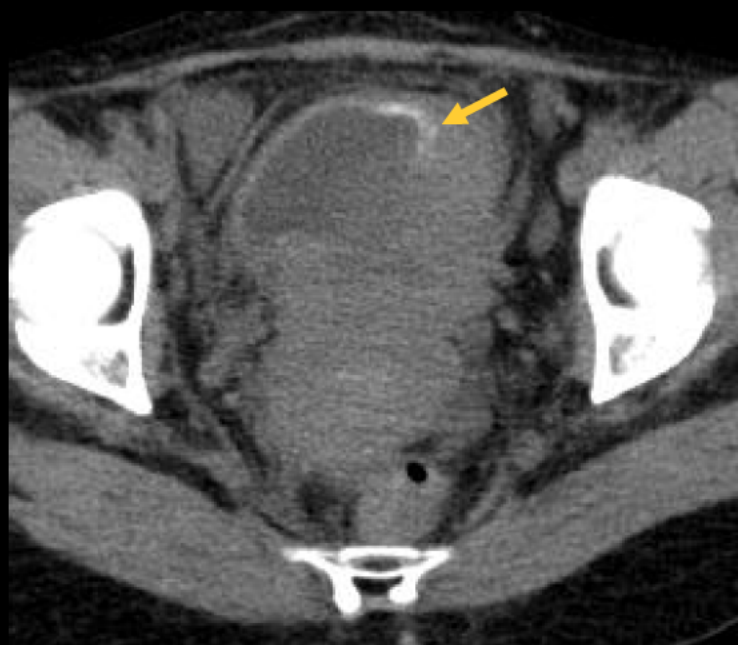**Several years prior**

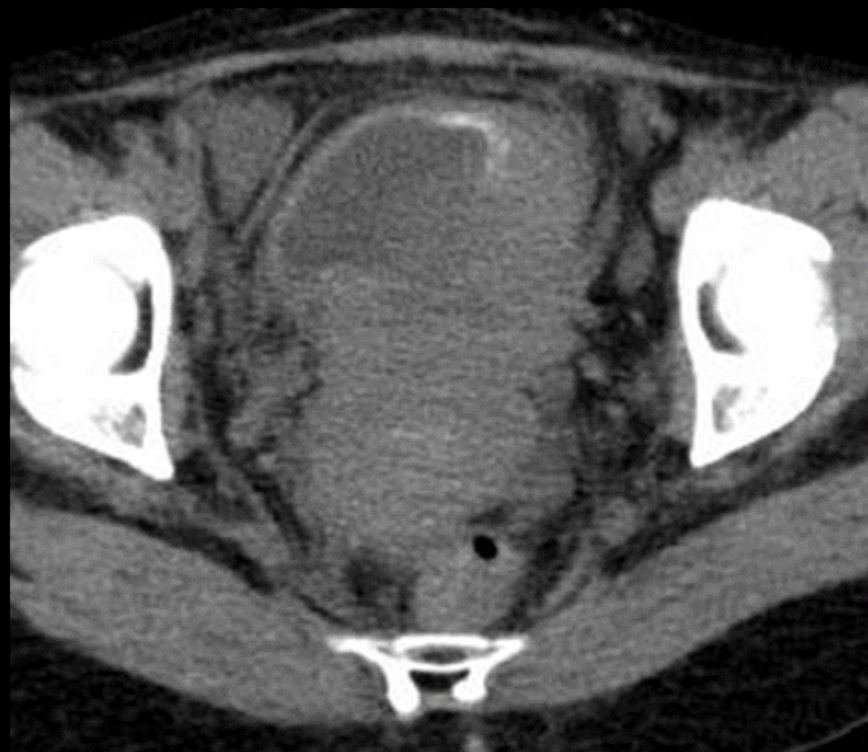
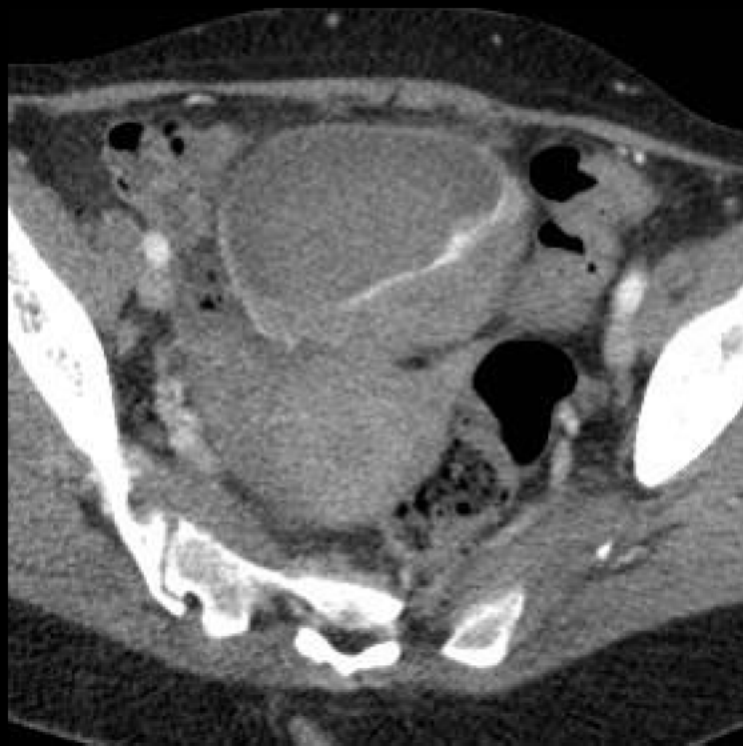


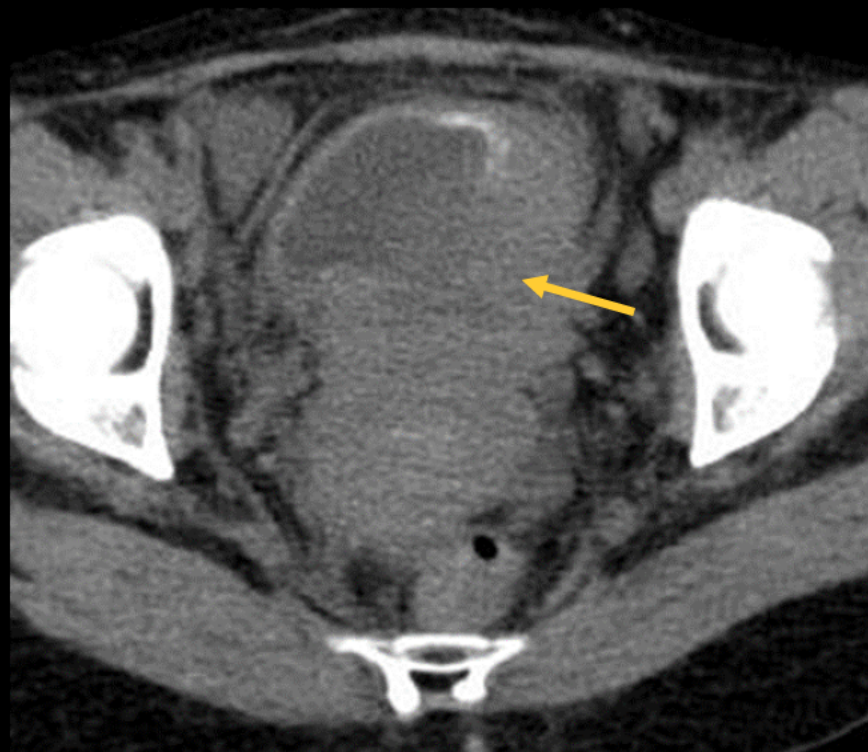
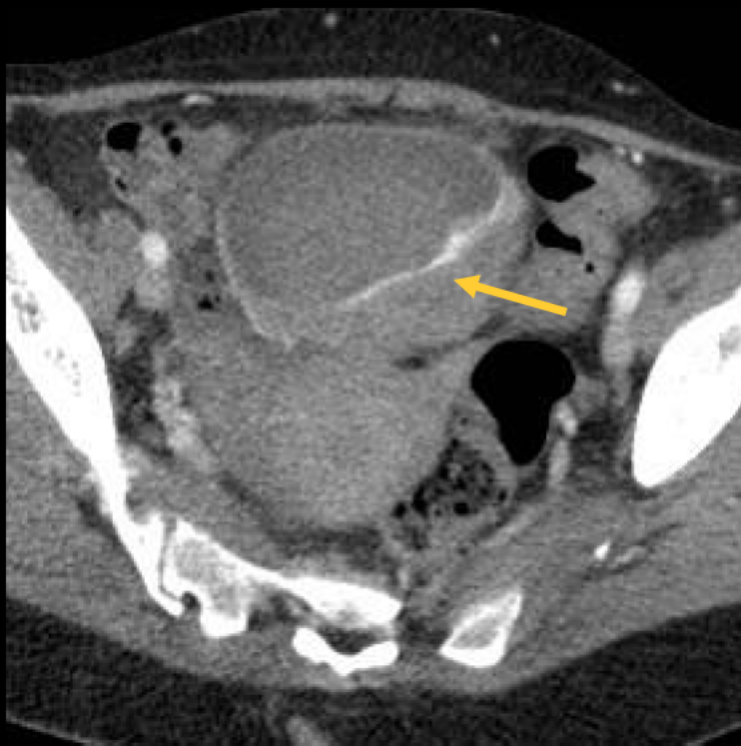




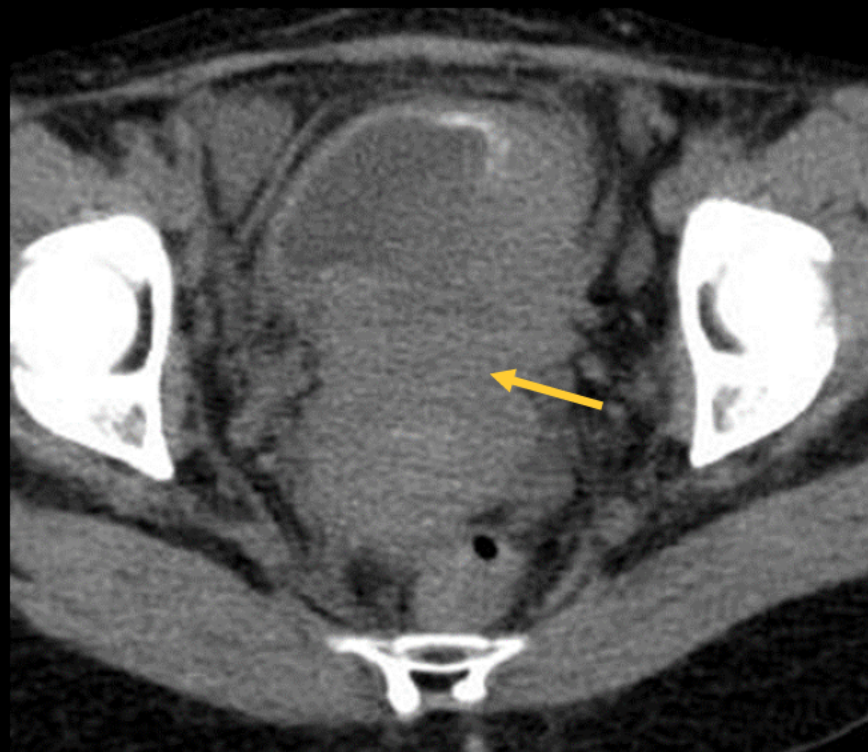
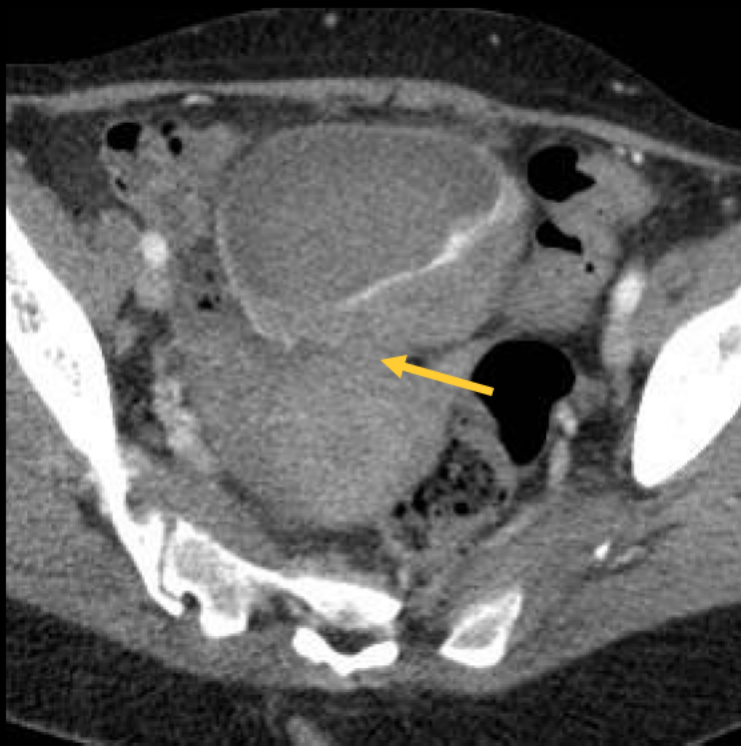


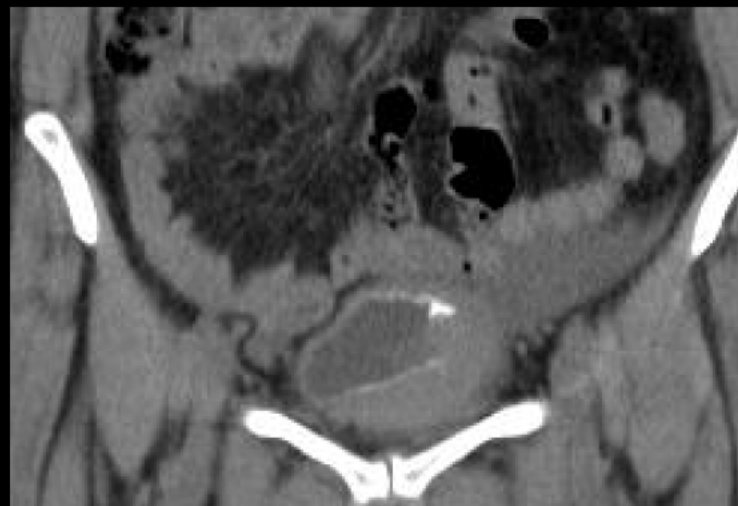
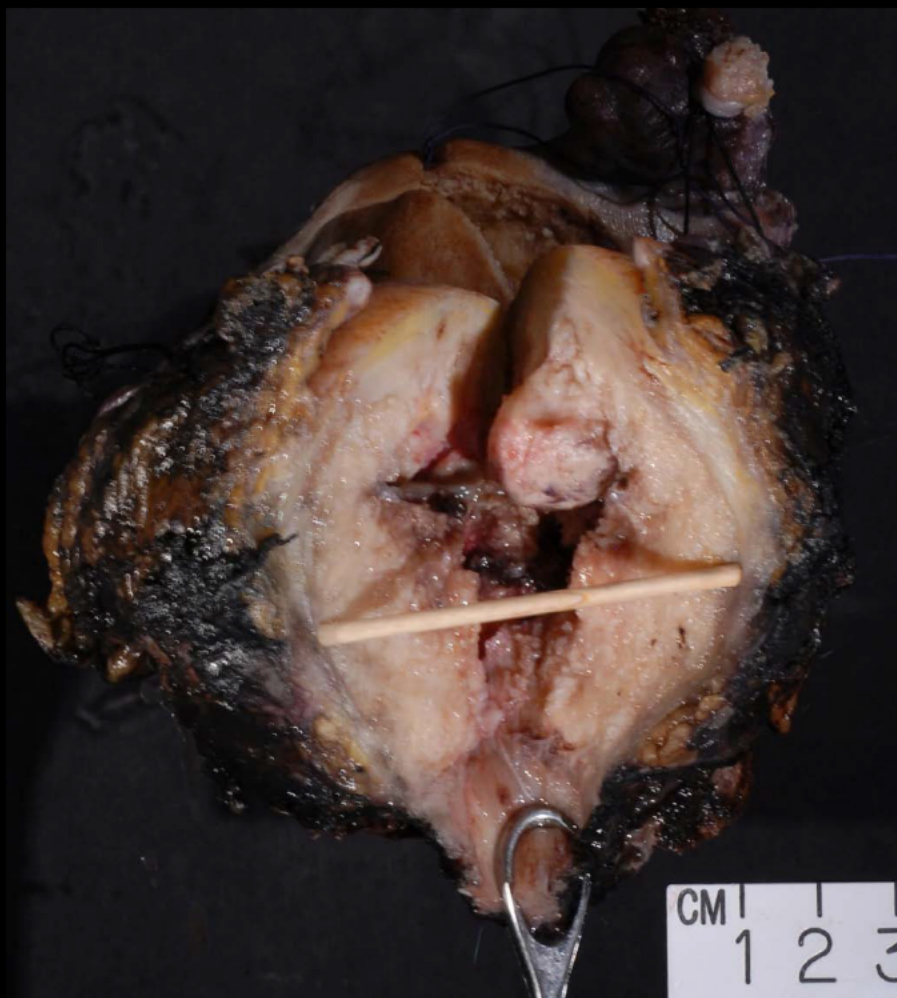


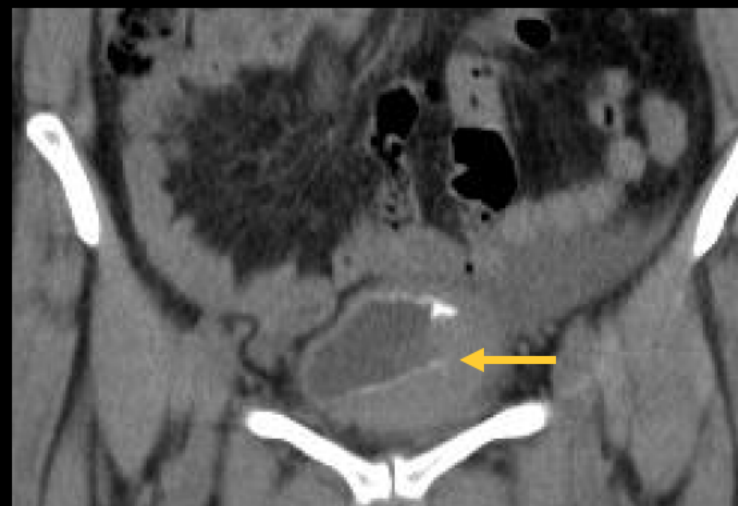
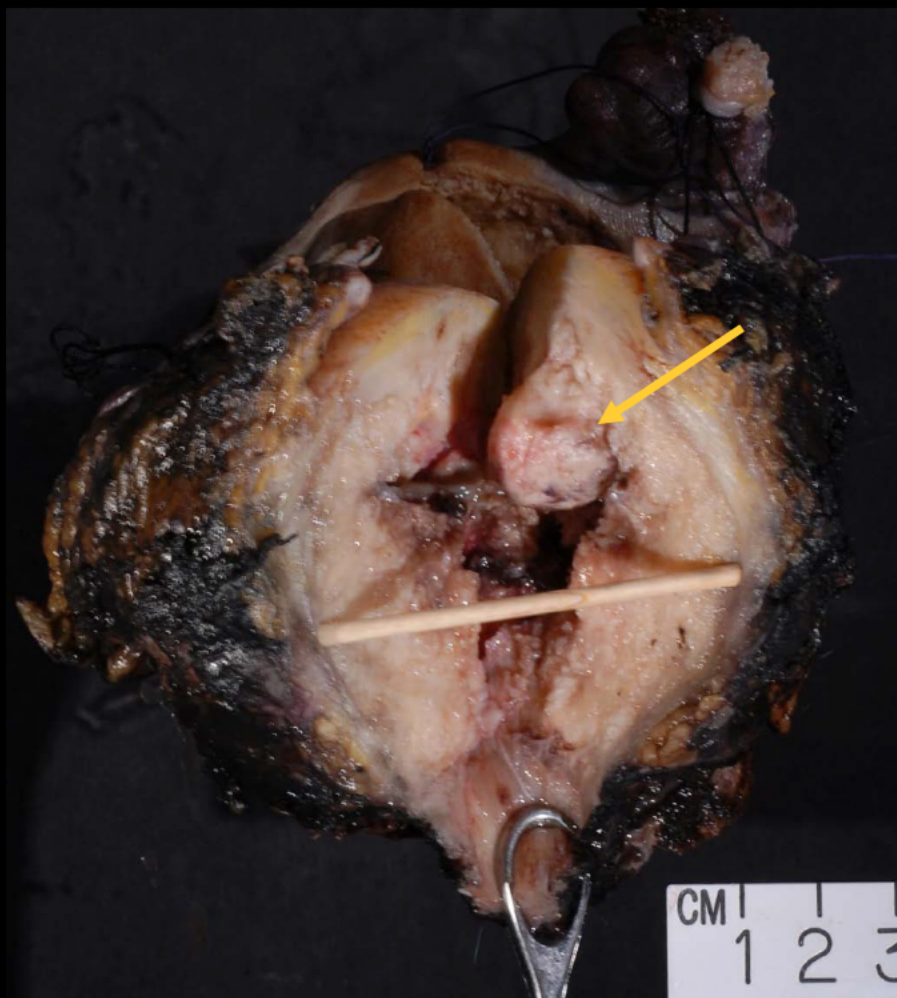




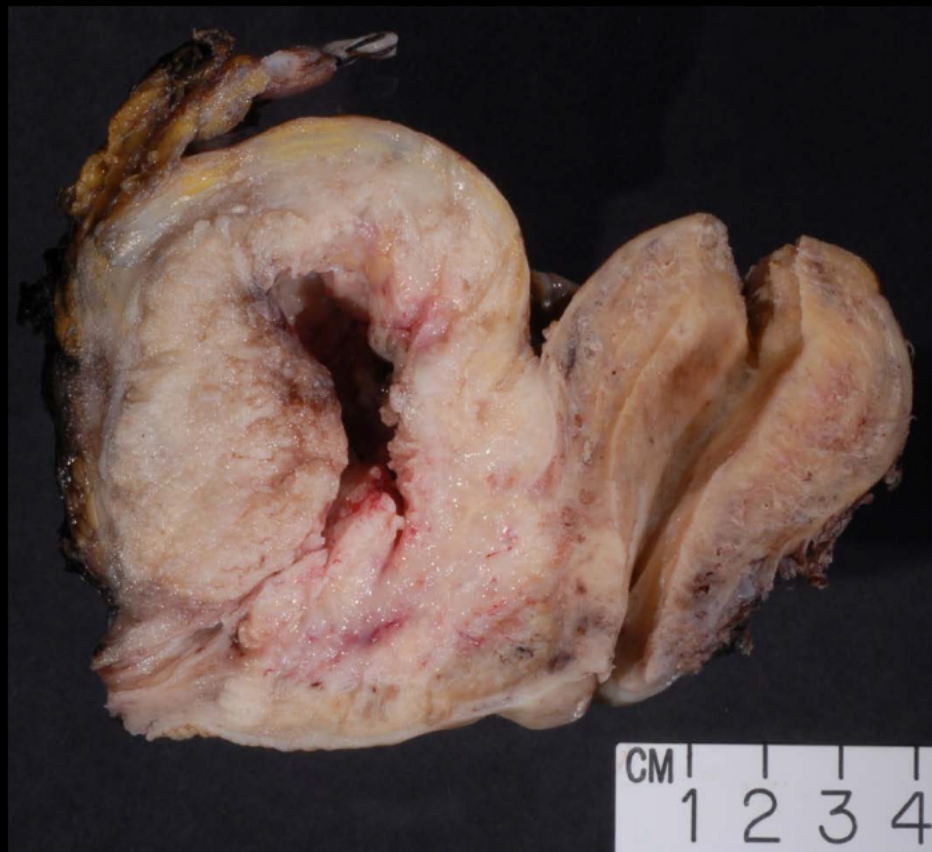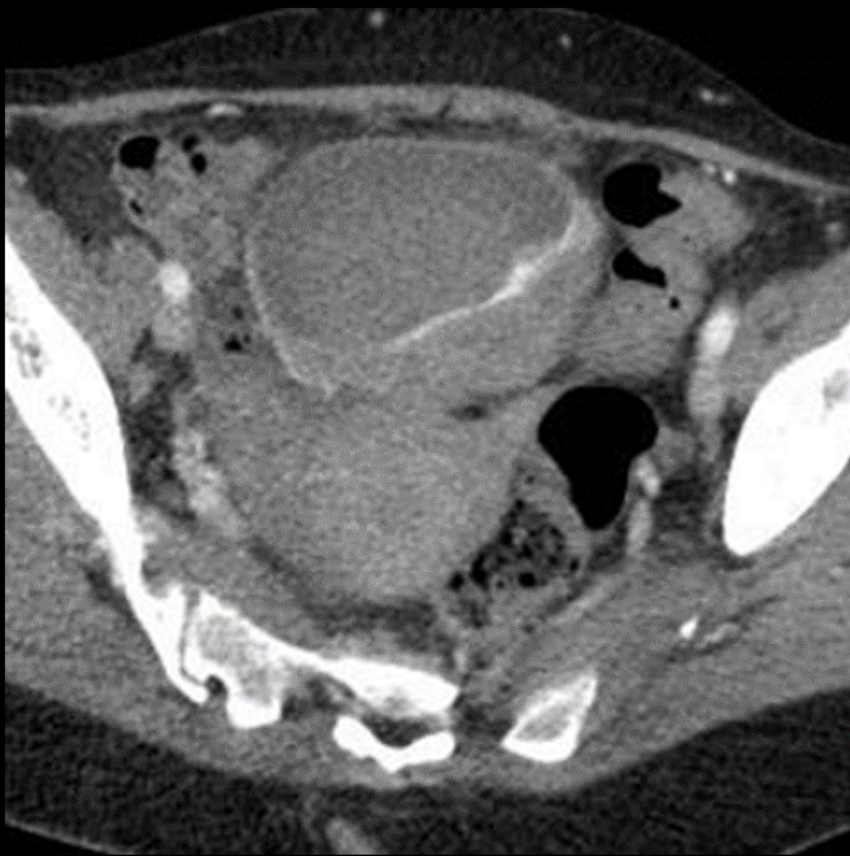




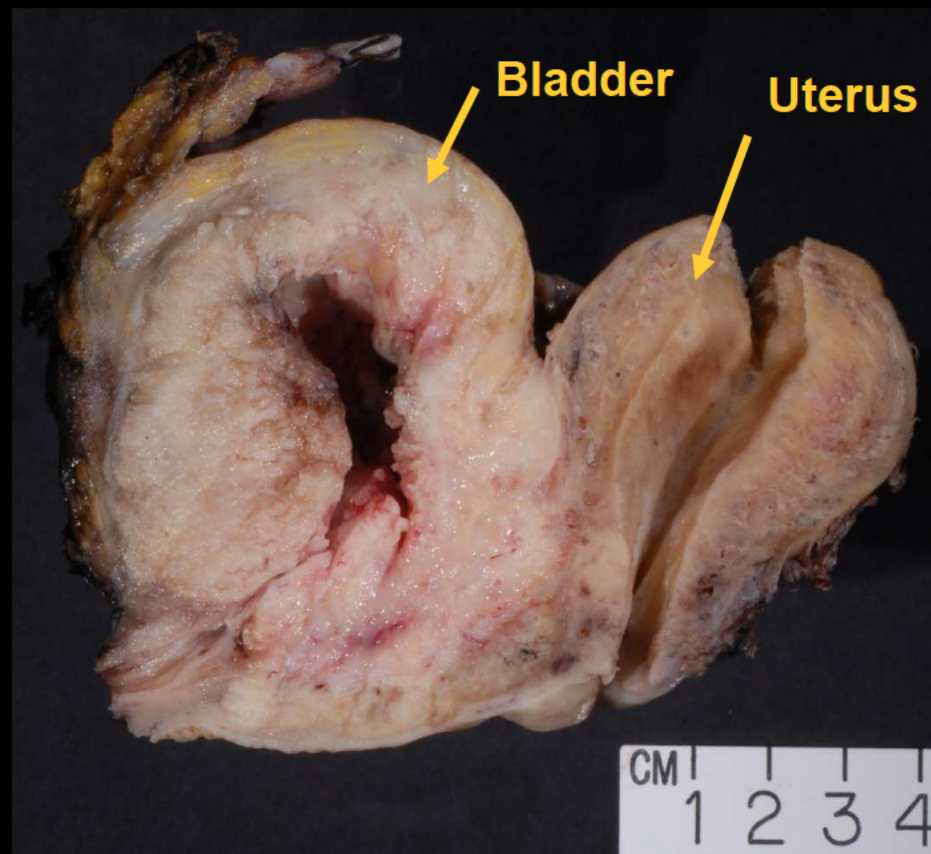
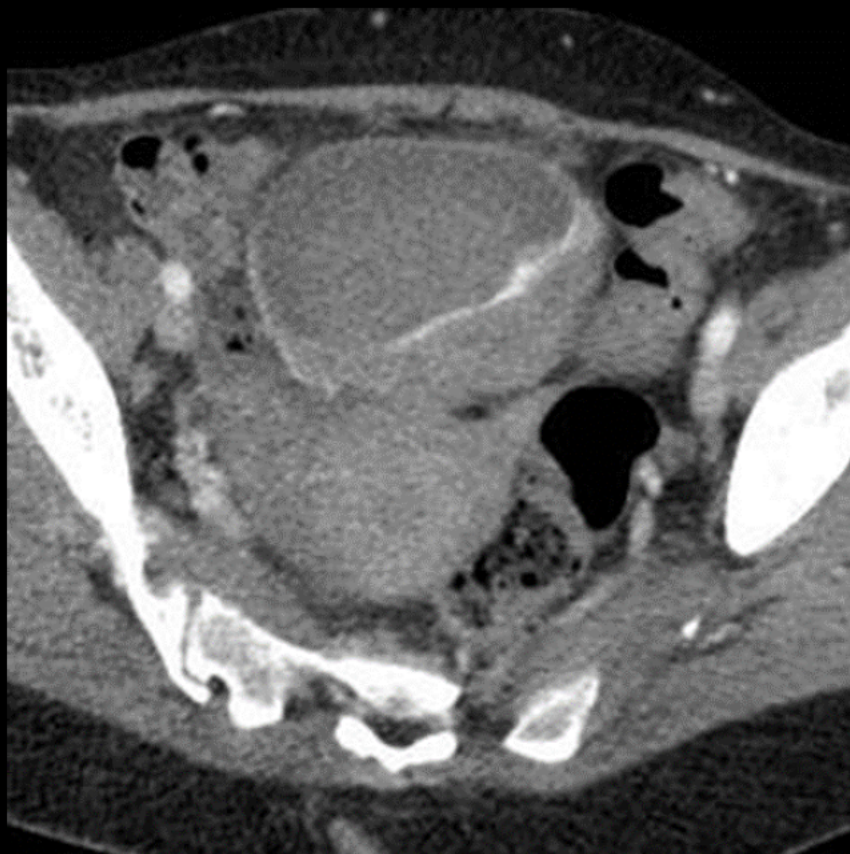


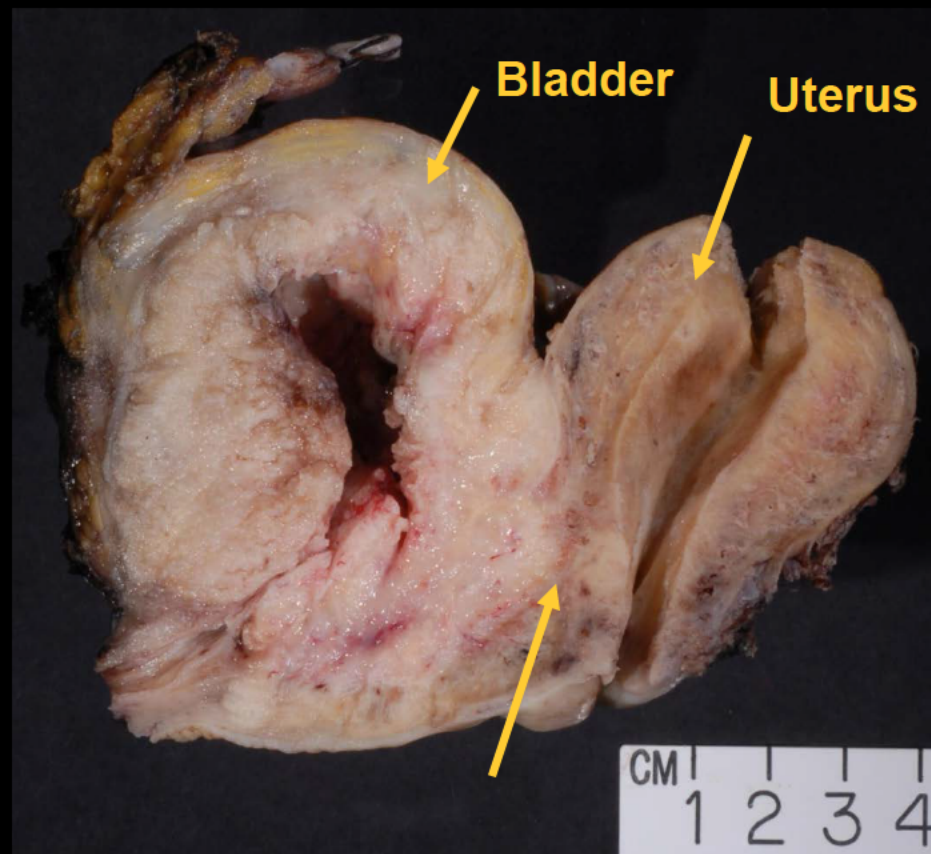
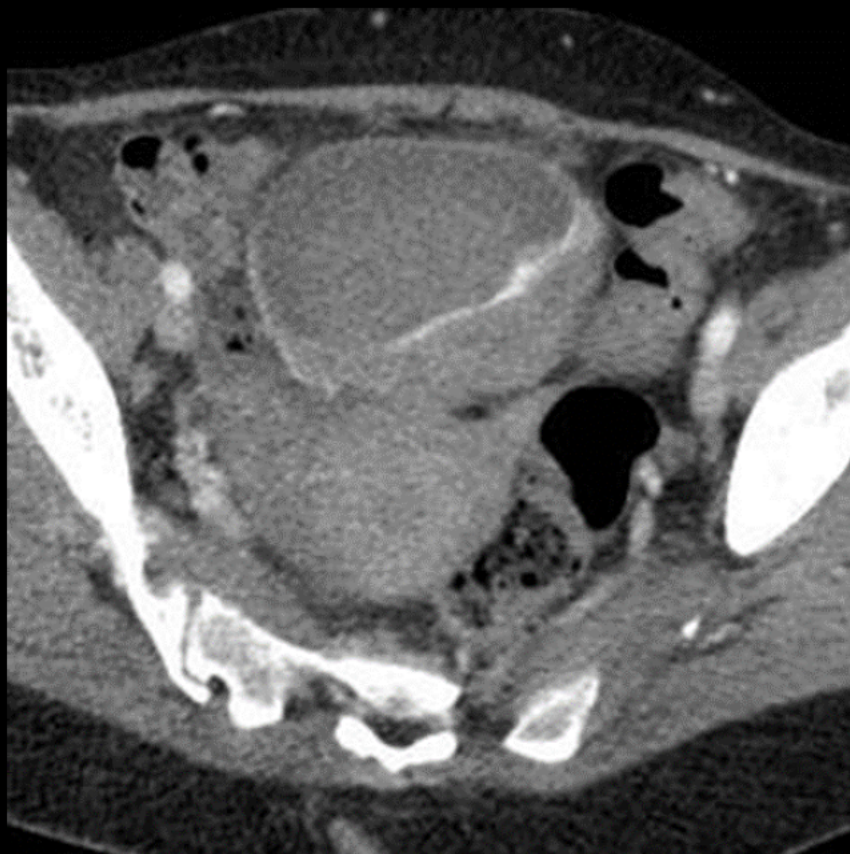




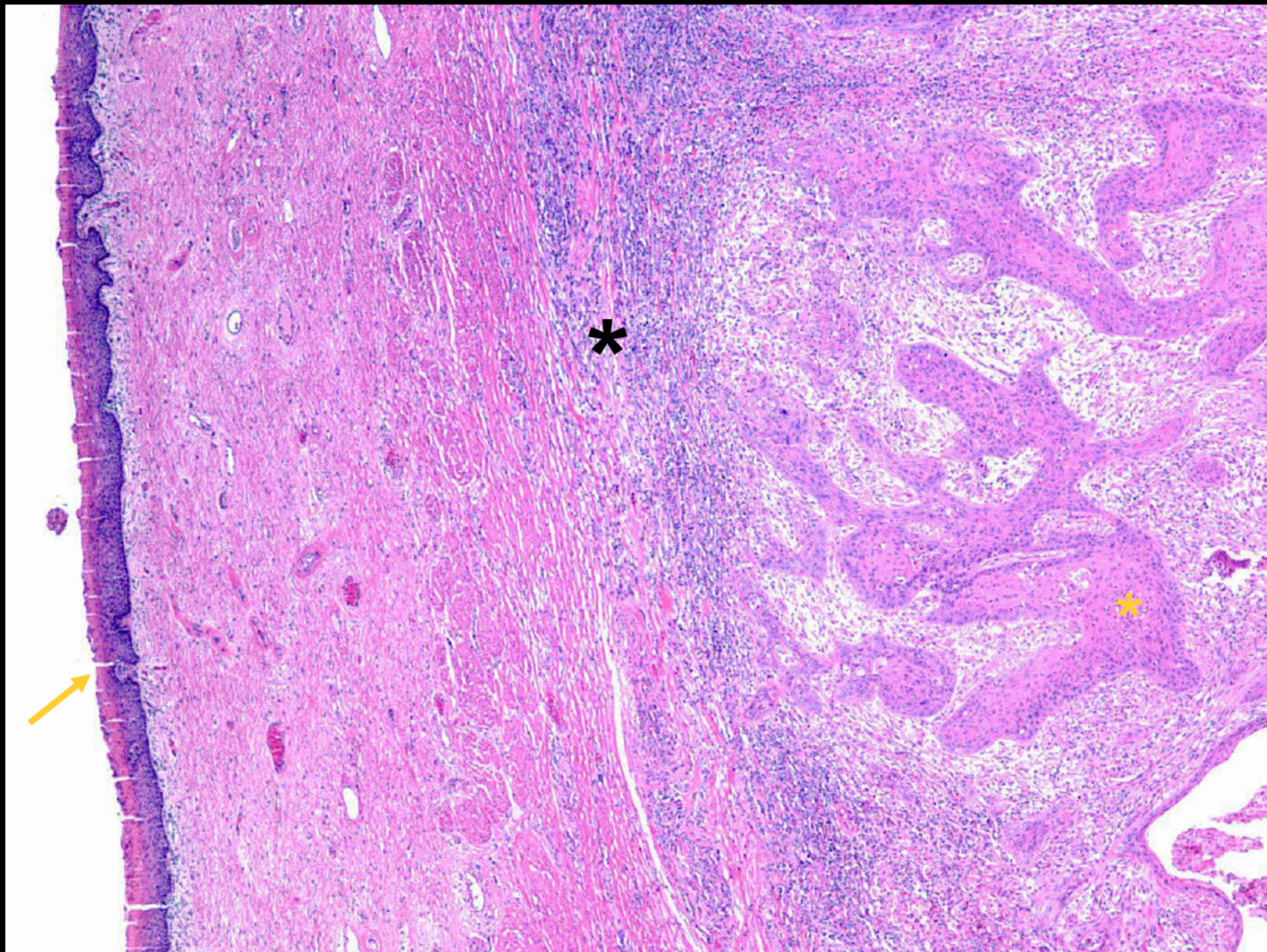




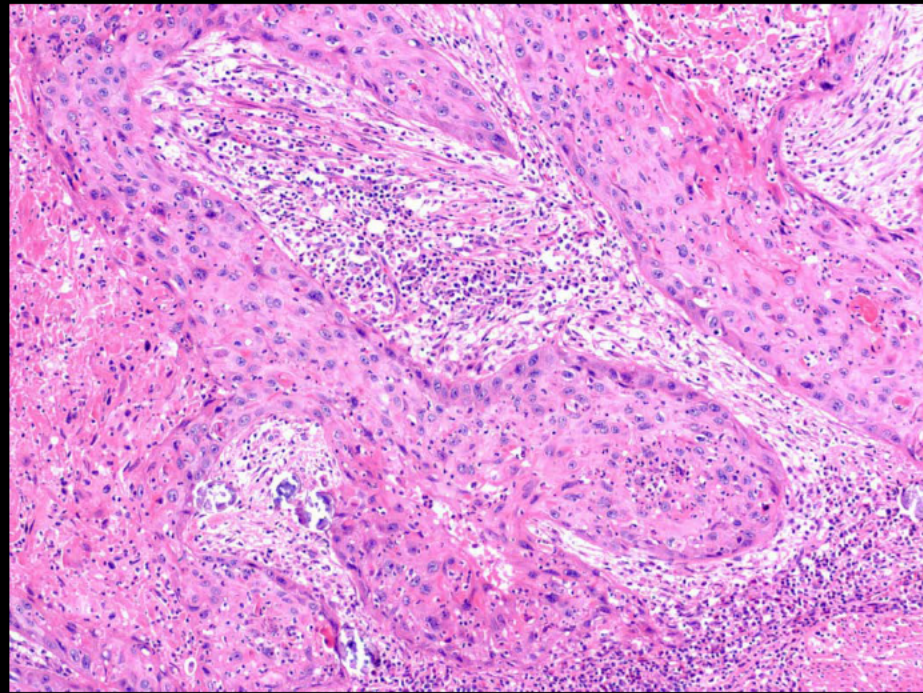
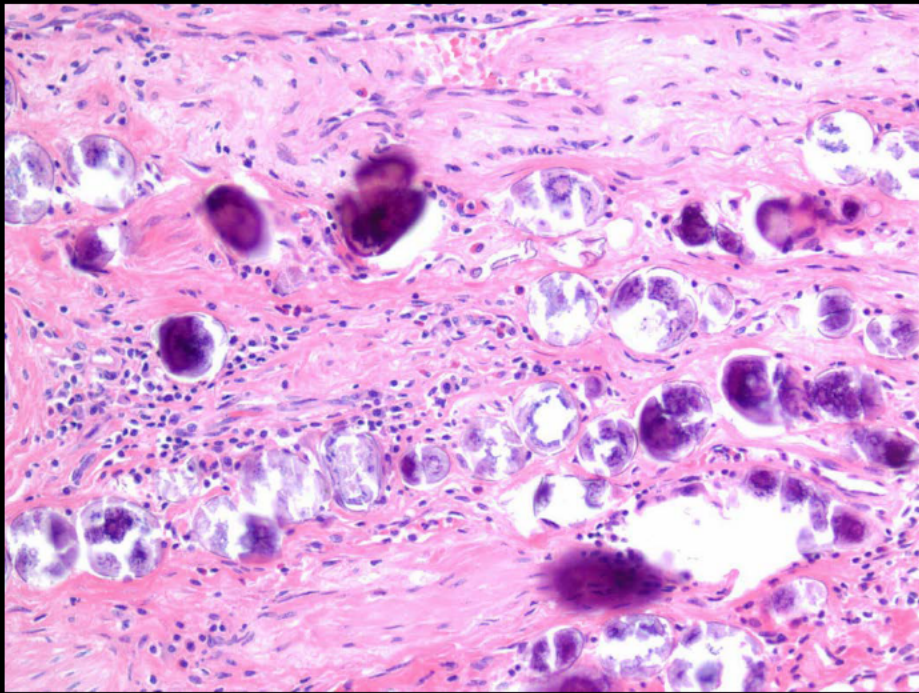




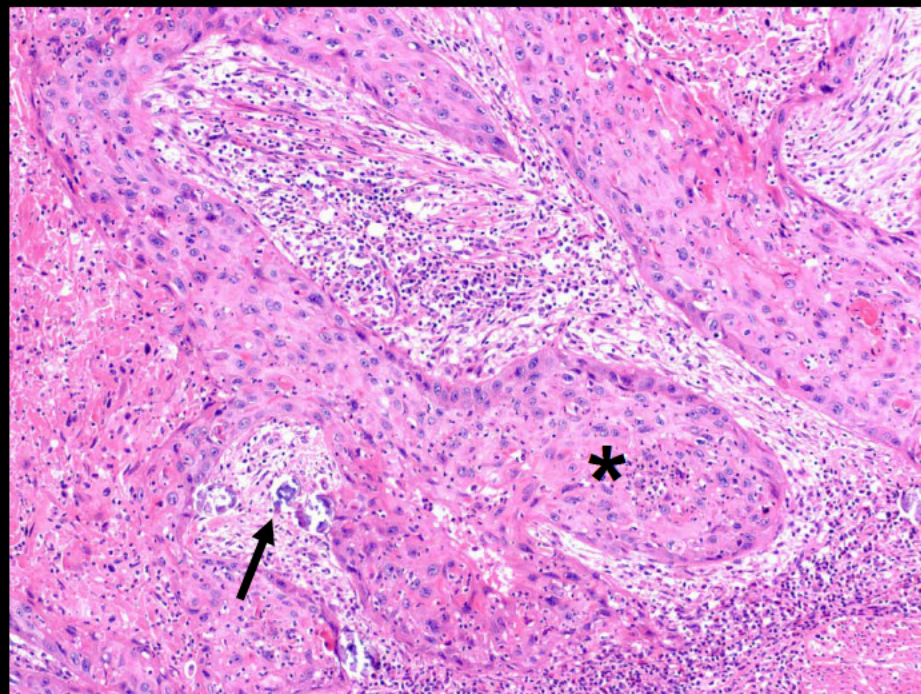
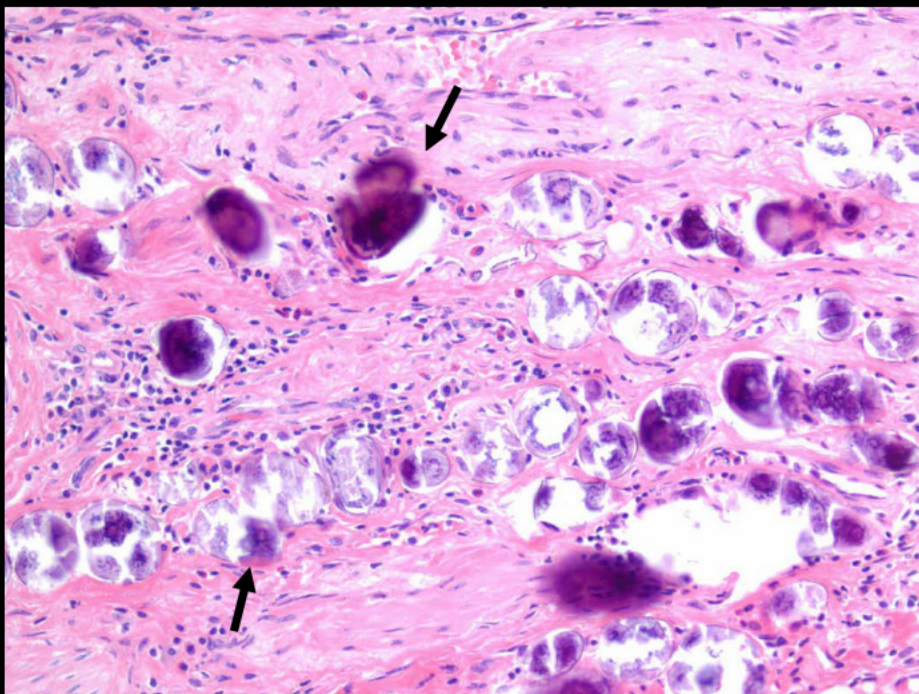












# Schistosomiasis with Squamous Cell Carcinoma of the Bladder

Matthew Poturalski, MD  
Cleveland Clinic  
Cleveland, OH