

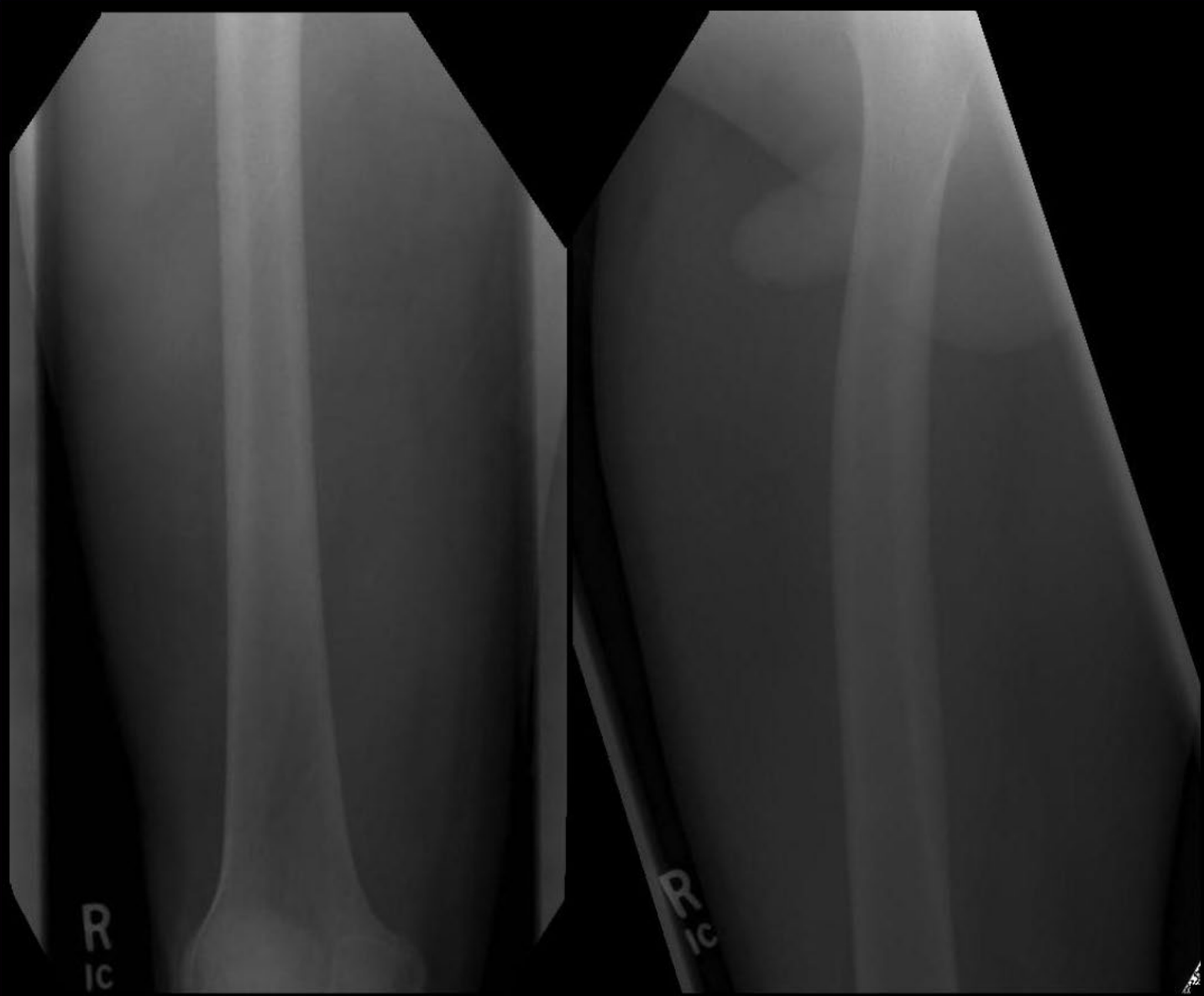
BEST CASES OF THE AIRP

July 25 – August 19, 2011

Musculoskeletal Best Case

27 year old Male:

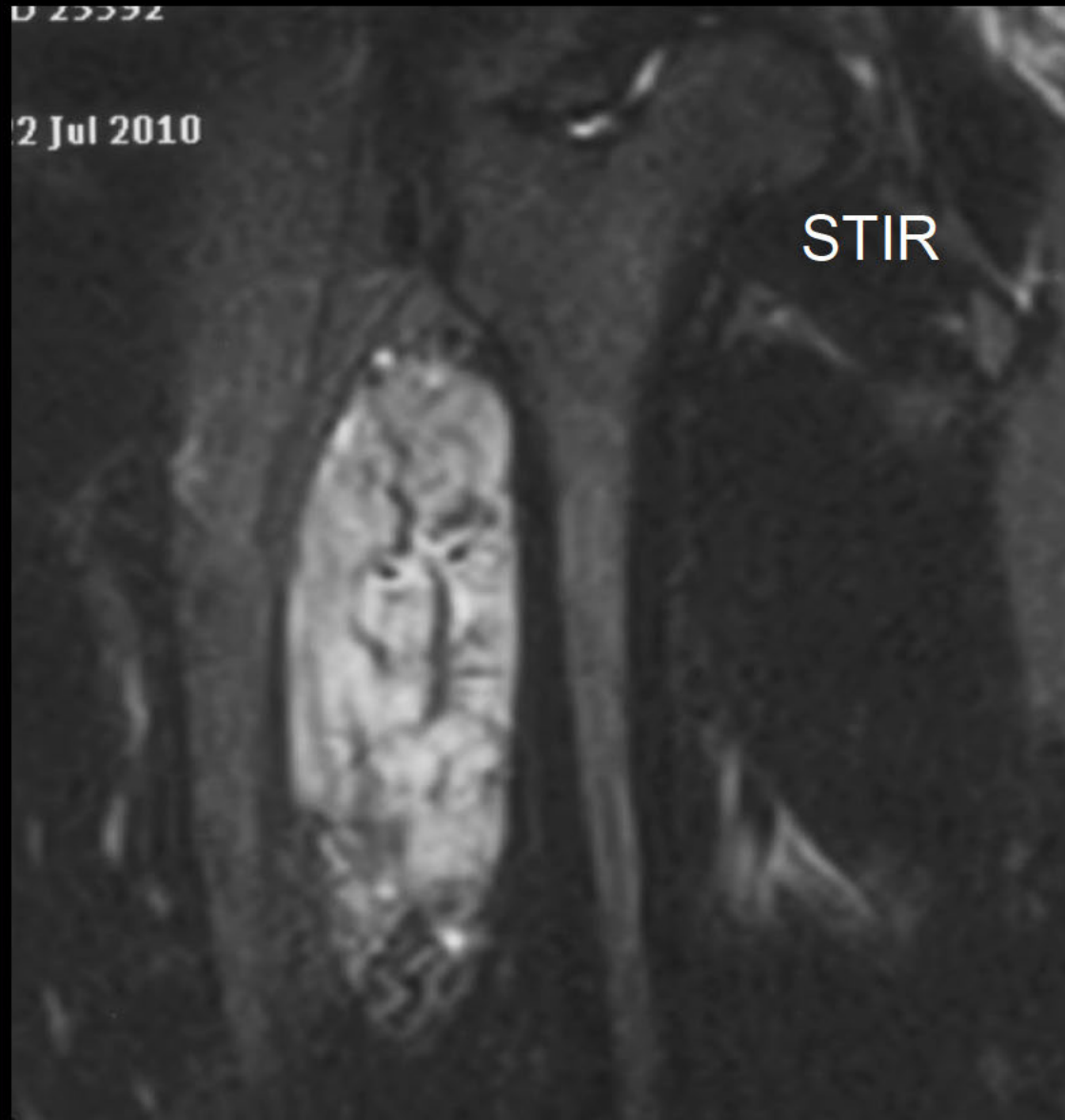
- Right thigh discomfort x 1 year
- Mass in the area of discomfort
x 6 months

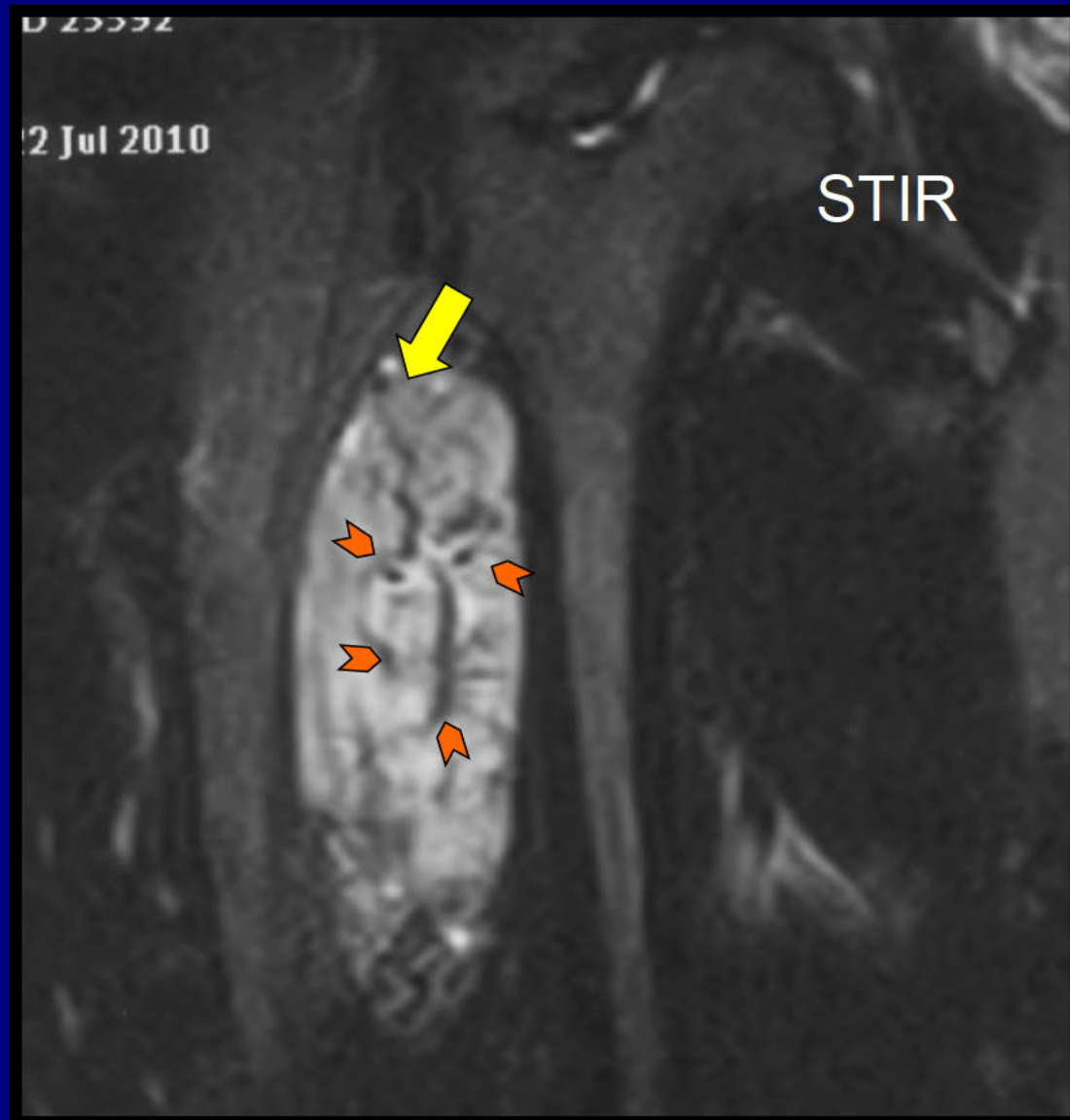


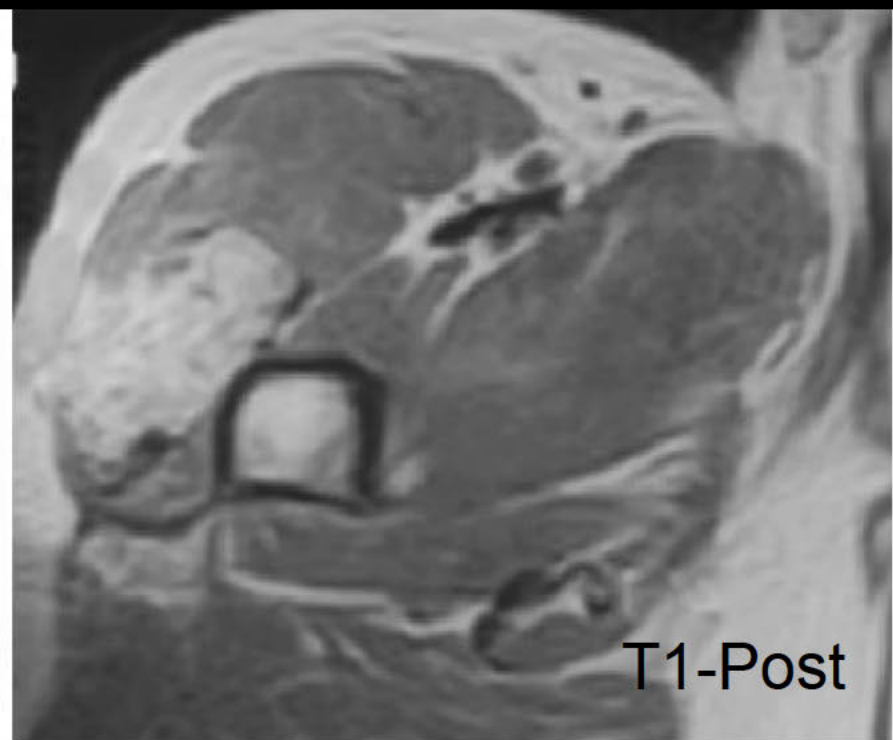
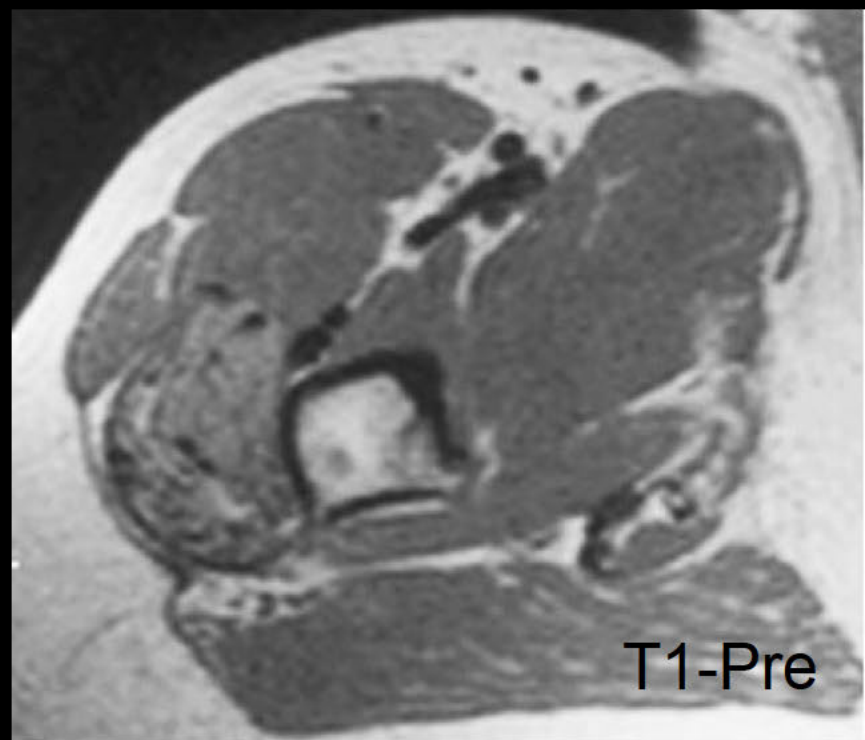
0 25592

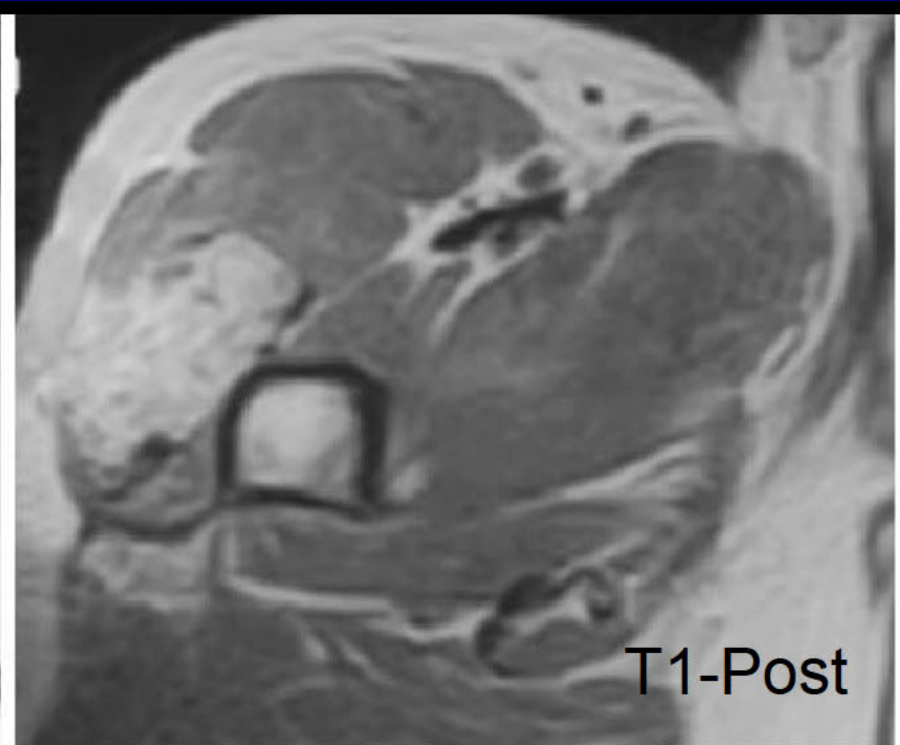
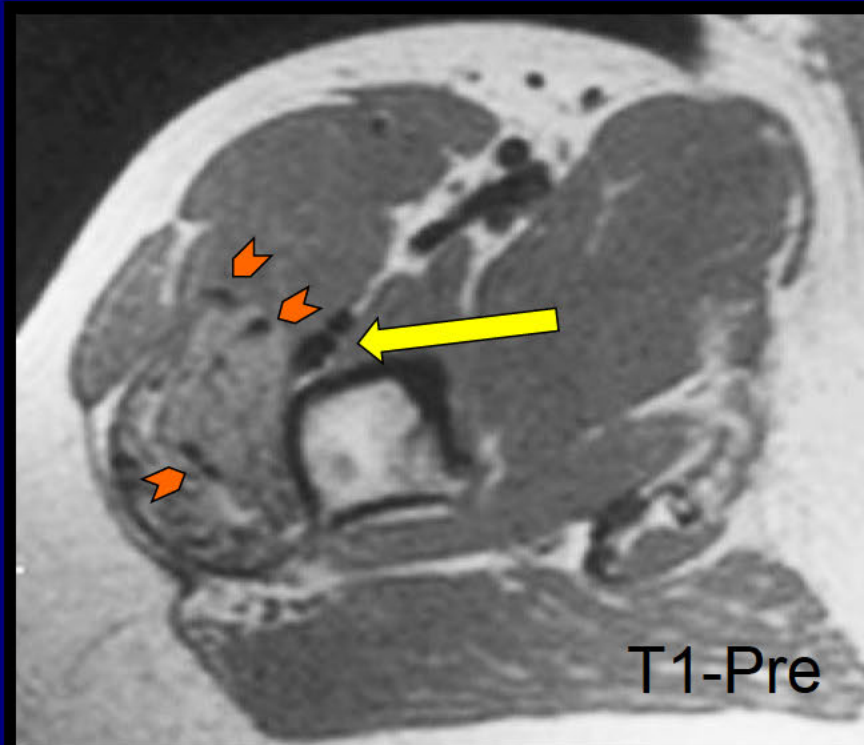
2 Jul 2010

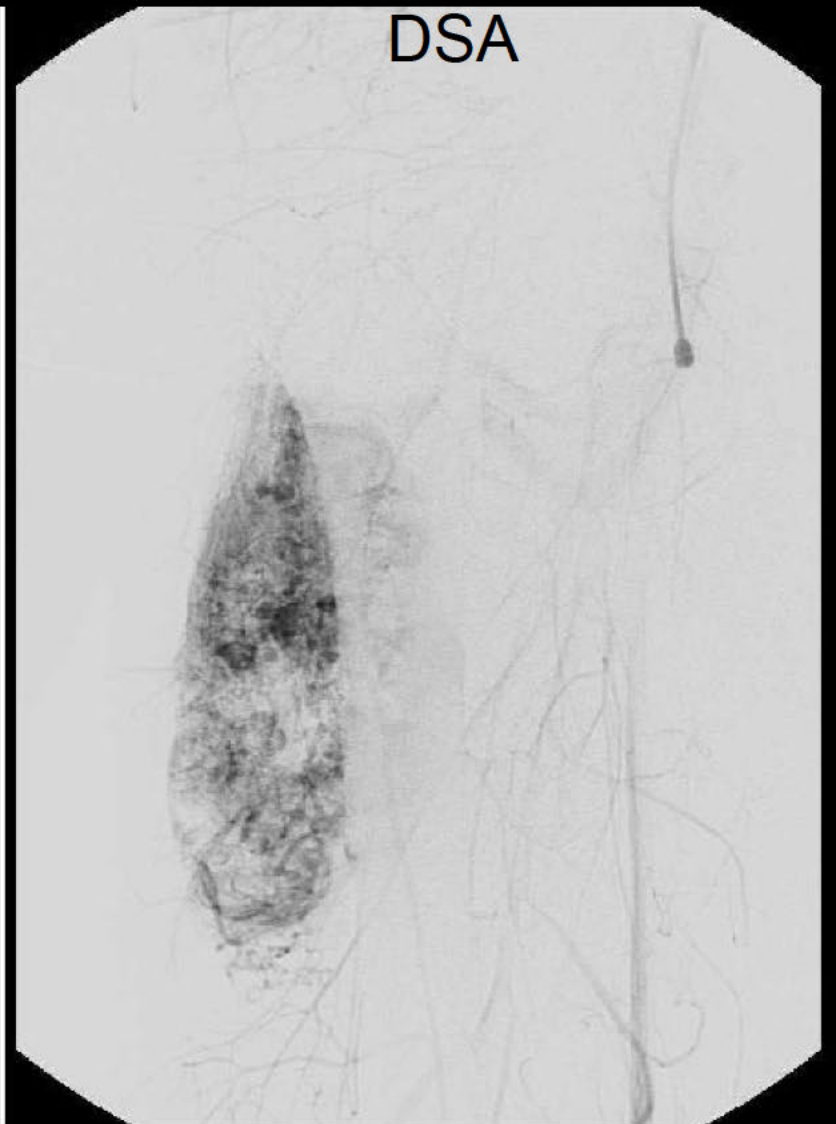
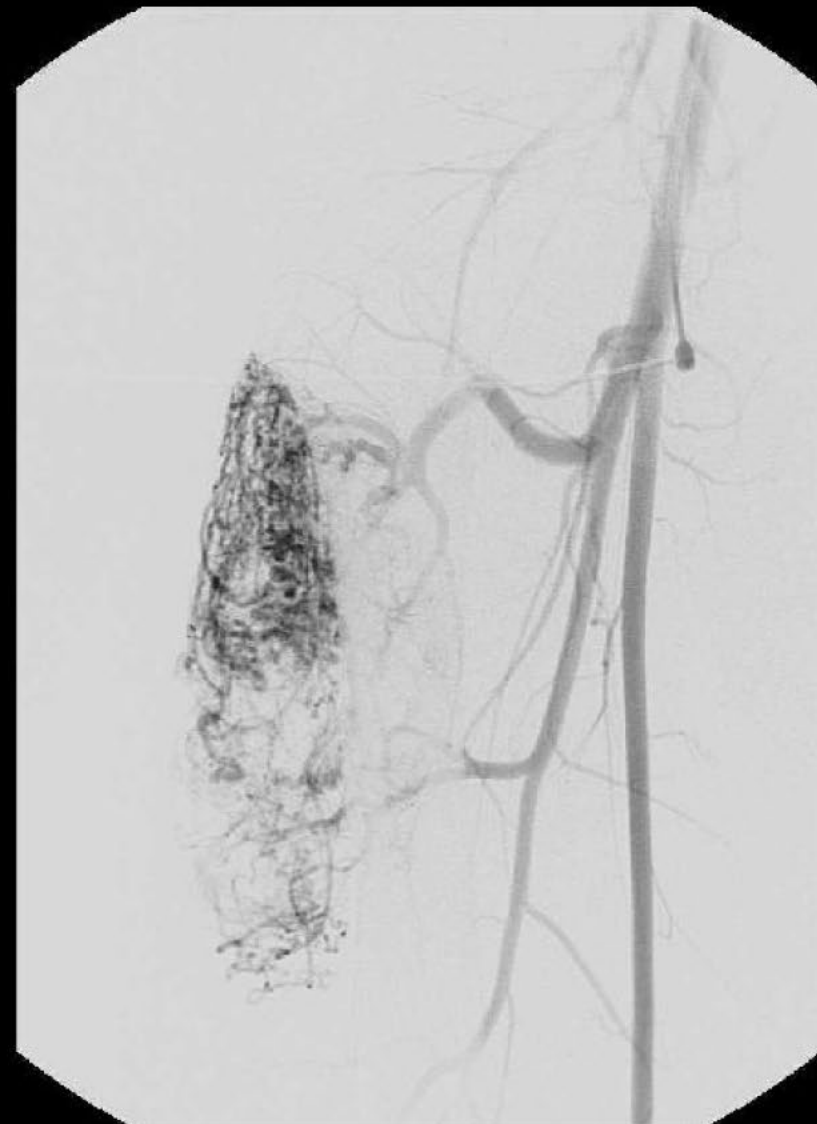
STIR

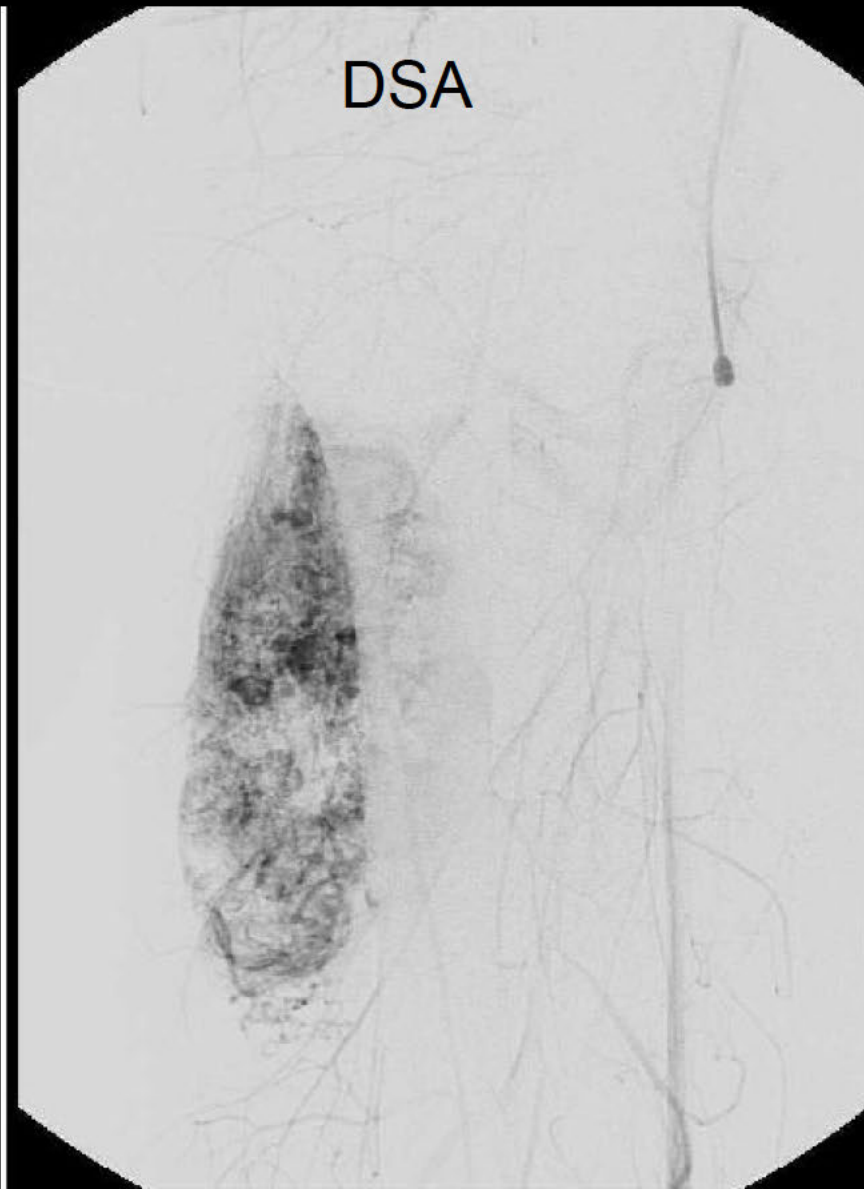
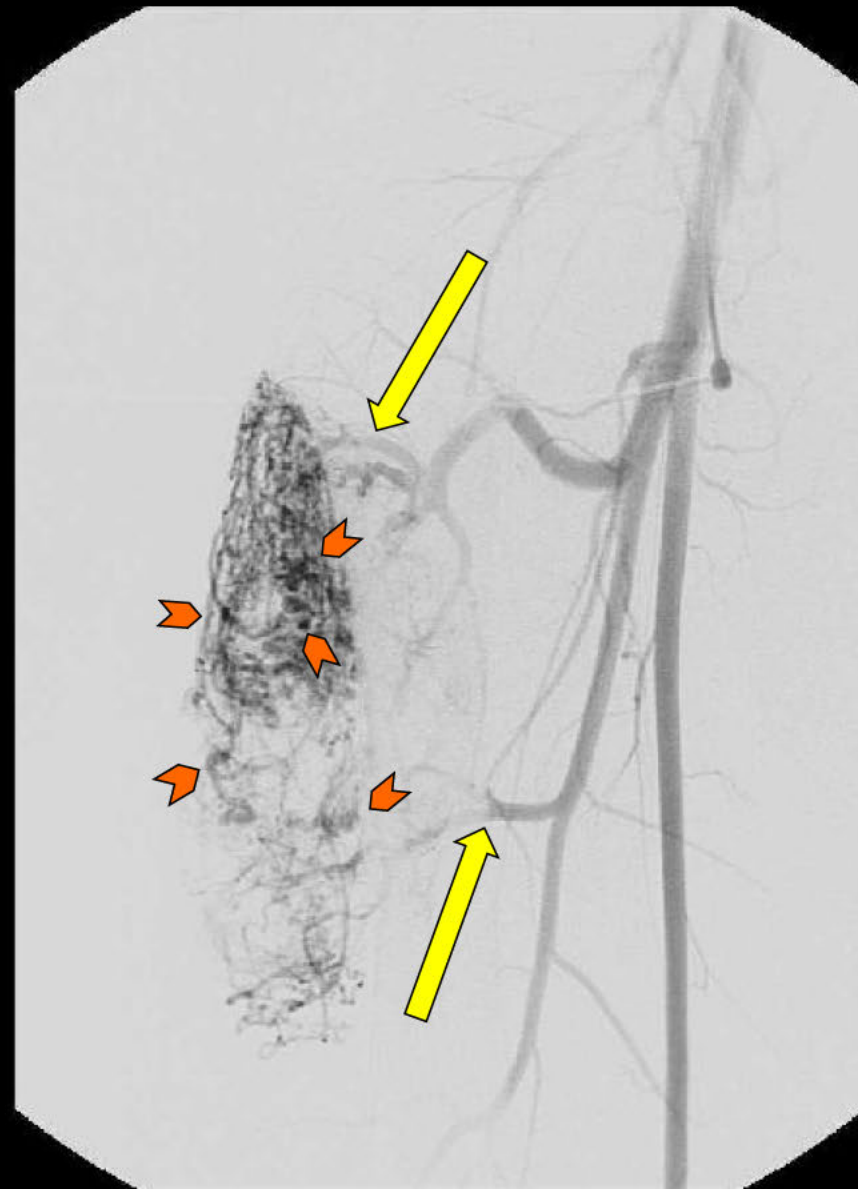

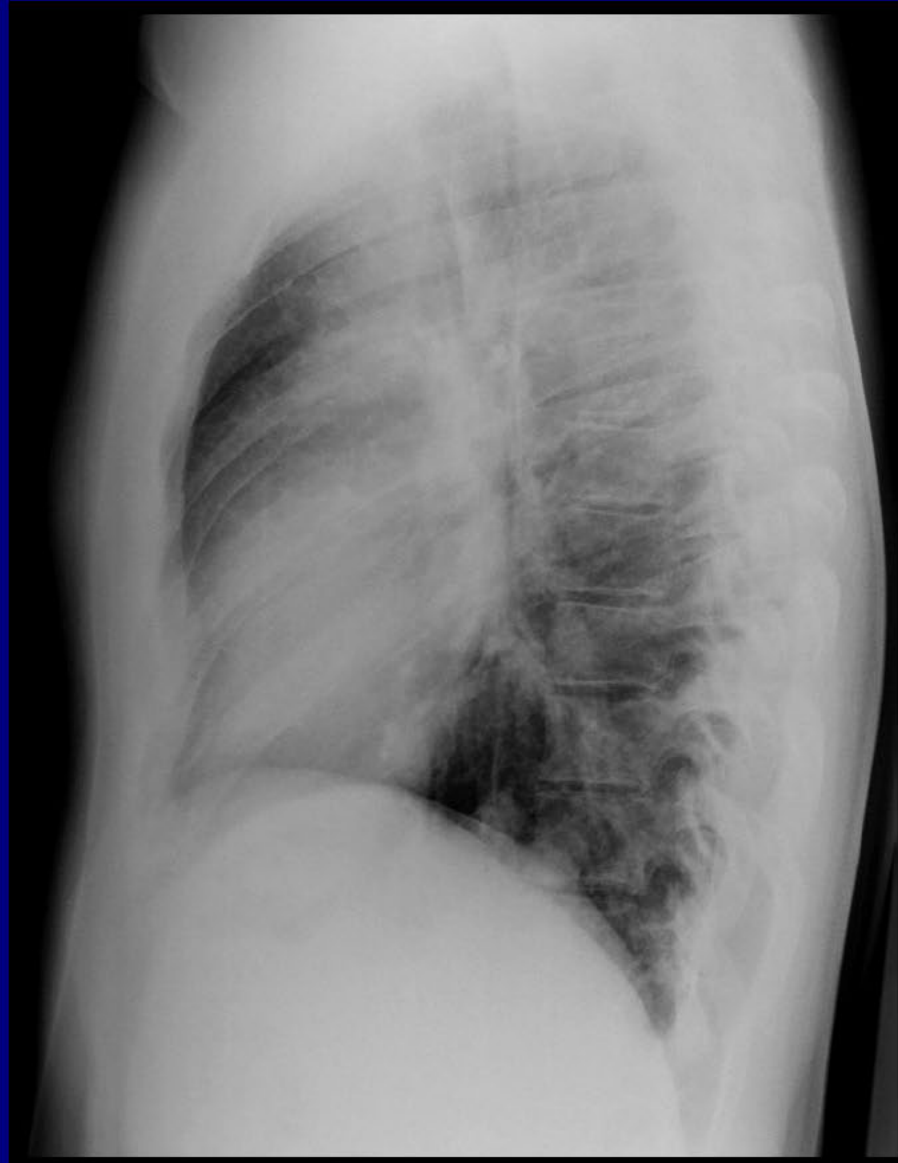


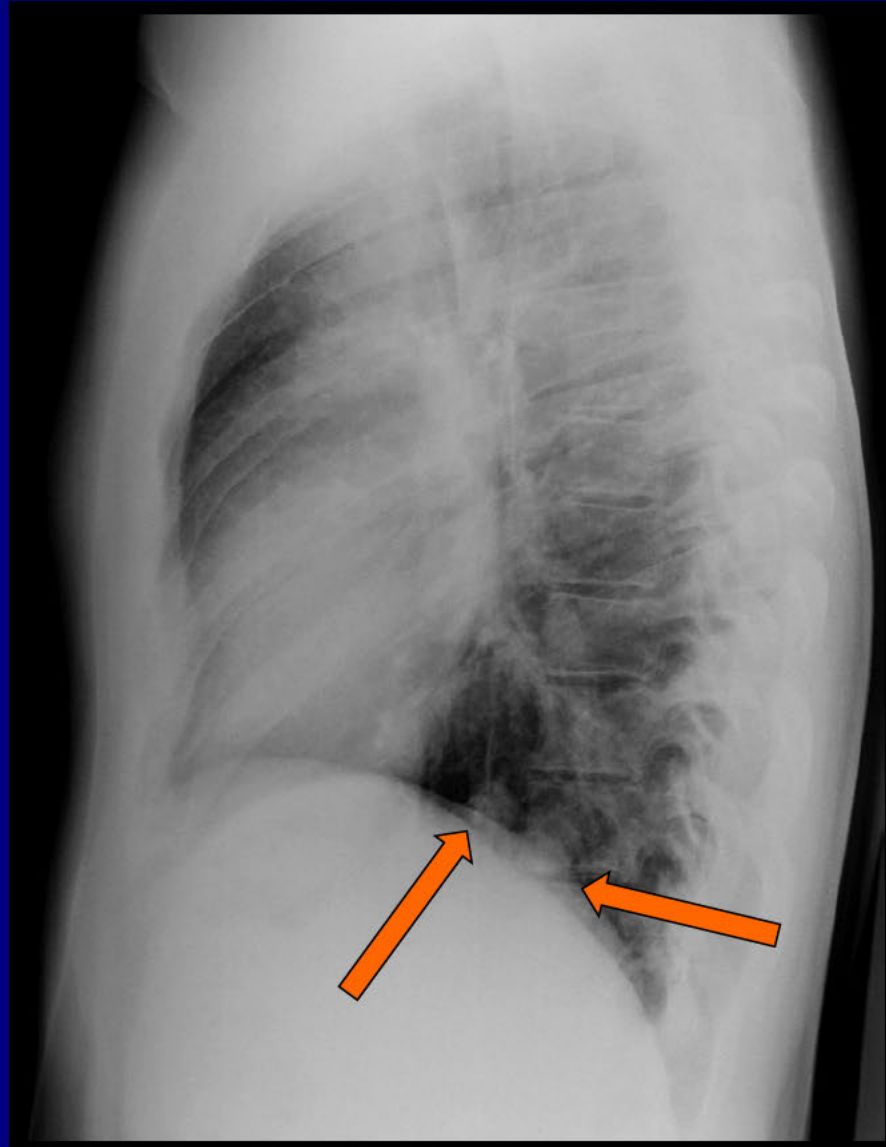



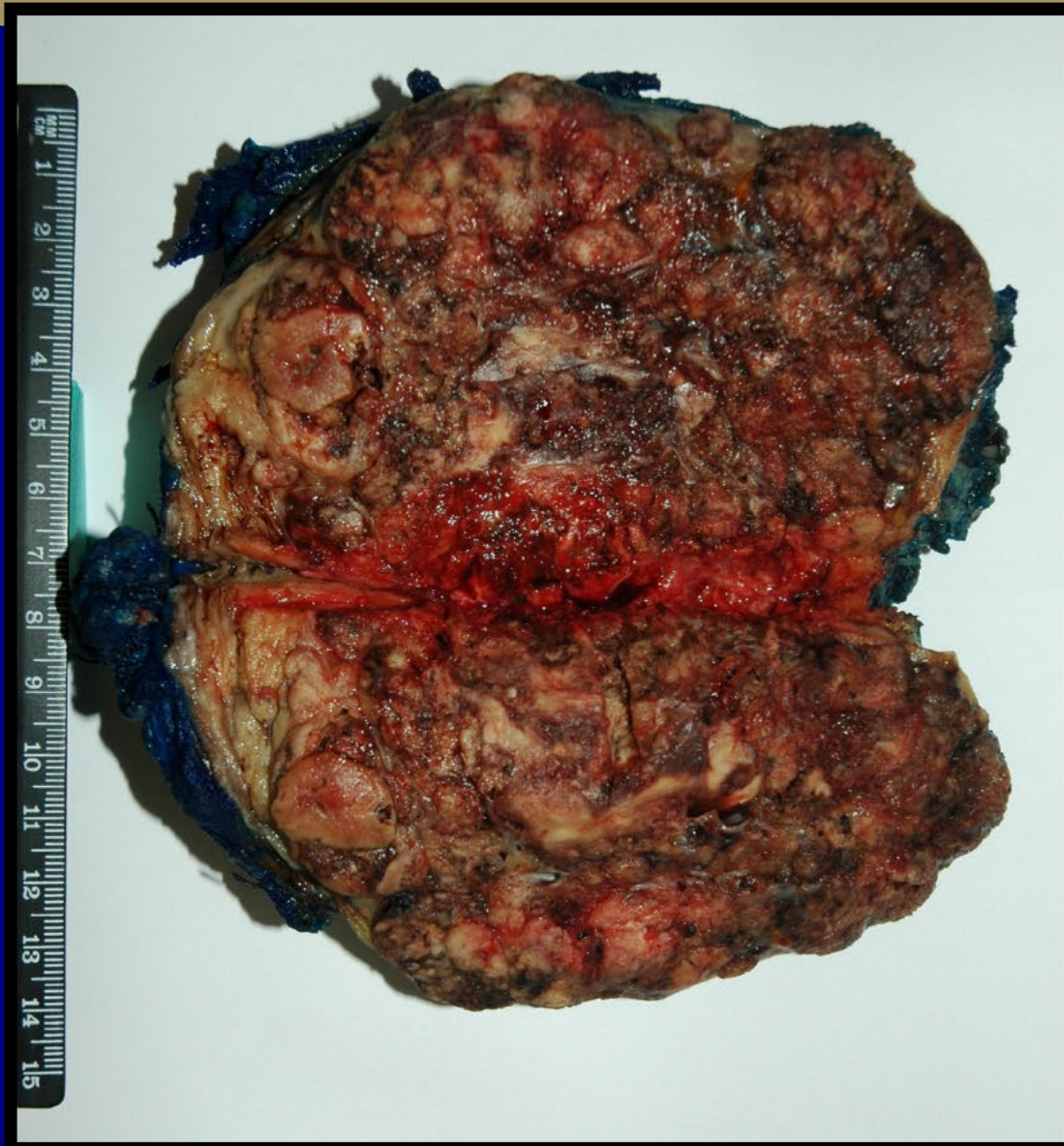
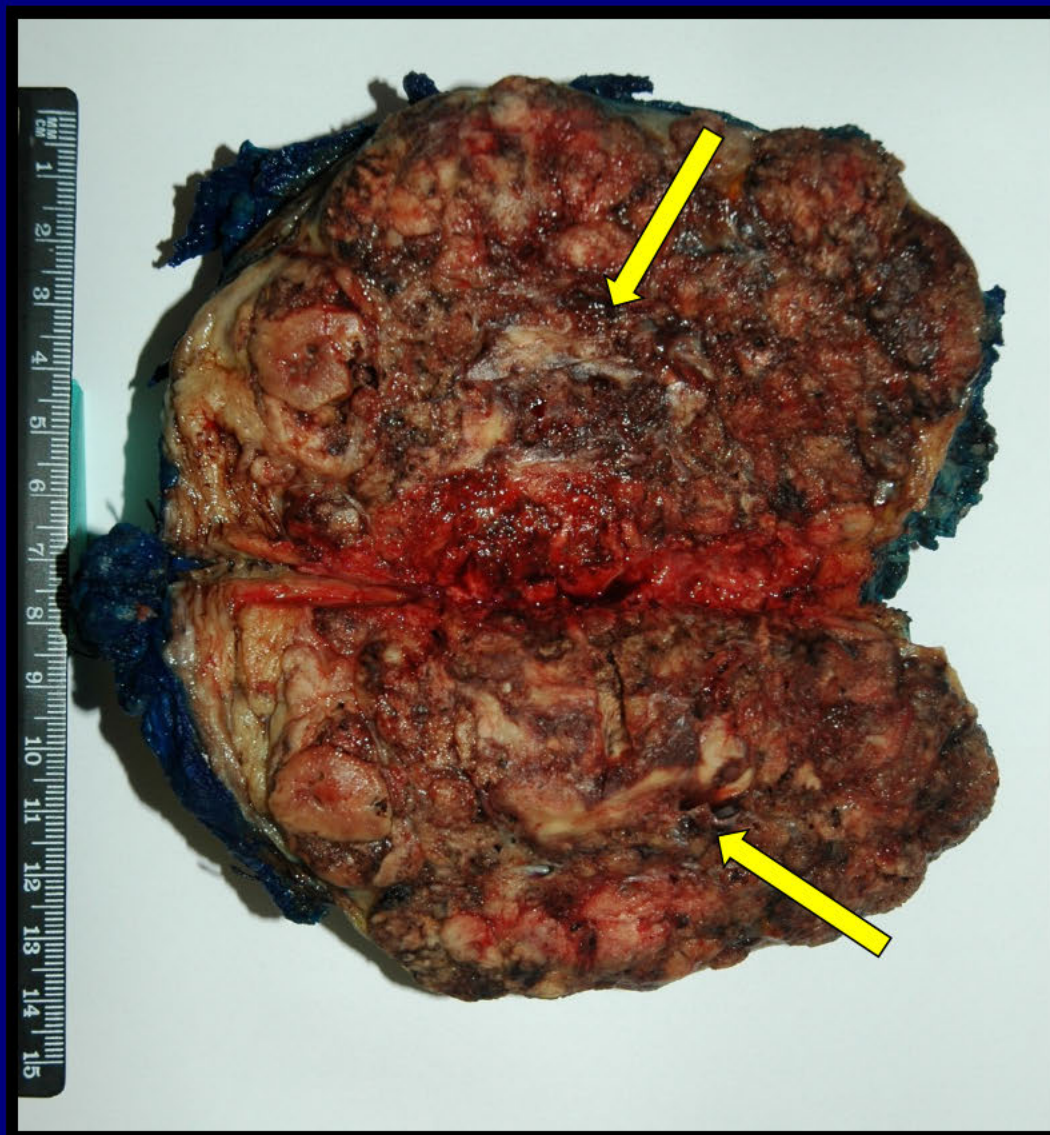


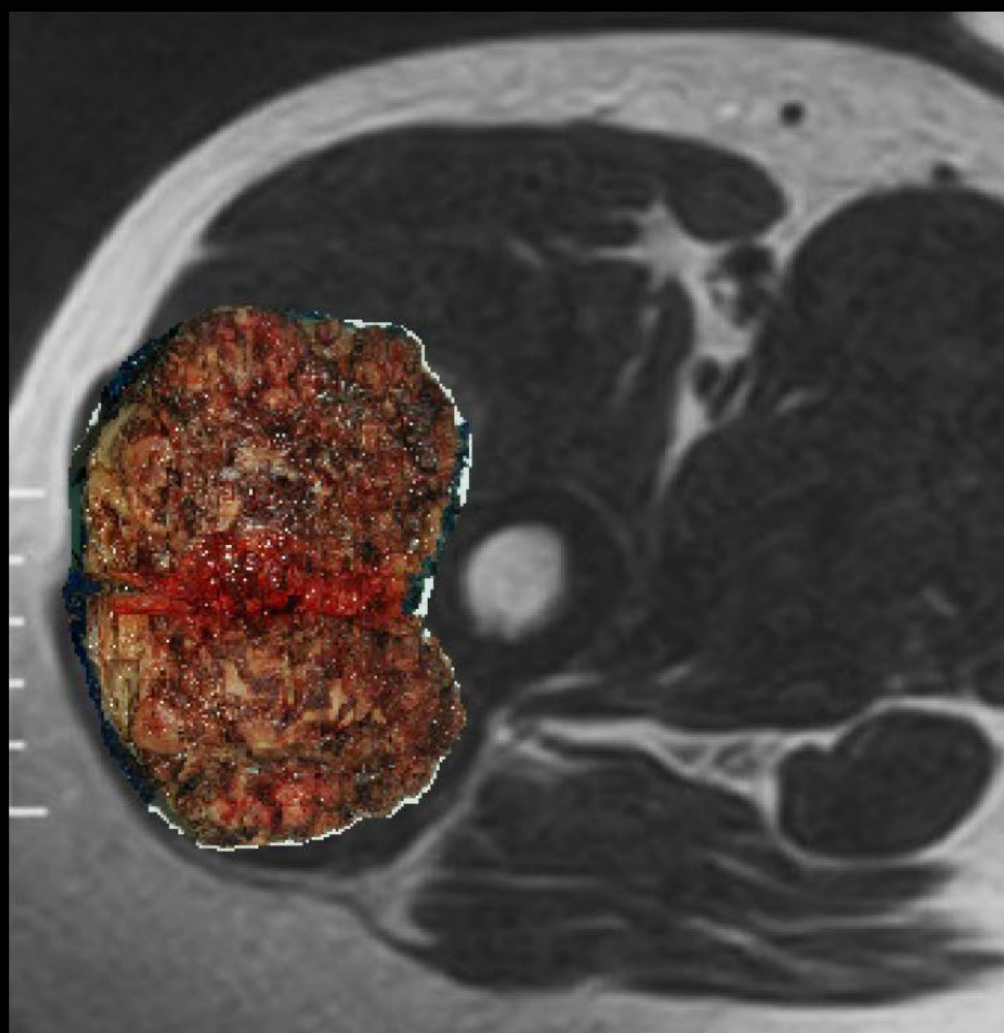
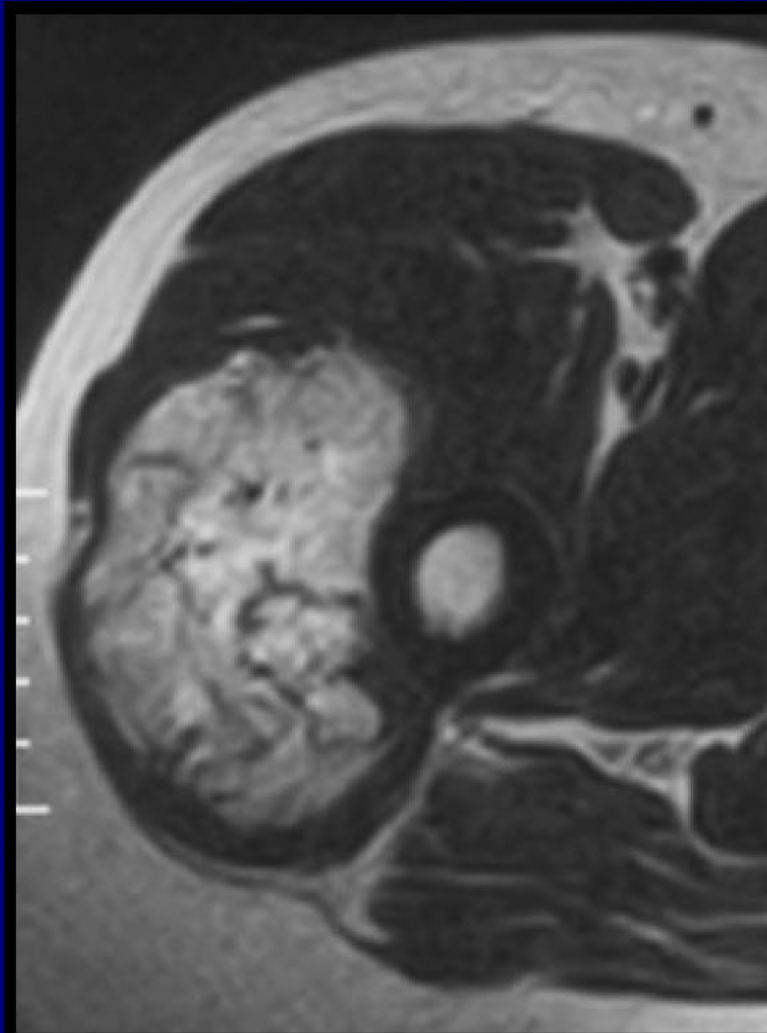


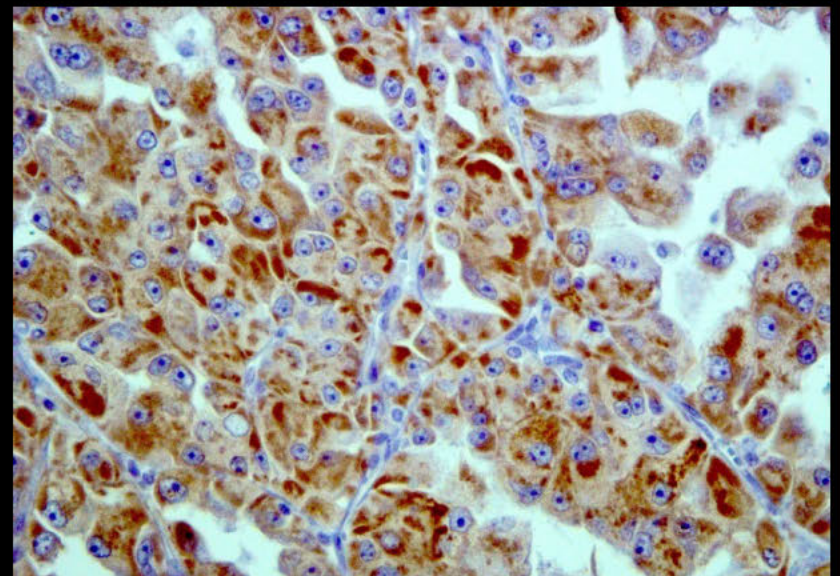
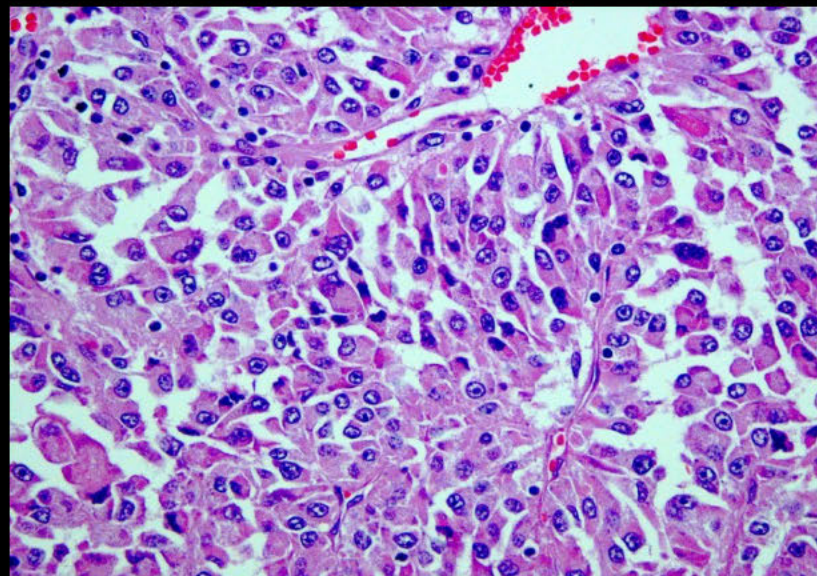
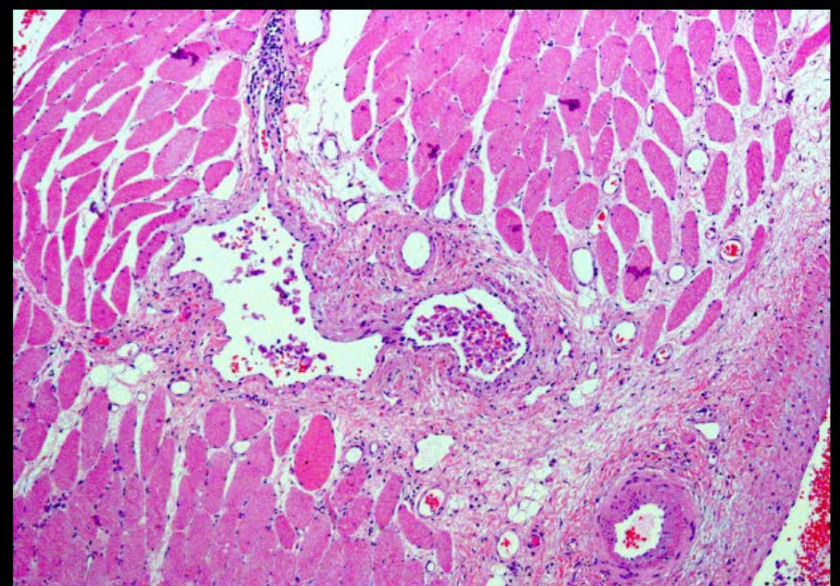
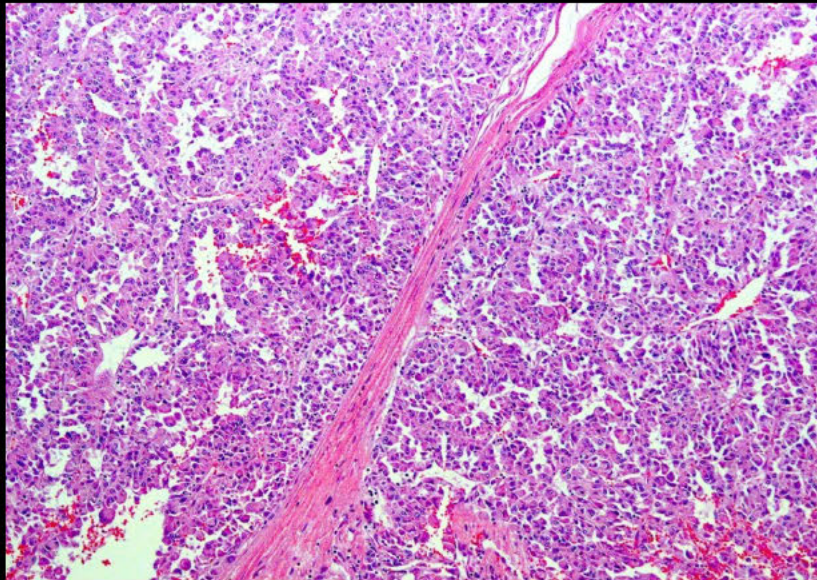


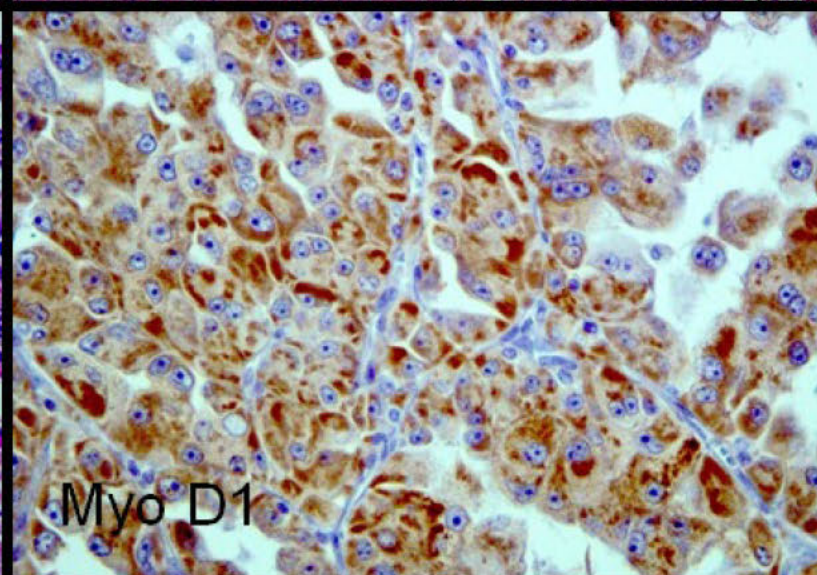
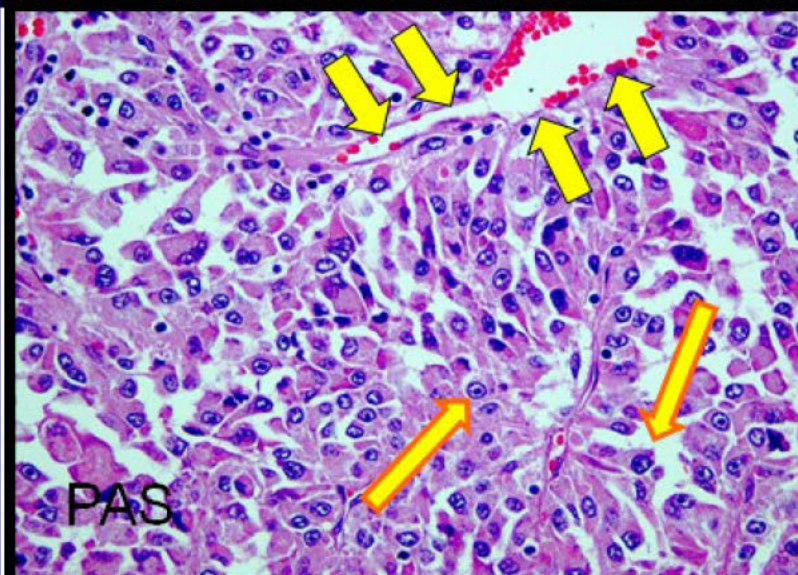
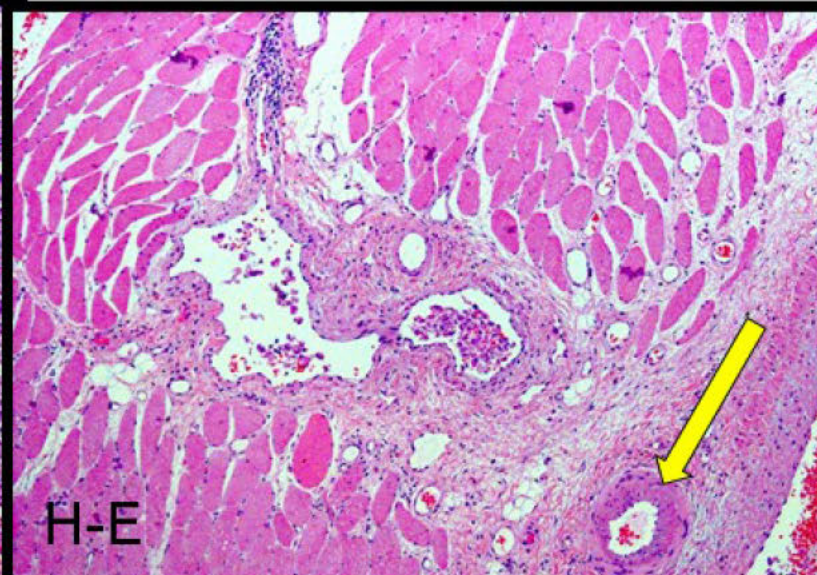
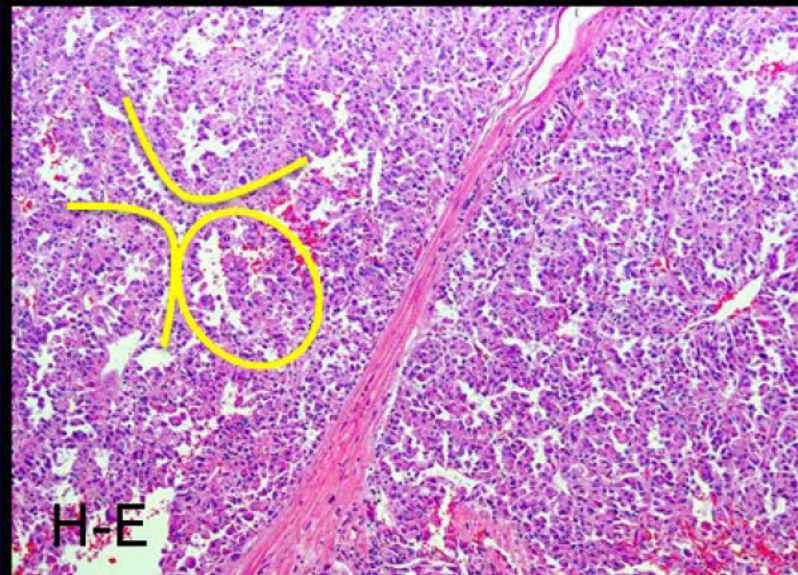












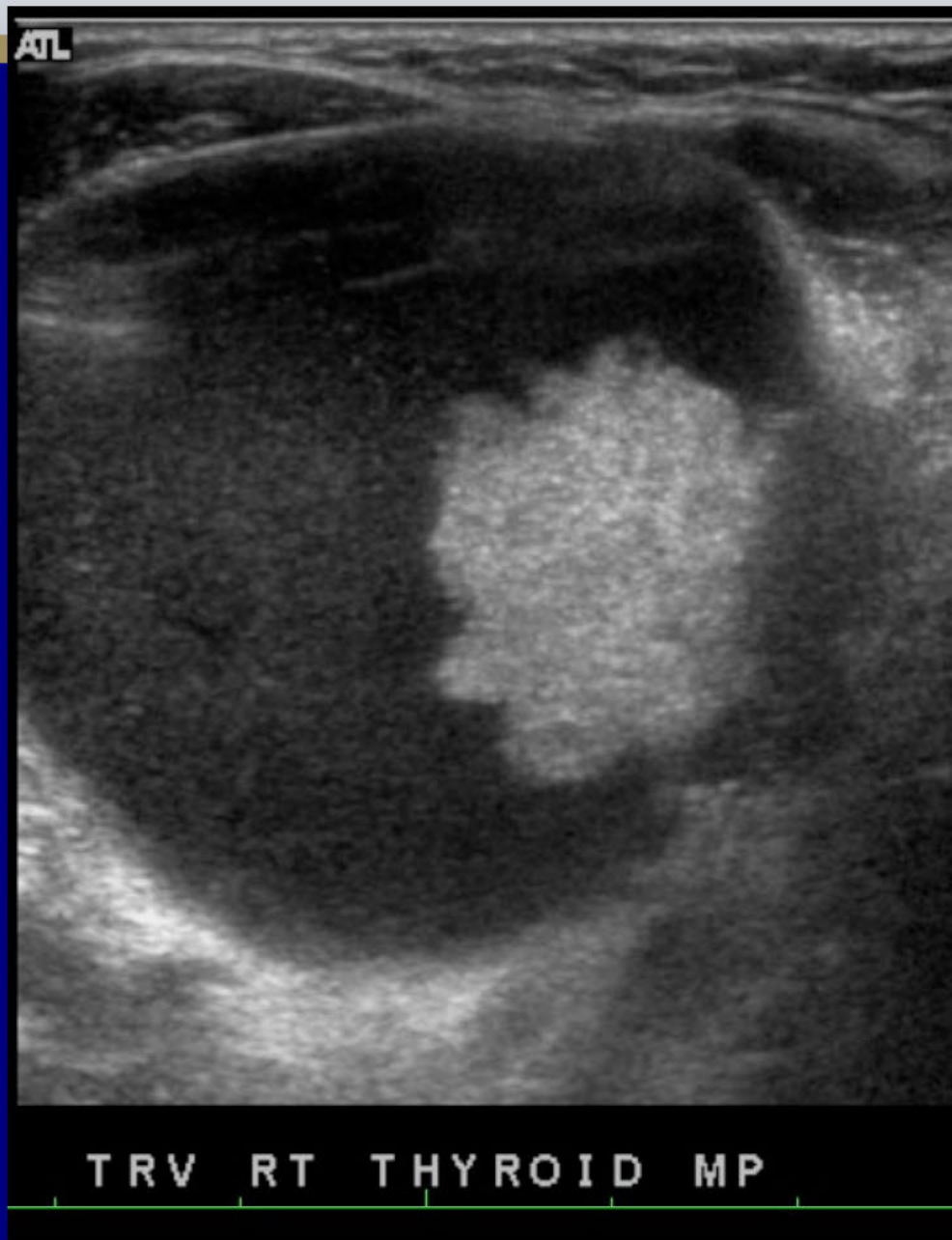
Diagnosis: Alveolar Soft Part Sarcoma

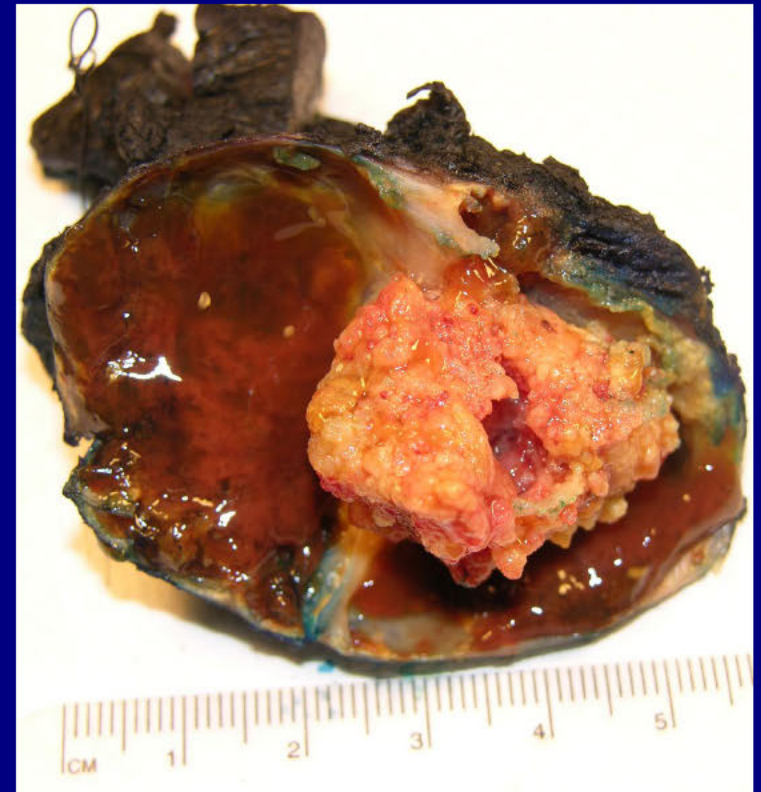
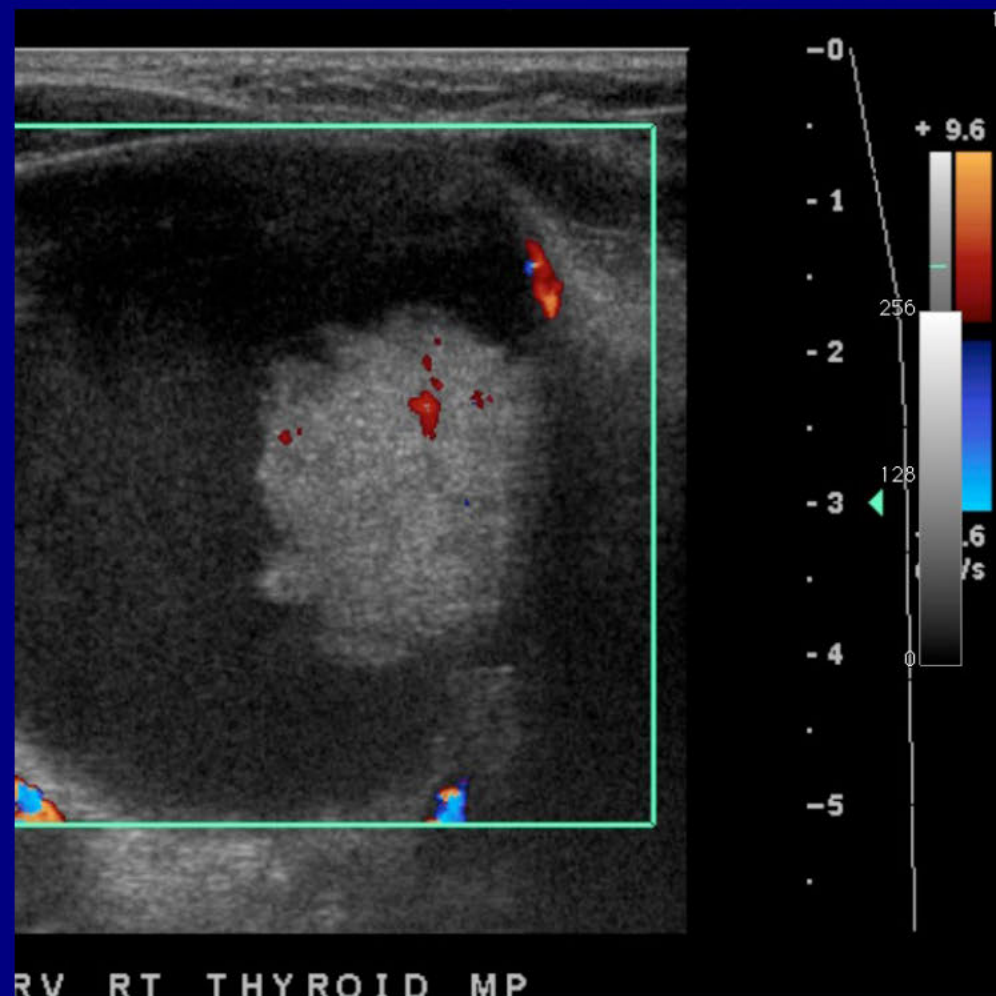
Malak Itani
American University of Beirut Medical Center
Beirut, Lebanon

Neuroradiology Best Case

History

52-year-old female with a history of a right-sided neck mass present for at least the past 2 years, which she stated had gotten noticeable larger over the past 6-12 months.



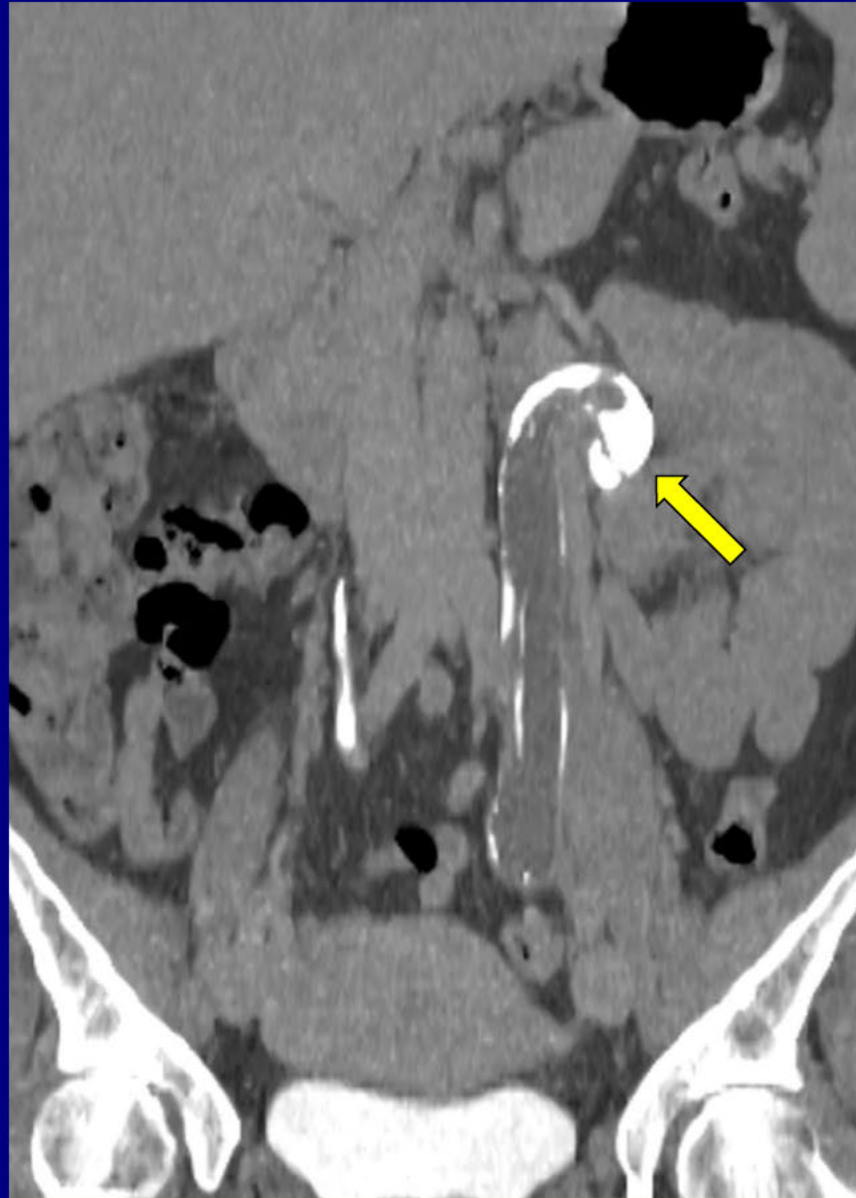


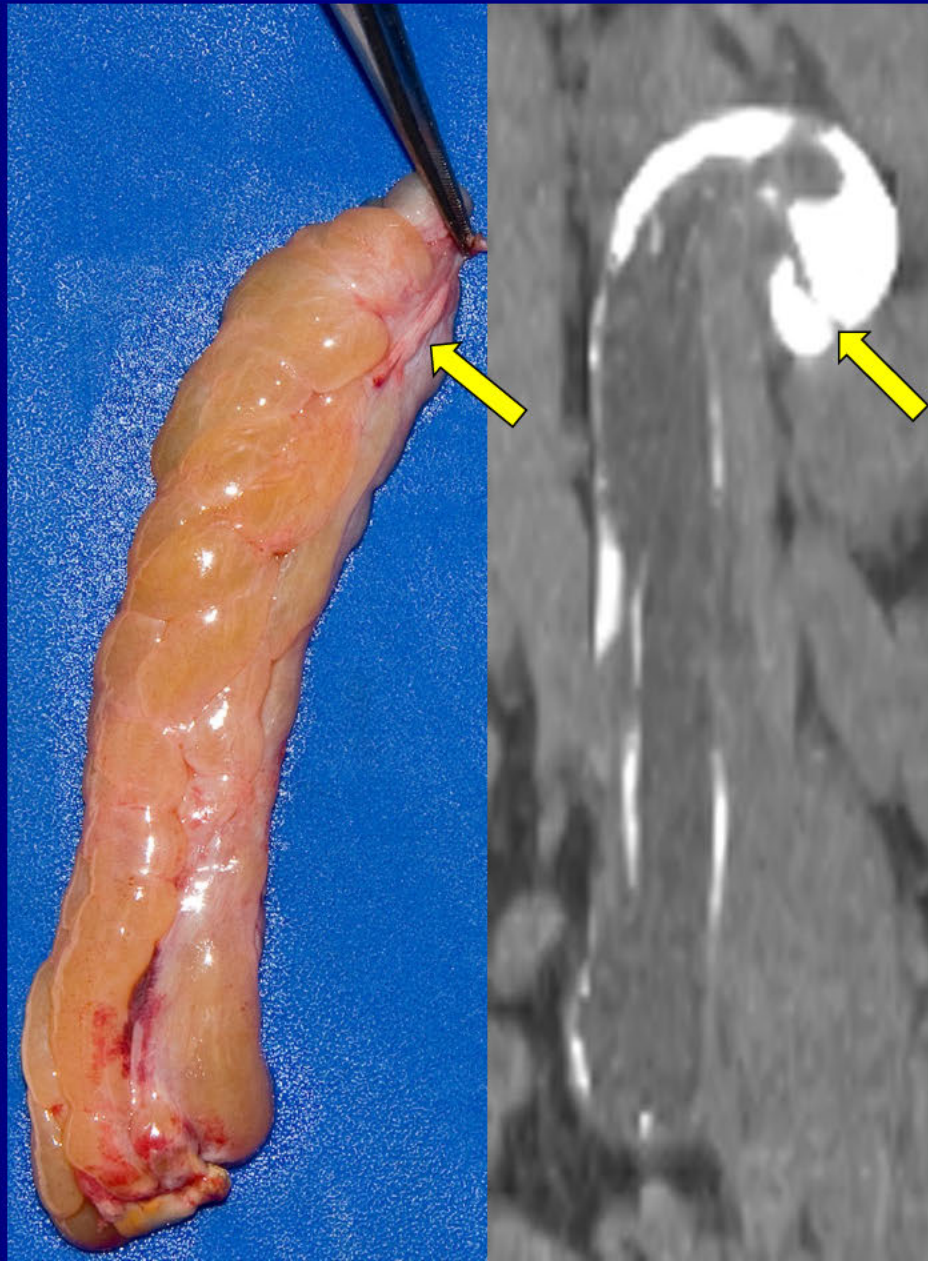
Papillary Thyroid Carcinoma

Resident: Migonne Morrell
LSU Interim Public Hospital
New Orleans, LA

Genitourinary Best Case

41-year-old female with
persistent left back and flank pain





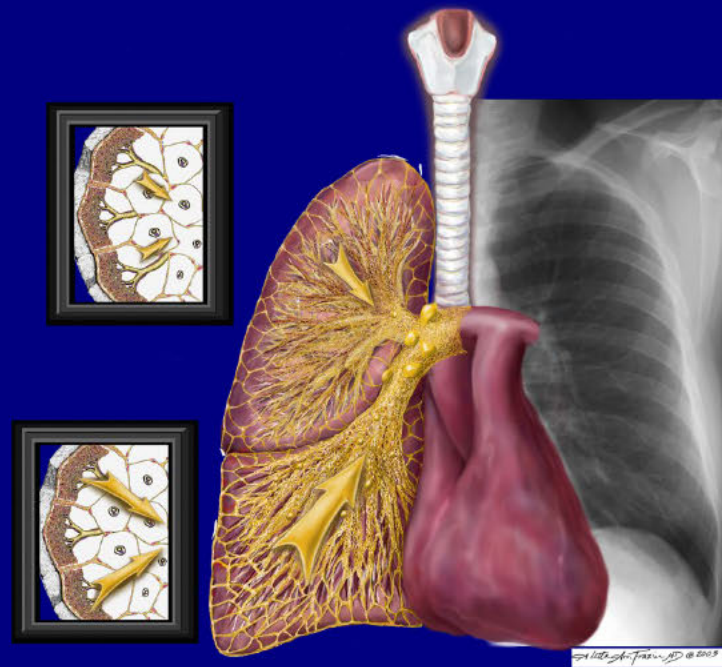
Ureteral Fibroepithelial Polyp

Dr. Evan Leitz

Virginia Mason Medical Center

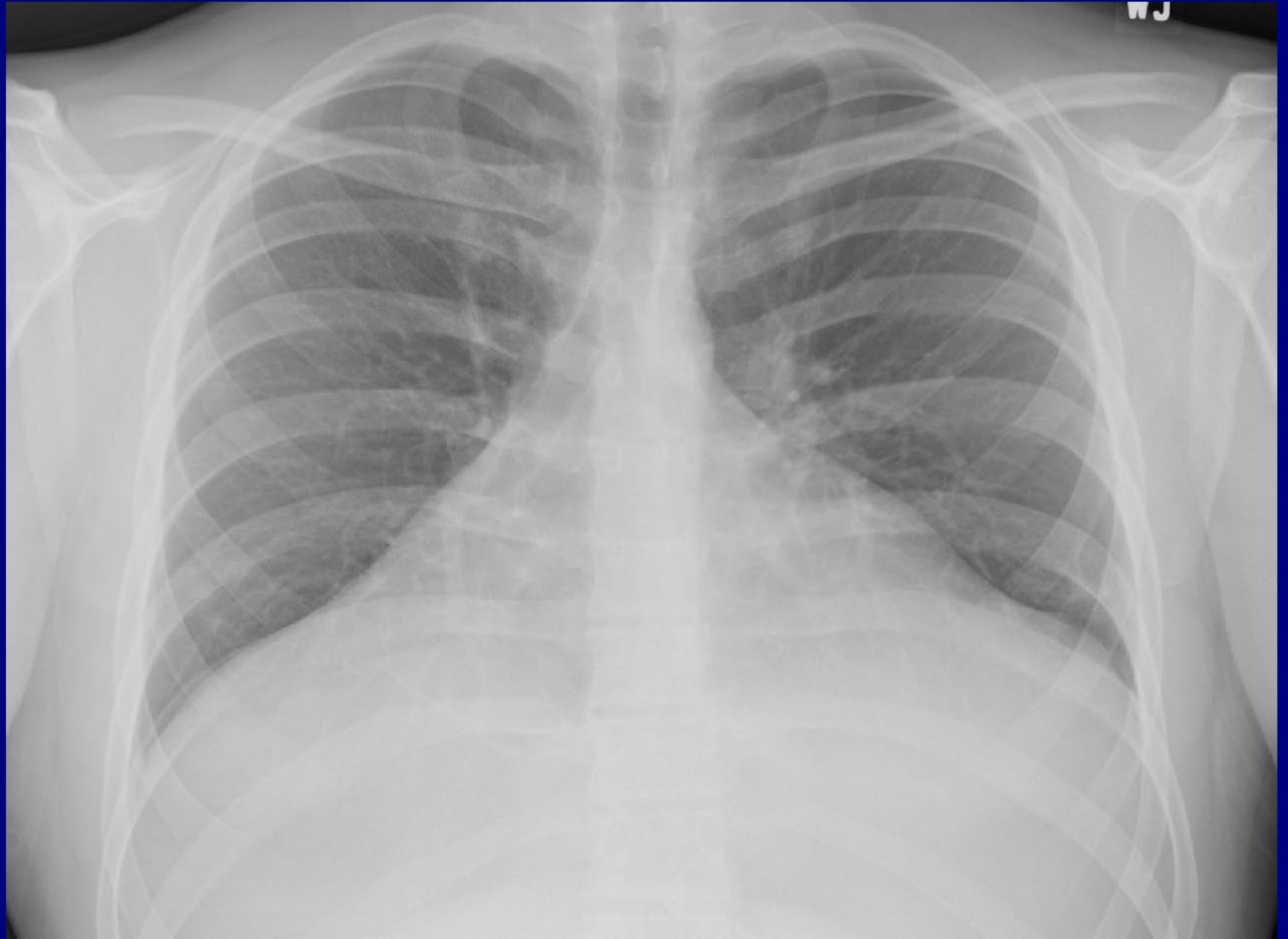Seattle, Washington, USA

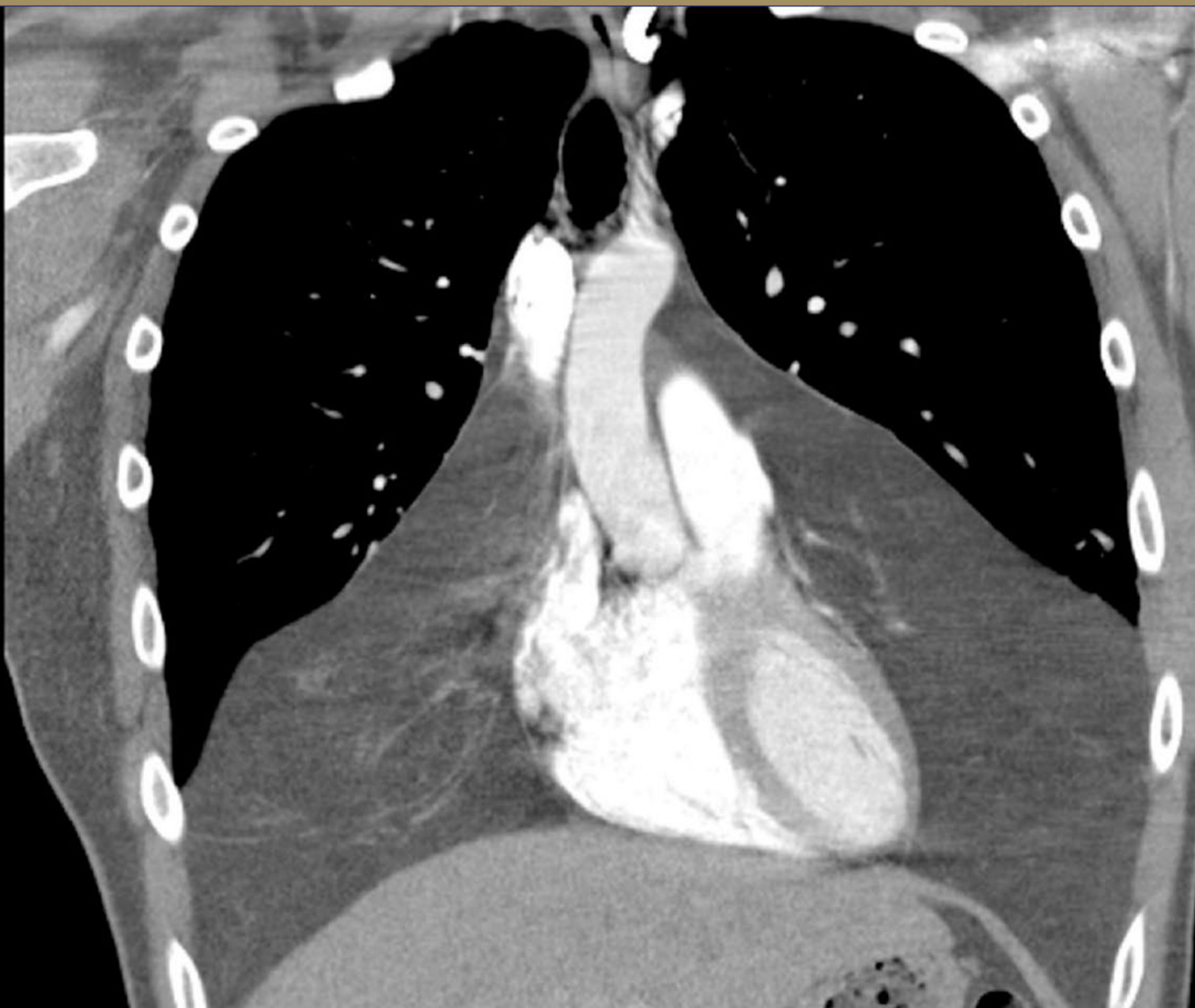PULMONARY AND MEDIASTINAL IMAGING

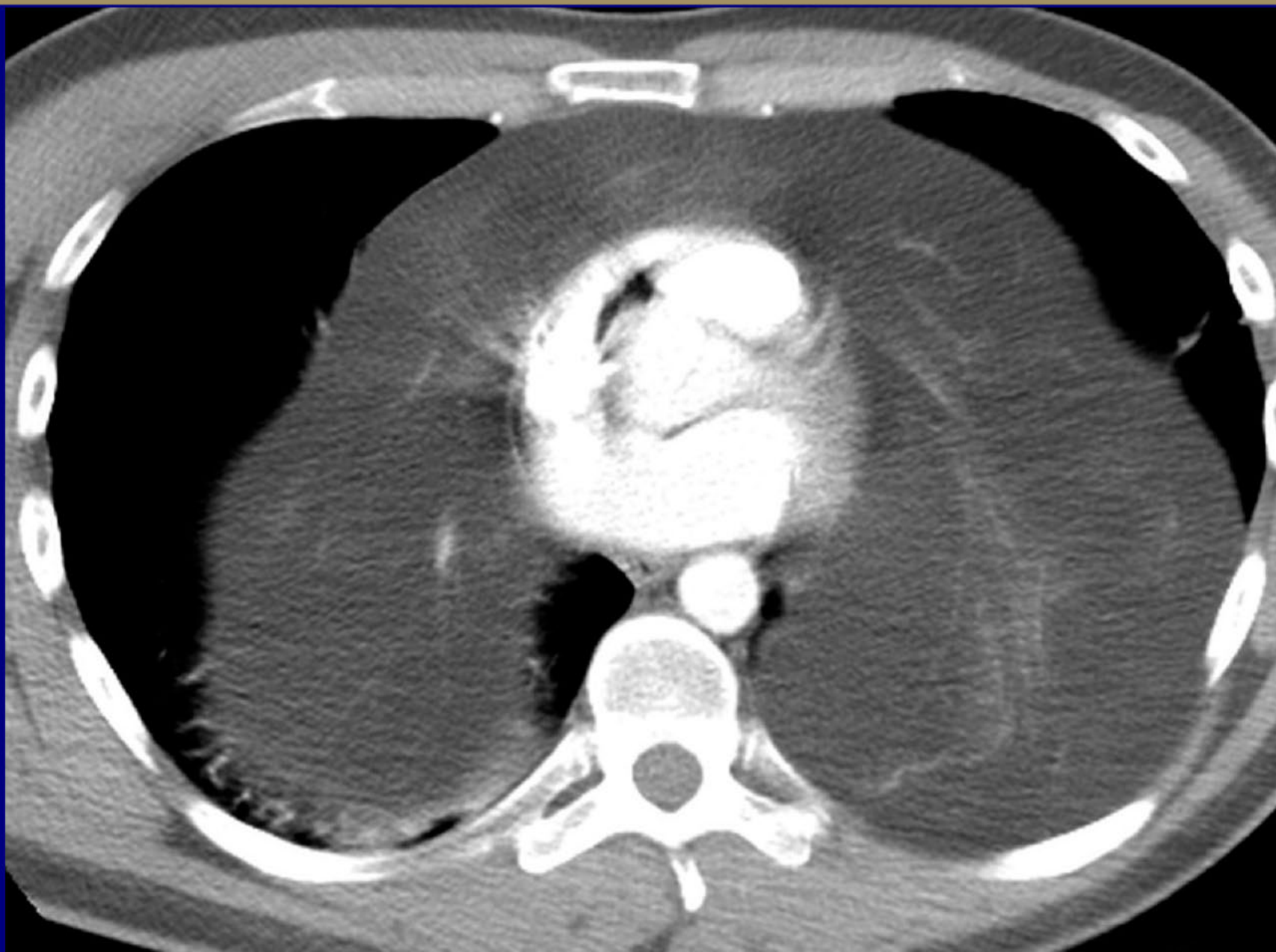


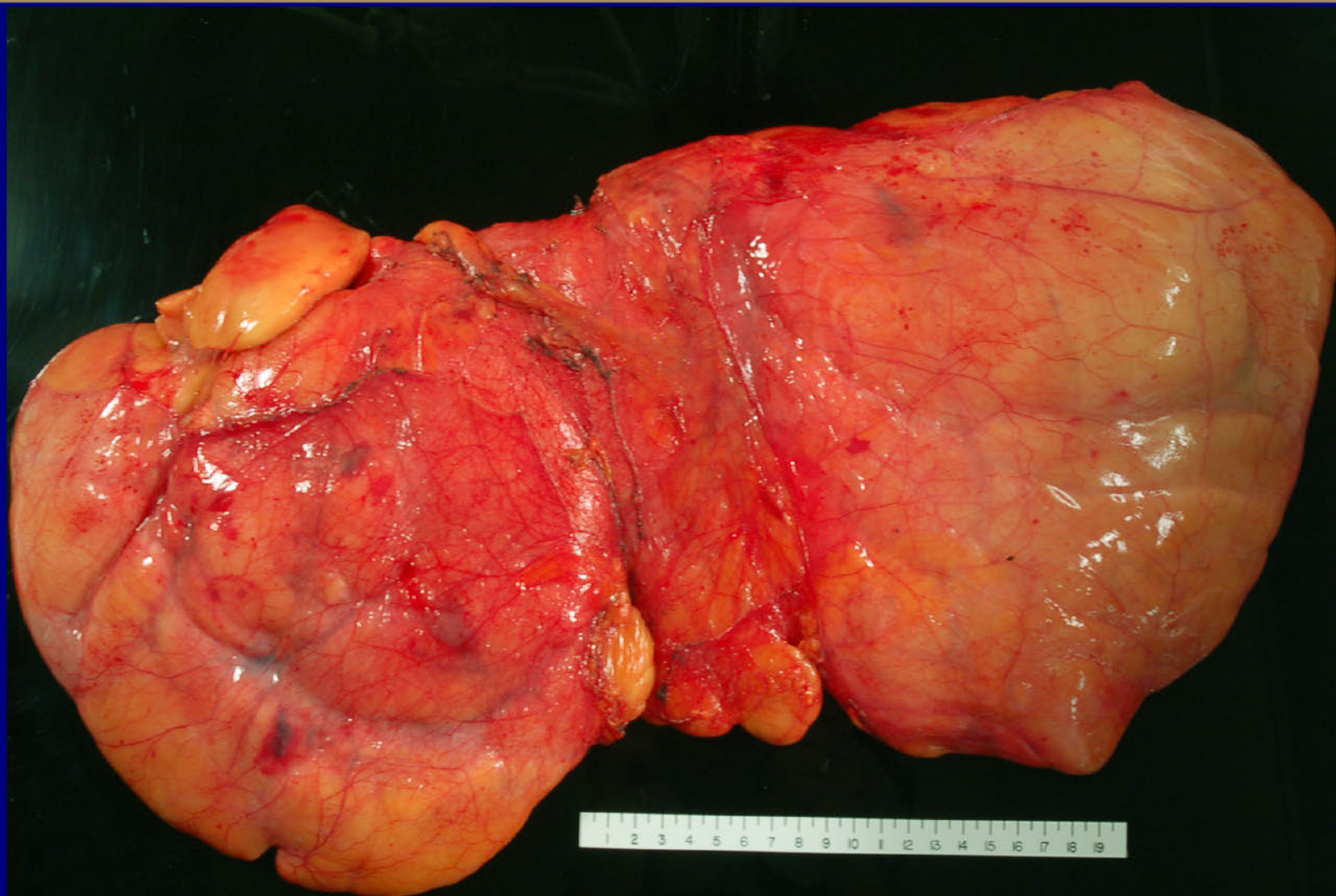
History

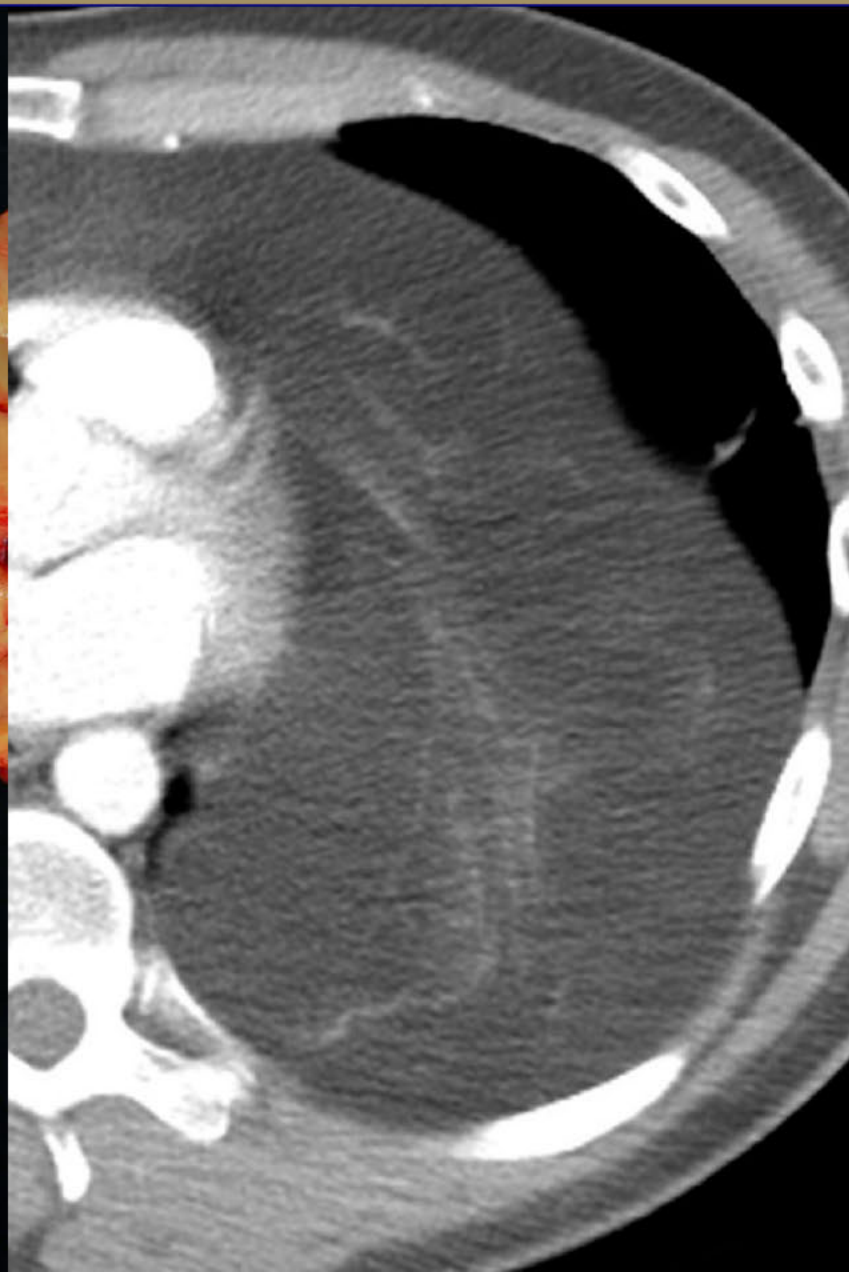
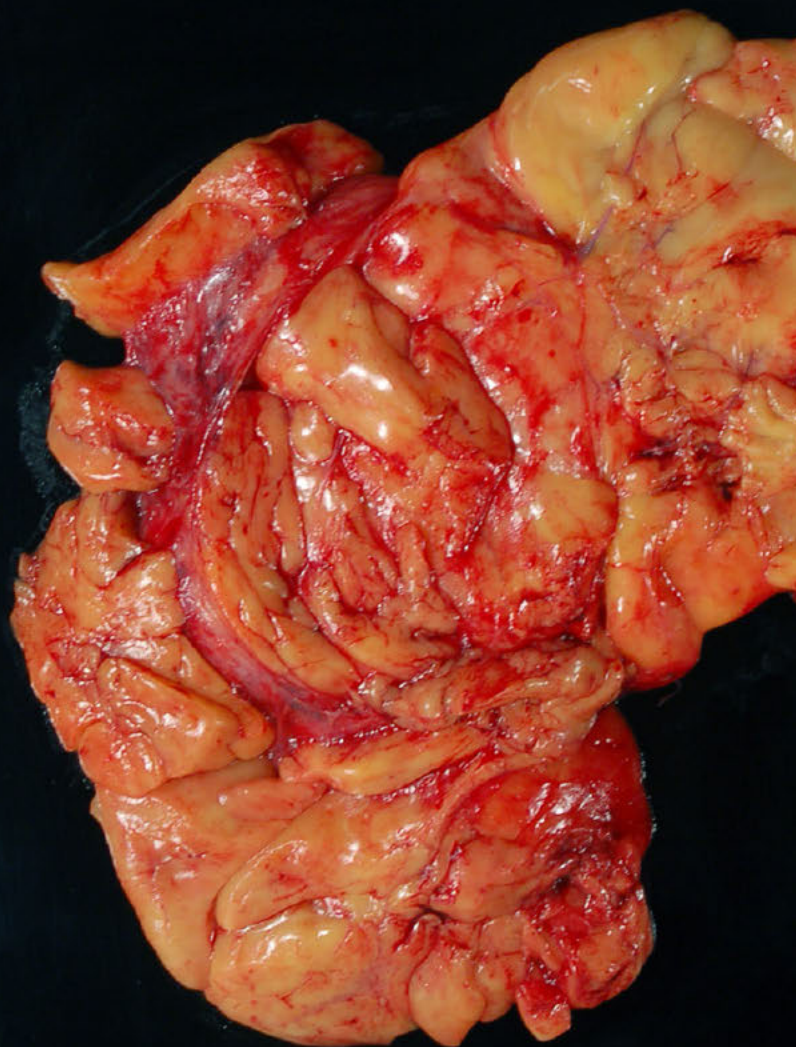
28 year old male with incidental finding after injury







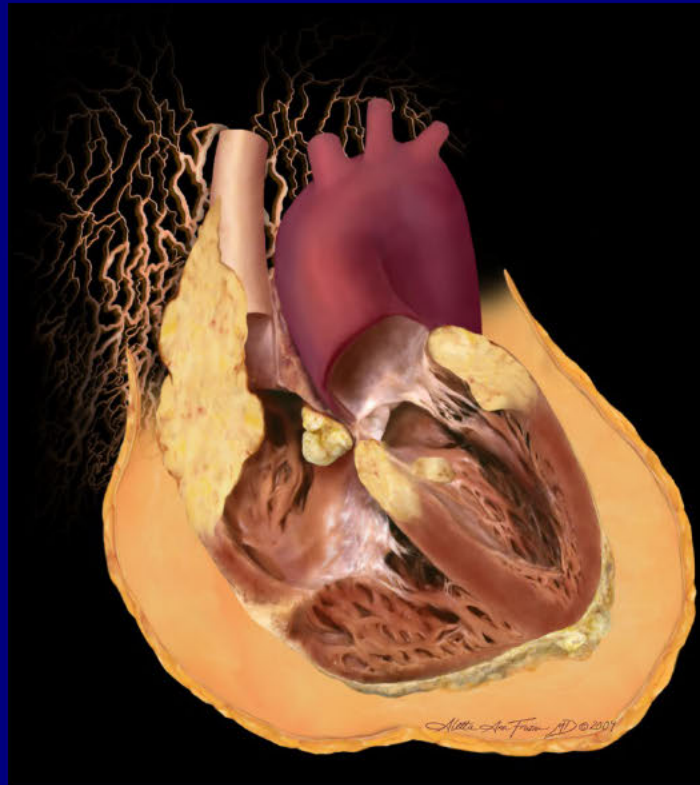




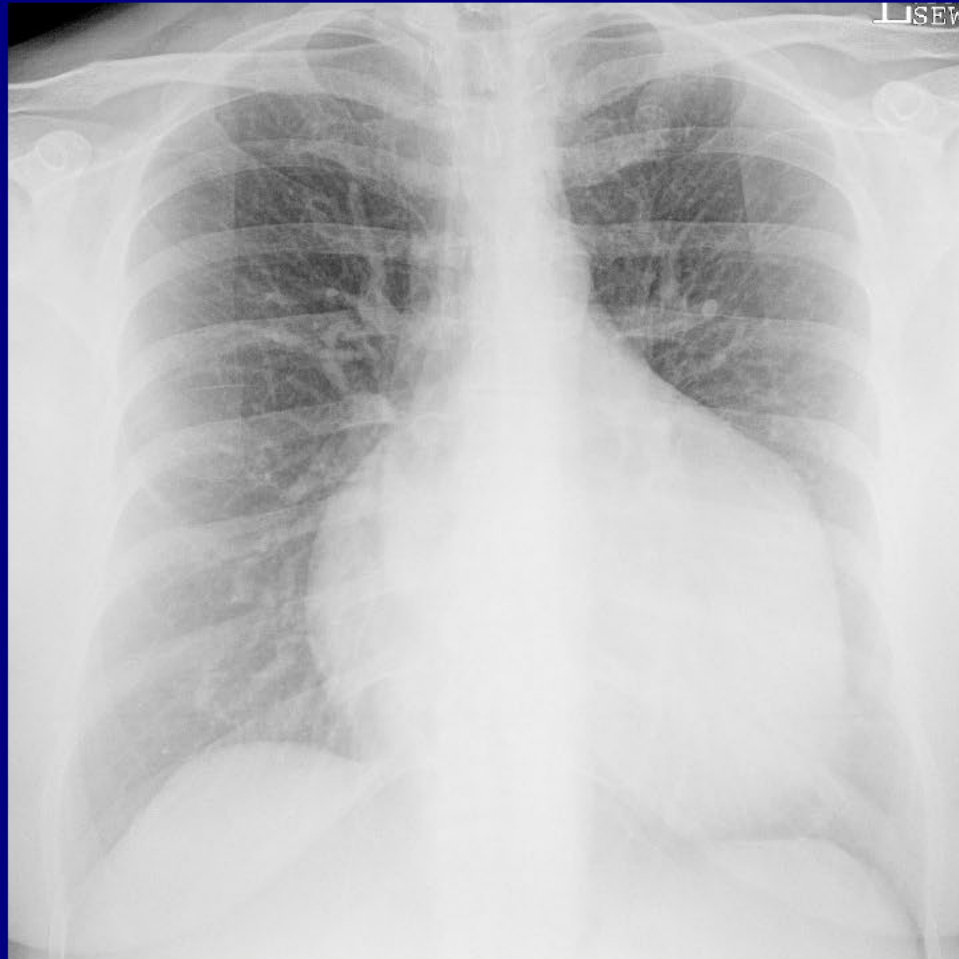Thymolipoma

John Socrates Scales, MD
University of Florida

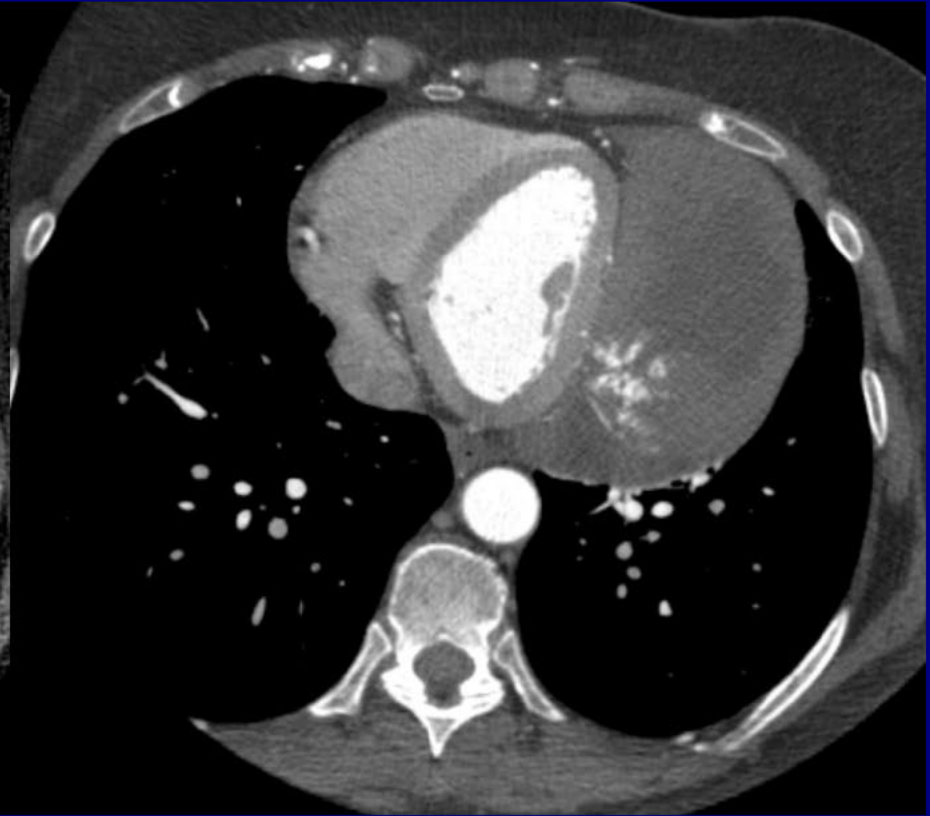
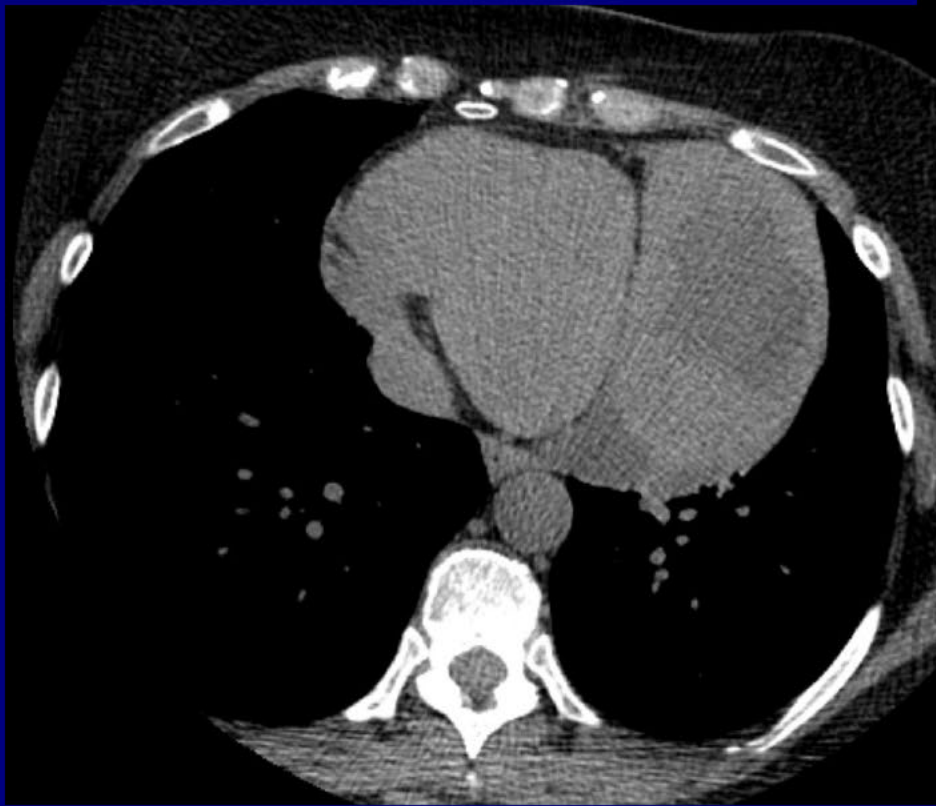
Cardiovascular Imaging



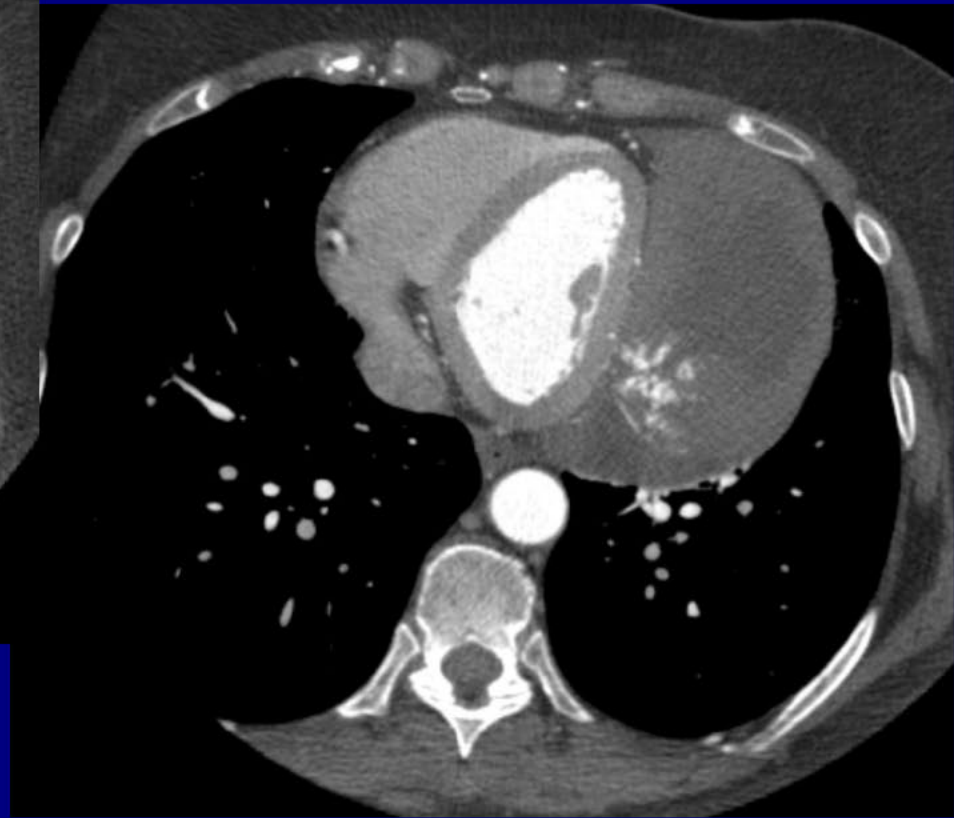
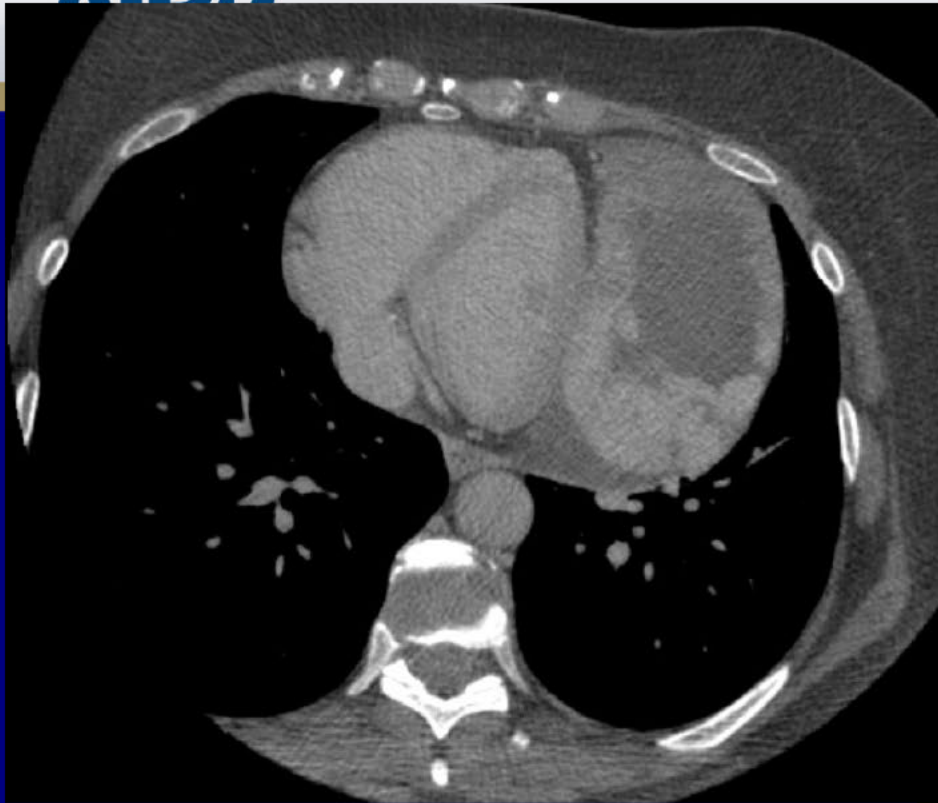
History



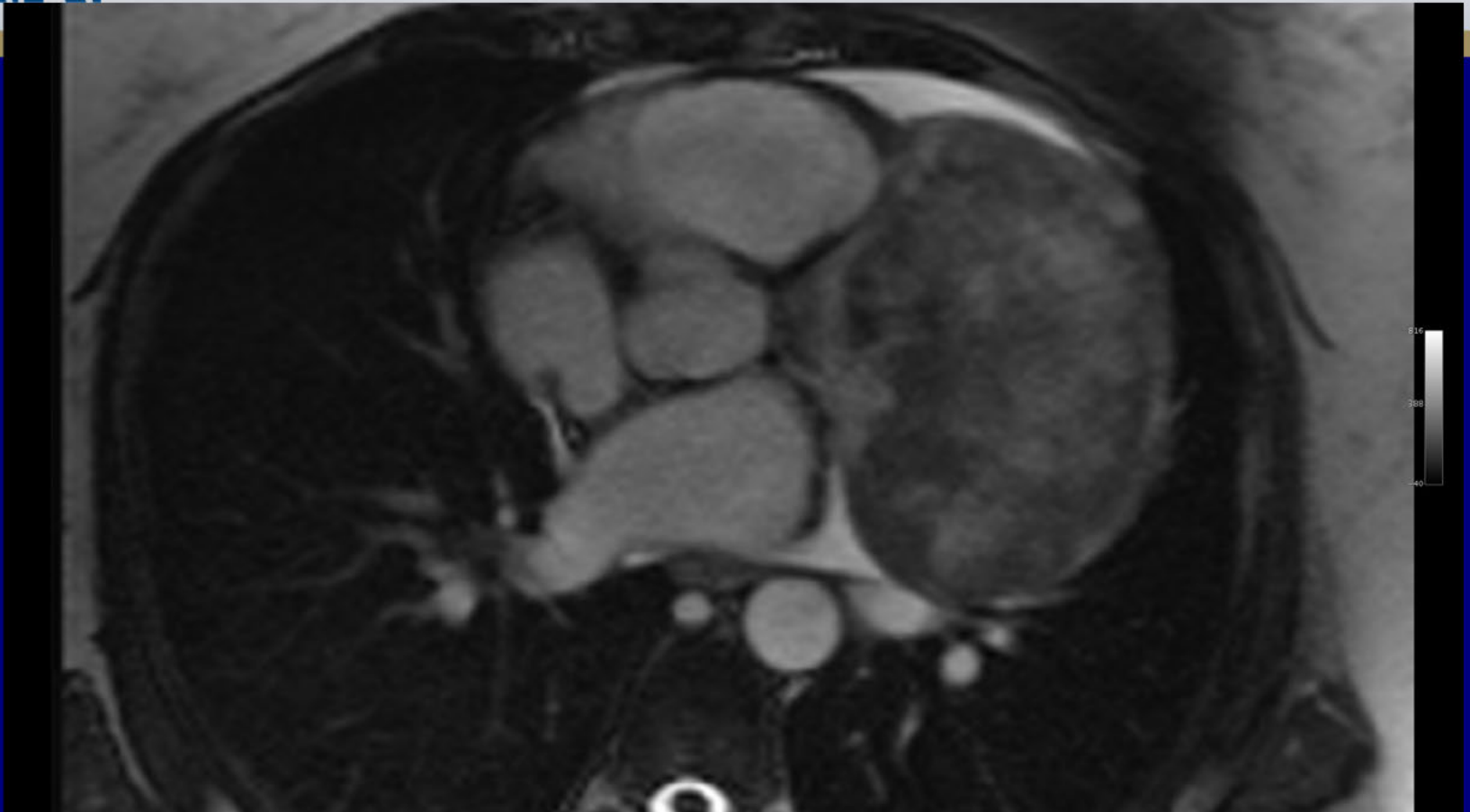58 yo female with chest xray abnormality detected during ER work-up for a macular rash. No significant past medical history



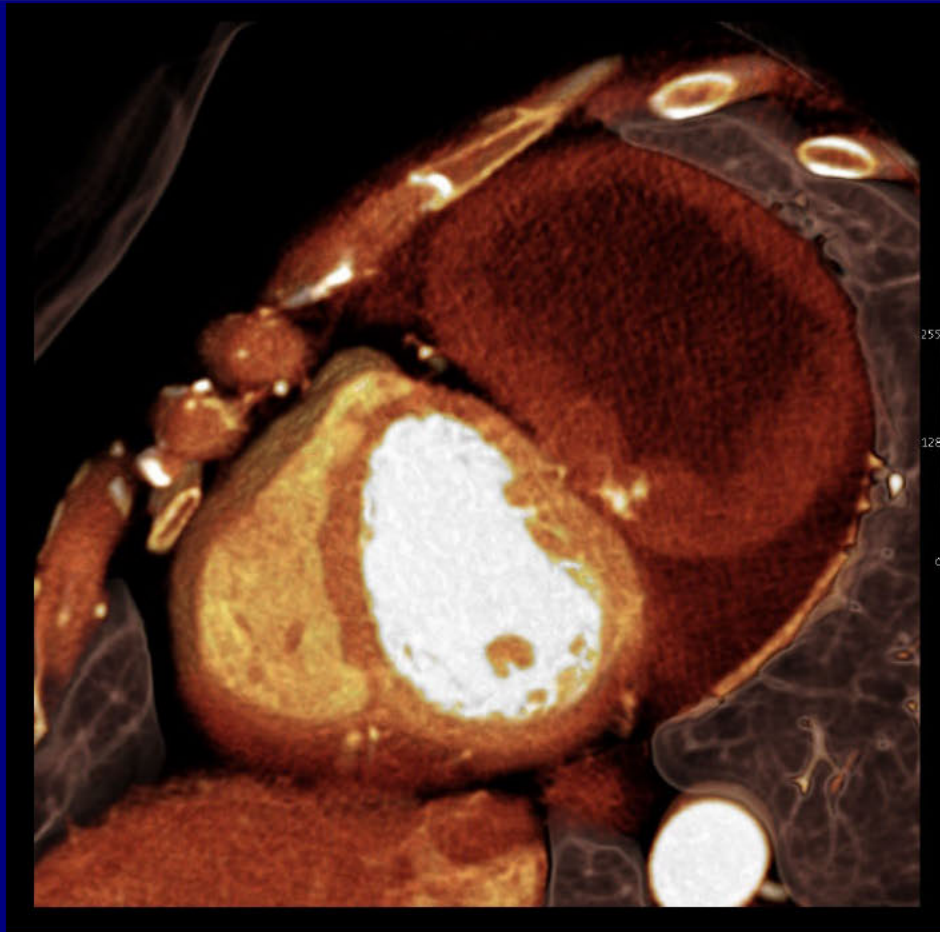
ECG-gated CTA (pre- and post-contrast) demonstrates a thick-walled soft tissue mass which appears centered within the pericardial cavity. This lesion produces mass effect upon the adjacent left ventricle. Post-contrast image shows peripheral arterial enhancement of the lesion.



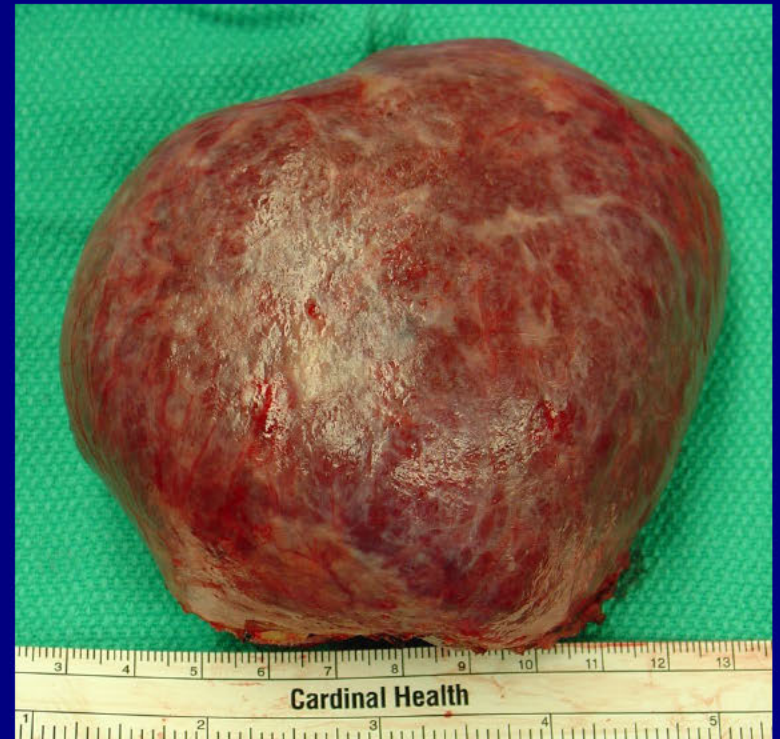Delayed post-contrast image (left) shows slow, progressive peripheral enhancement of the lesion.



An axial steady state free precession (SSFP) MR cine at the level of the aortic valve shows a fixed, heterogeneous soft tissue mass which arises from the visceral pericardium. The mass extends into the pericardial cavity and is surrounded by a small pericardial effusion.



3D reconstruction from cardiac CTA



Gross resected specimen:

Cardiovascular: Best Case

Pericardial lymphangioma

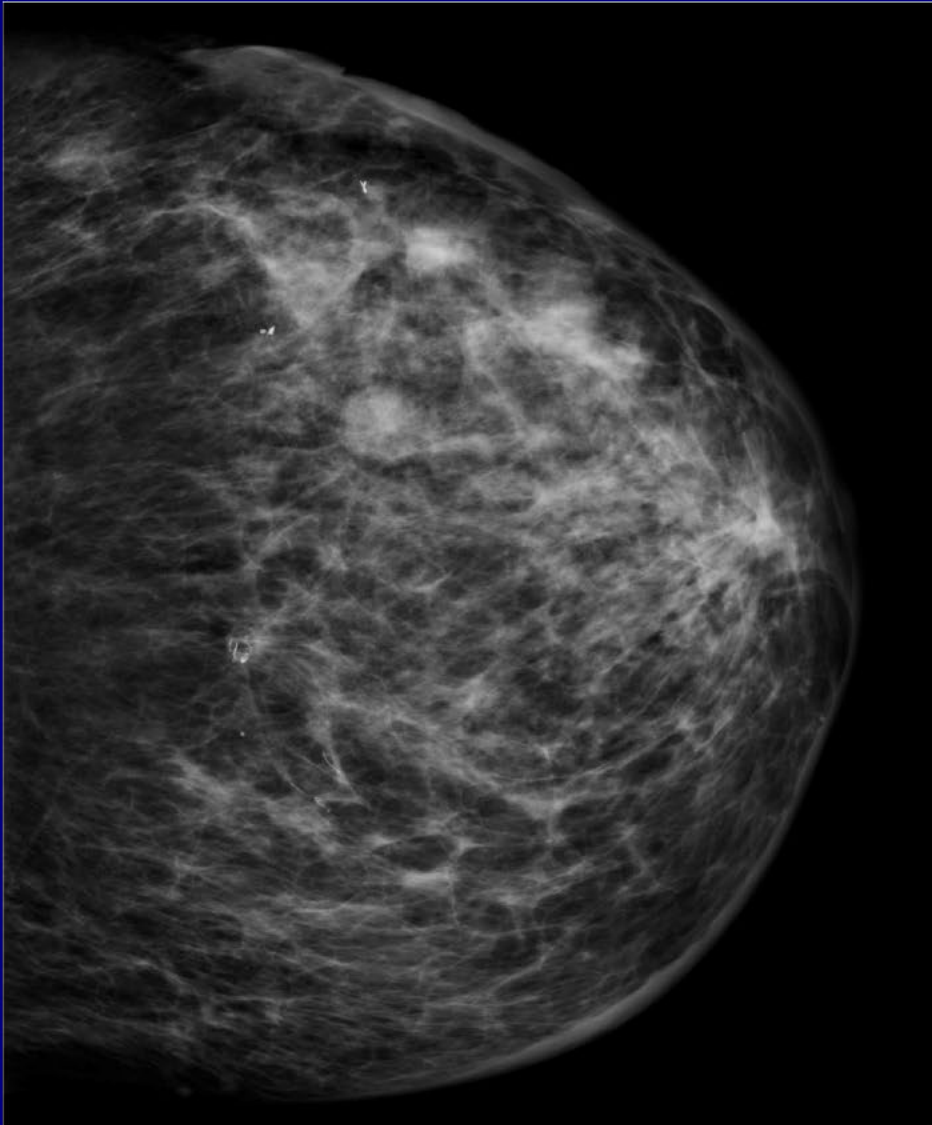
Contributor:

Thomas Estes, MD

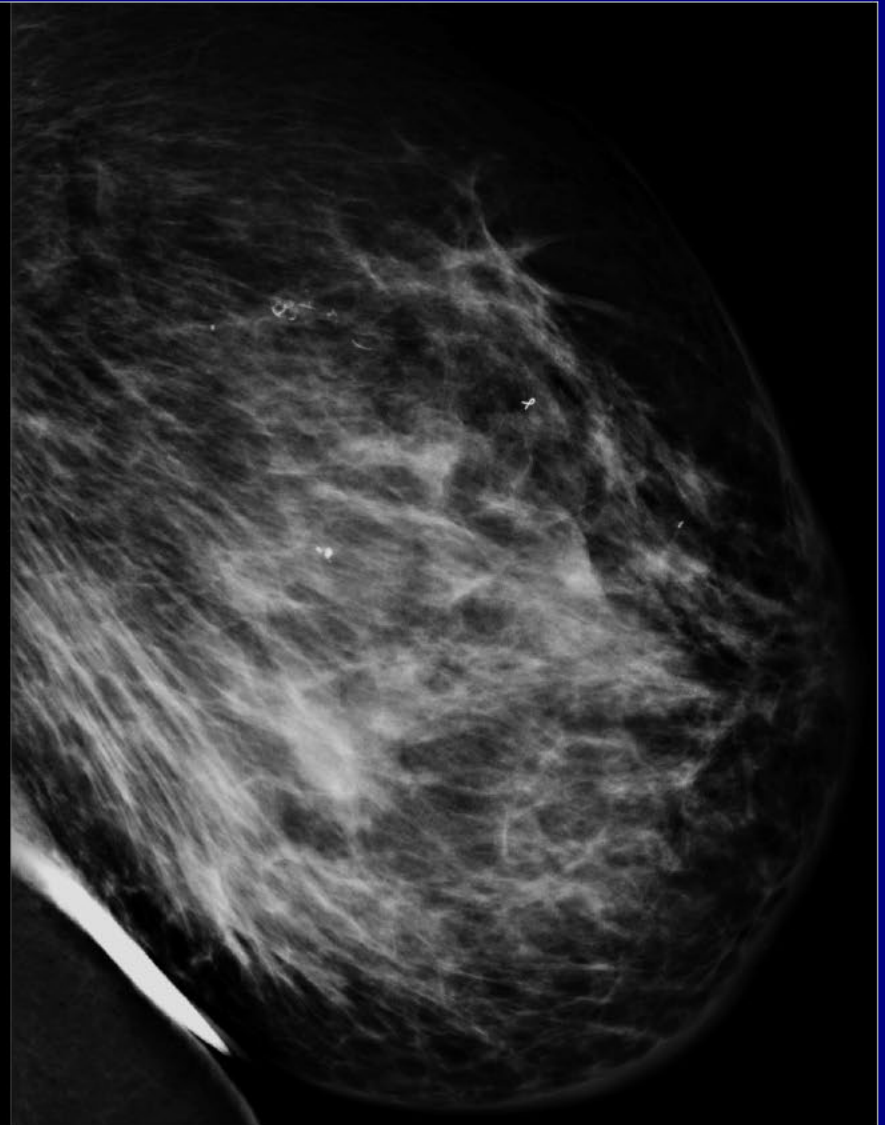
Wake Forest University Baptist Medical Center
Winston-Salem, North Carolina

Breast Best Case

64 year old female s/p resection of a left breast invasive ductal carcinoma in 2003 followed by XRT and chemotherapy . She now presents with "bruising" of the lateral aspect of the left breast with no apparent trauma. She then developed bleeding ulcers at the outer aspect of her left breast.

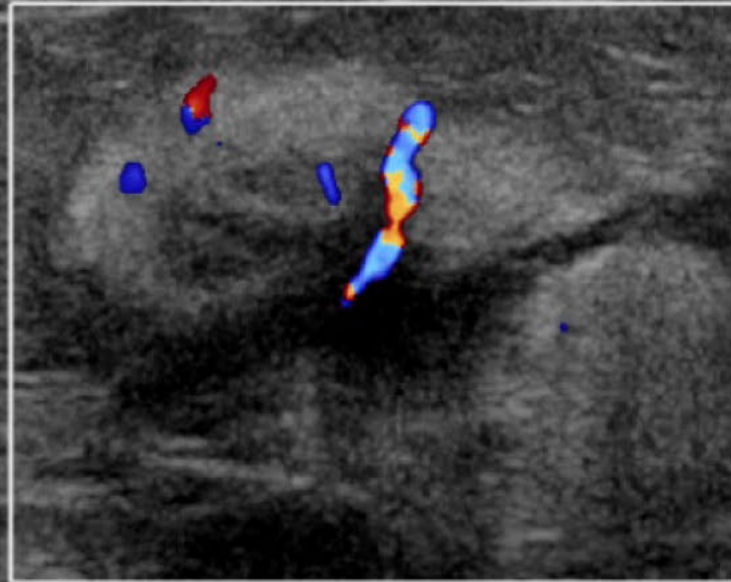


CC



ML

P



Lt Breast 3:00 7CM Sag

DM

Image size: 512 x 512
View size: 1200 x 1200
WL: 269 WW: 593

A

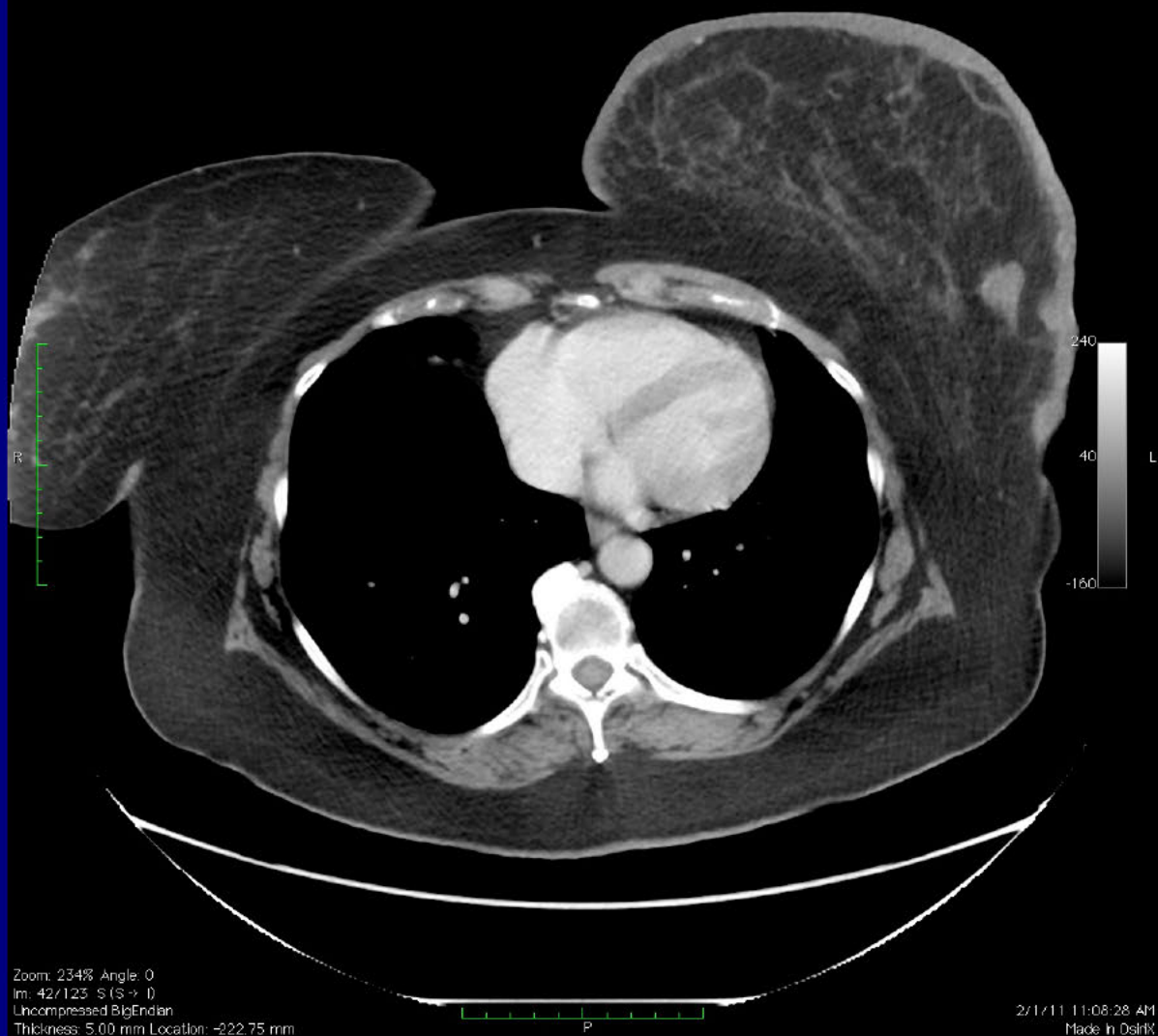
-(-)
localizer - Localizers
5617303
I

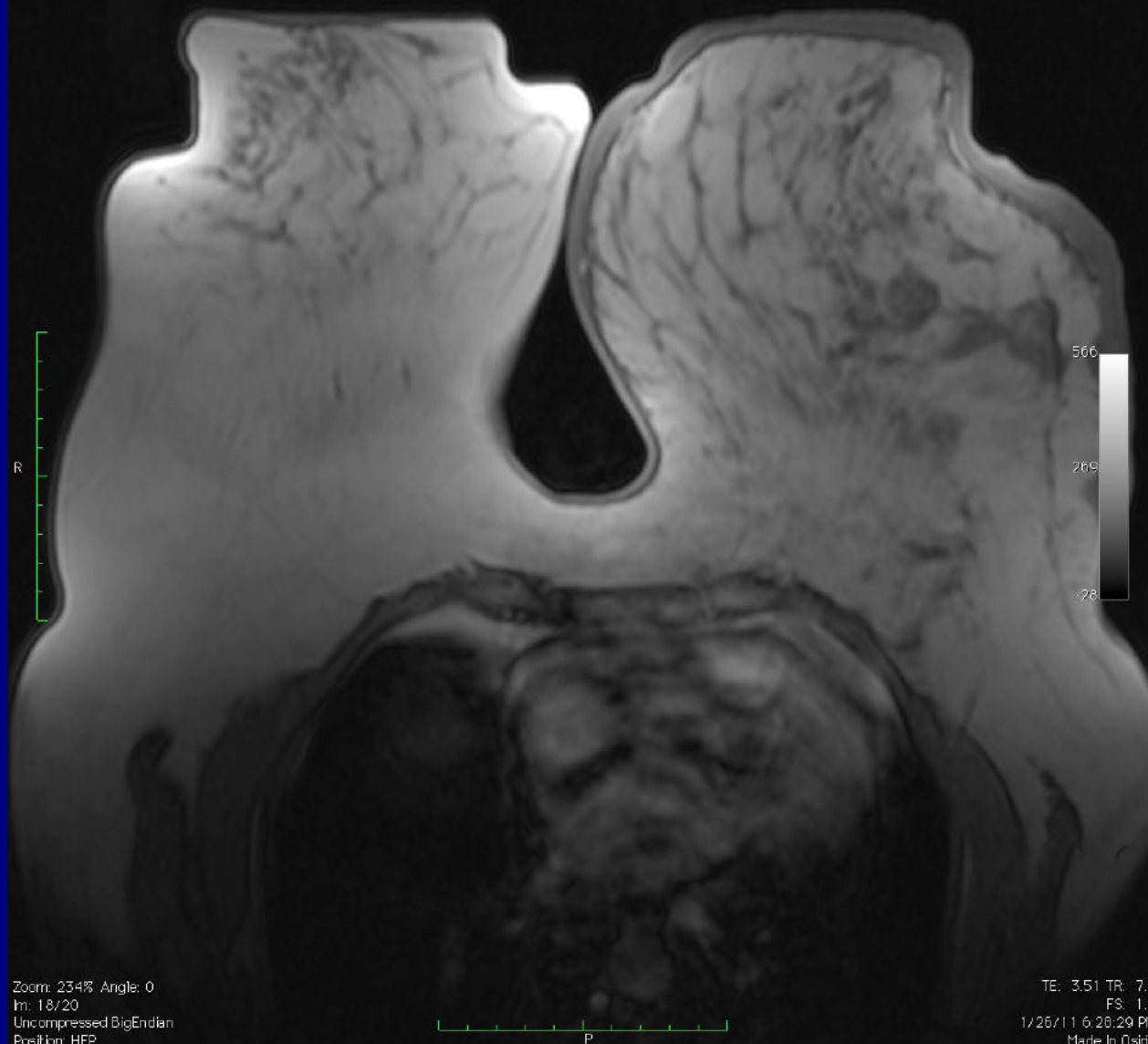

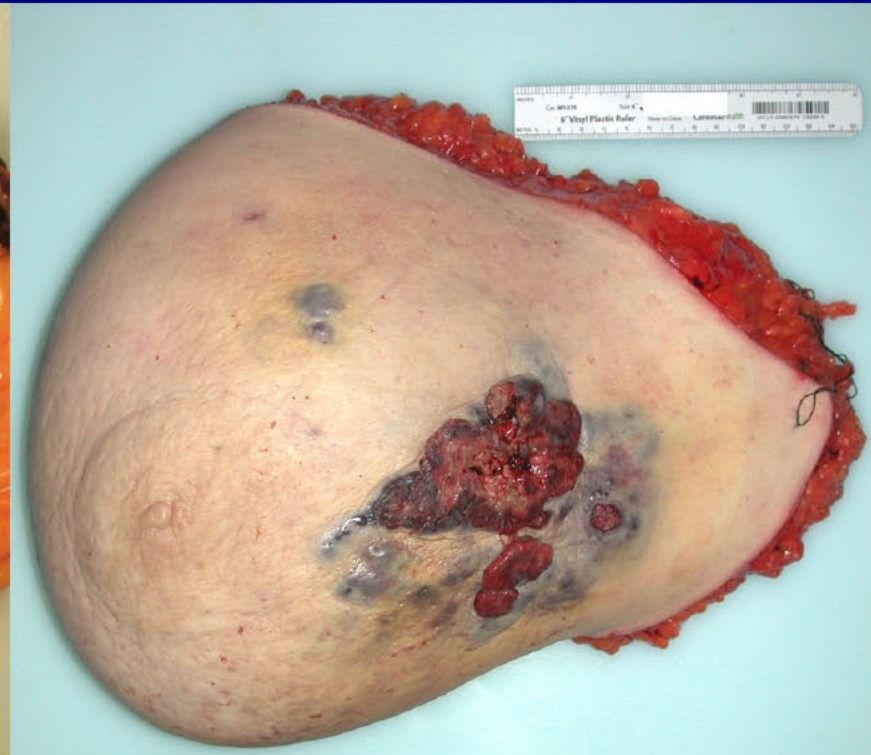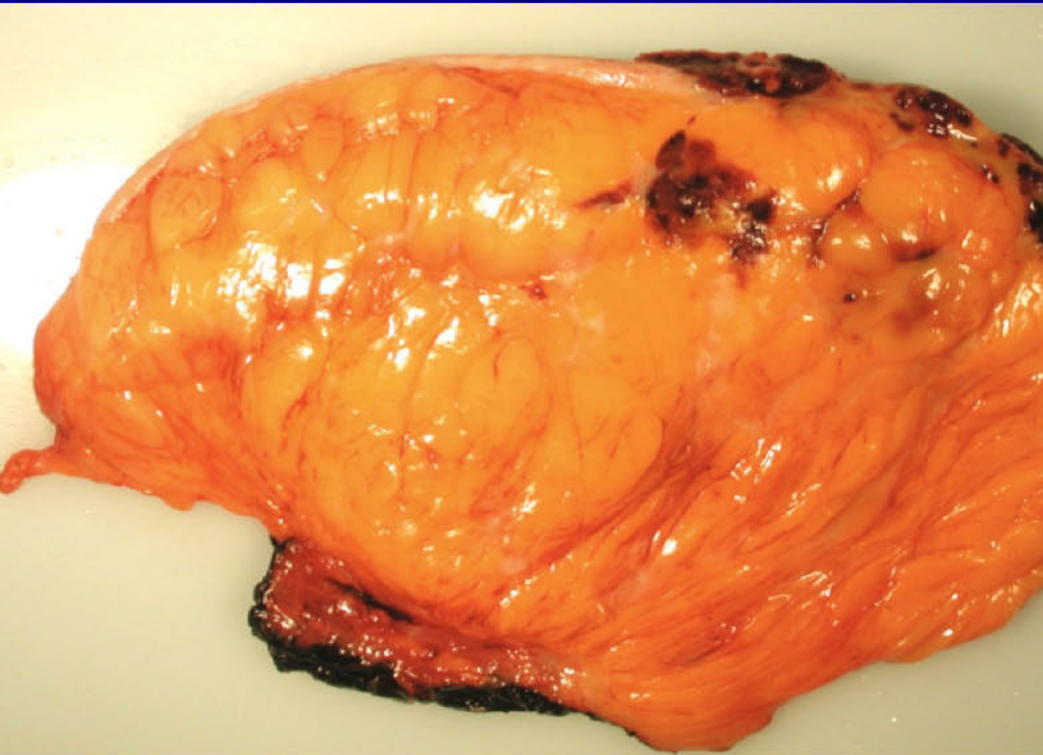
Image size: 512 x 512
View size: 1200 x 1200
WL: 40 WW: 400

A

5.9 ROUTINE ONCOLOGY TORSO - C+ CHEST-ABD-PEL
5375
2



Angiosarcoma



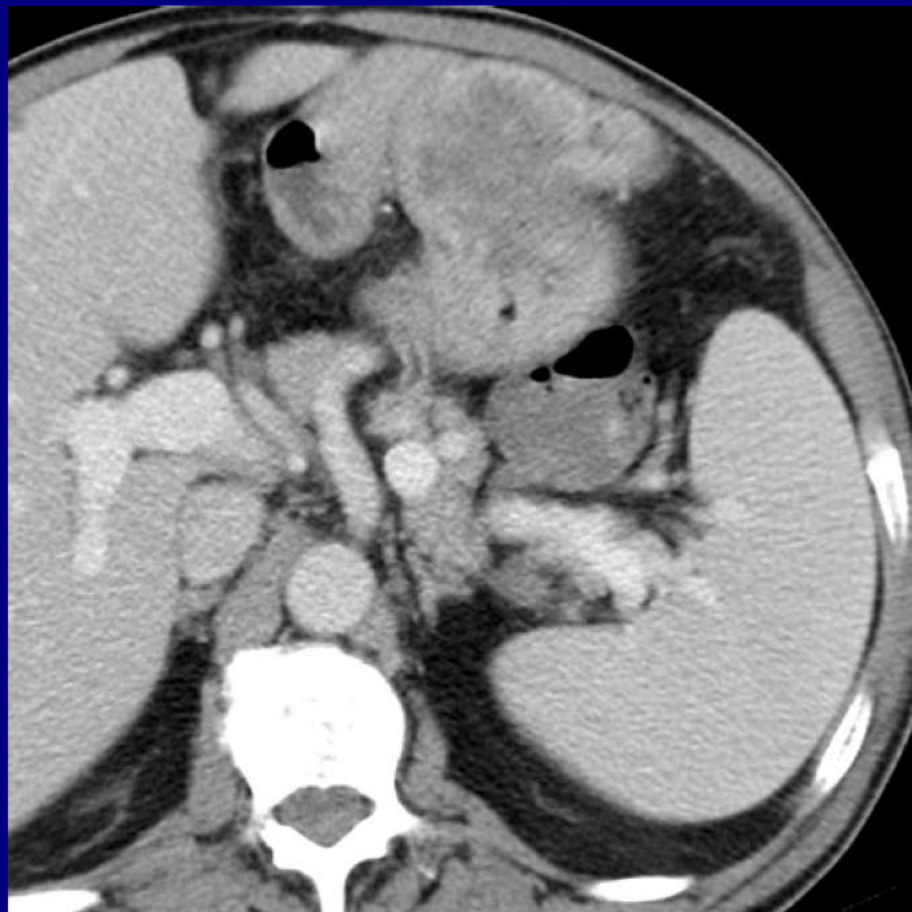
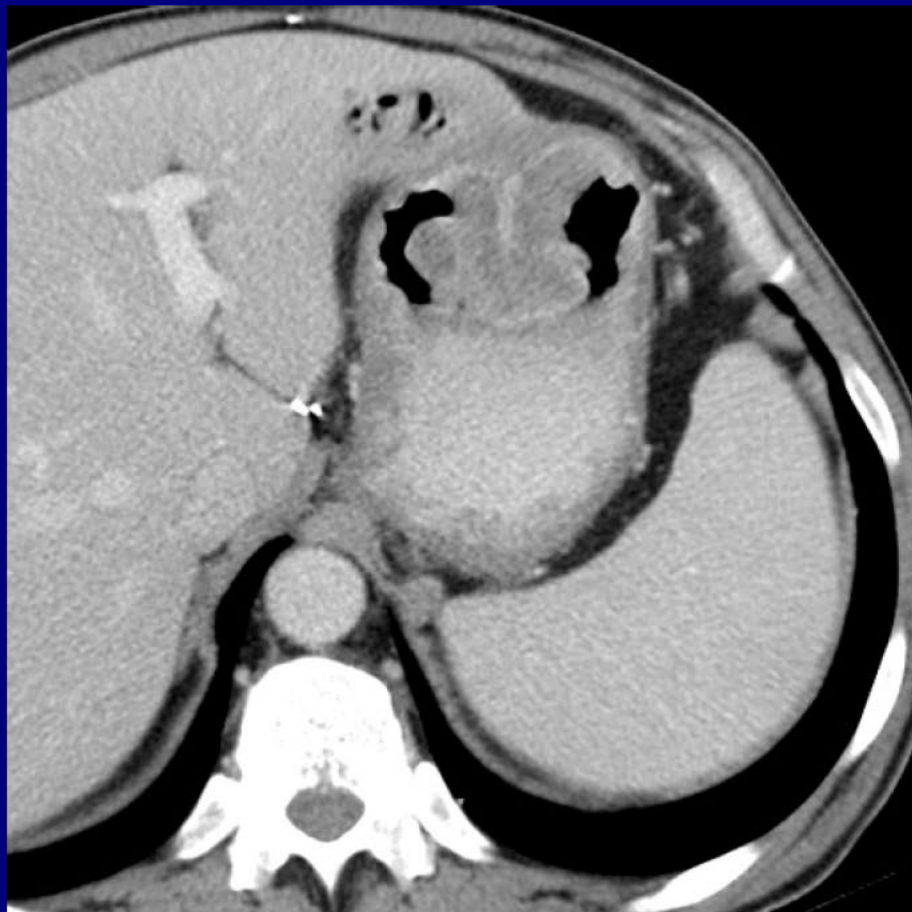Angiosarcoma

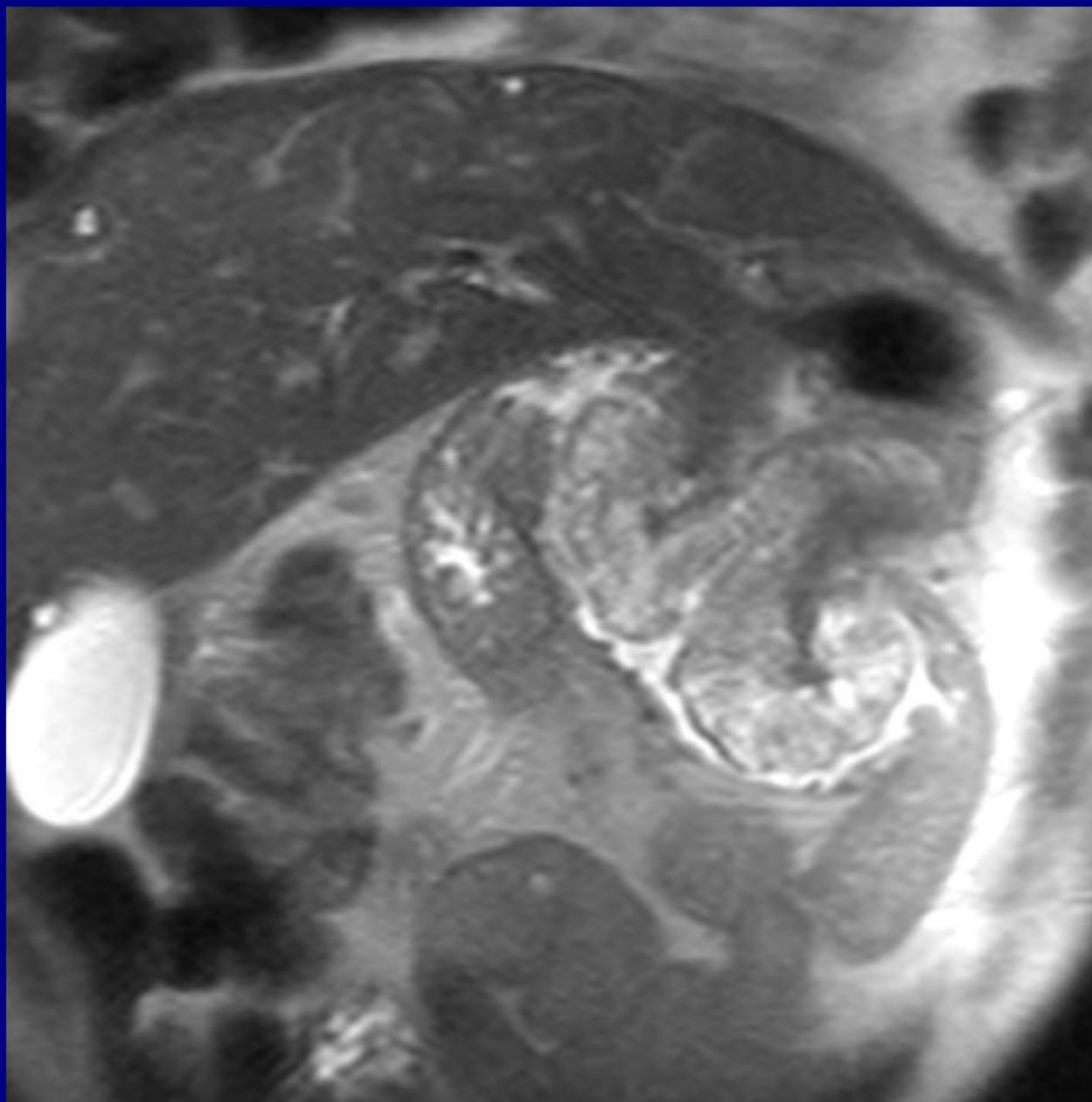
Leo Tsai MD

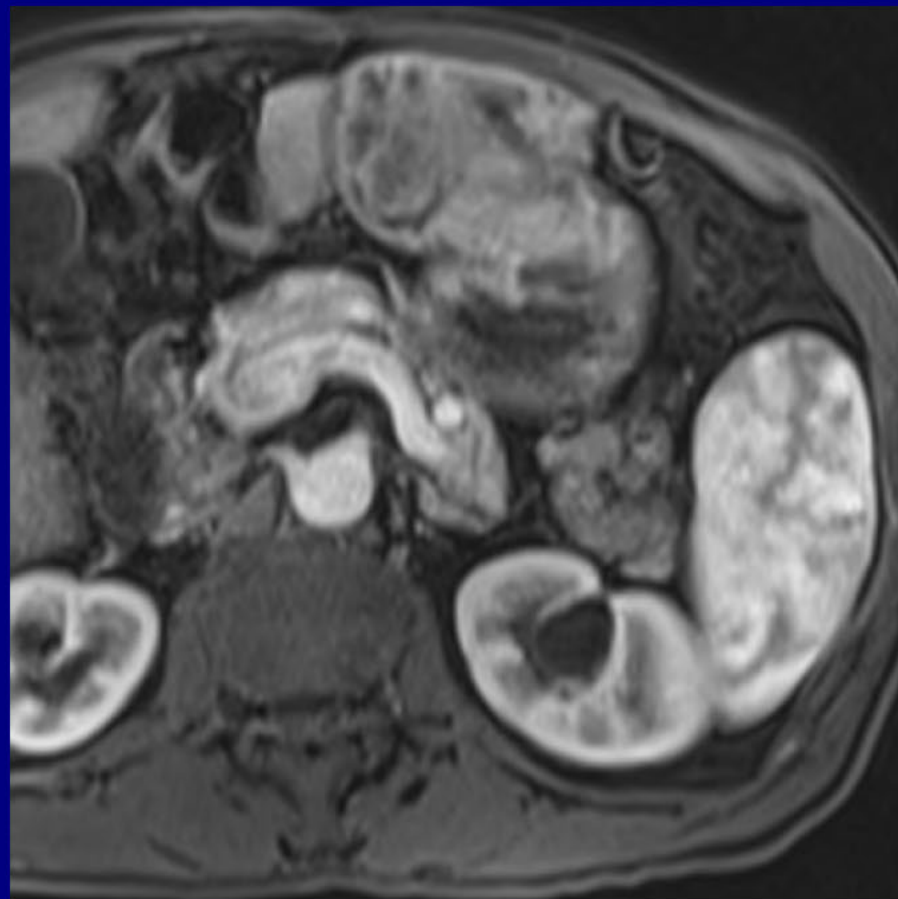
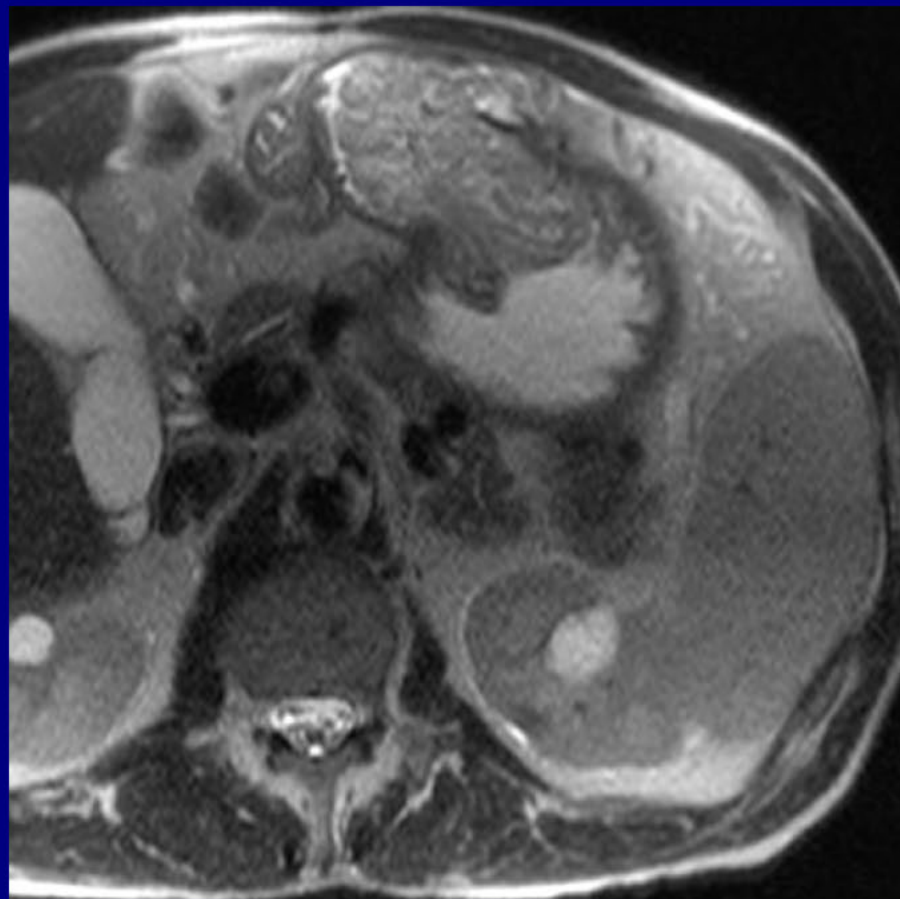
Beth Israel Deaconess Medical Center
Boston, MA

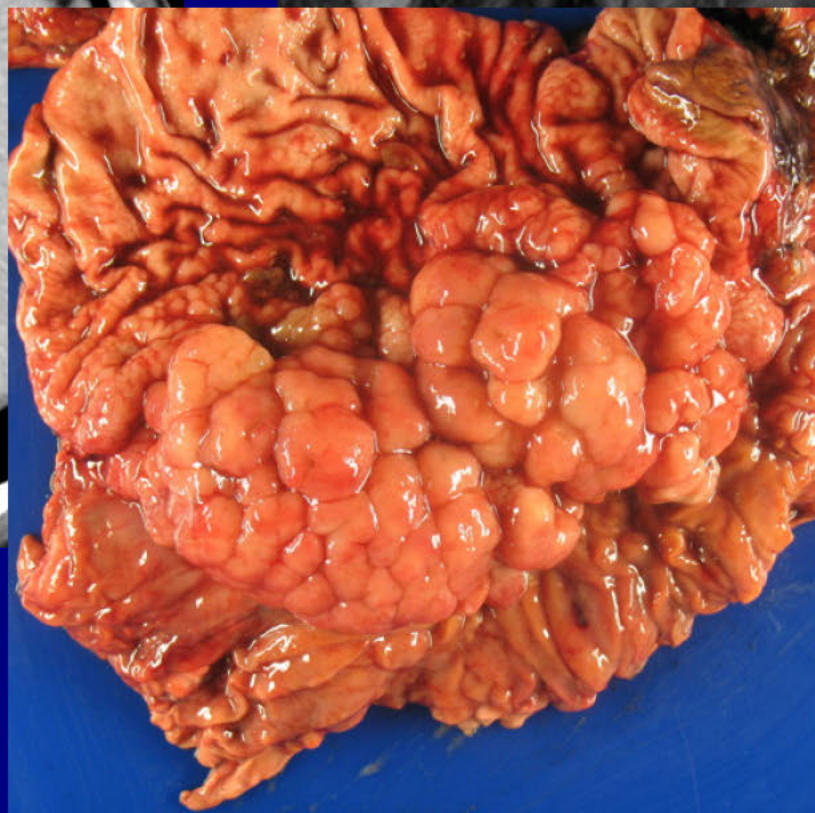
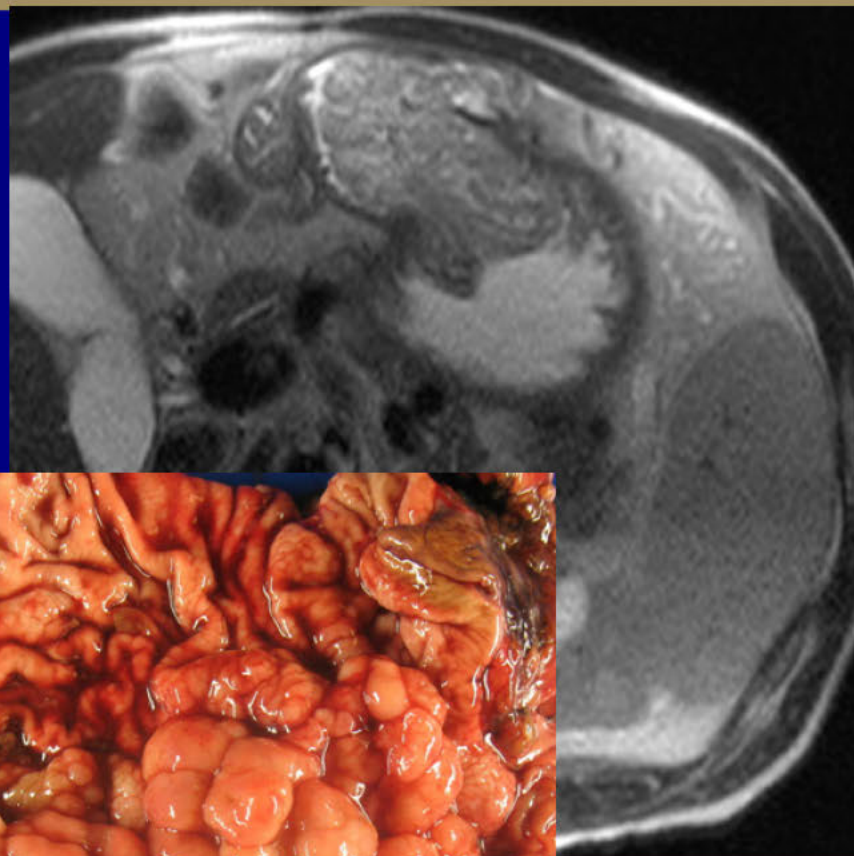
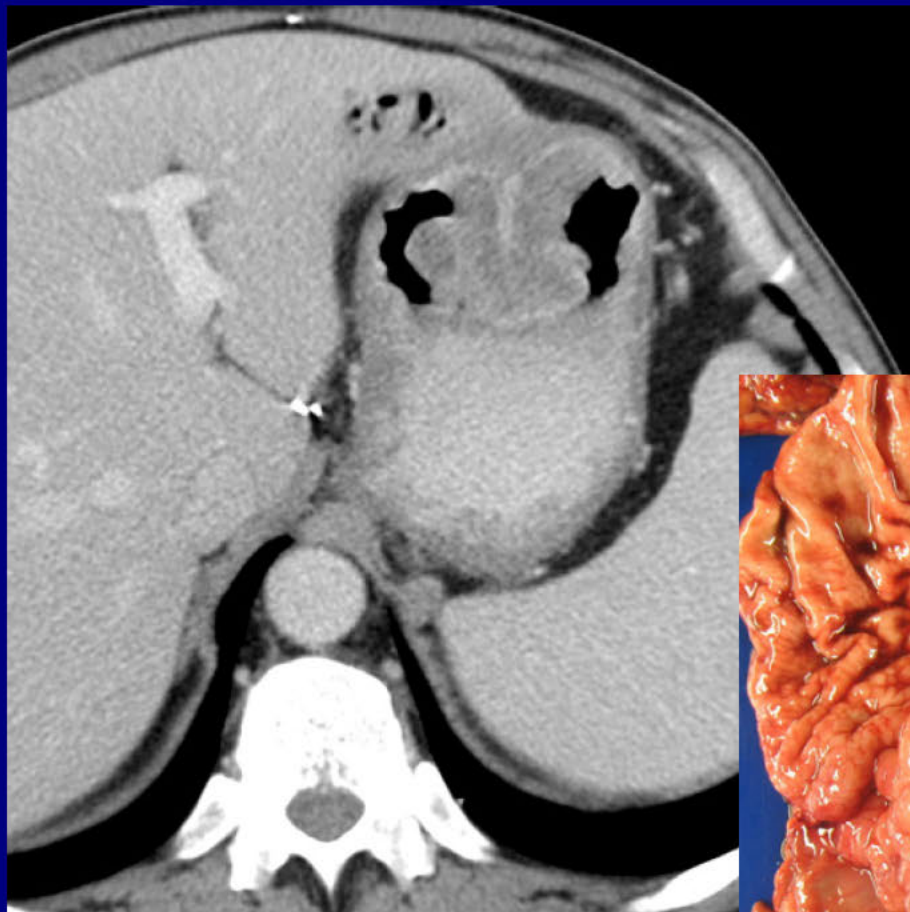
Gastrointestinal Best Case

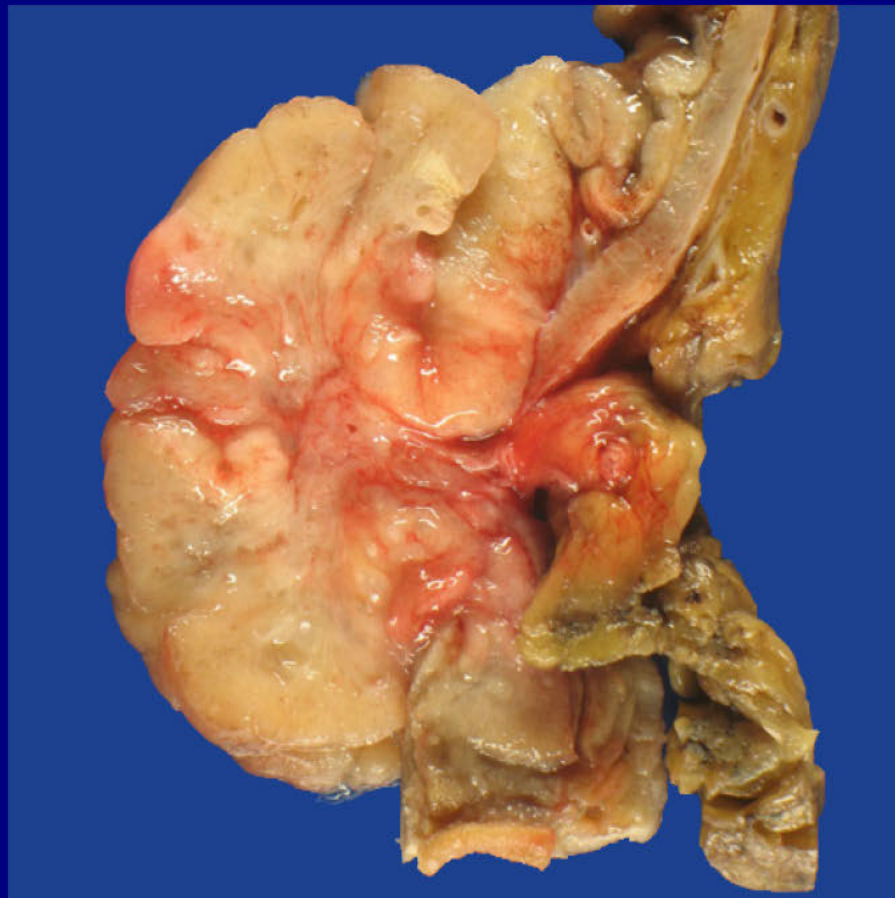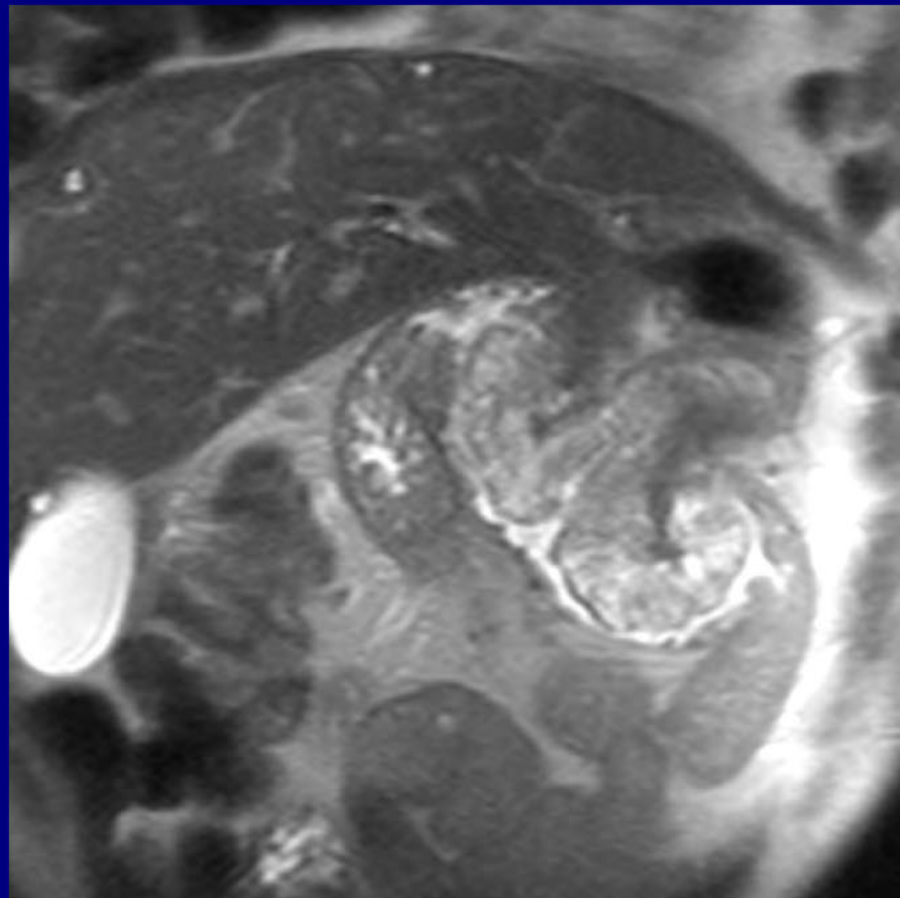
55-year-old man with right-sided abdominal pain and symptomatic anemia; history of prior Billroth II procedure 22 years prior











Gastritis Cystica Polyposa

Vivek Kaira

Yale New Haven Hospital,
New Haven, CT

Many thanks to all of you for
submitting such great cases!
Have a safe trip home -

From the staff of the
American Institute for Radiologic Pathology