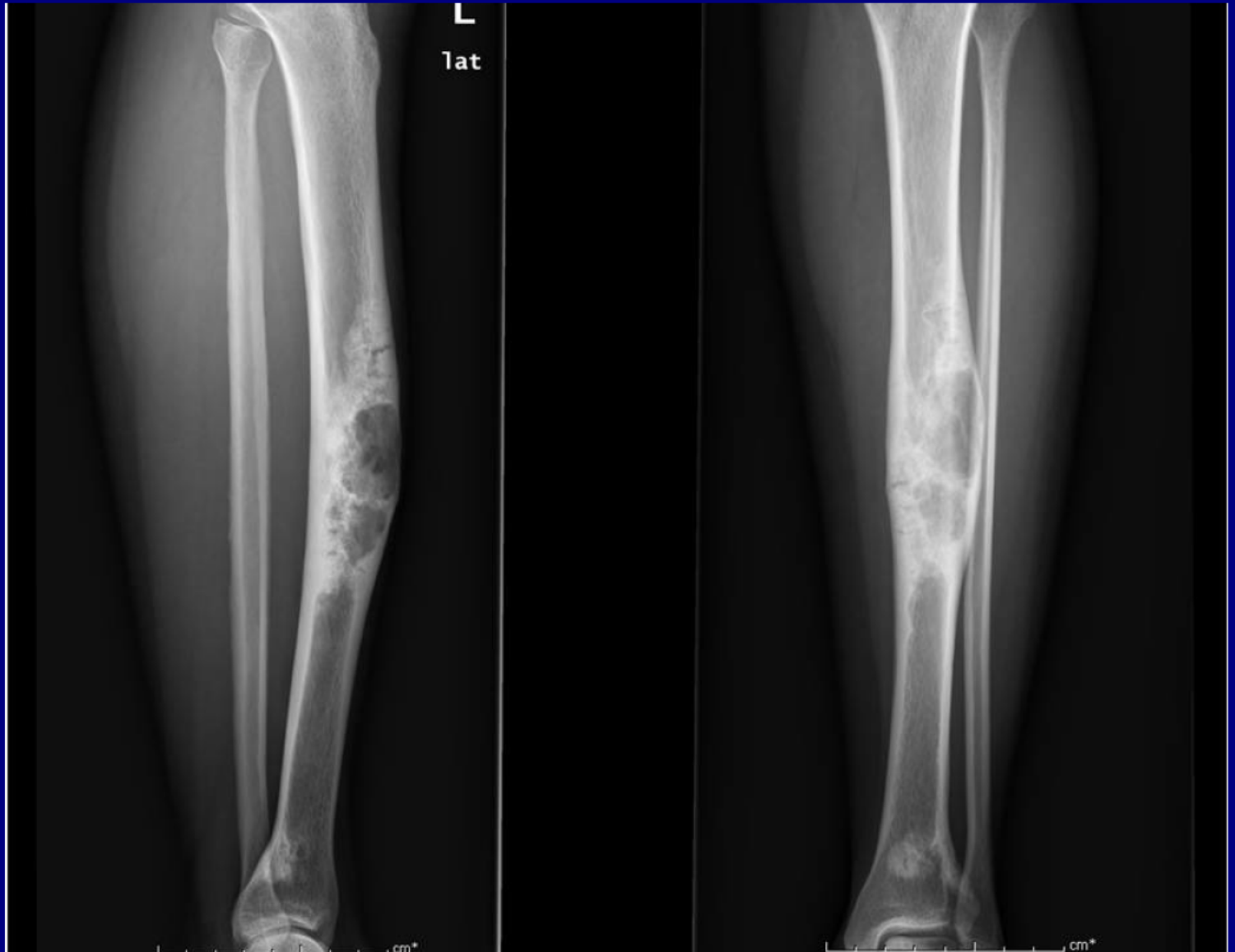

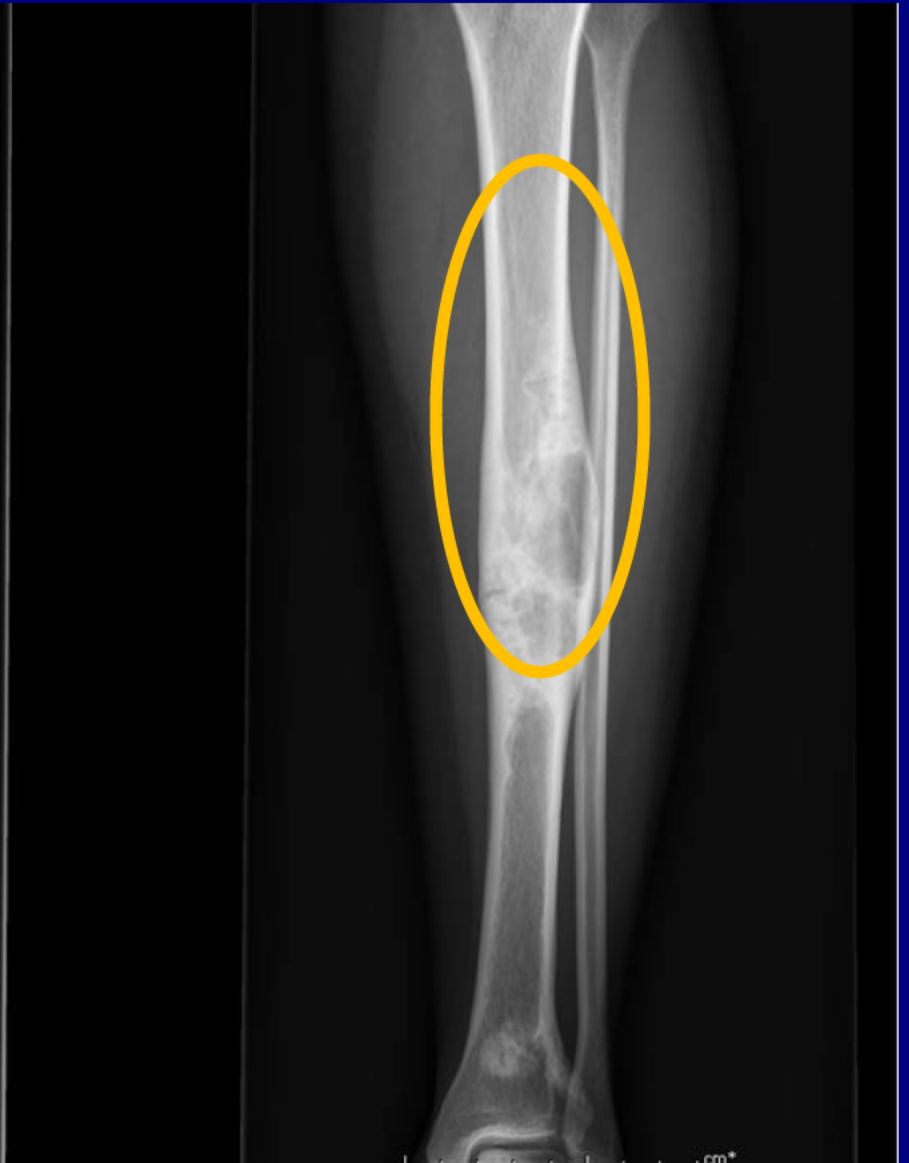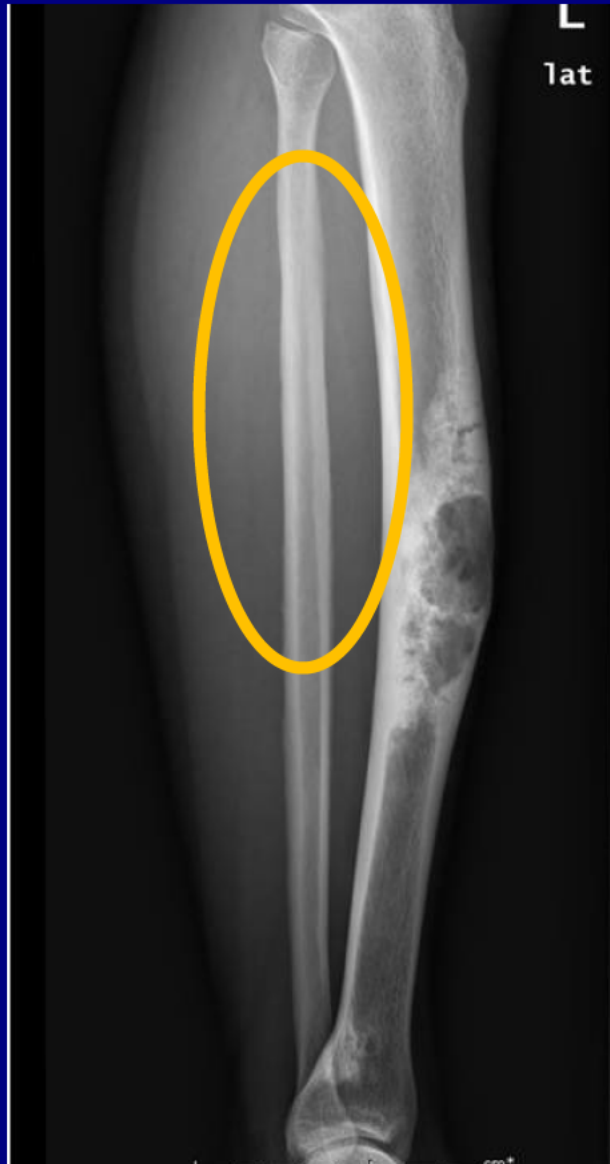BEST CASES OF THE AIRP

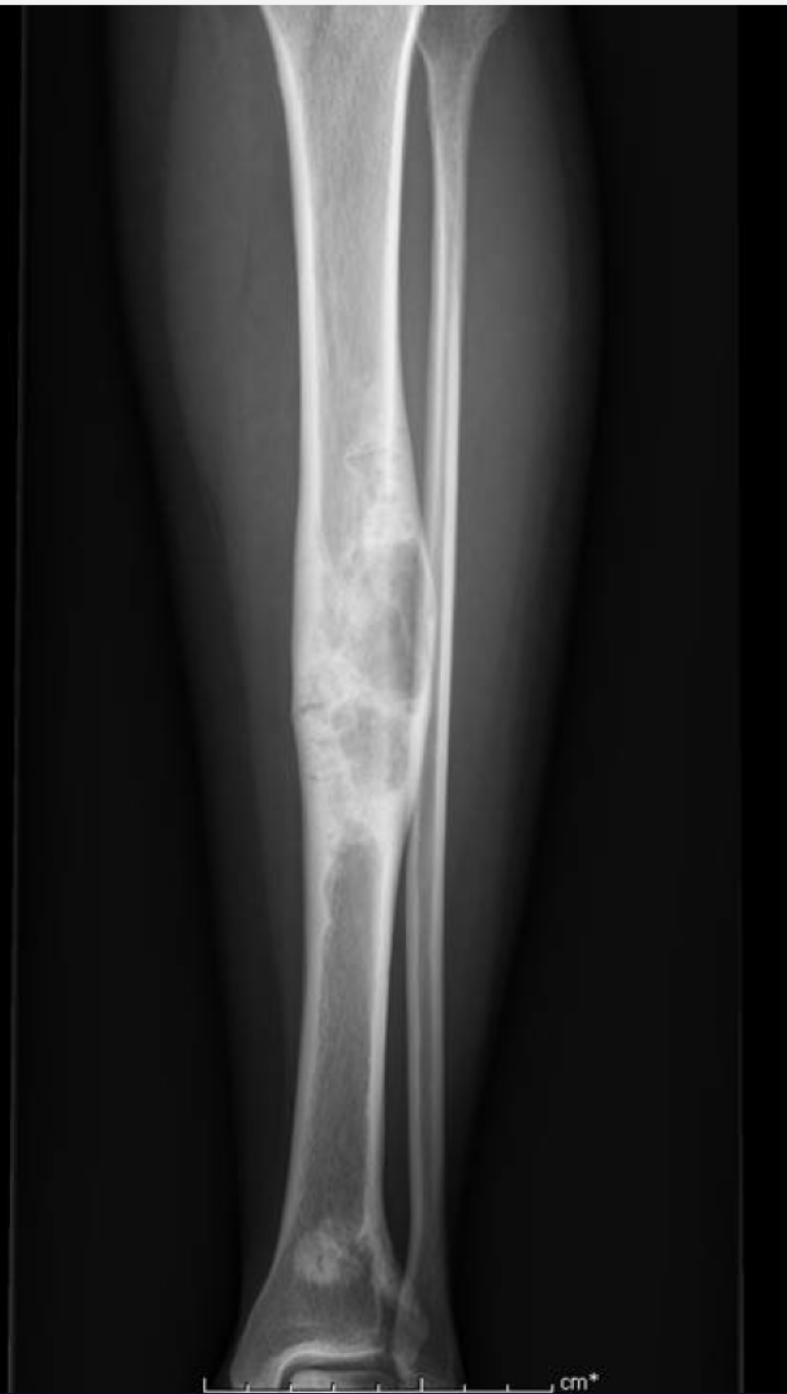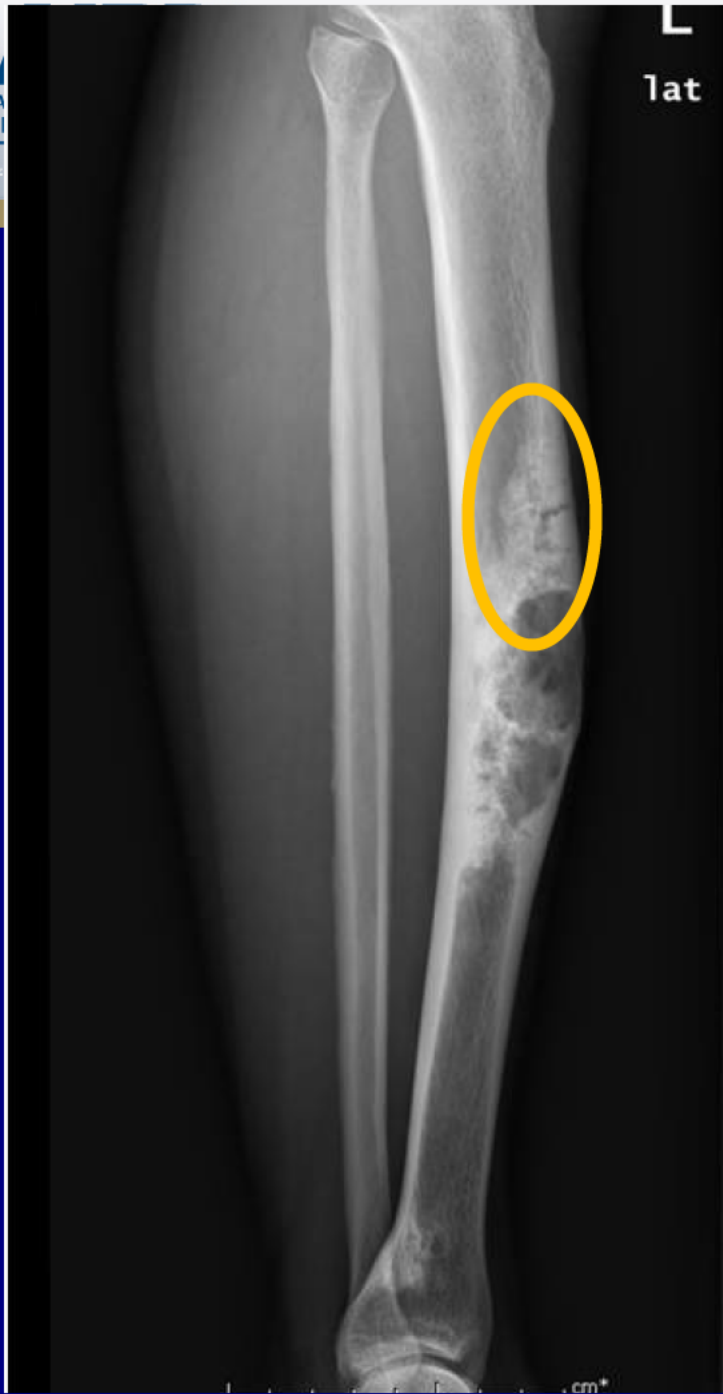July 23 – August 17, 2012

Musculoskeletal Best Case

46-year-old female presented with left lower leg pain for 7 months. She has a history of traumatic fracture of the left lower leg after falling, and it has appeared deformed since then.

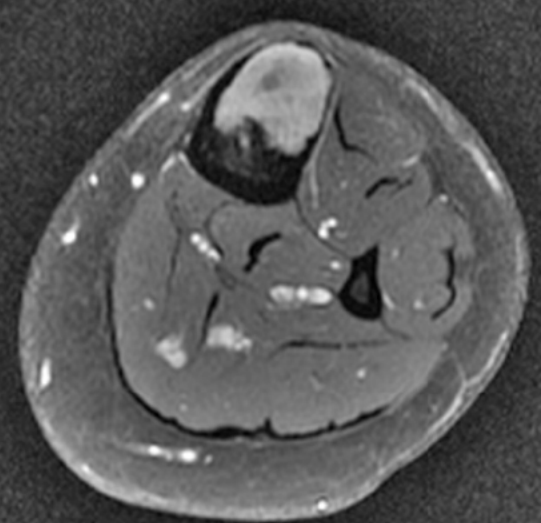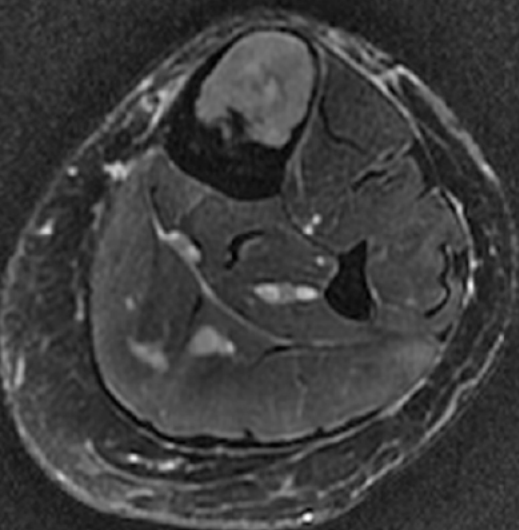
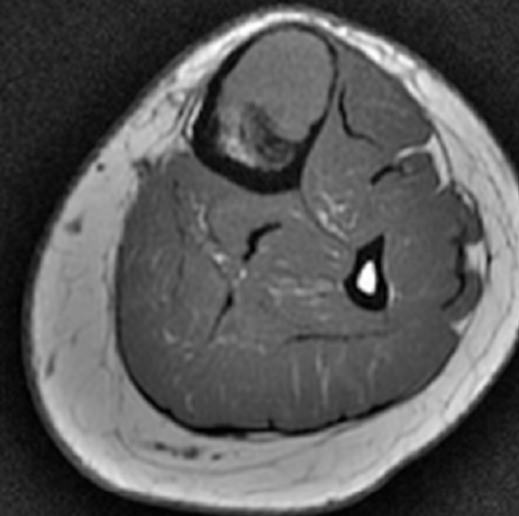
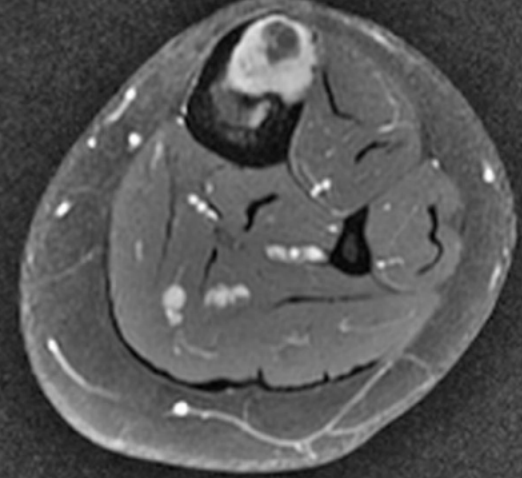
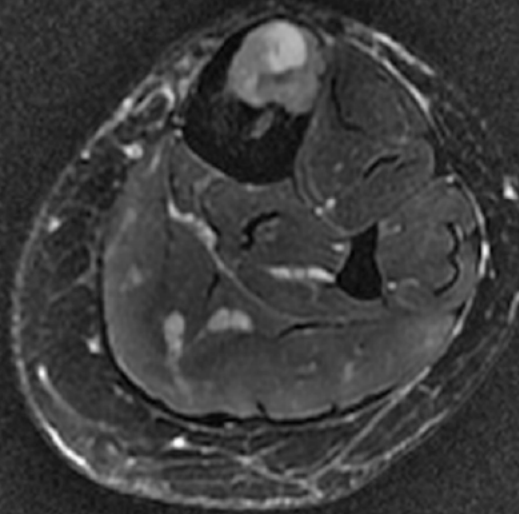
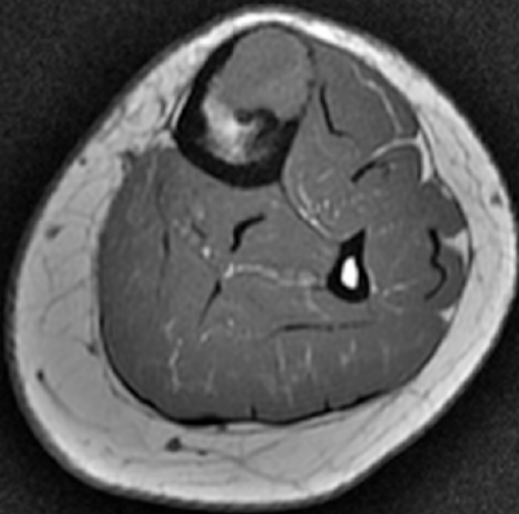


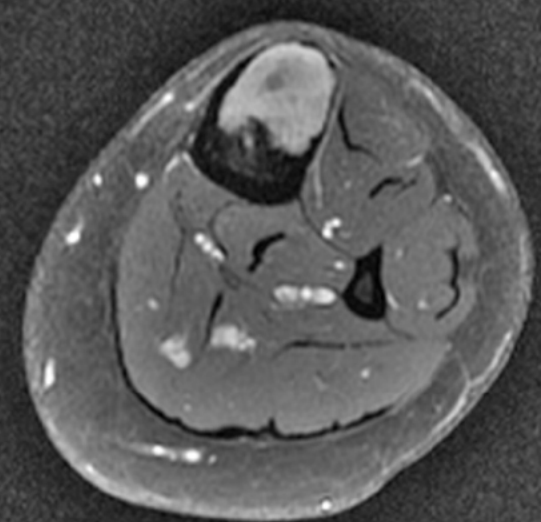
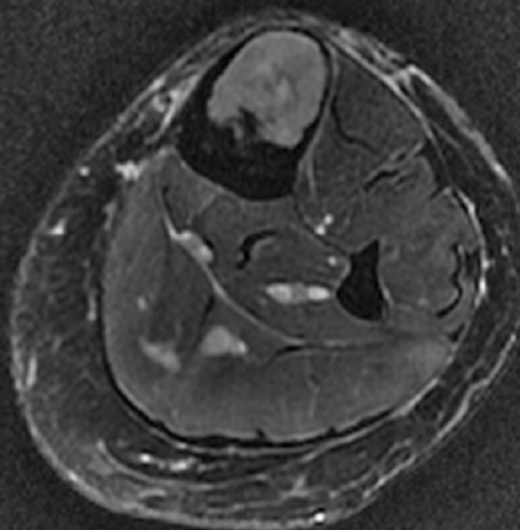
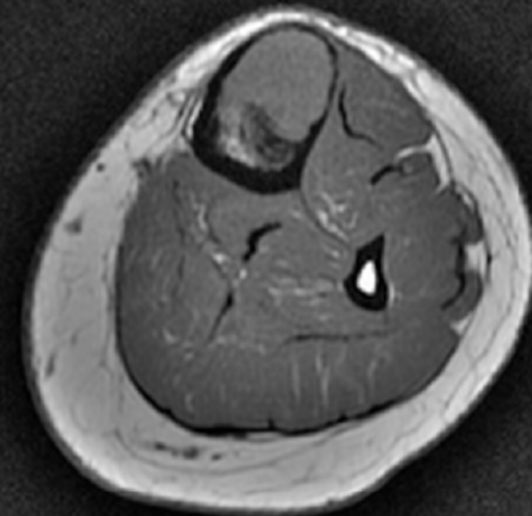
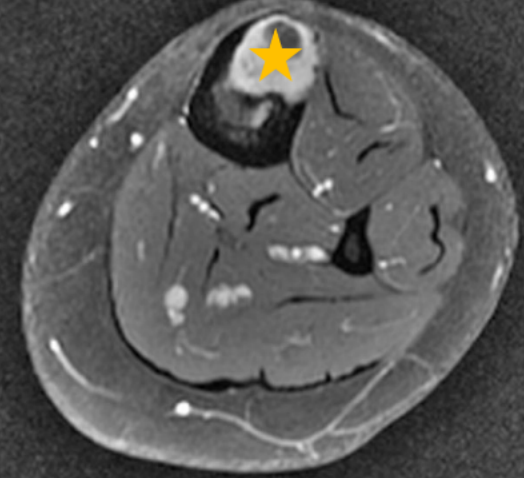
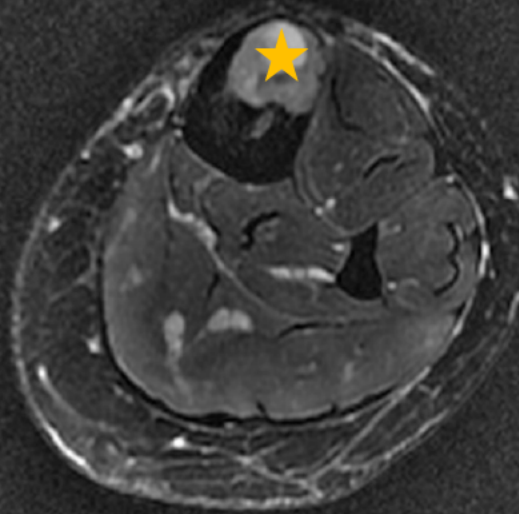
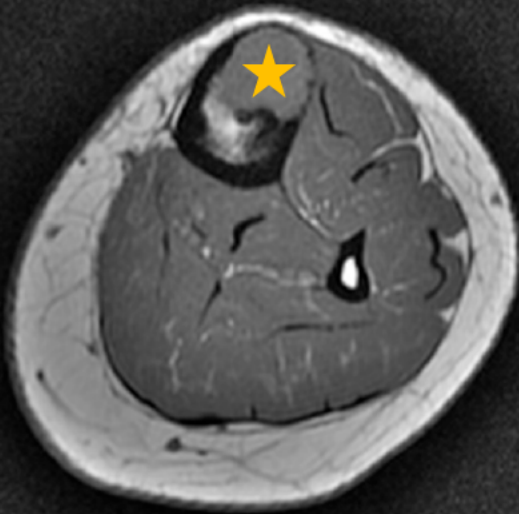




T2

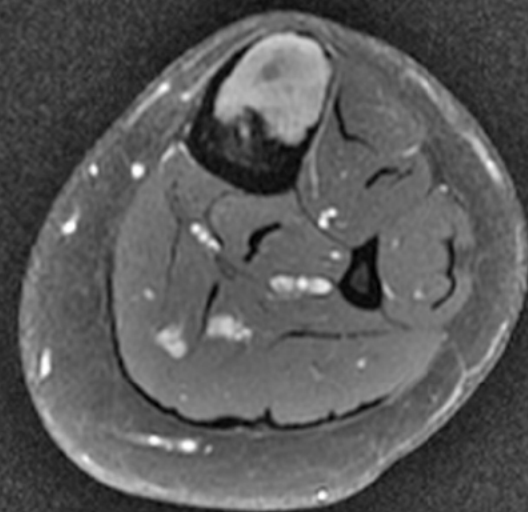
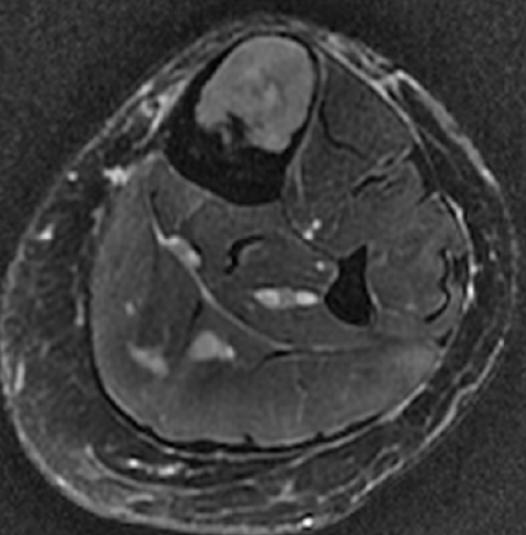
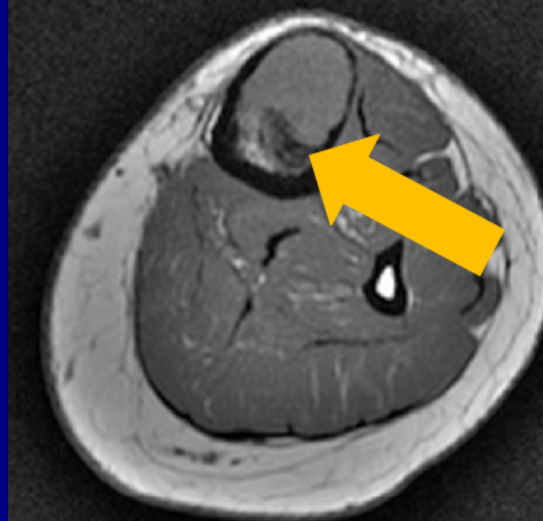
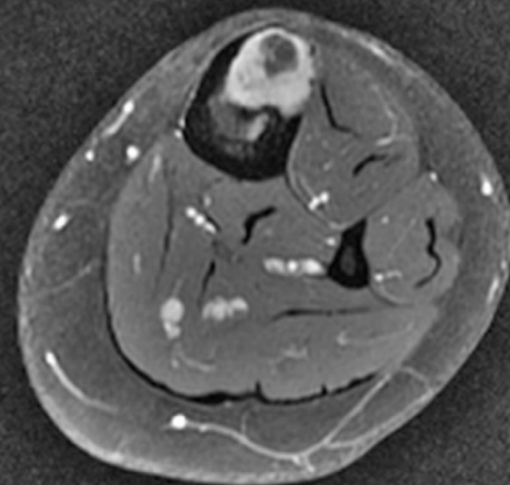
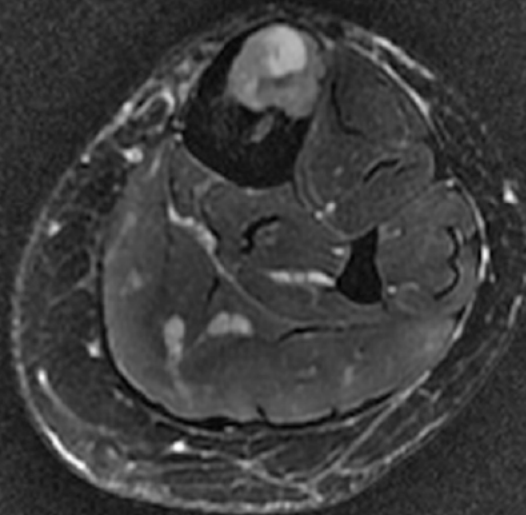
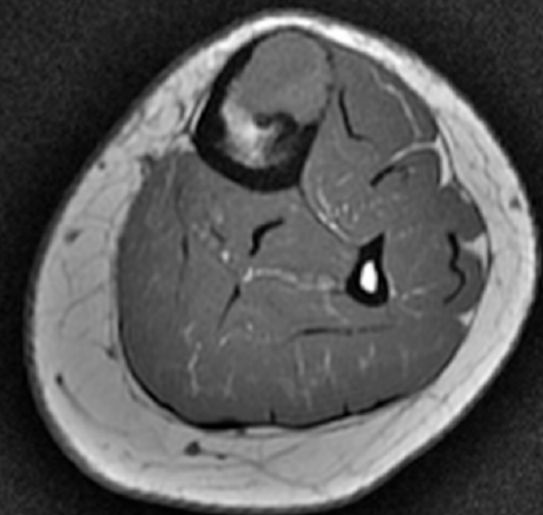
T1 GD

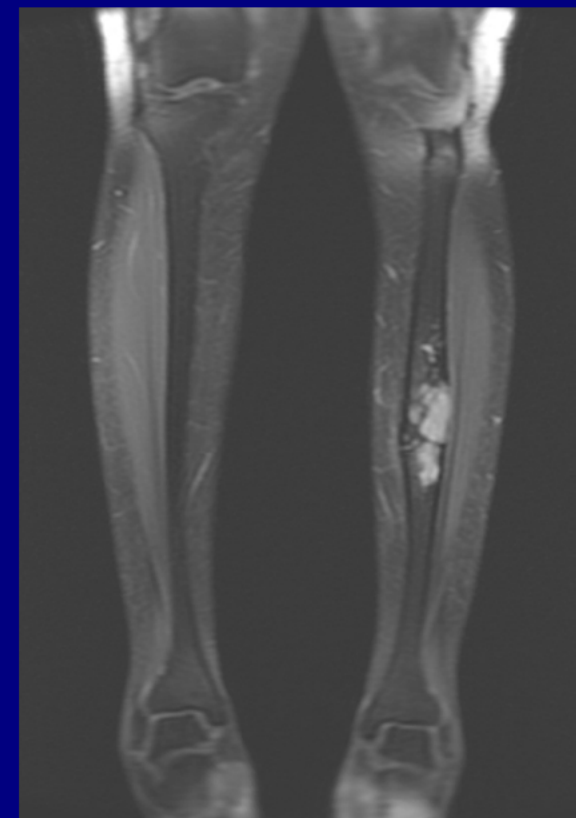
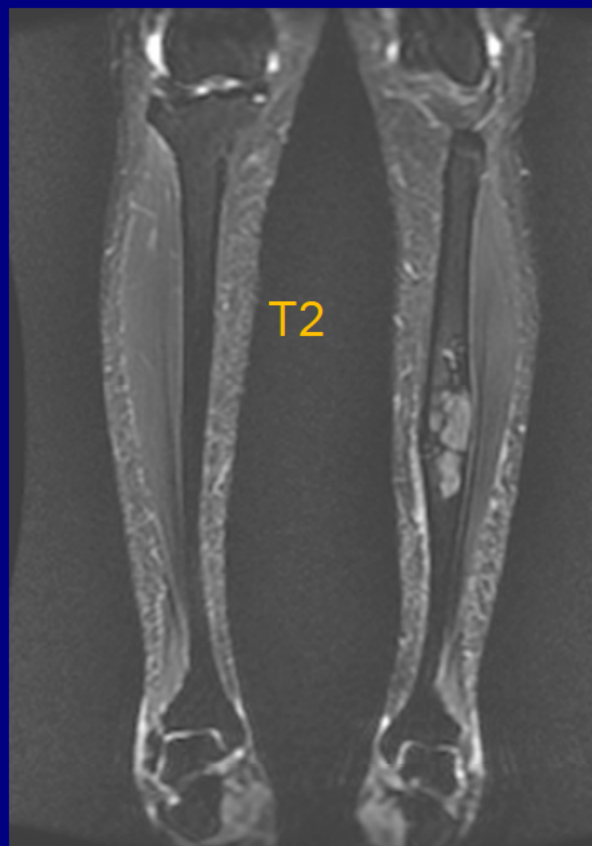
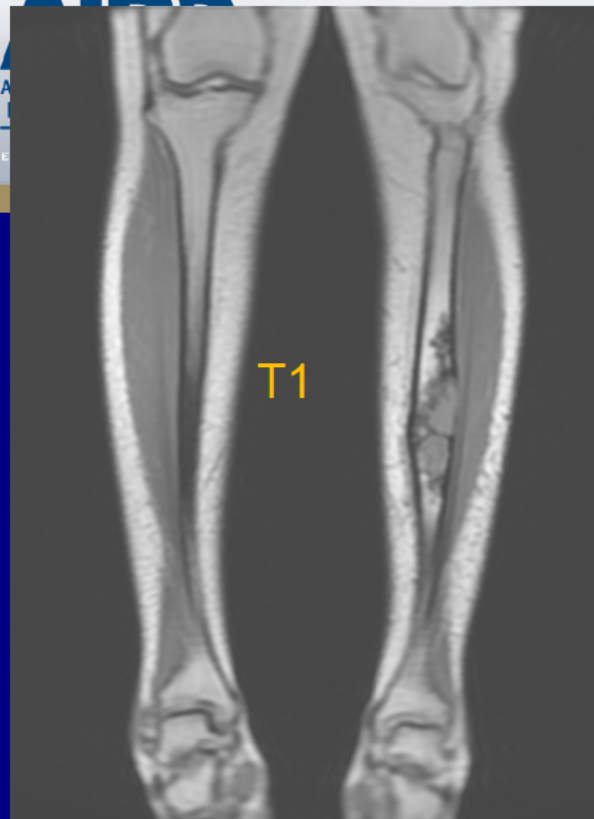



T2

T1 GD





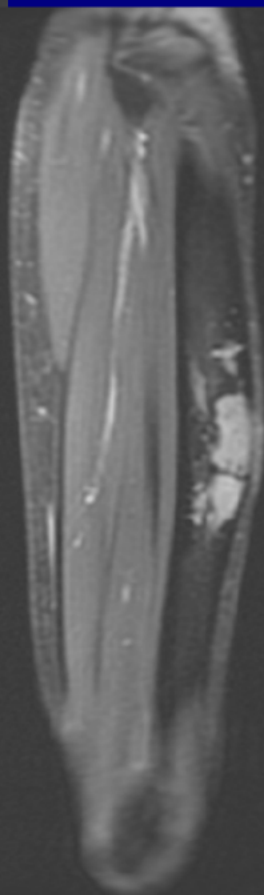
T1



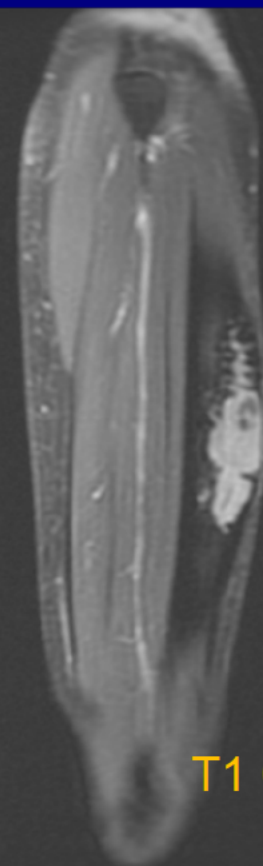
T1



T1 GD



T1 GD



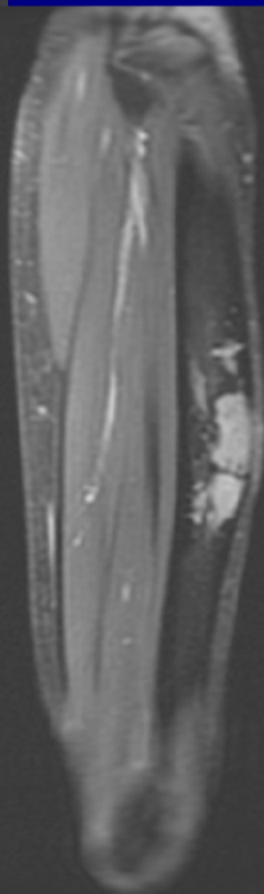
T1



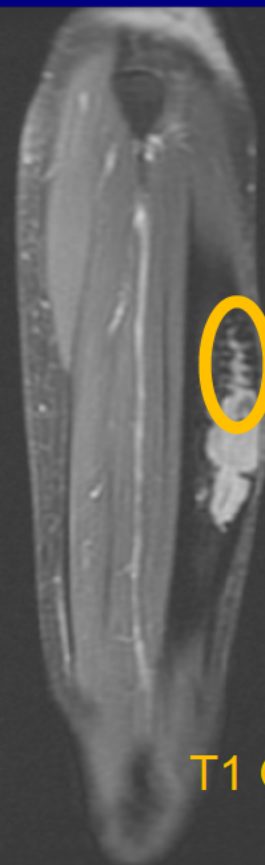T1



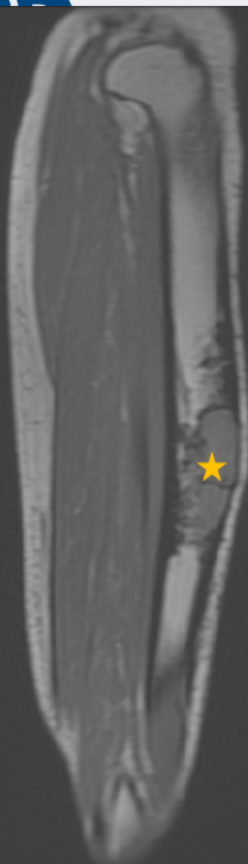
T1 GD



T1 GD



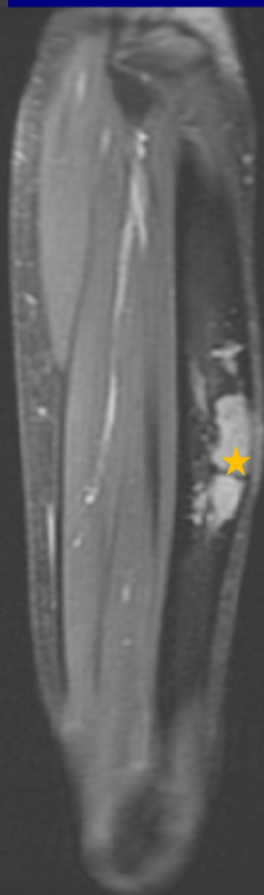
T1



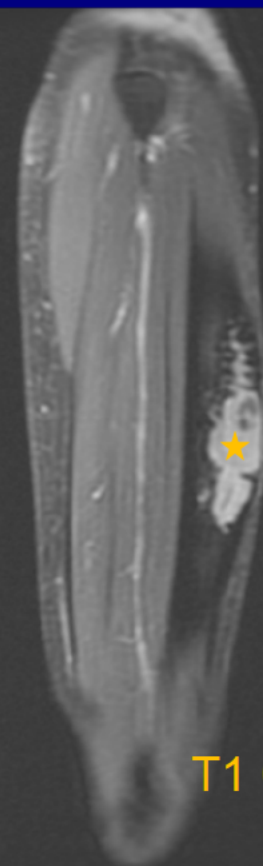
T1

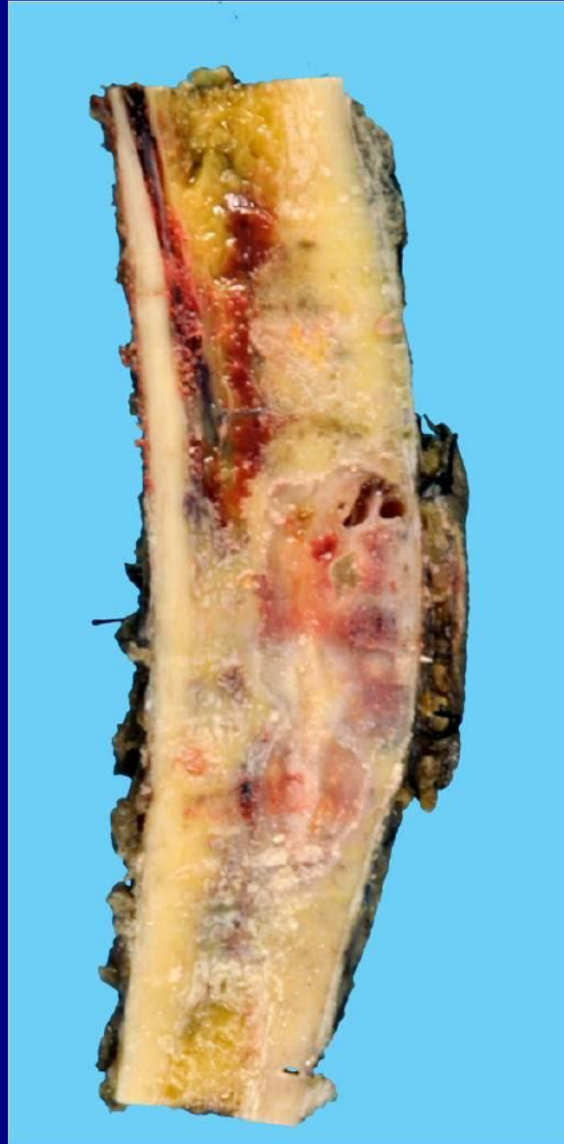

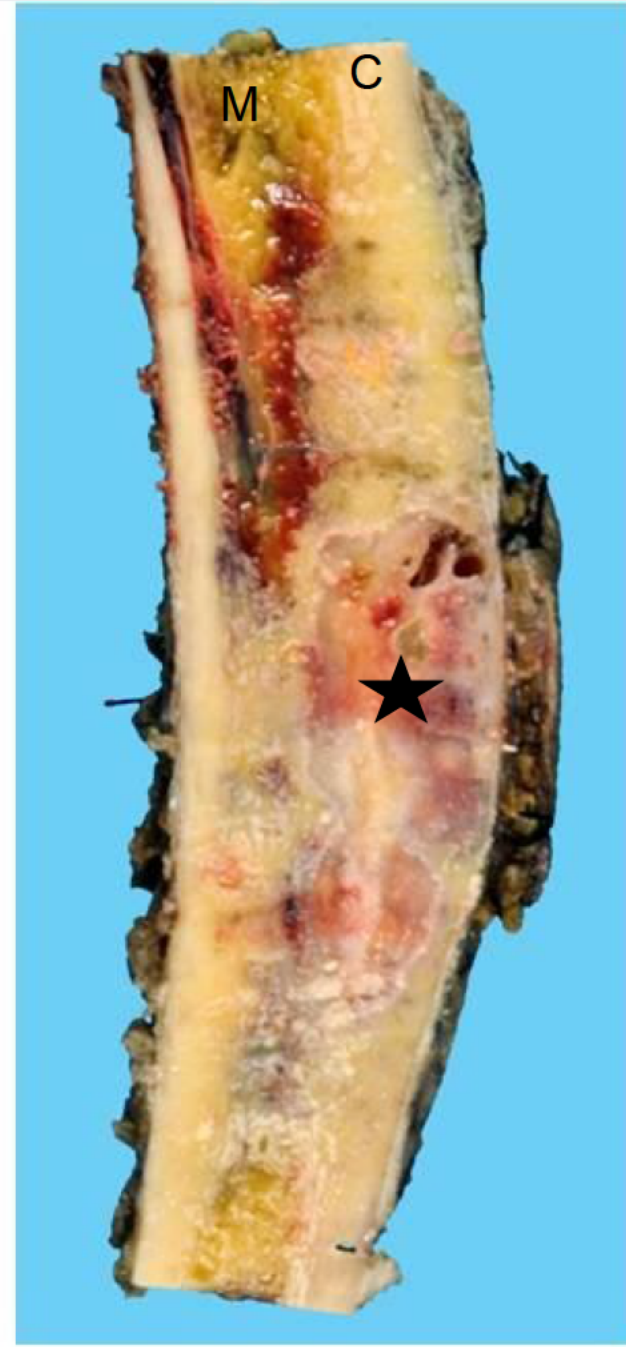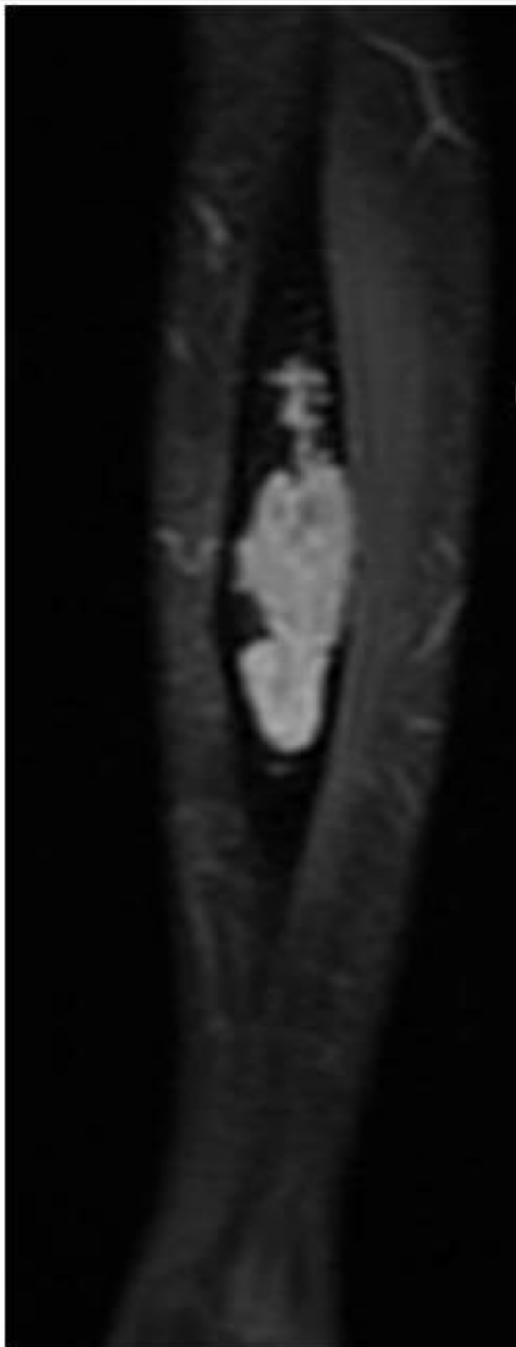
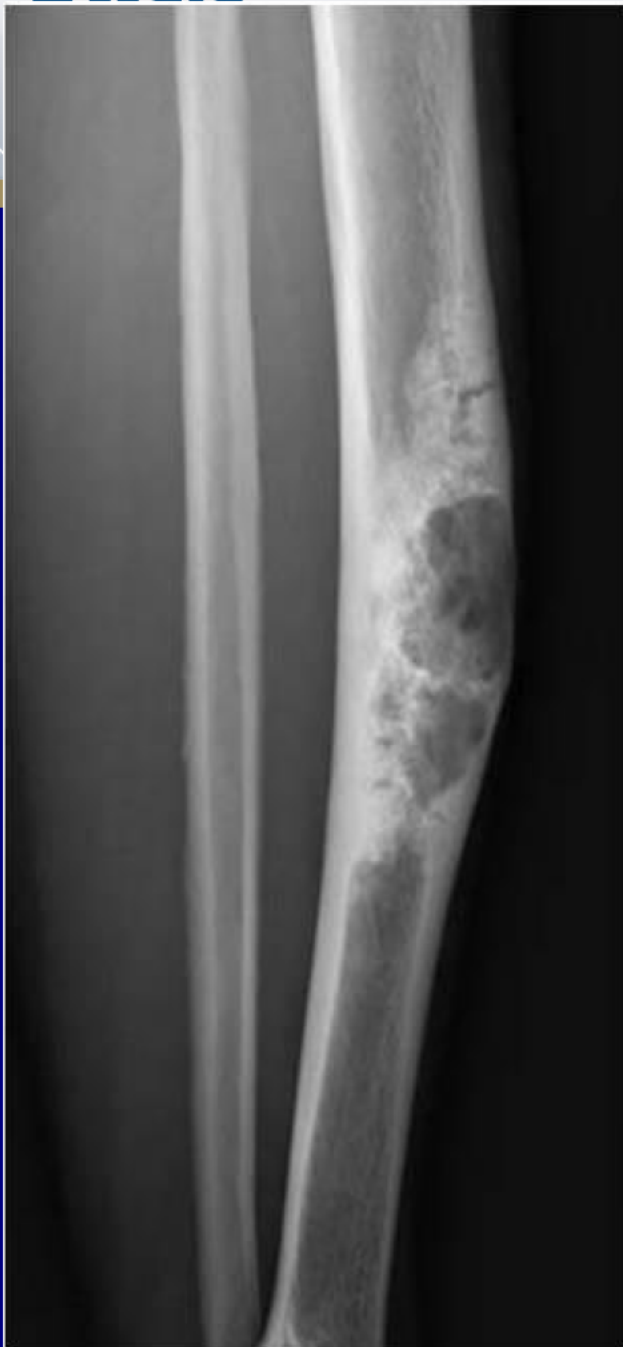T1 GD

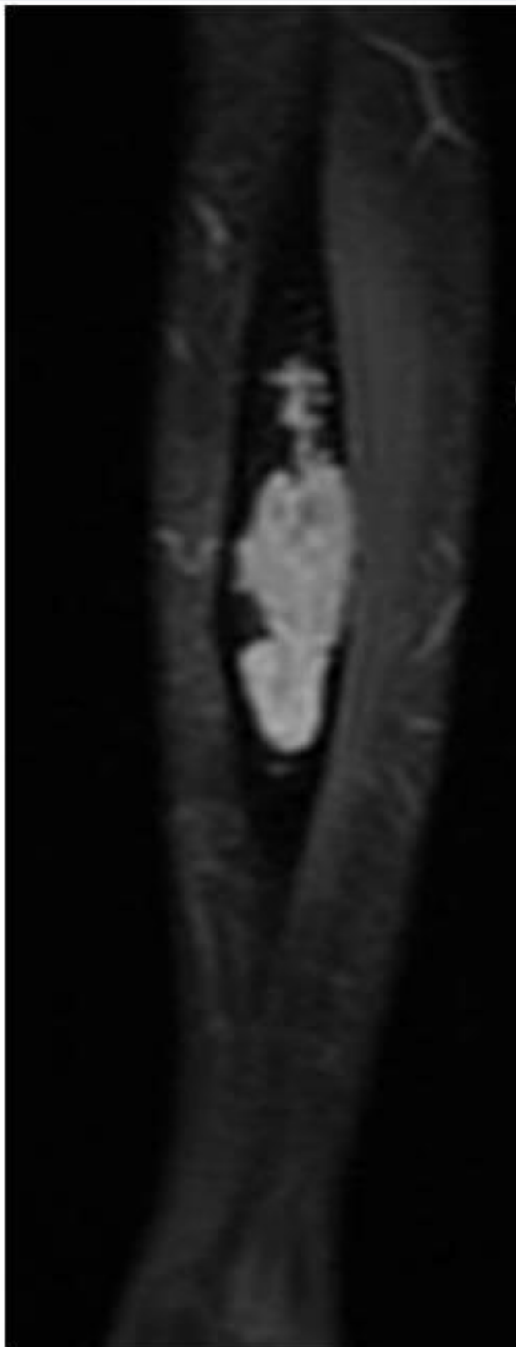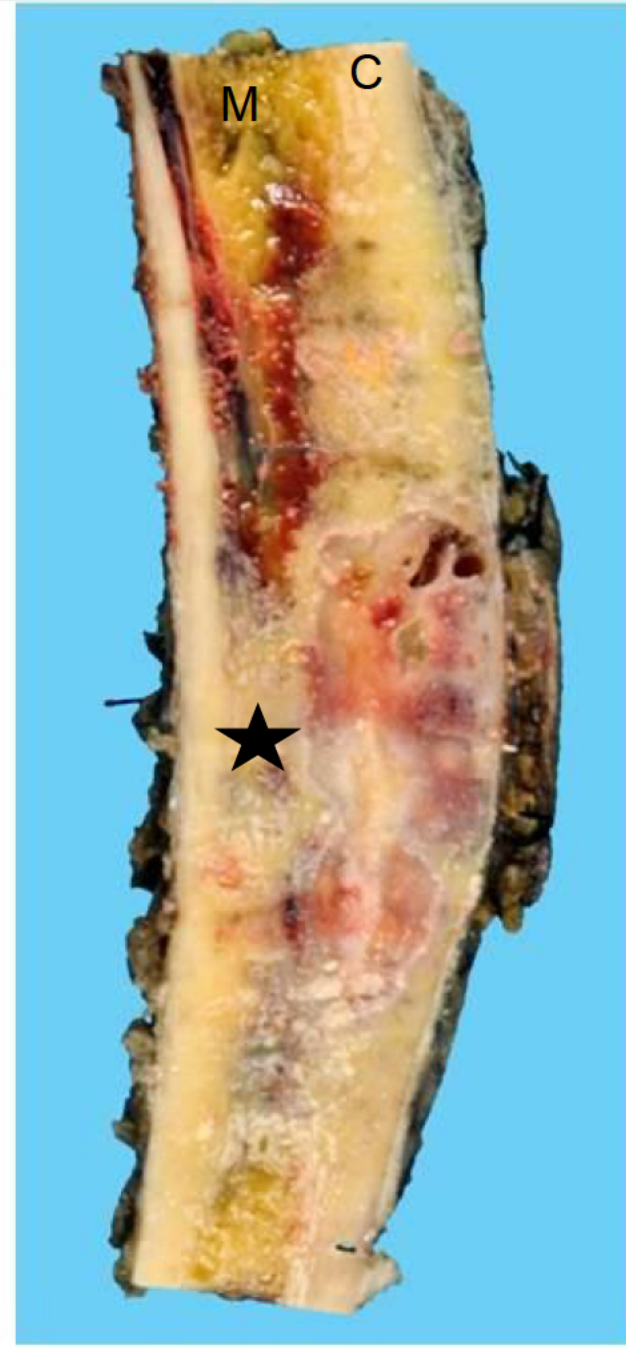


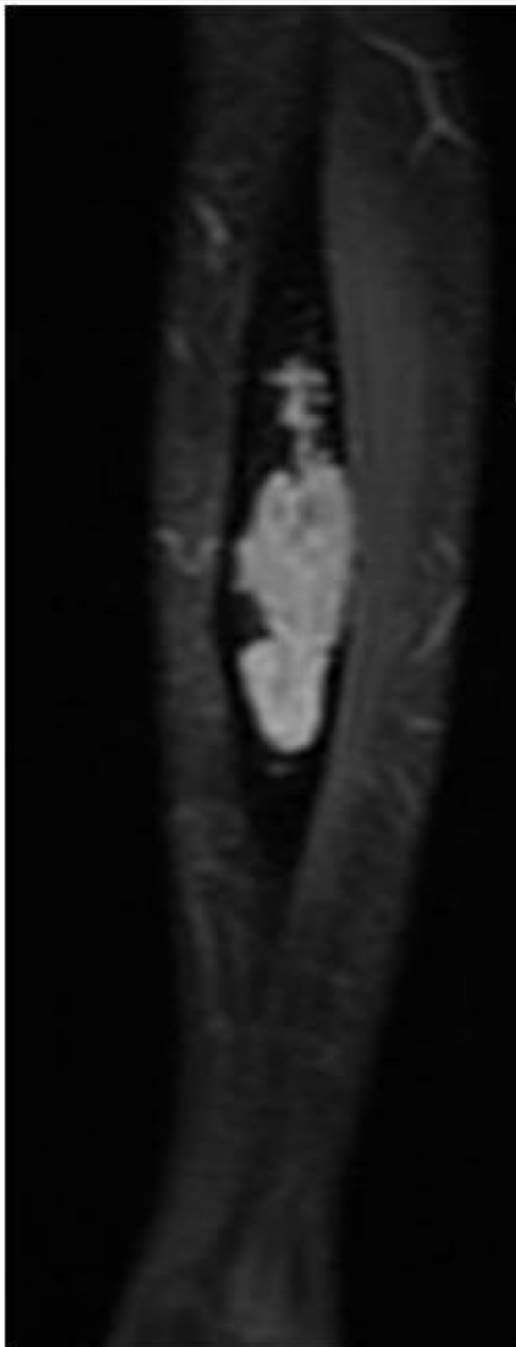
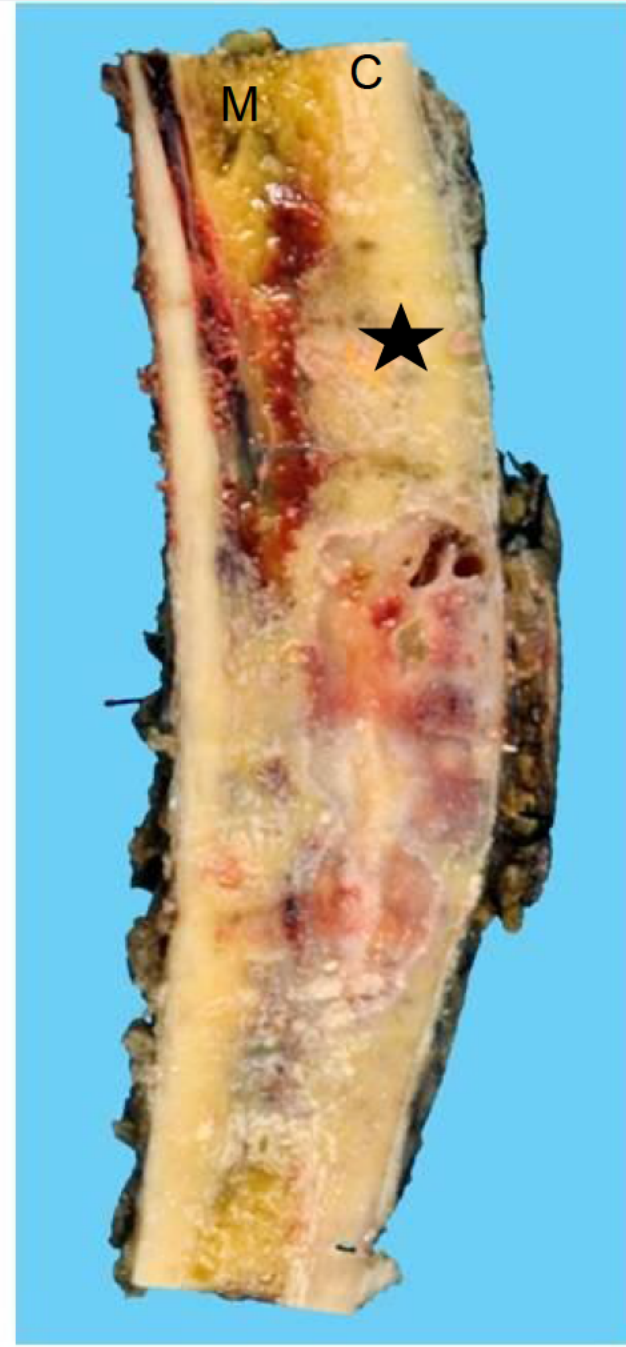T1 GD

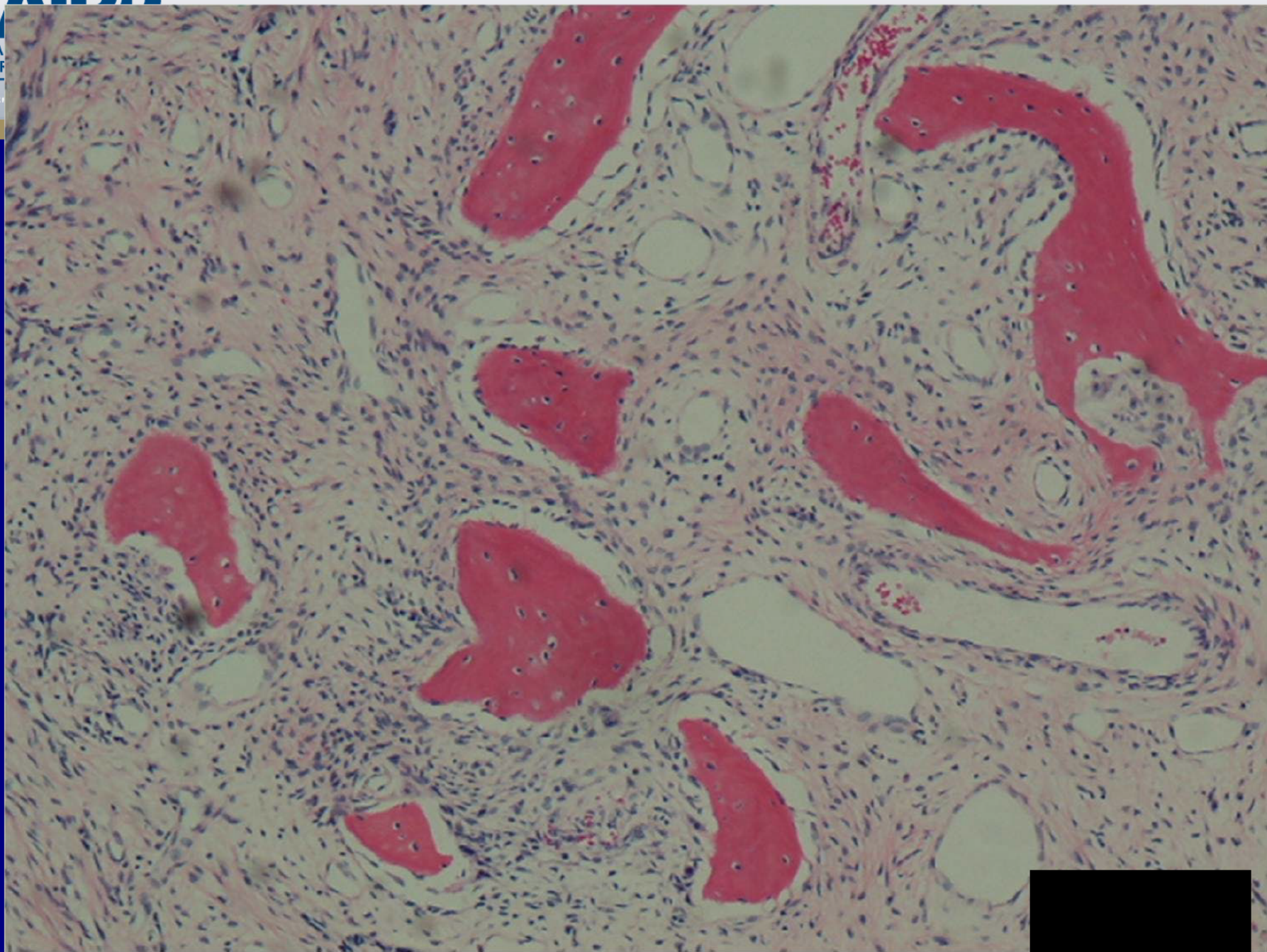


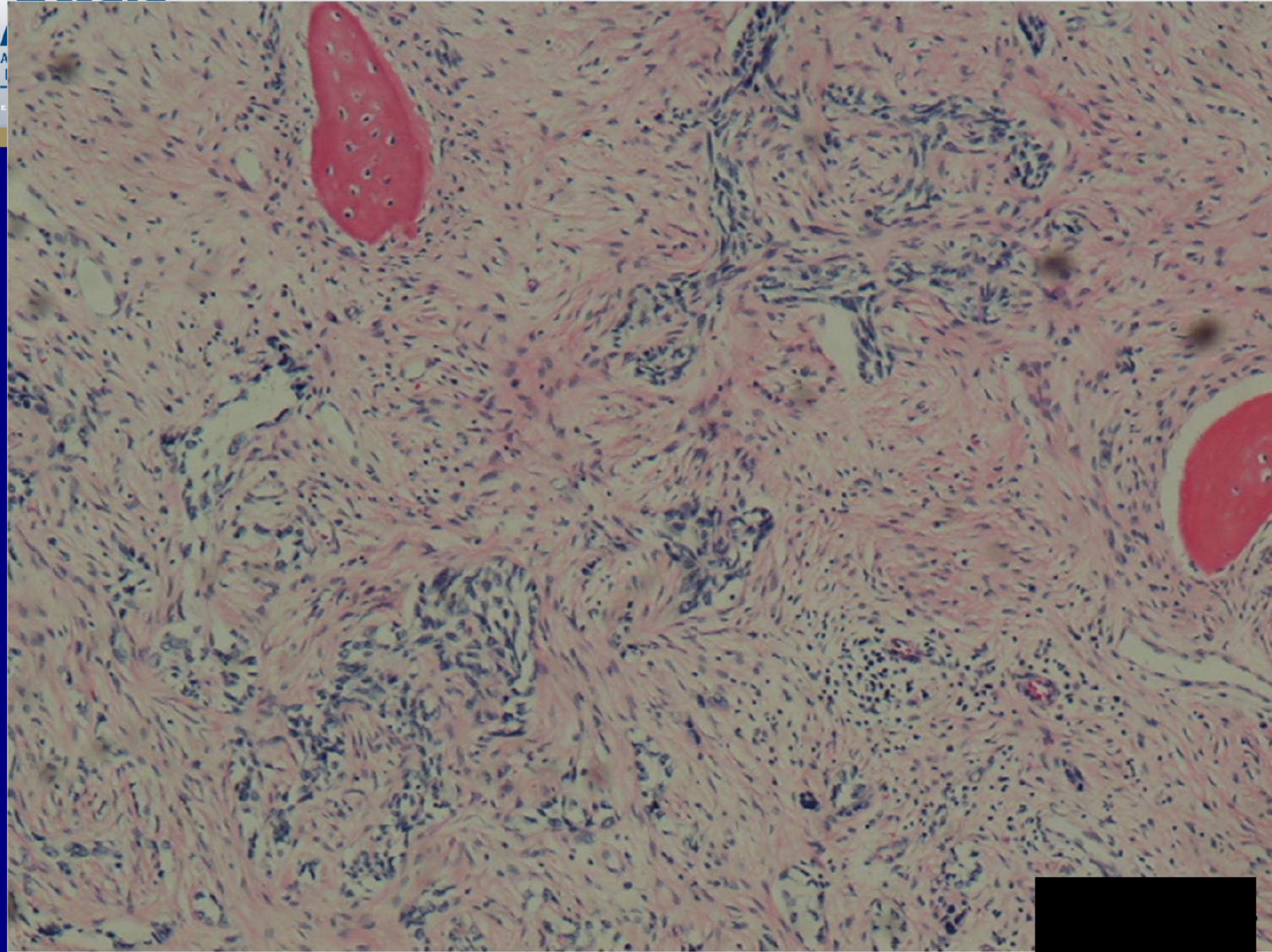


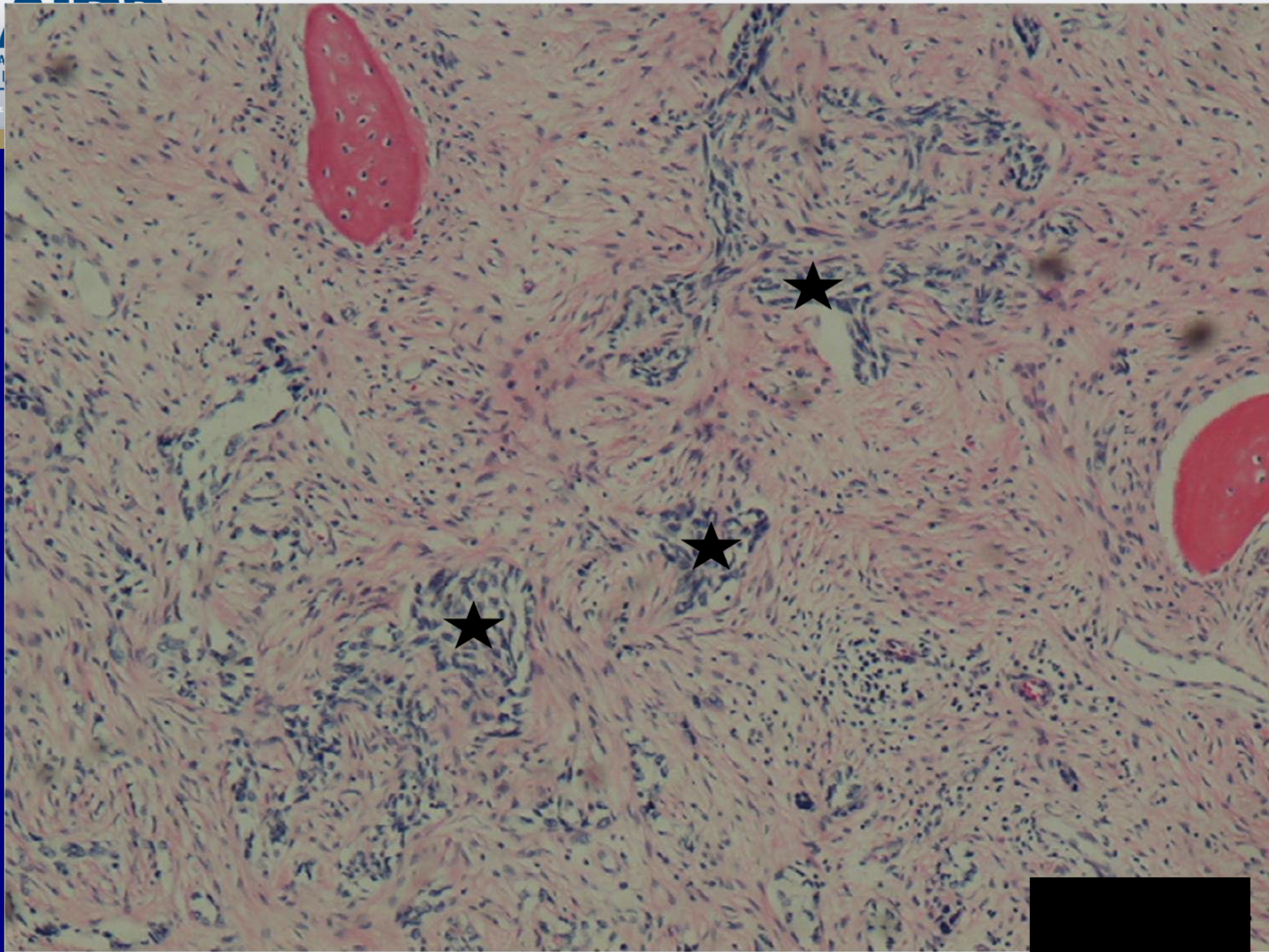



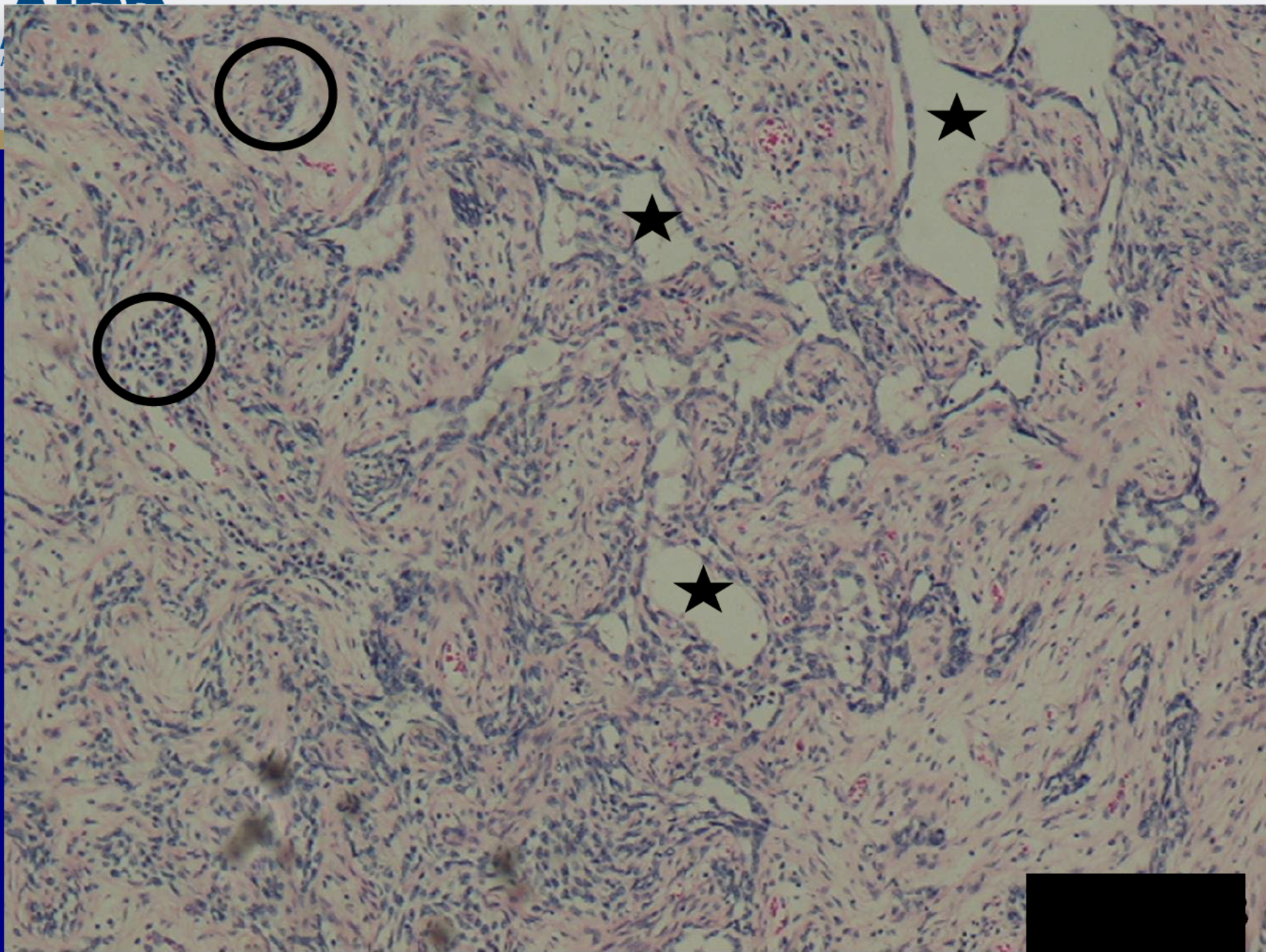


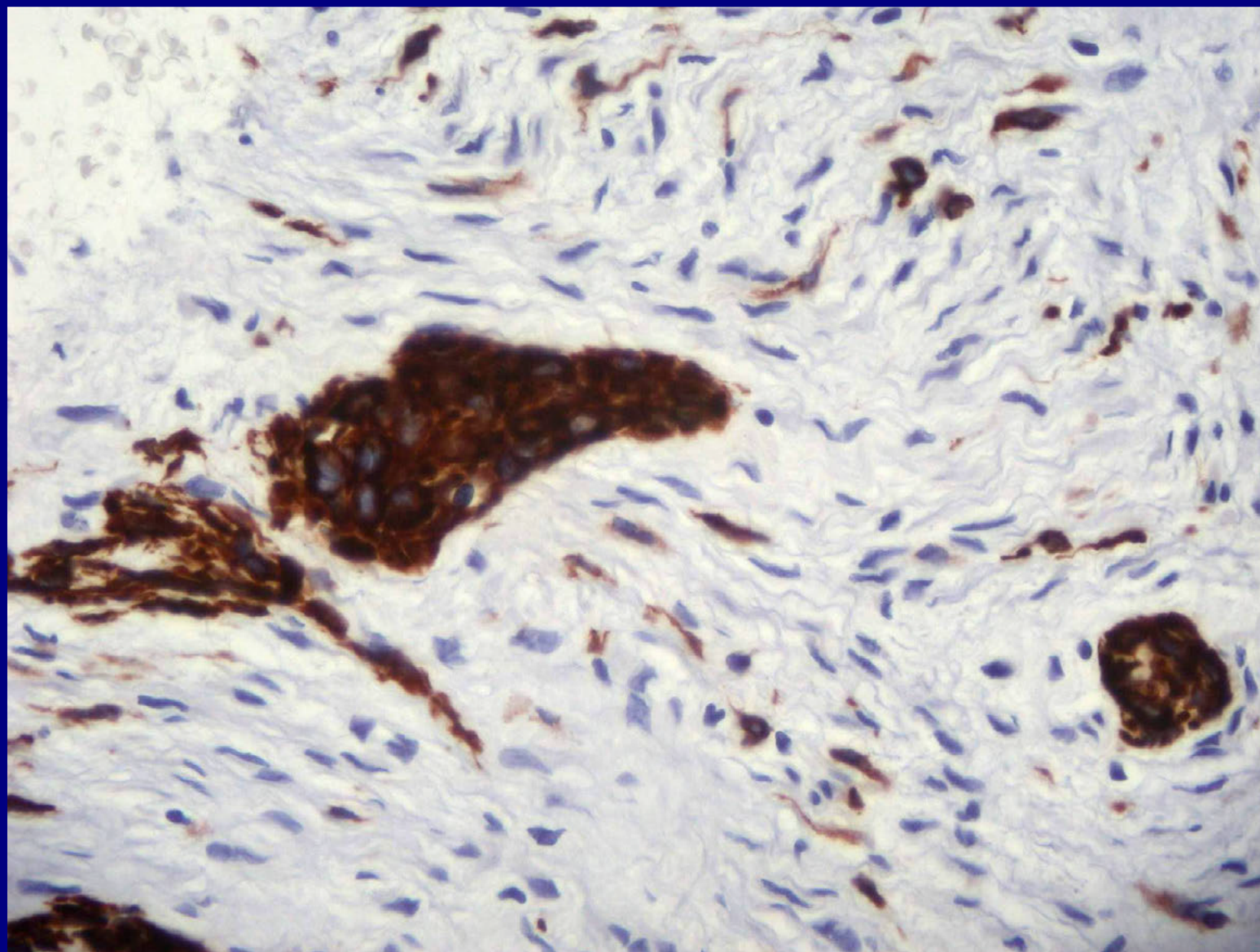












Adamantinoma

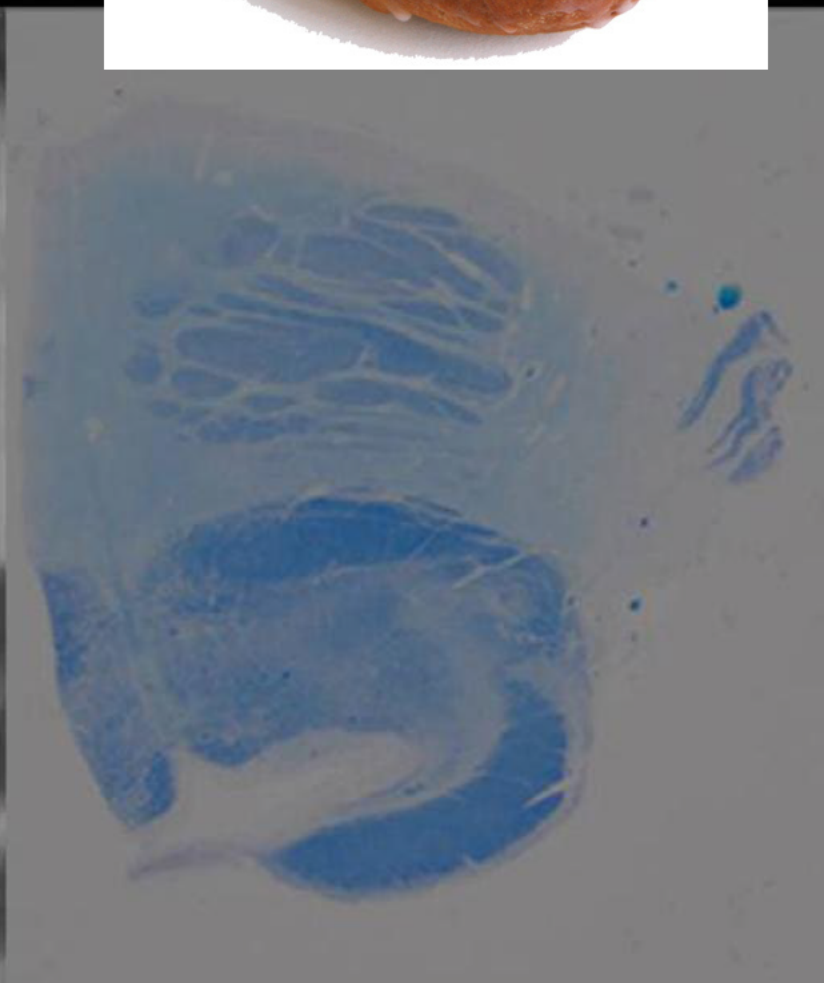
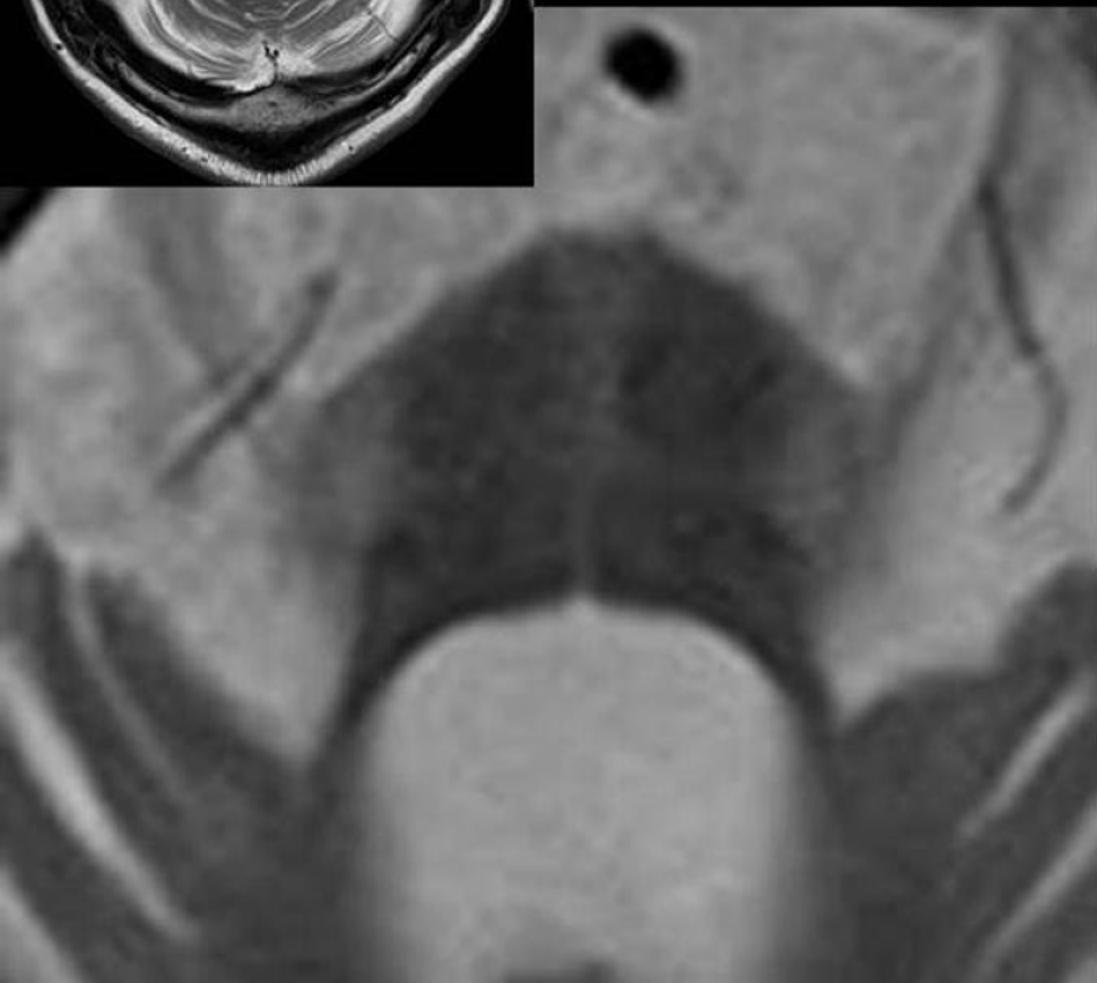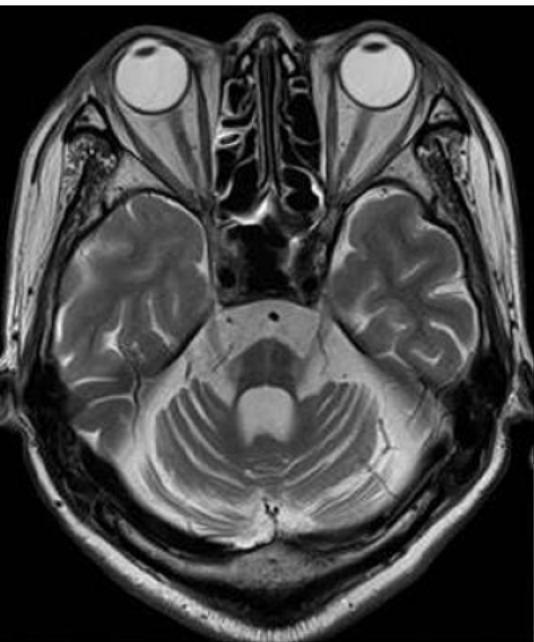Anilawan Smitthimedhin, MD

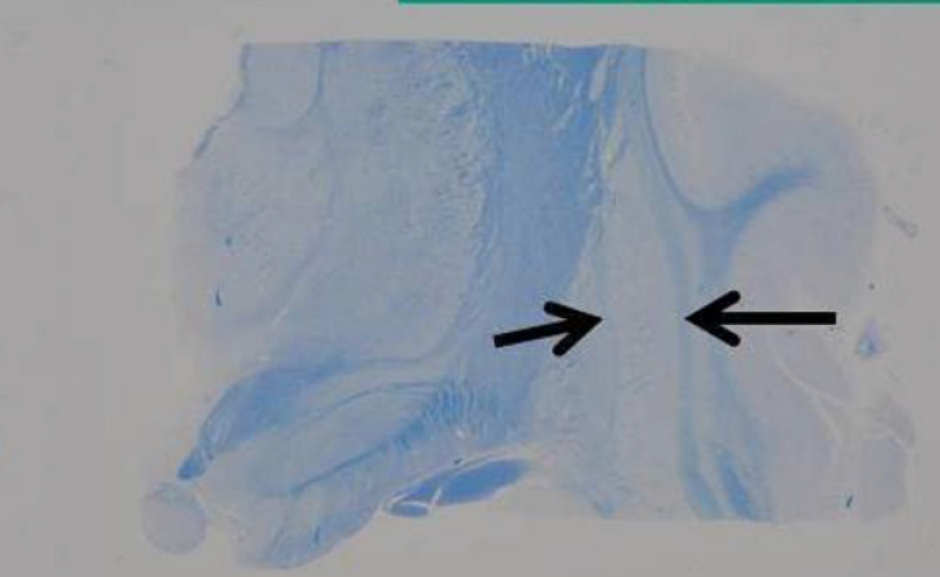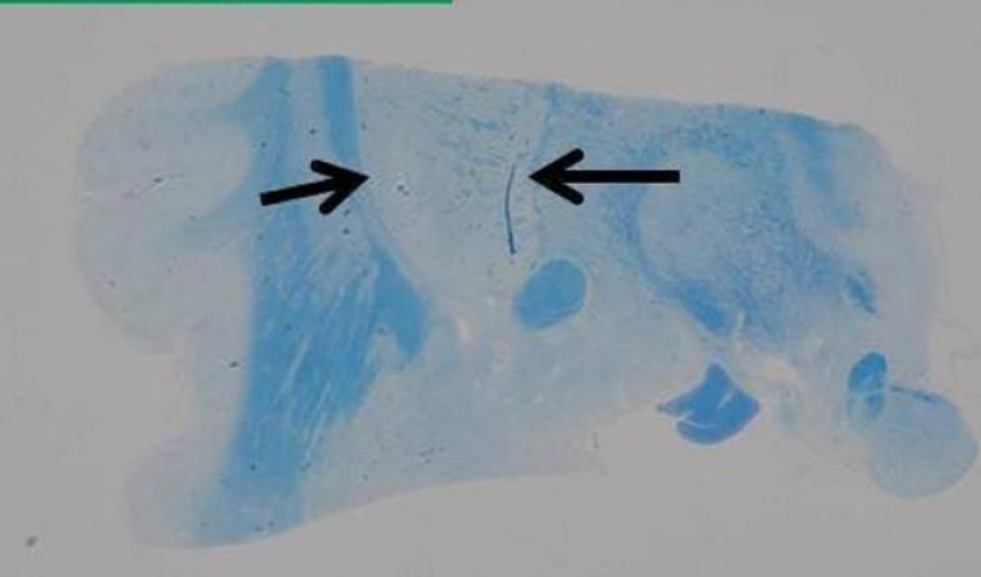
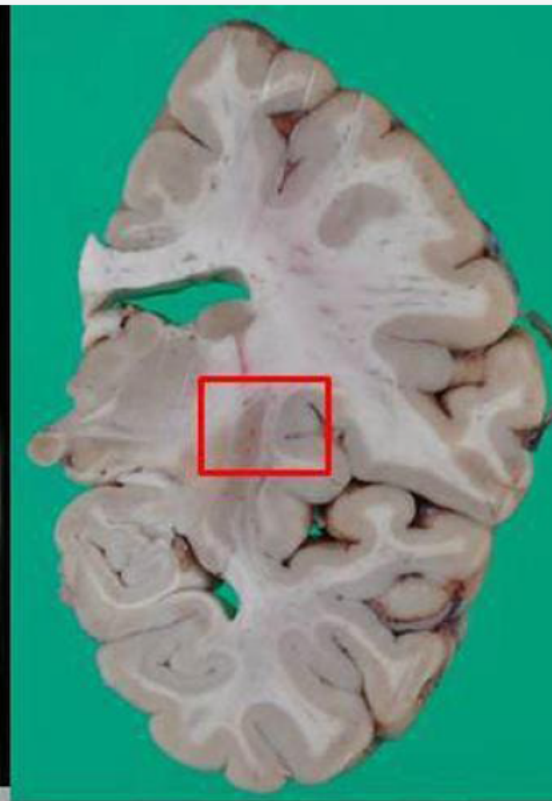
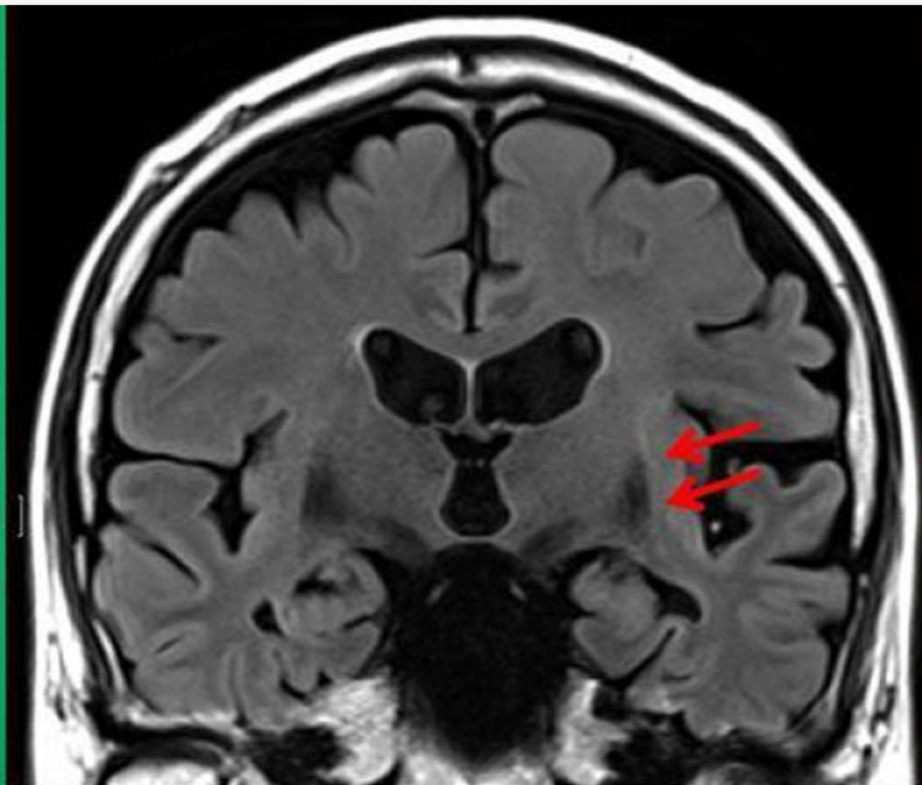
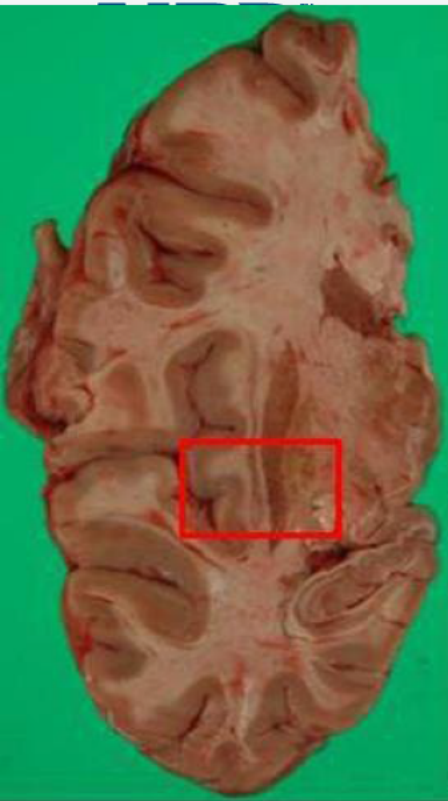Mahidol University

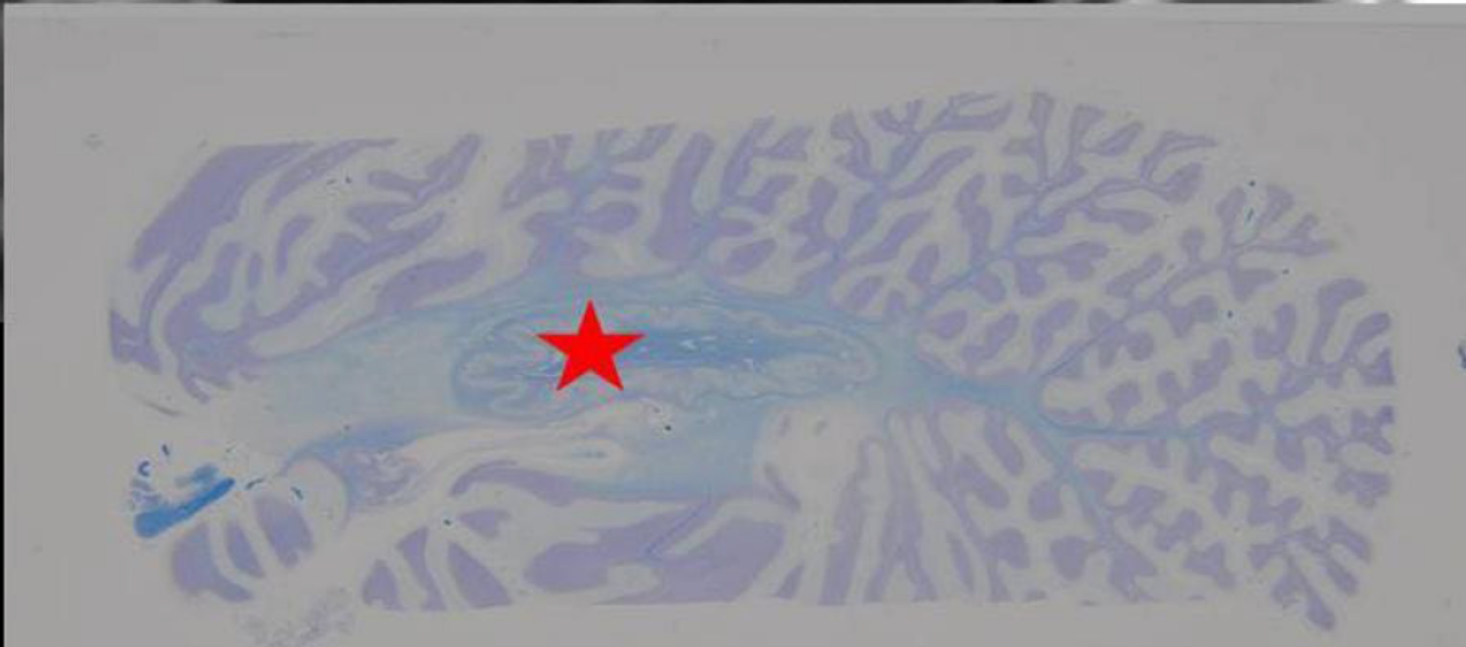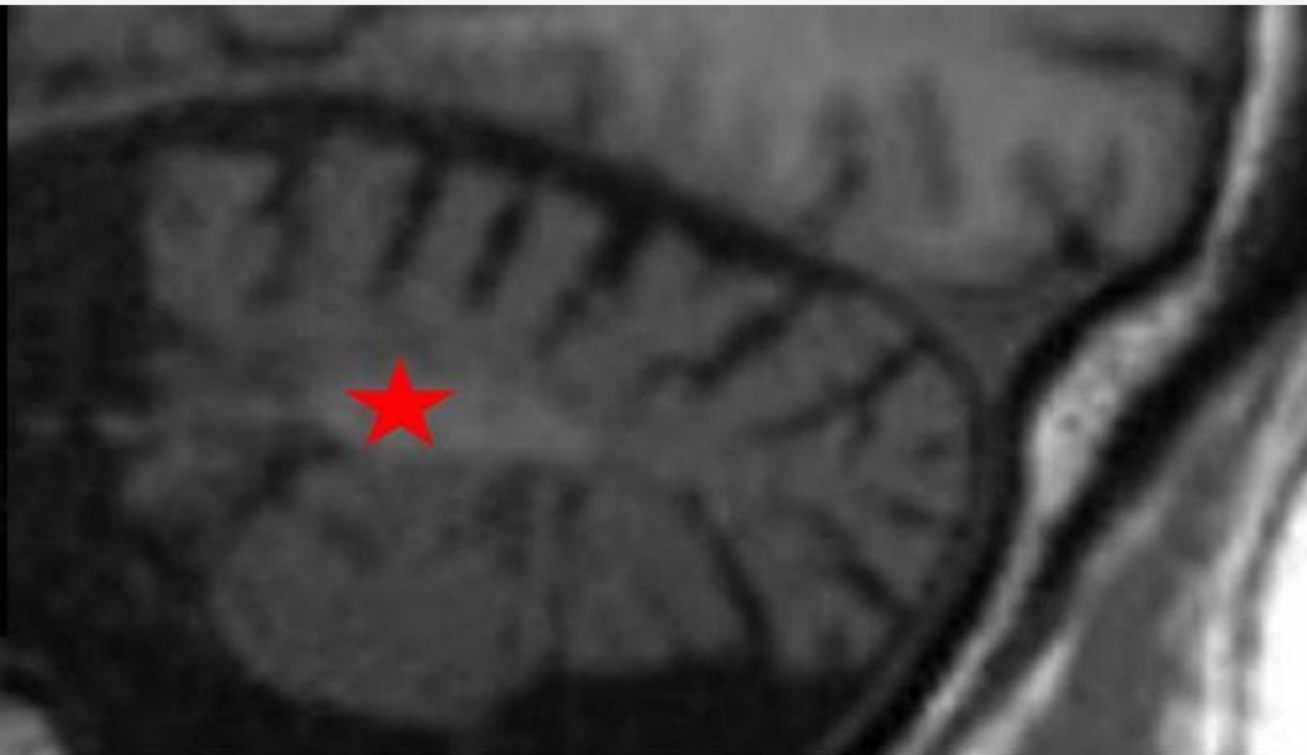
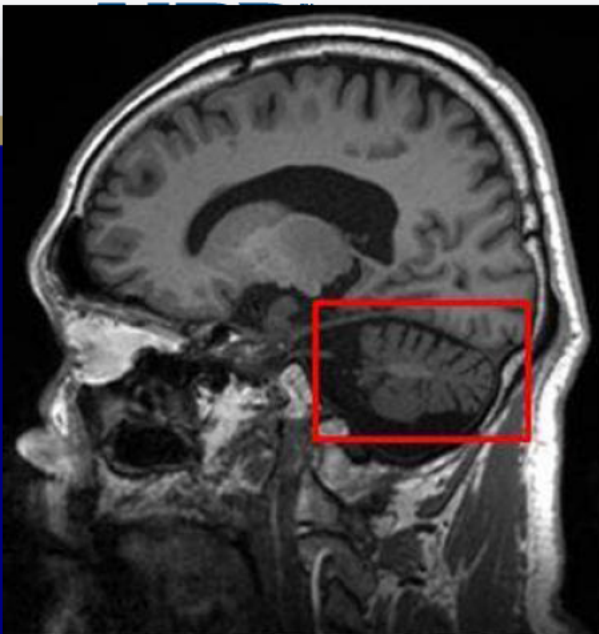
Nakhon Pathom, Thailand

Neuroradiology Best Case

A 67-year-old male presented at age 59 with trembling gait, slurred speech and excessive perspiration as well as inability to write and drive. At 60, he underwent MRI which detected cerebellum and brain stem atrophy. He frequently experienced orthostatic fainting. At 64, he was unable to walk and due to his mobility impairments he started using a wheelchair. At home at the age of 67 he passed away.







Multisystem Atrophy-C

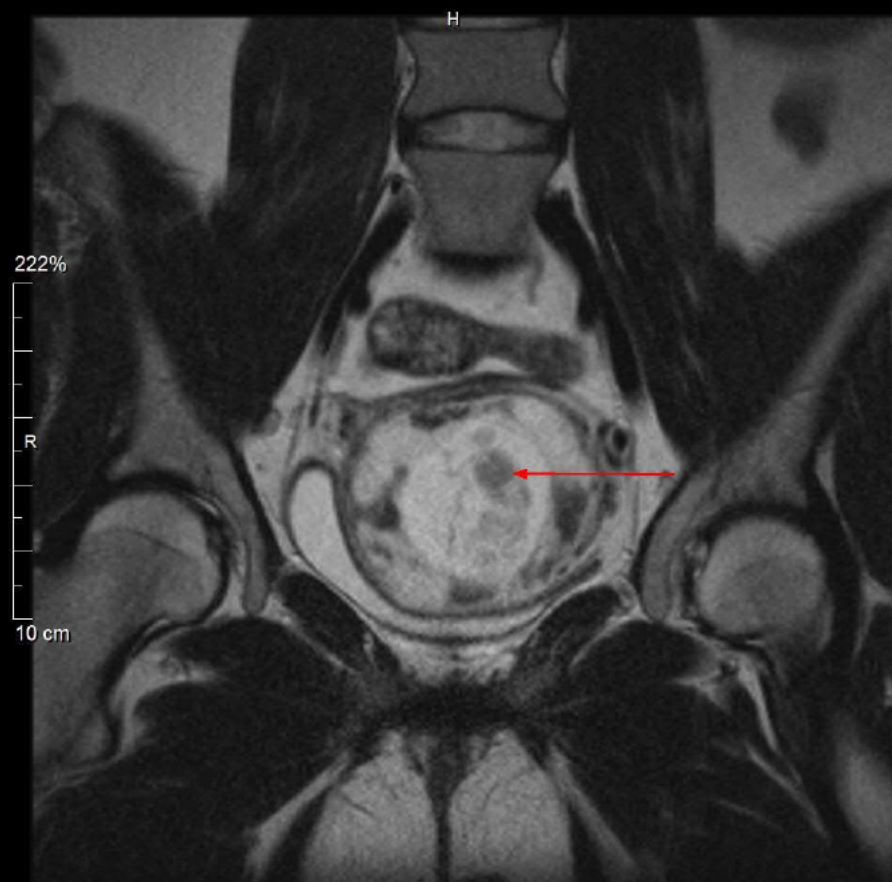
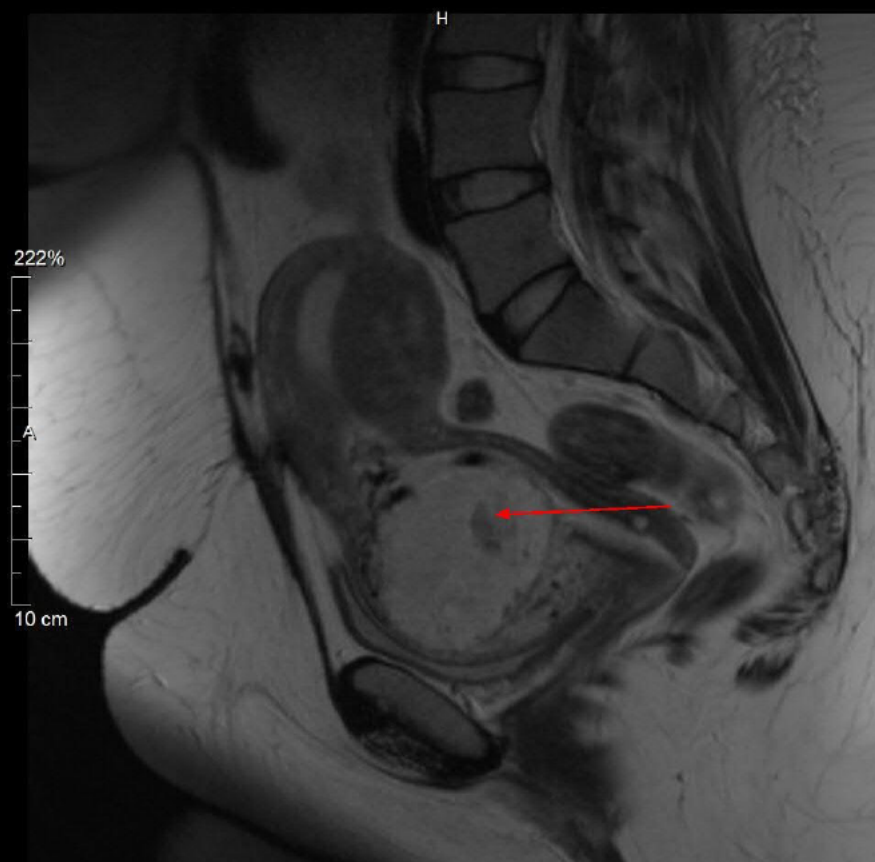
Kimiteru Ito, MD

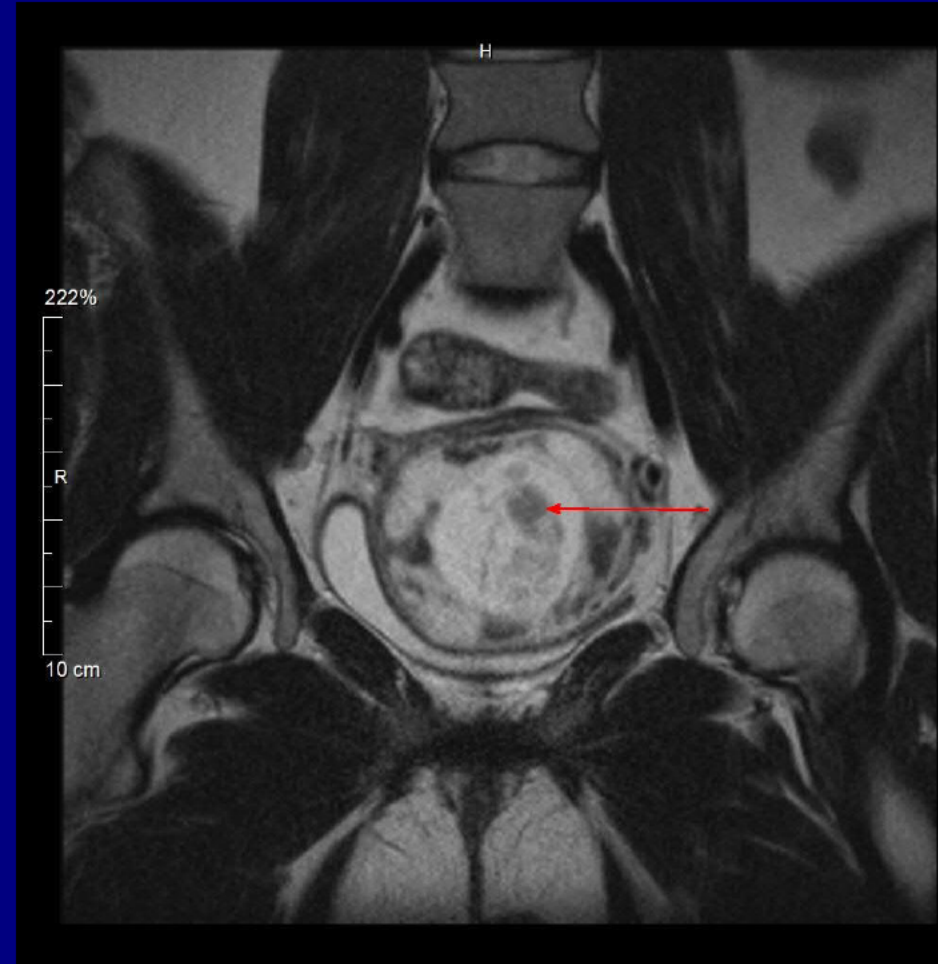
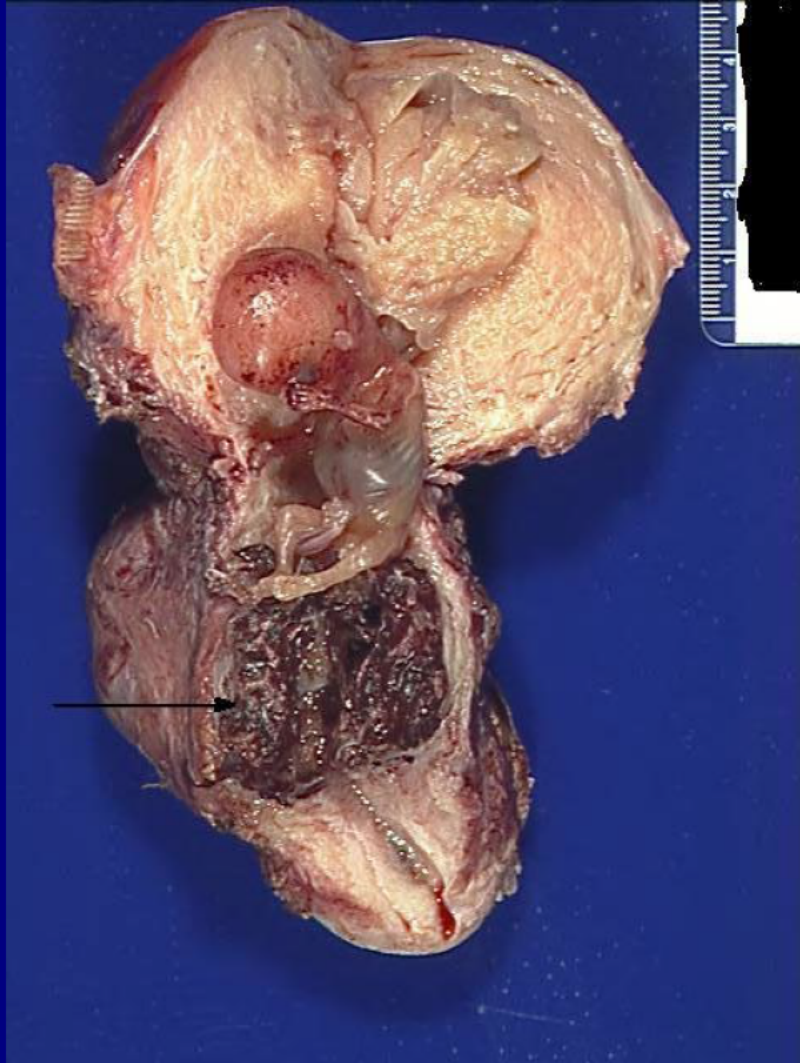
Japanese College of Radiology Fellowship

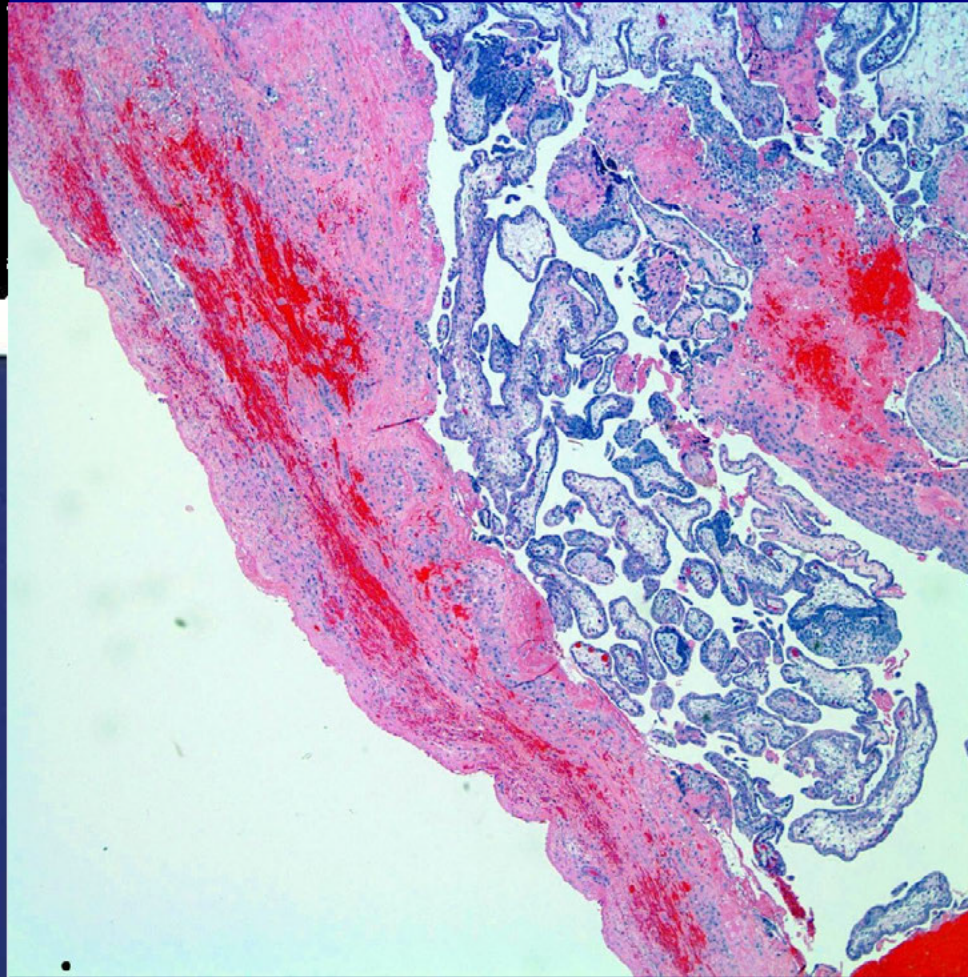
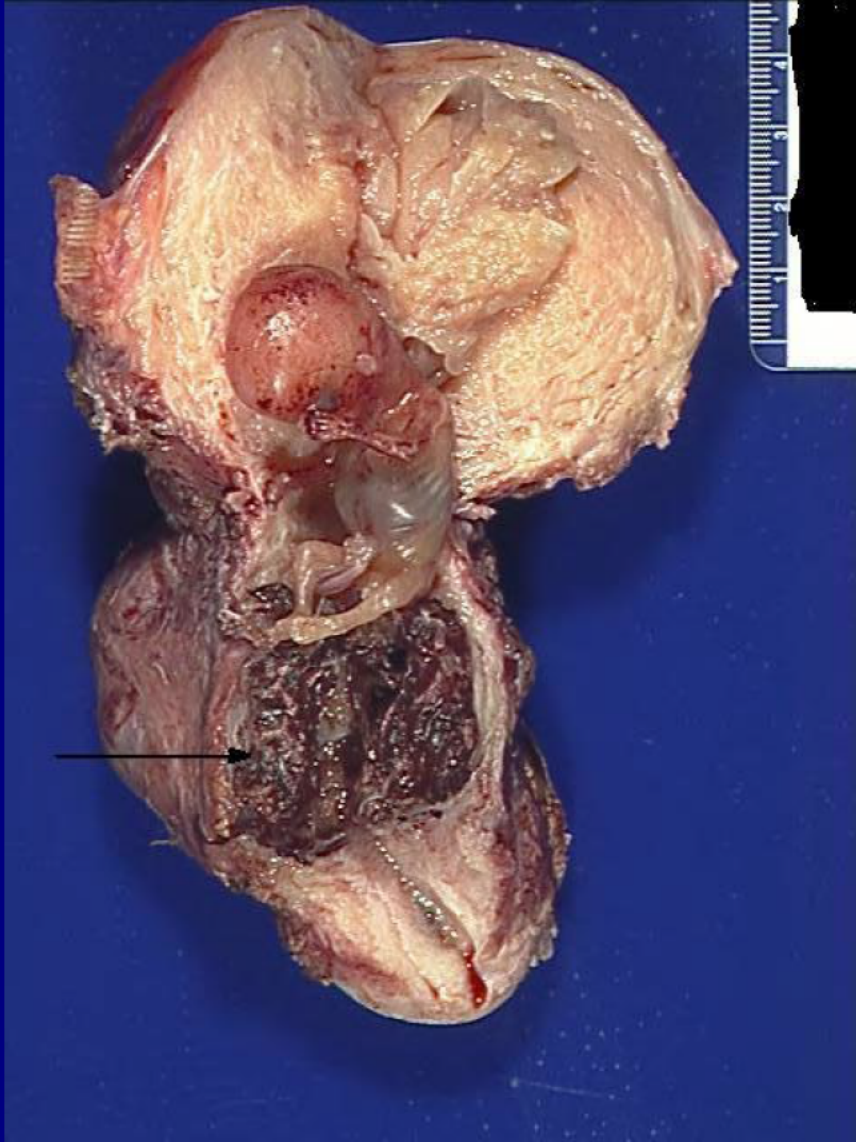
Tokyo, Japan

Genitourinary Best Case

27-year-old female with past history of two caesarian sections at 11 weeks gestation reports 2 episodes of spotting and crampy abdominal pain



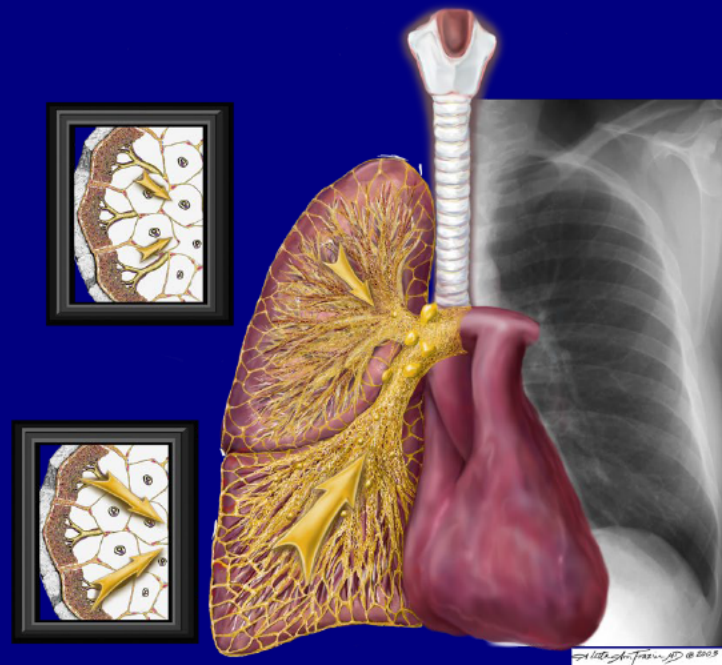




Lower Uterine Segment/Cervical Ectopic Pregnancy with Placenta Increta

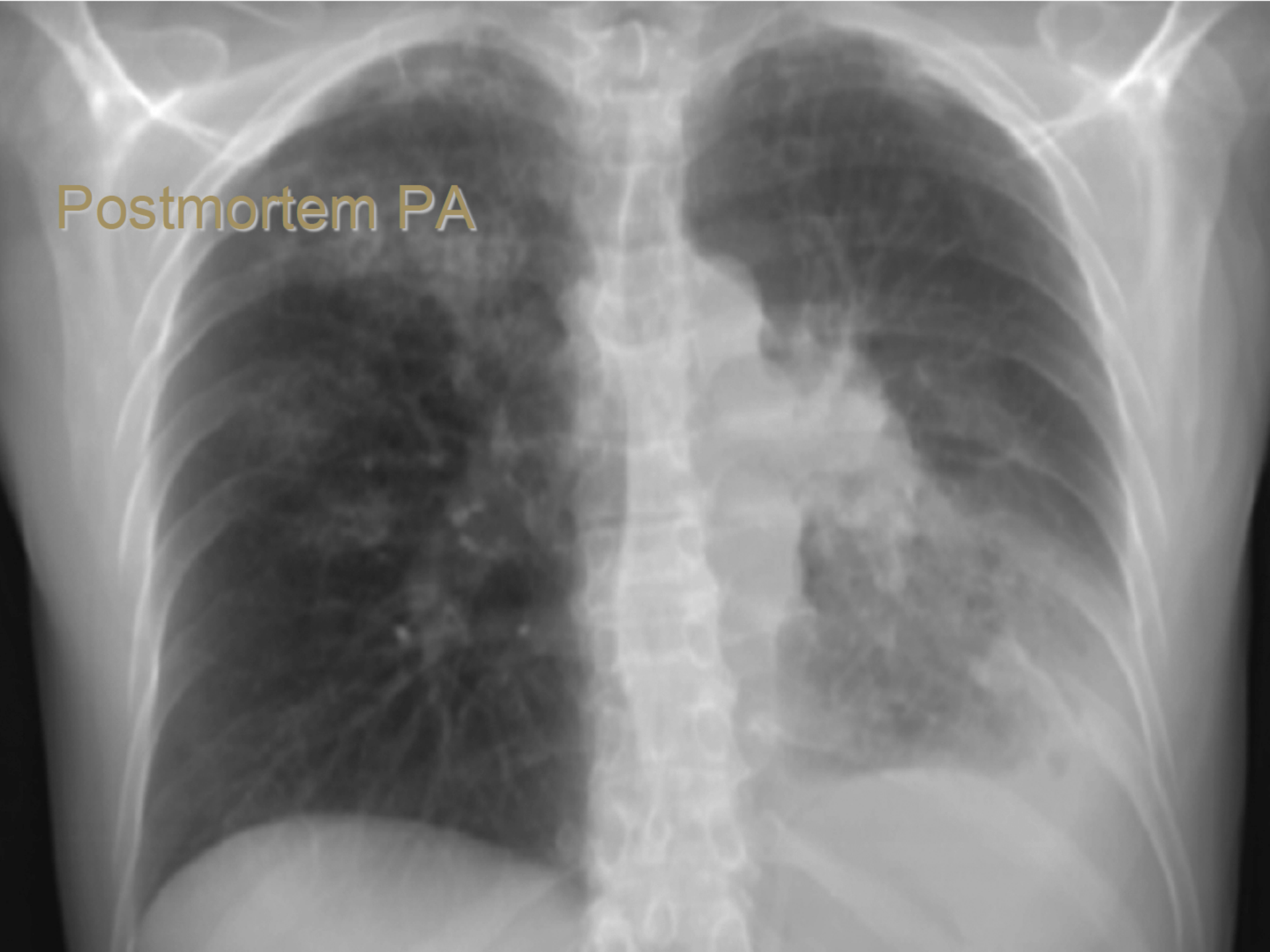
Ajay Puri, MD
Baystate Medical Center
Springfield, Massachusetts

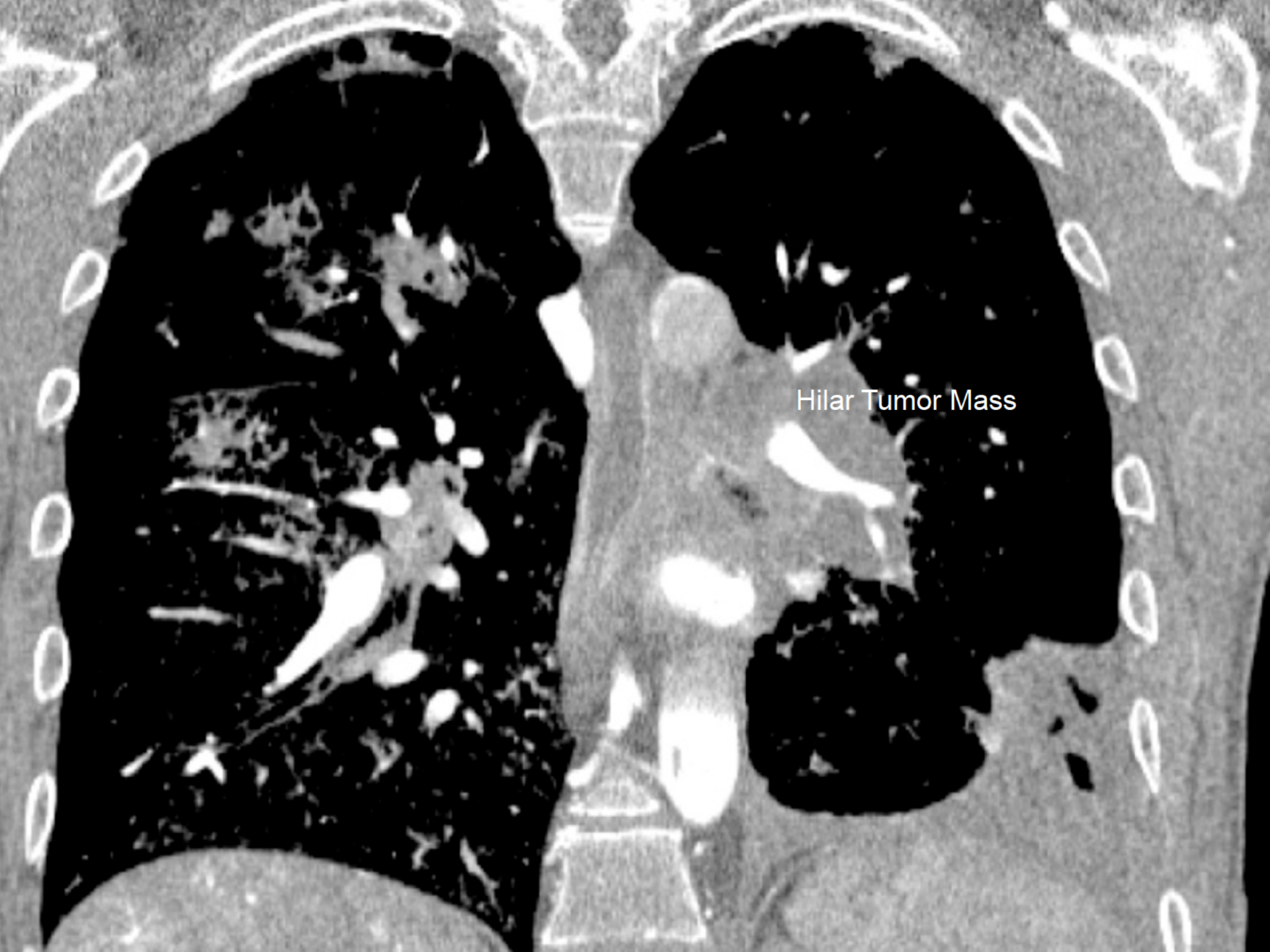
PULMONARY AND MEDIASTINAL IMAGING



52-year-old male, with known diagnosis of lung cancer, awakened coughing up blood. The patient could not be revived when brought to the emergency room.

Postmortem PA





Hilar Tumor Mass

Postmortem CT Angio

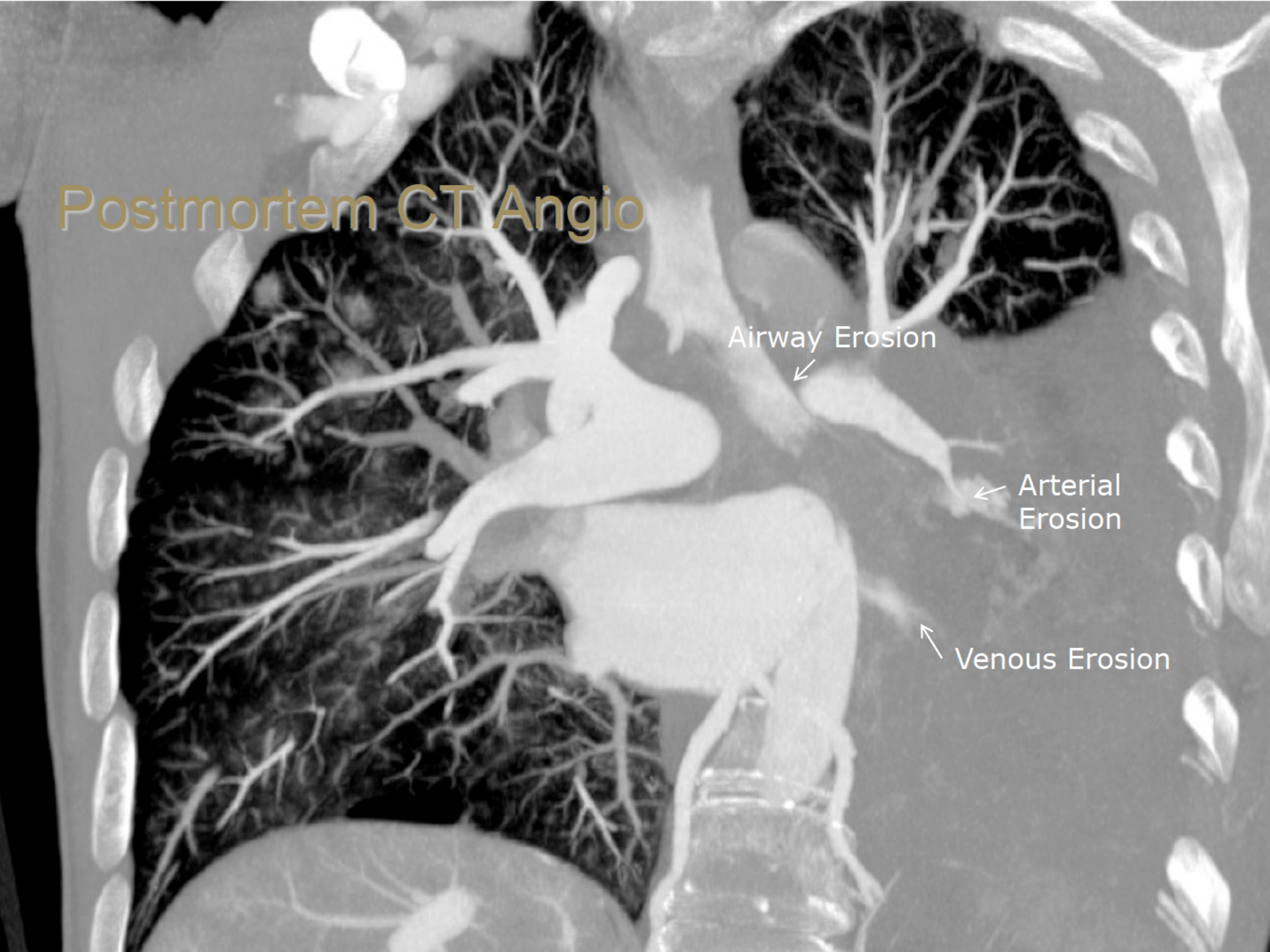
Airway Erosion

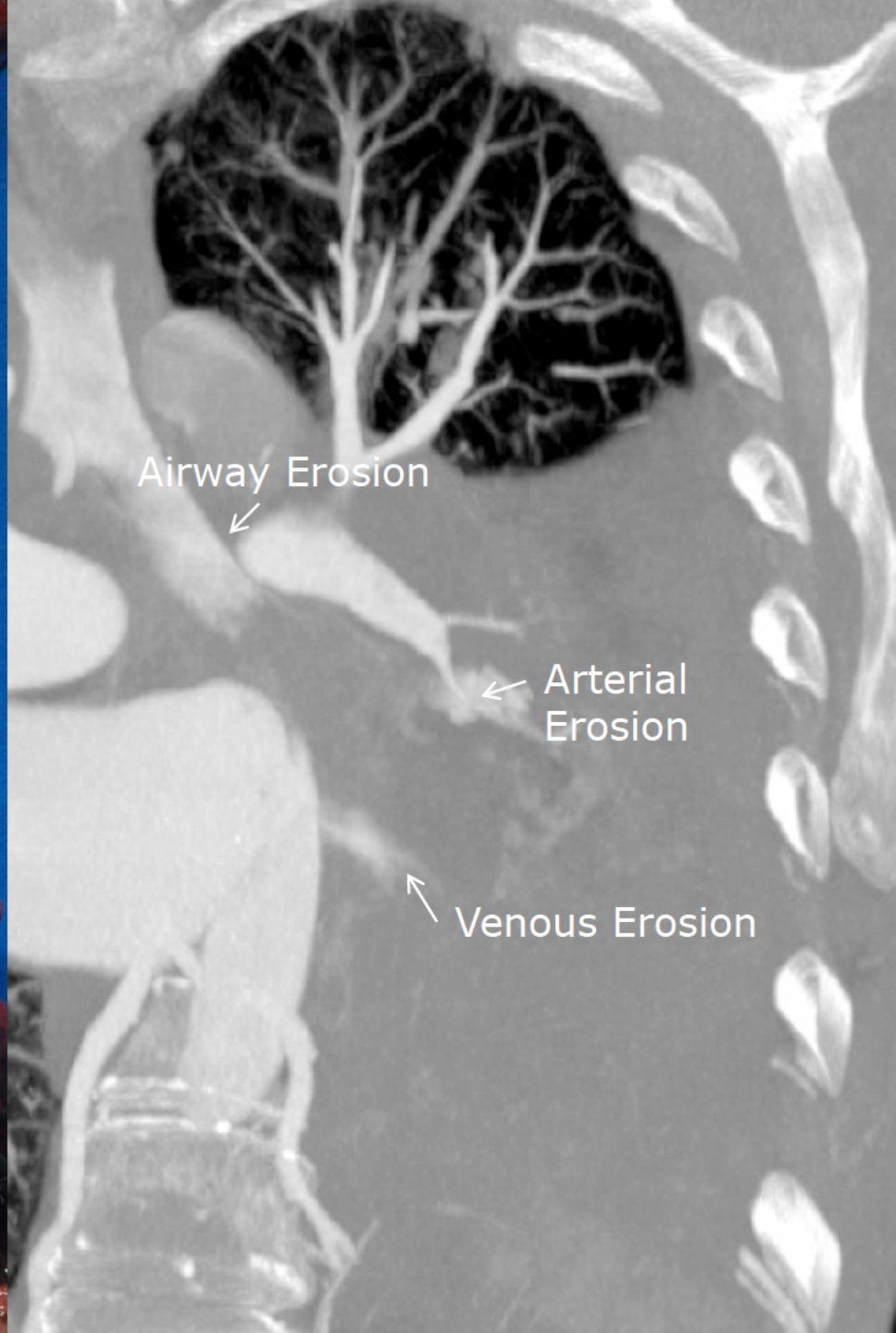
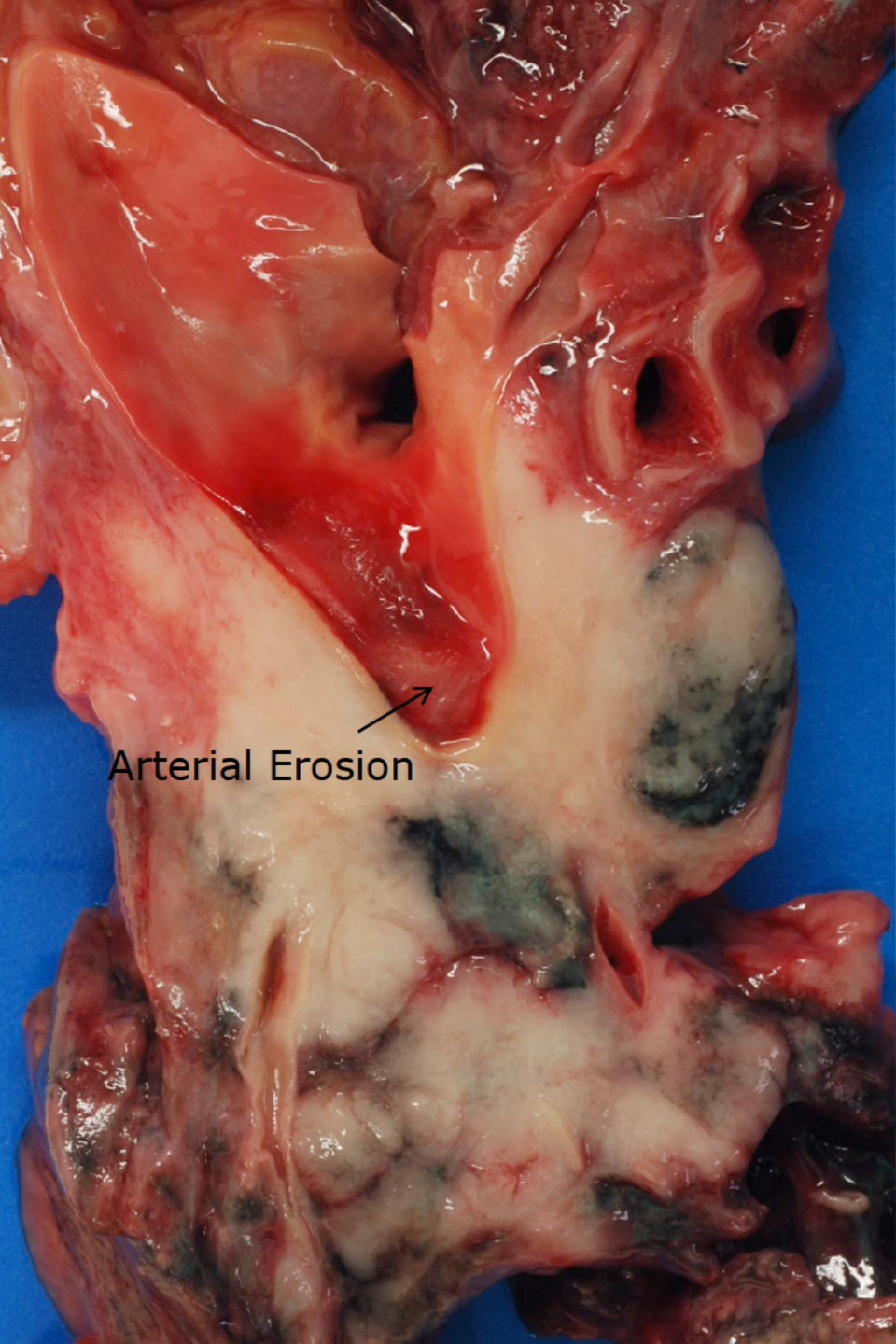

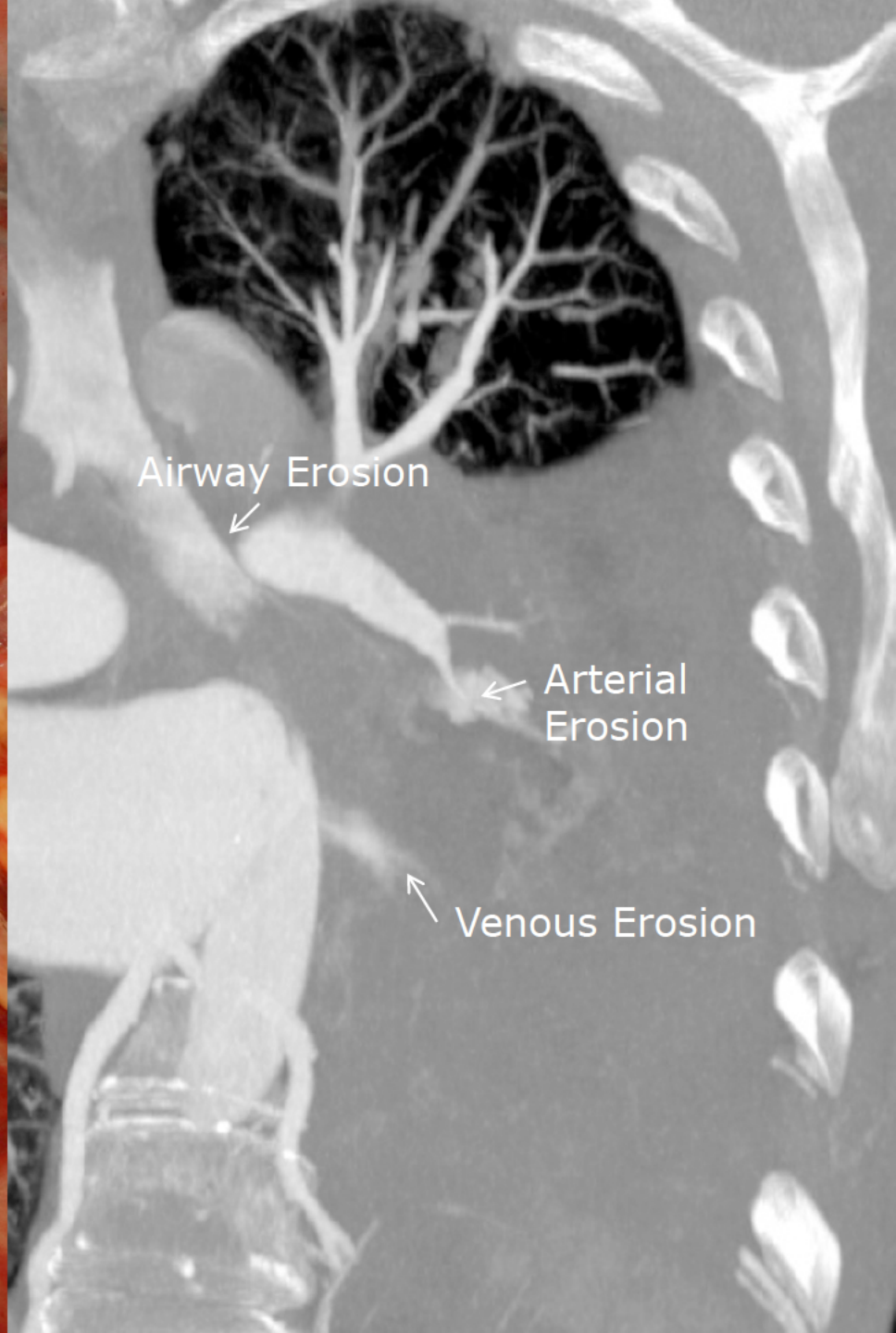
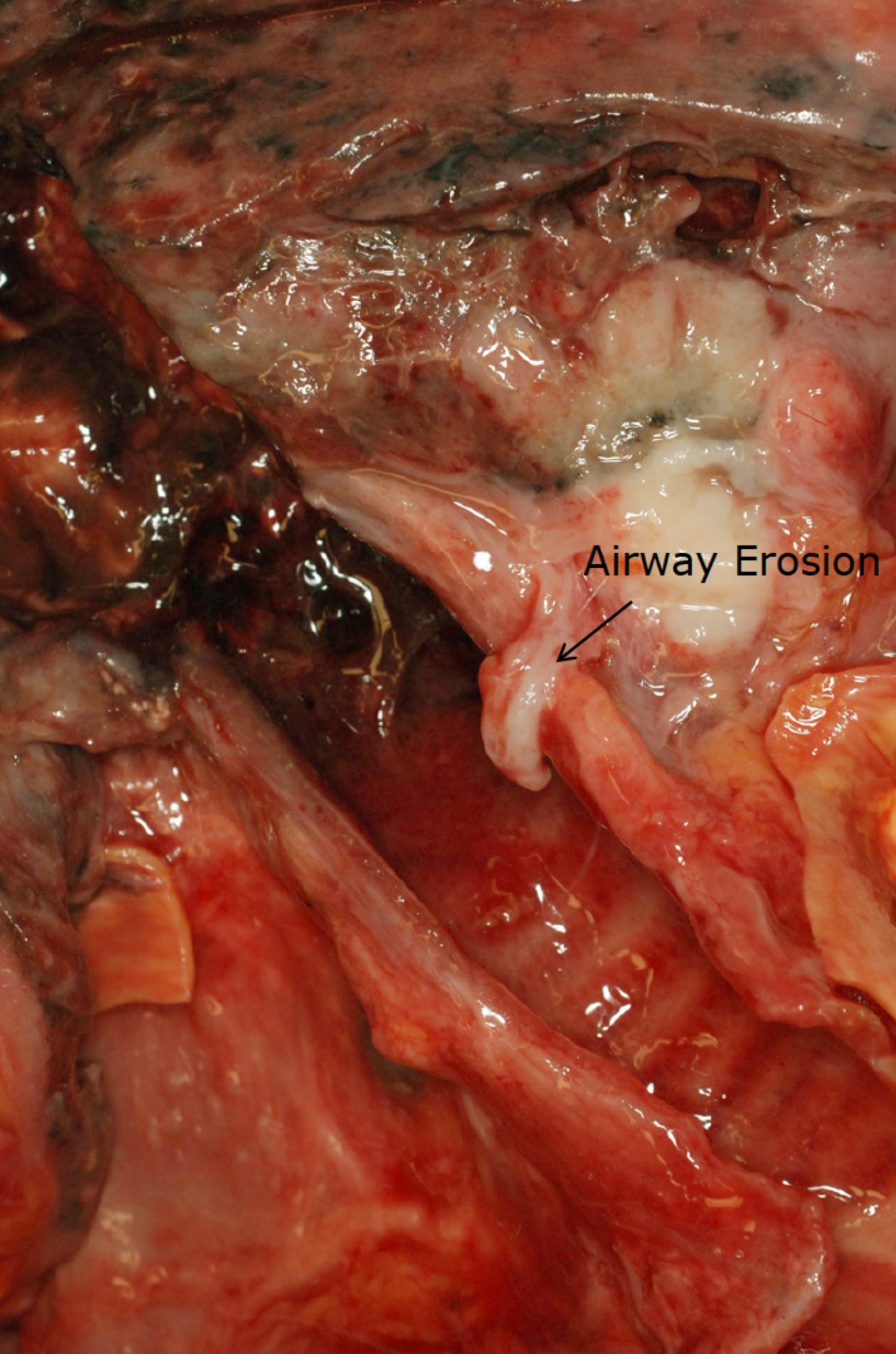
Arterial
Erosion

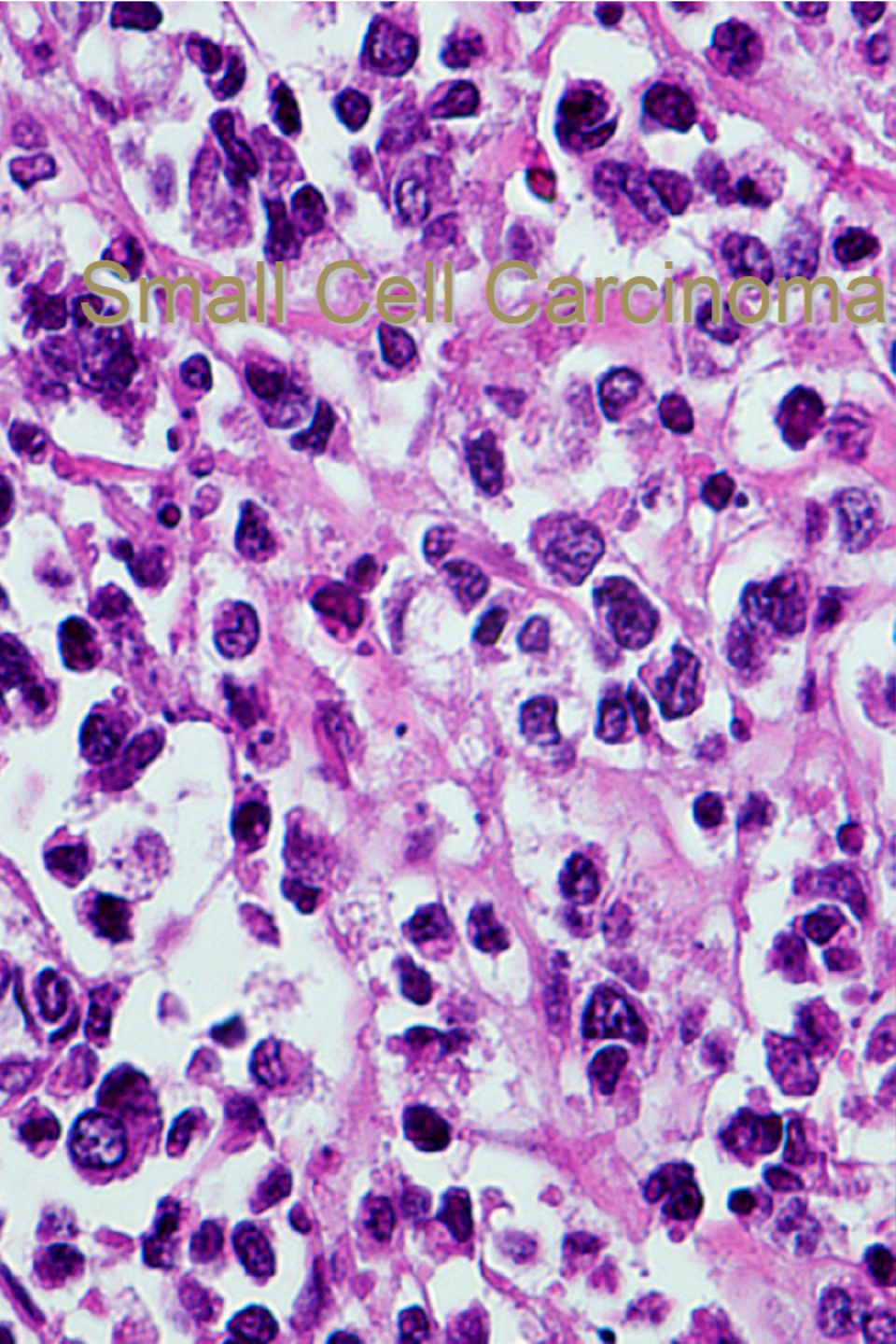


Venous Erosion

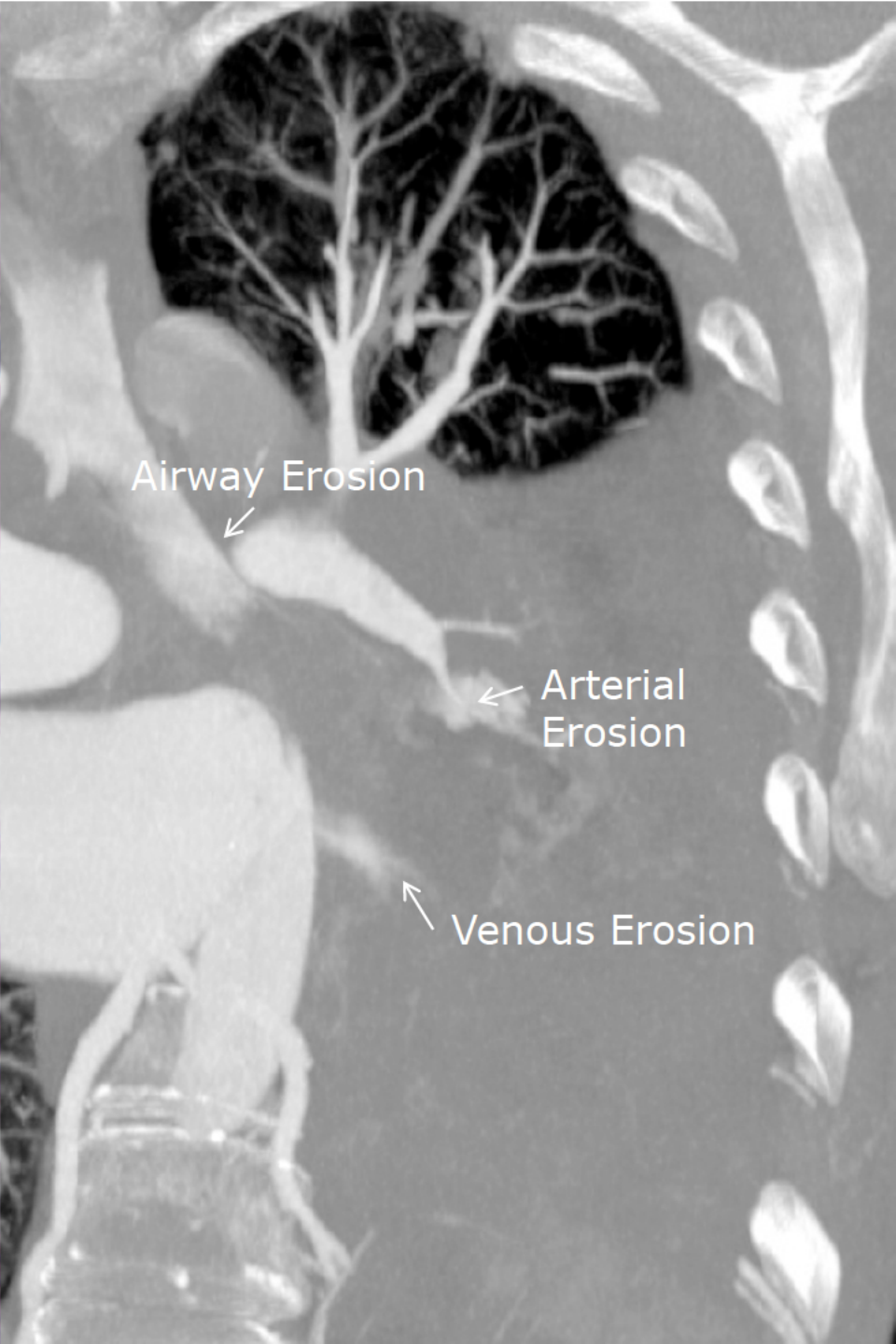








Small Cell Carcinoma



Small Cell Lung Cancer

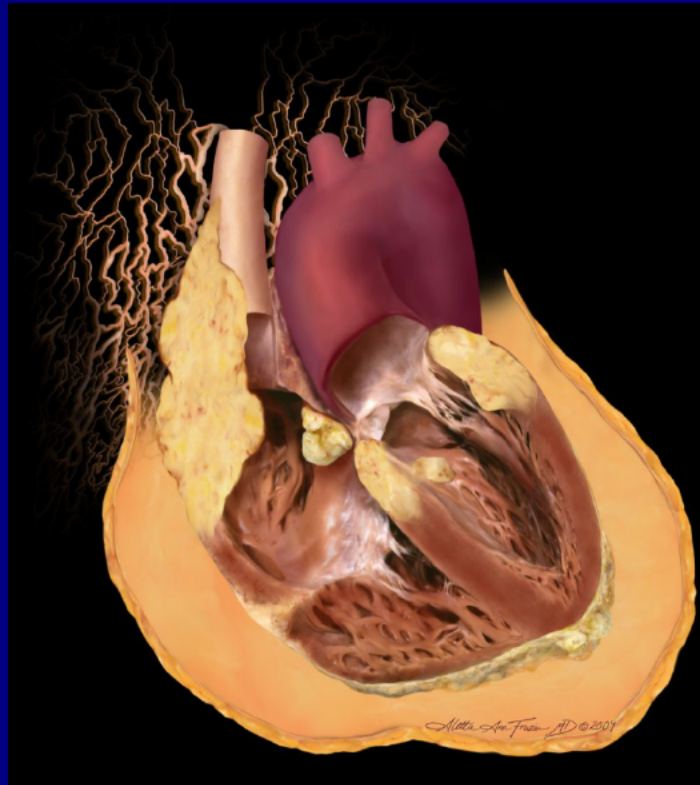Erosion of the pulmonary artery, vein and bronchus

Patricia Flach, MD

University of Bern

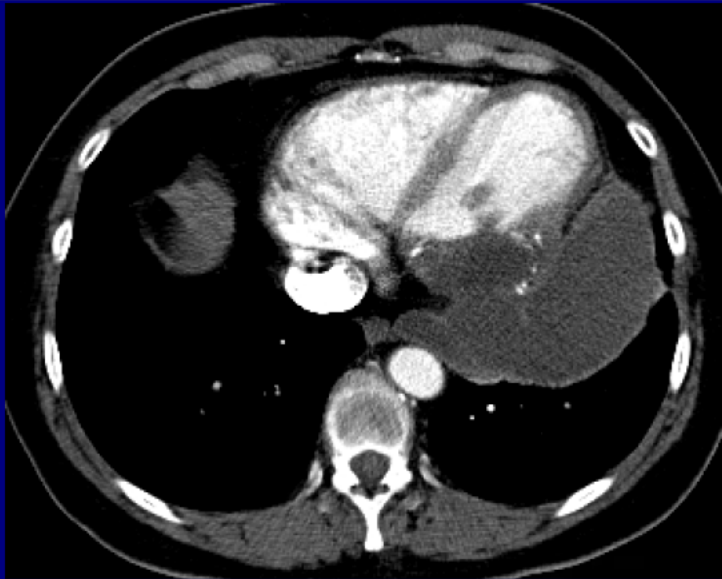
Bern, Switzerland

Cardiovascular Imaging

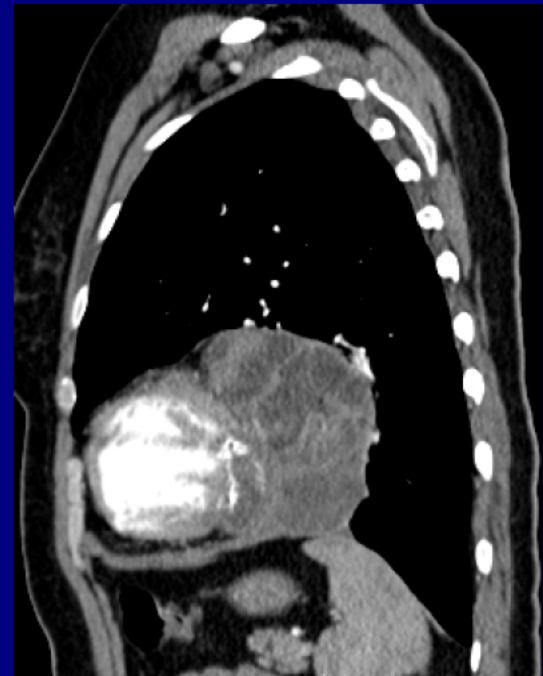
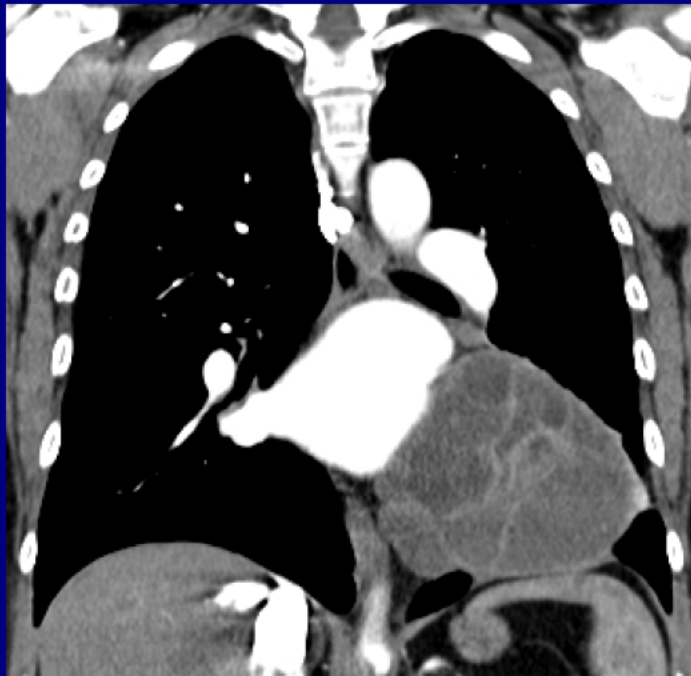

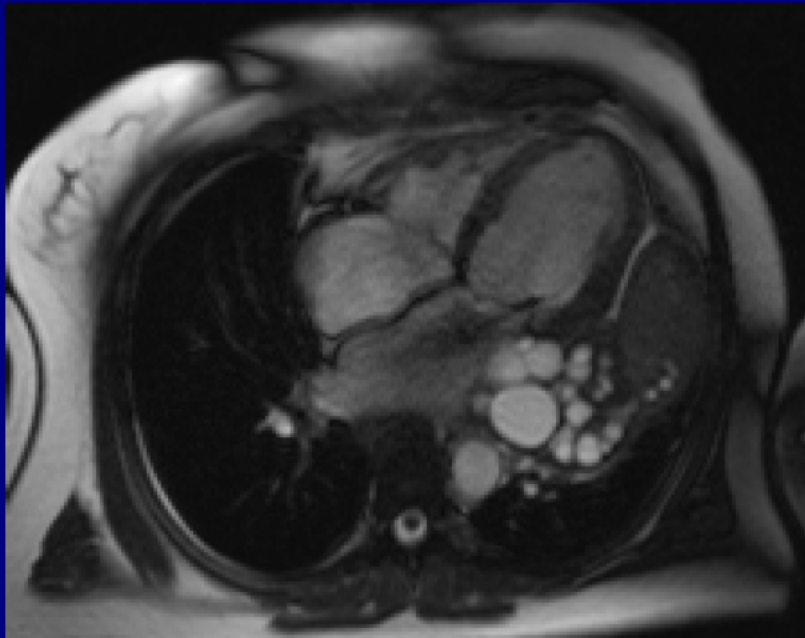
52 year old female presents to ER with two-day history of dyspnea. The patient emigrated from Romania 20 years ago.

EKG and transthoracic echocardiogram reveal atrial fibrillation and severe mitral regurgitation.

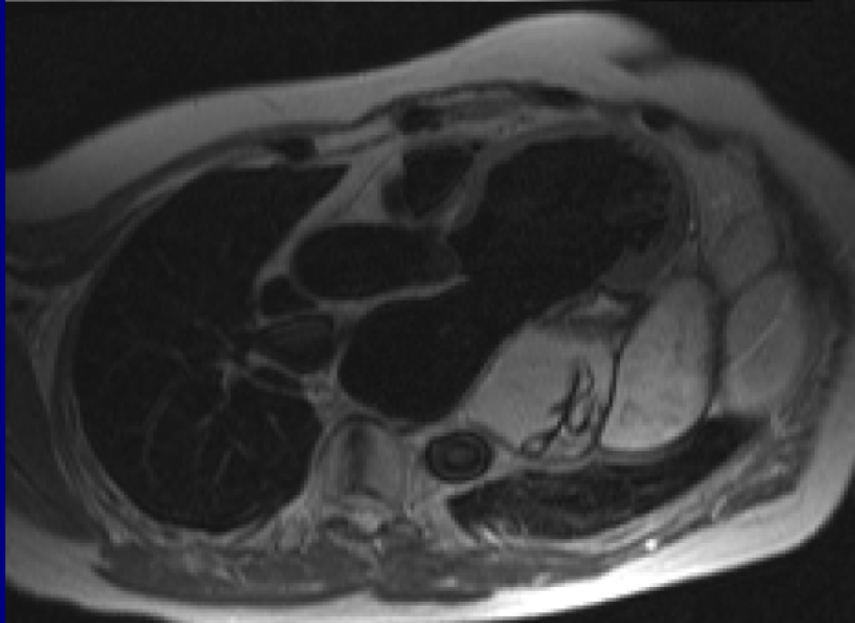


Axial, coronal & sagittal CT reformatted images confirm a complex grouping of cystic structures with punctate mural calcification associated with the left ventricle.



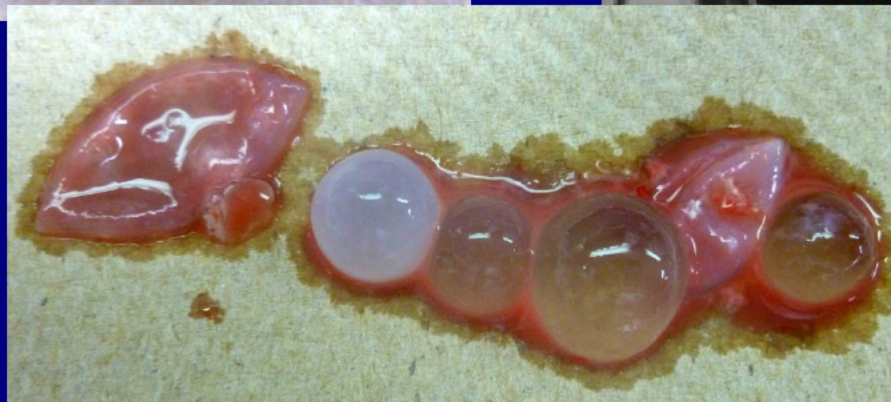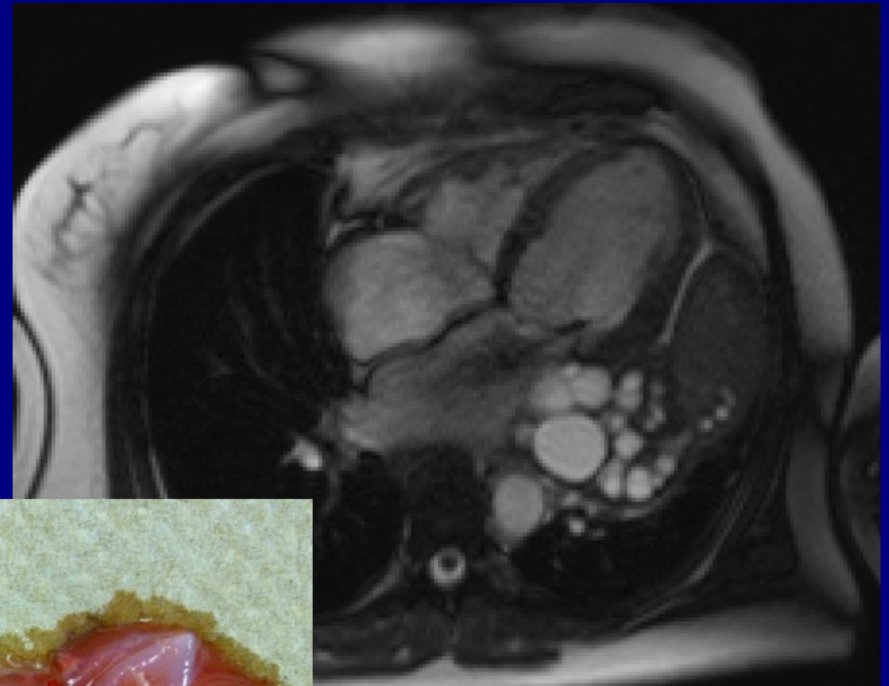

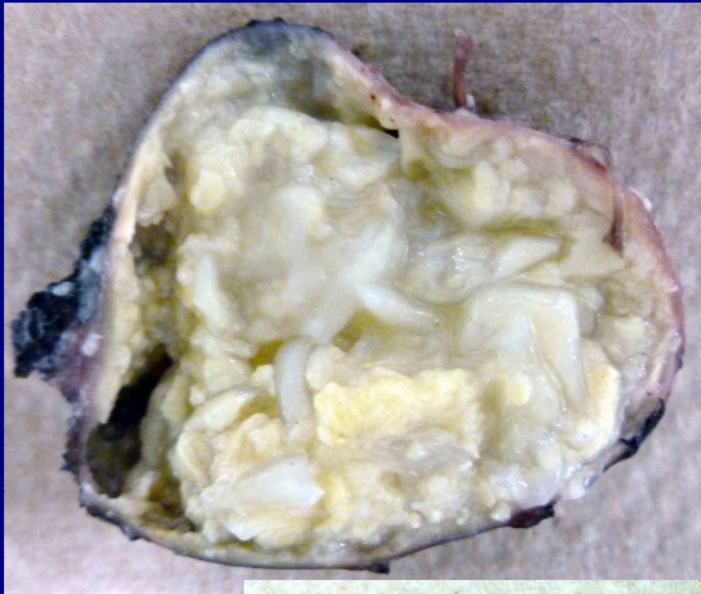
4-chamber SSFP and 3-chamber triple inversion recovery MR images of the heart demonstrate a complex, multi-septated mass invading the basal inferolateral segment of the left ventricle, resulting in mitral regurgitation.

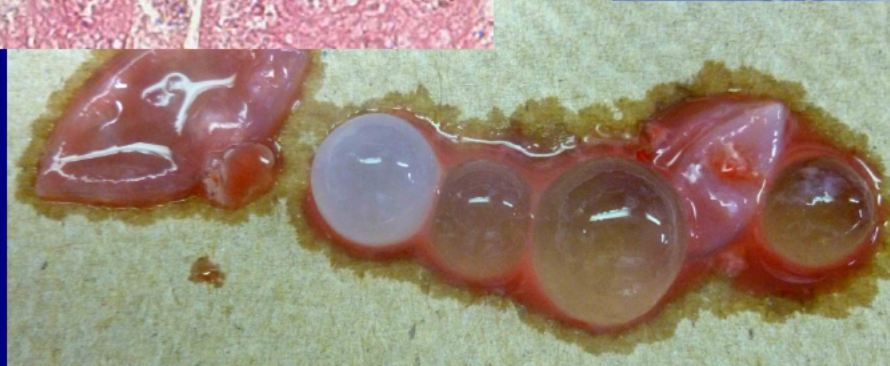

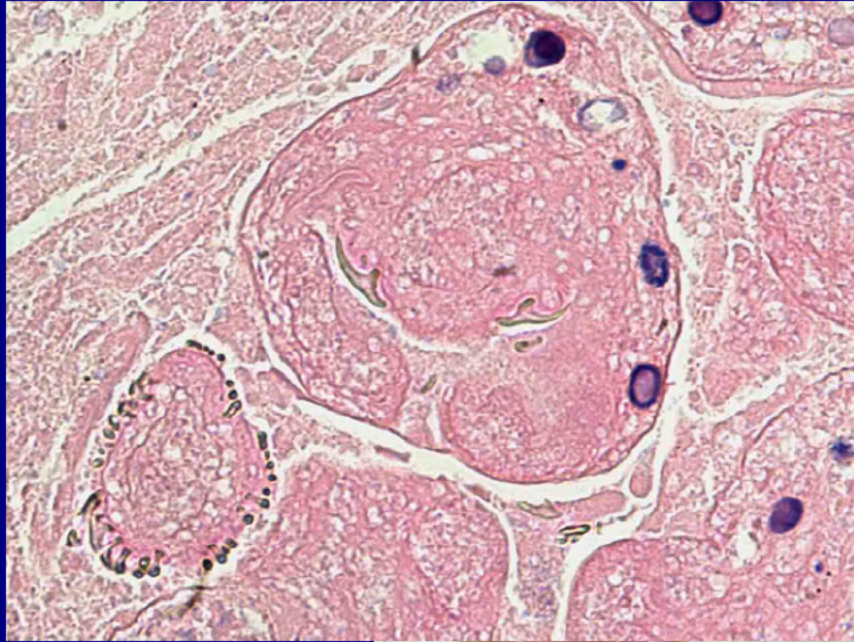


Thin curvilinear structure inside some cysts (lower image) is characteristic of daughter cyst membrane detachment.

Resected specimen shows distended and collapsed cystic structures. Some cysts are lined by fibrous tissue and polypoid lesions.



Histologic examination reveals classic hooklets of echinococcus (left, H&E) with lamellated cyst walls (right, trichrome stain).



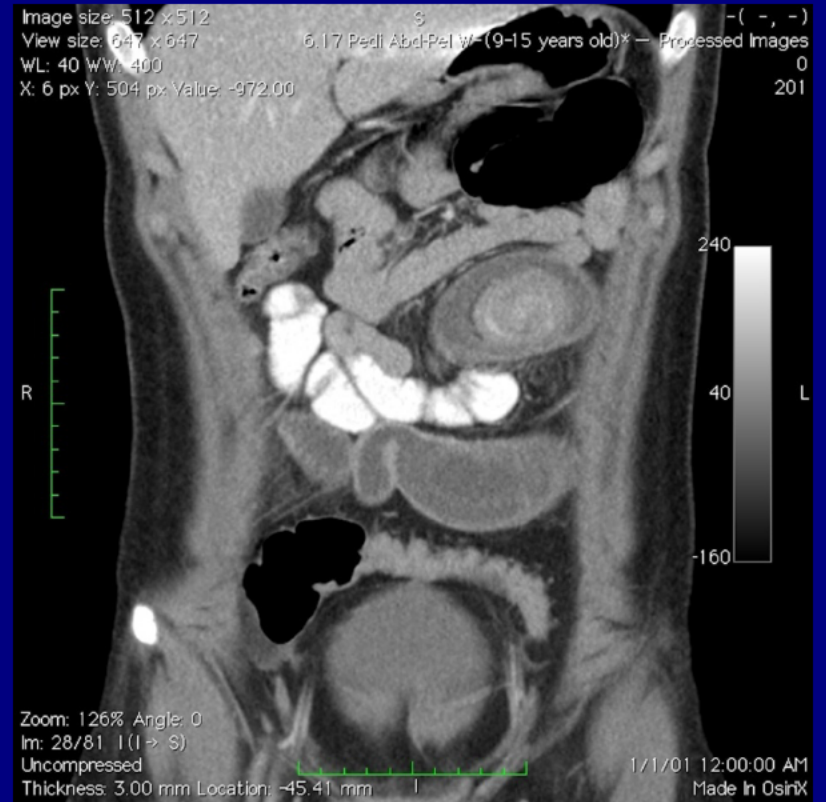
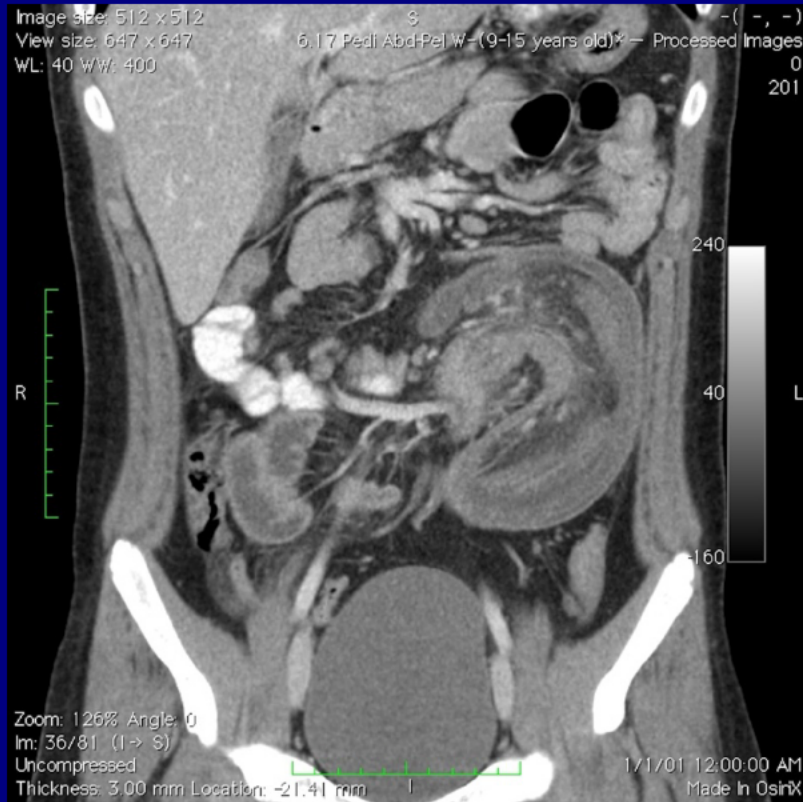
Additional history provided by the patient:
hepatic echinococcal infection
approximately 15 years ago.

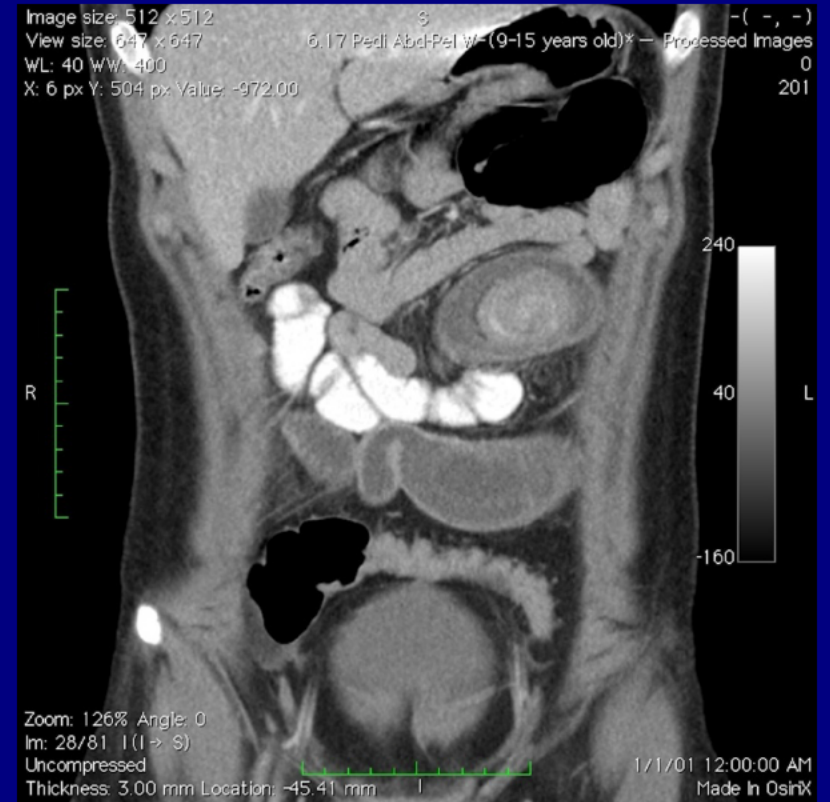
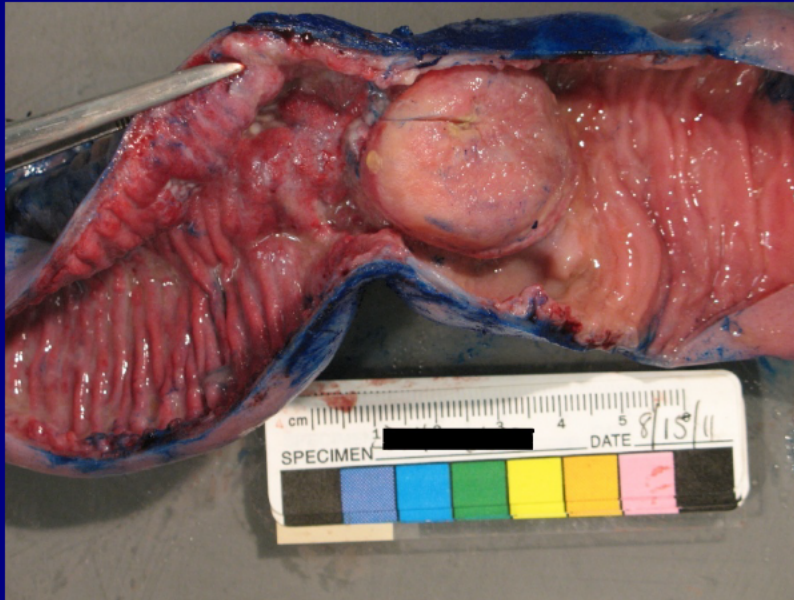Cardiac Cystic Echinococcus

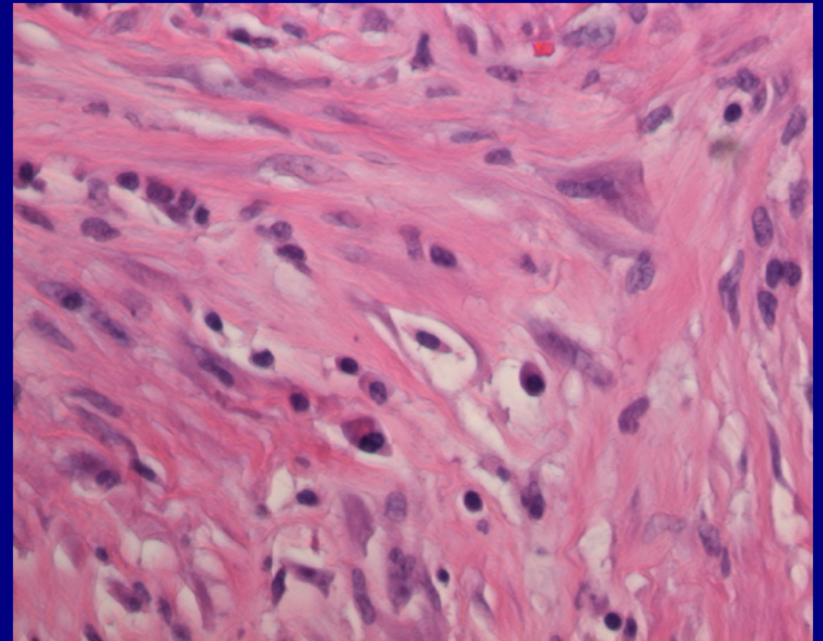
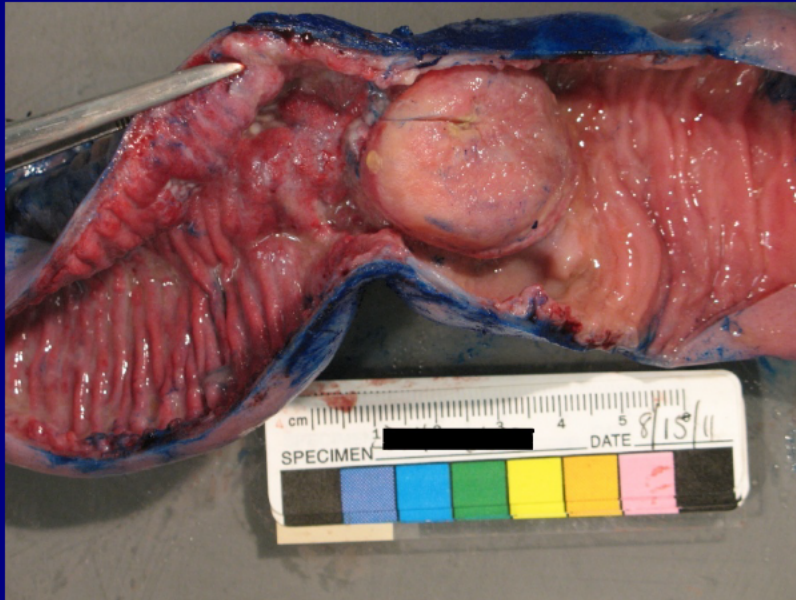Thomas Ward, MD
Mount Sinai Medical Center
New York, New York

Pediatric Best Case

15-year-old with 3 days of diffuse abdominal pain and 1 day of vomiting







Inflammatory Myofibroblastic Tumor, Intussusception

Vincent Yang, MD

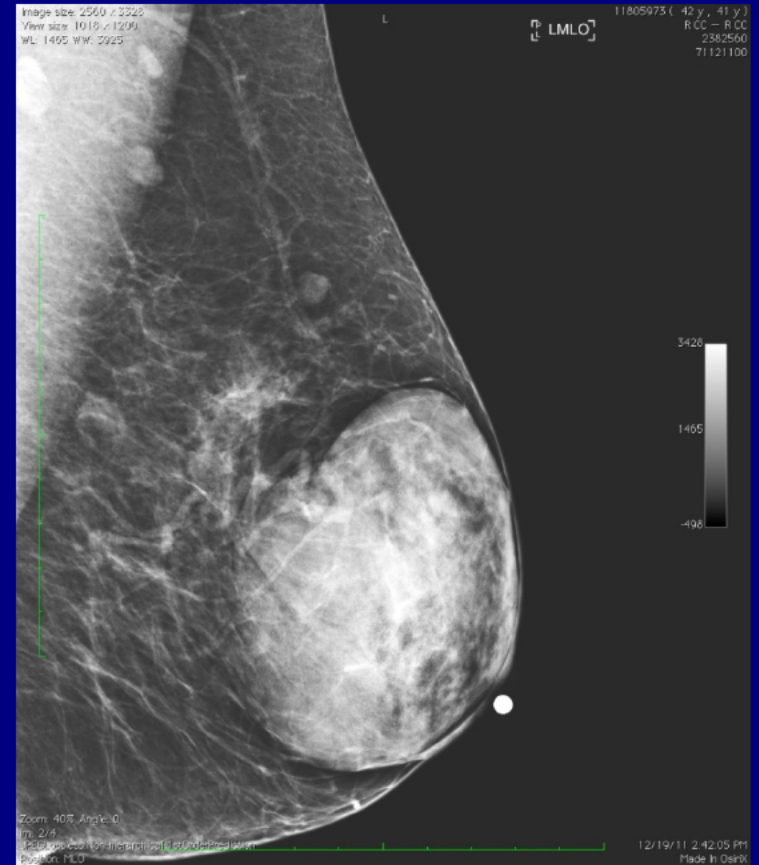
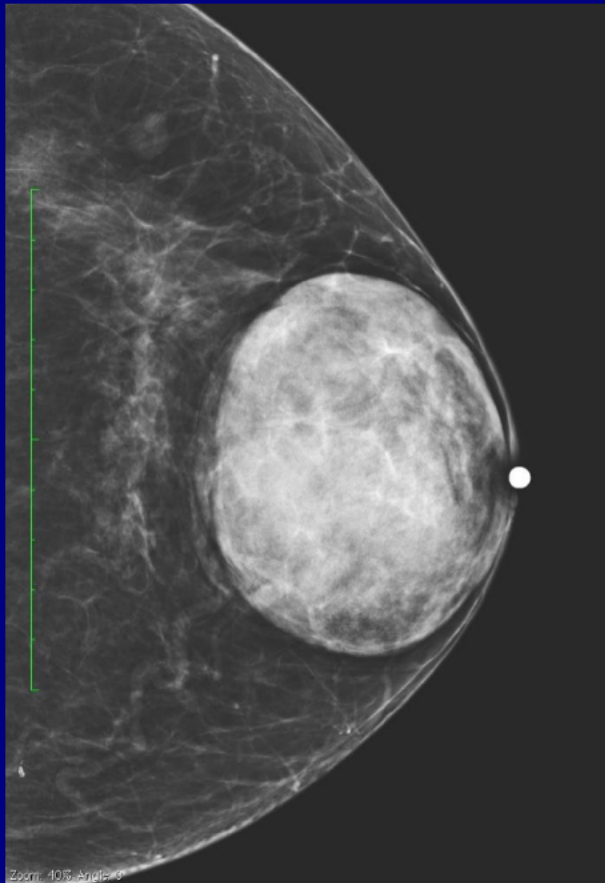
University of Texas Health Science
Center

Houston, Texas

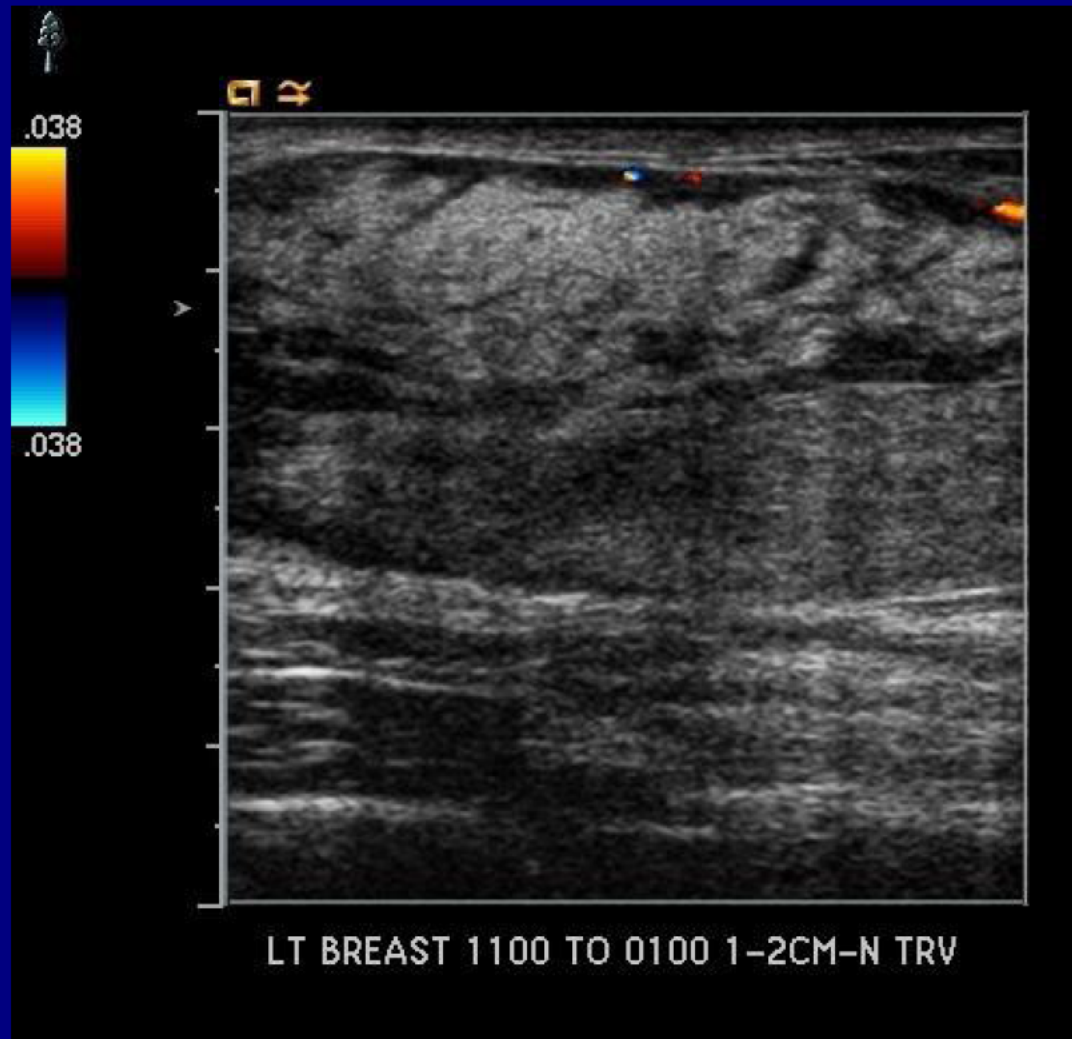
Breast Best Case

42-year-old African American female presented with history of enlarging left breast mass. Patient is G4P4 with menarche occurring at age 15. There is a family history of breast cancer in her paternal grandmother who died of the disease at age 81. Her daughter had ovarian cancer at 27 years of age. The patient is status post right oophorectomy for an unknown reason.

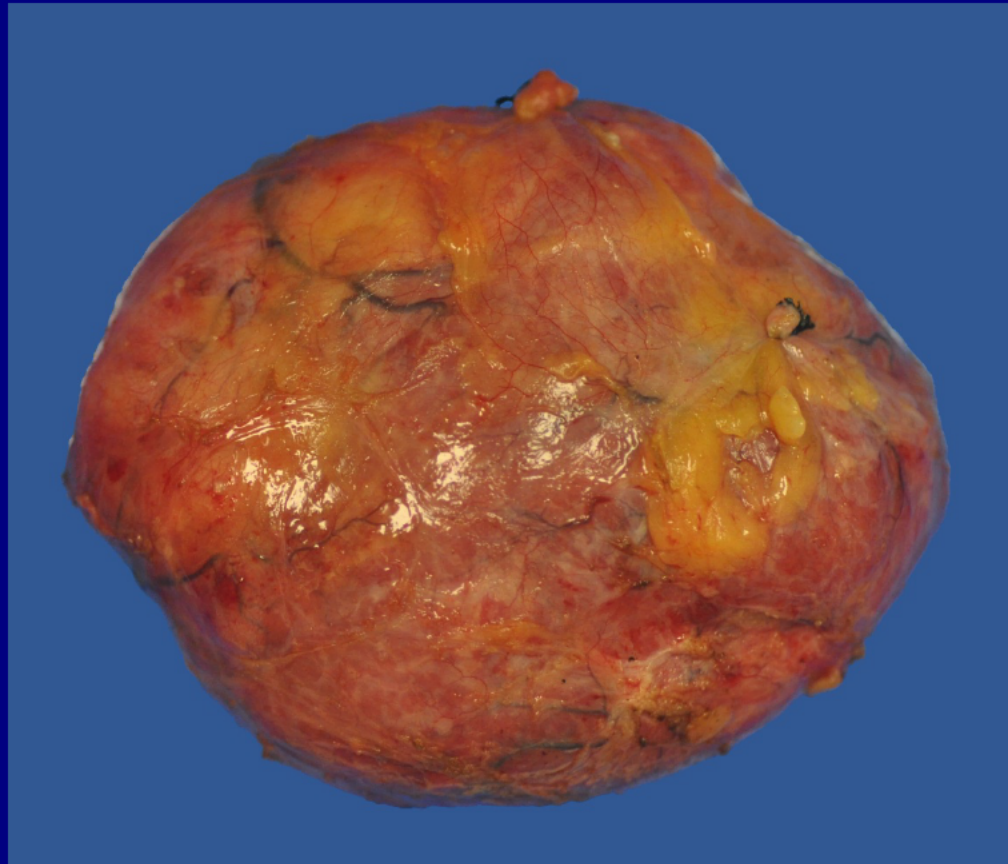
Digital Mammogram

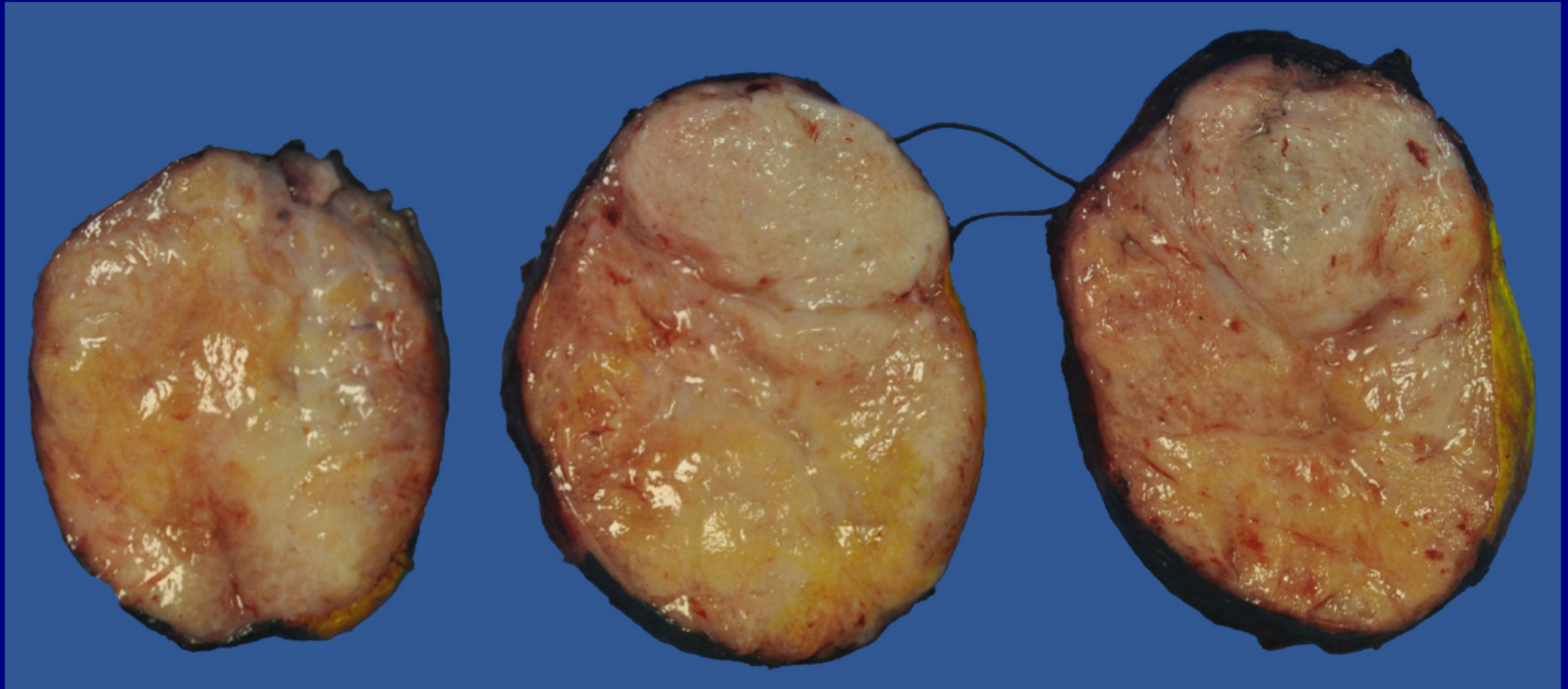


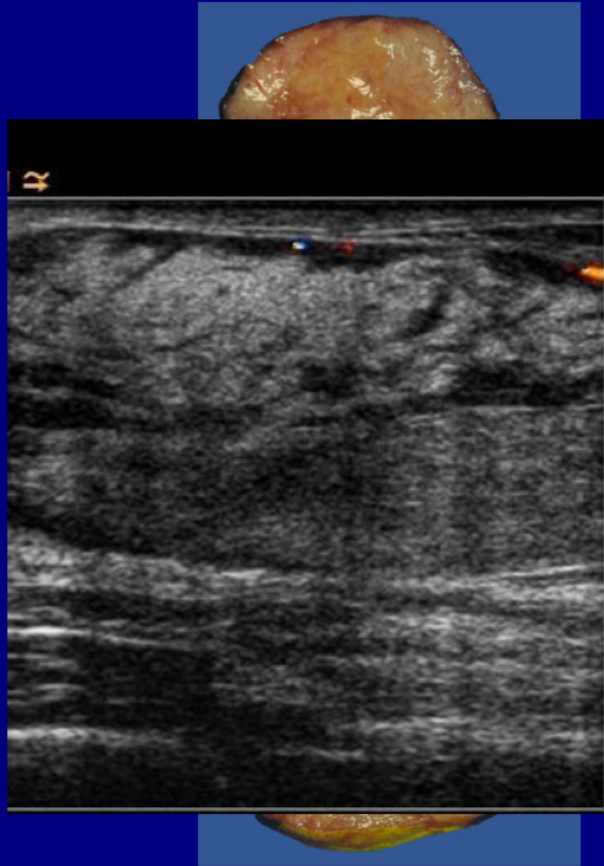
Ultrasound



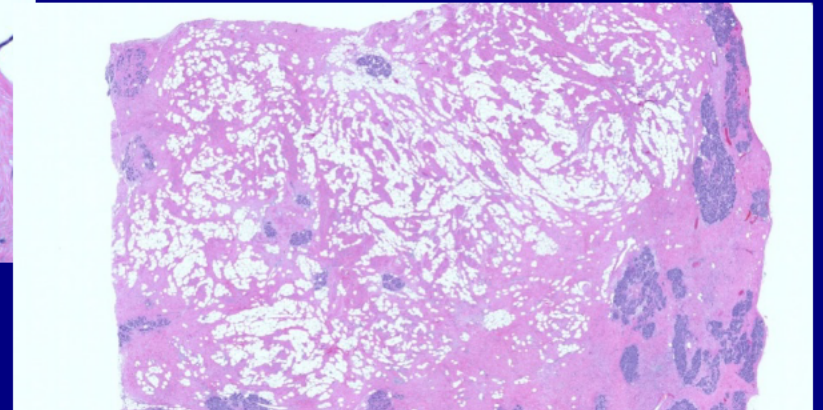
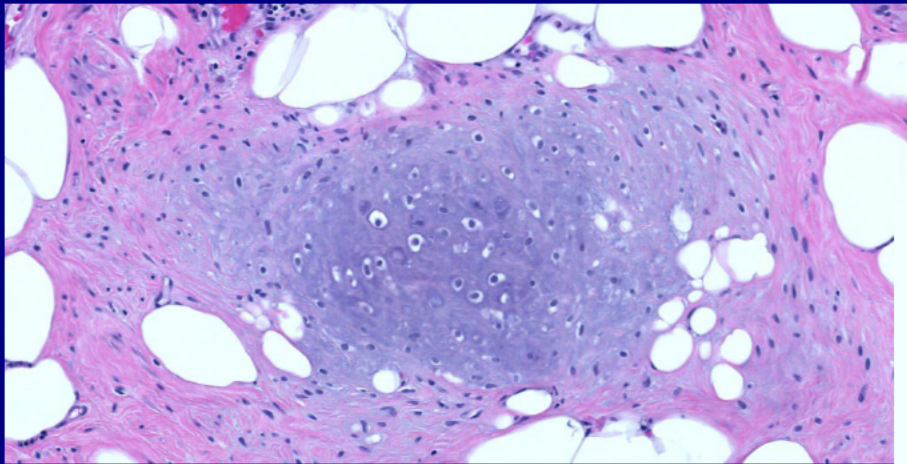
Gross







Histology



Choristoma

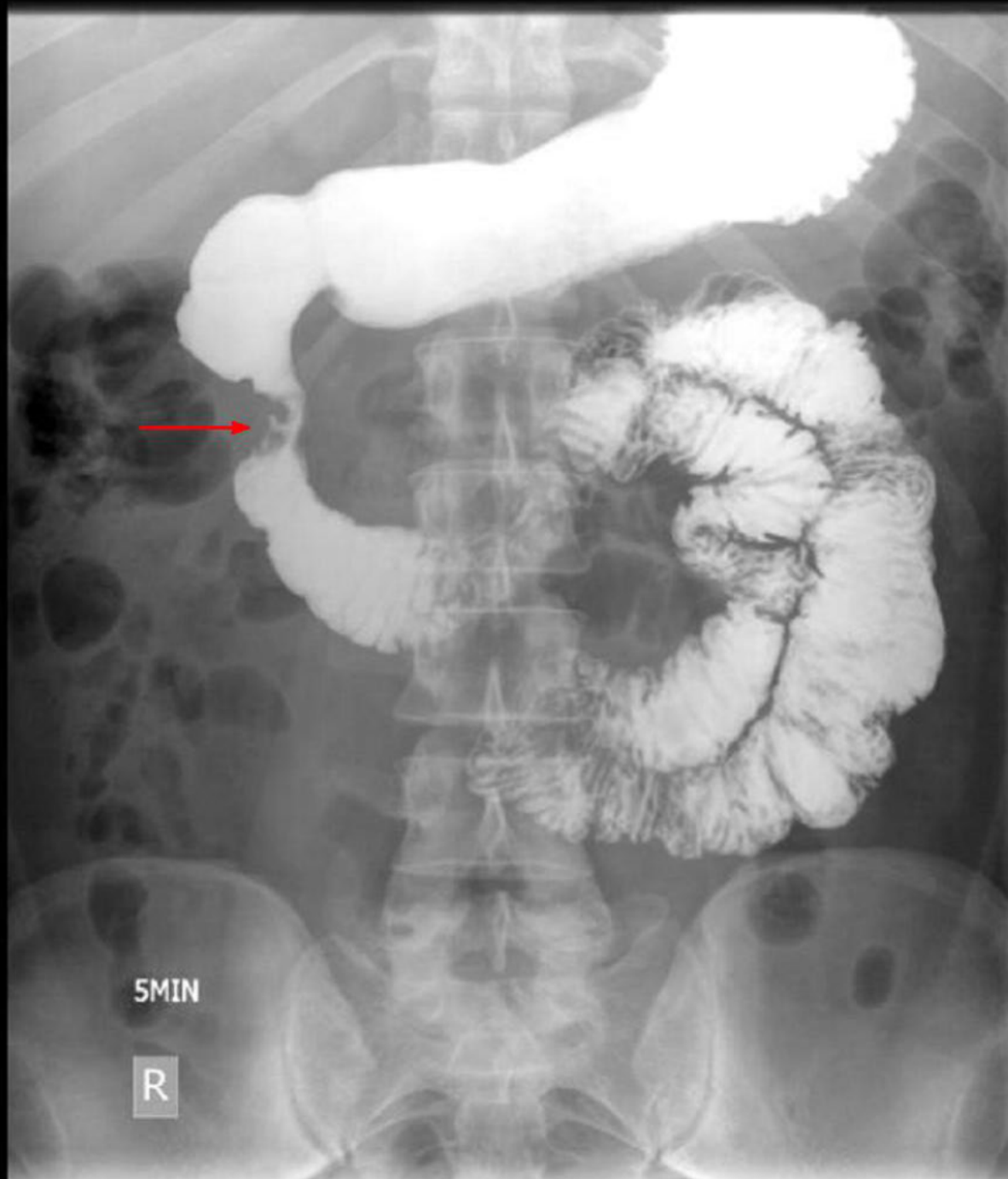
(Hamartoma containing muscle and cartilage)

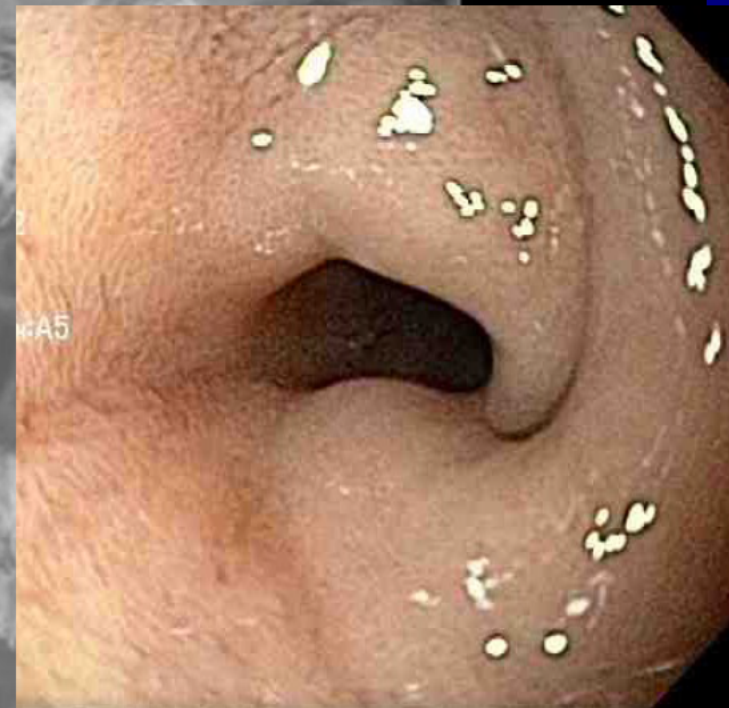
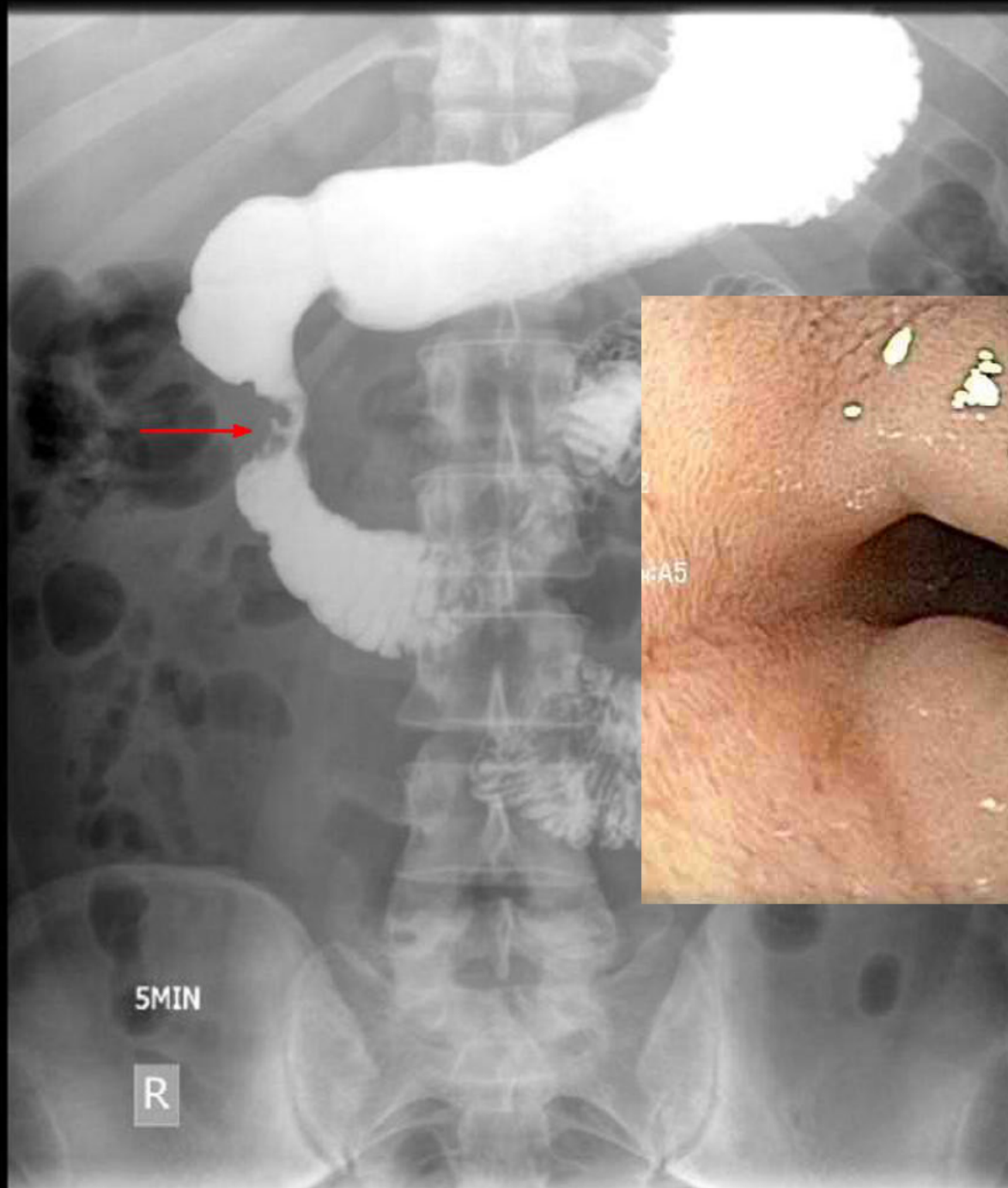
Kyle Hayden, MD

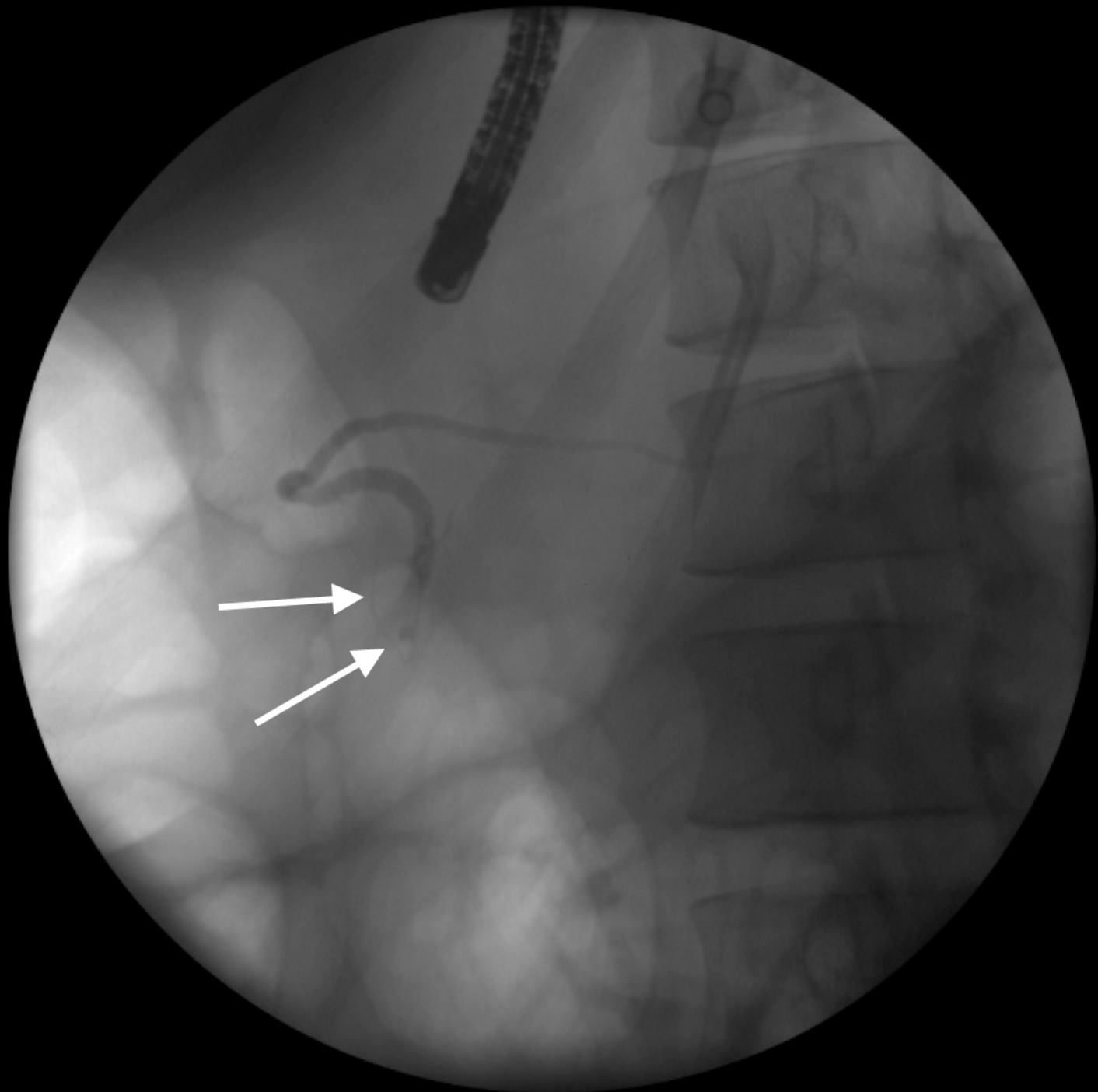
University of Florida Health Science Center
Jacksonville, Florida

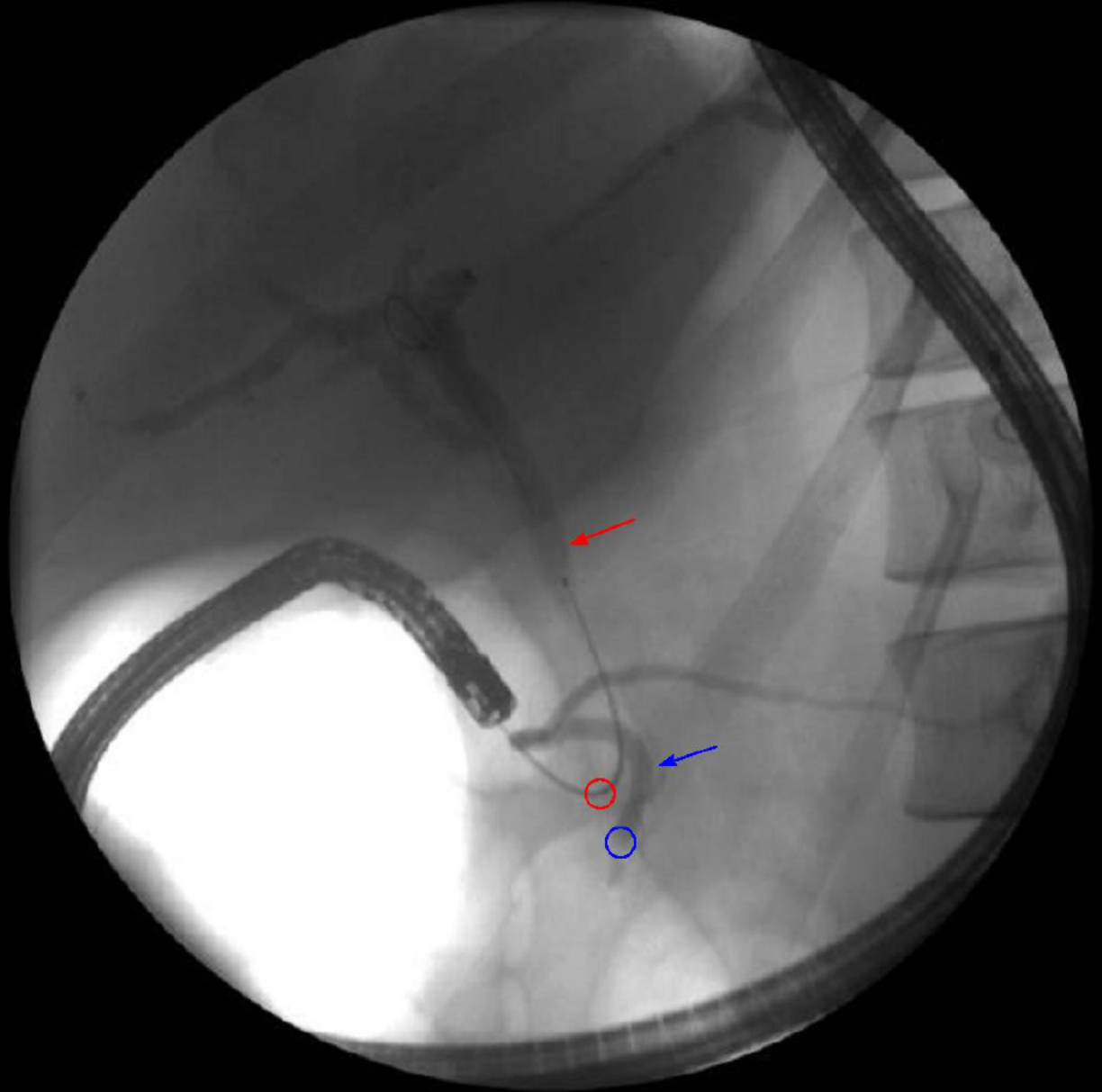
Gastrointestinal Best Case

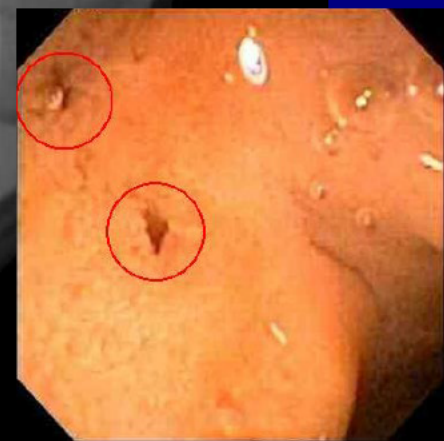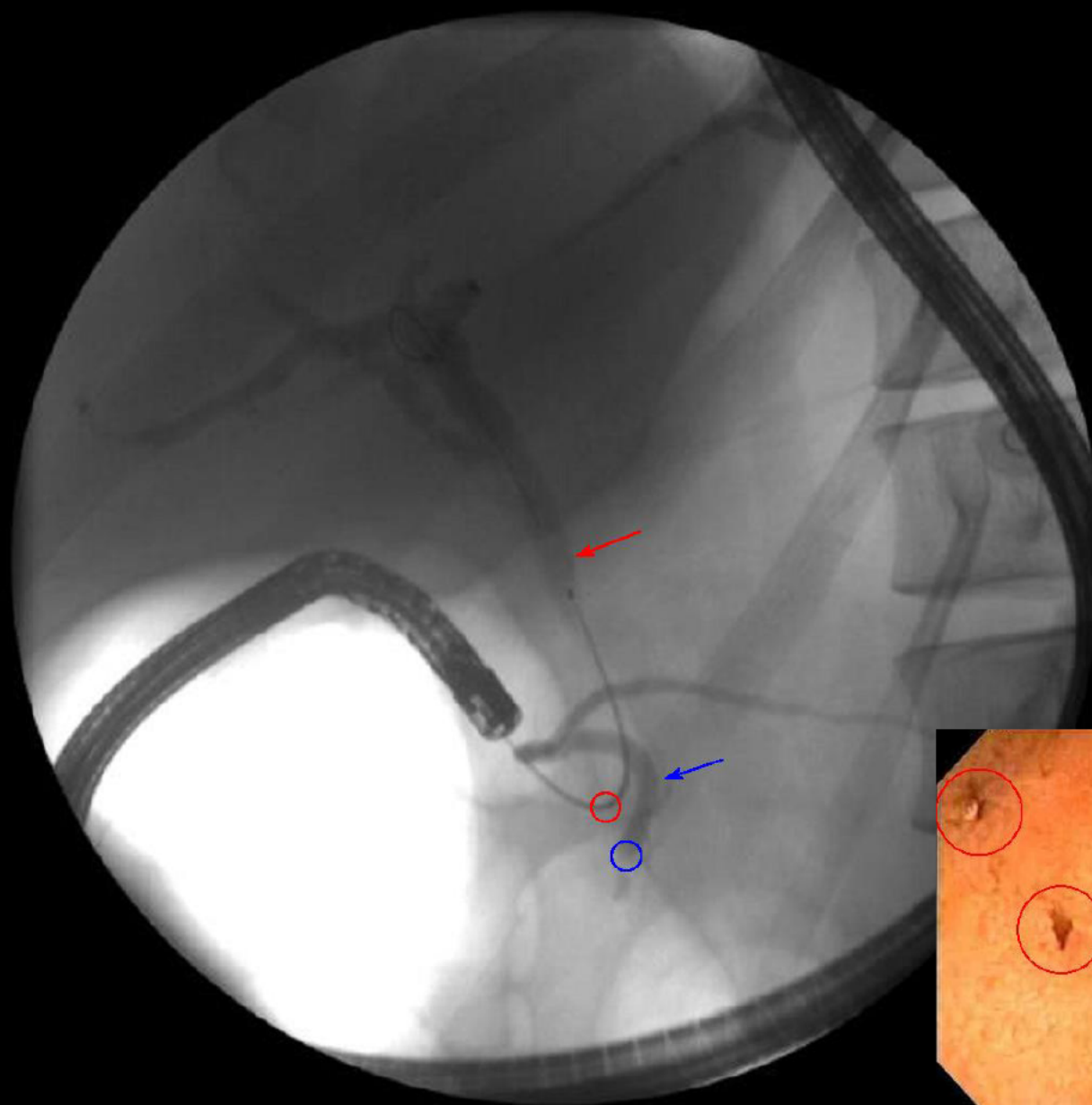
42-year-old man with intermittent episodes of right upper quadrant pain, jaundice, and low-grade fever

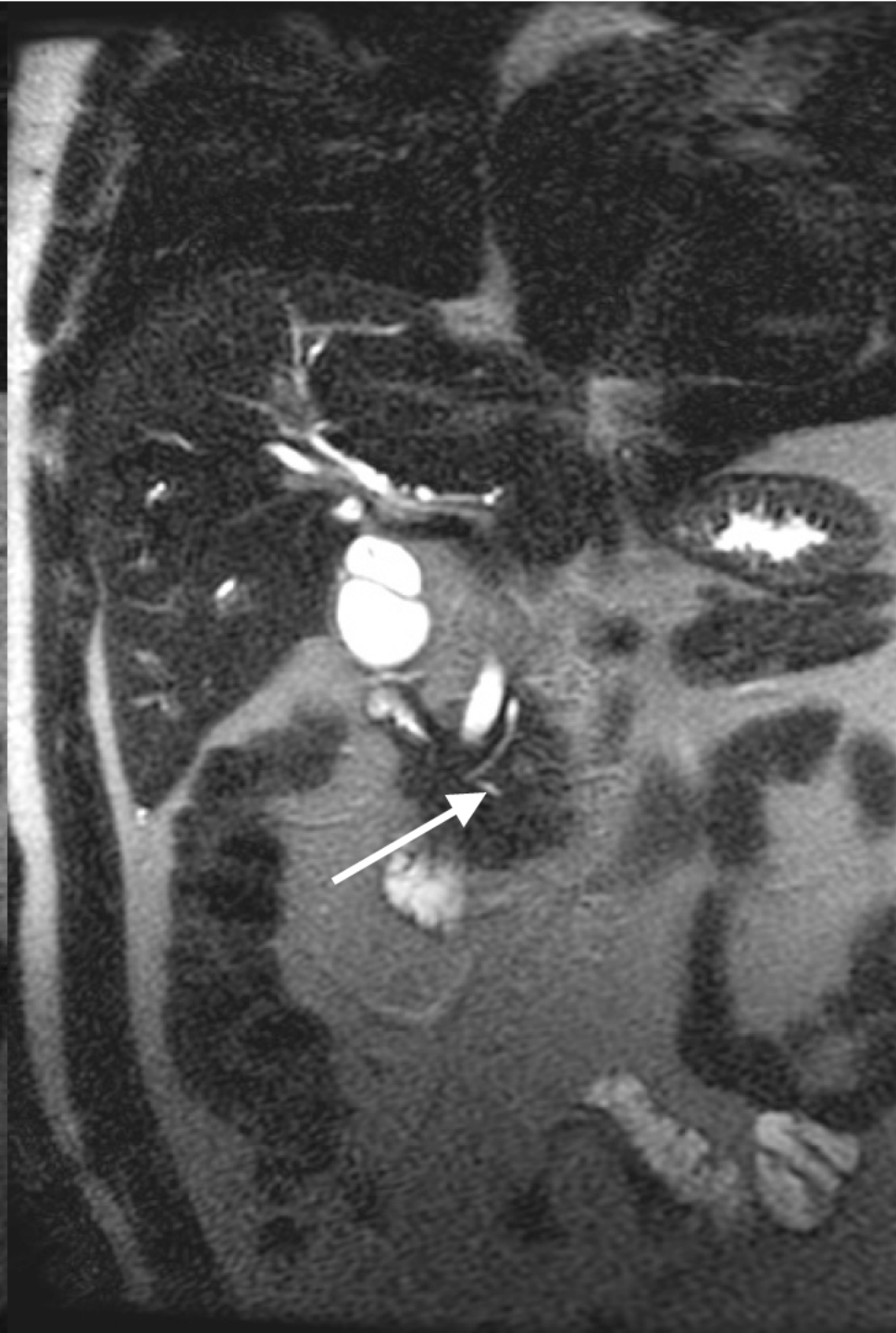
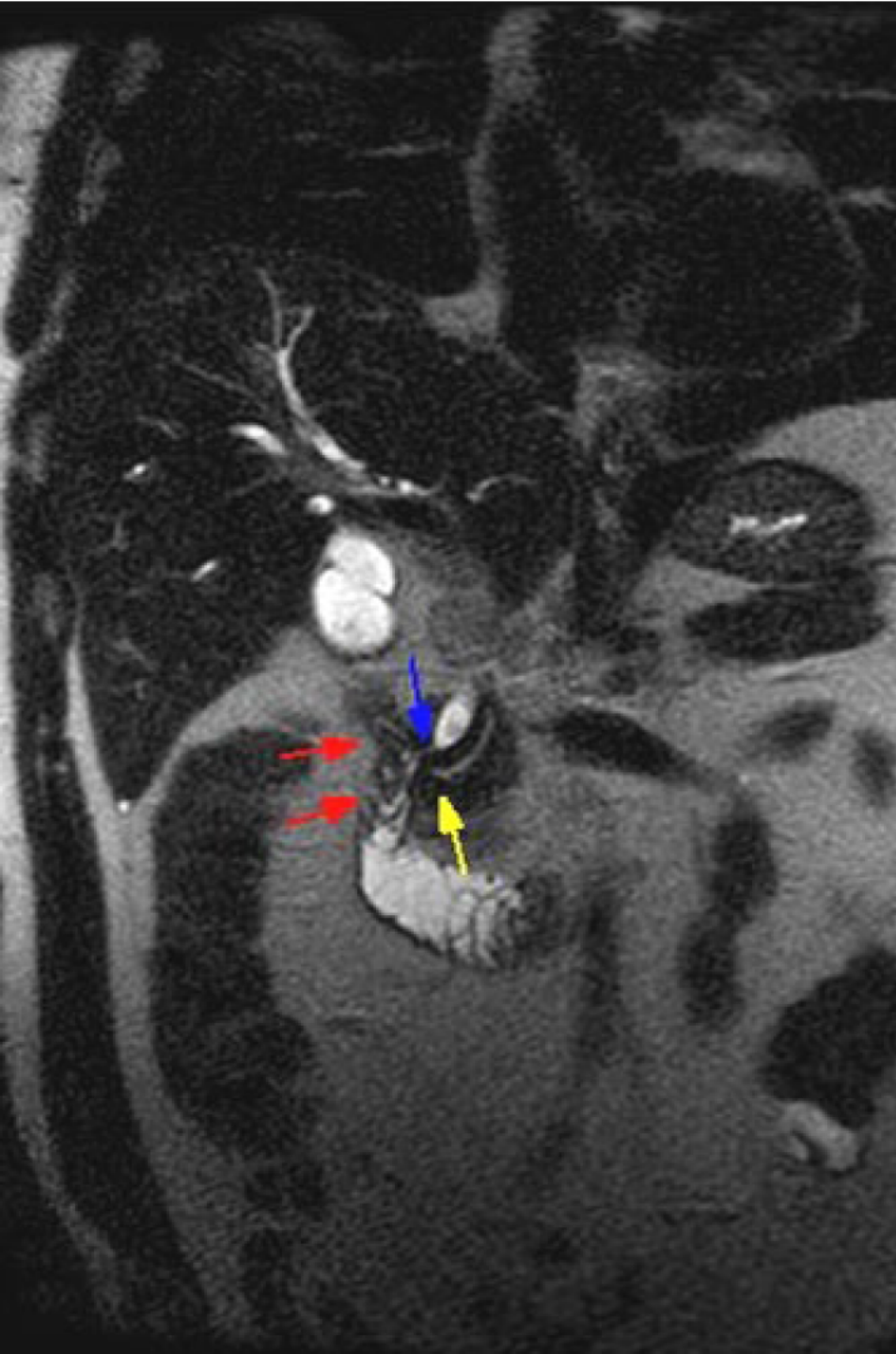


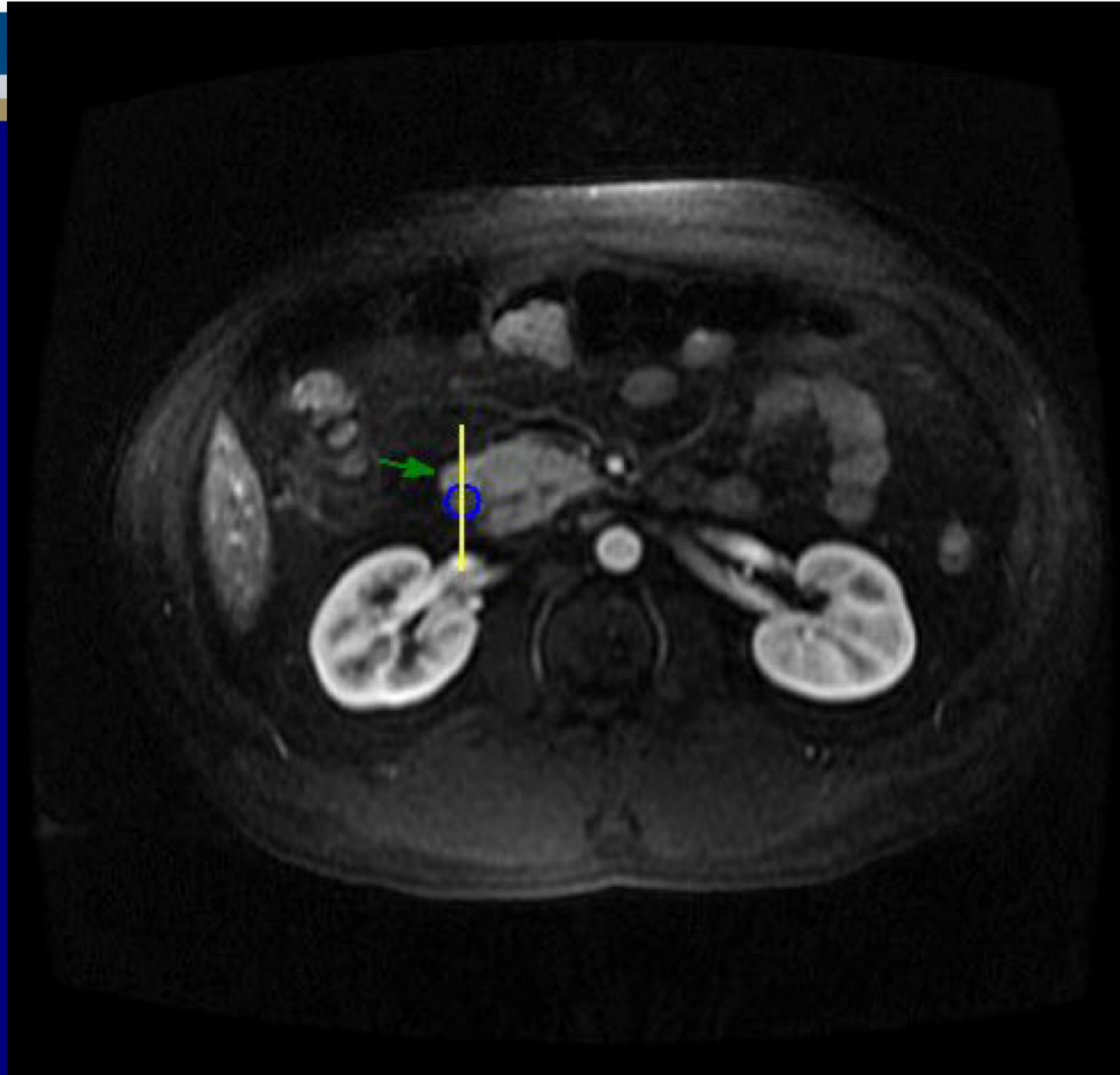

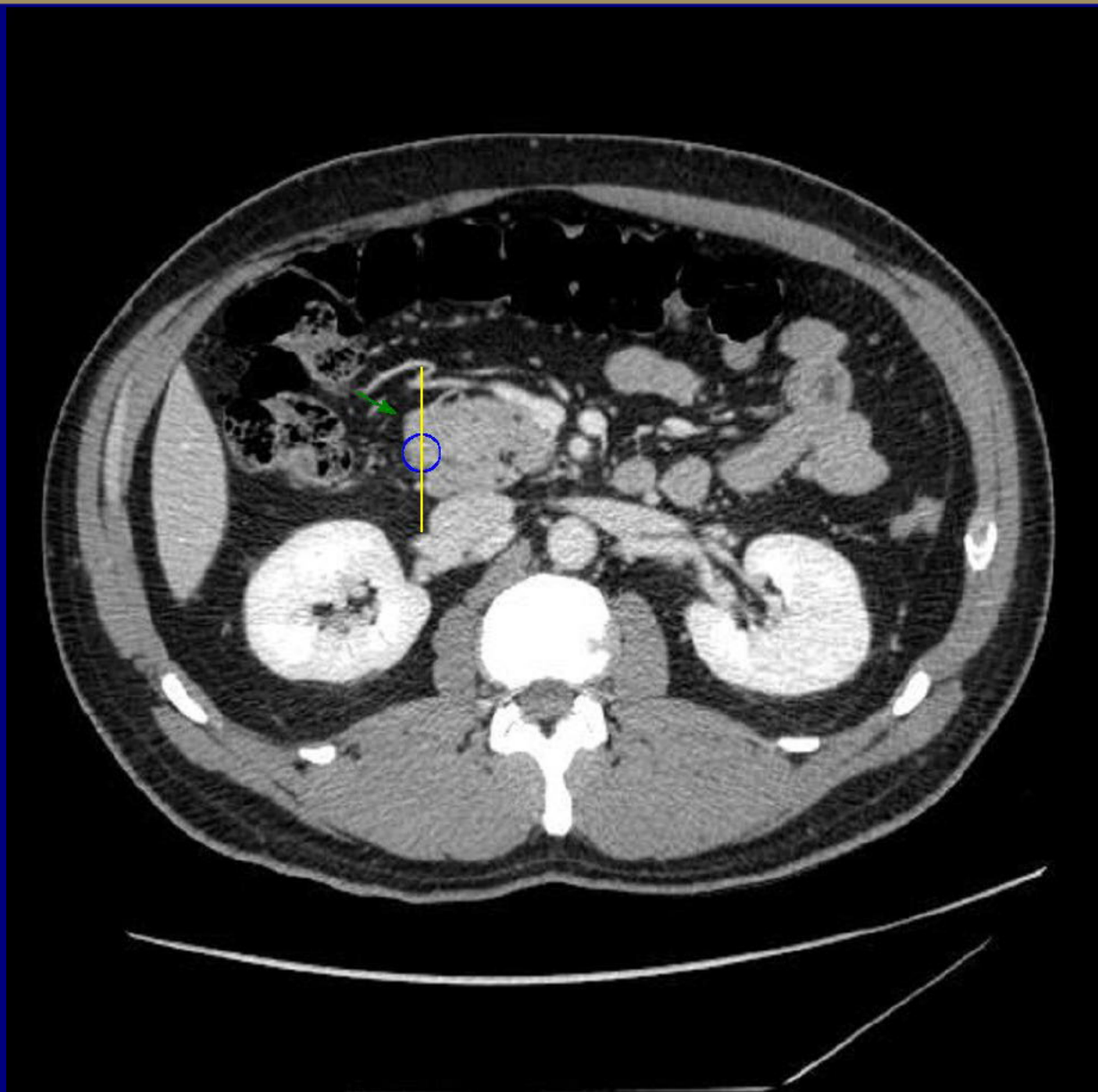


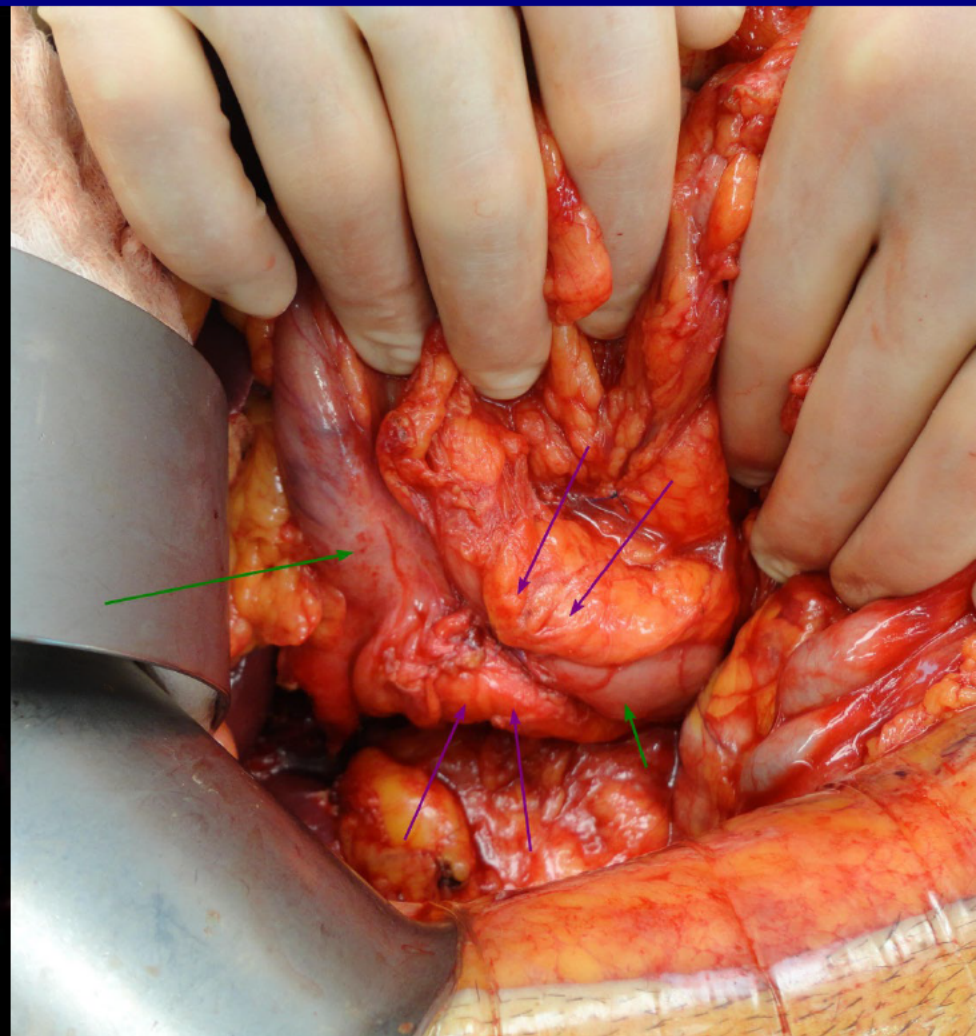

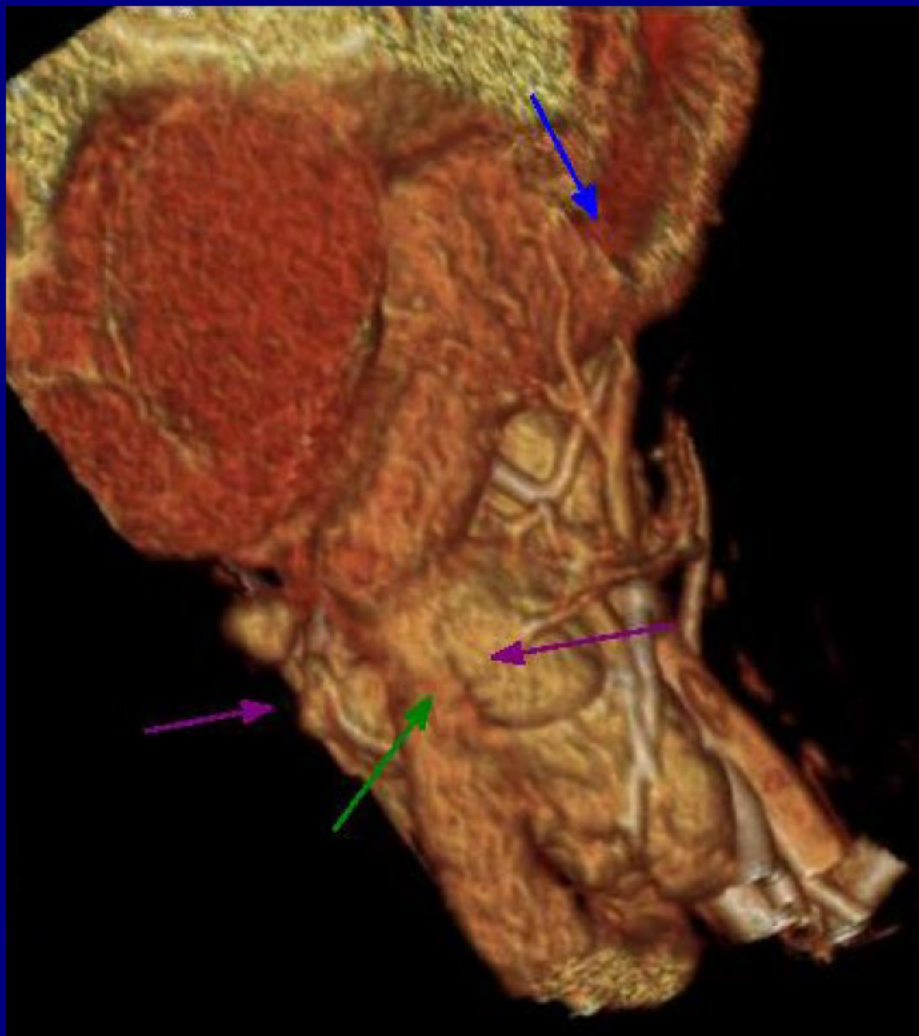










Annular Pancreas

Gregory Havlena, MD
Stanford University,
Stanford, California

Many thanks to all of you for submitting
such great cases!
Have a safe trip home –

From the staff of the
American Institute for Radiologic Pathology