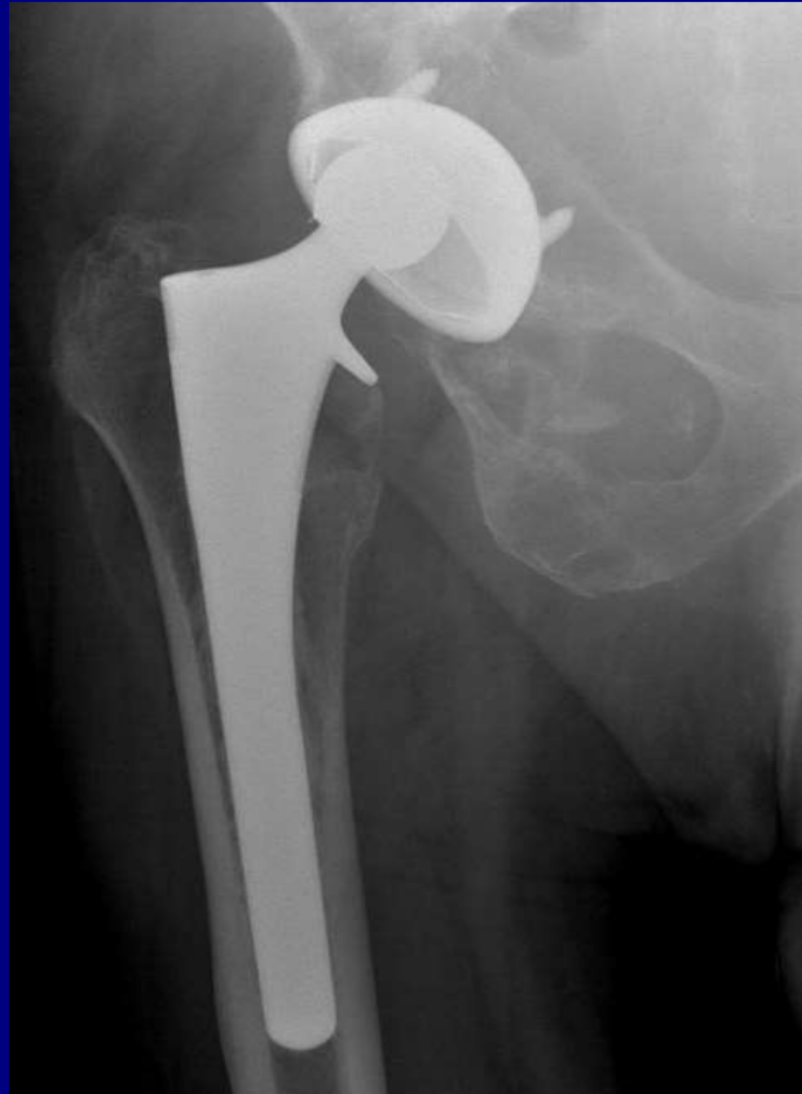

Best Cases of the AIRP

July 22 – August 16, 2013

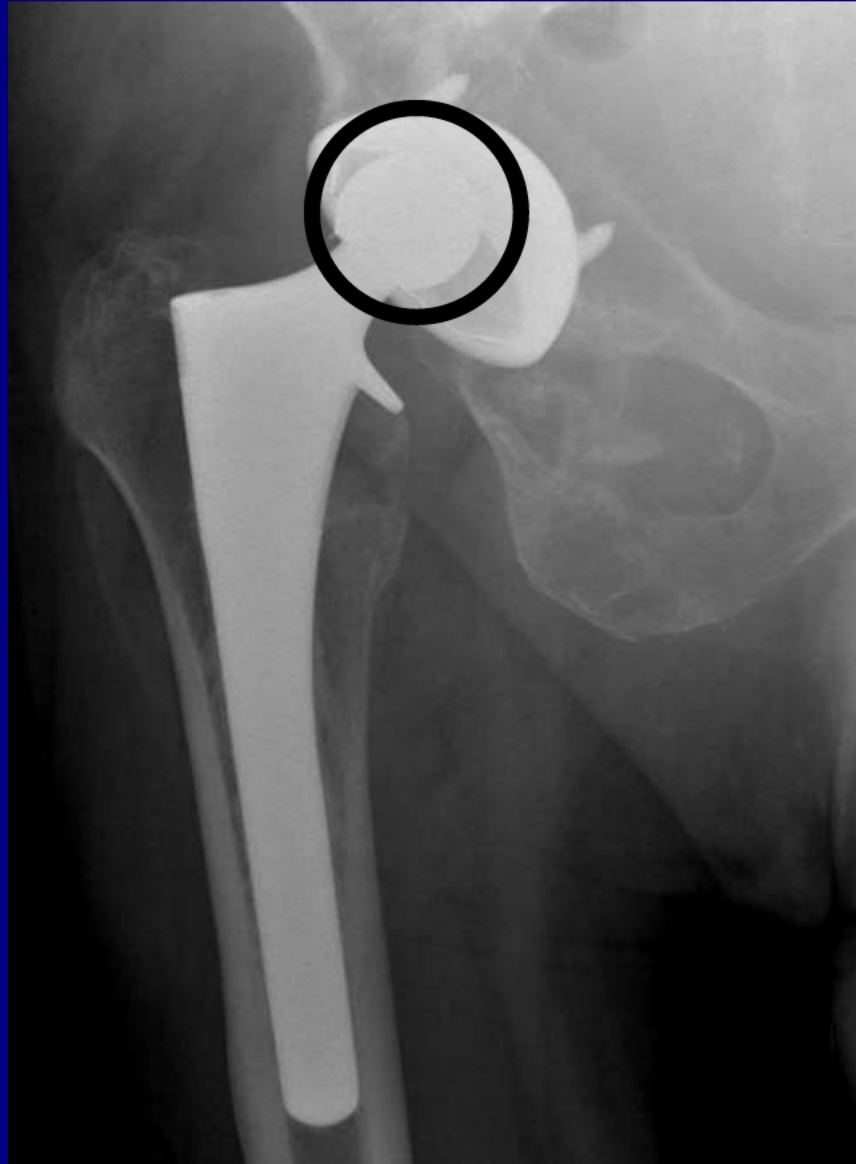Musculoskeletal Best Case

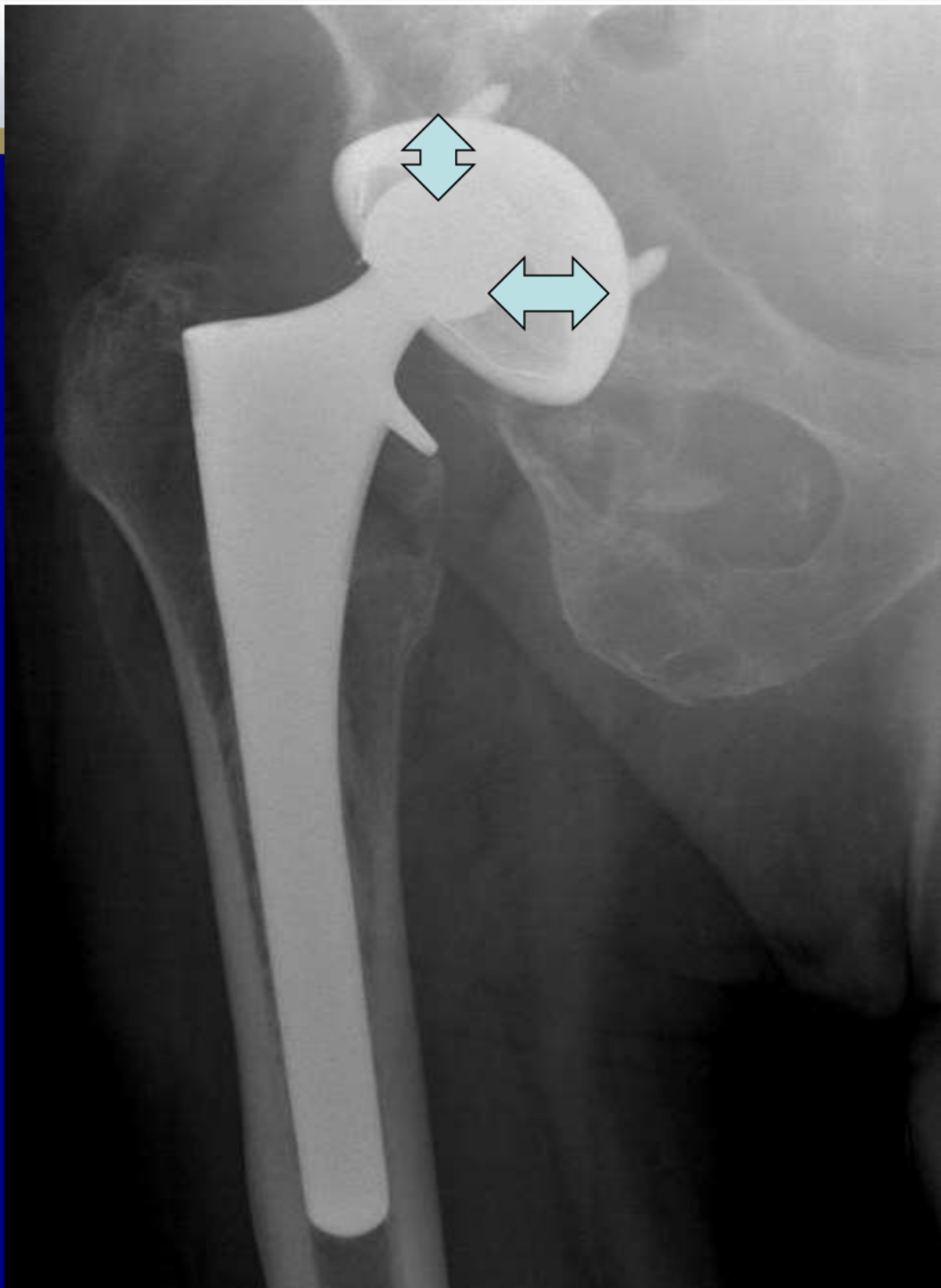
78 year old male with prior total hip arthroplasty in 1988. Patient now presents with 2-3 months of worsening right hip pain/weakness and urinary frequency



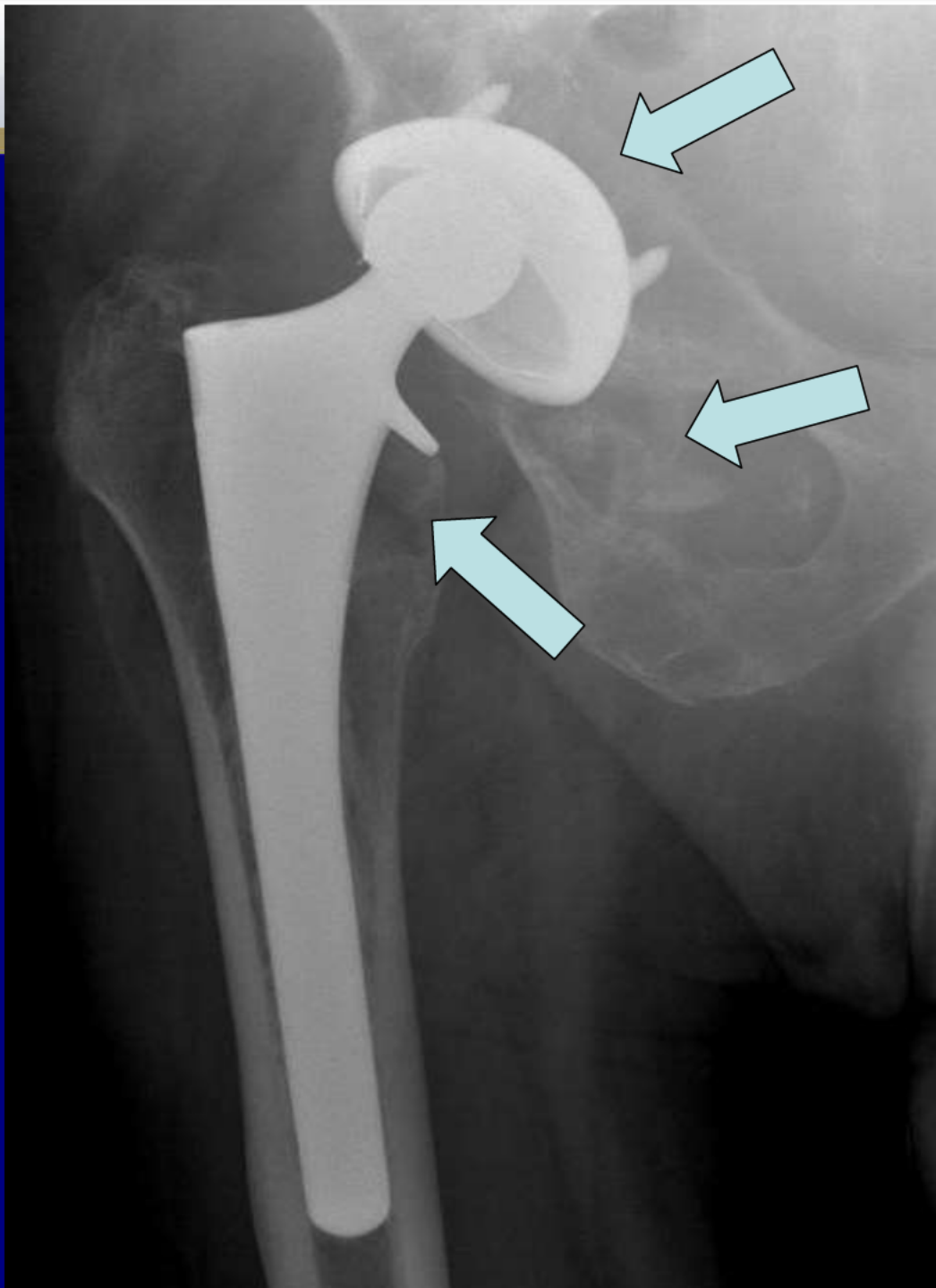
Preop Radiograph

Preop Radiograph

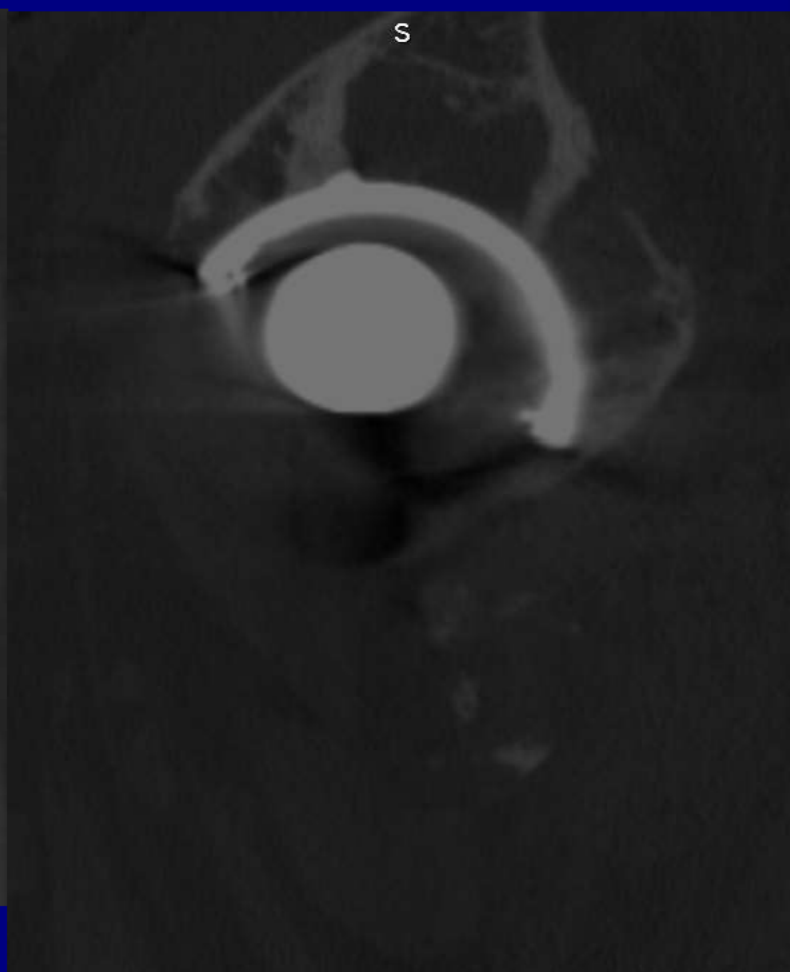
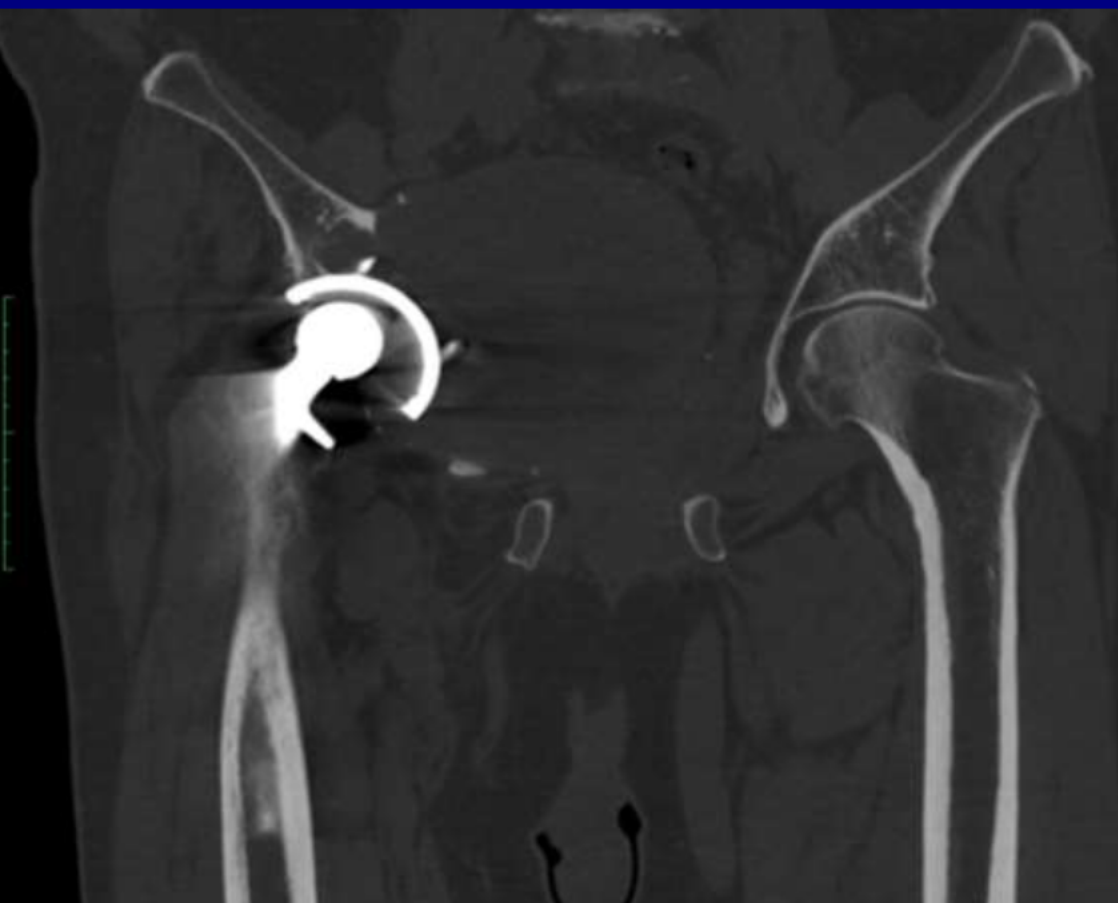

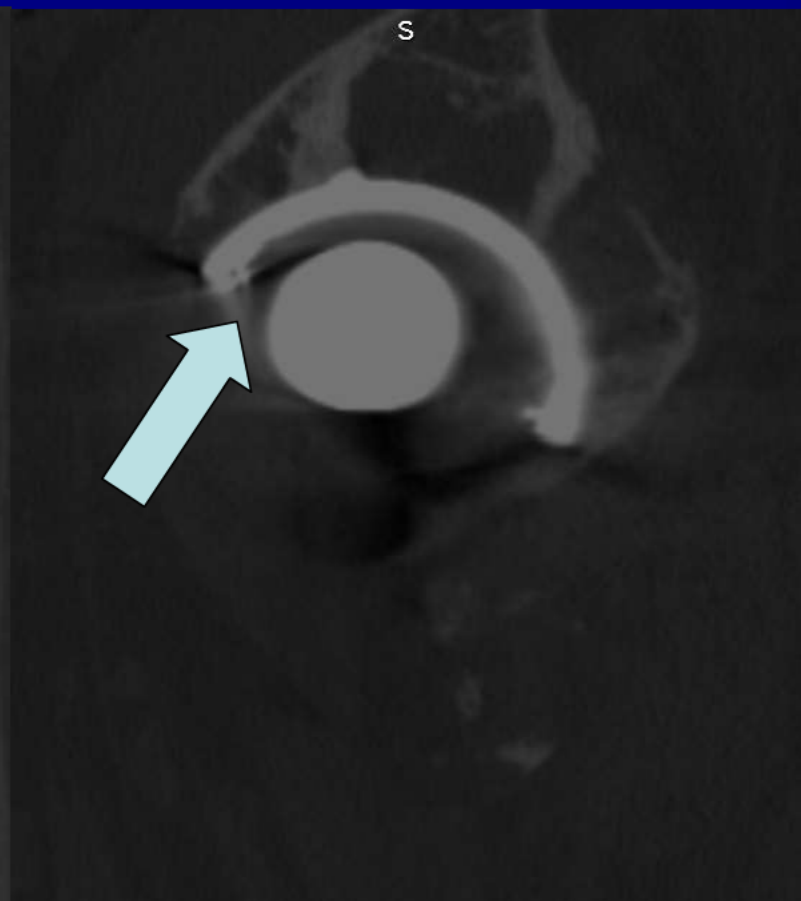
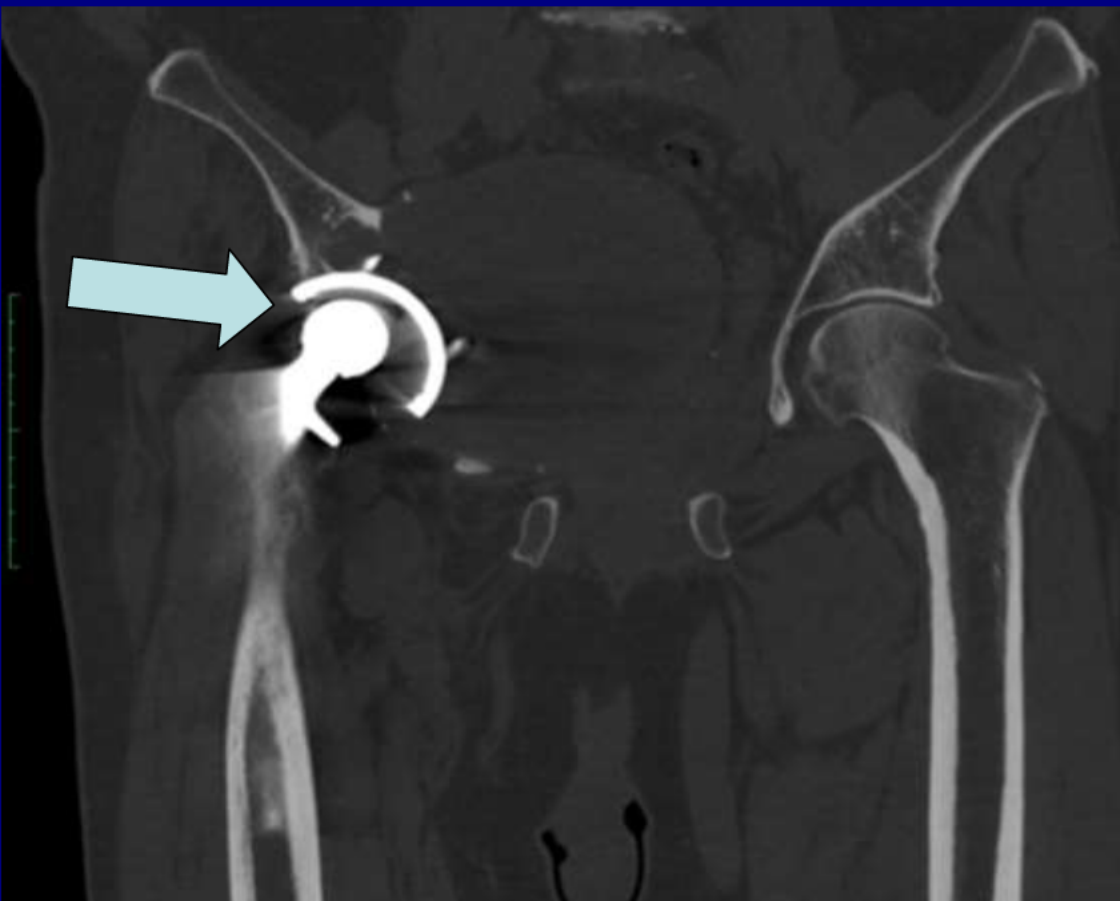


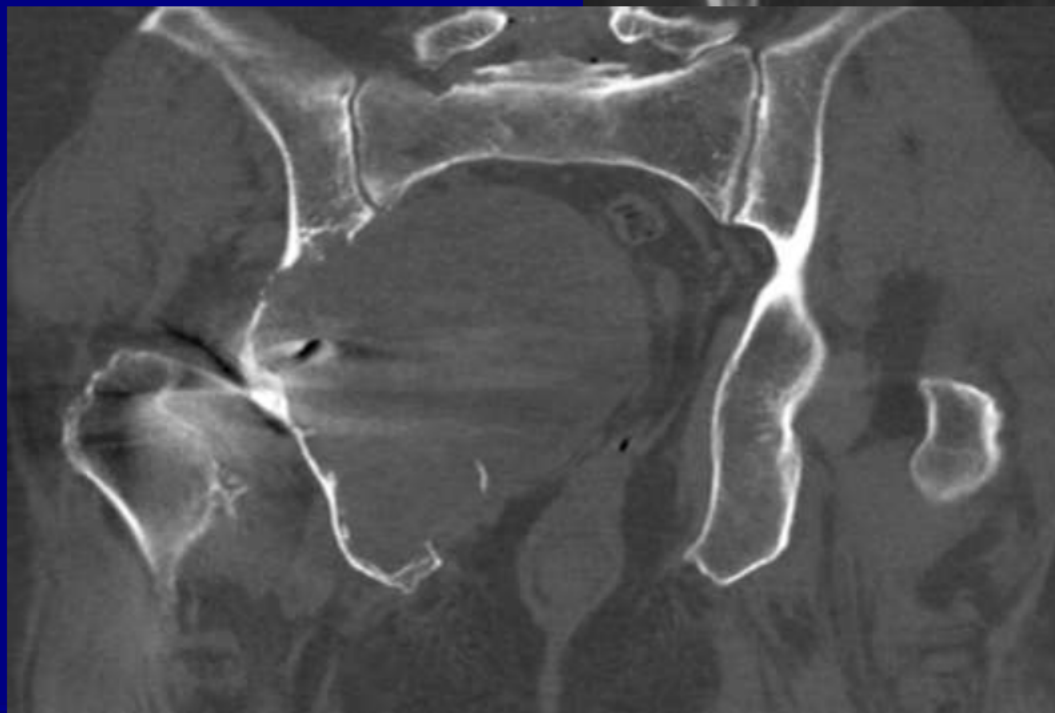
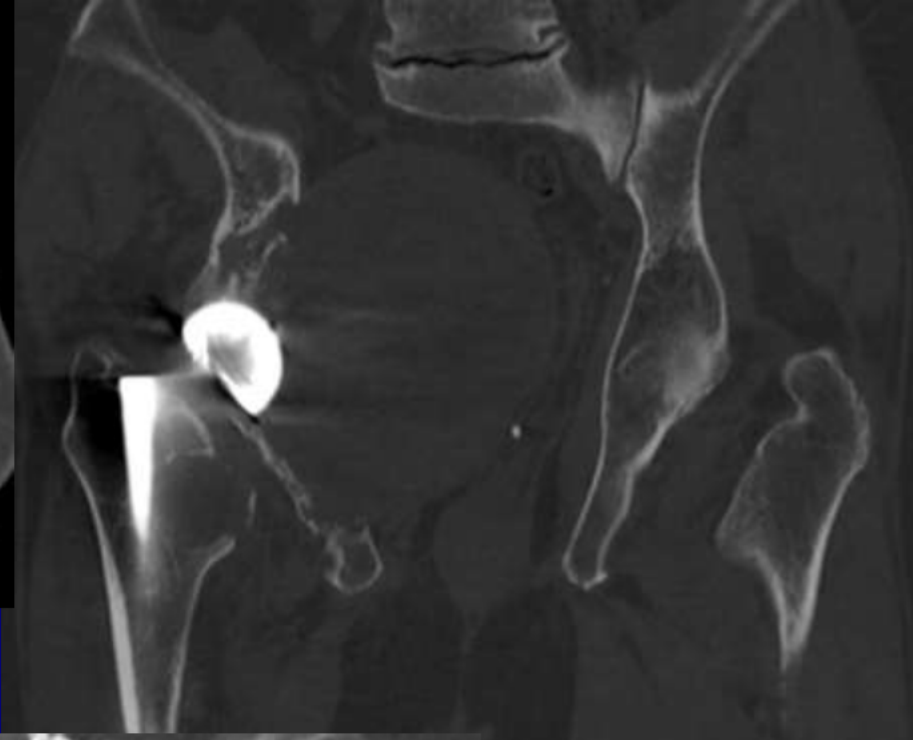
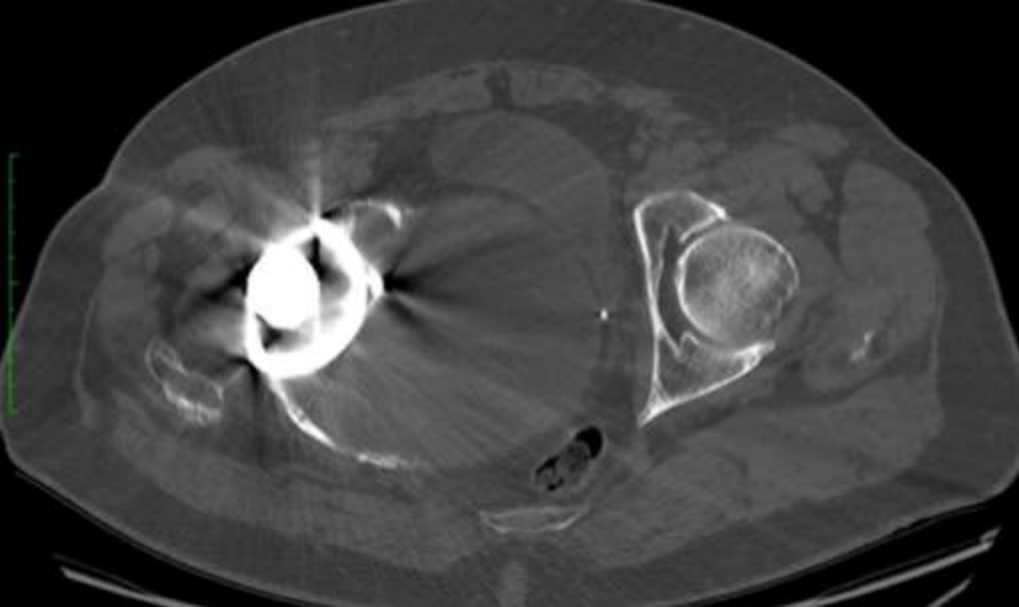
Preop
Radiograph

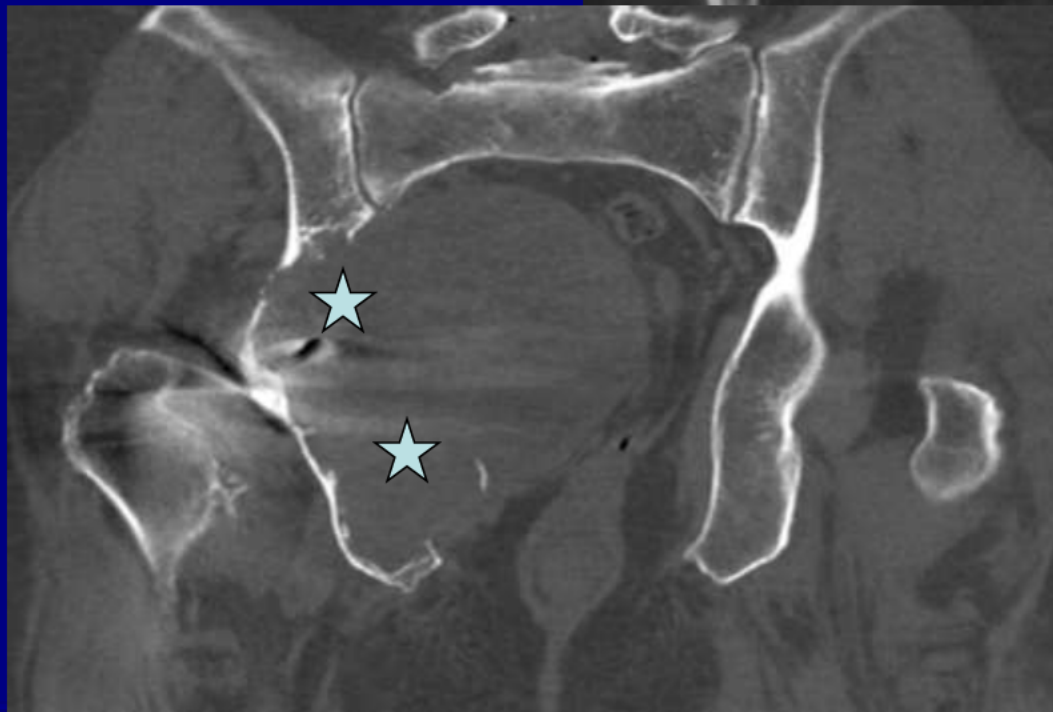
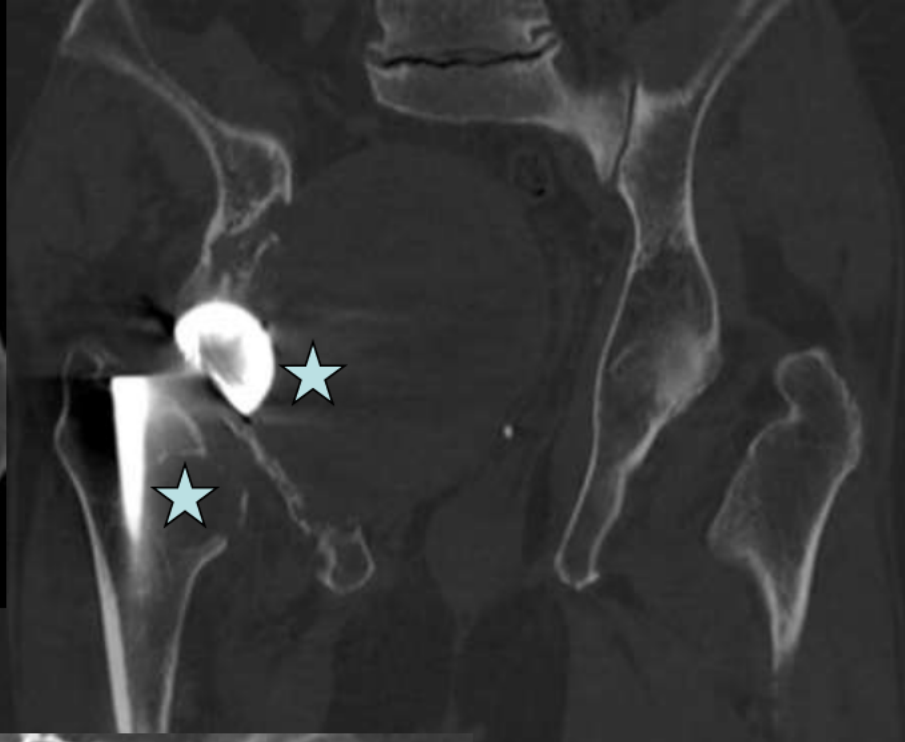
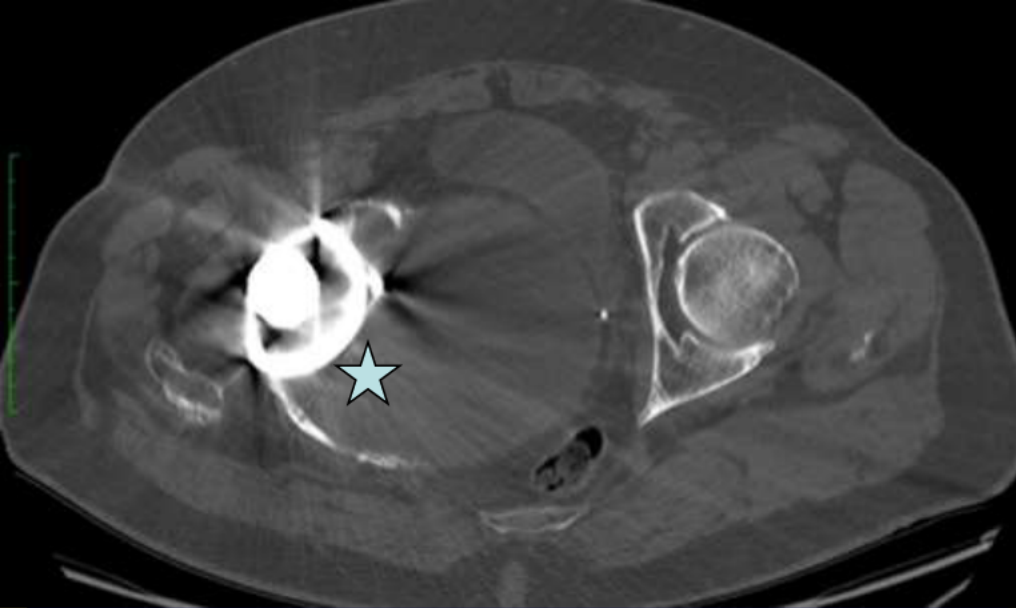


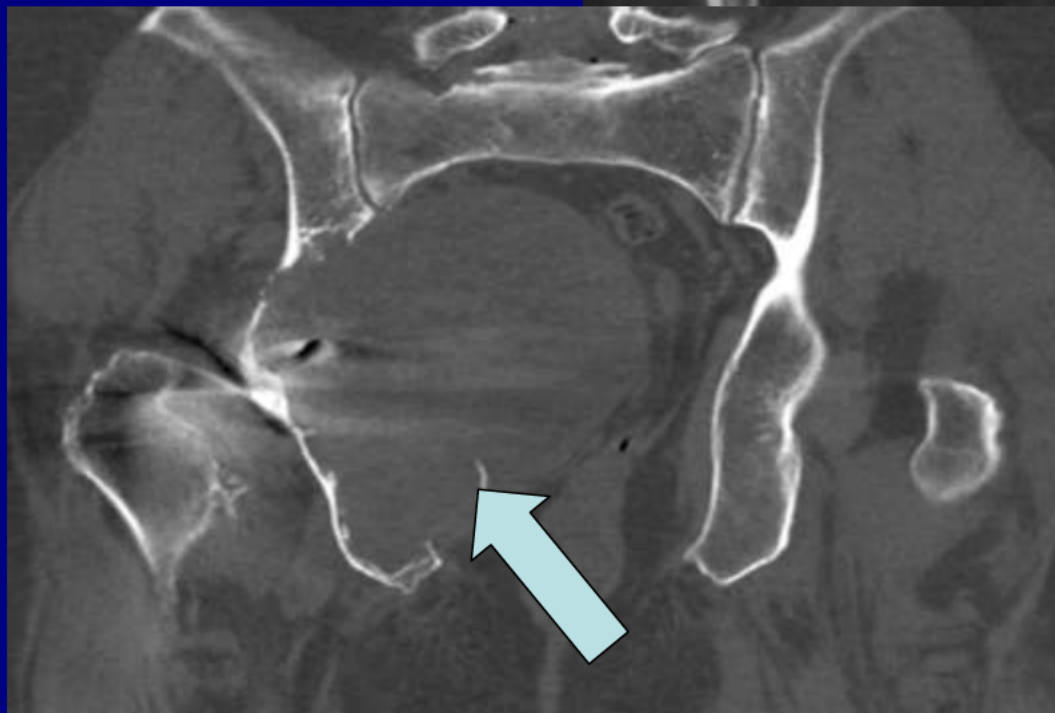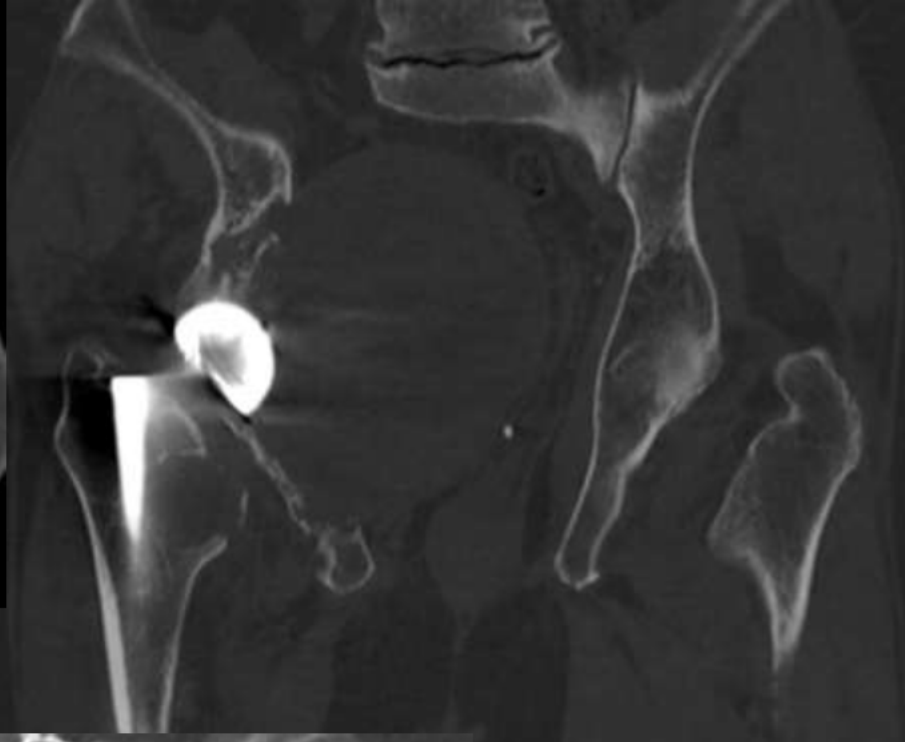
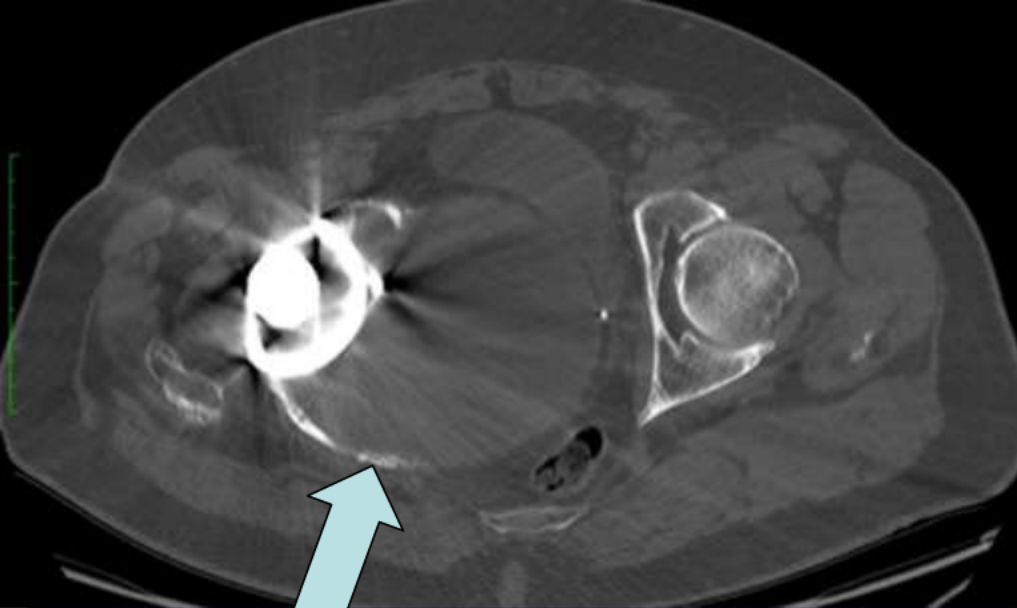
Preop
Radiograph

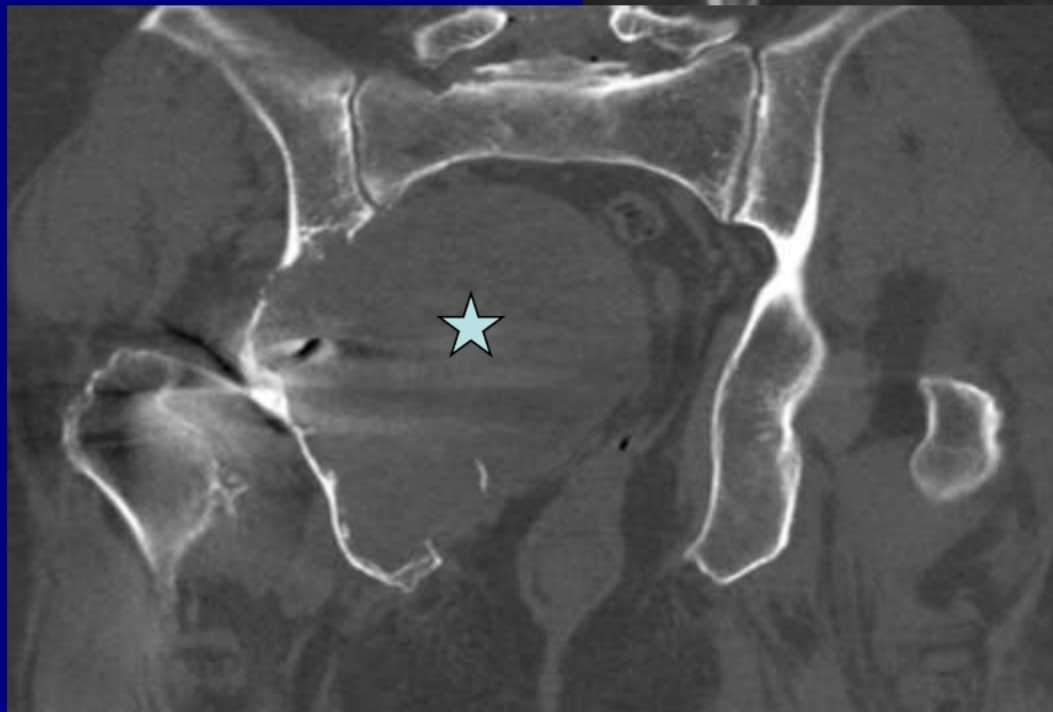
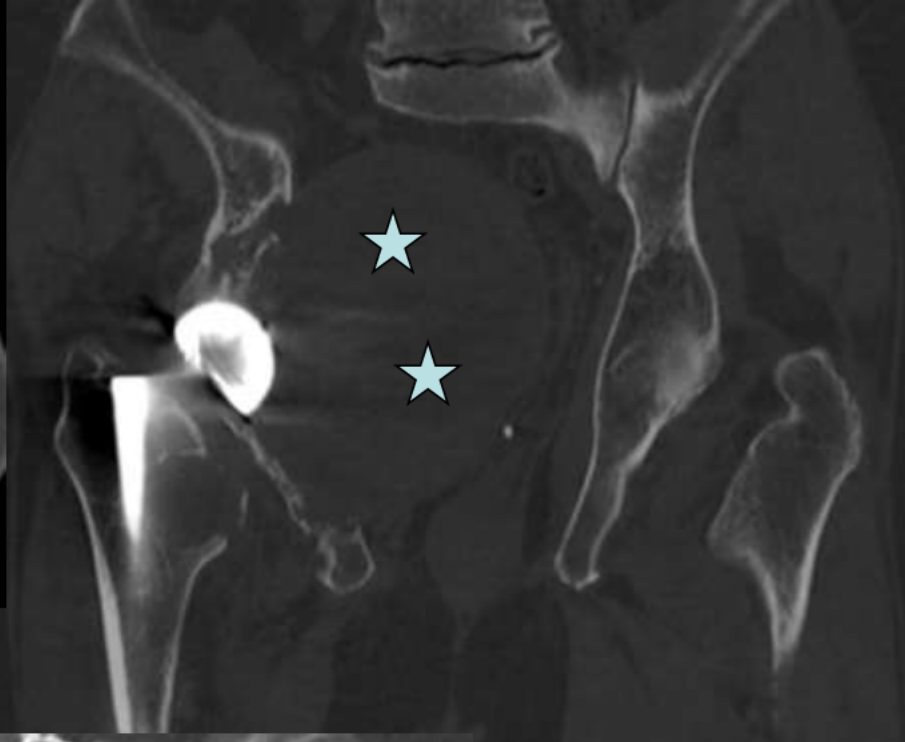
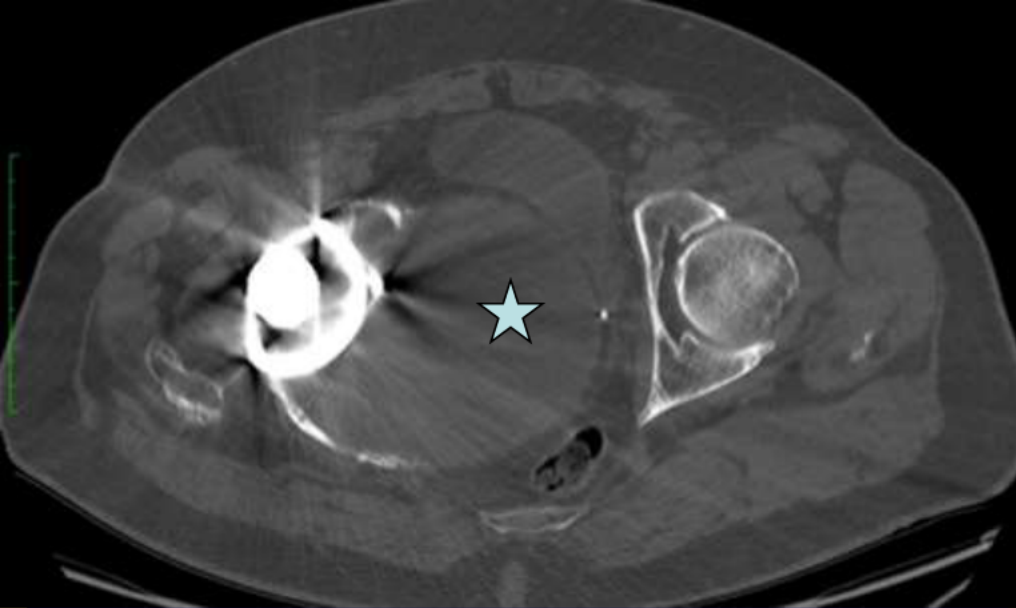


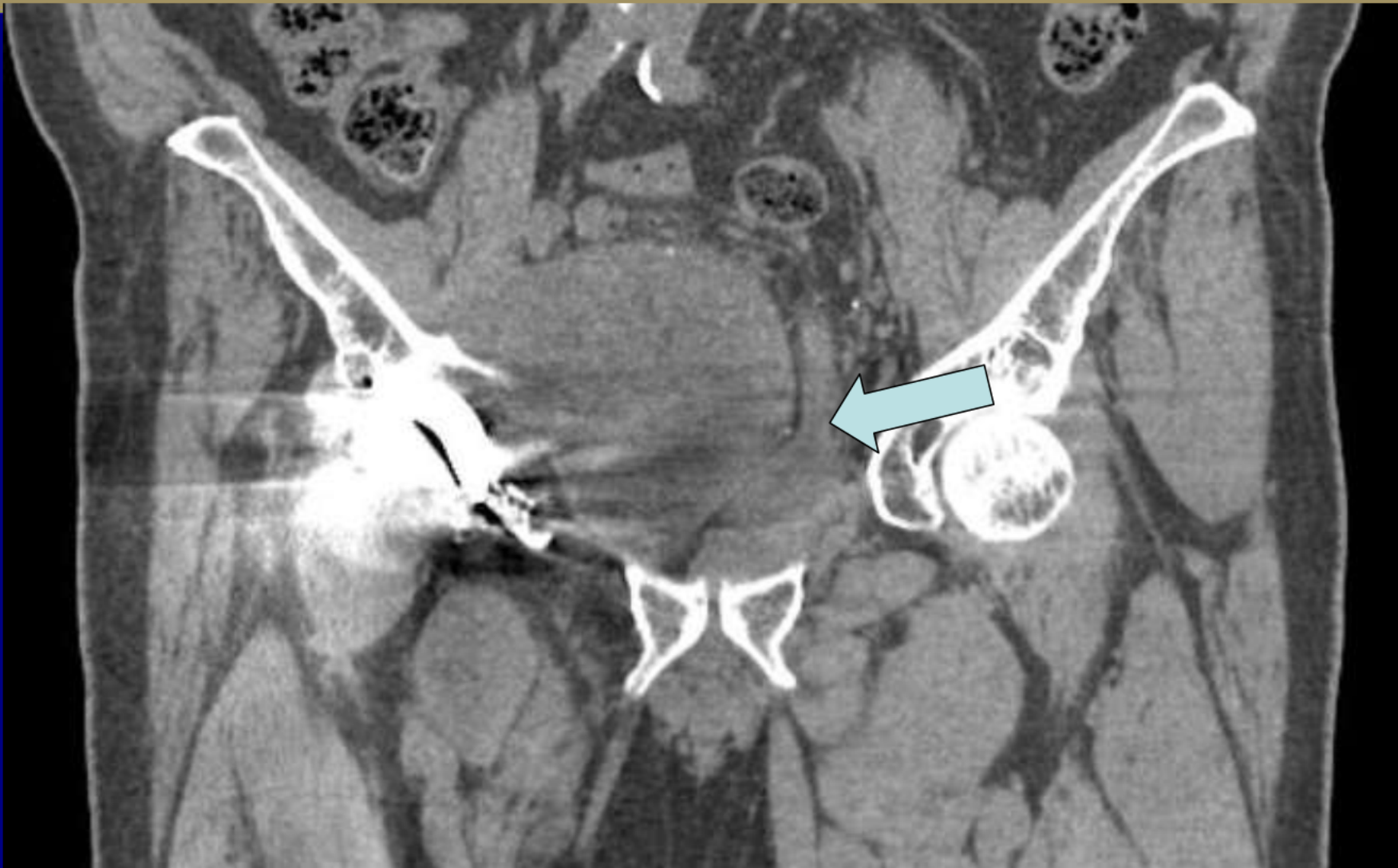




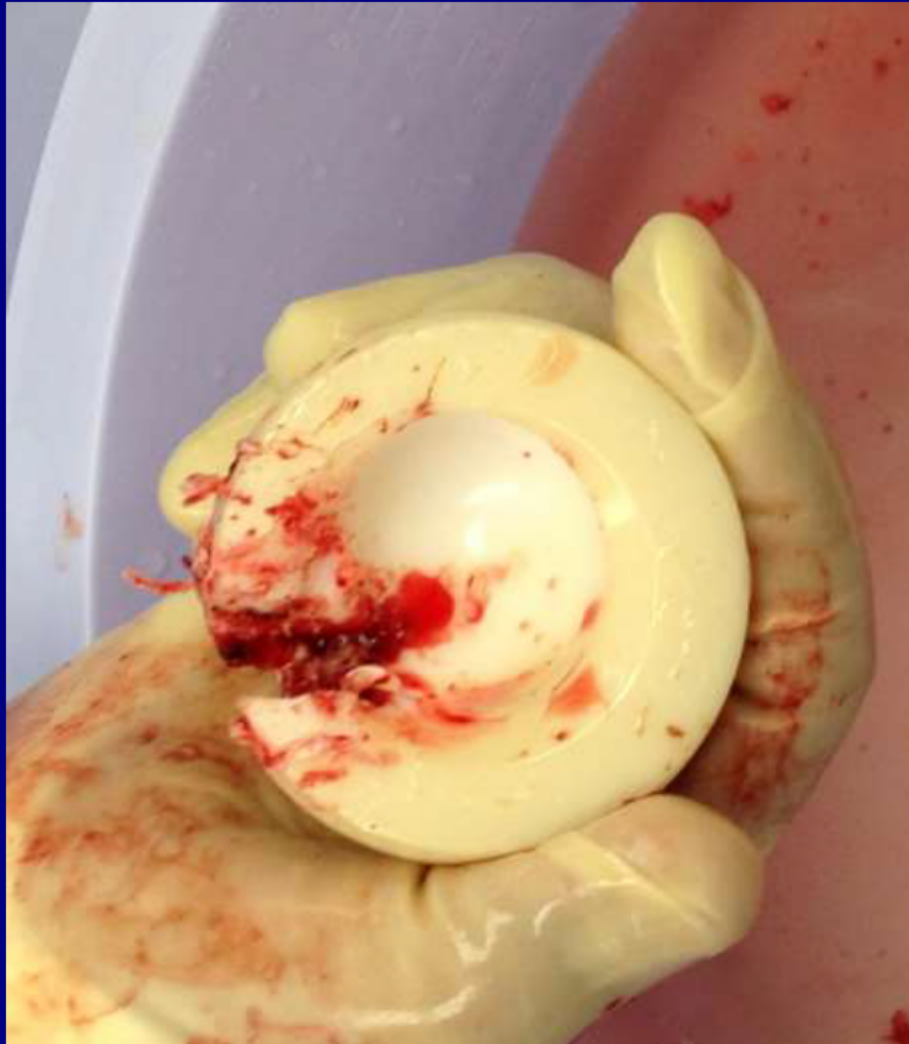







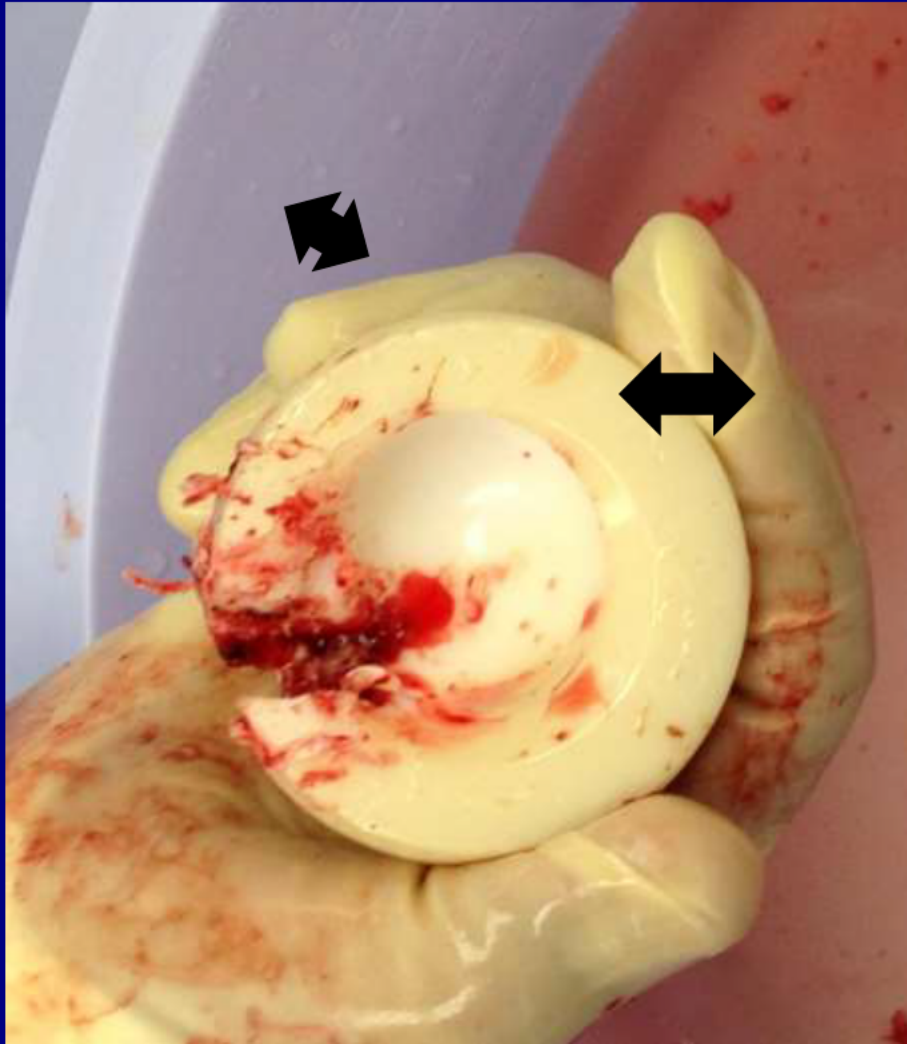
Bladder Compression



Polyethylene Liner

Fluid Aspirate

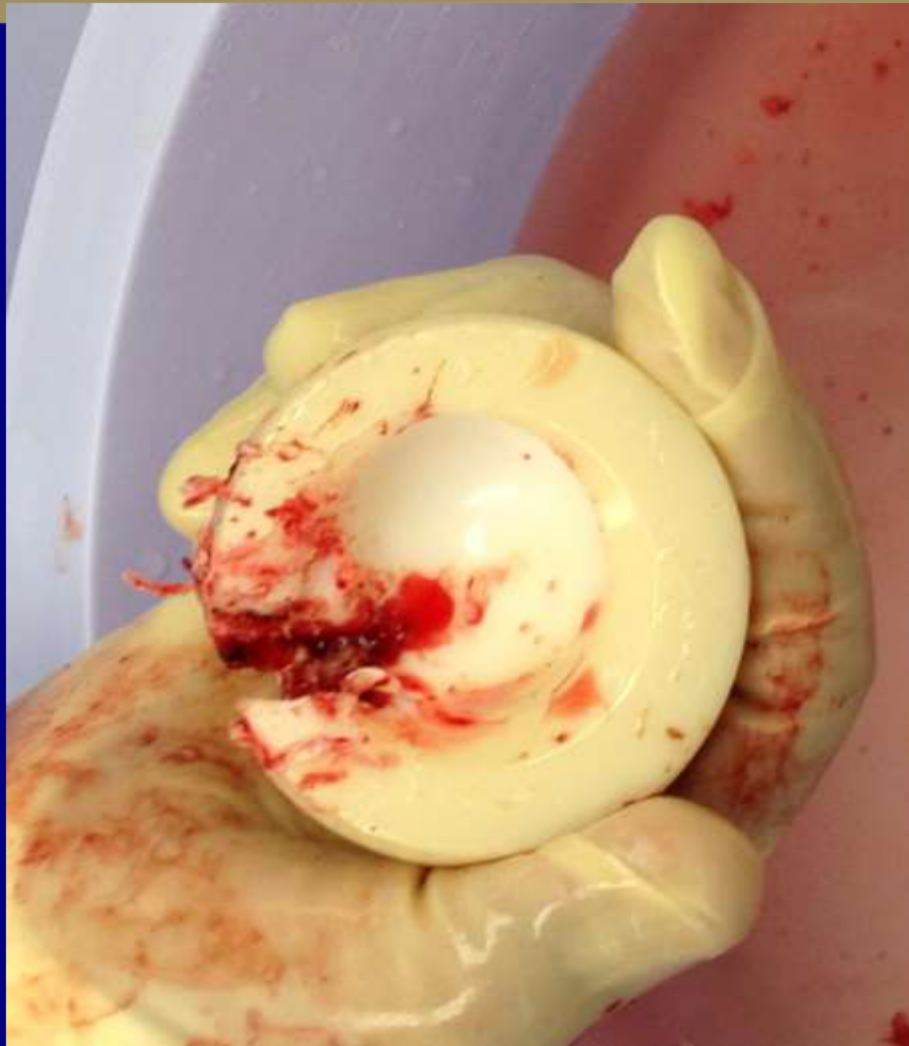



Polyethylene Liner

Fluid Aspirate

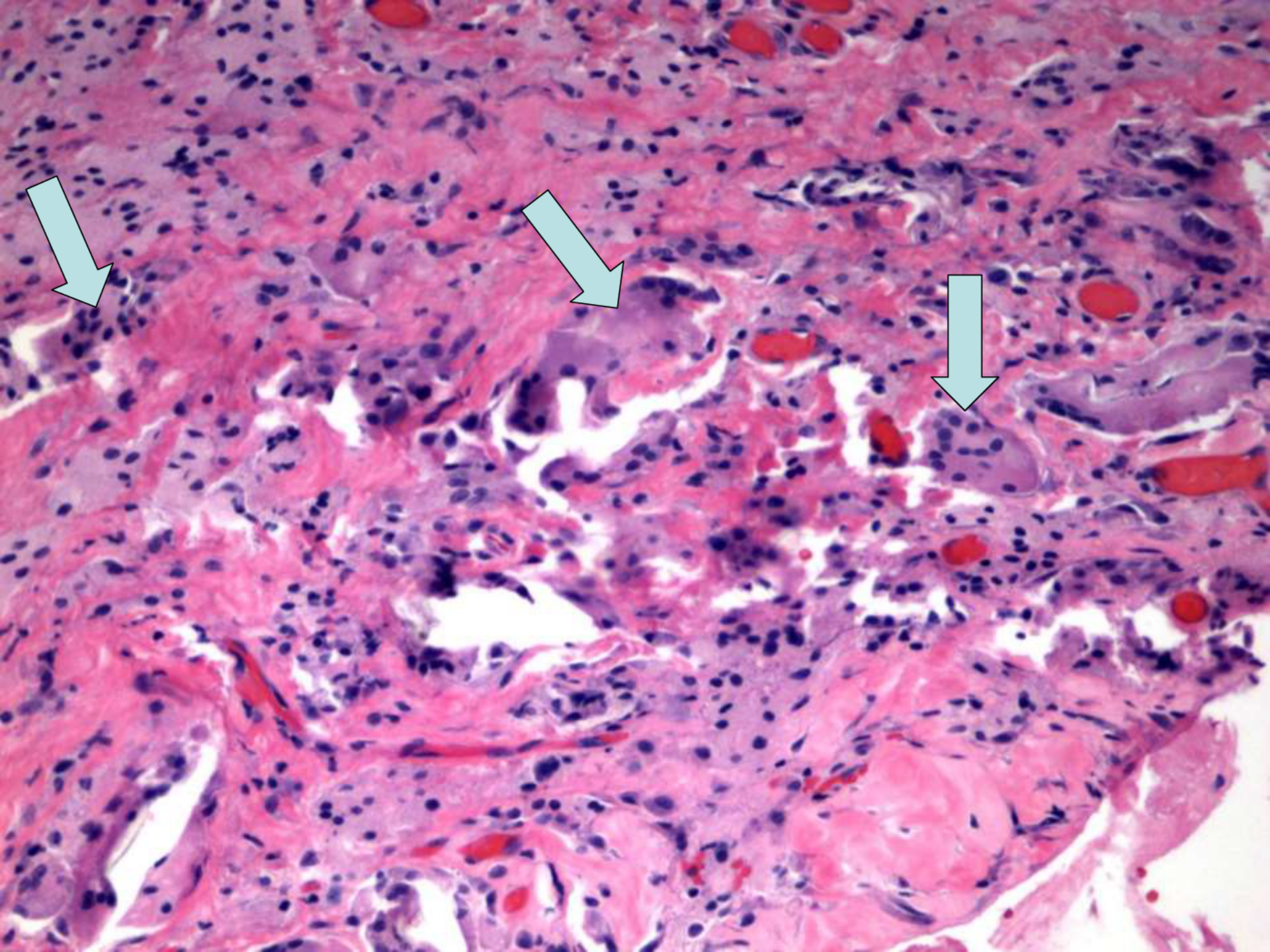


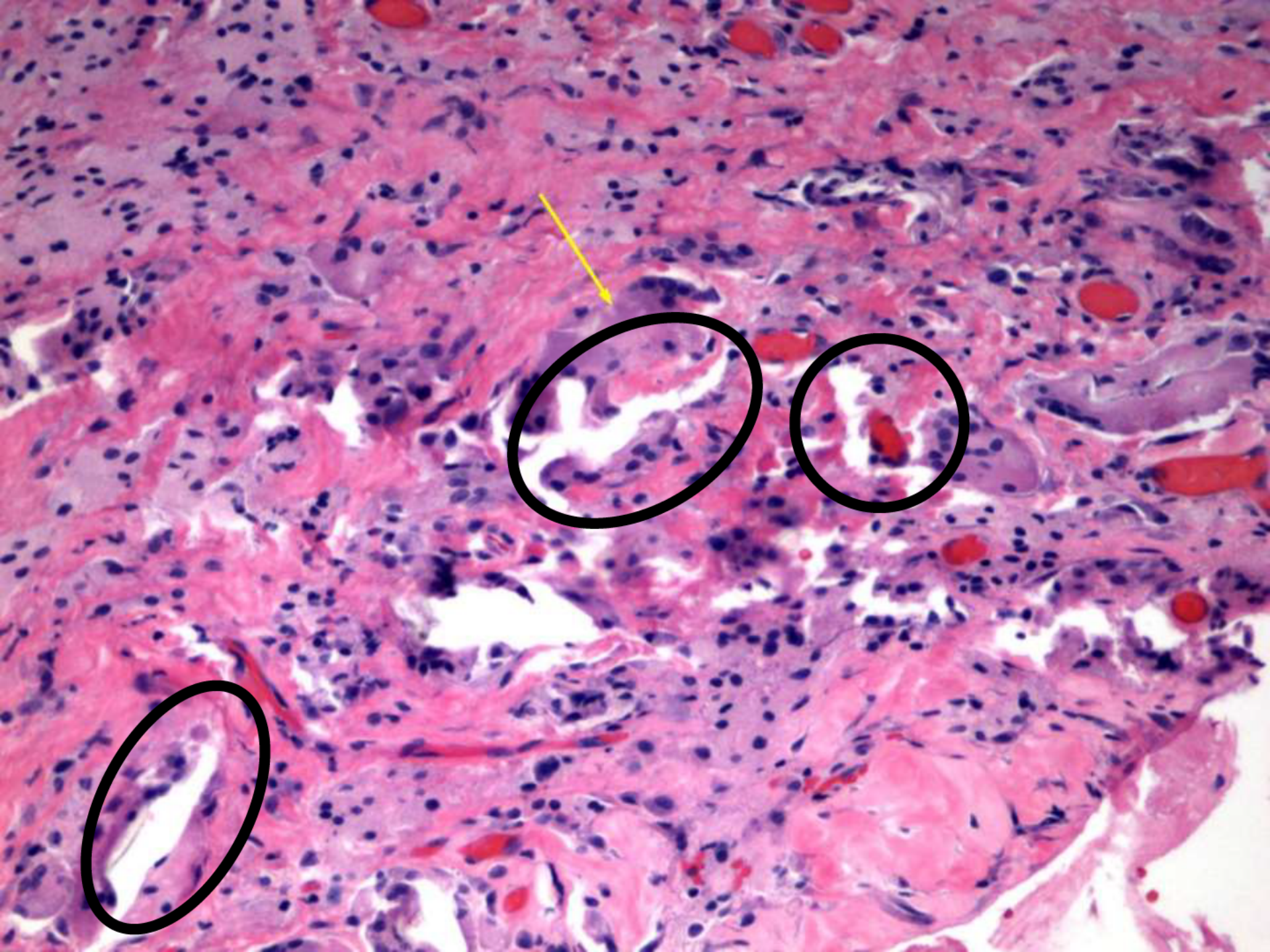


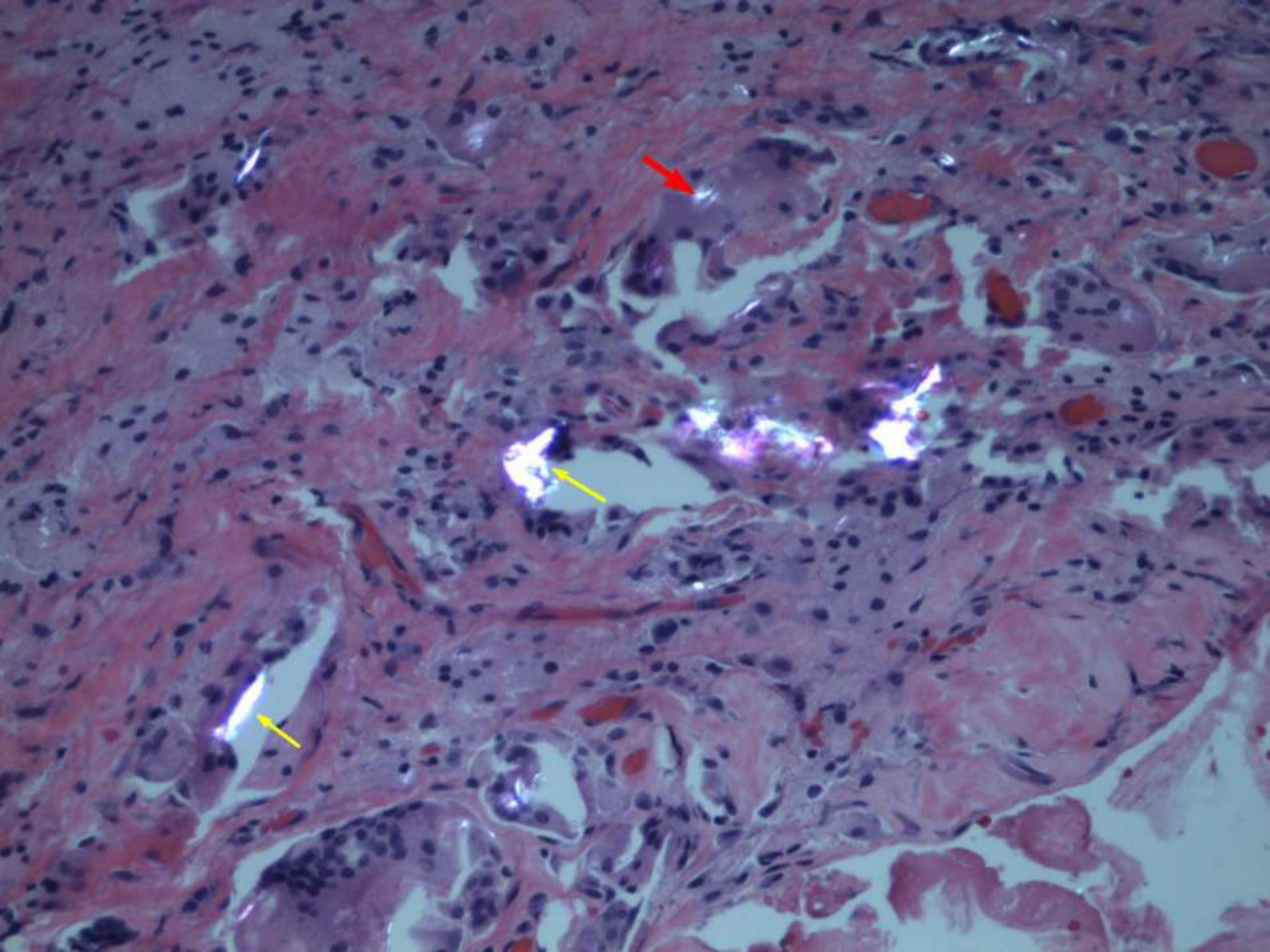
Polyethylene Liner

Fluid Aspirate



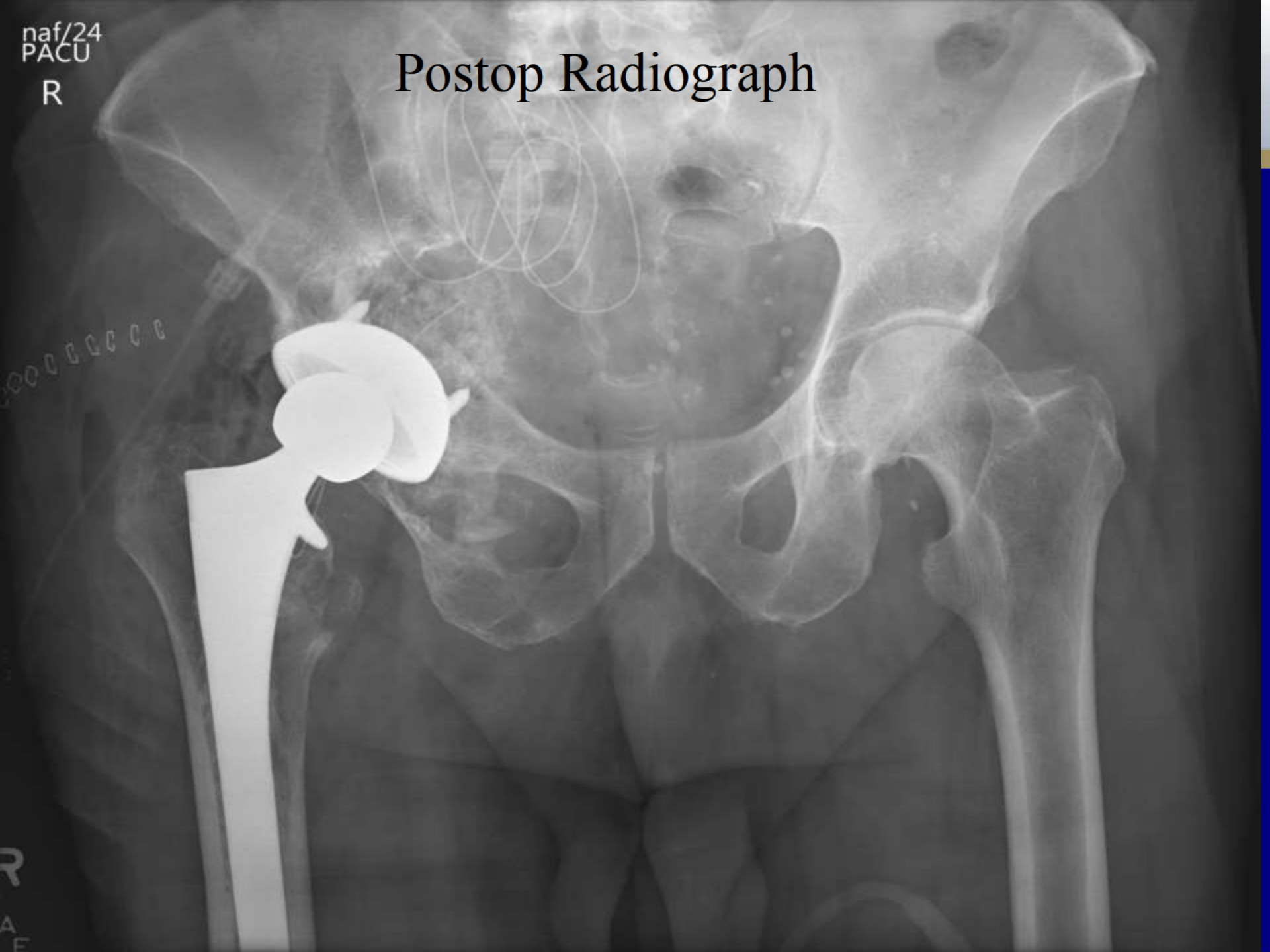






naf/24
PACU
R

Postop Radiograph



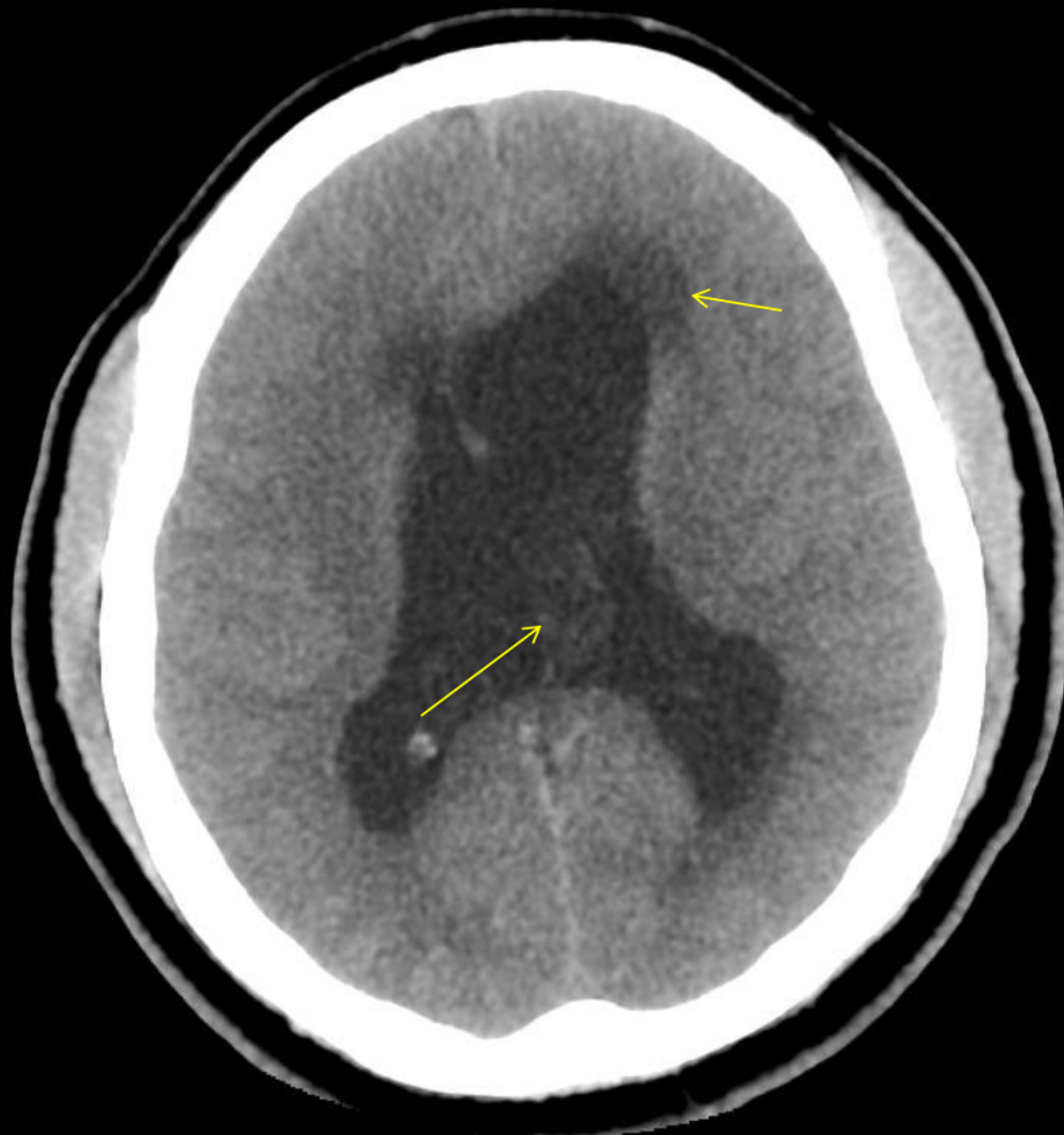
R
A
F

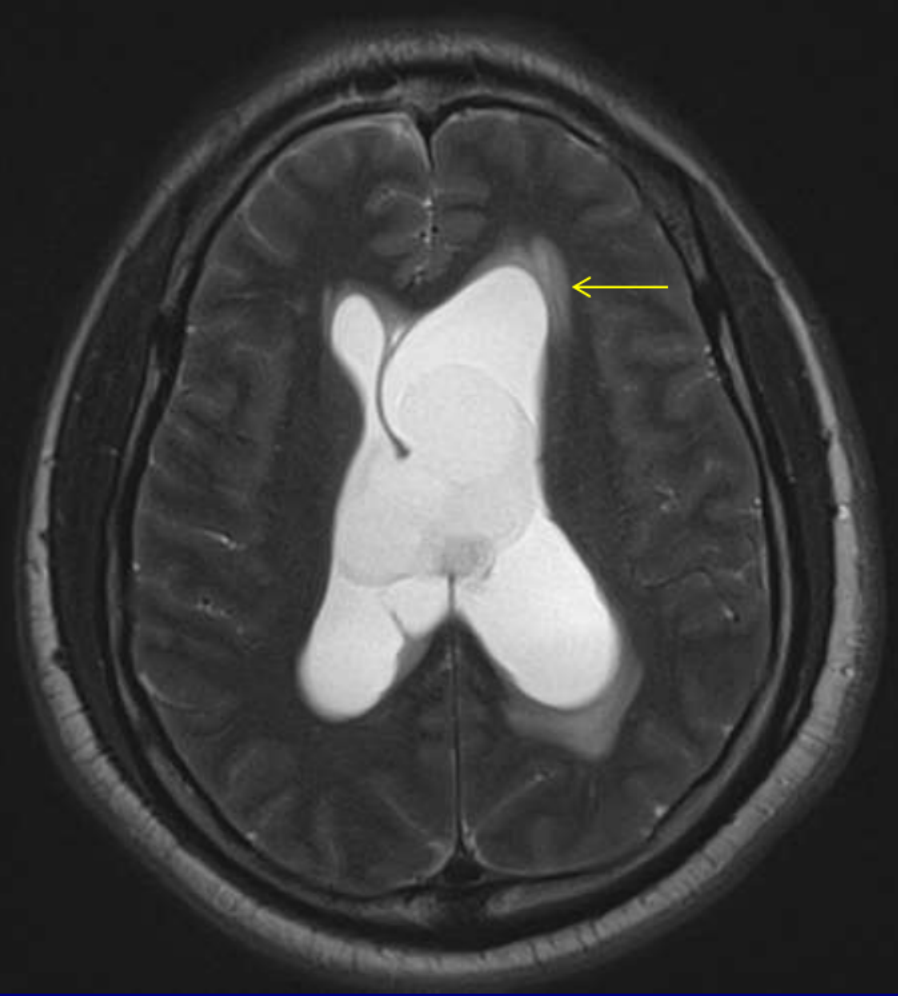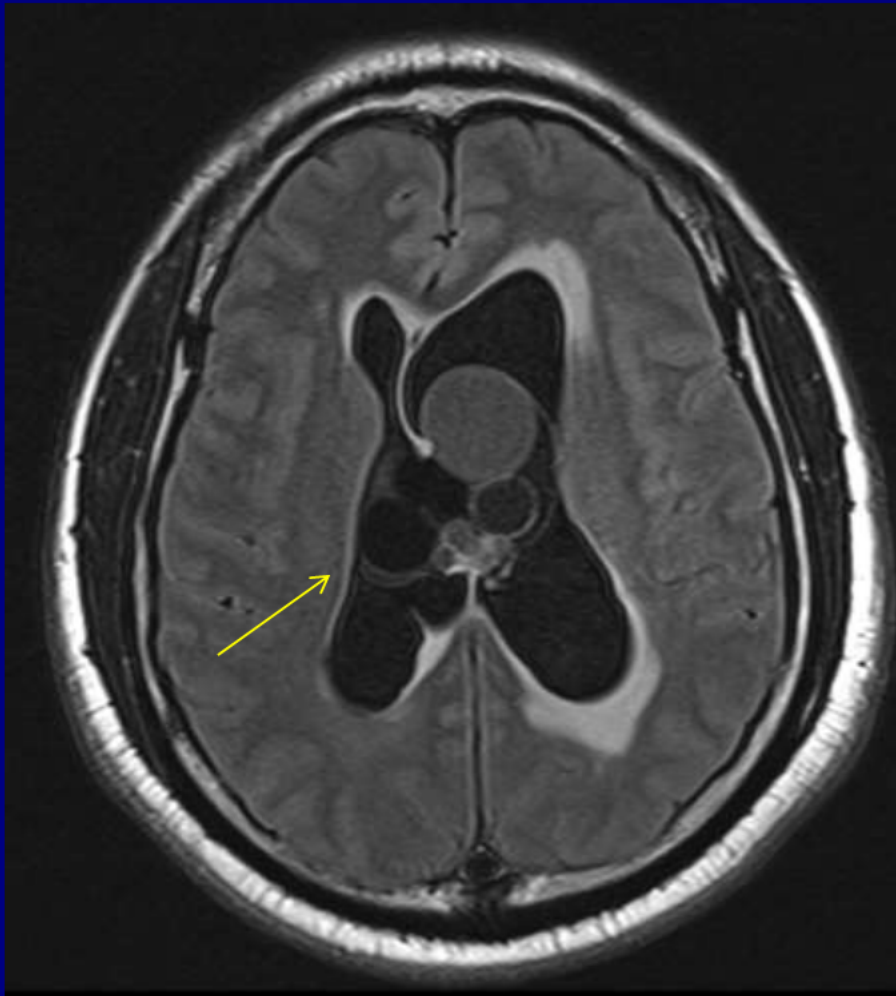
Small Particle Disease/Osteolysis

Jacob Harter, MD
Stanford University
Palo Alto, CA

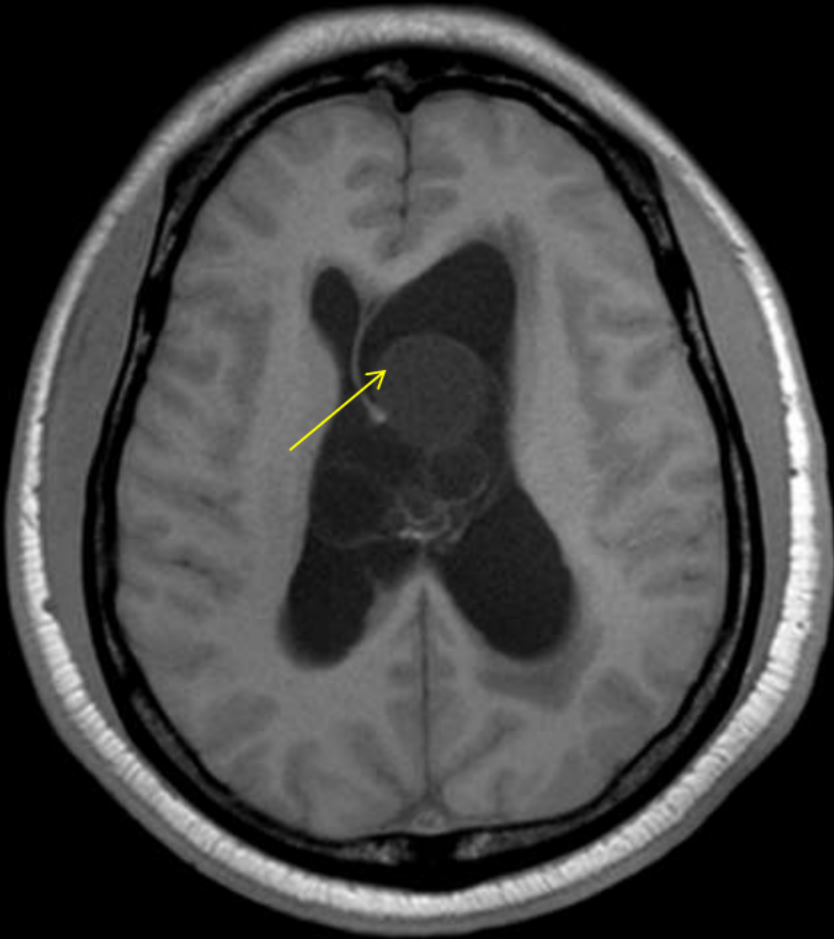Neuroradiology Best Case

45-year-old man with no significant past medical history, presenting with 1 week of worsening headache and cognitive dysfunction

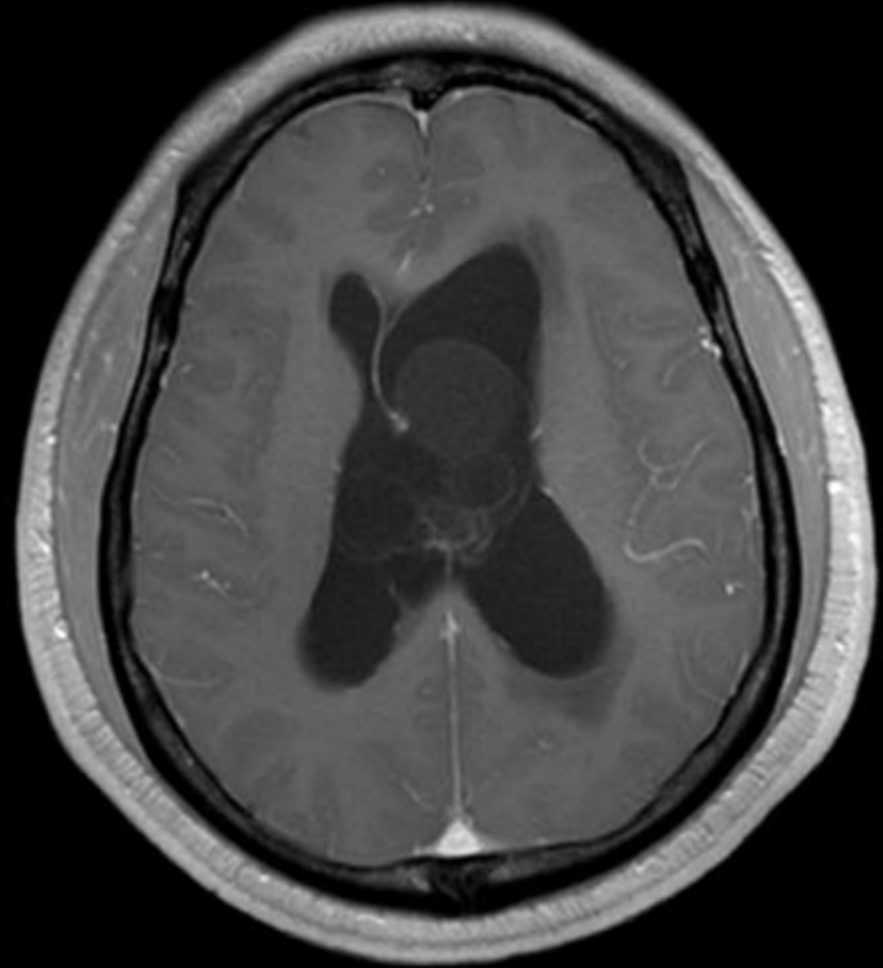


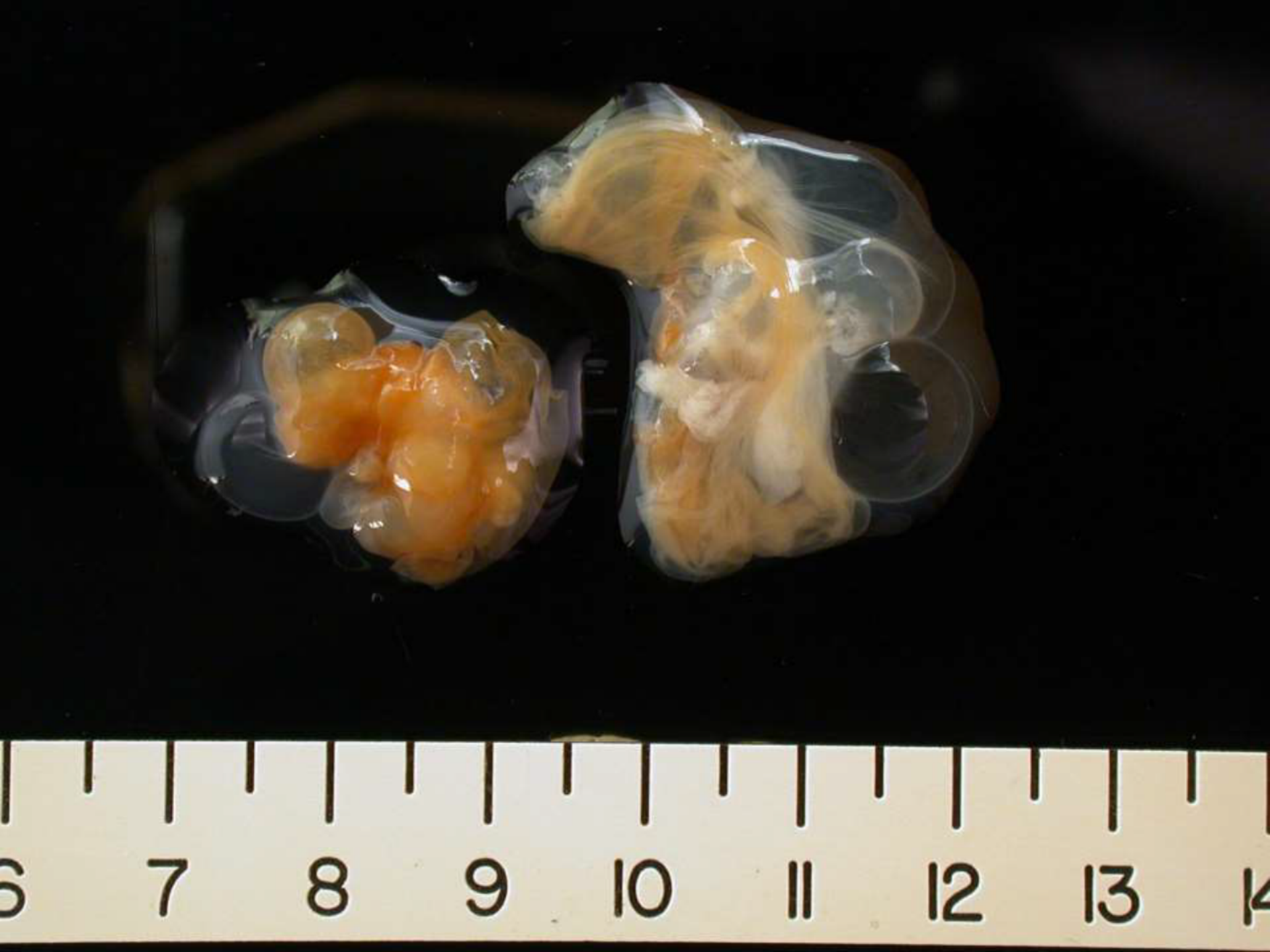

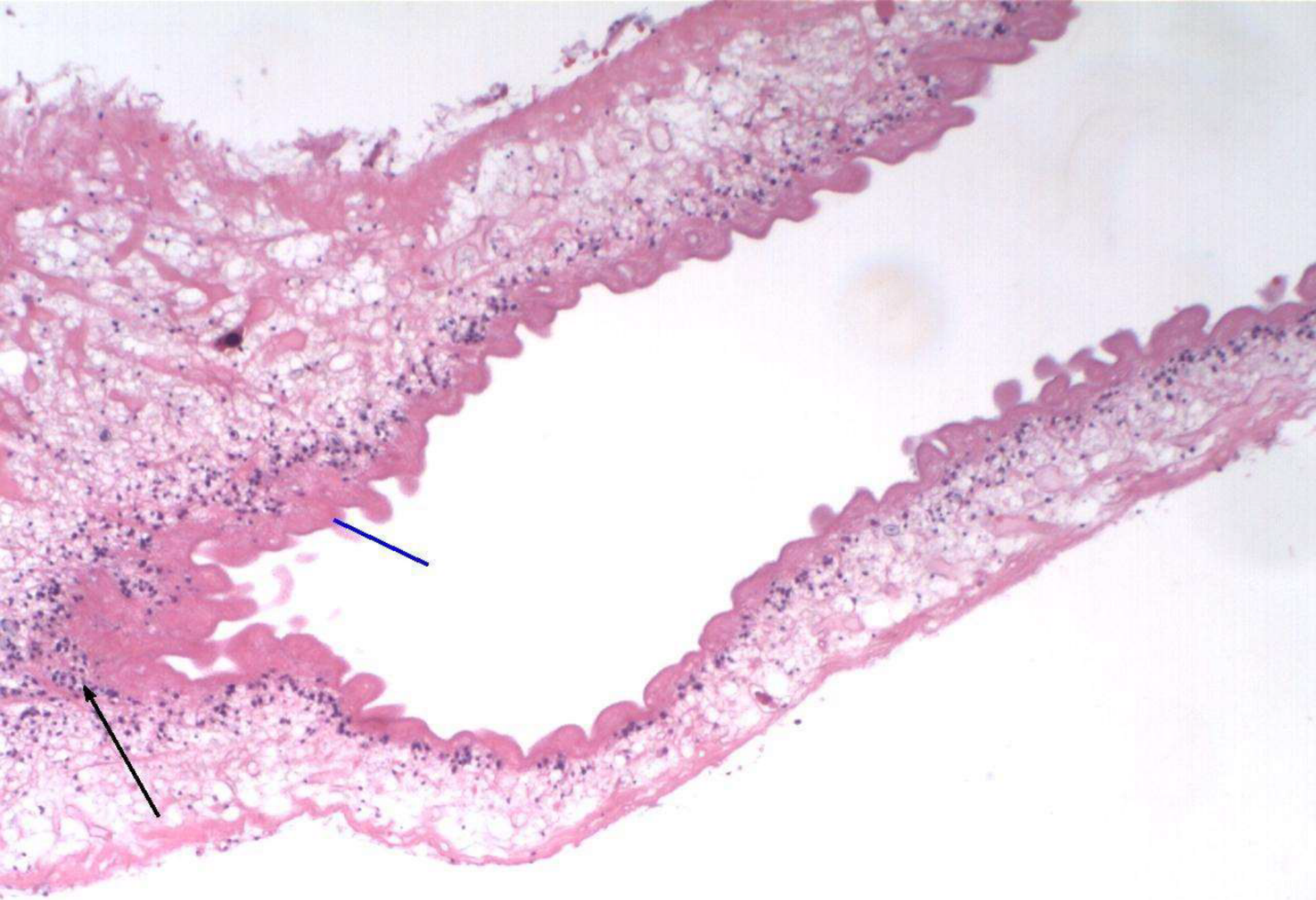Ax T1 pre



Ax T1 post





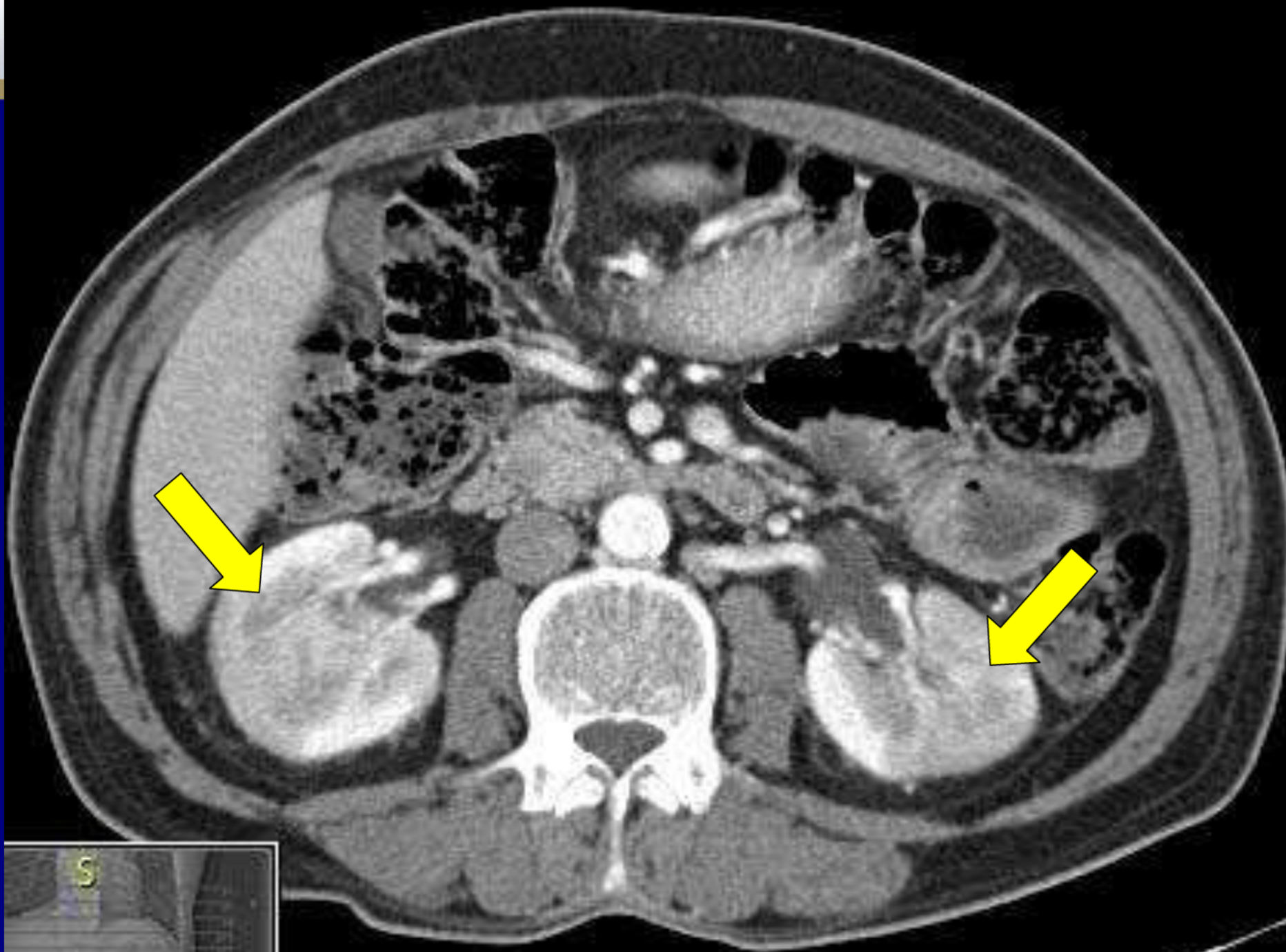


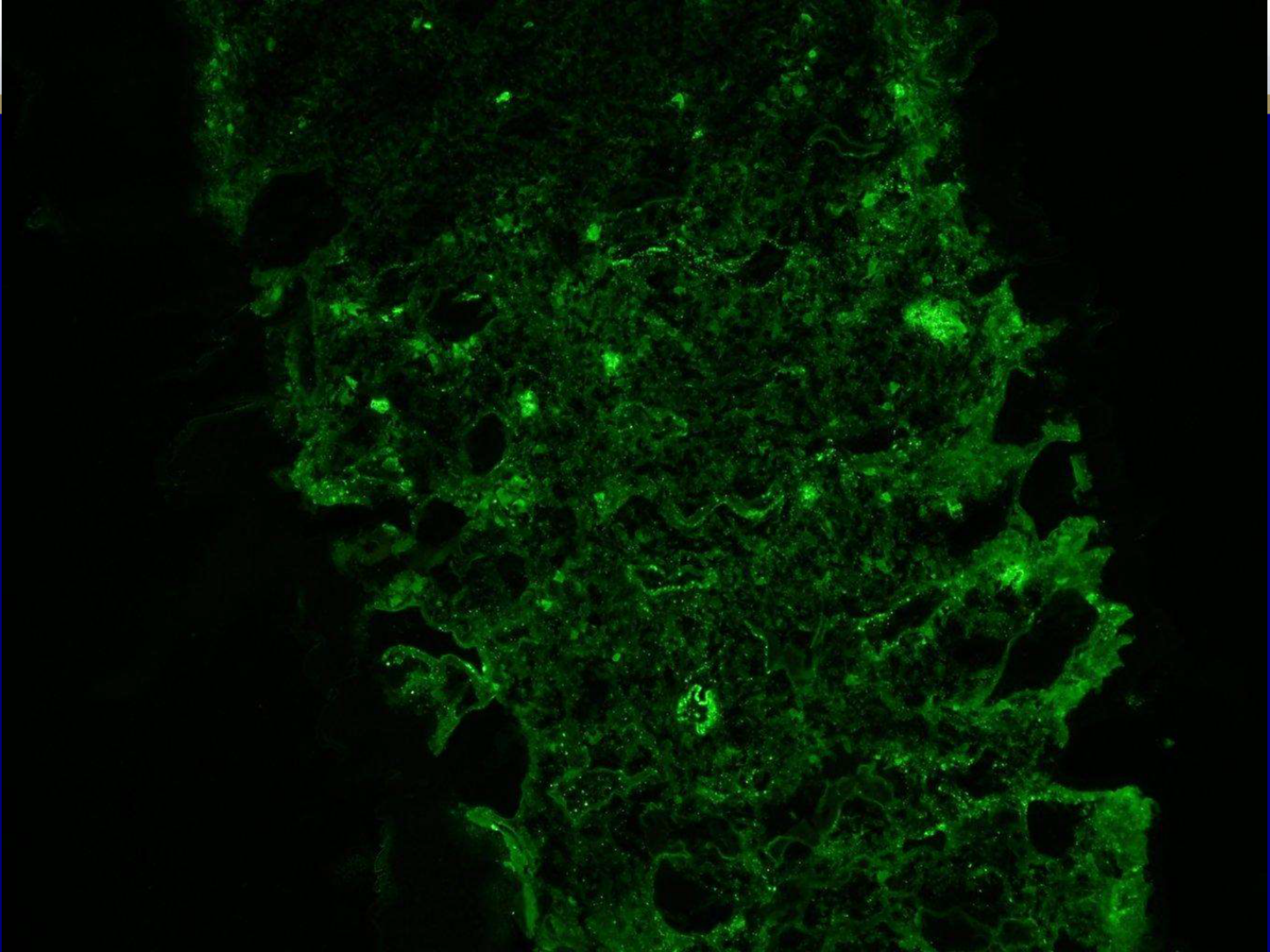
Neurocysticercosis

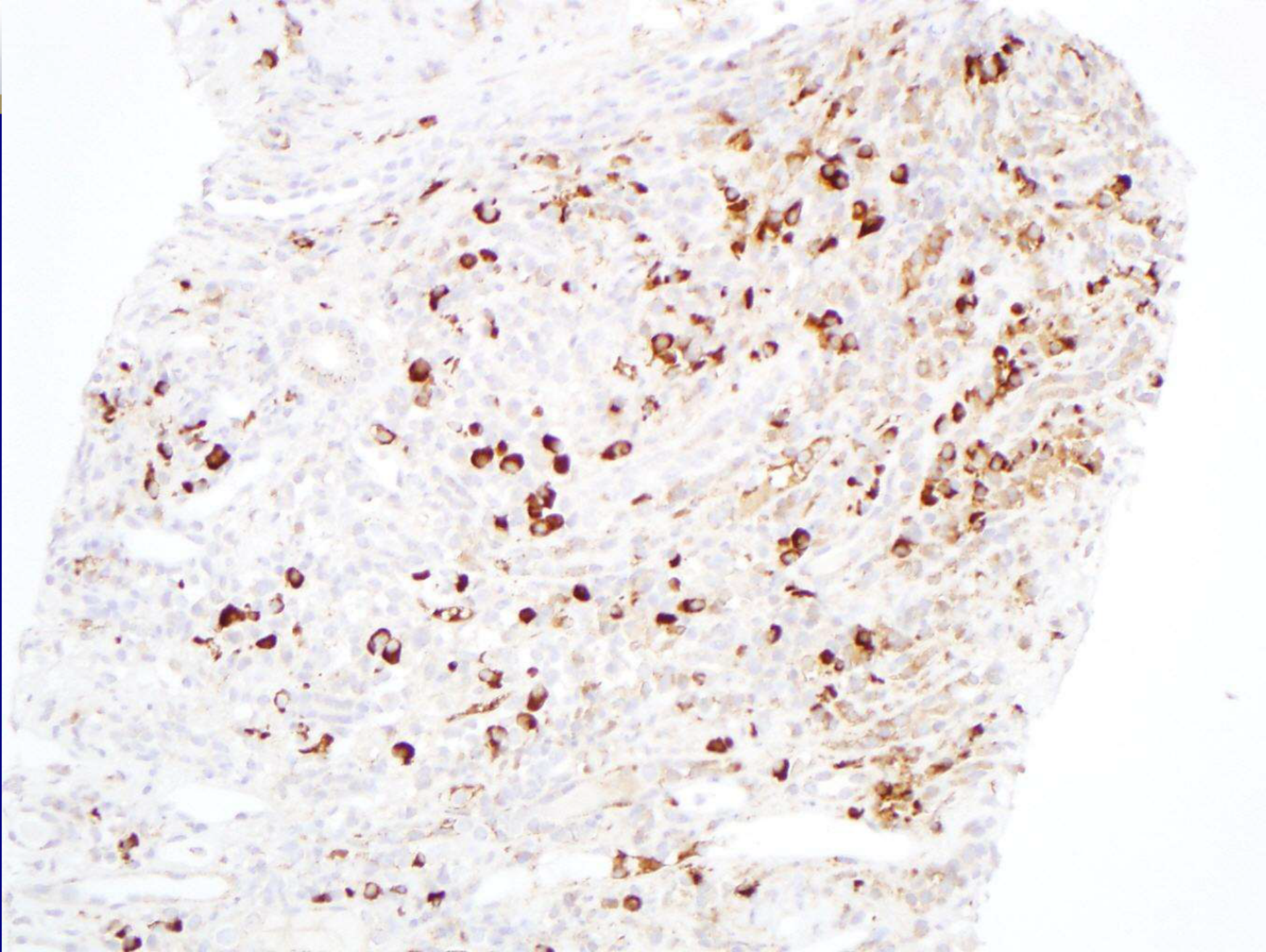
Jordan LeGout, MD
University of Florida
Gainesville, Florida

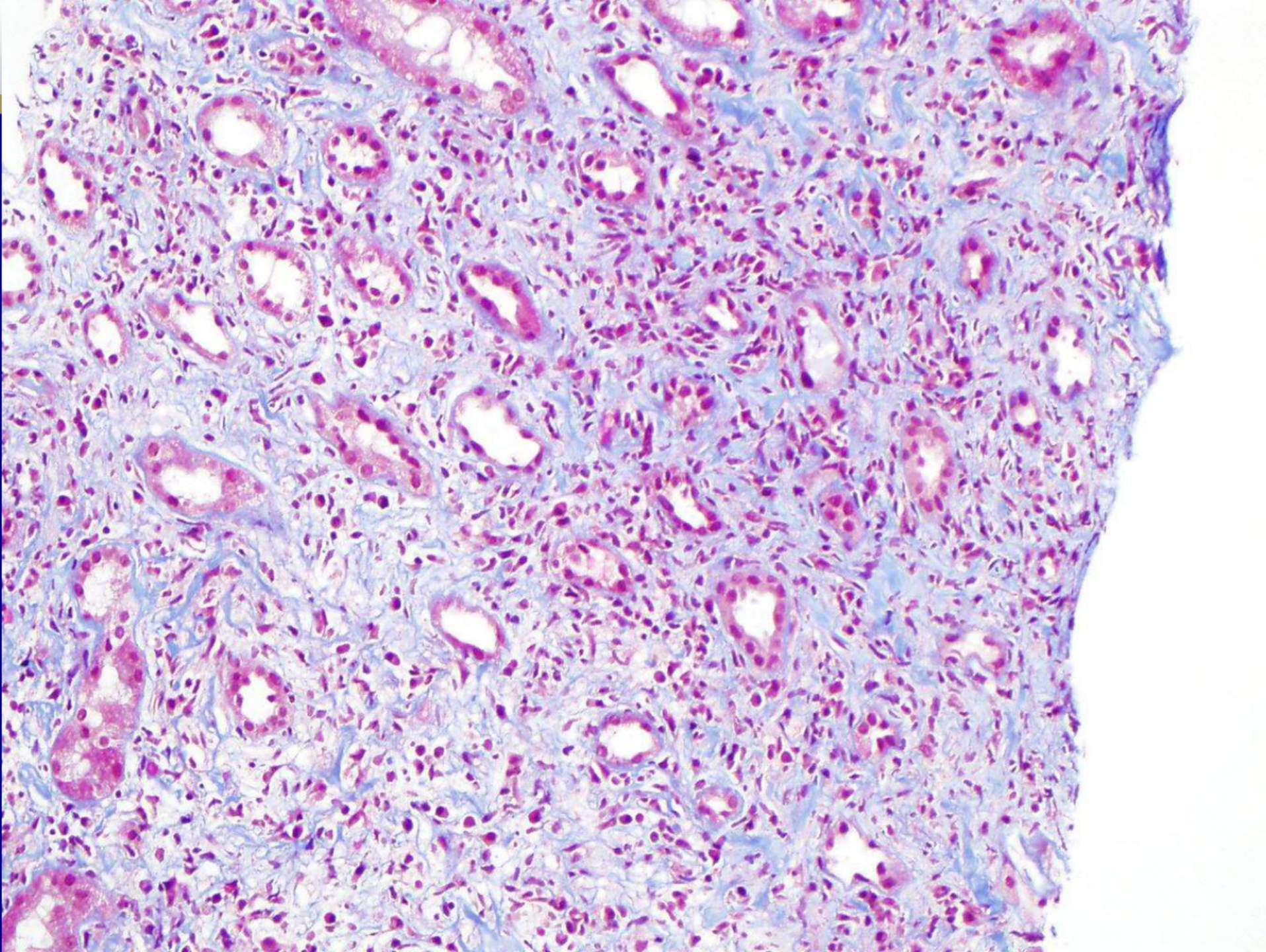
Genitourinary Best Case

66-year-old man with epigastric pain and history of mild pancreatitis 6 months ago





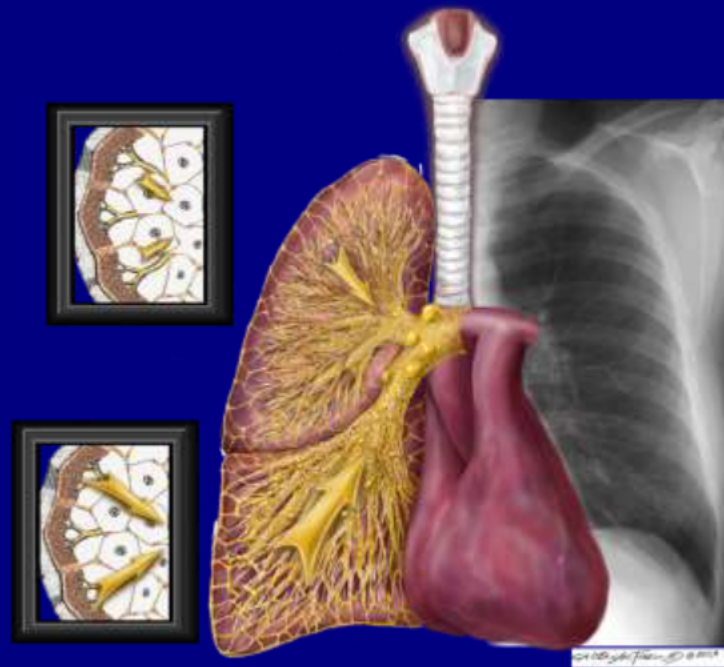




IgG4-related Tubulointerstitial Nephritis

Jay Vlaminck, MD
Mayo Clinic
Rochester, Minnesota

PULMONARY AND MEDIASTINAL IMAGING



46-year-old female with rheumatoid arthritis who presents with left-sided chest pain and shortness of breath

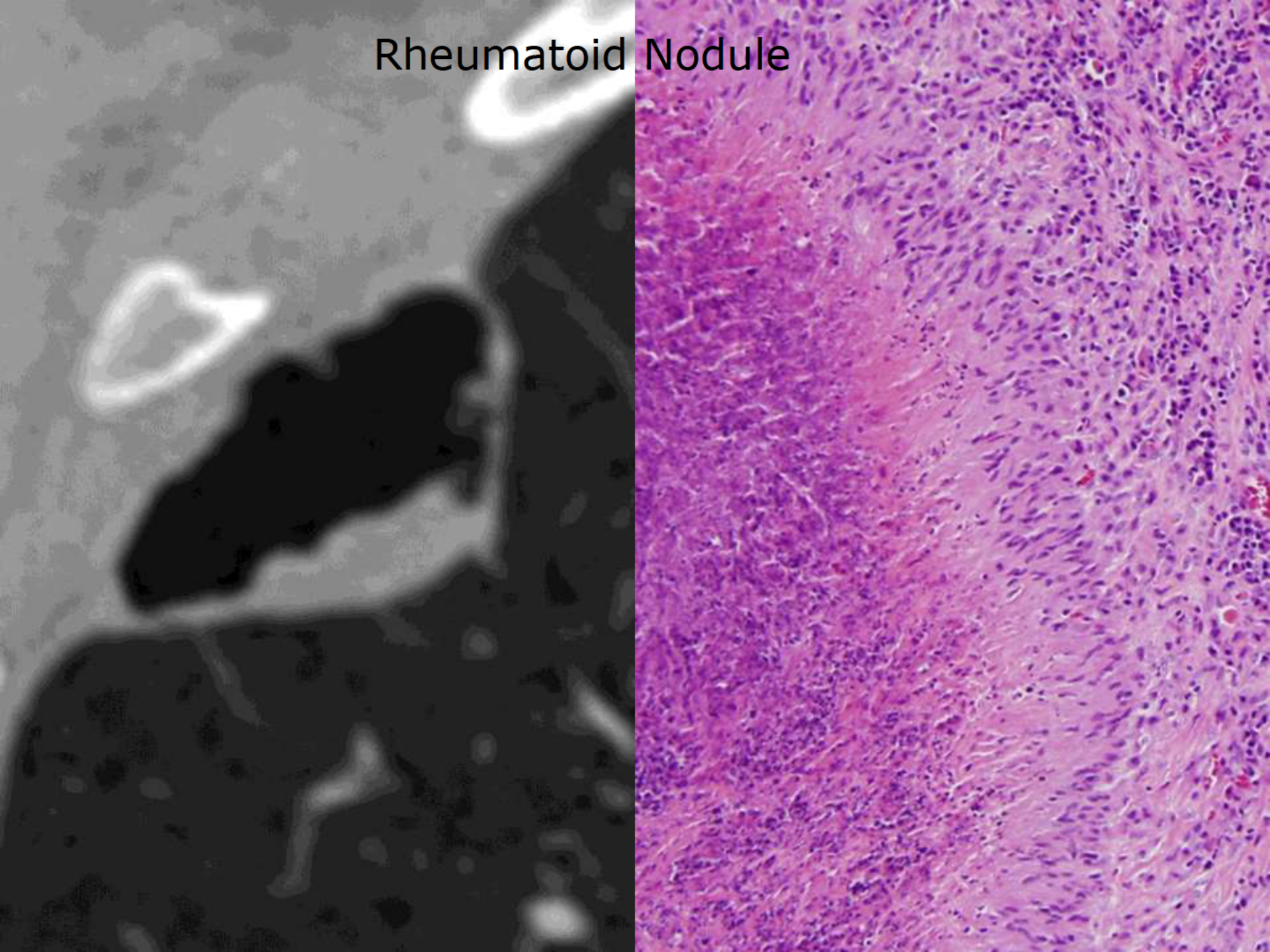
Cavitary Nodule

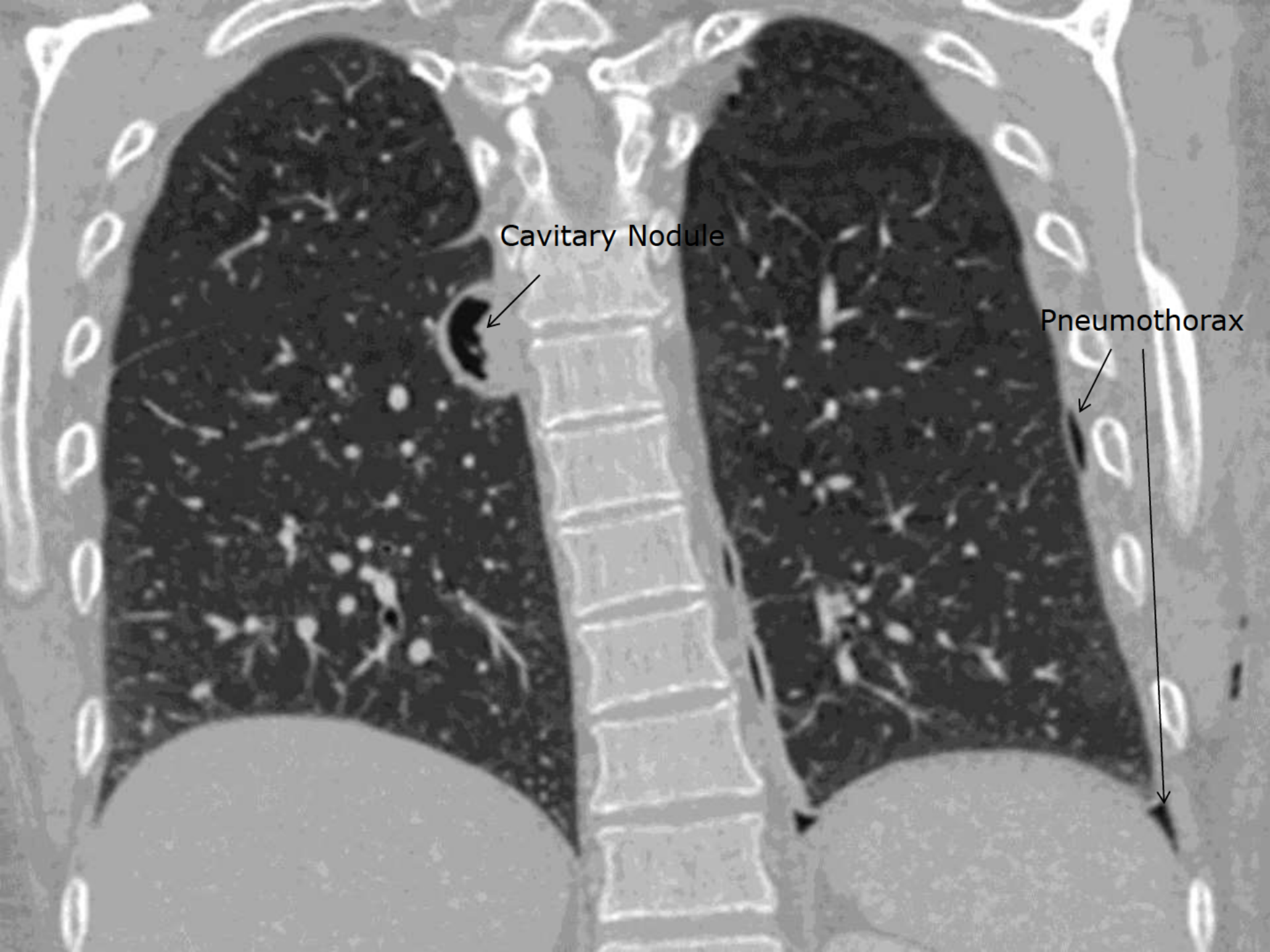


Cavitary Nodule



Rheumatoid Nodule

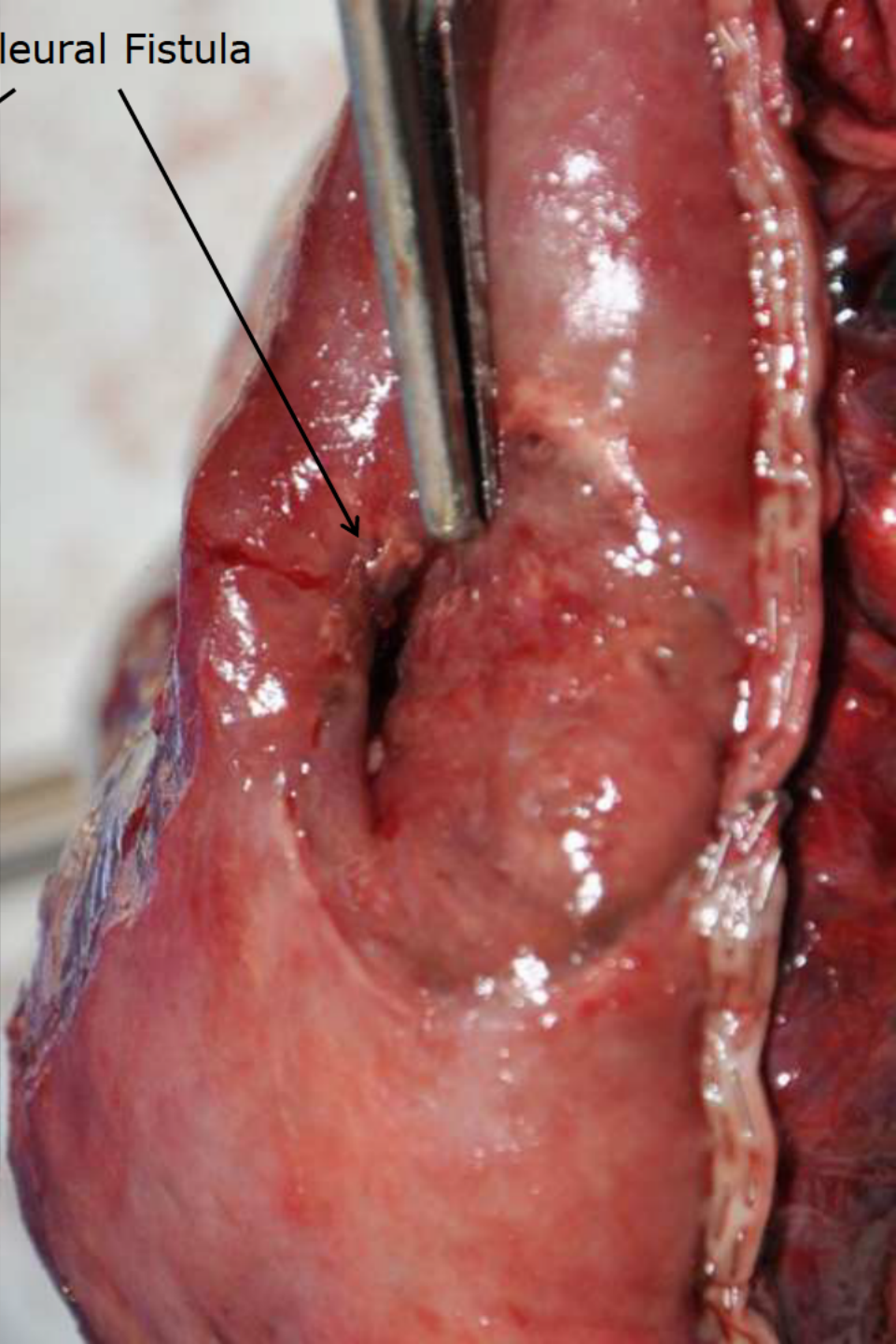
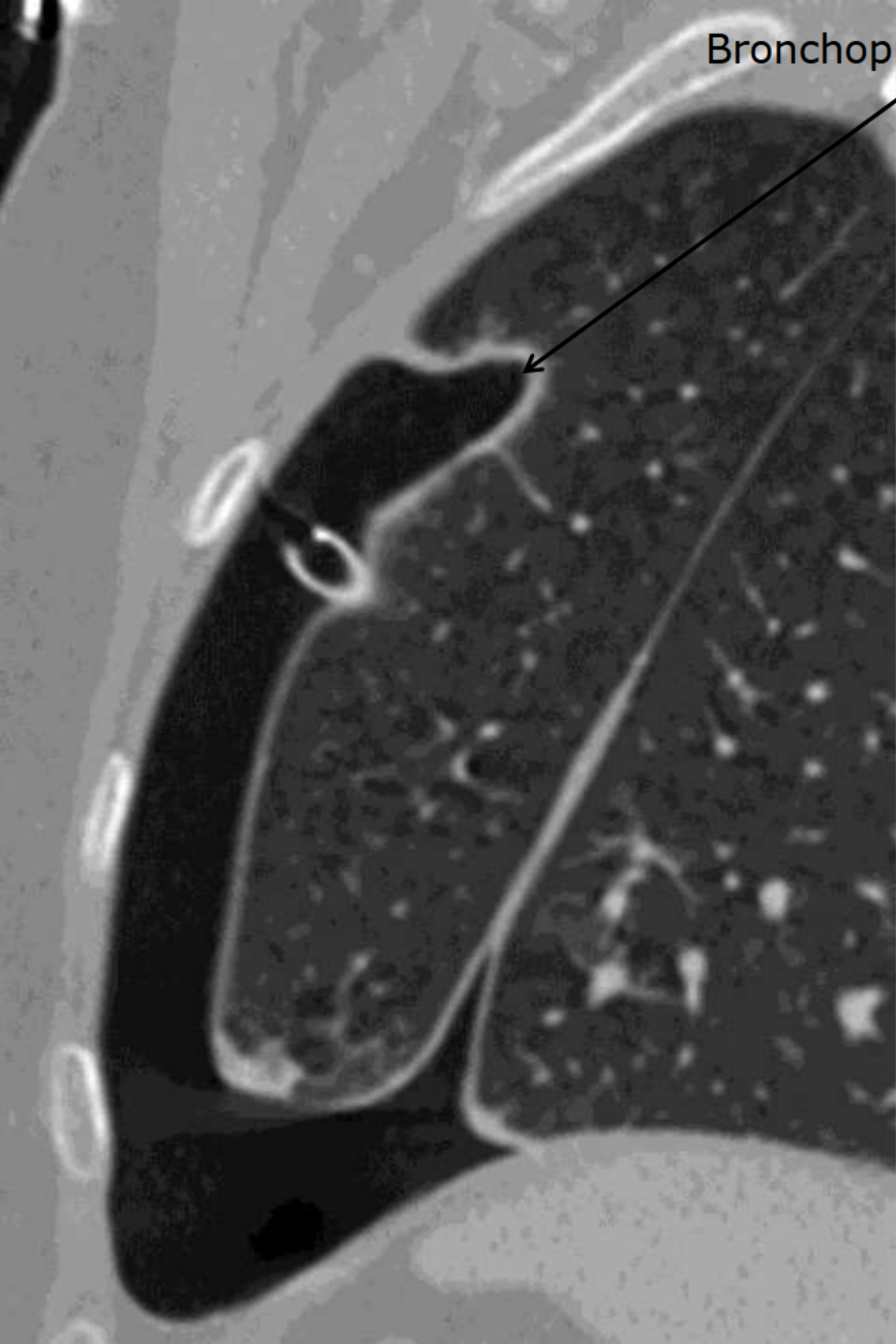




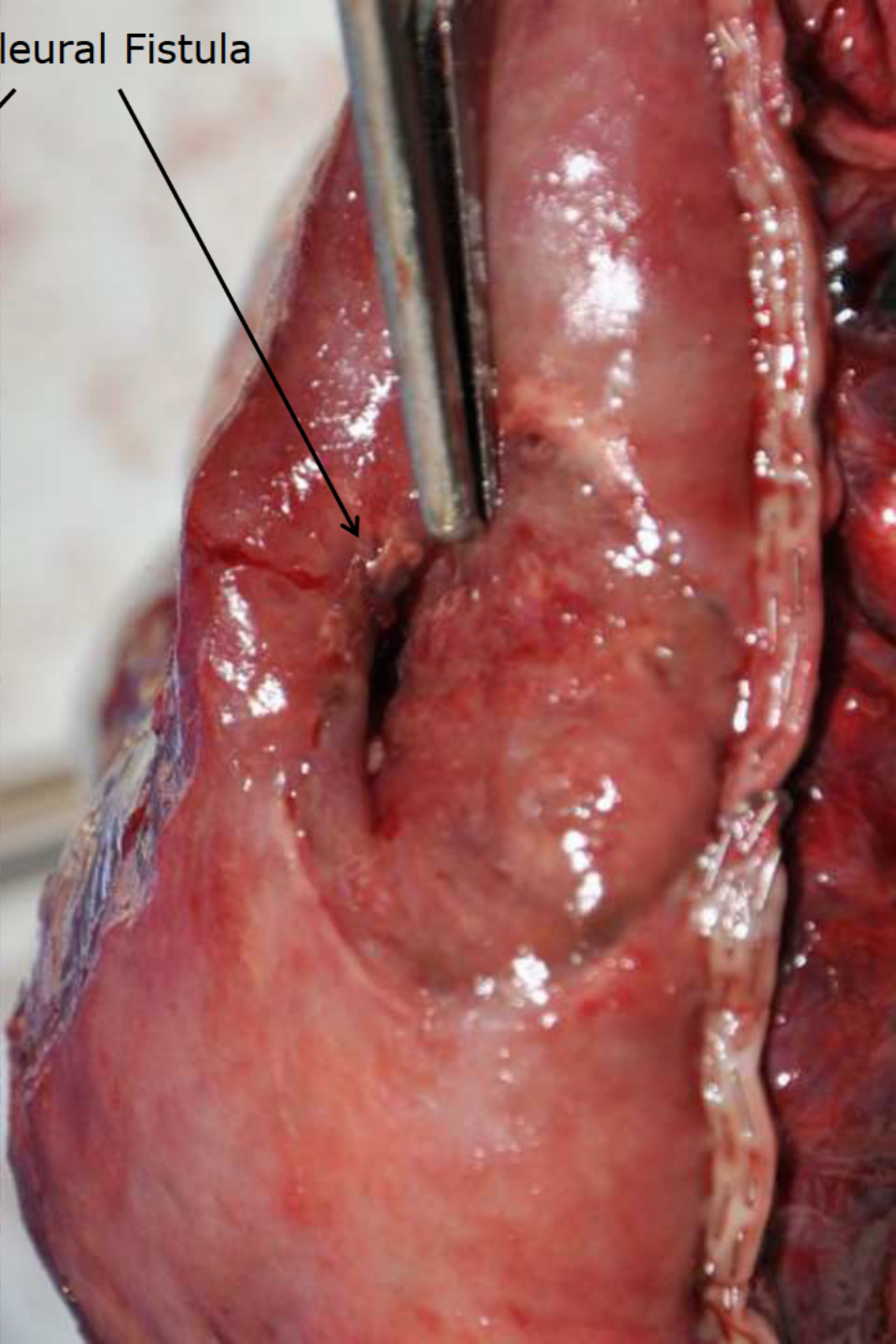
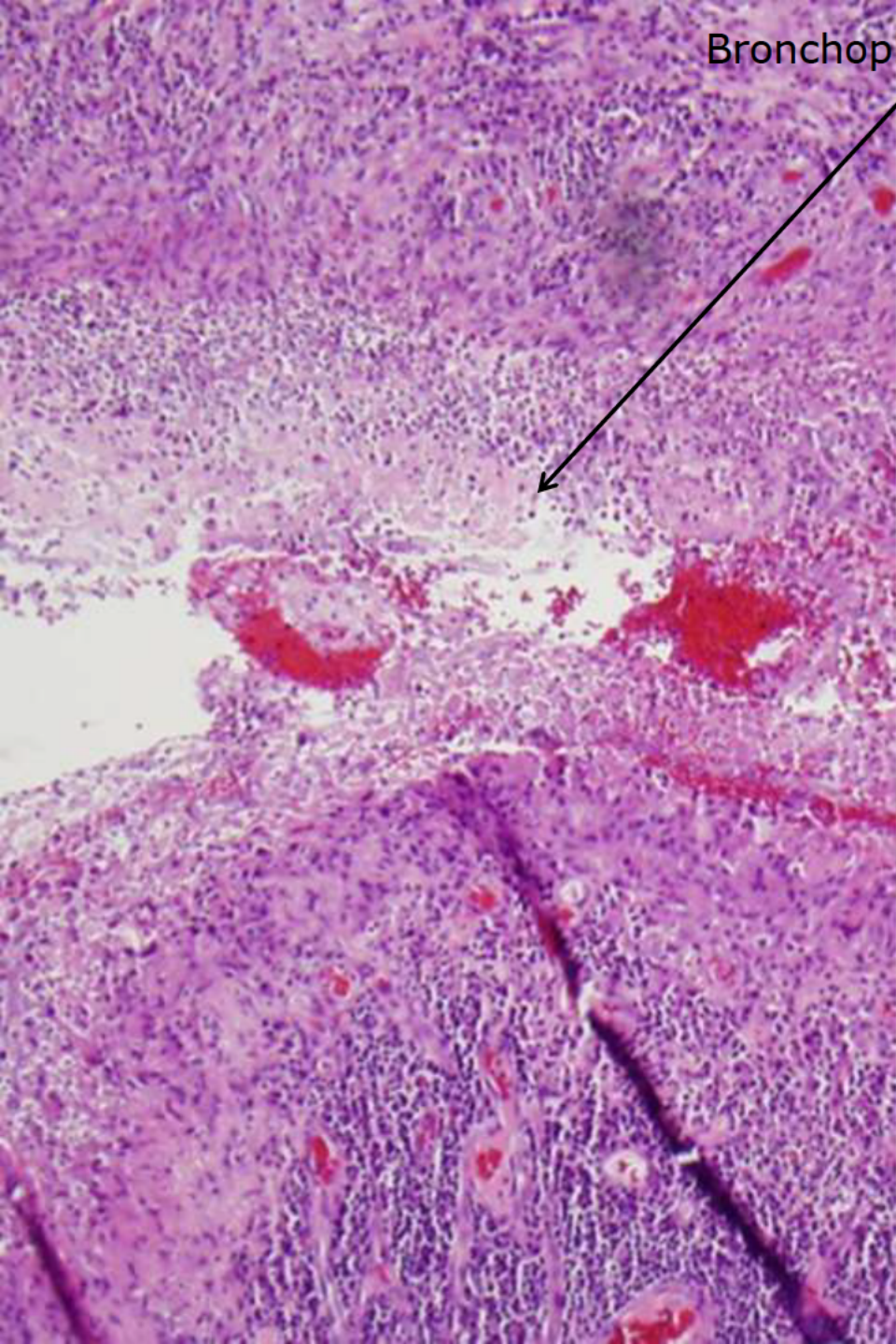
Cavitary Nodule

Pneumothorax

Bronchopleural Fistula



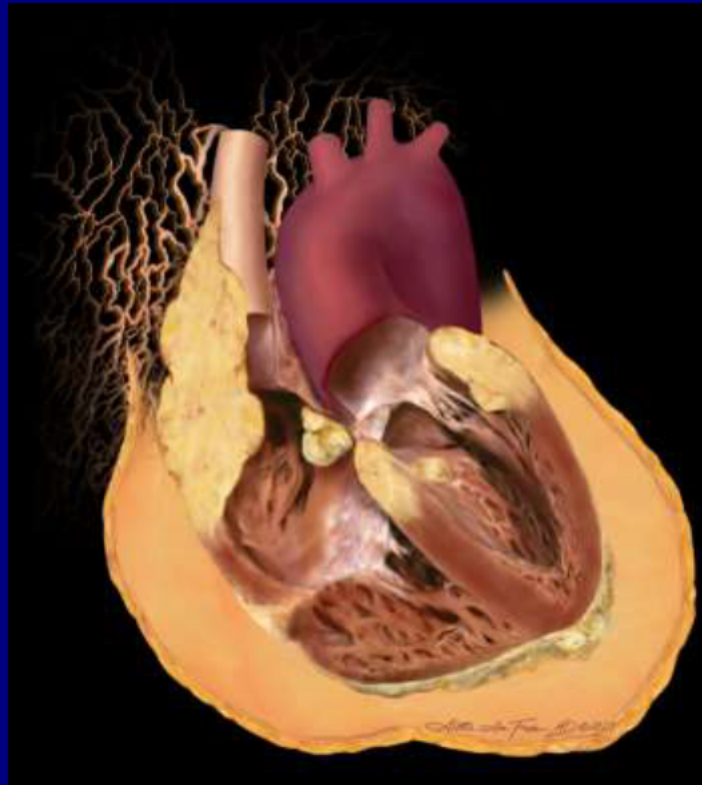
Bronchopleural Fistula



Rheumatoid Nodules with Bronchopleural Fistula

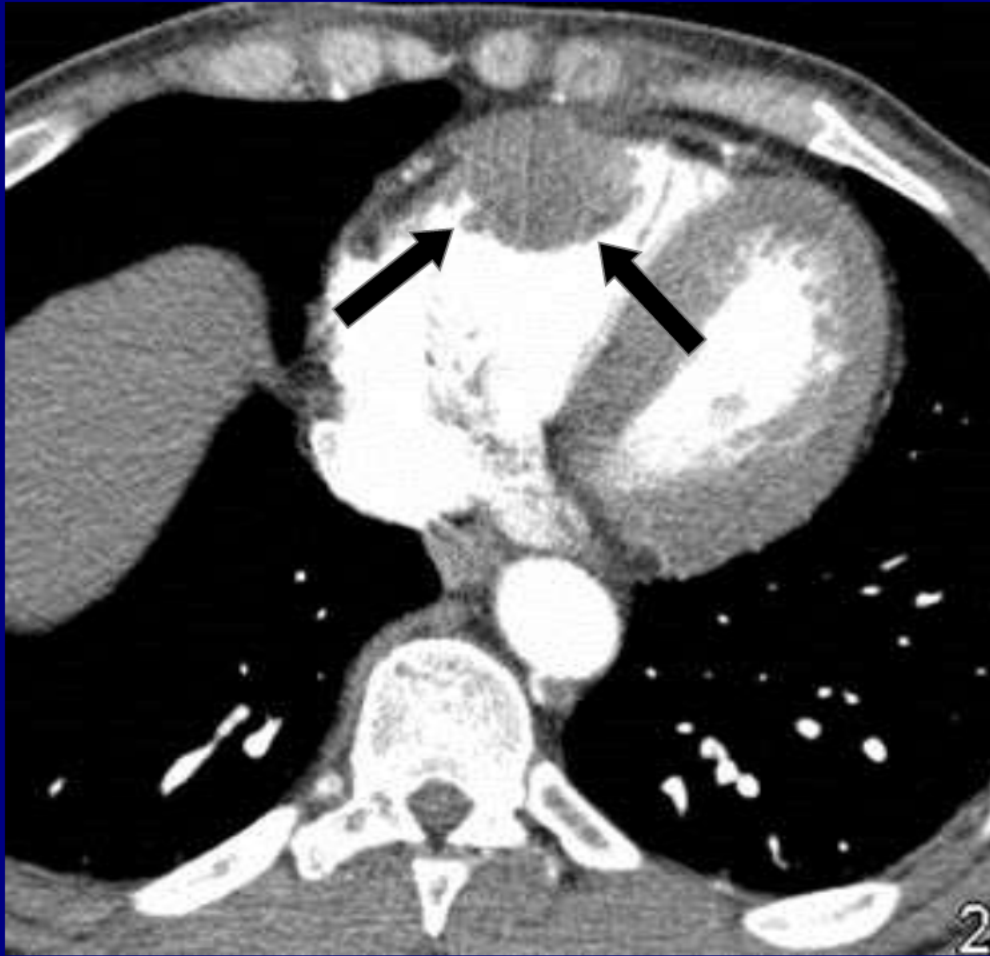
John Cho, MD
Geisinger Health System
Danville, Pennsylvania

Cardiovascular Imaging

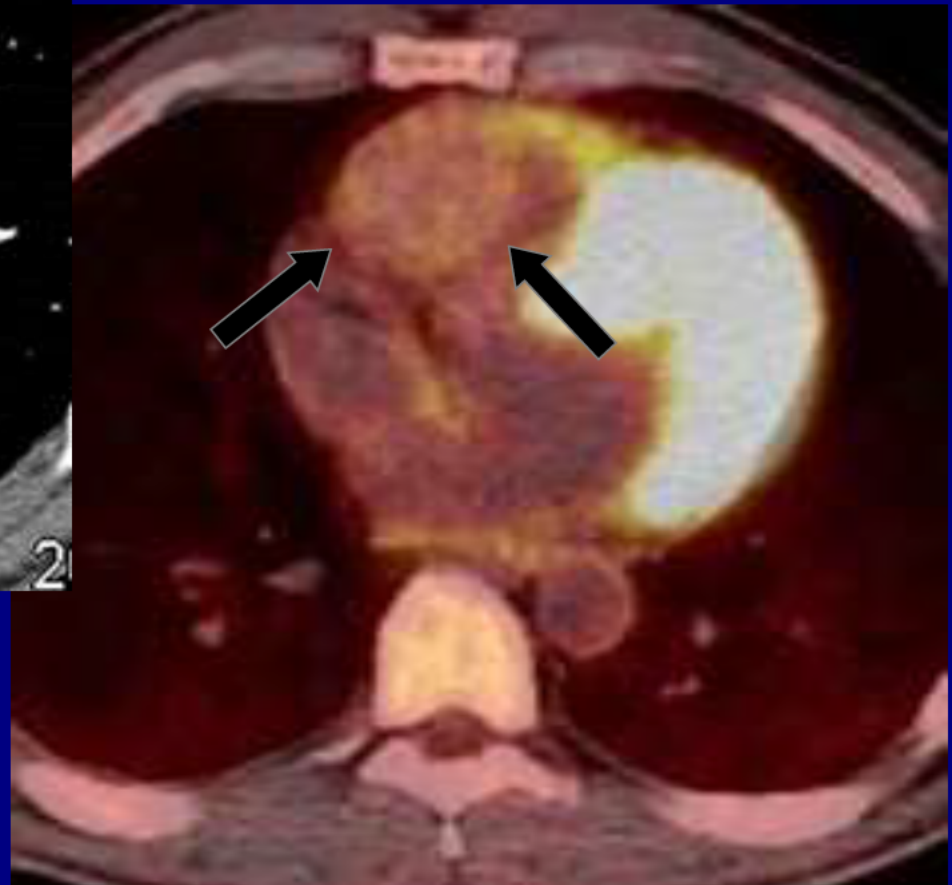
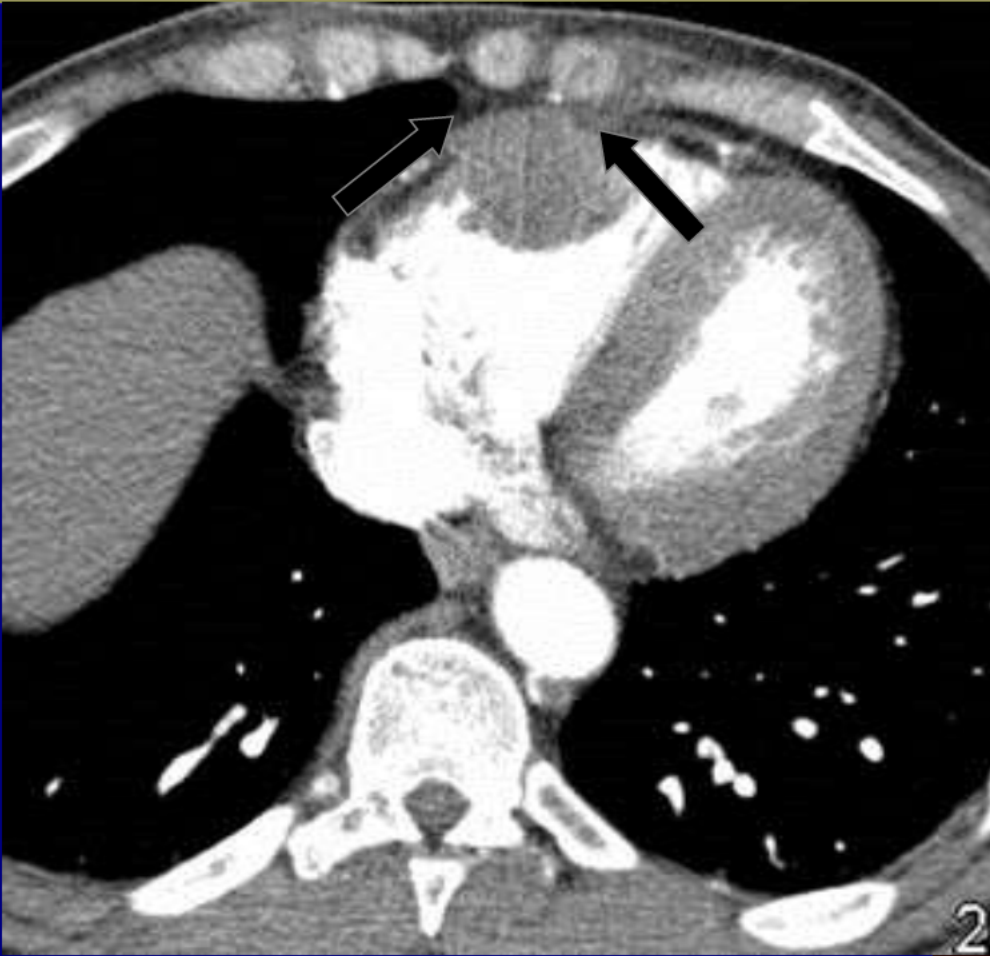


46-year old male presents to ER status post syncopal episode with several days of pleuritic chest pain

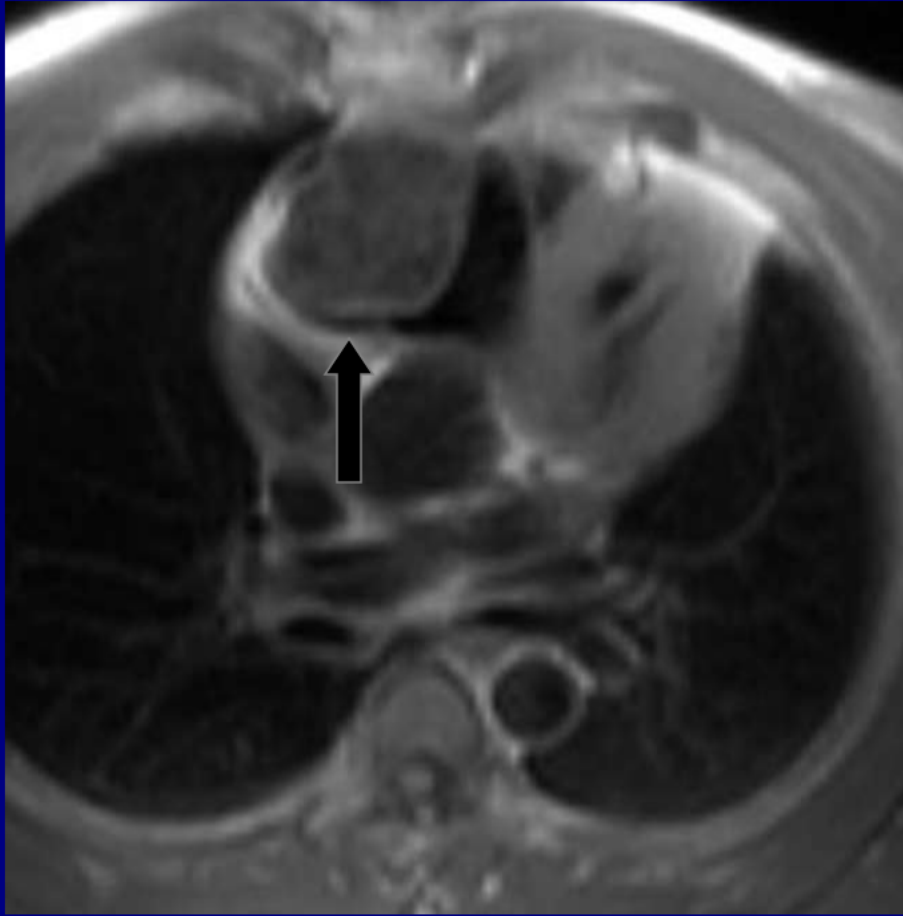
EKG demonstrated right bundle branch block with nonspecific ST-T wave changes. Cardiac enzymes within normal limits



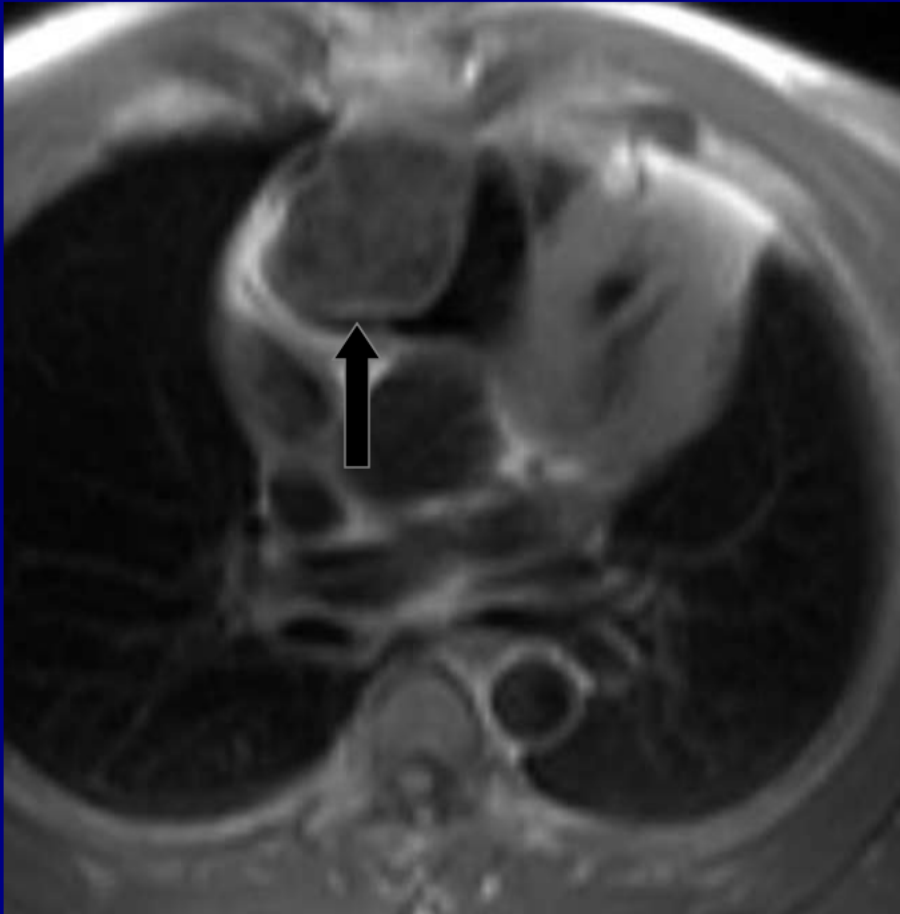
CTA: partly intramural, partly intracavitary soft tissue mass centered in right ventricular wall



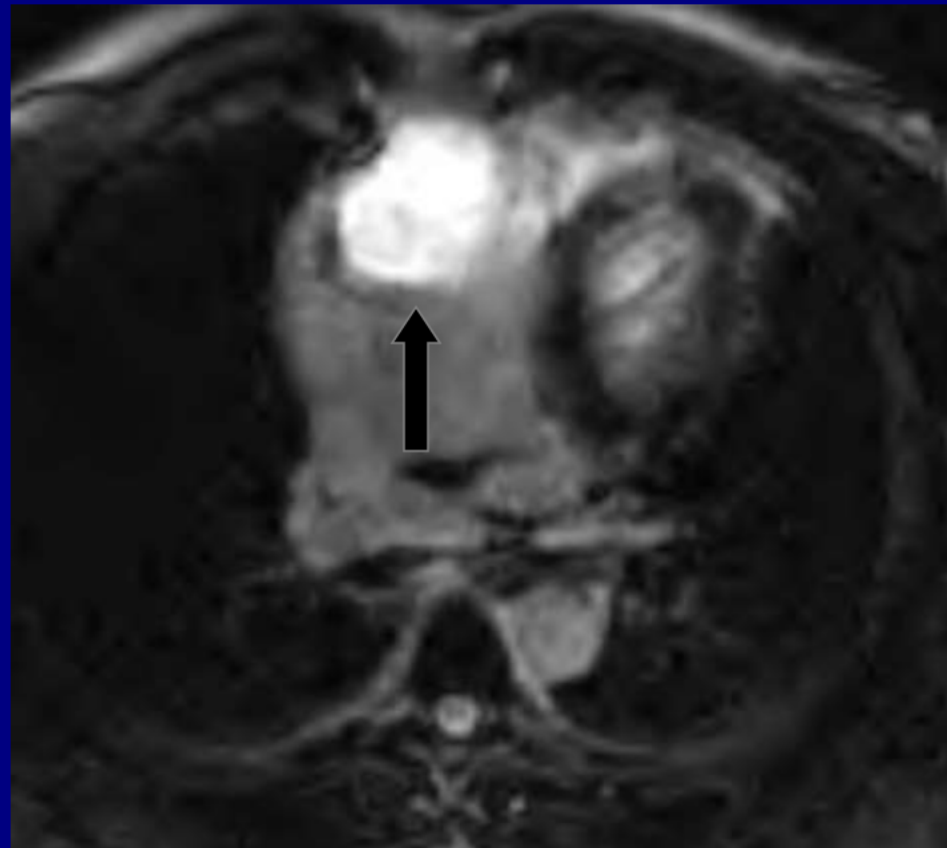
Fused PET/CT: mild tracer uptake within the lesion (max 2.9 SUV) with relative central photopenia

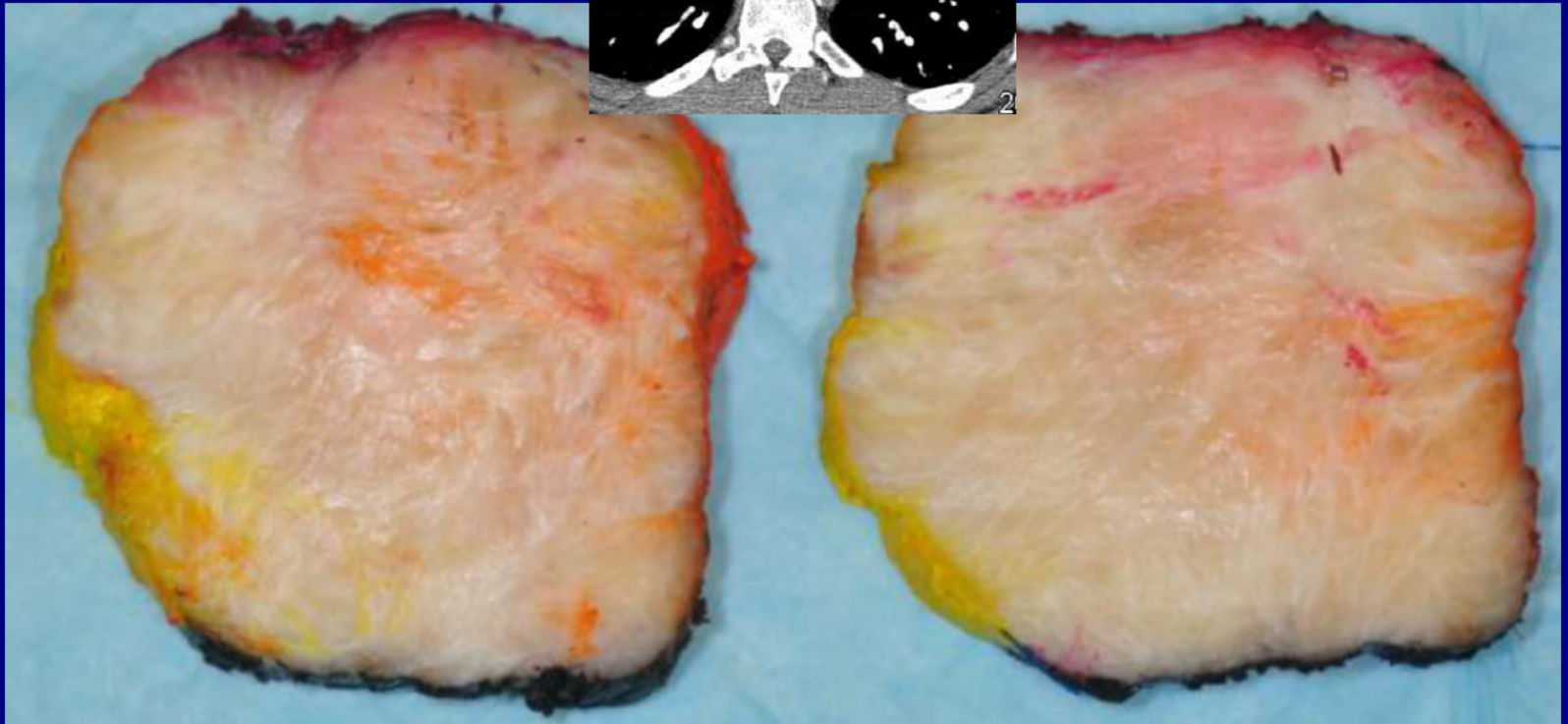
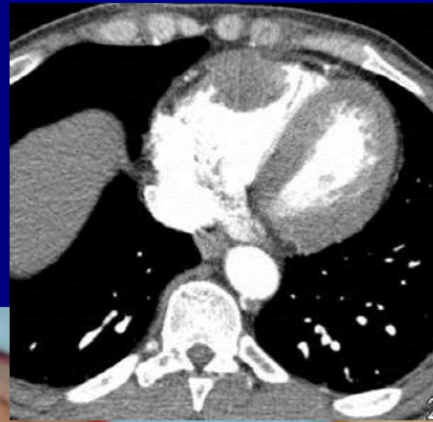


Axial MR, T2 STIR: Mass hypointense to myocardium, with thin rim of high signal

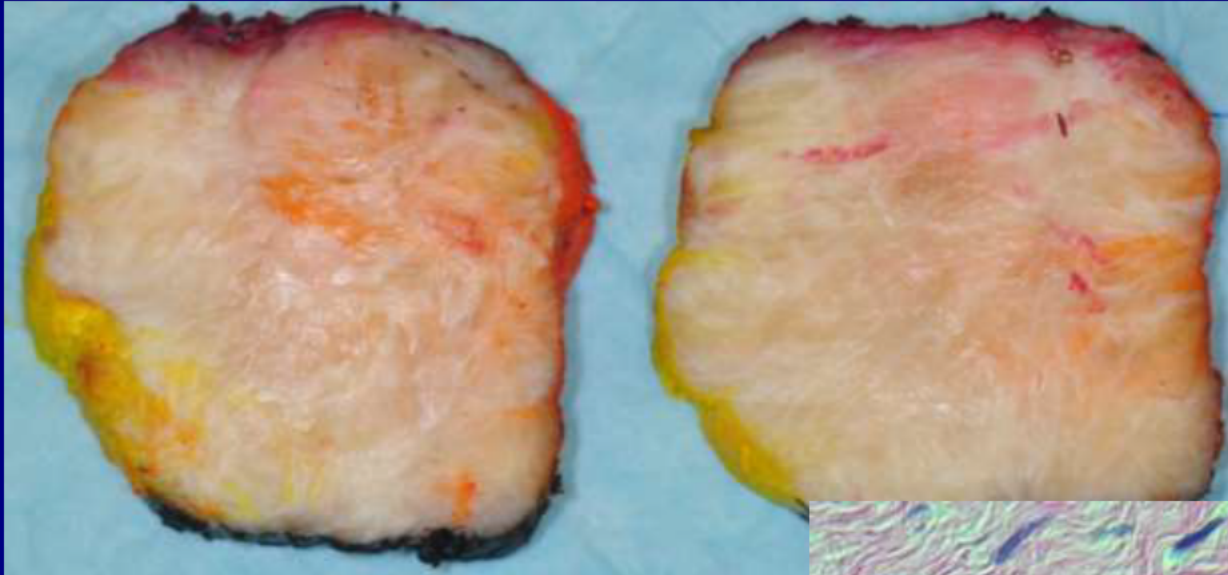


Axial MR, T1 post gadolinium: Mass shows remarkable delayed enhancement

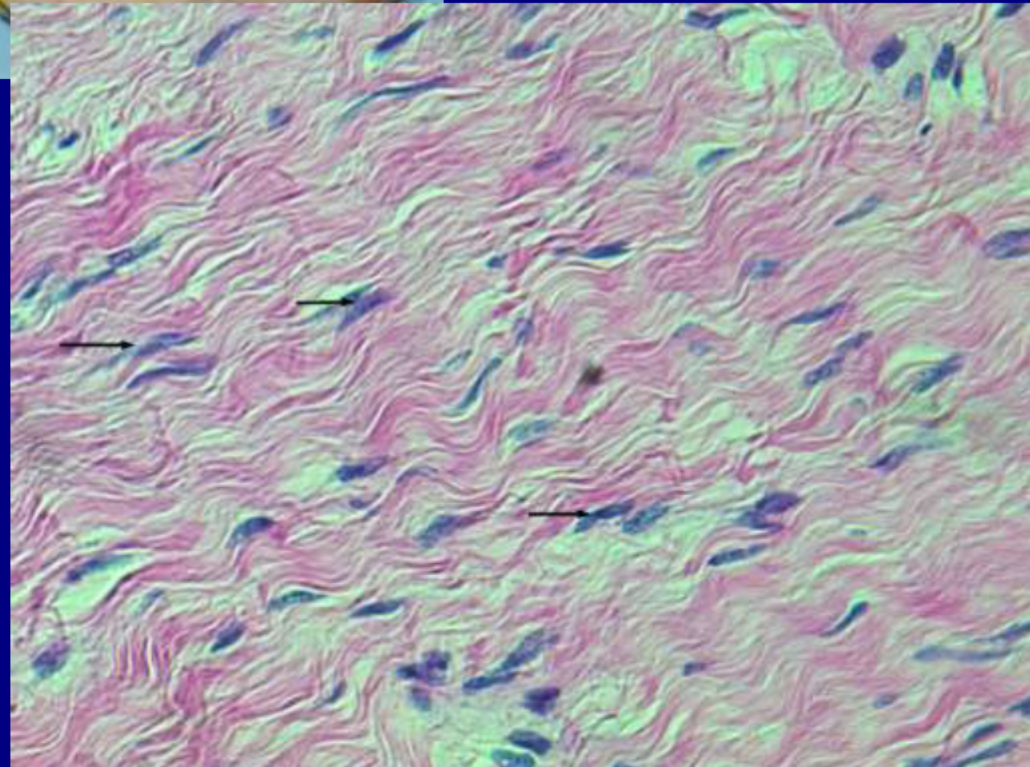




Gross resected specimen shows a well-circumscribed 4 cm lesion comprised of relatively homogeneous pale tan and white whorled soft tissue



H&E stain shows multiple layering fibroblasts comprised of pink collagen. No mitotic figures are present

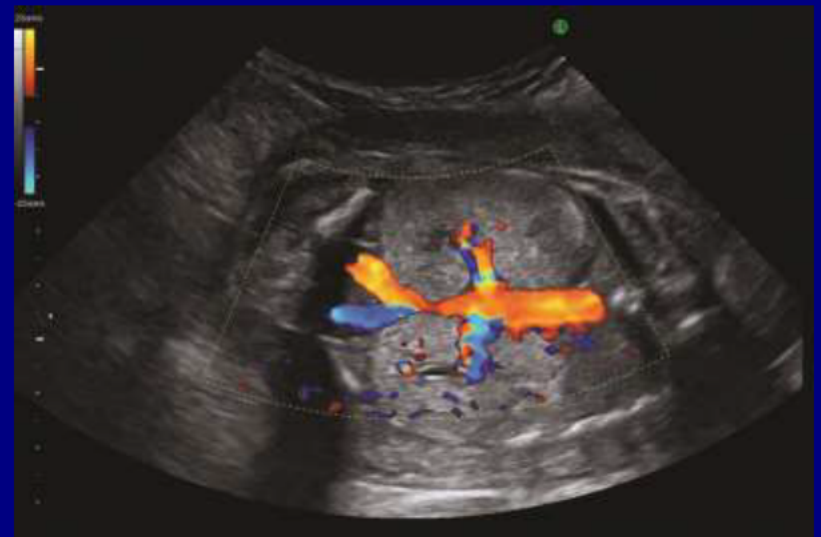
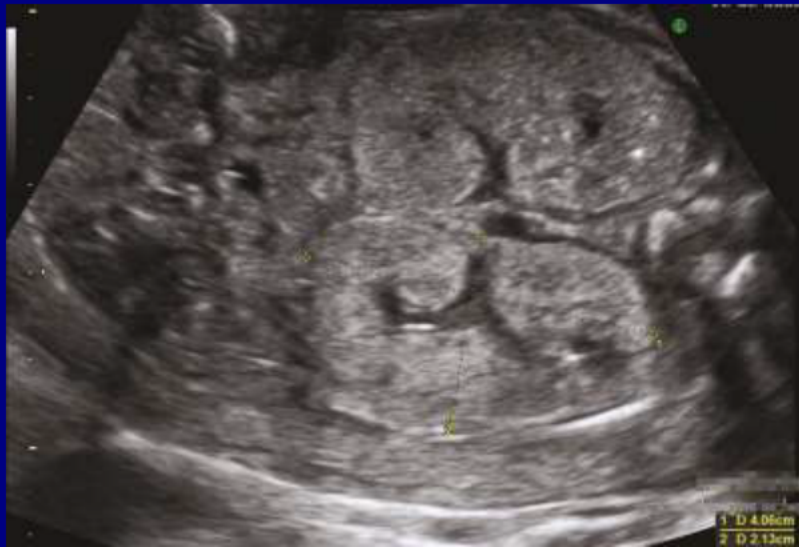
Primary Cardiac Fibroma

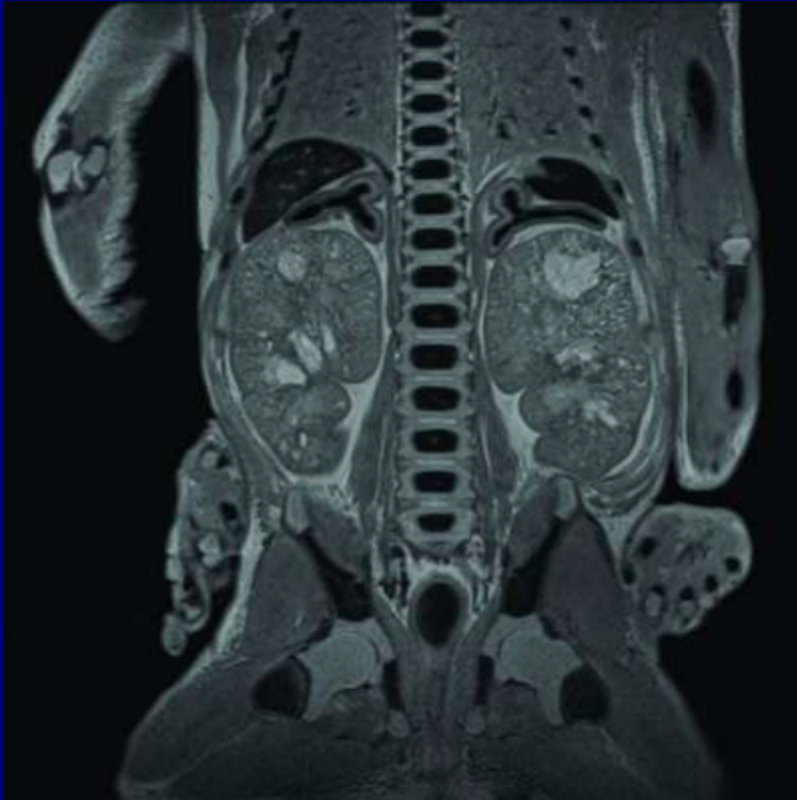
Sara Maria Fernandez, MD
University of Florida Health Science
Center
Jacksonville, Florida

Pediatric Best Case

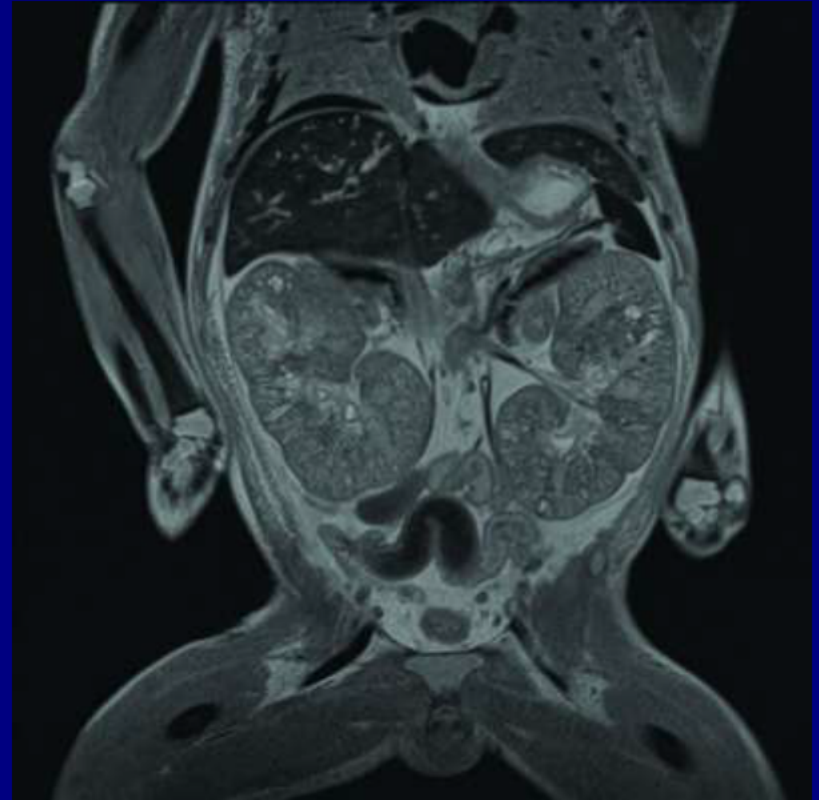
30-year-old pregnant woman for routine
prenatal ultrasound



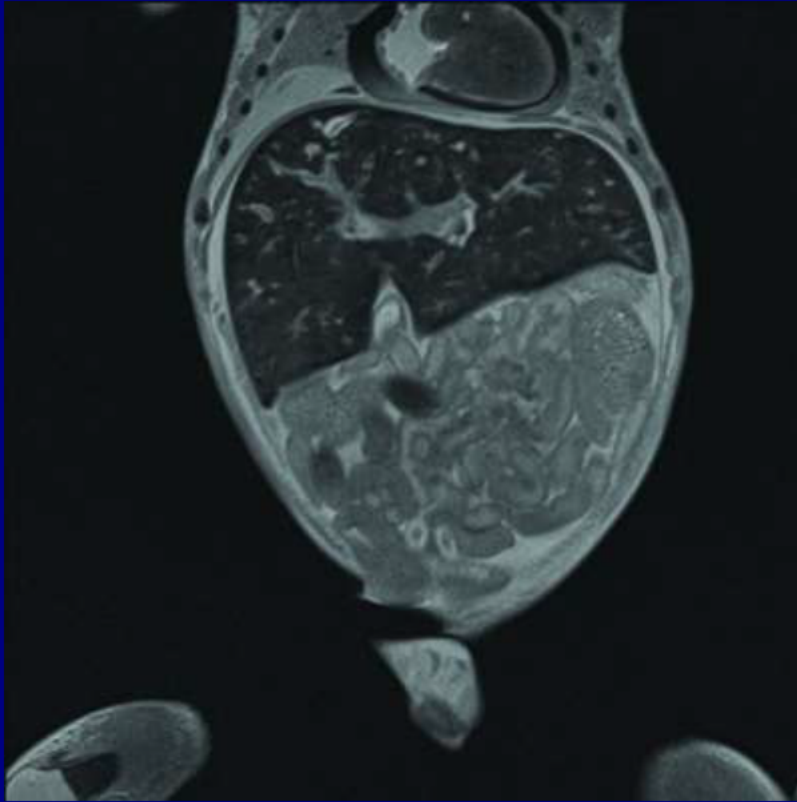
T2



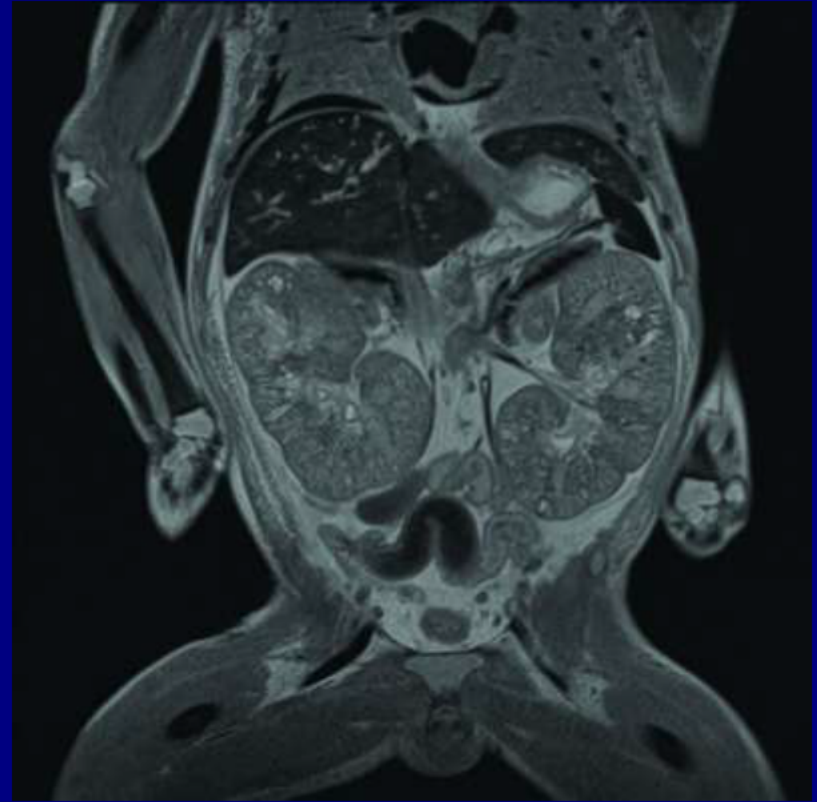
T2

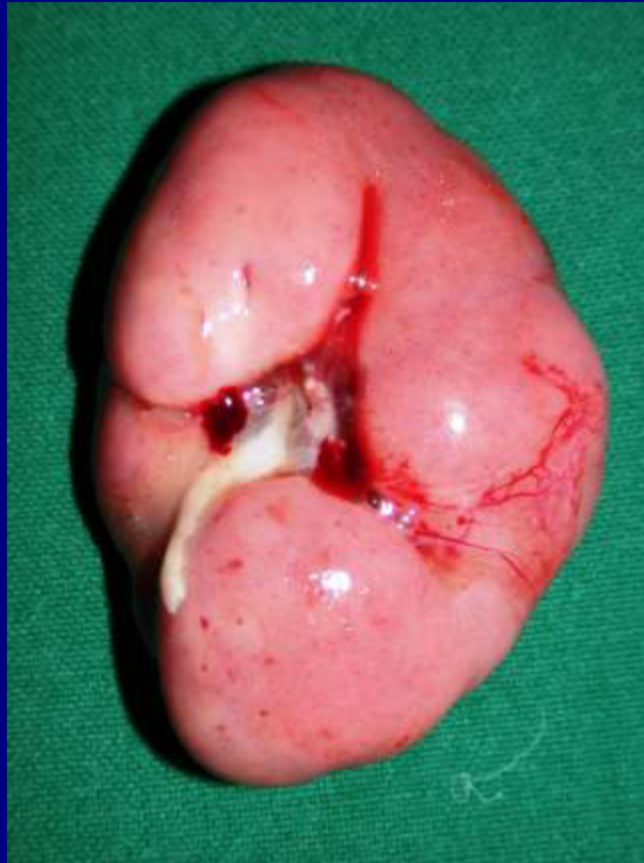


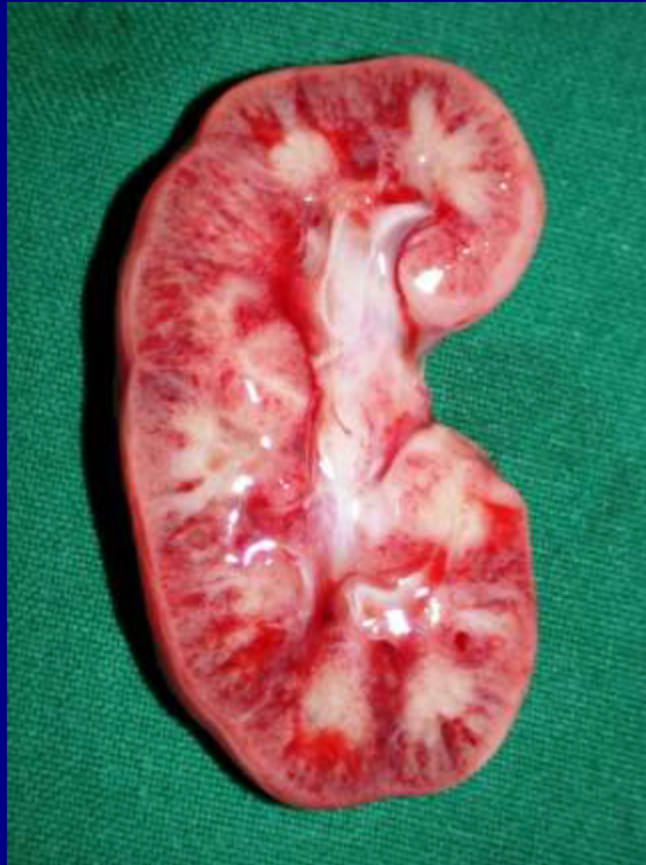T2

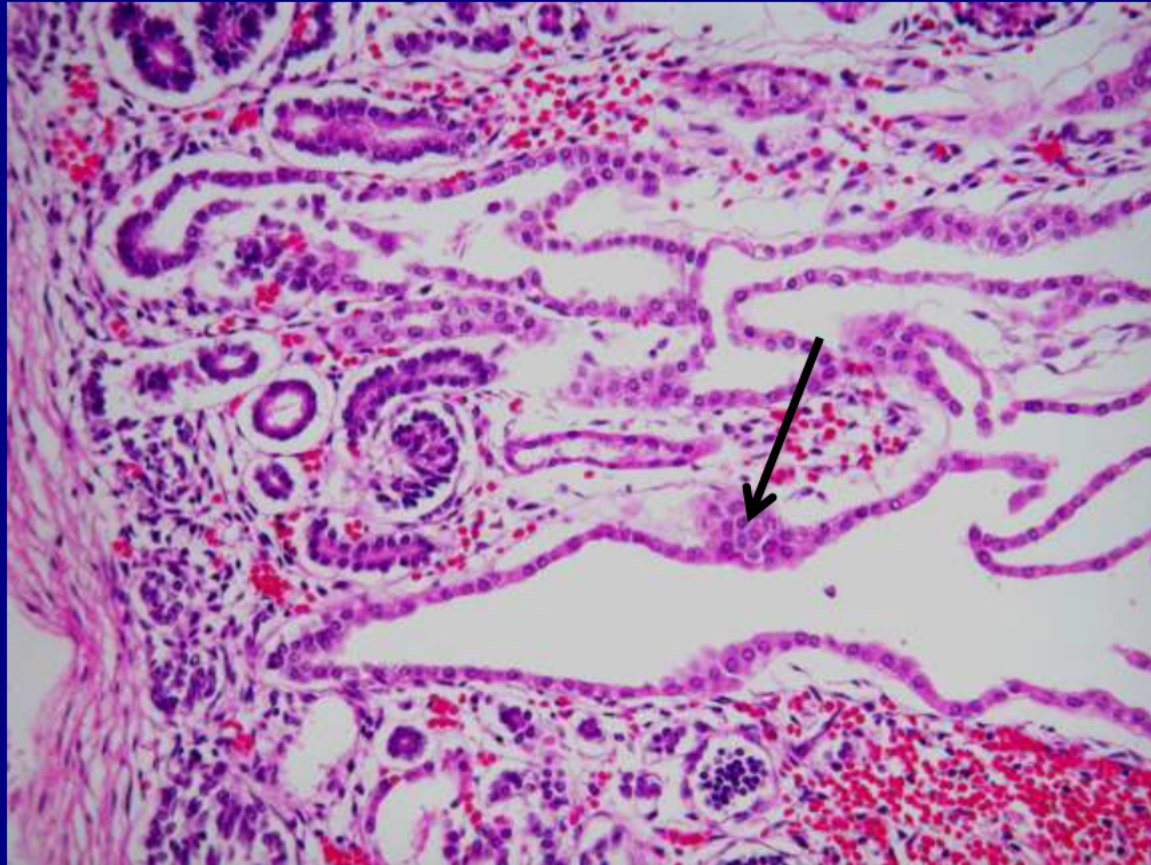


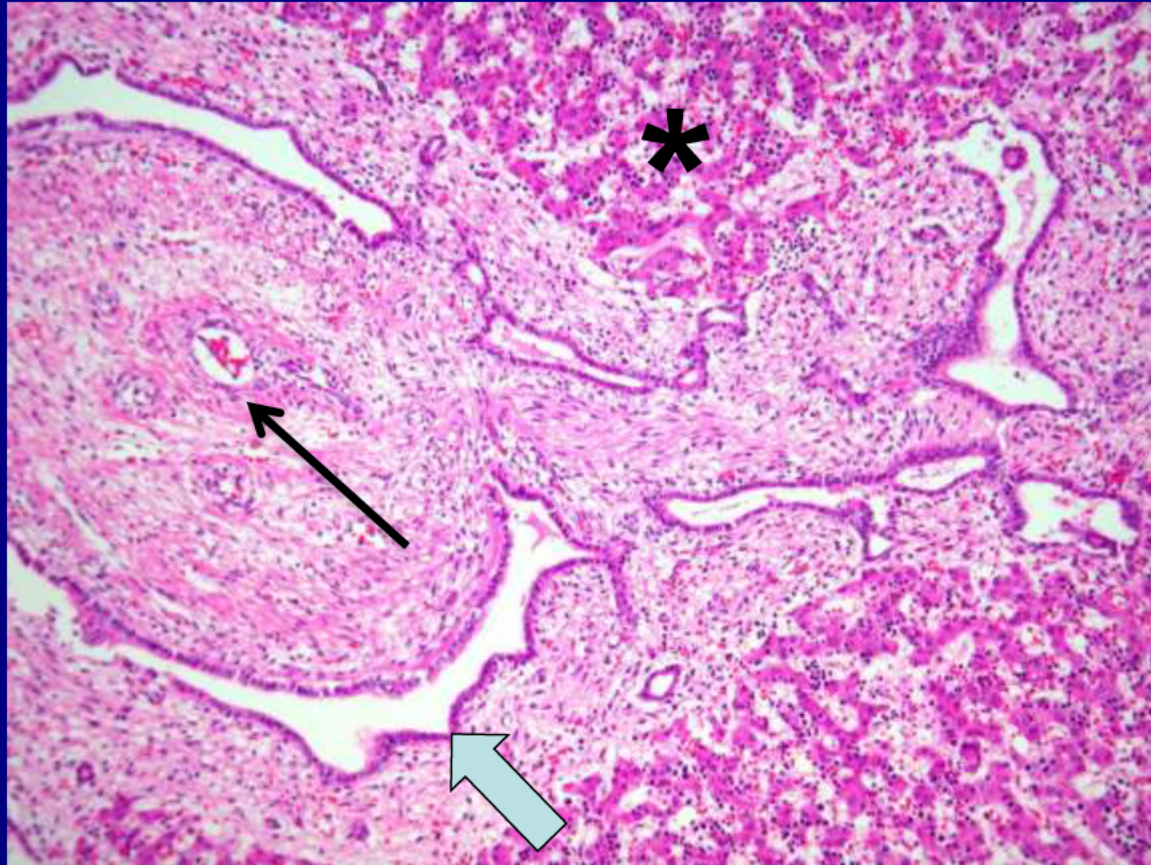
T2











Autosomal Recessive Polycystic Kidney Disease

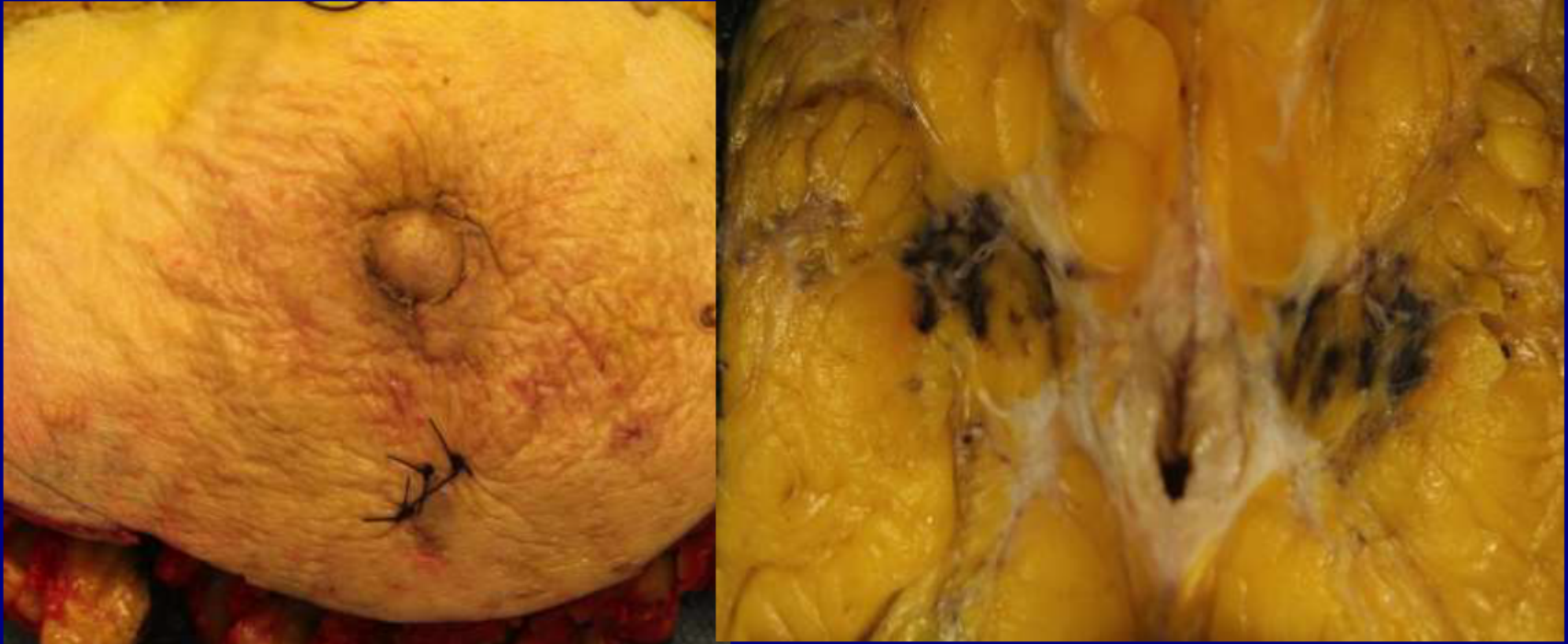Jean-Louis Samain, MD
Katholieke Universiteit Leuven
Leuven, Belgium

Breast Best Case

73-year-old woman with history of previous right breast infiltrating ductal carcinoma located at the 9-10 o'clock position, treated with lumpectomy, axillary node dissection and adjuvant radiotherapy in 2004 at age 64

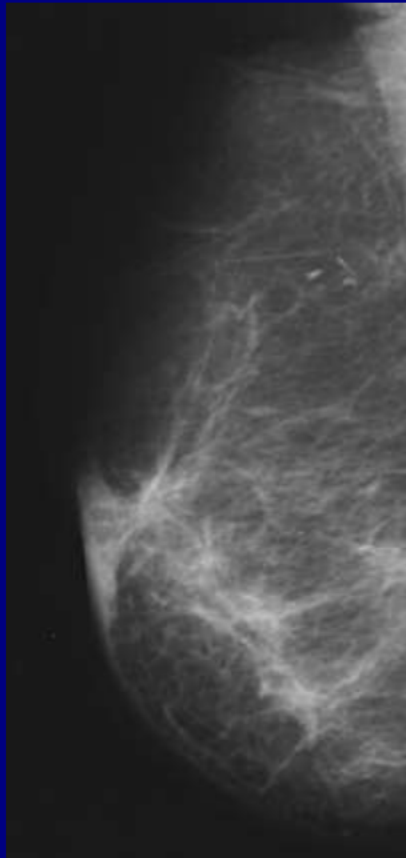
Eight years later in 2012 at age 73 the patient noticed new right breast purple and violaceous discoloration with eventual tenderness and pruritus

Skin Discoloration

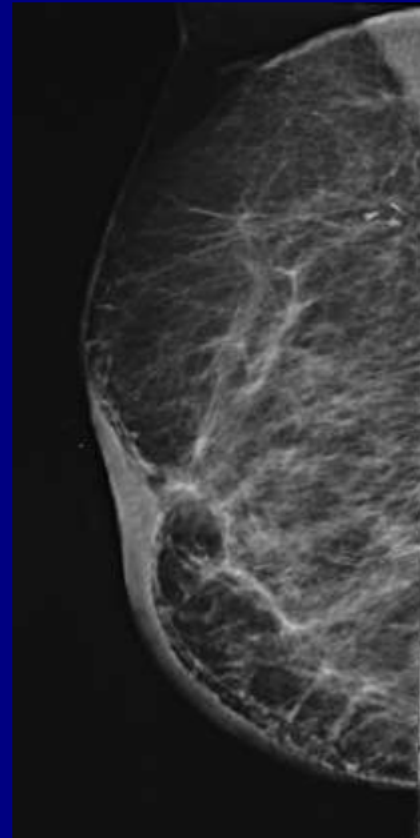


RT Mammogram MLO View

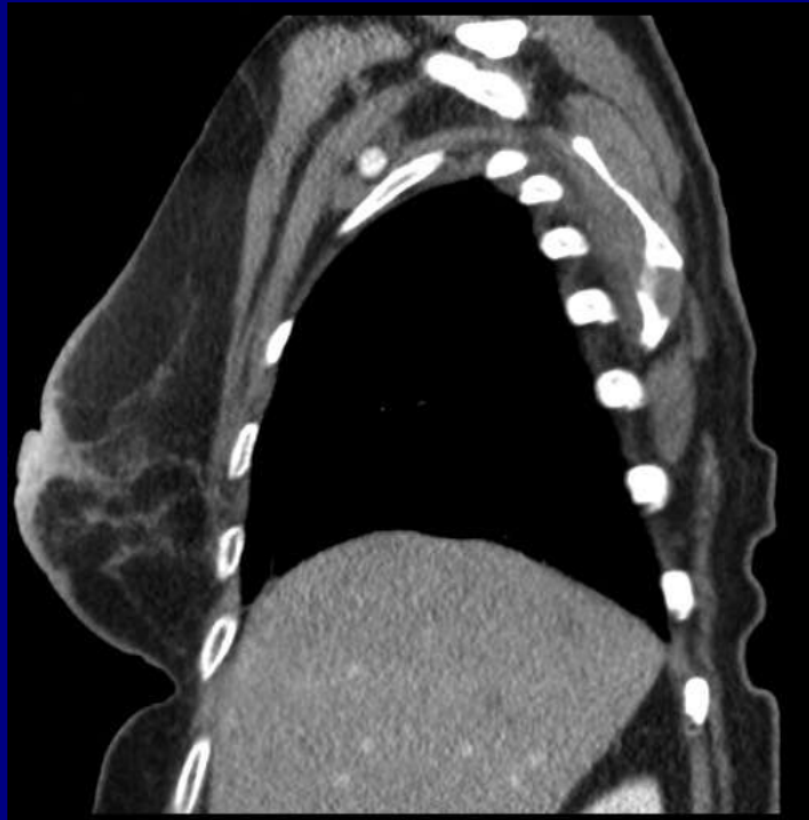
- Dec 23, 2011



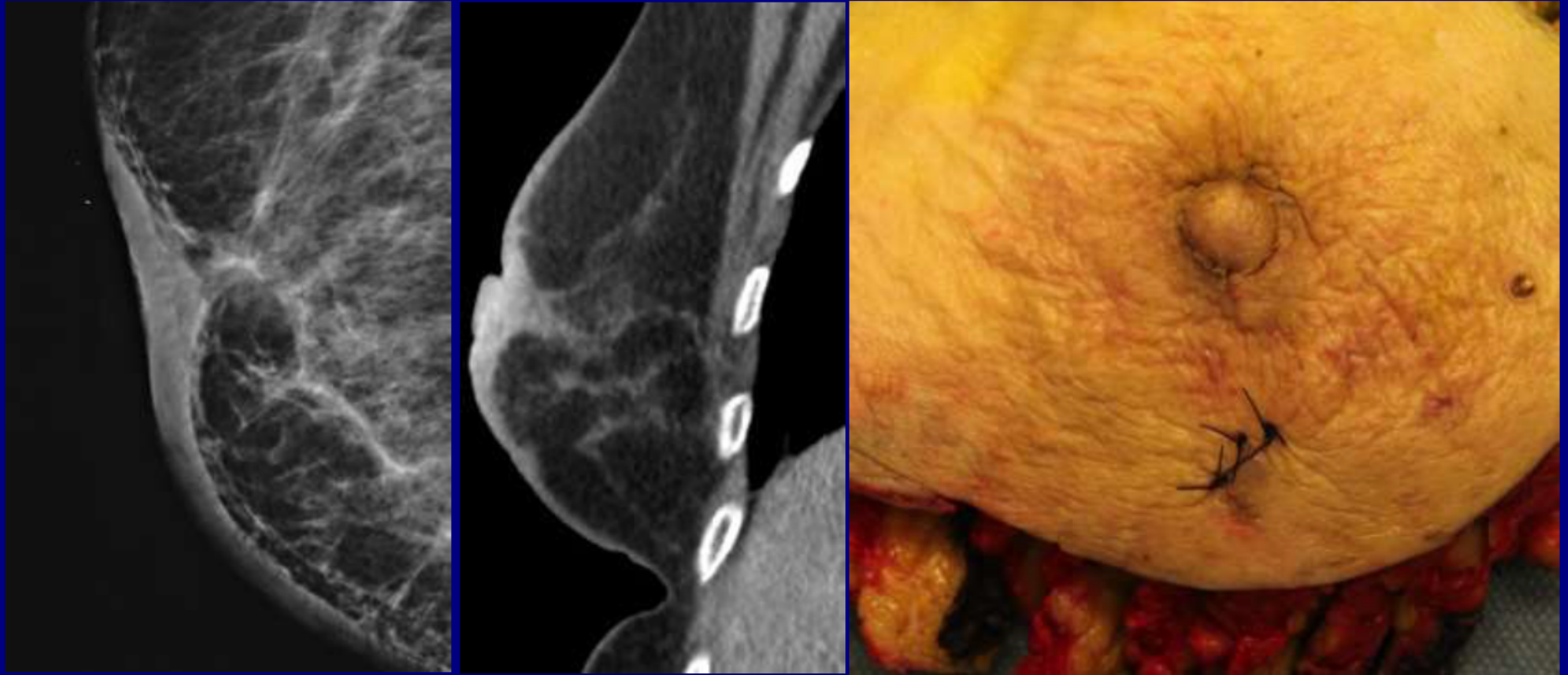
- Nov 9, 2012



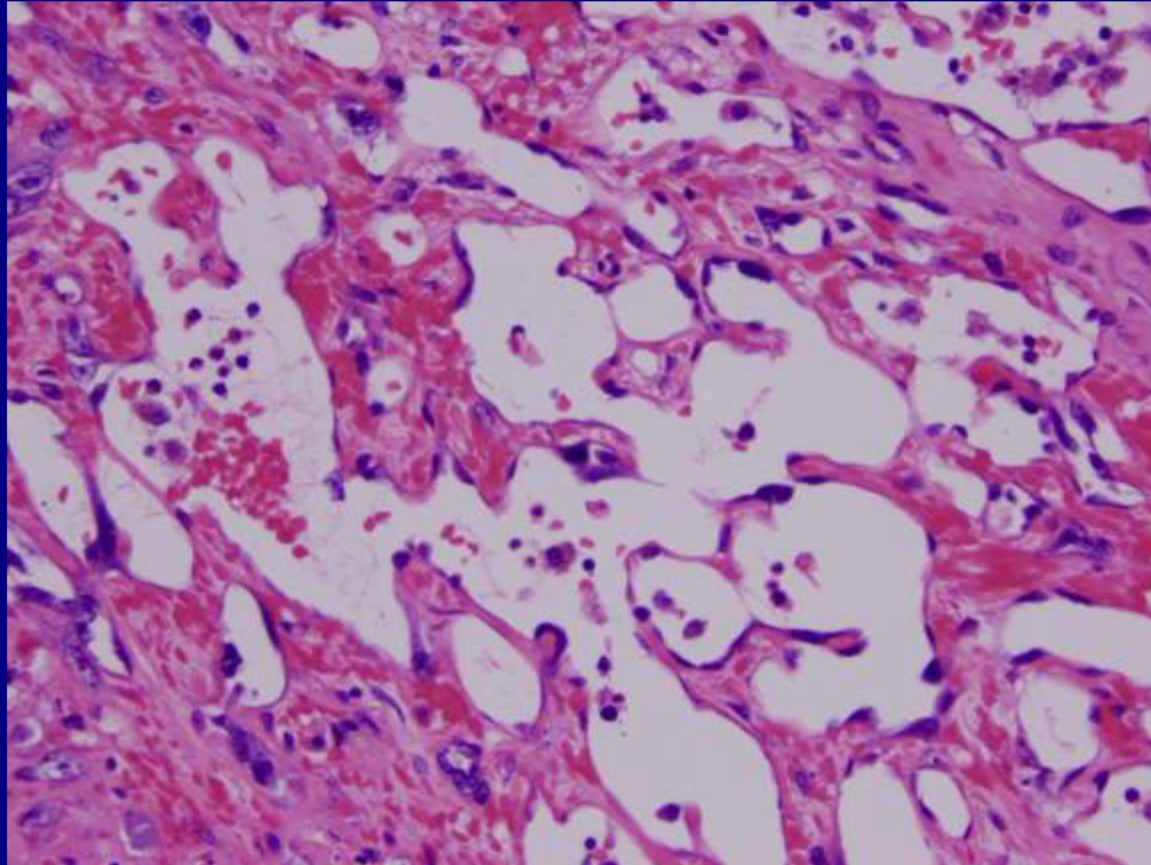
CT



Correlation



Histology



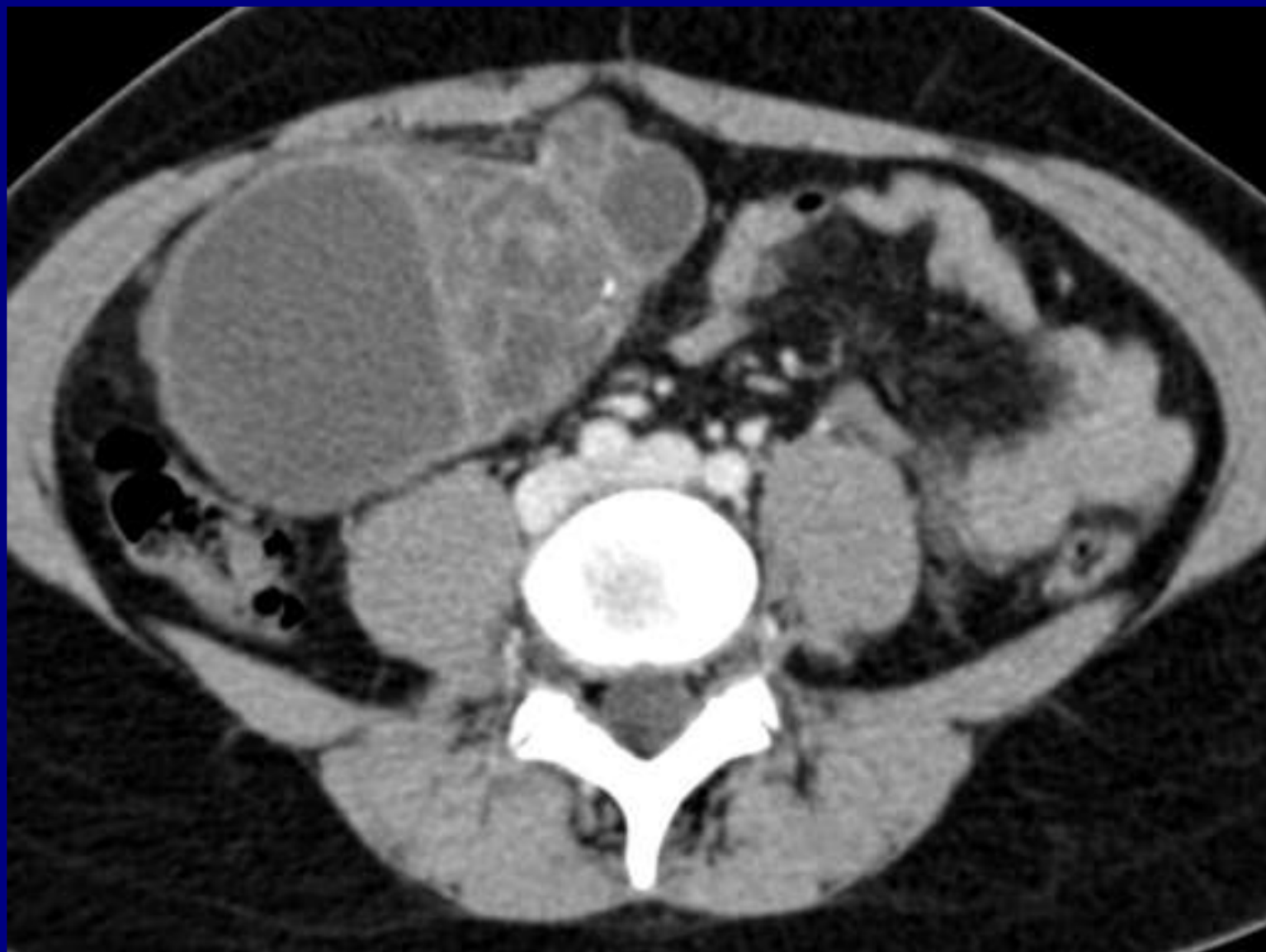Angiosarcoma of the Breast After Radiation

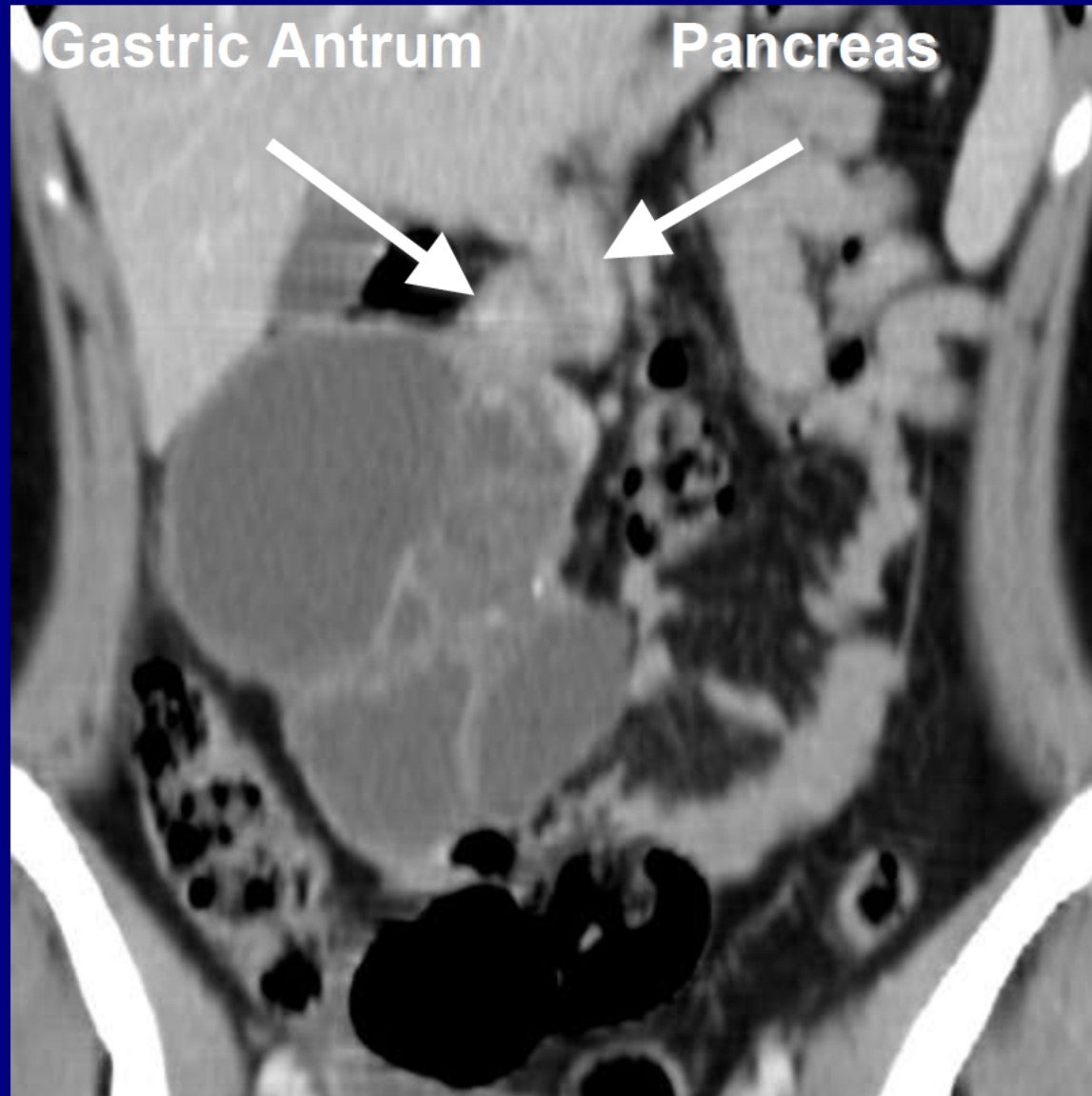
Sasha Bhan, MD

McMaster University Medical Center
Hamilton, Ontario, Canada

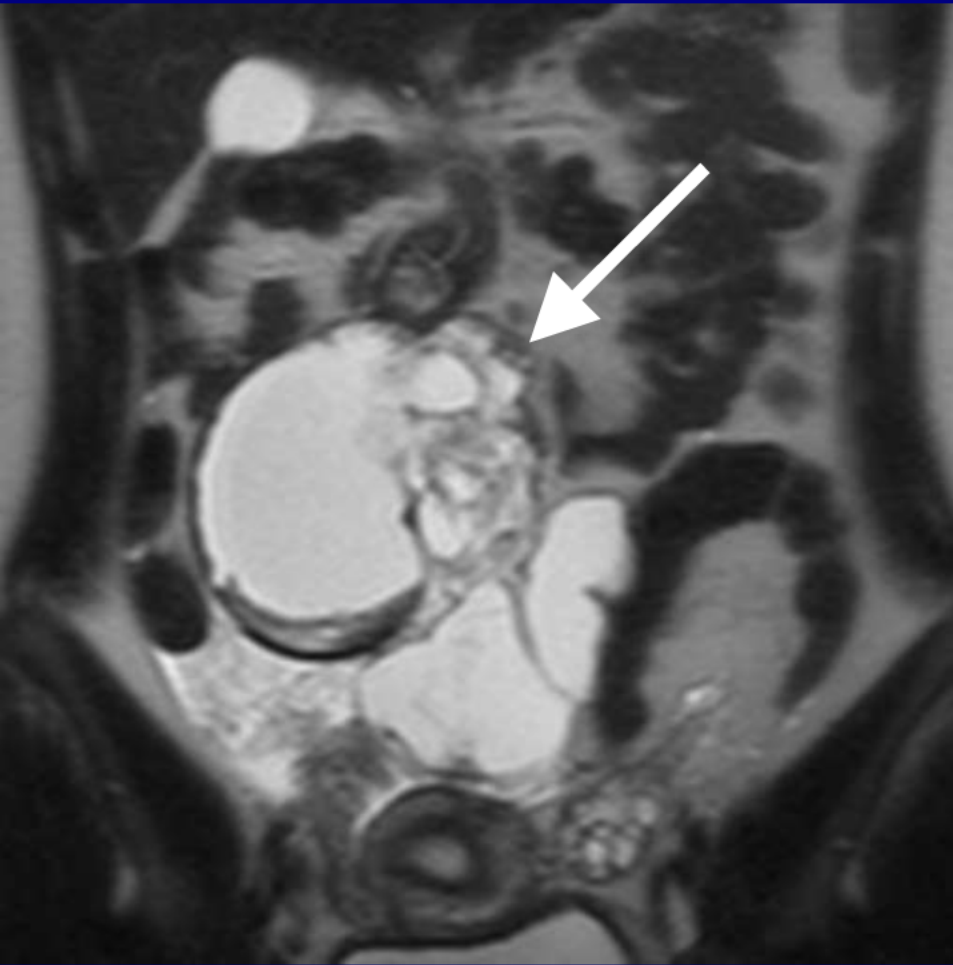
Gastrointestinal Best Case

19-year-old woman with a 5-month history of diffuse abdominal pain

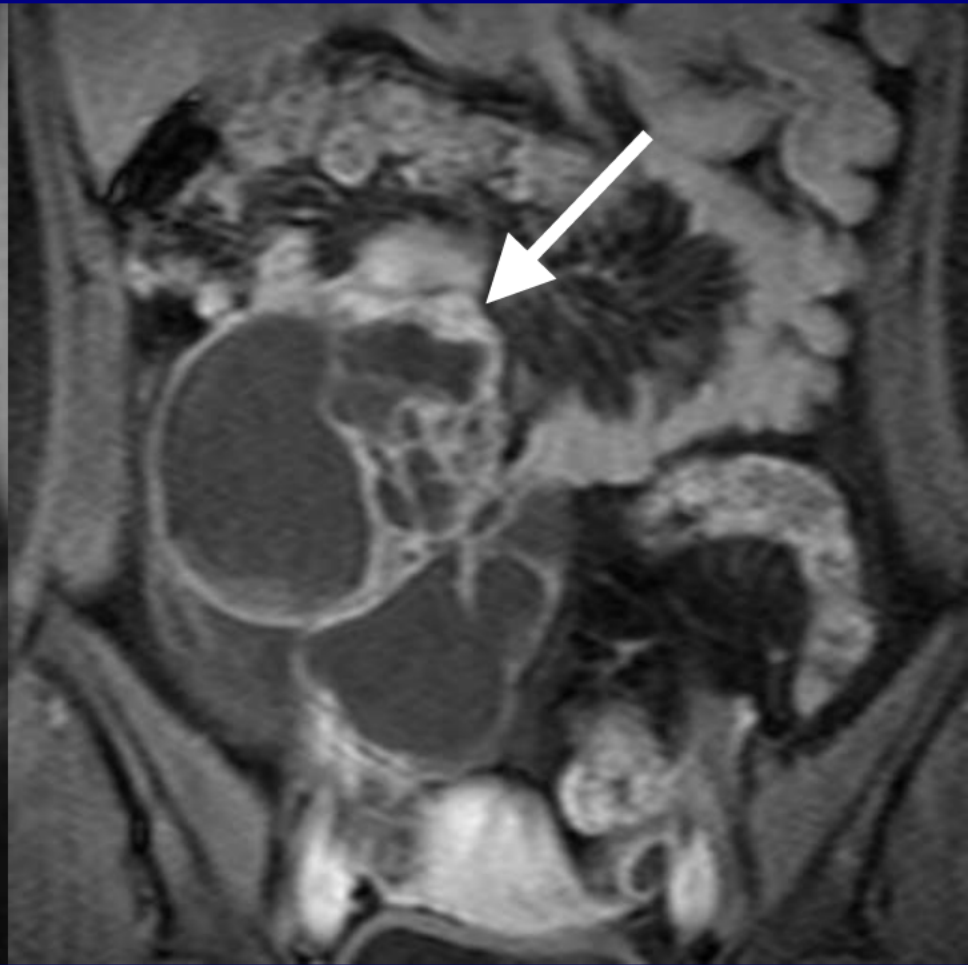

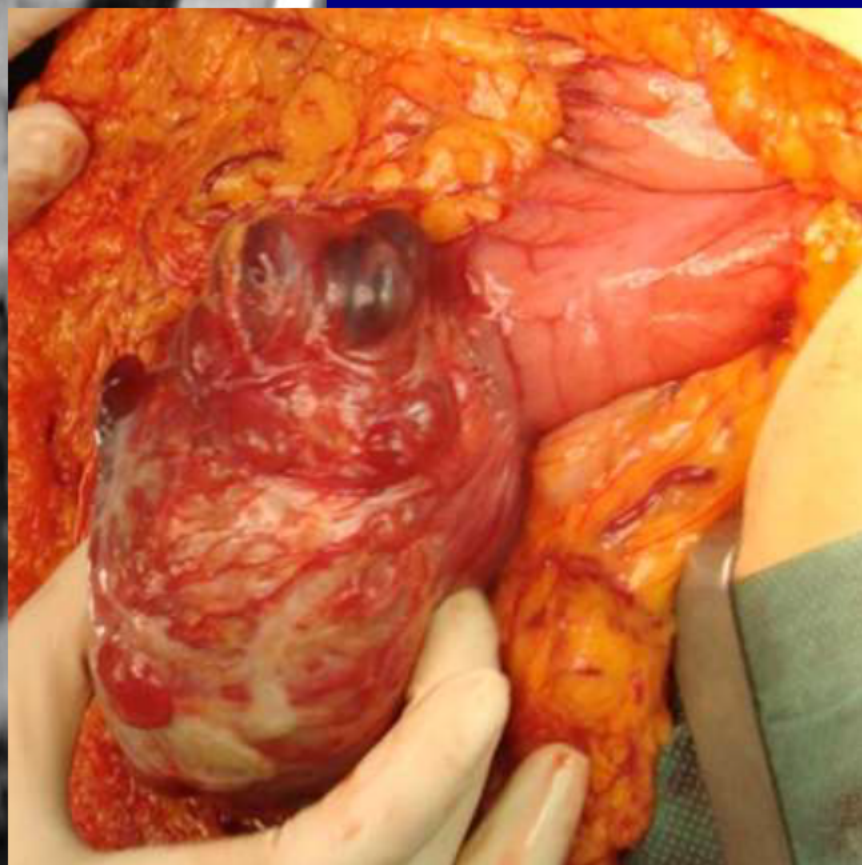
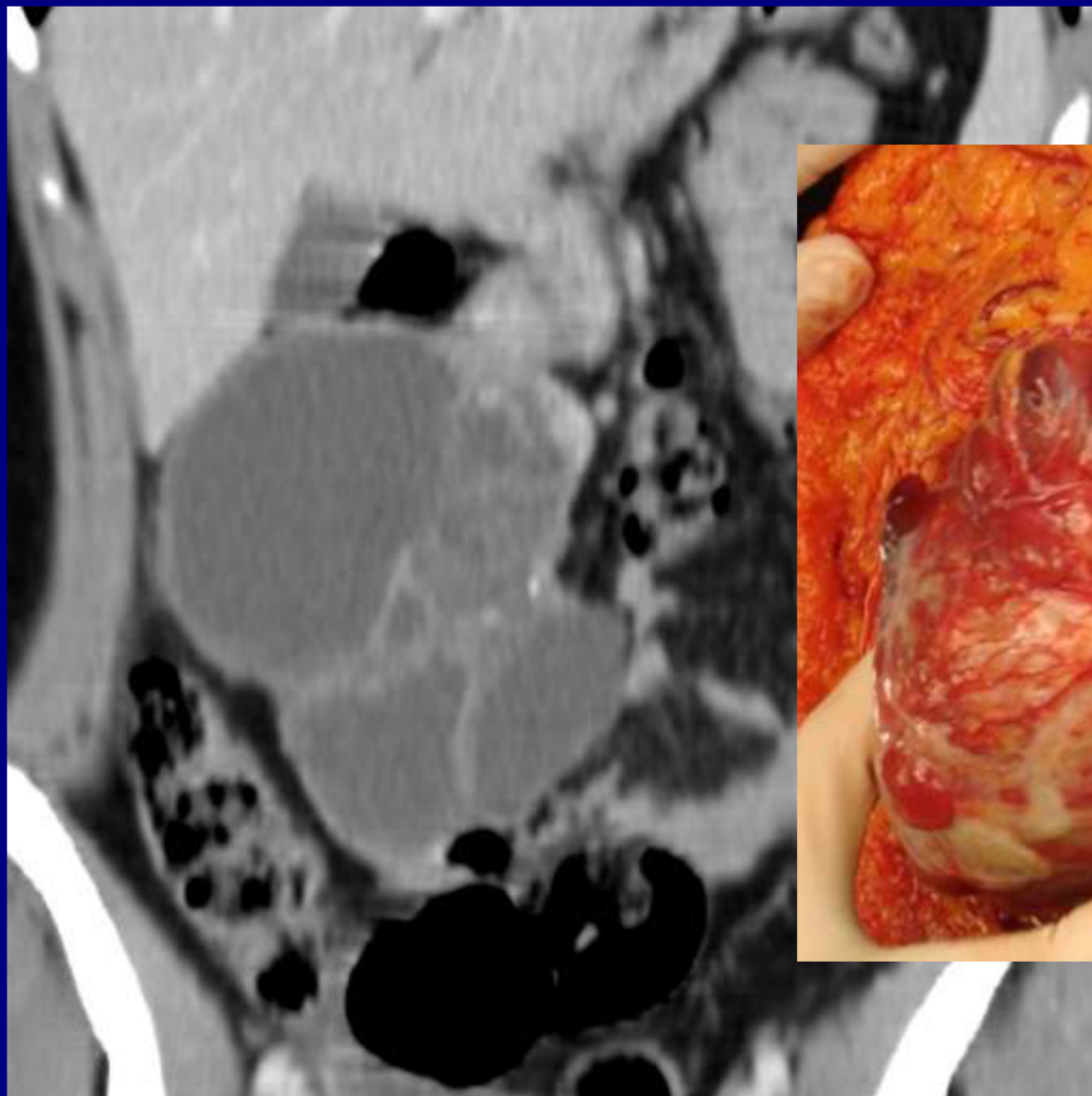


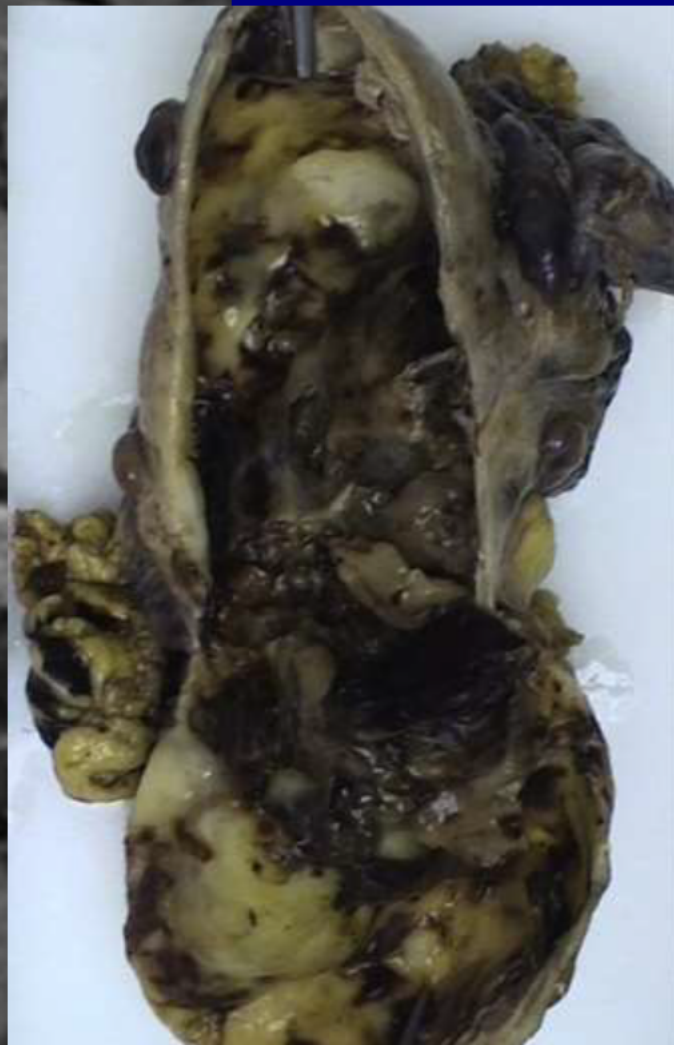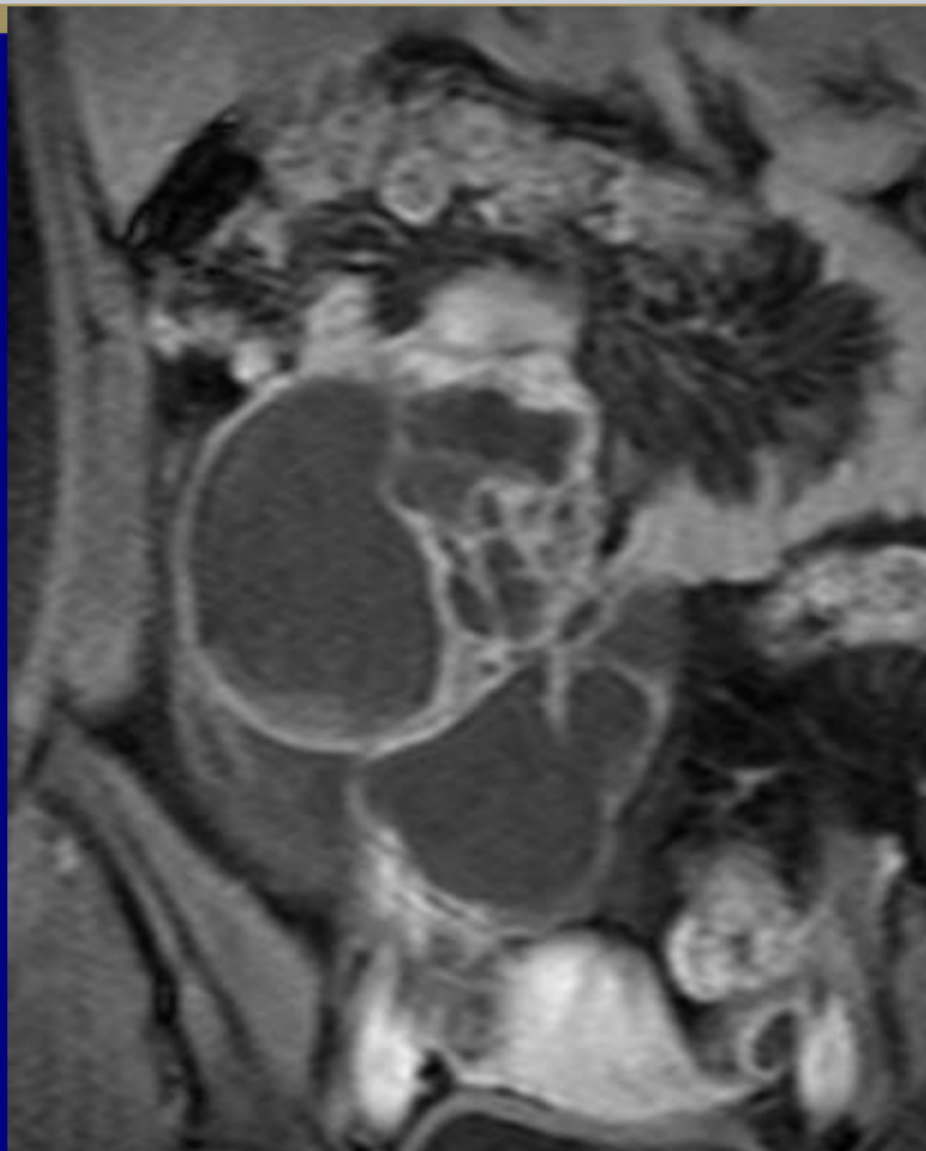
T2W



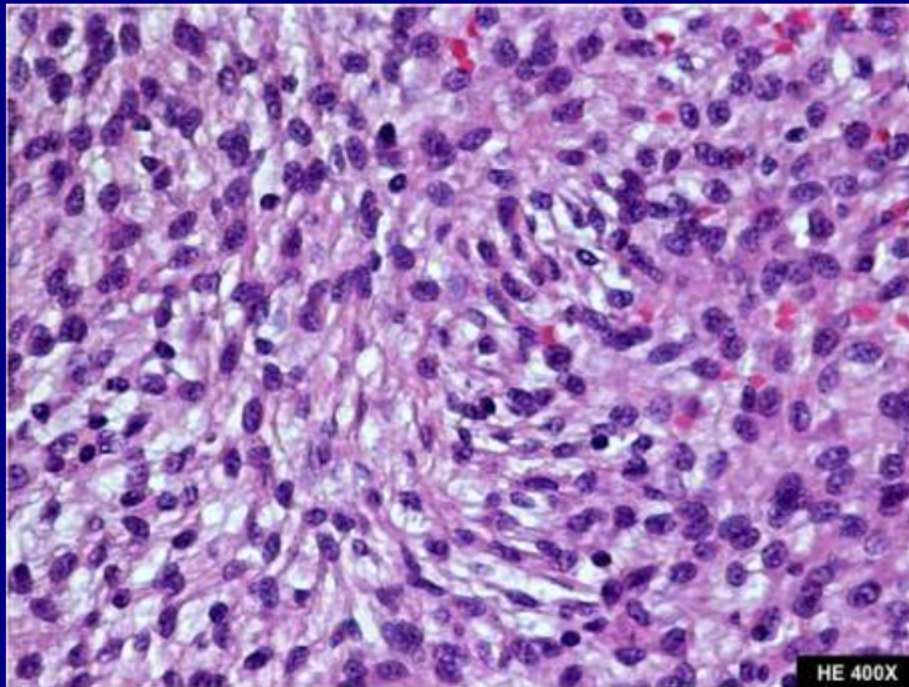
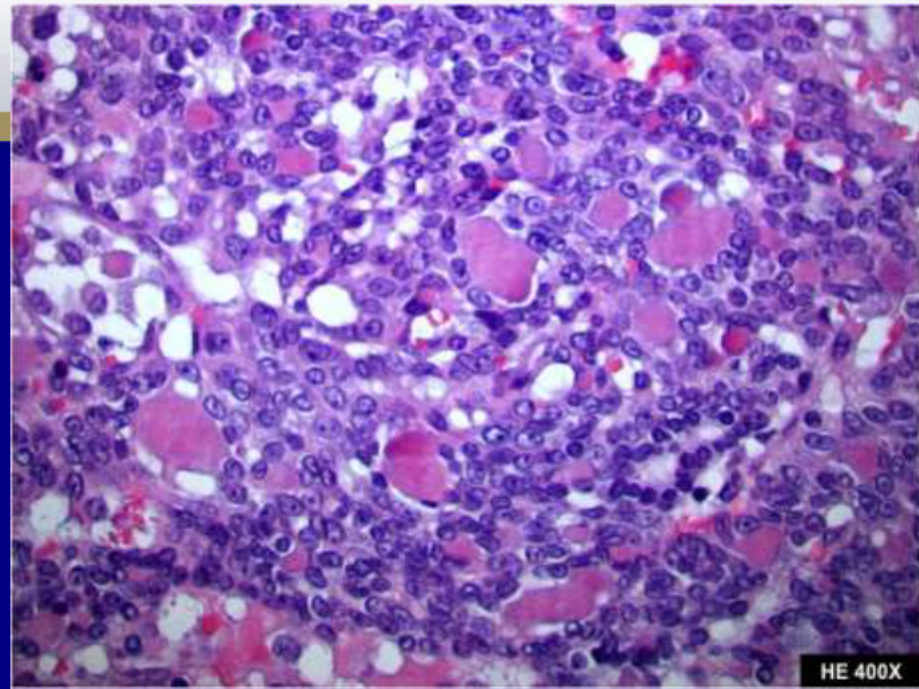
T1W Post







Epithelial
component



Mesenchymal
component

Gastroblastoma (Epitheliomesenchymal Biphasic Tumor of the Stomach)

Teresa Fernandes, MD
Centro Hospitalar de São João
Porto, Portugal

Many thanks to all of you for submitting
such great cases!
Have a safe trip home –

From the staff of the
American Institute for Radiologic Pathology