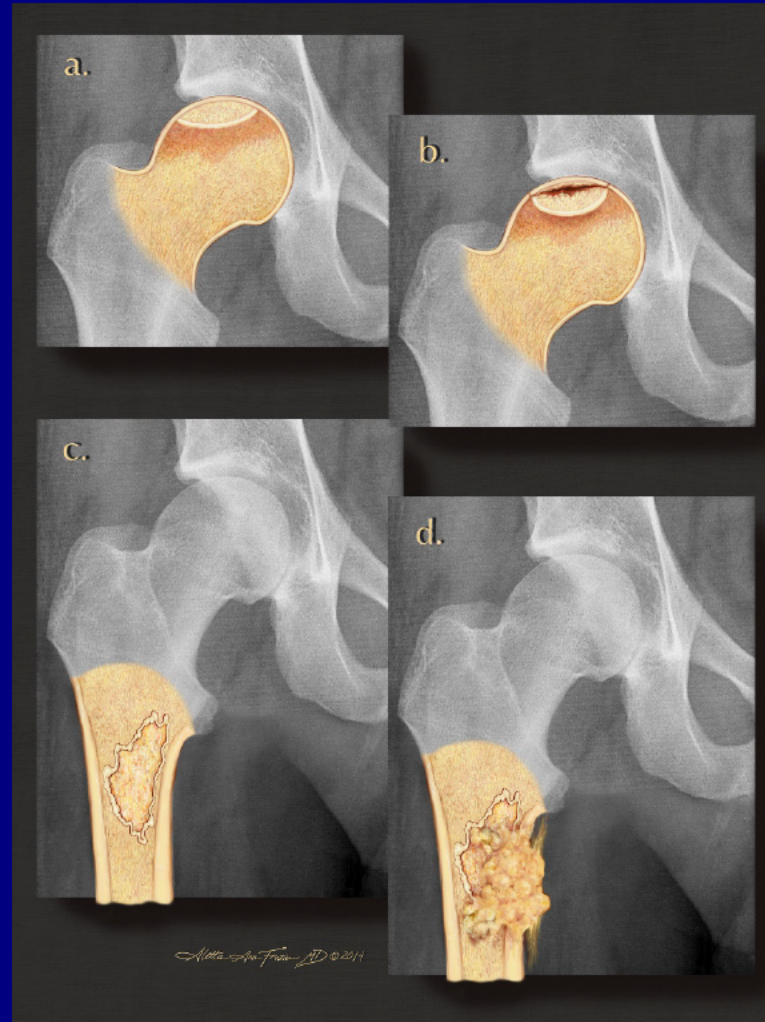


# Best Cases of the AIRP

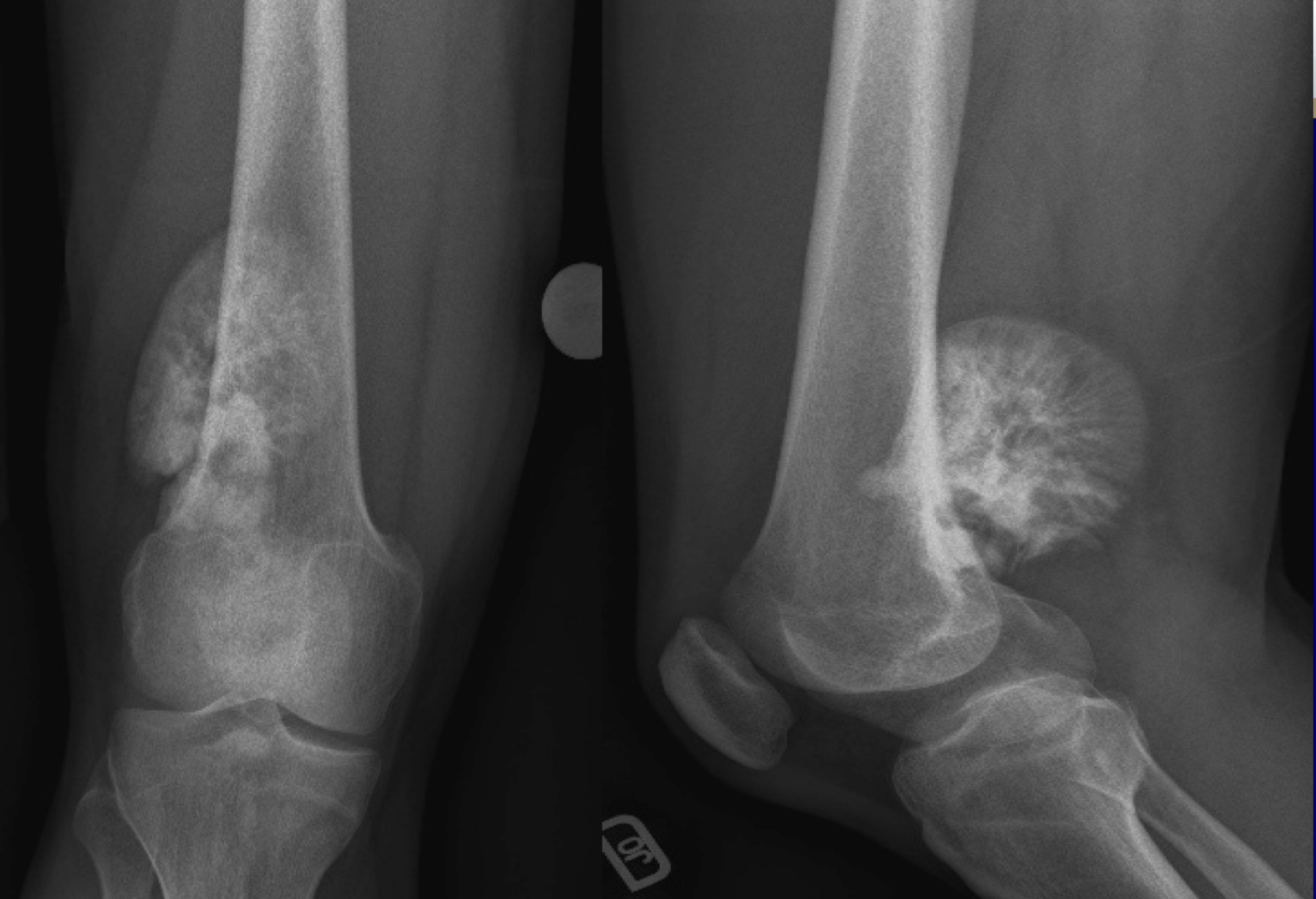
**July-August, 2015**

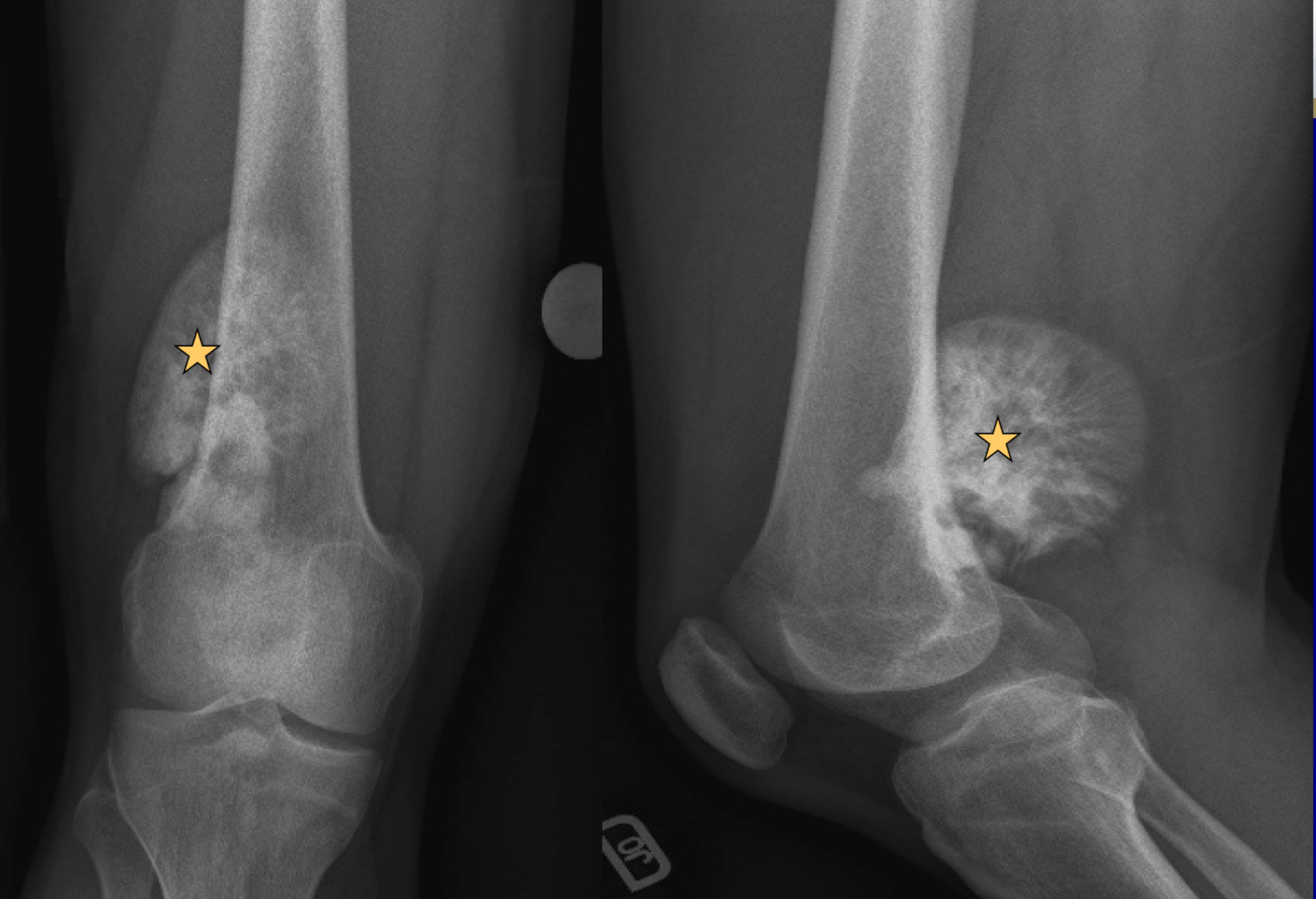


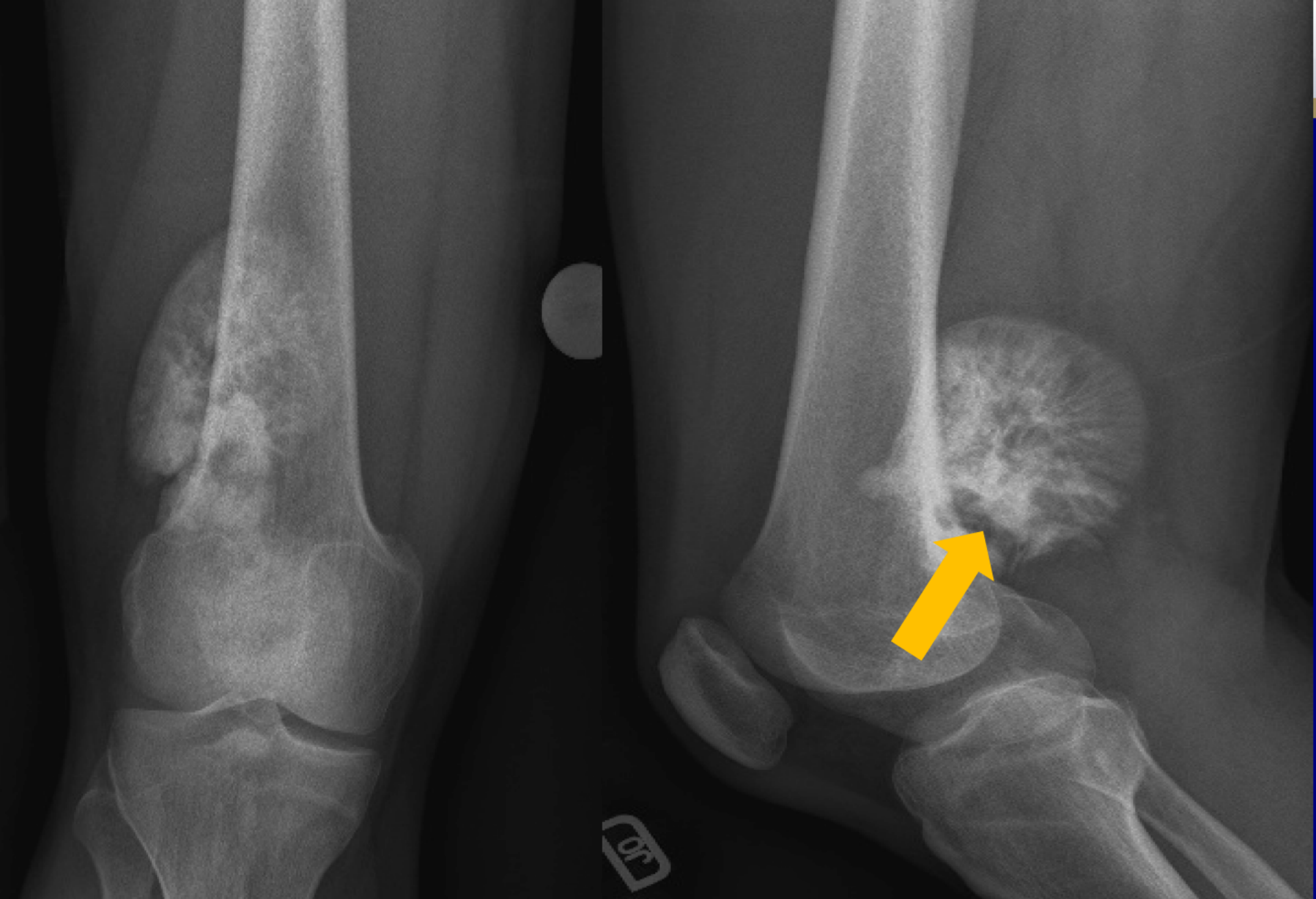
# Musculoskeletal Best Case



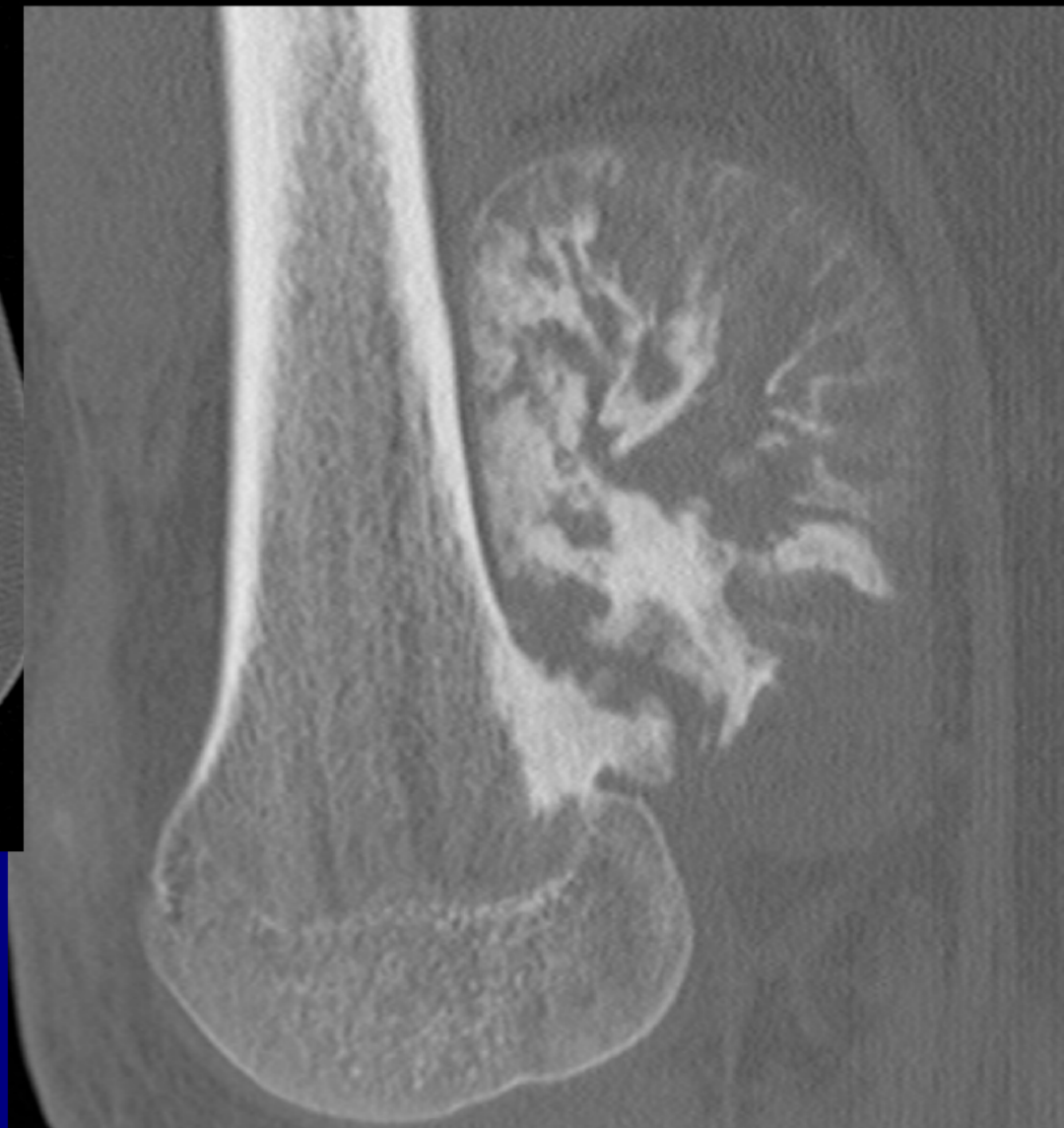
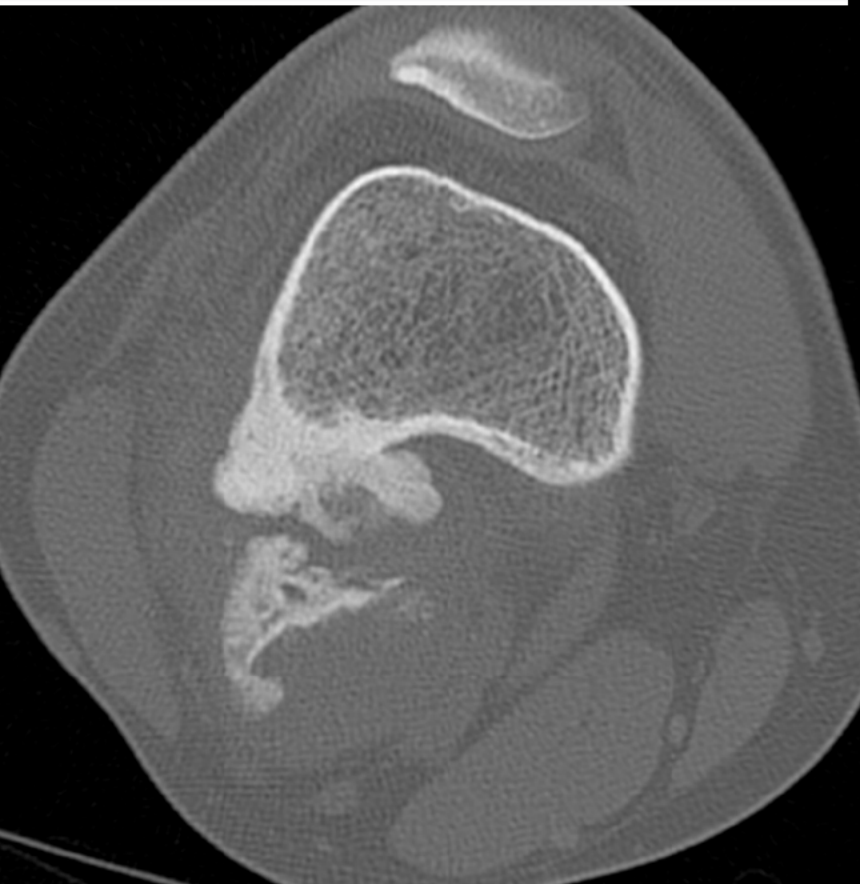**27 year old male with one-year history of  
slowly enlarging right popliteal mass**

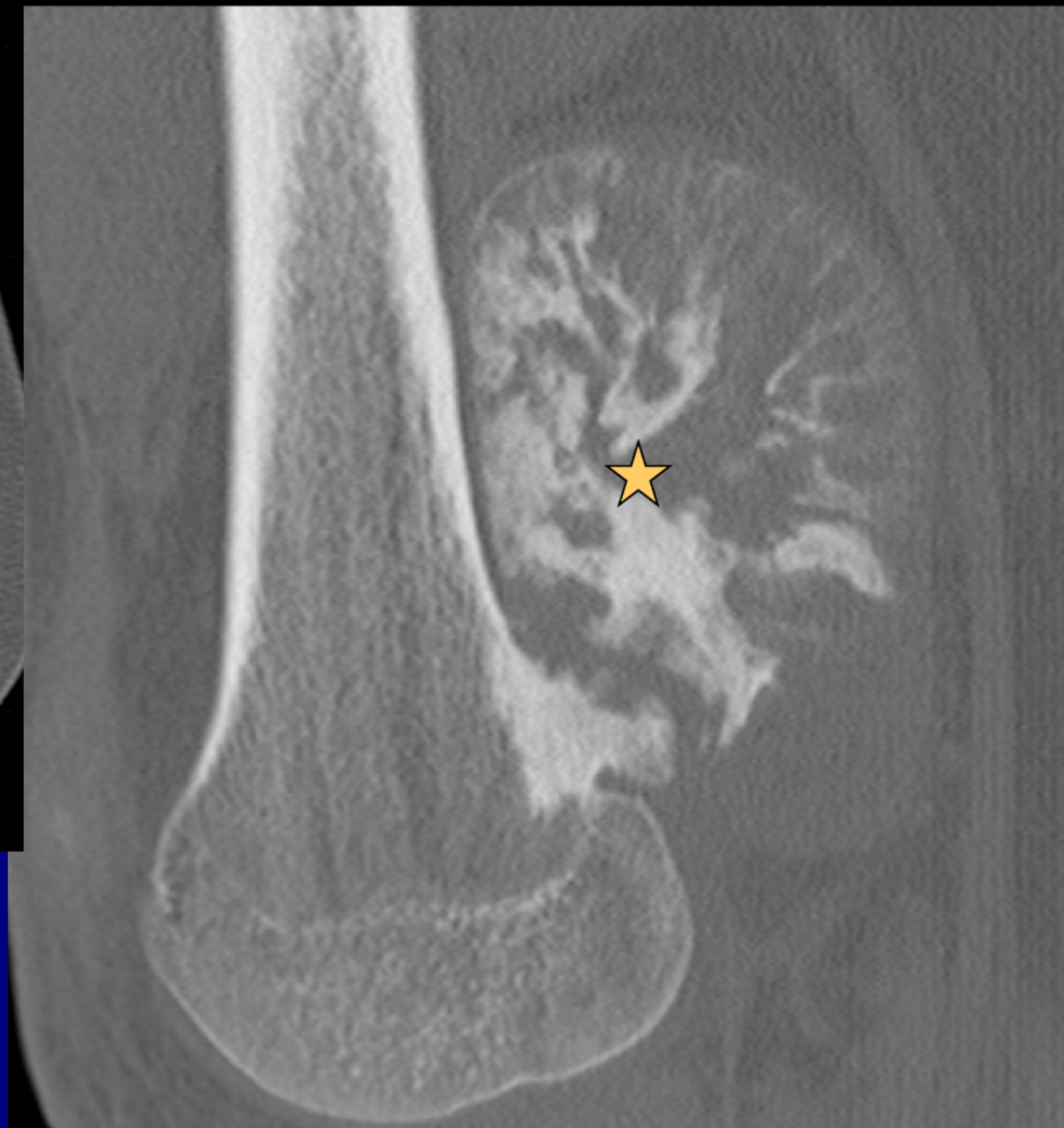
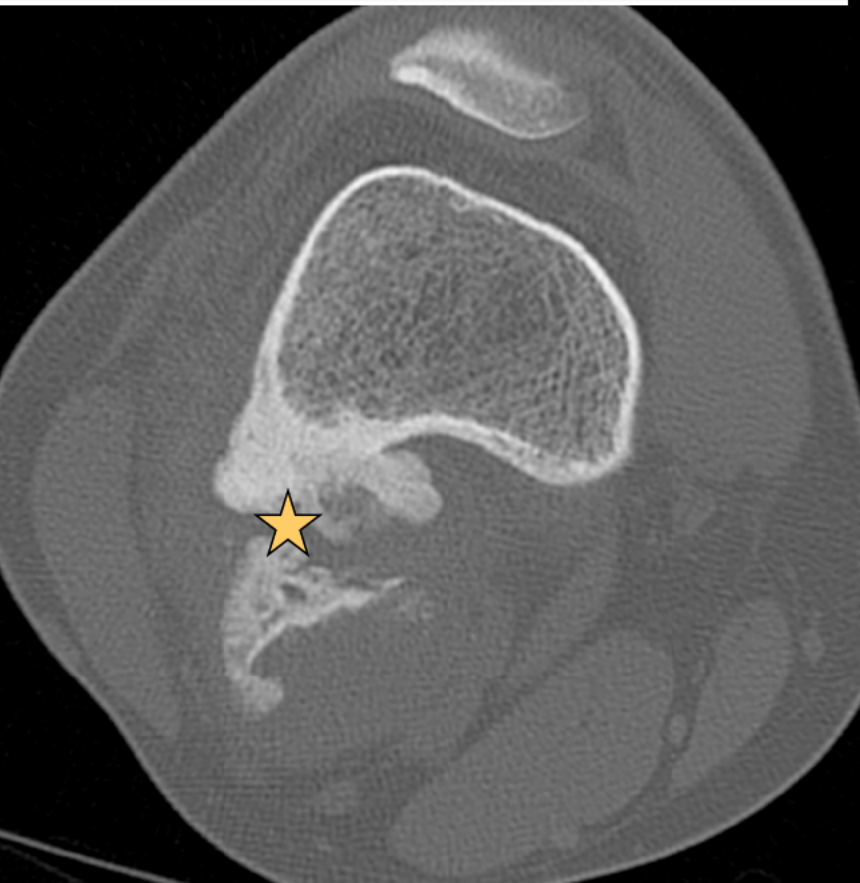

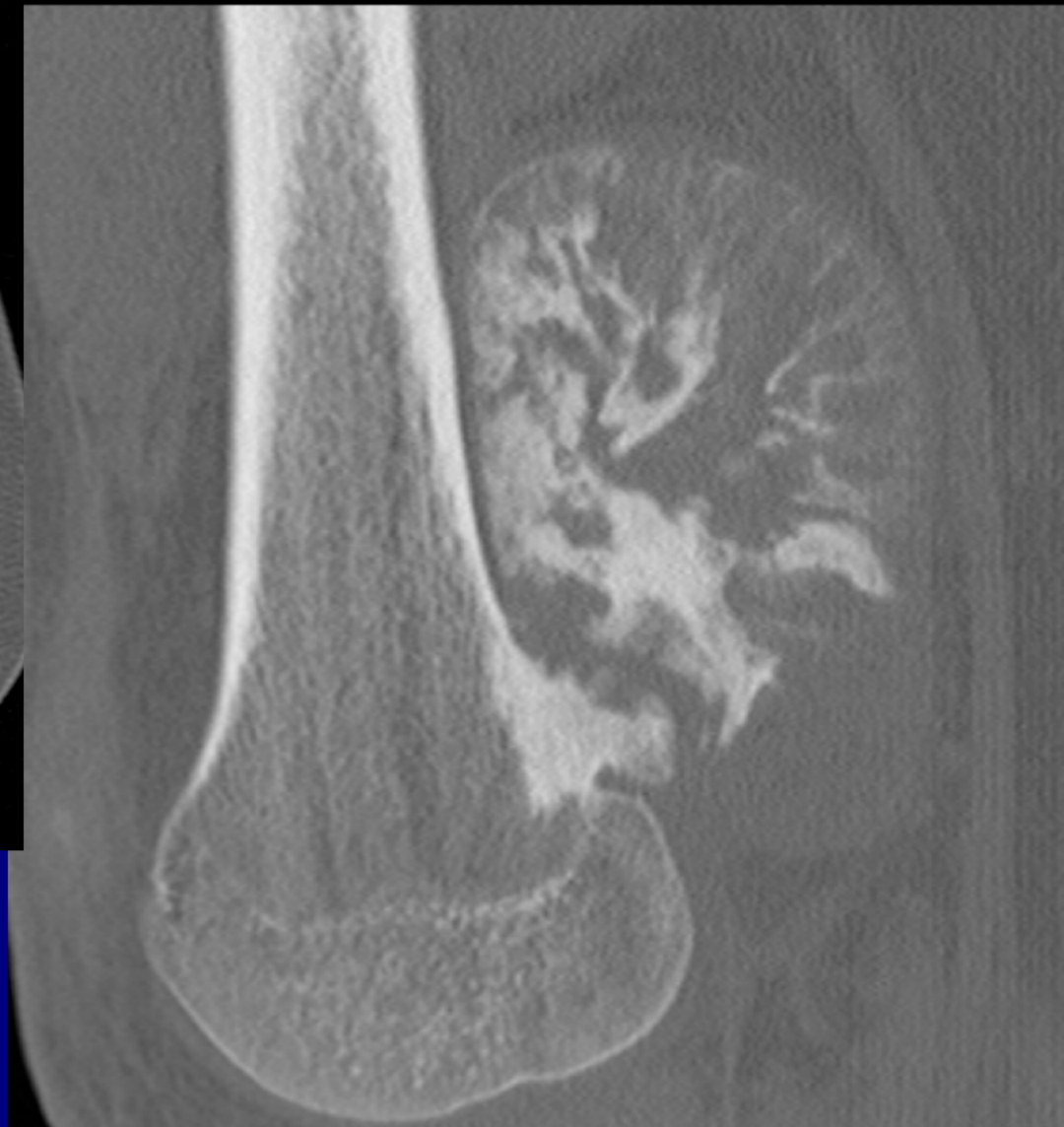

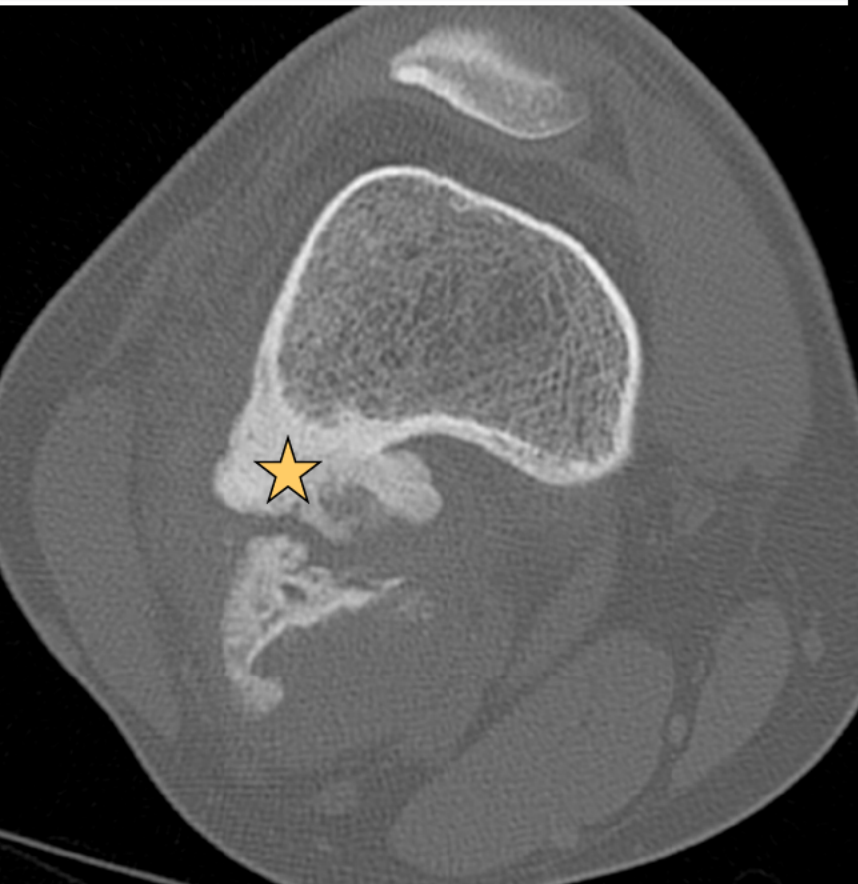


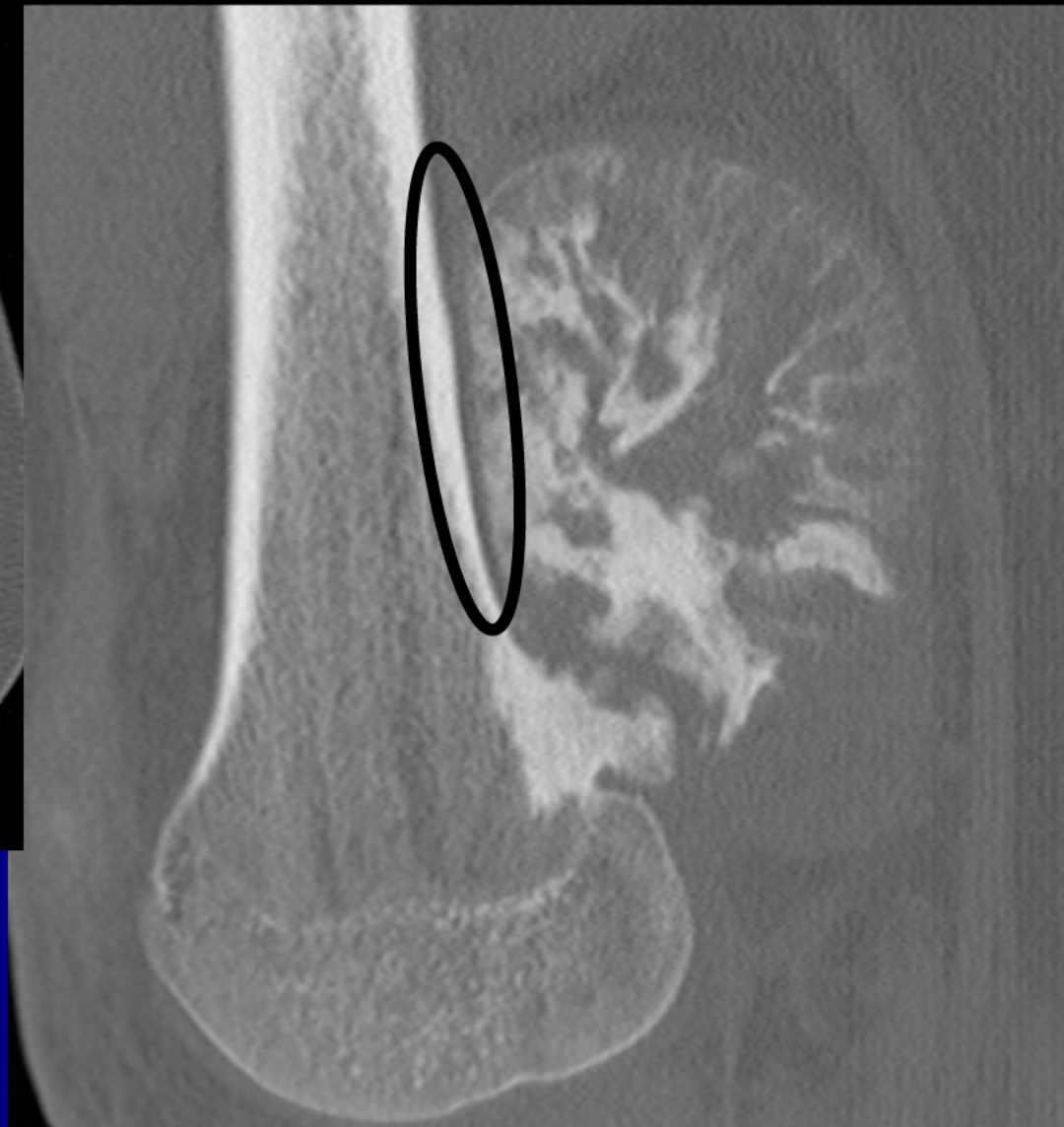




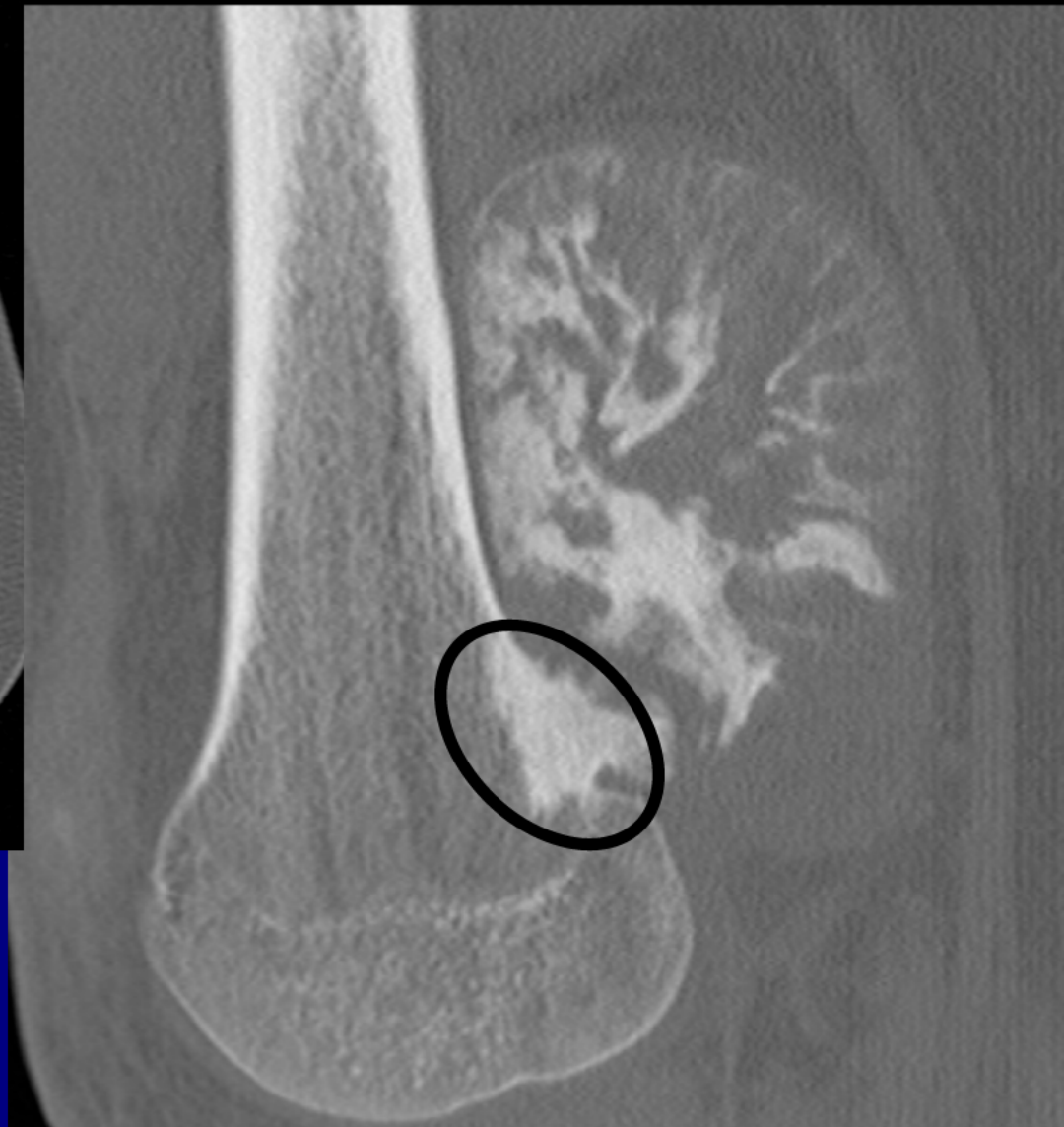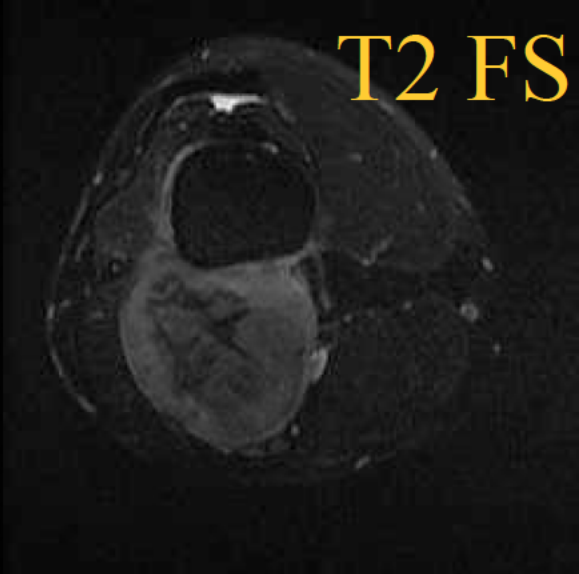
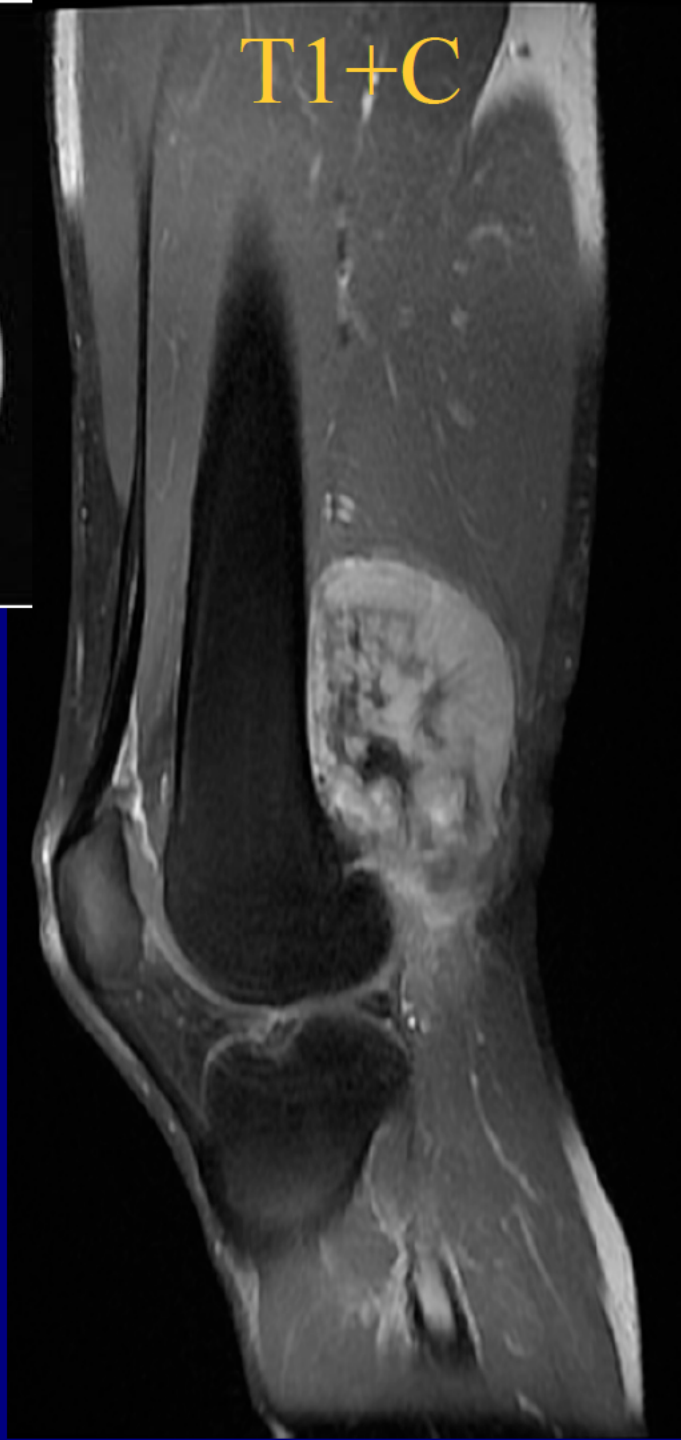
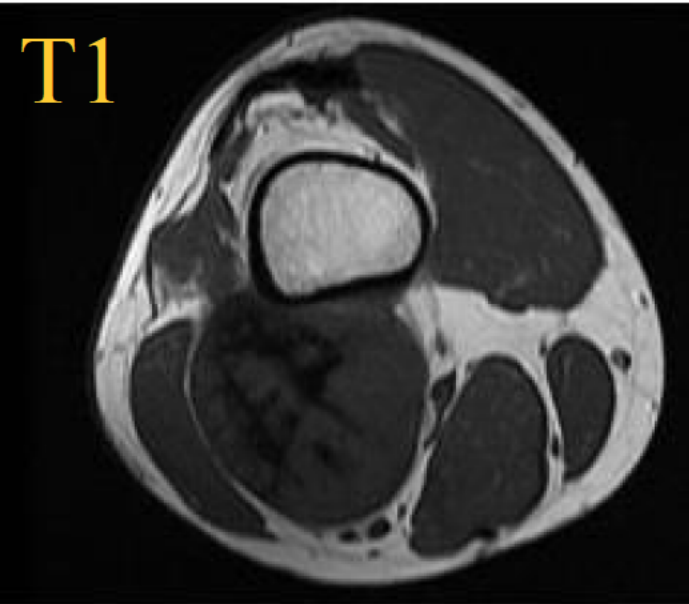




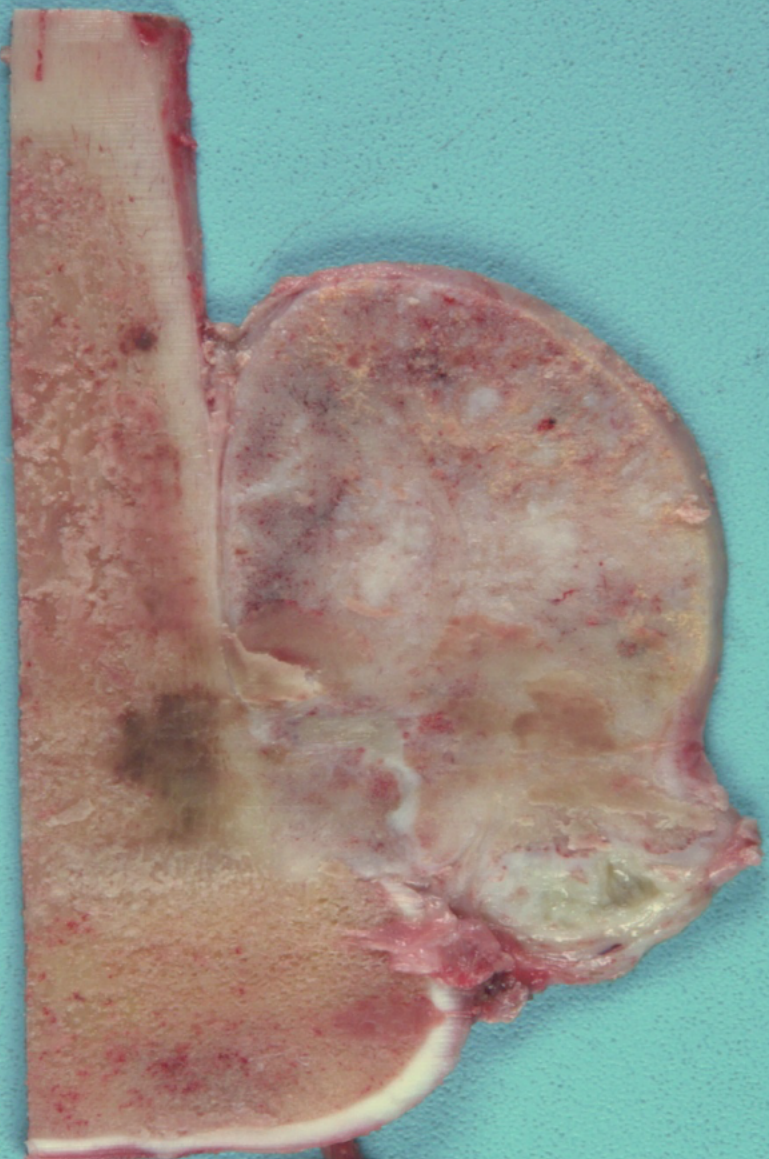
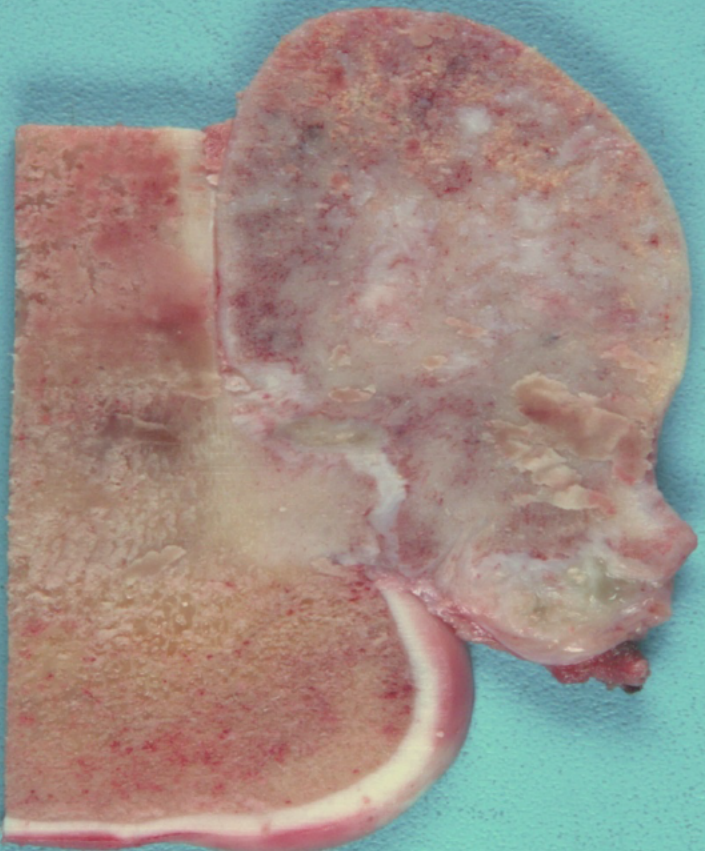




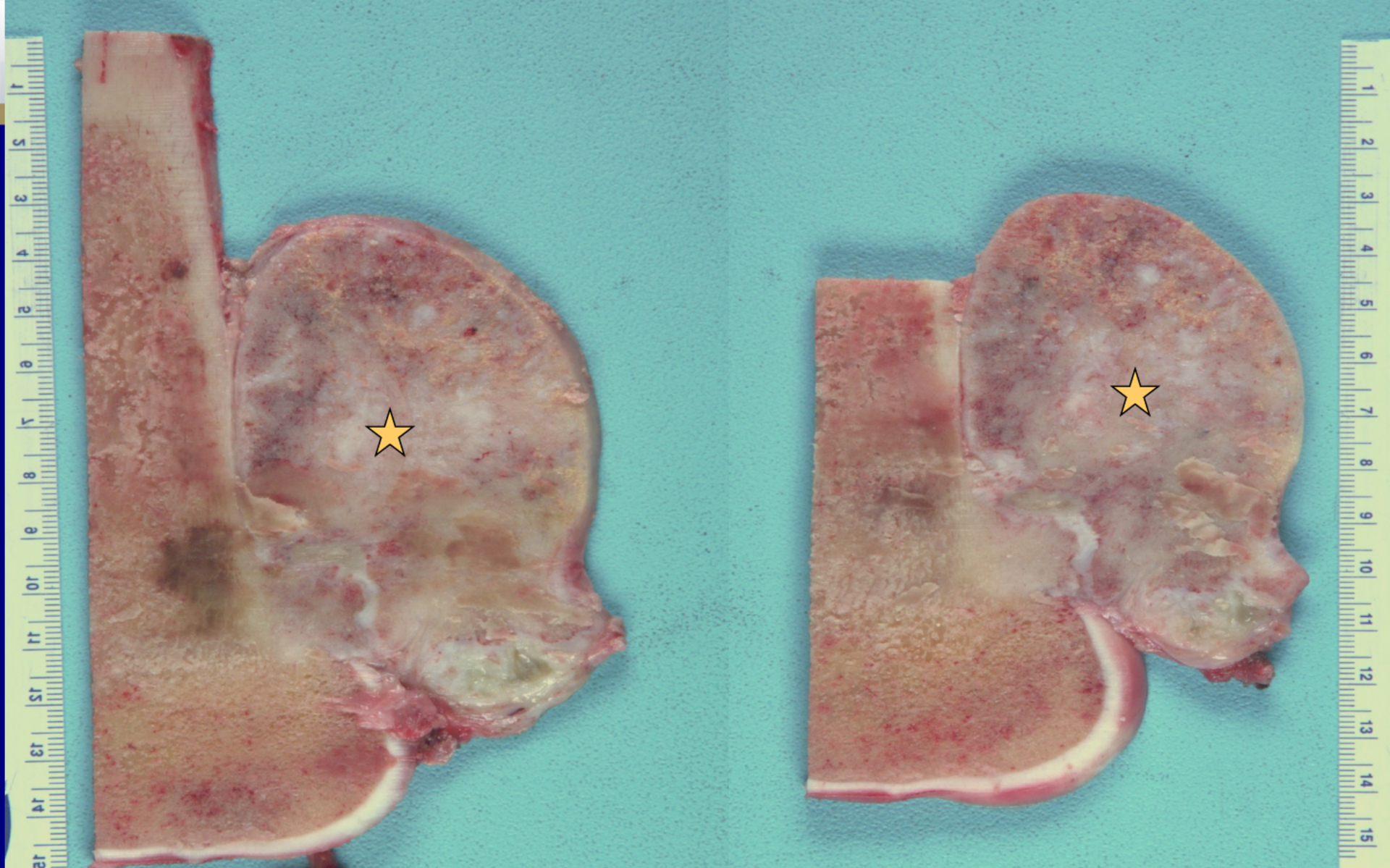




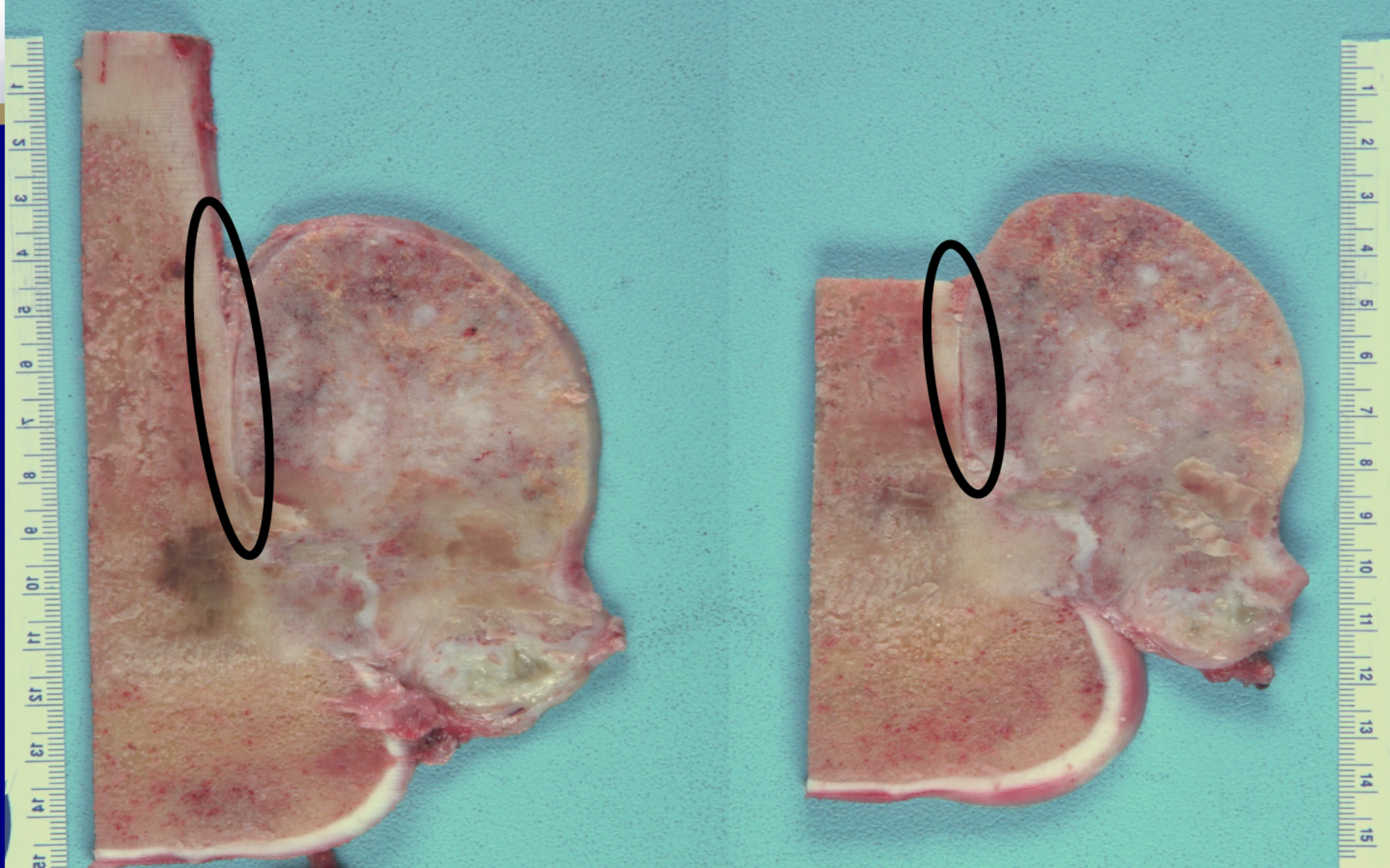




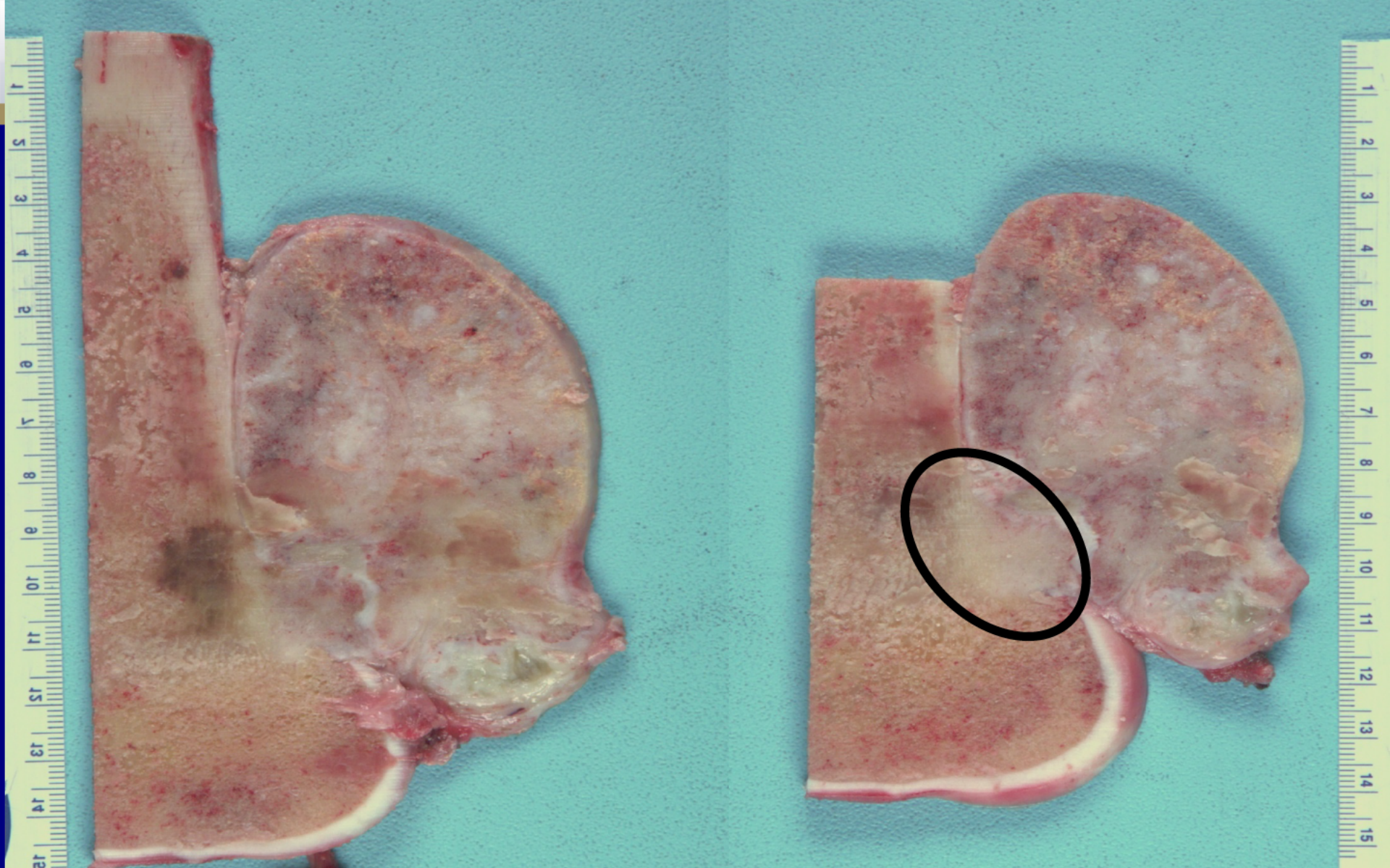




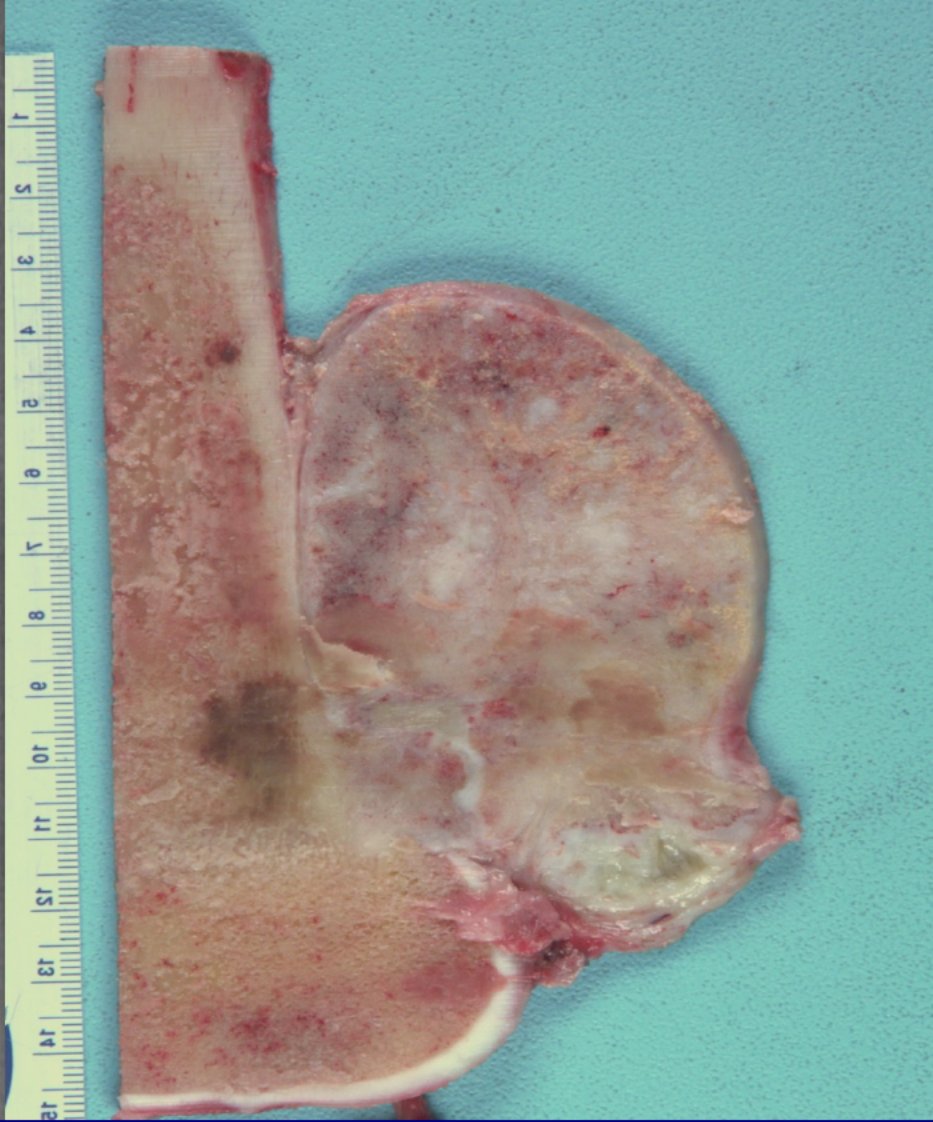




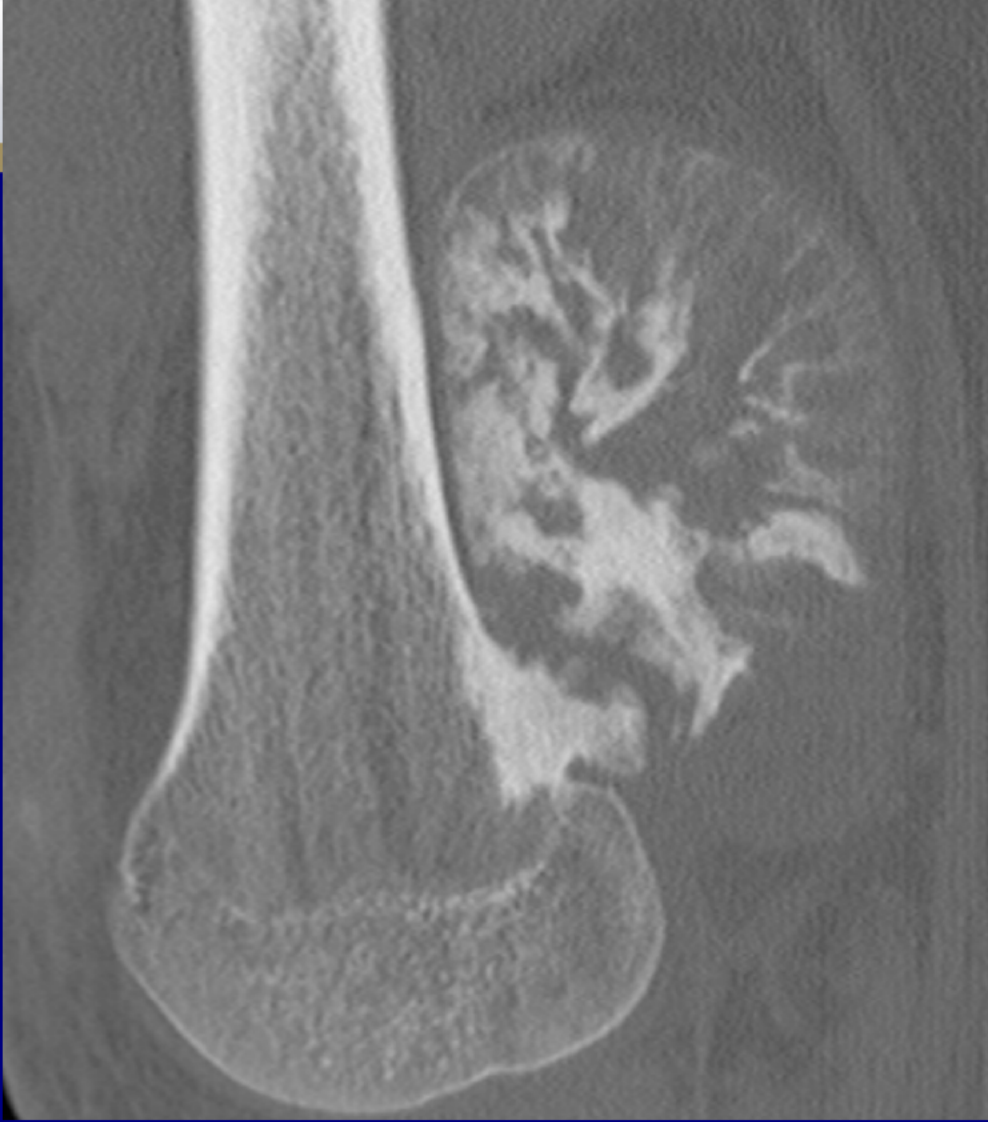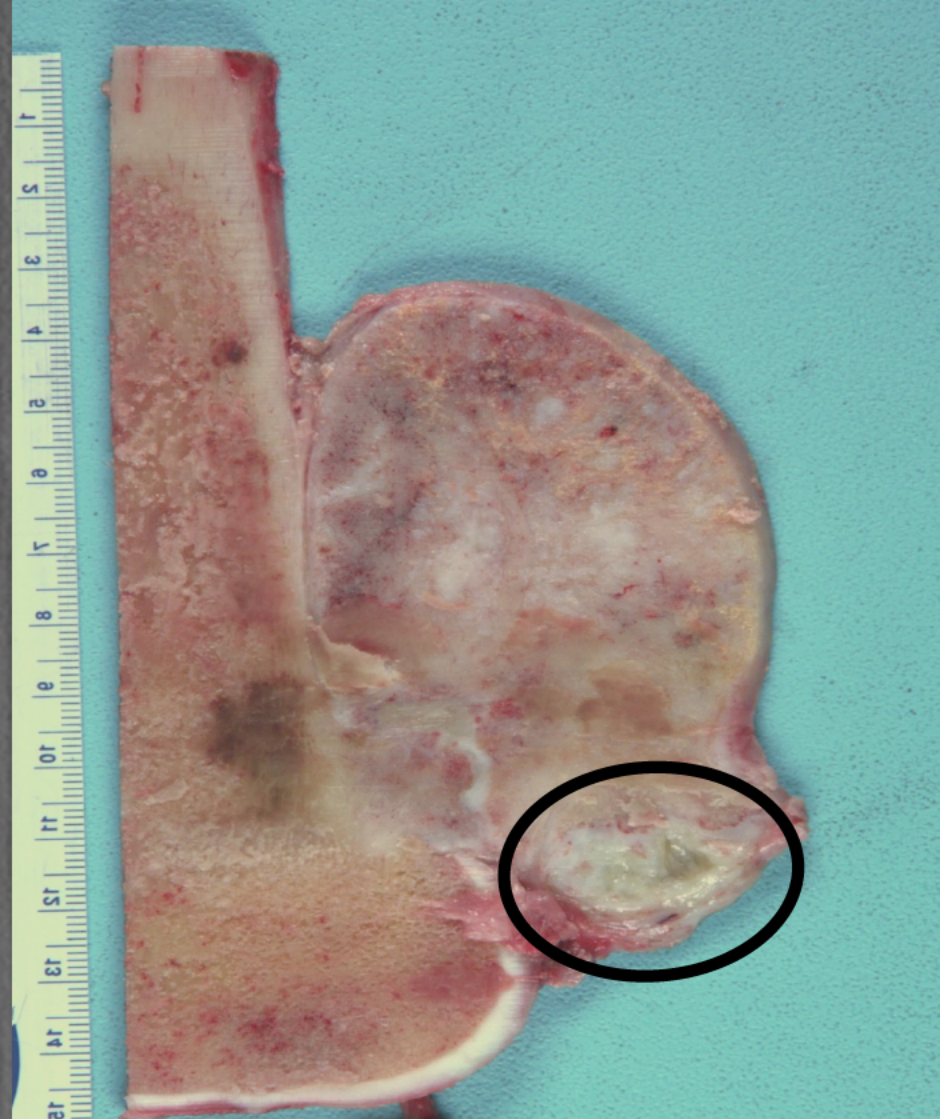




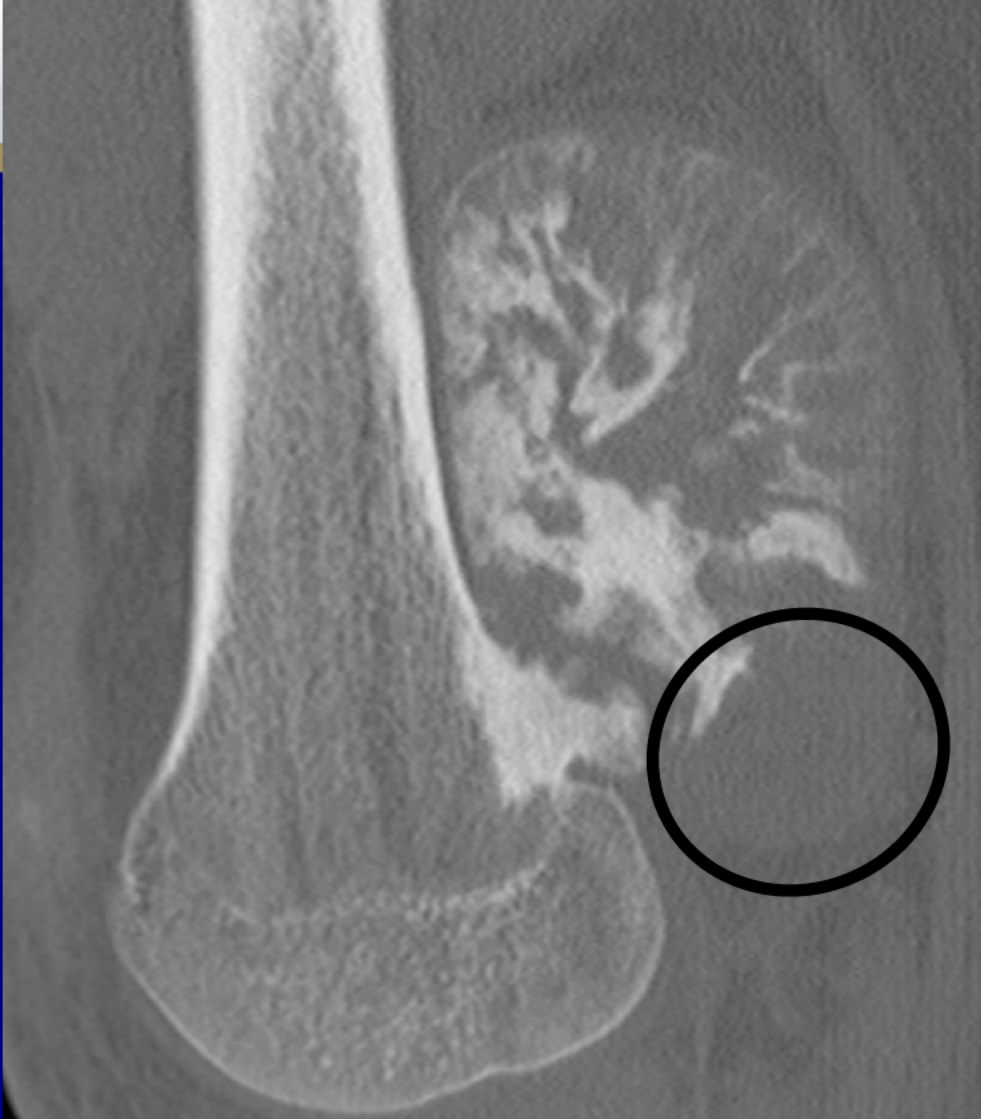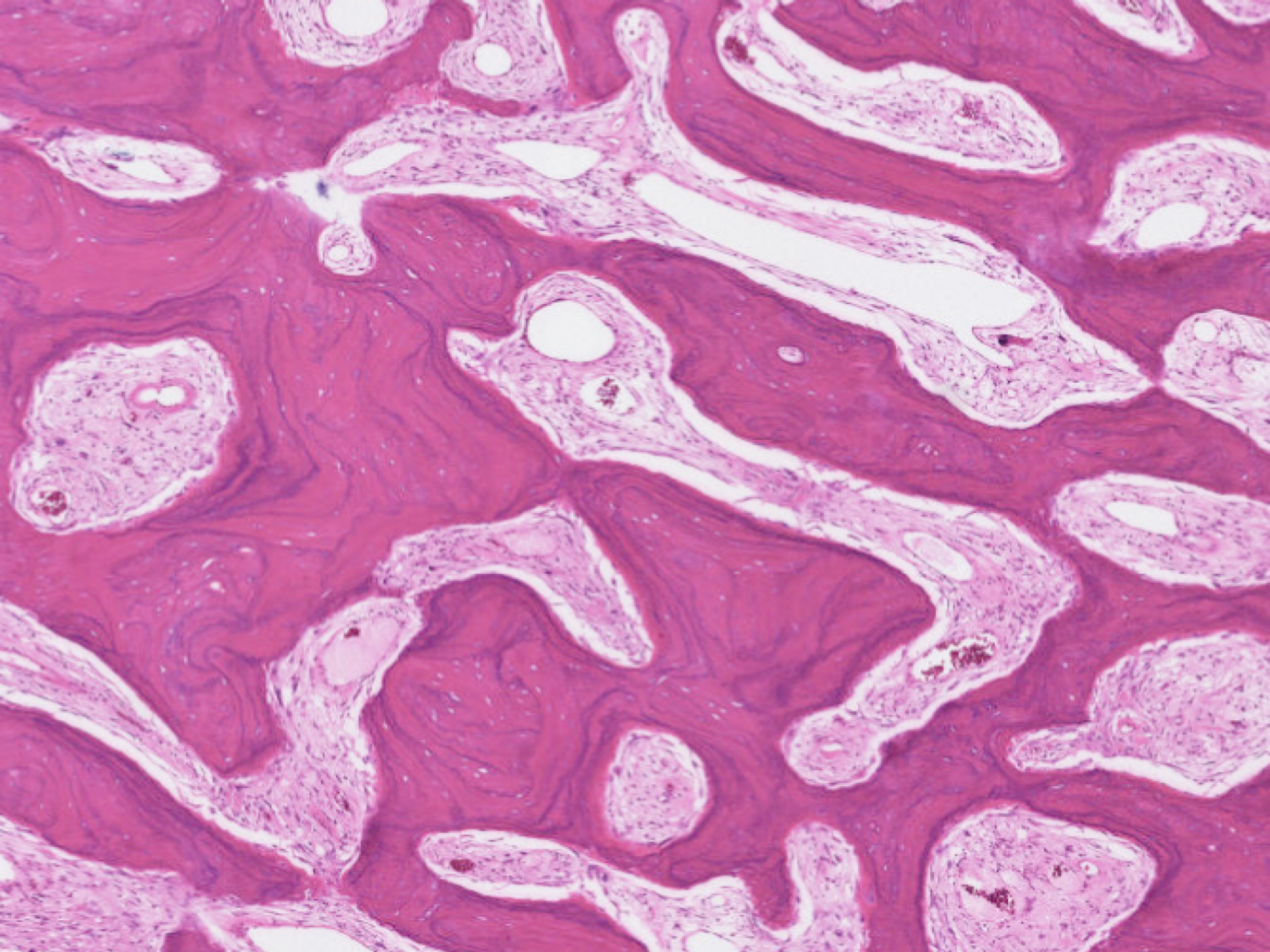












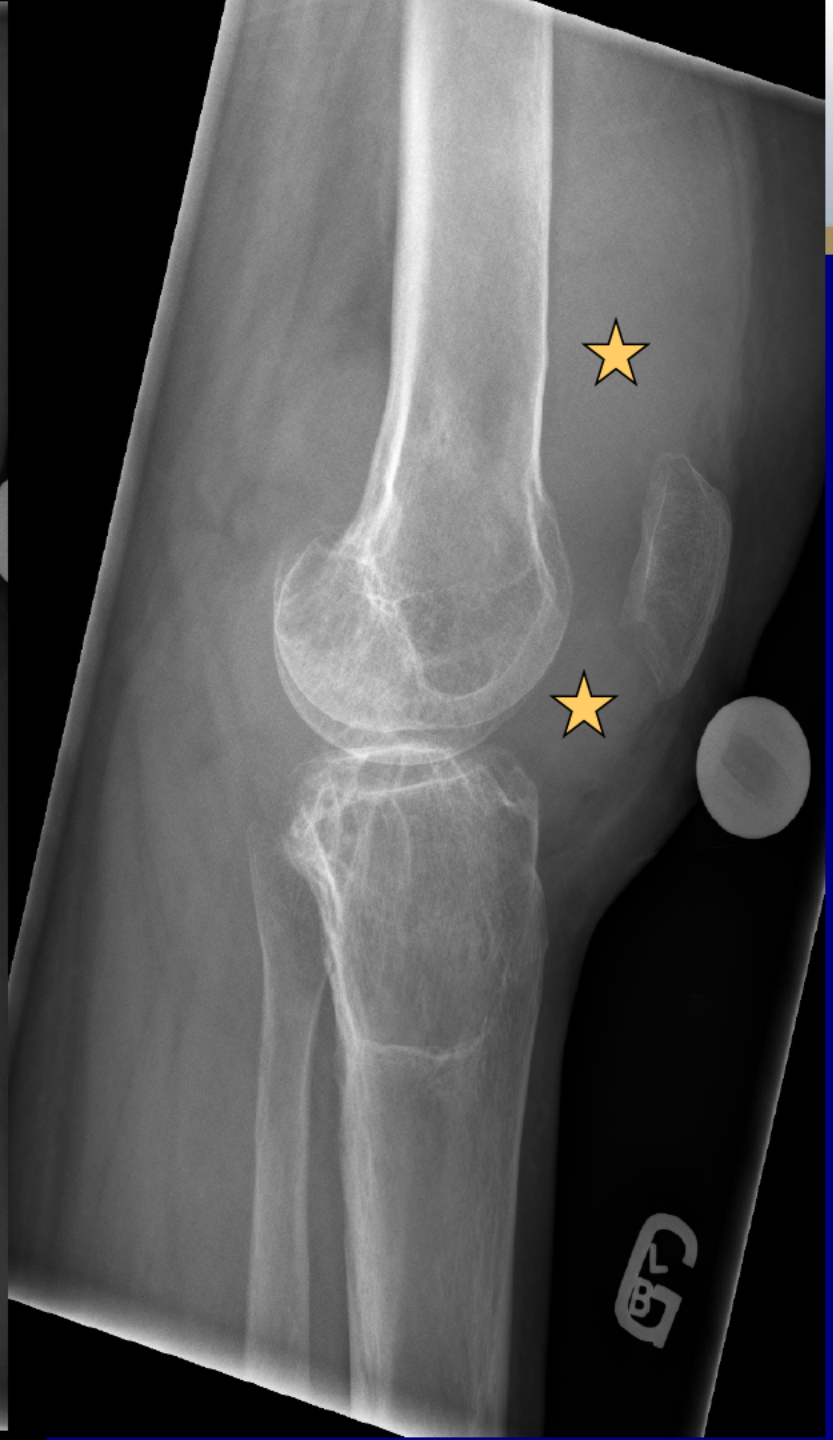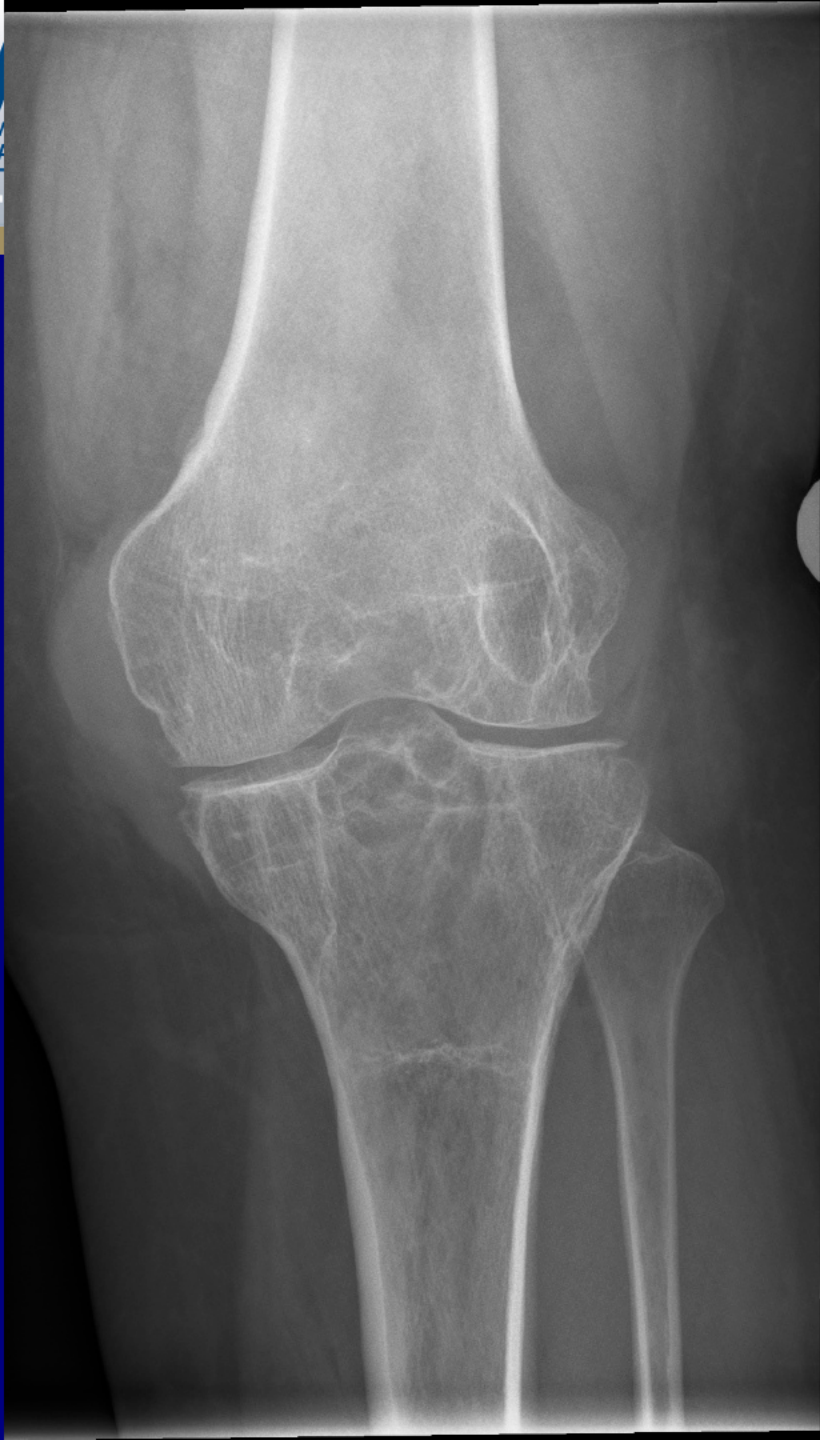# Parosteal Osteosarcoma

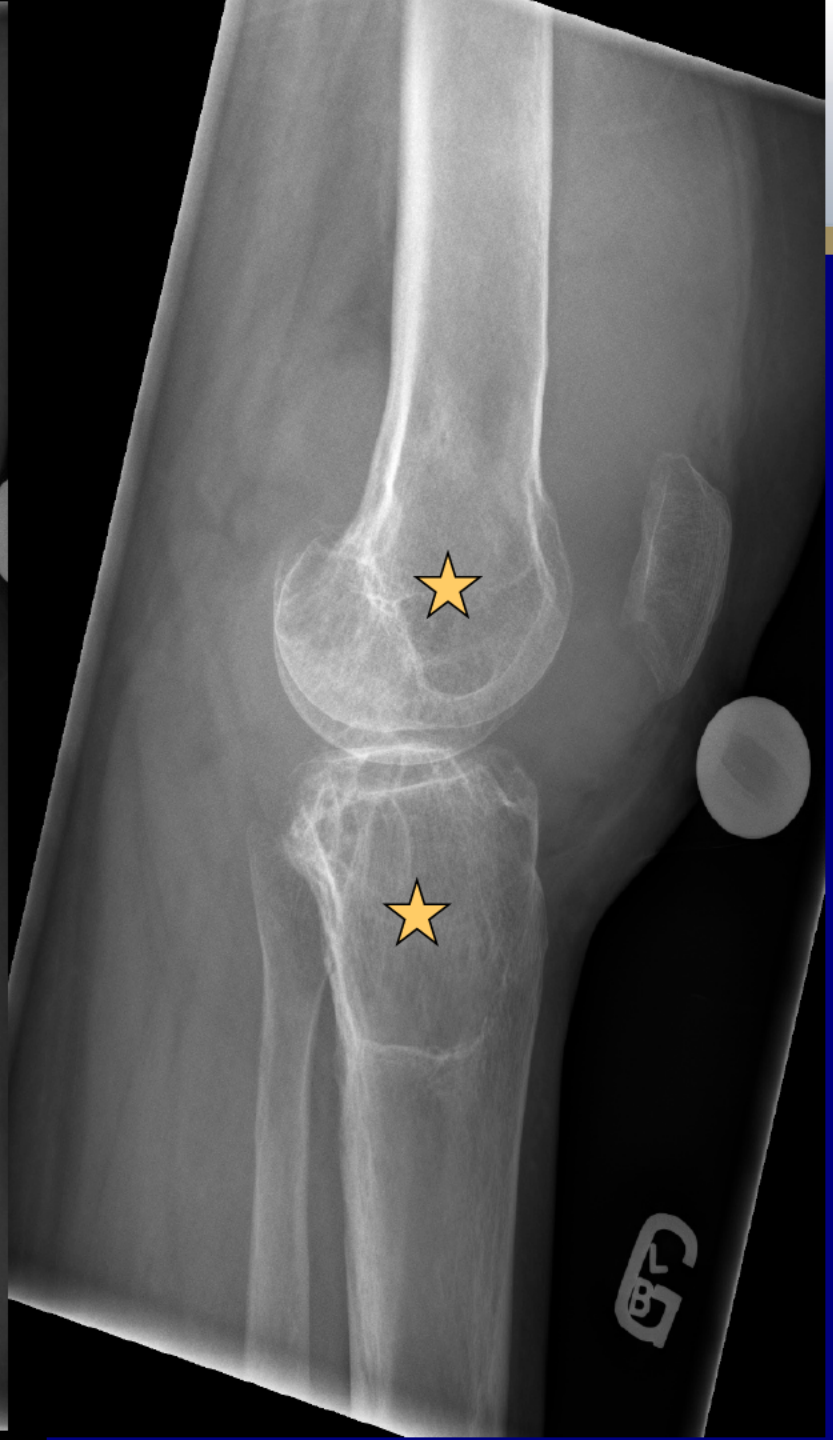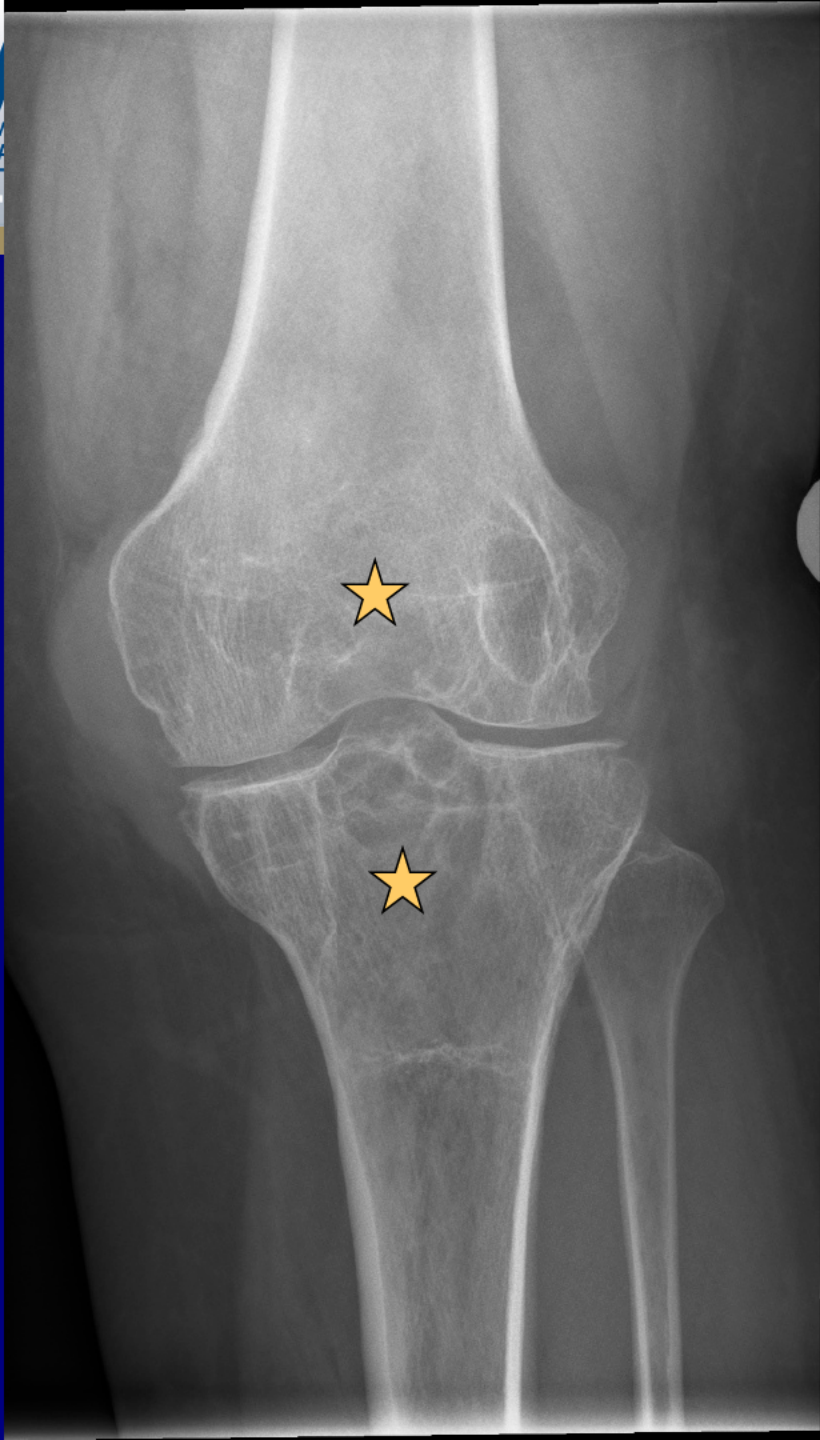**Dr. Nicolas Murray**  
**Laval University**  
**Quebec City, Quebec, Canada**

**Honorable mention!**

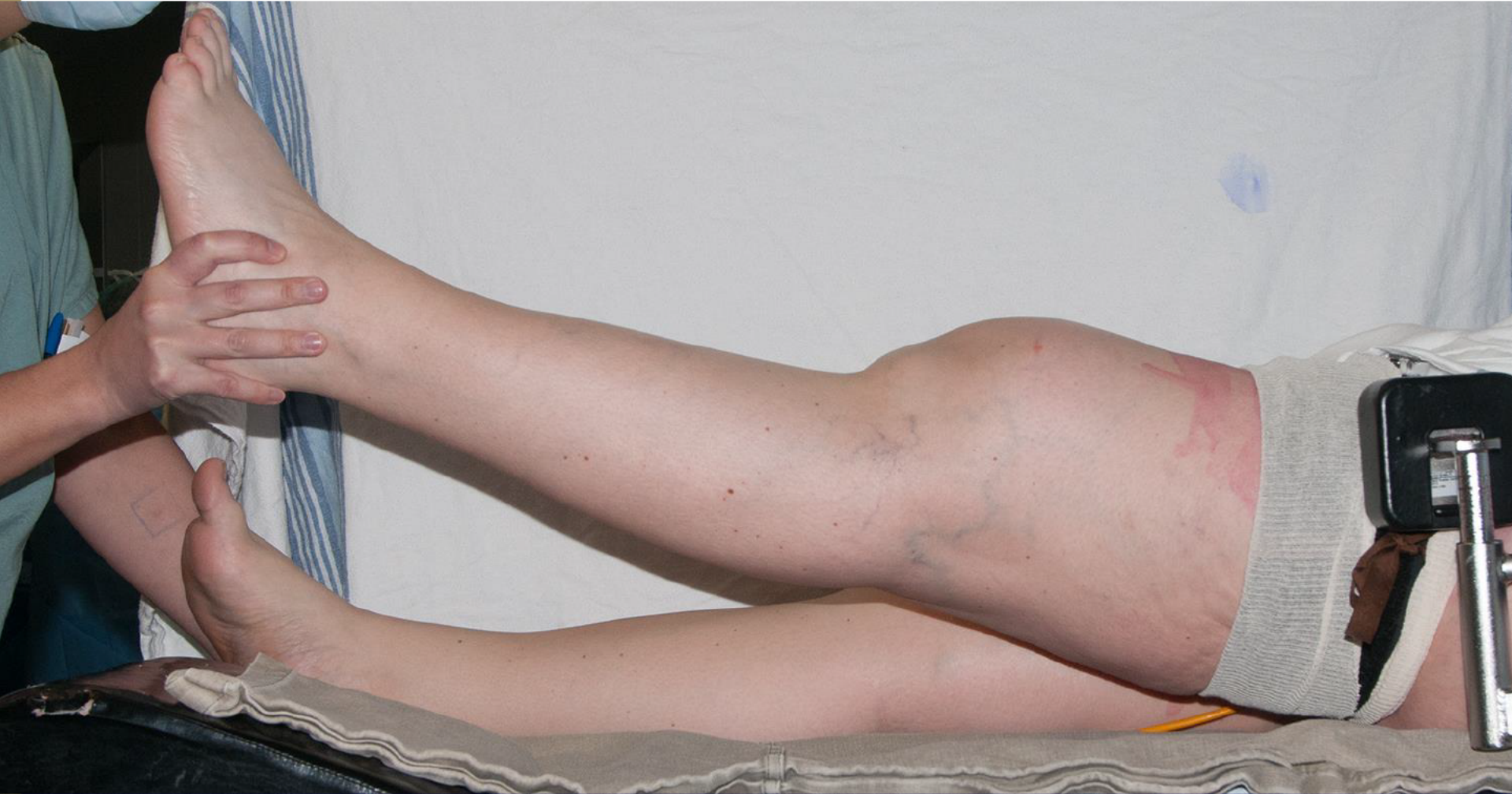**32 year-old female with progressive  
knee swelling for 4 years**



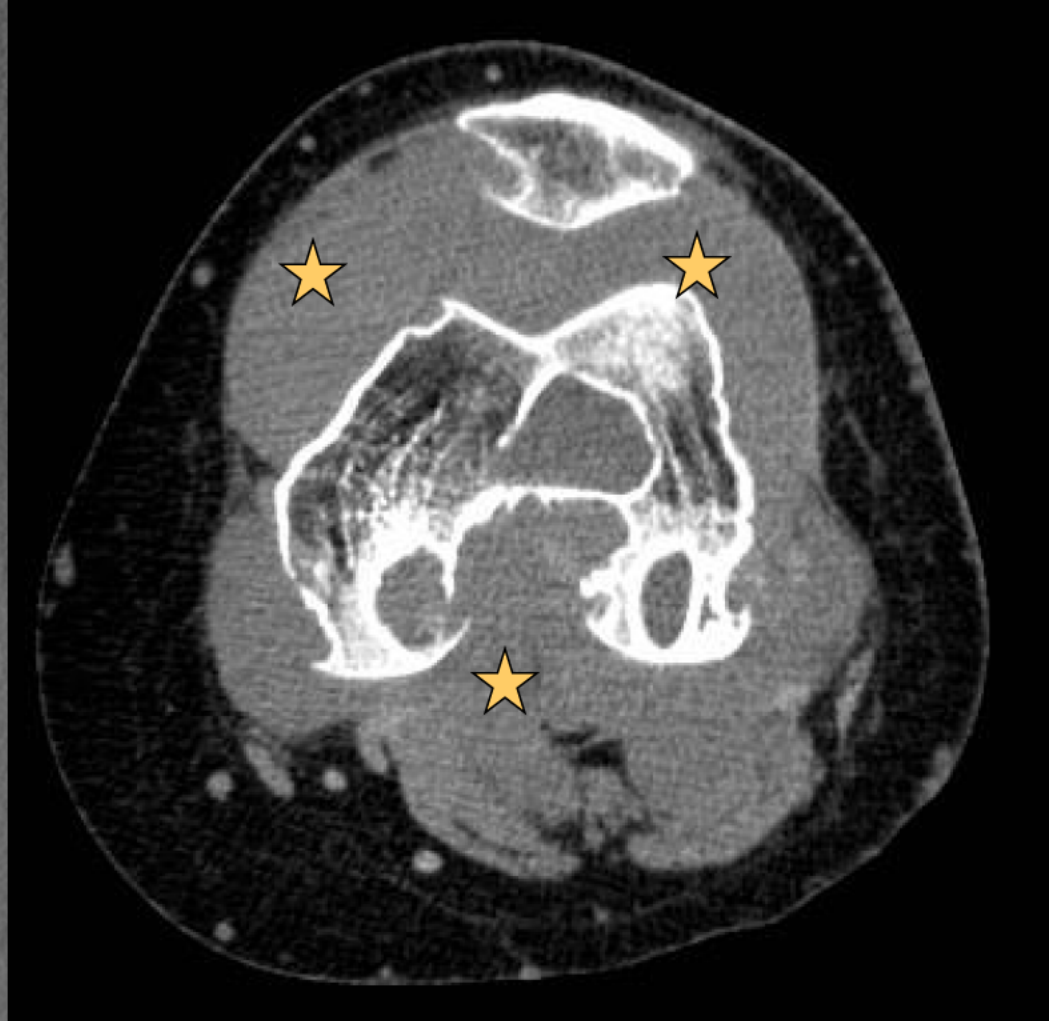
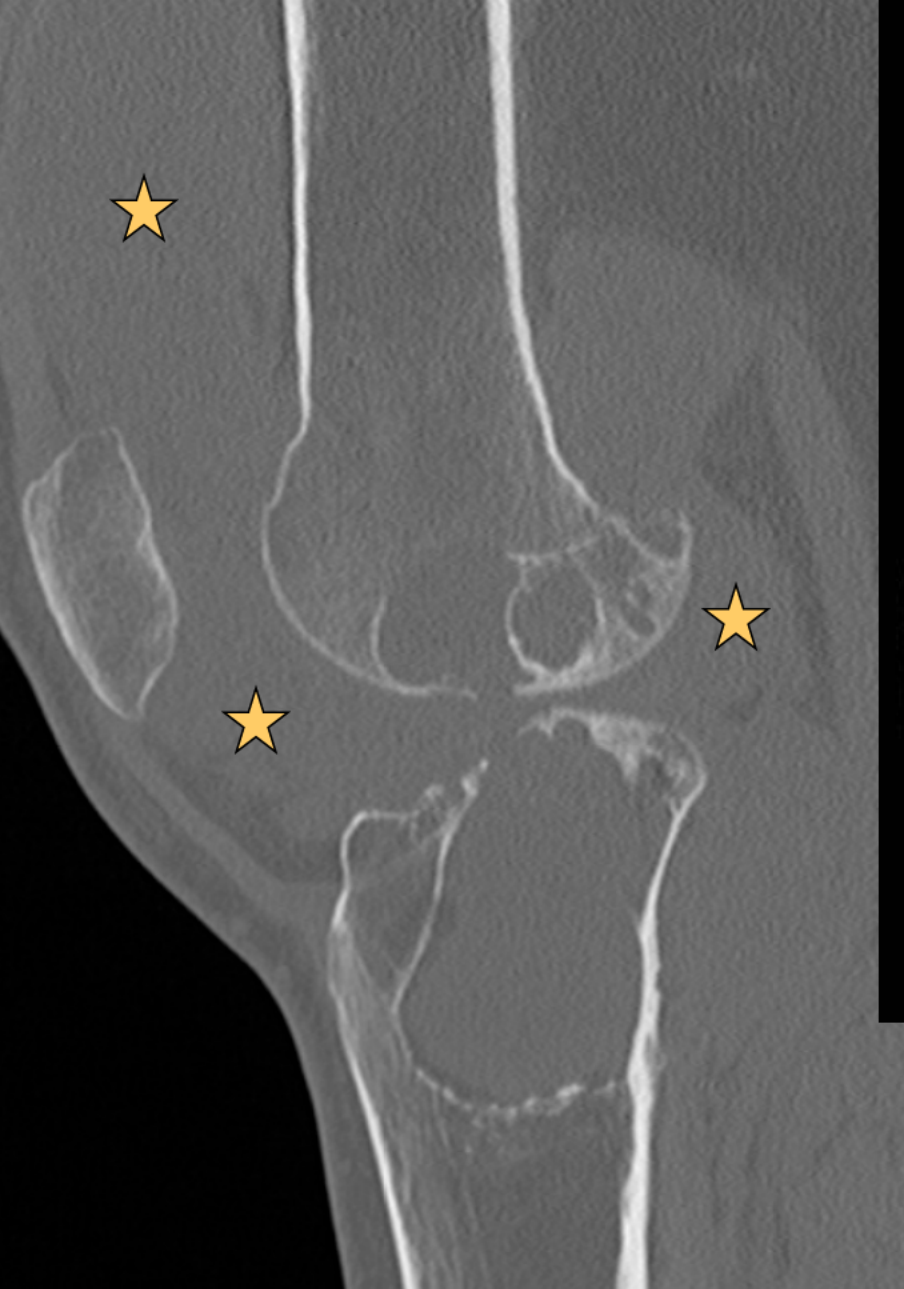
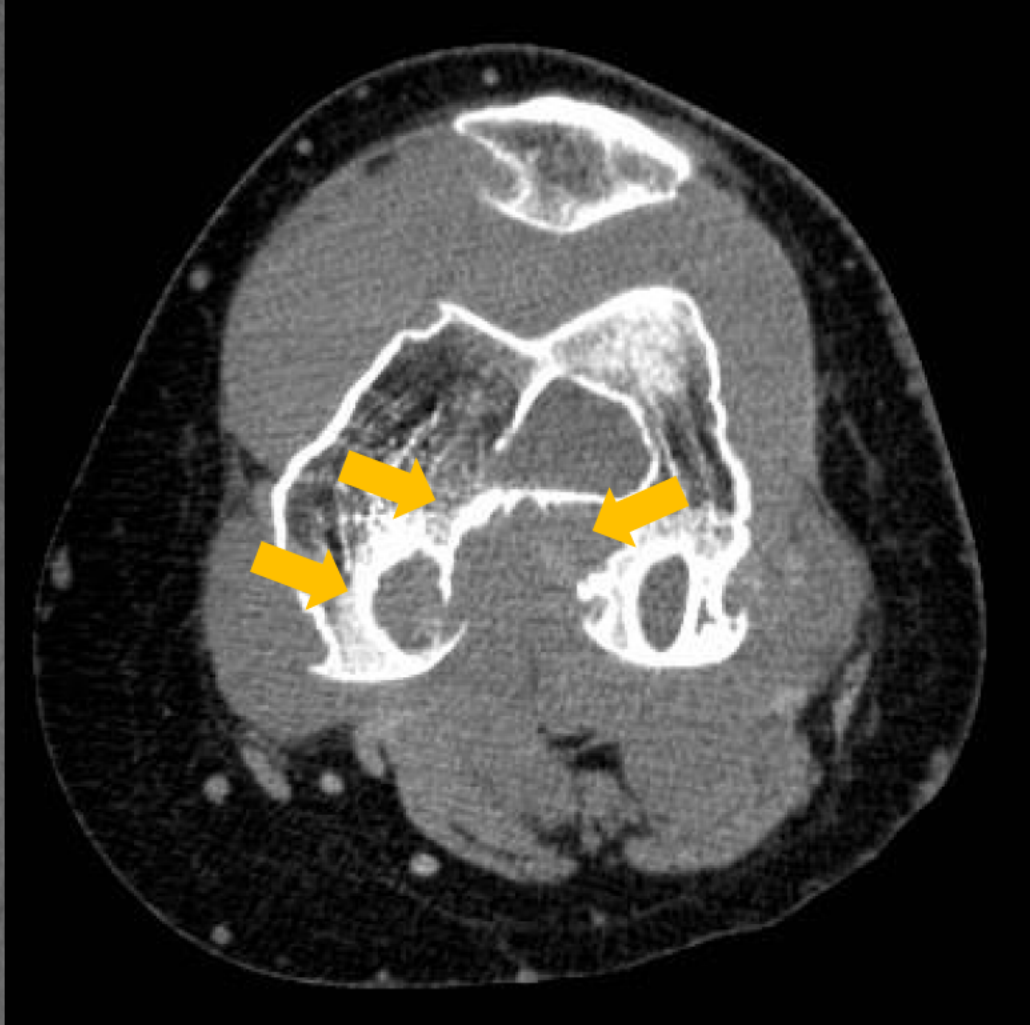


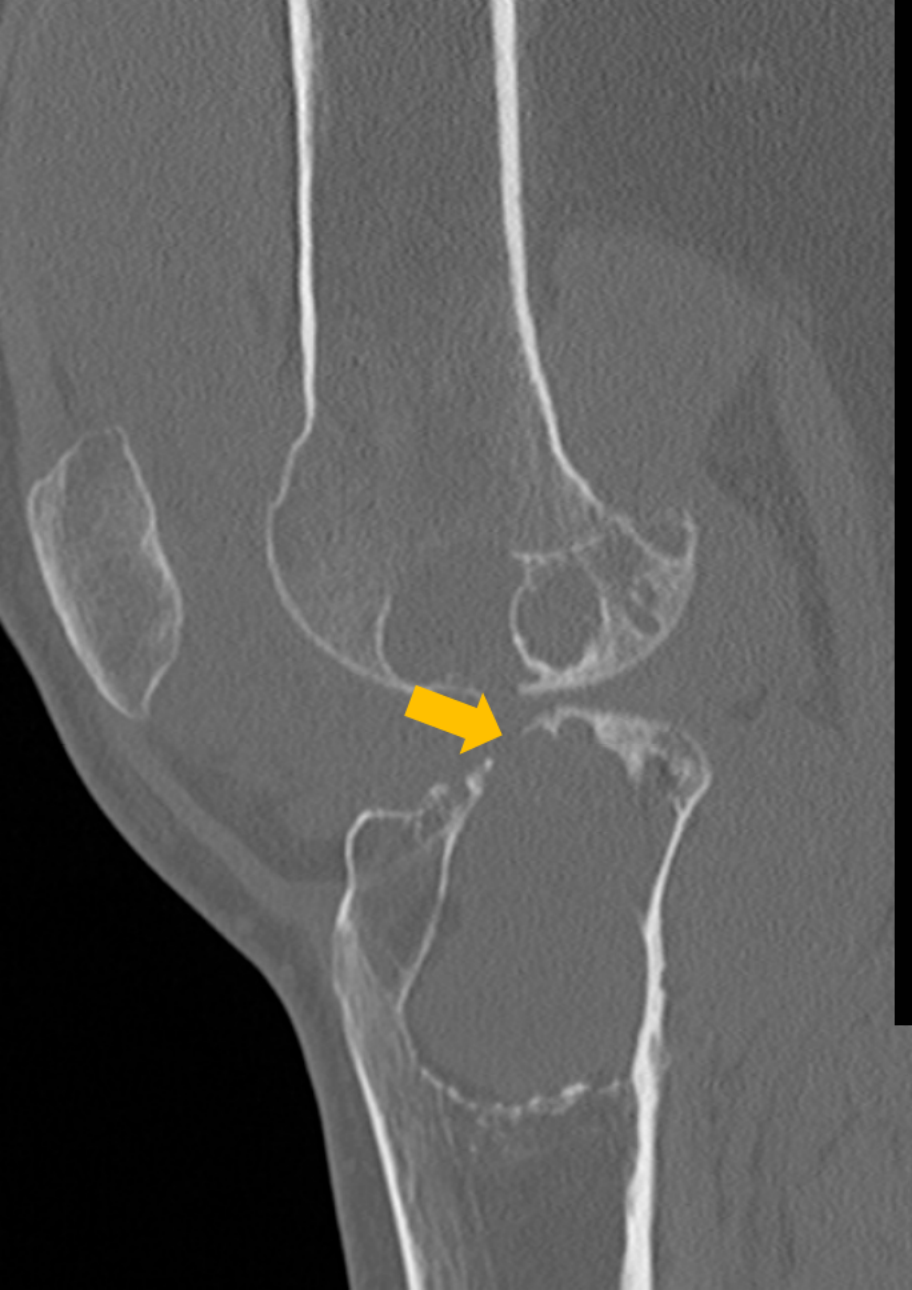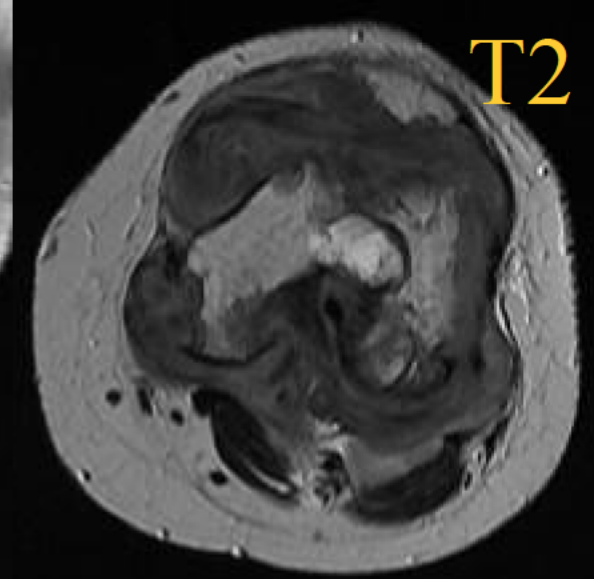
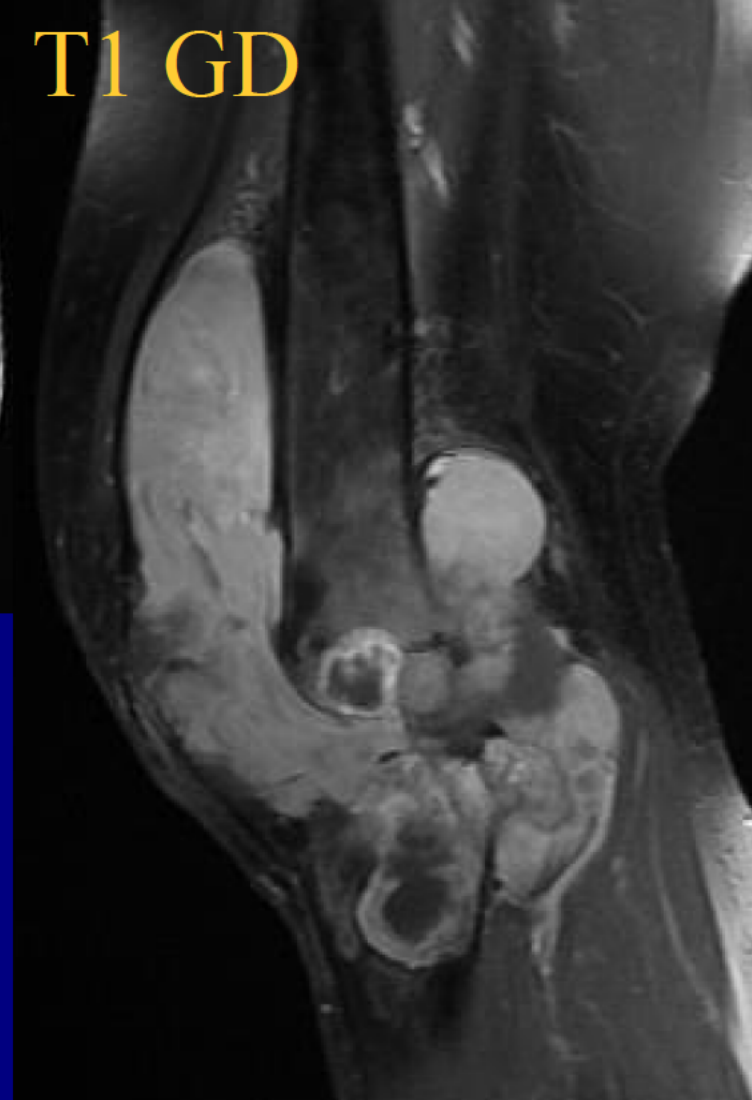
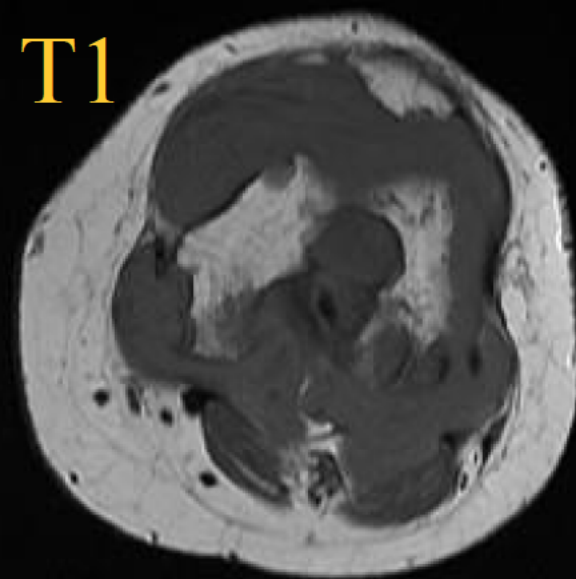


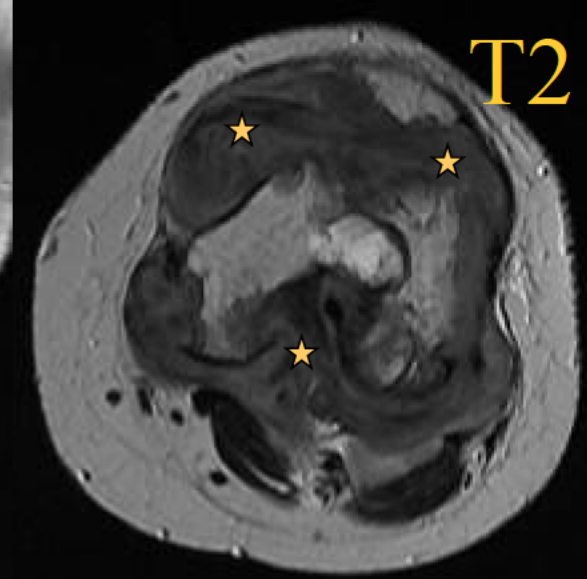
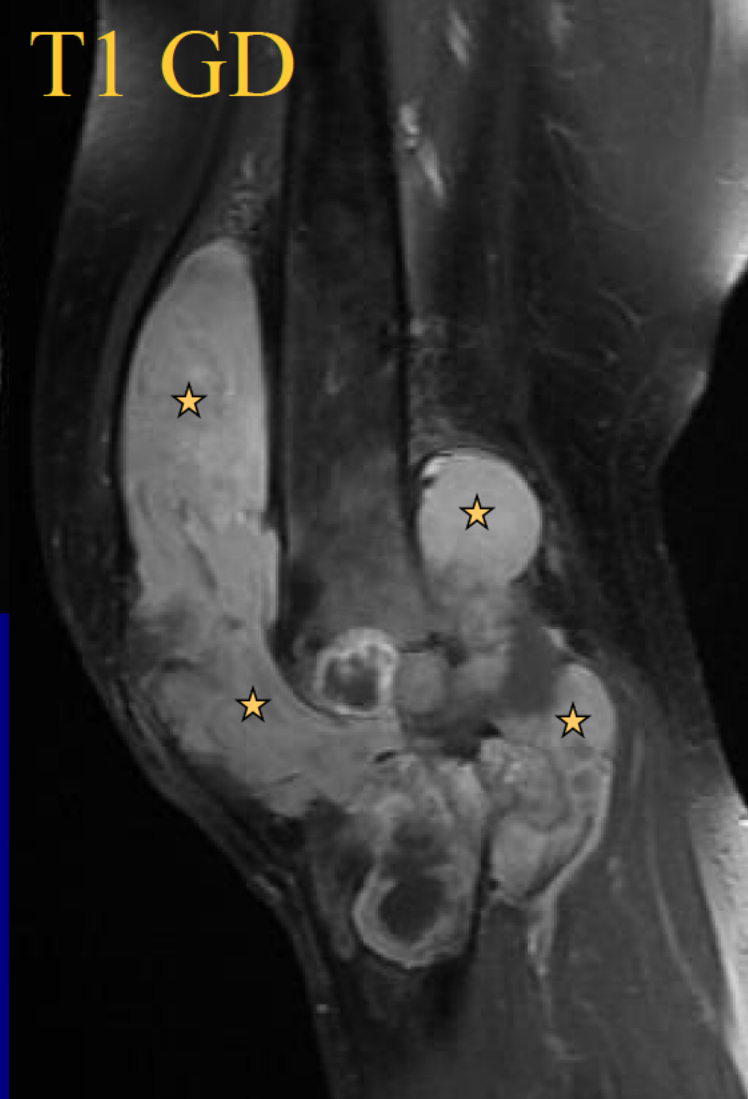
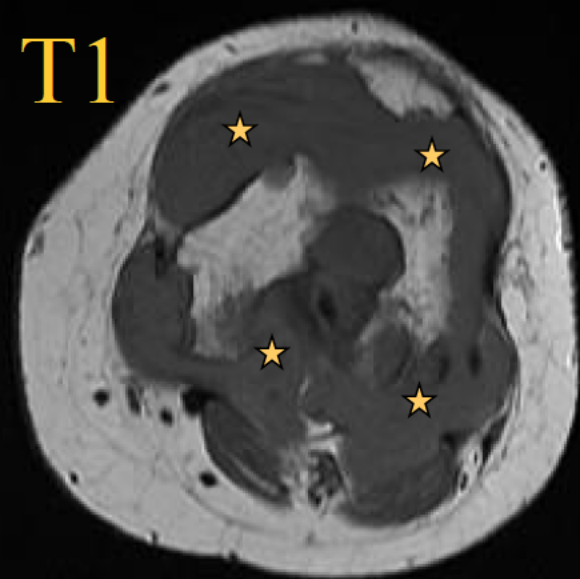


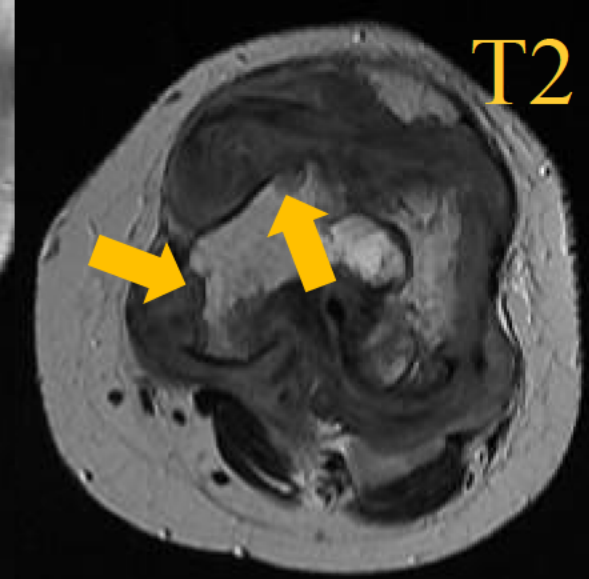
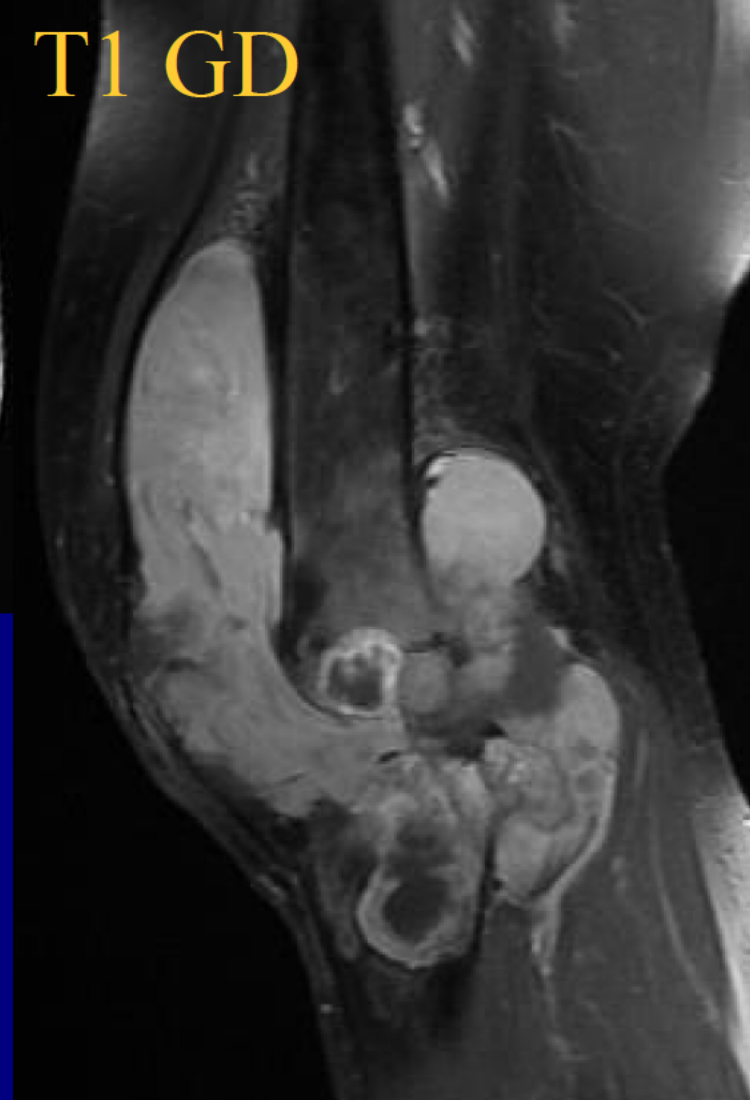
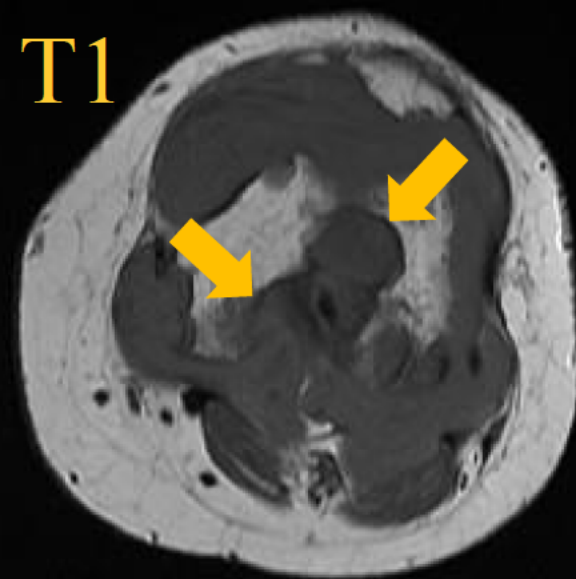





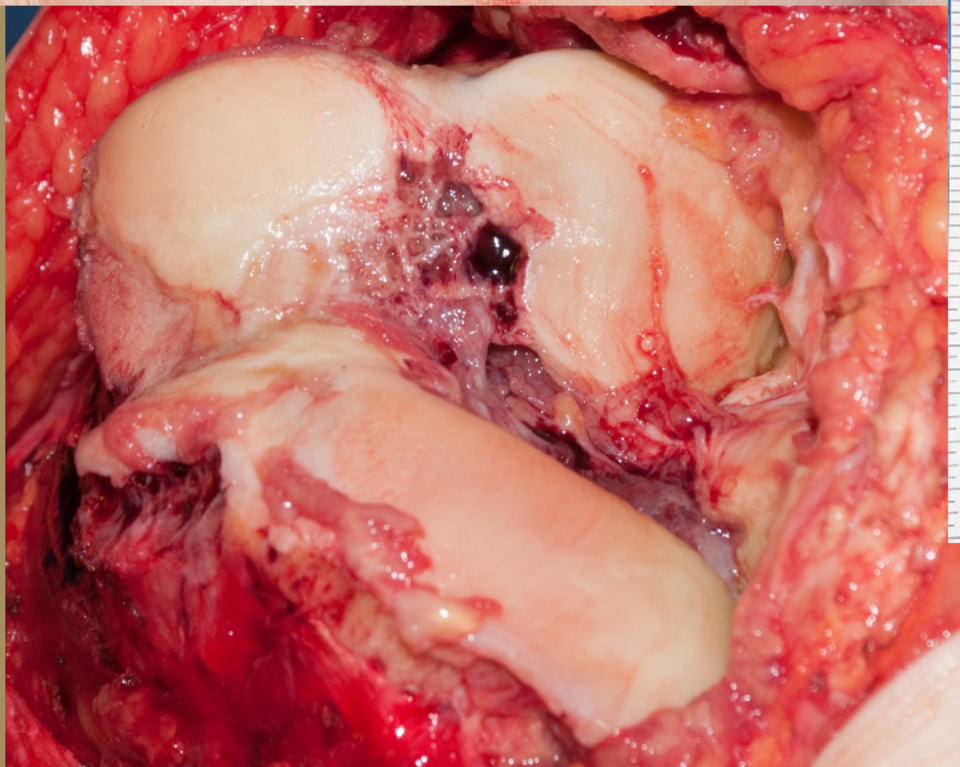
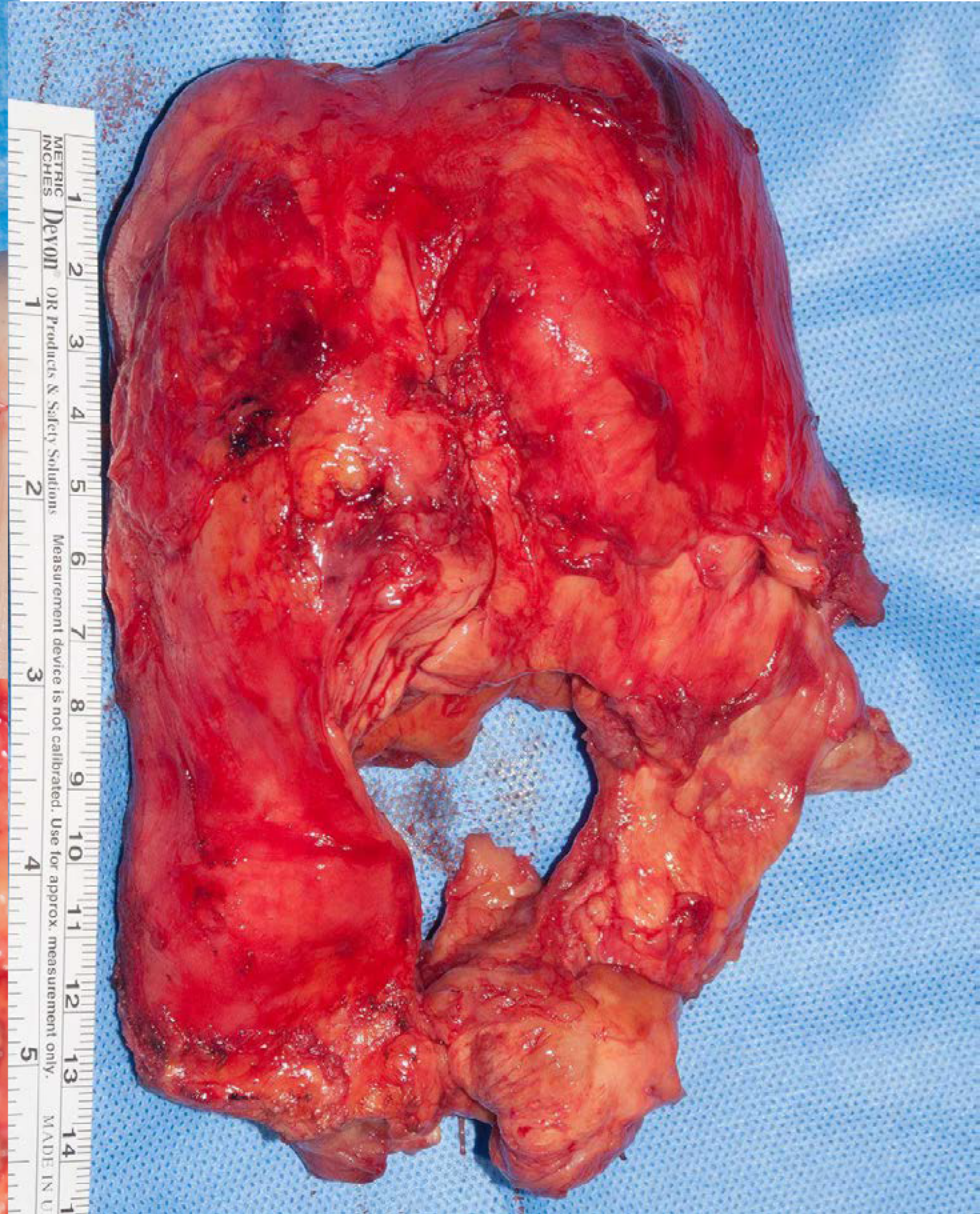
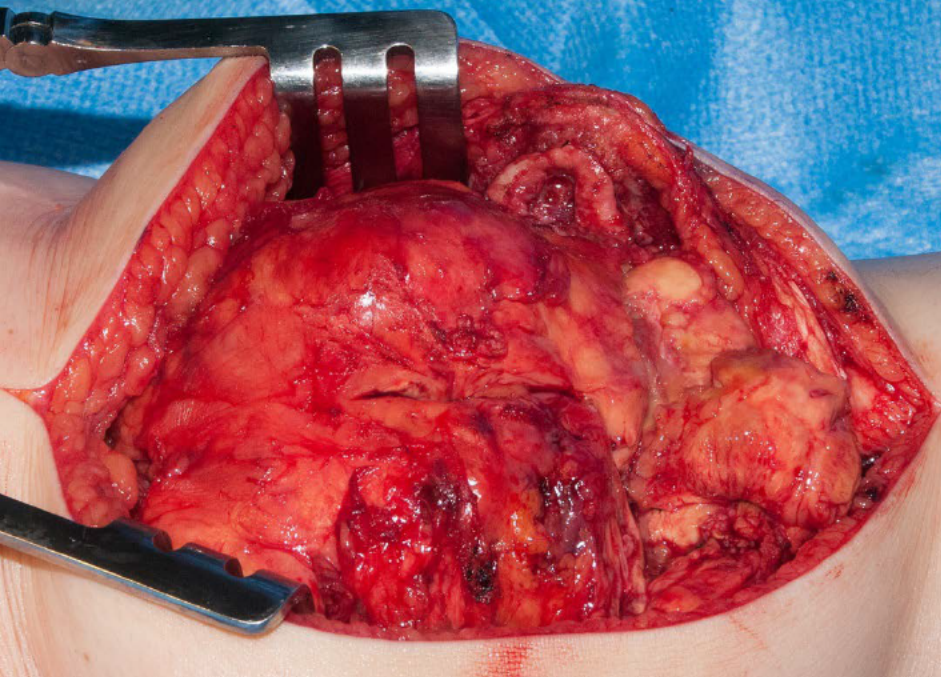




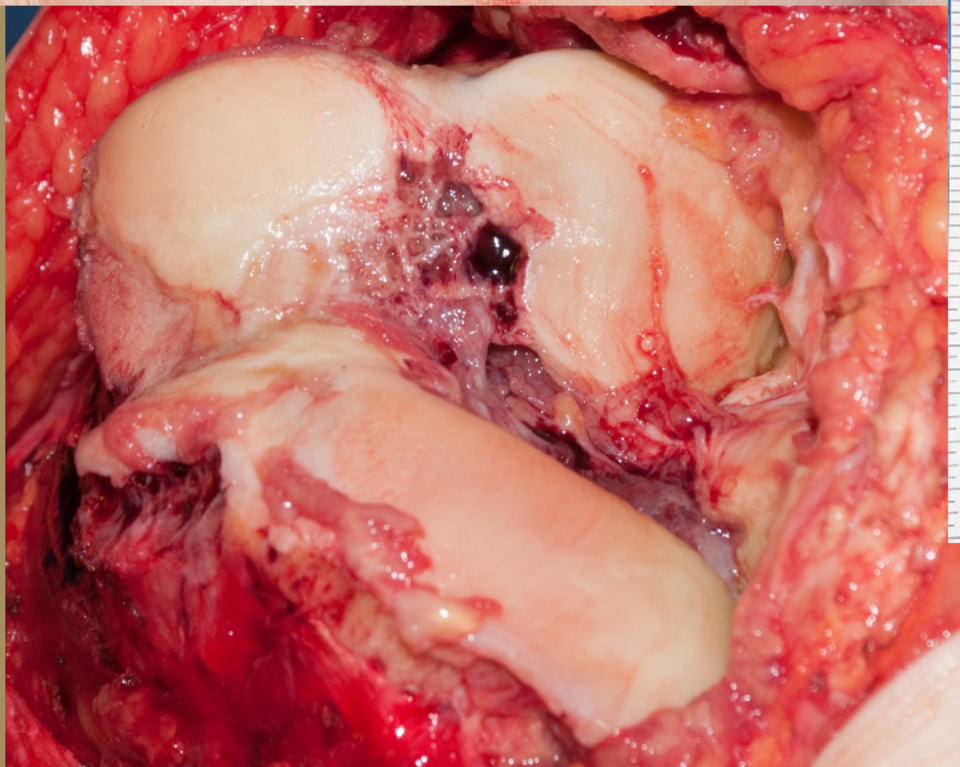
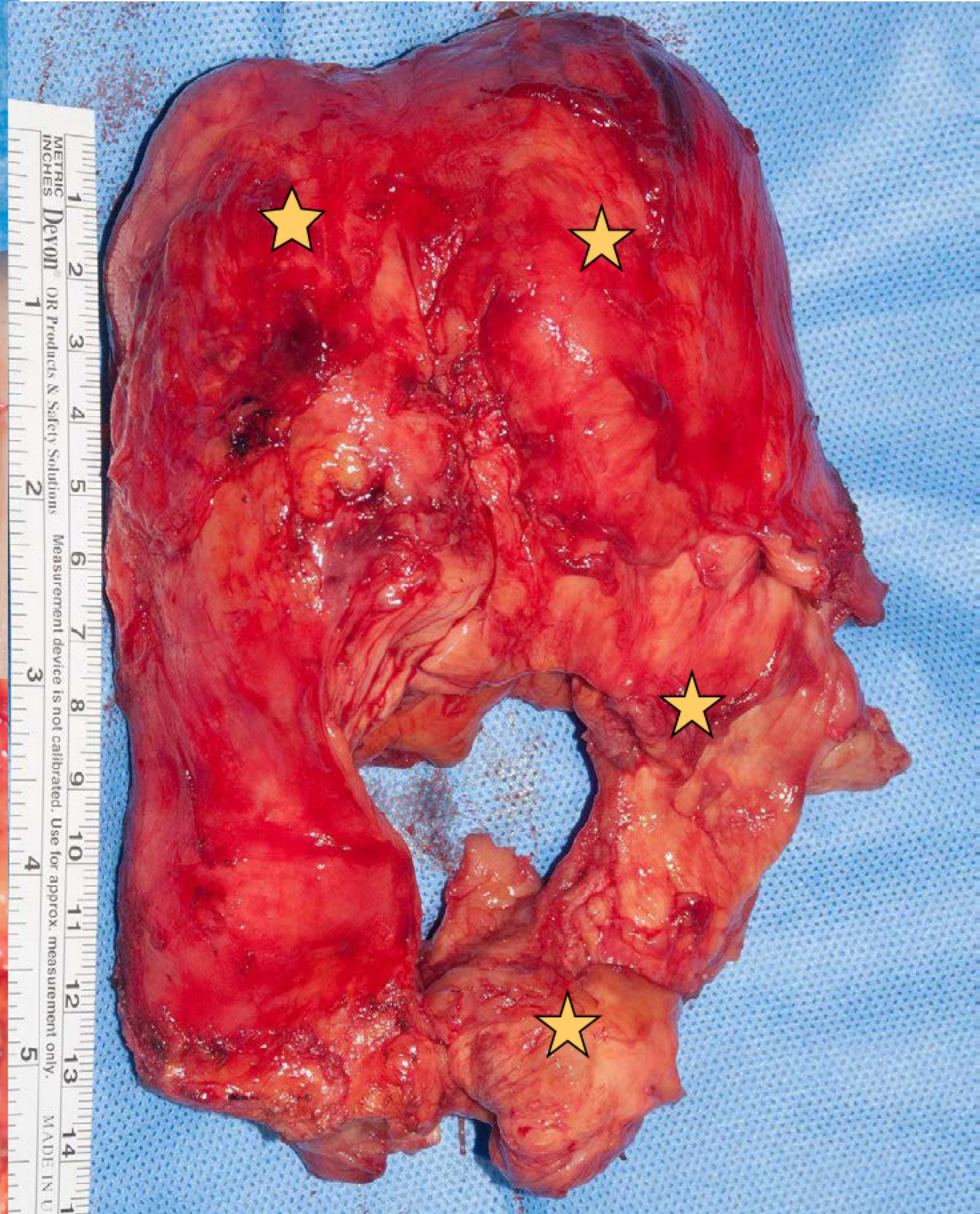
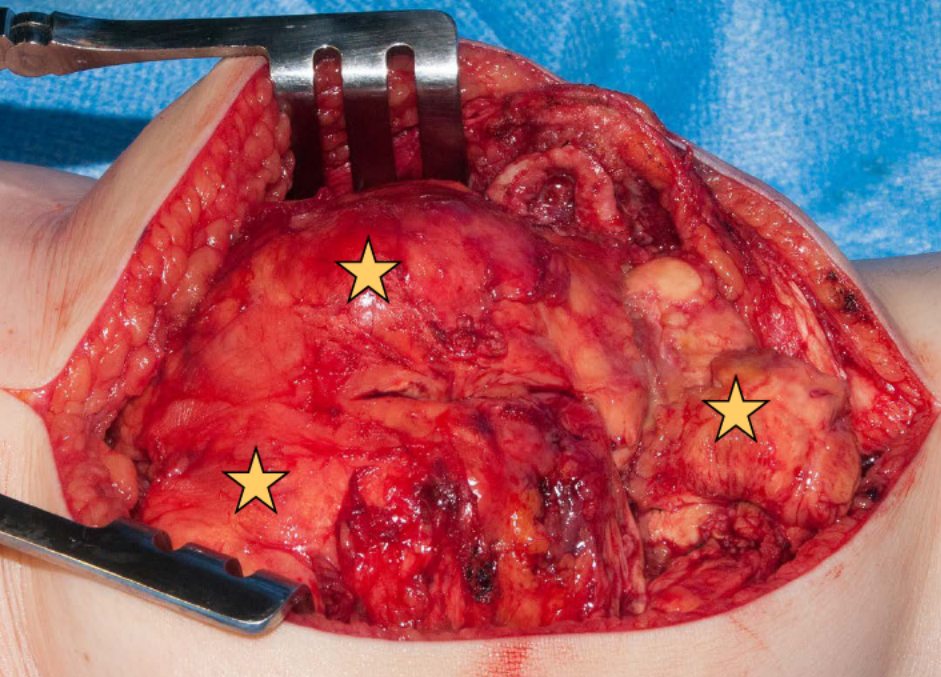





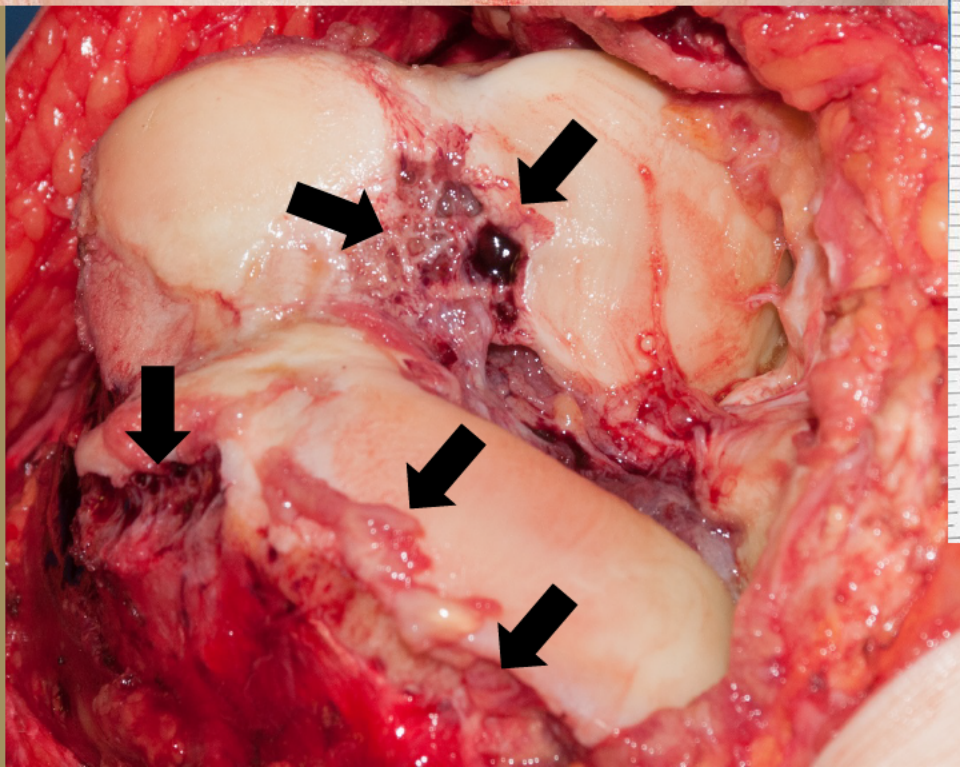
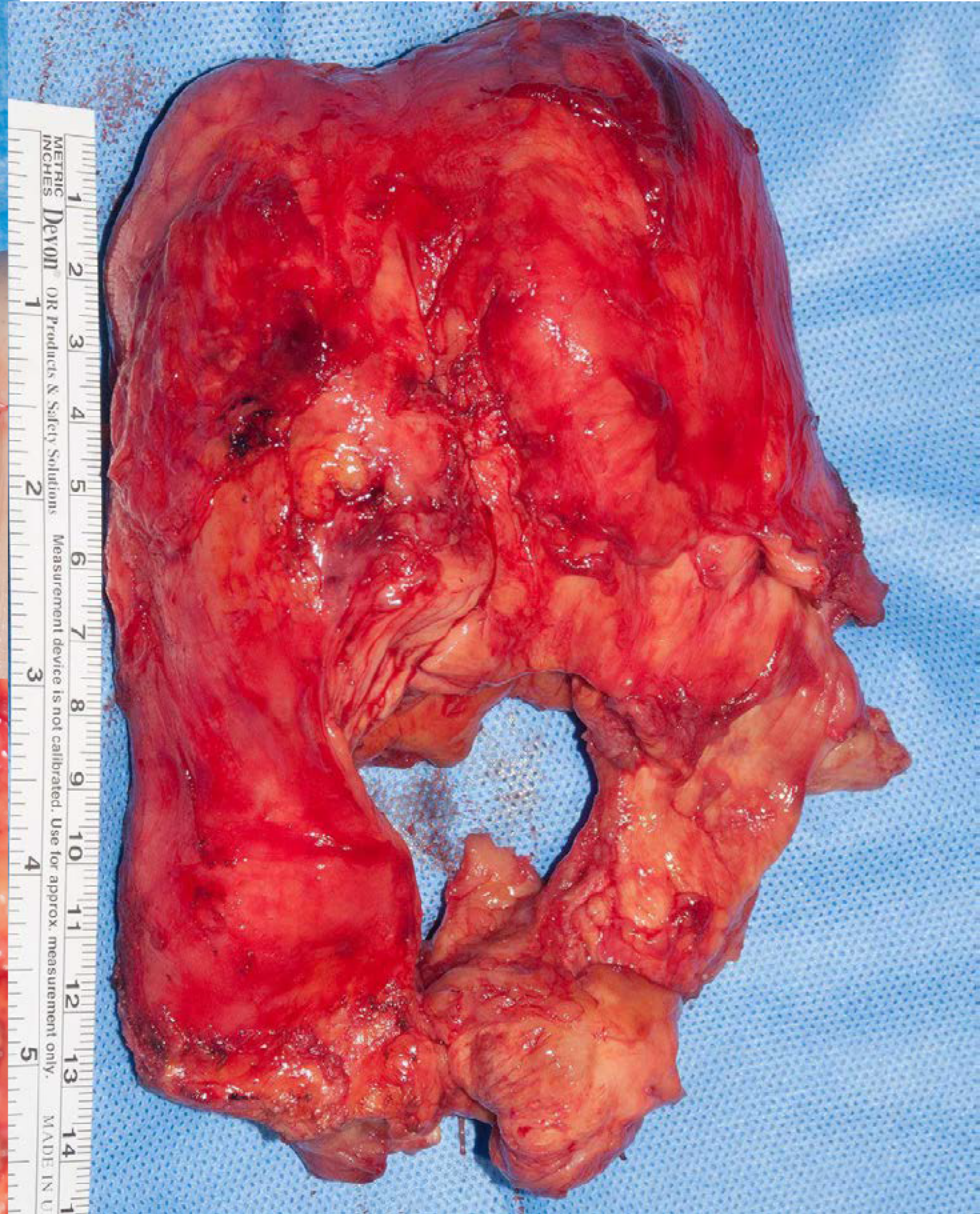
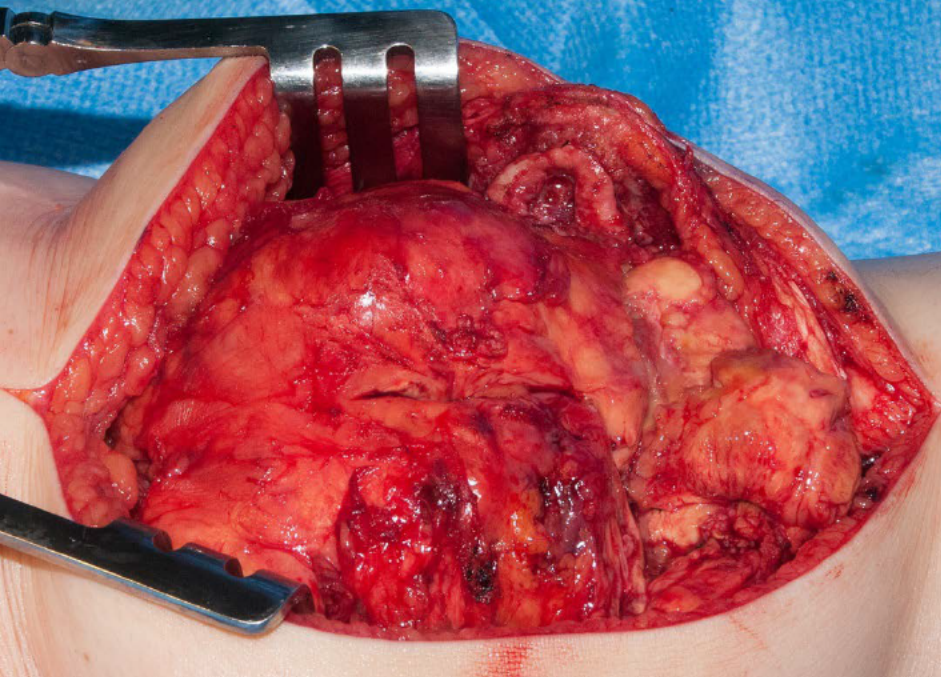




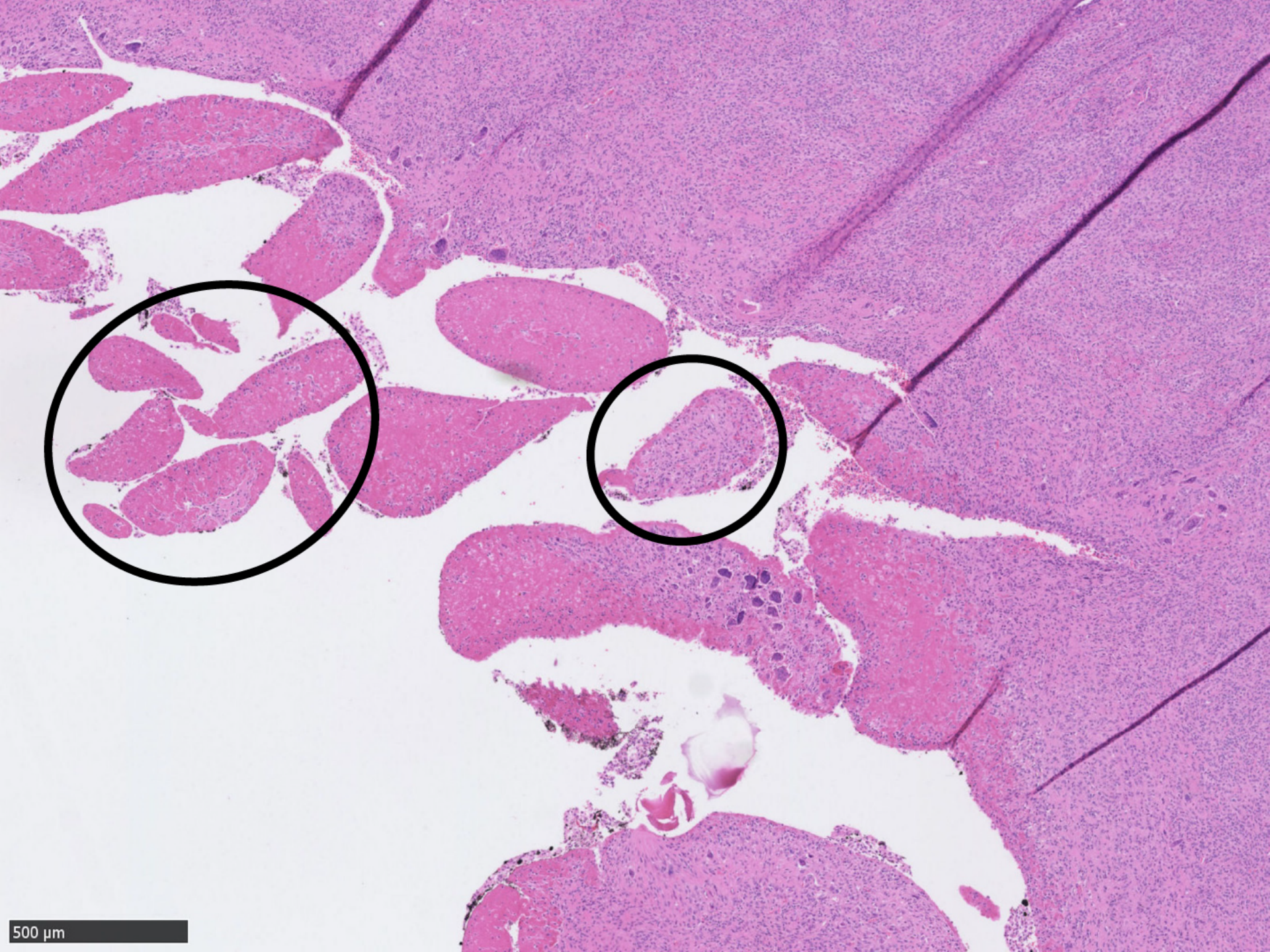






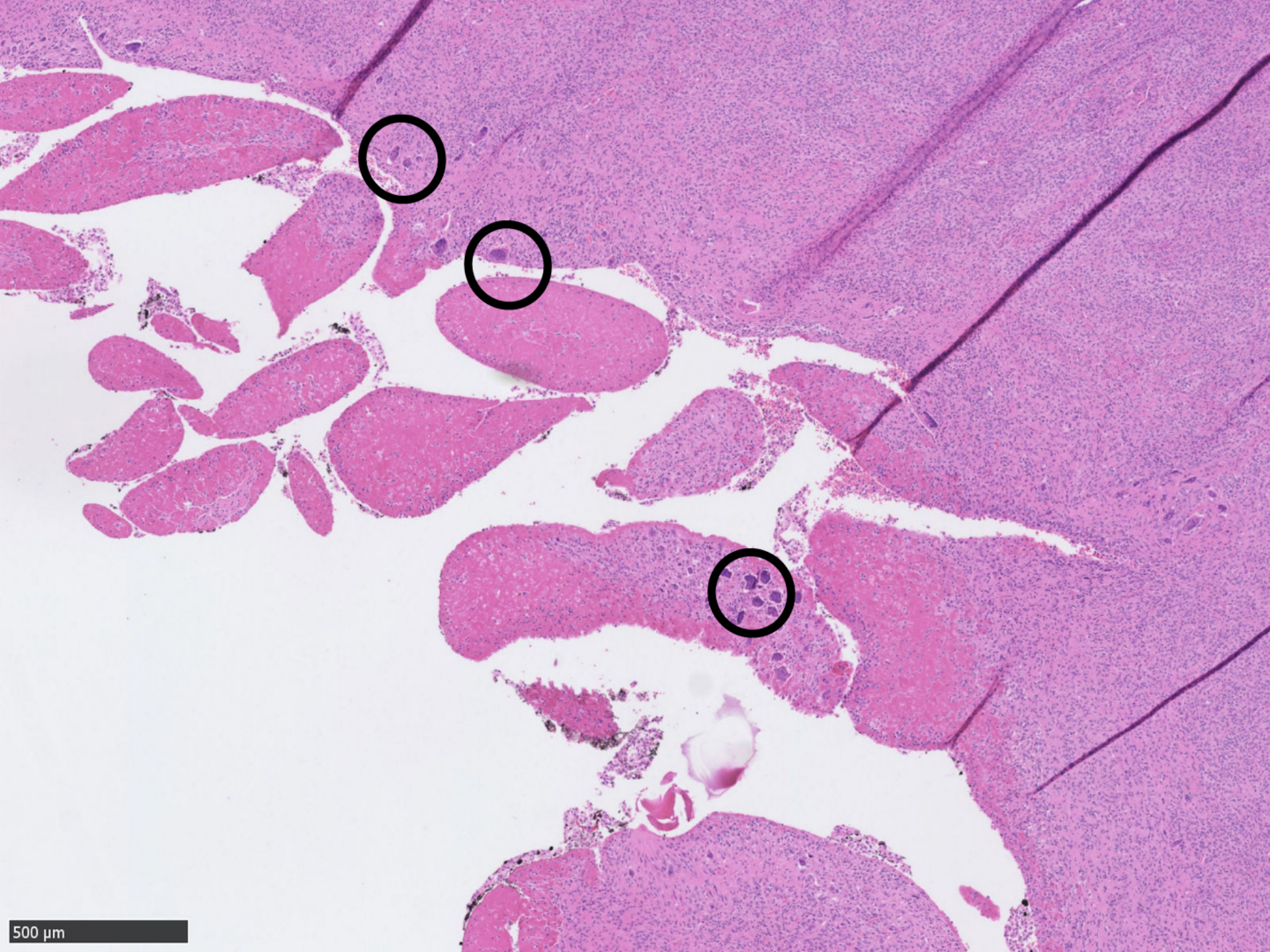






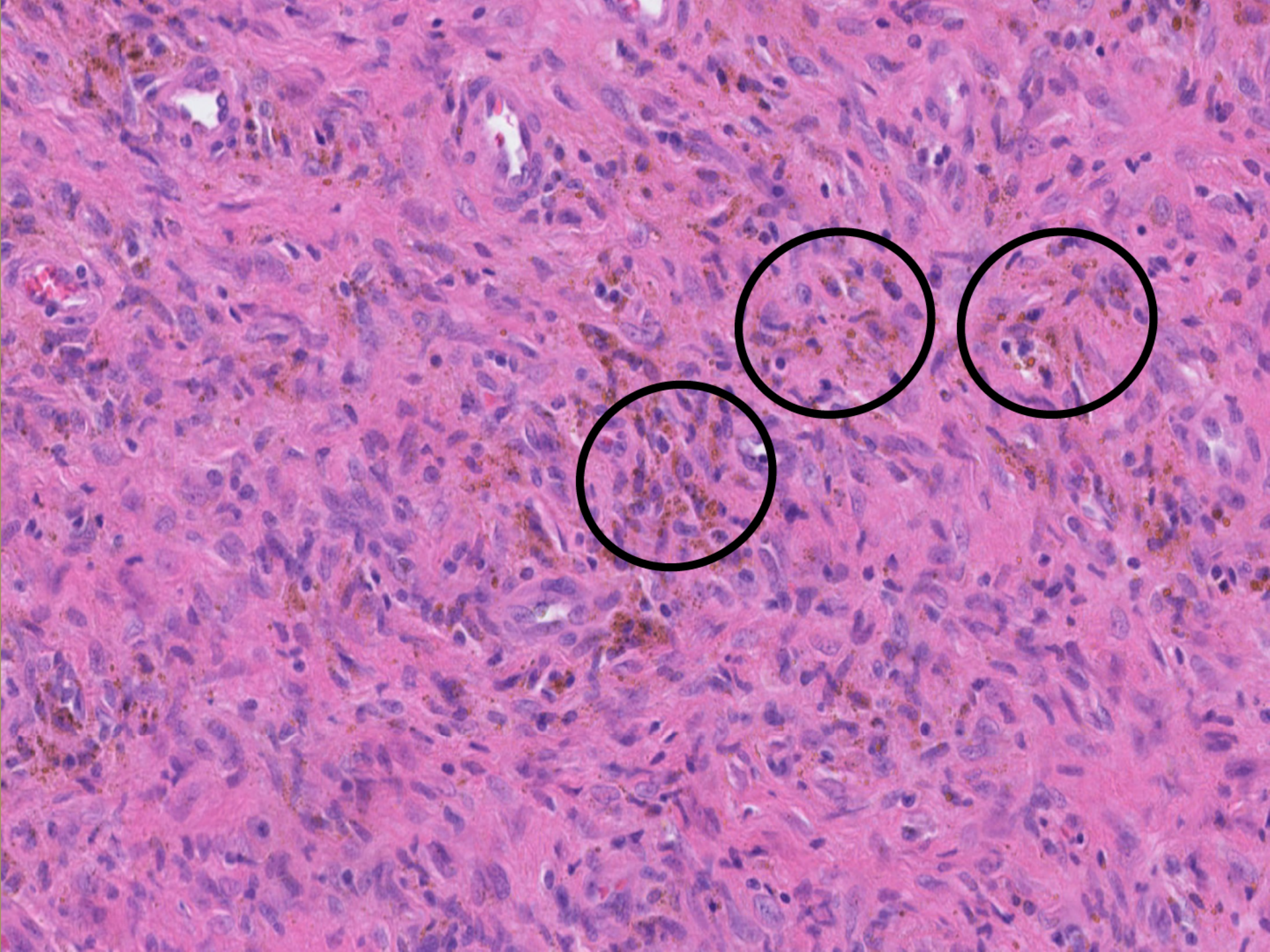500  $\mu$ m





500  $\mu$ m



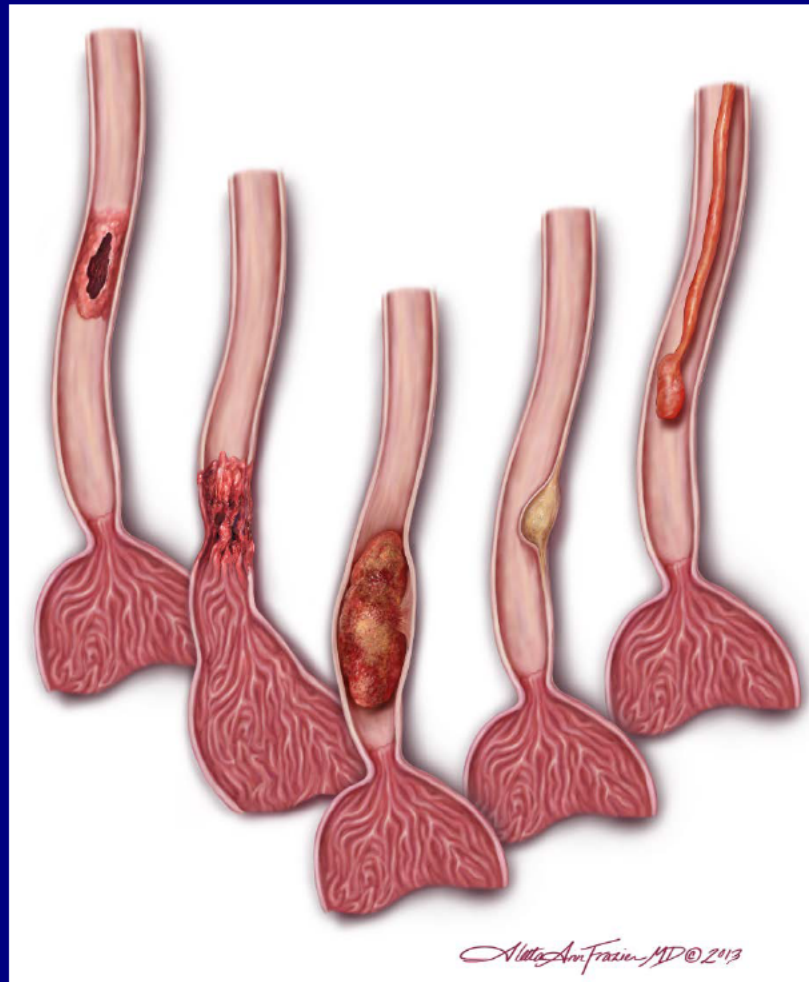

# **Pigmented villonodular synovitis, diffuse type**

**Louis-Gabriel Racine, MD**  
**Laval University**  
**Quebec City, Quebec, Canada**



# Gastrointestinal Best Case



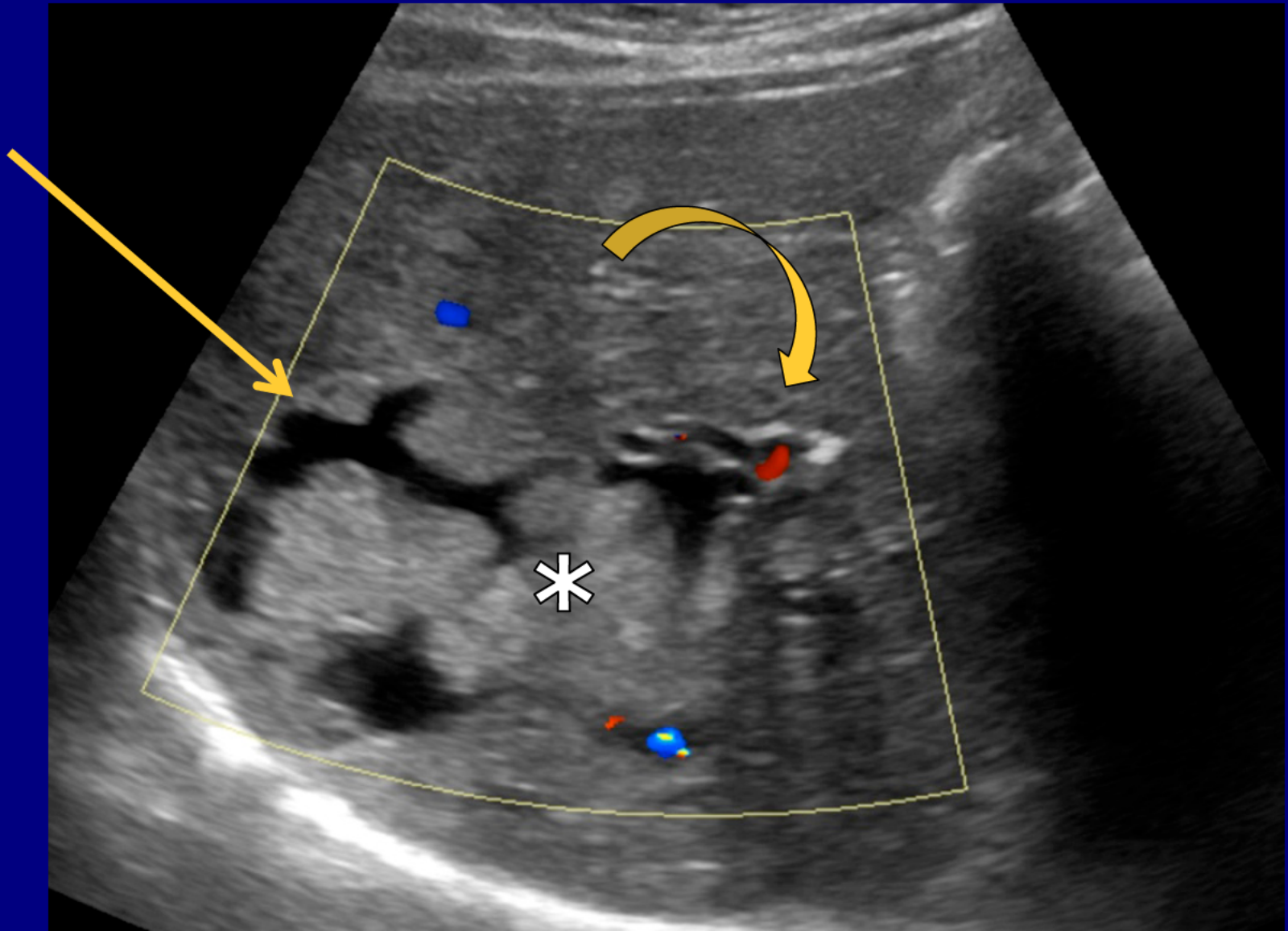


**38 year old female with left lumbar  
pain.**

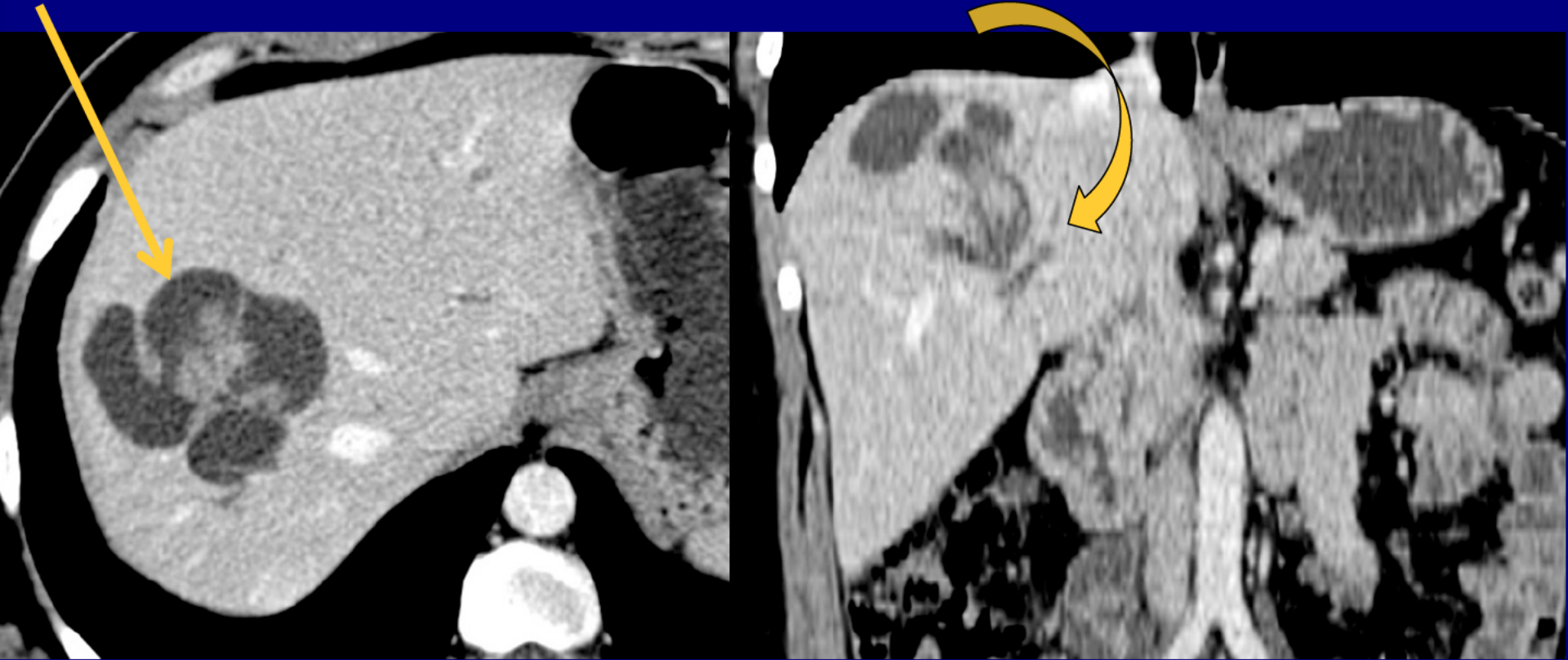
**(-) fever**

**(+) nausea, anorexia**

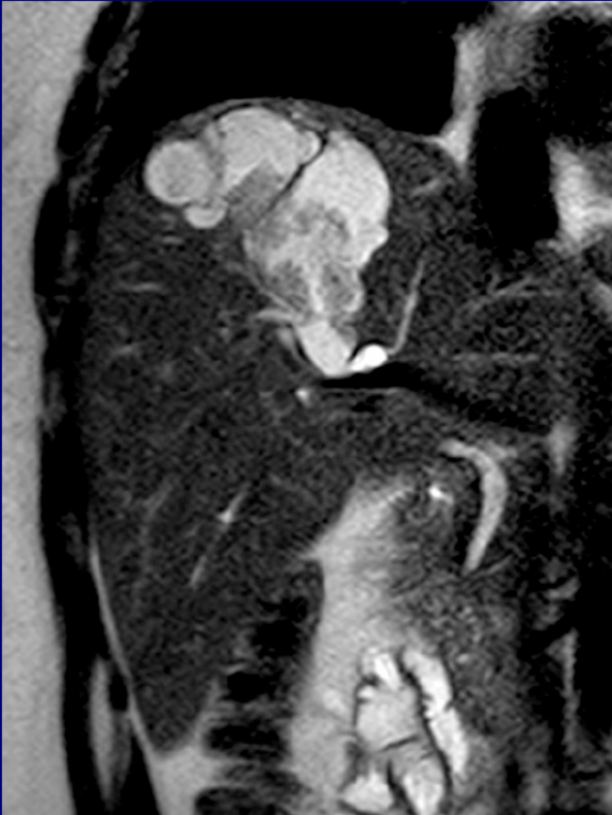
# Ultrasound



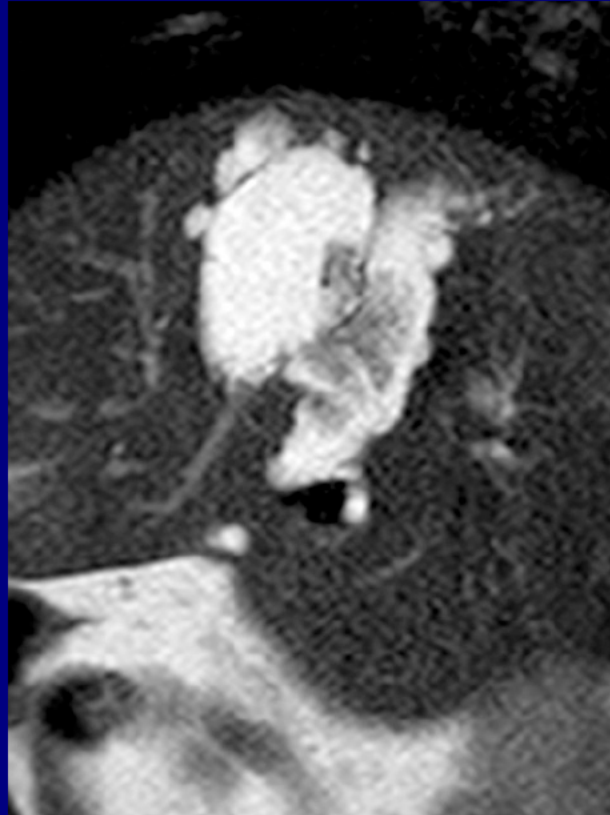
CT



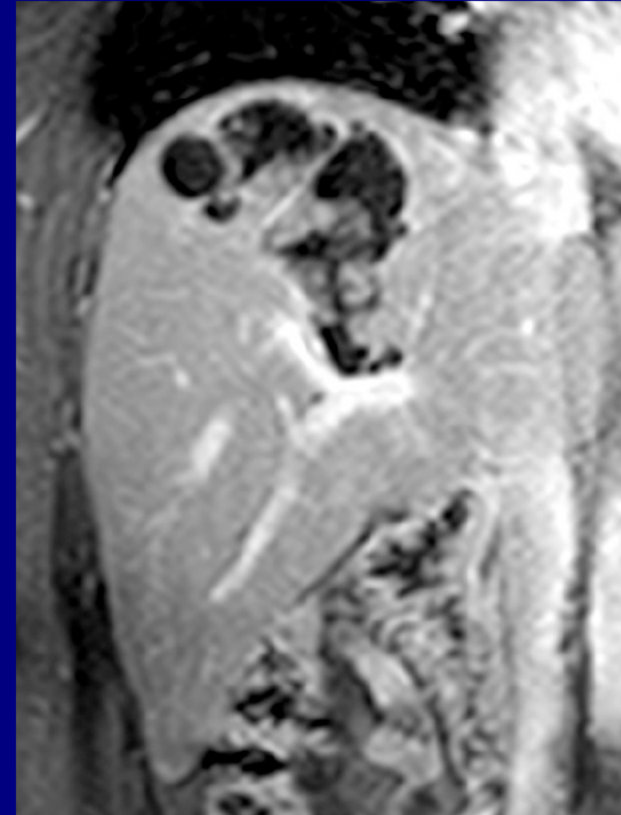
# MR



**T2 HASTE CORONAL**



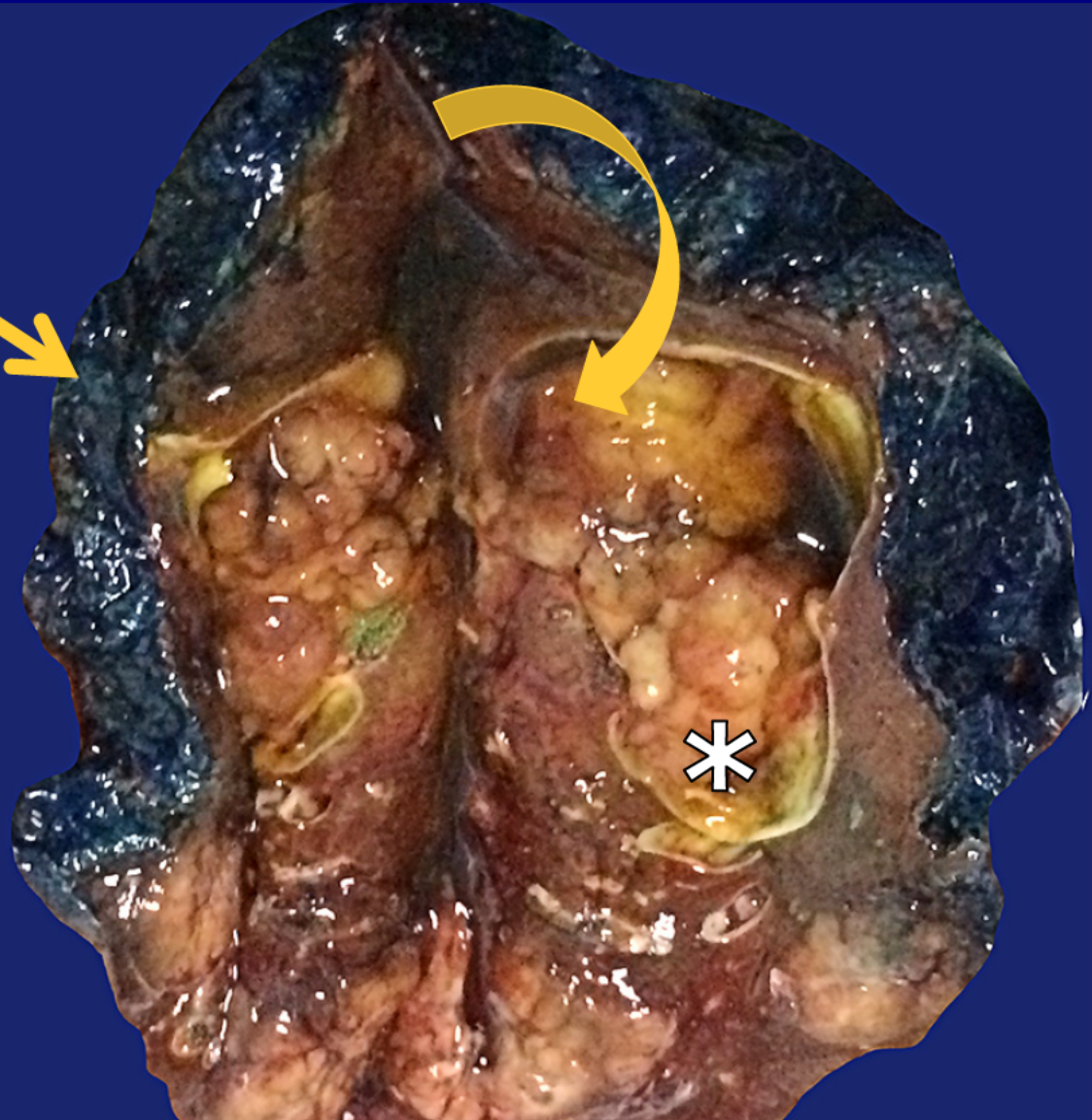
**T2 HASTE SAGITTAL**

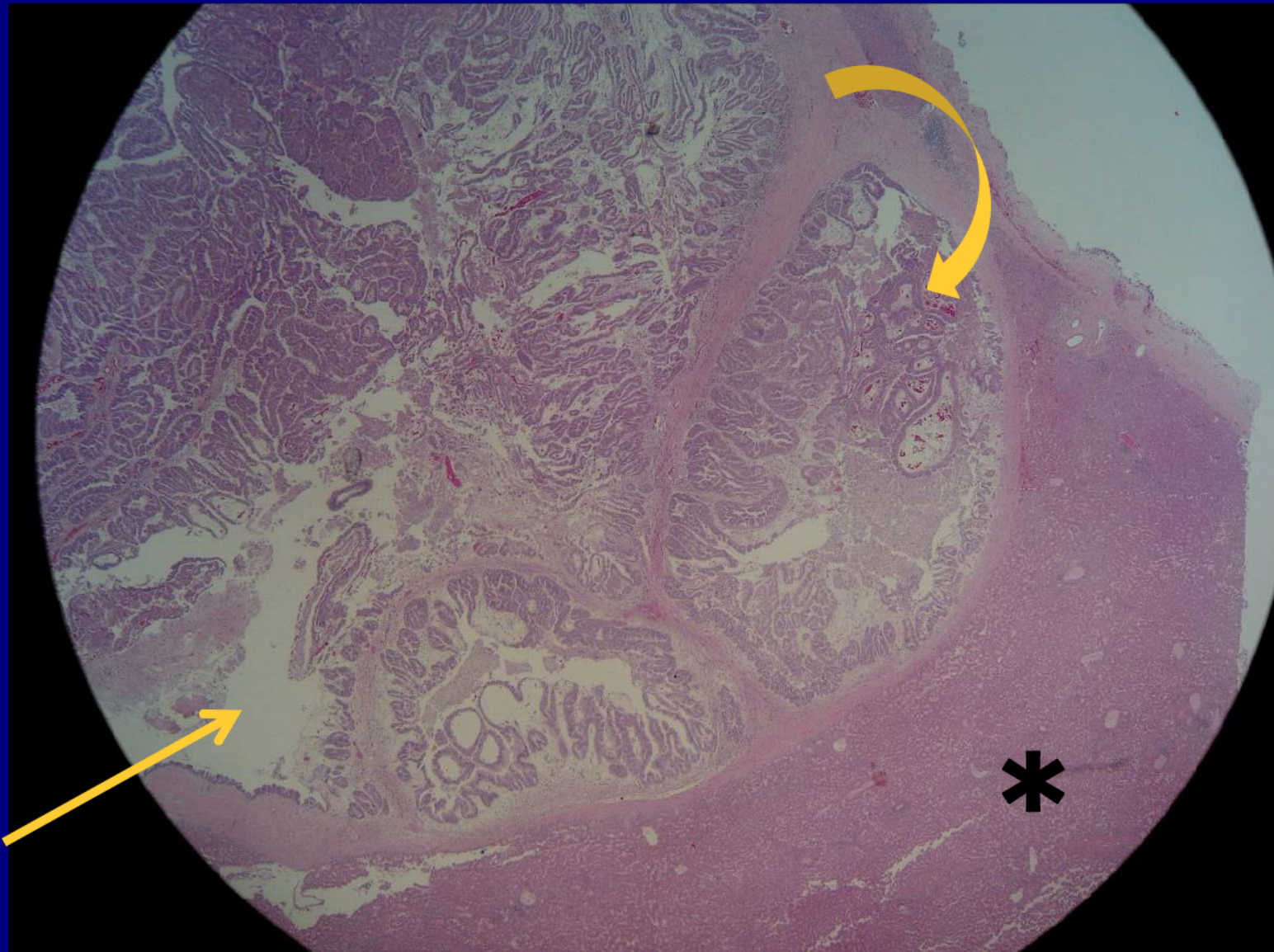


**T1 POST-GD**

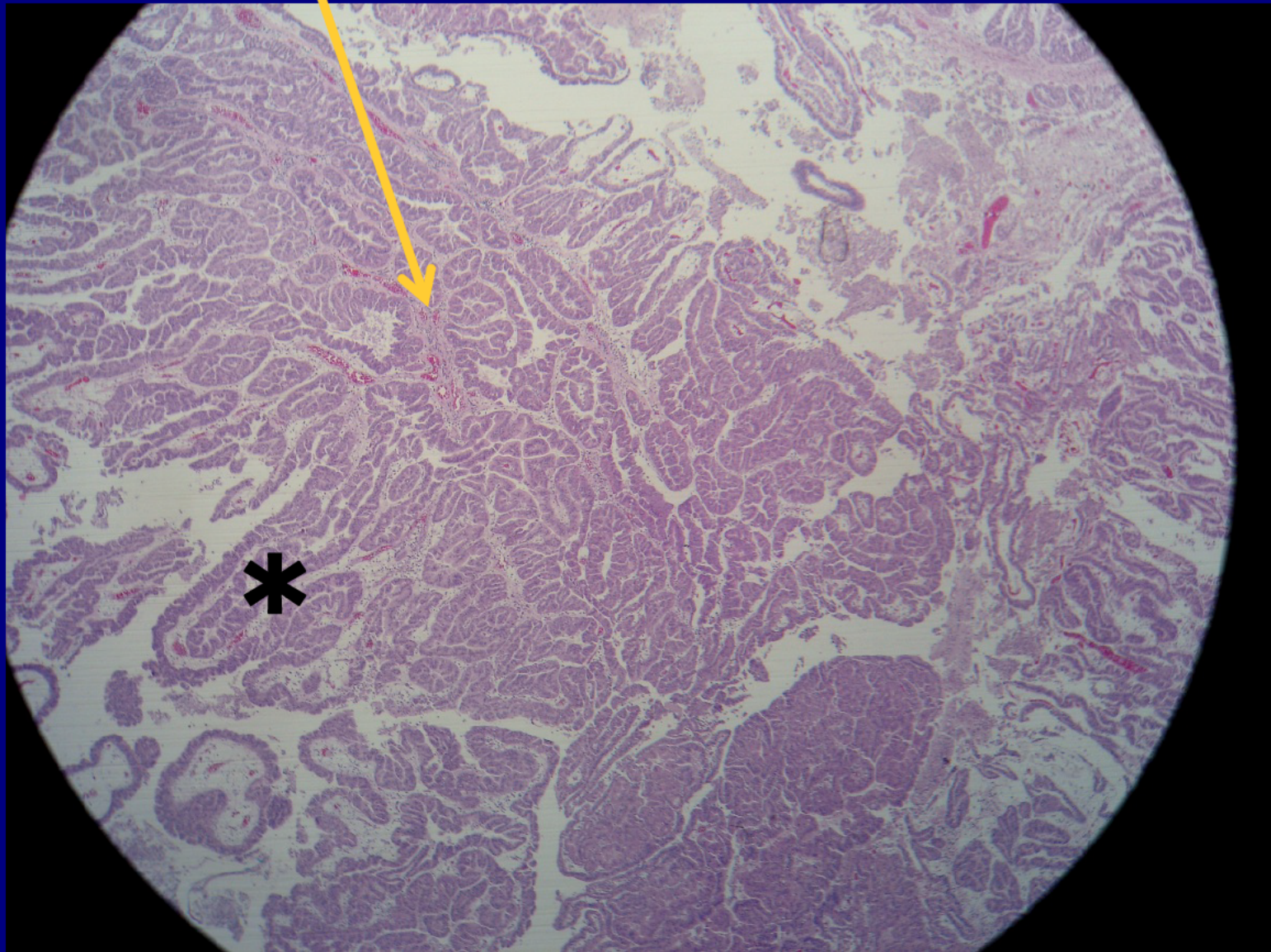


Gross







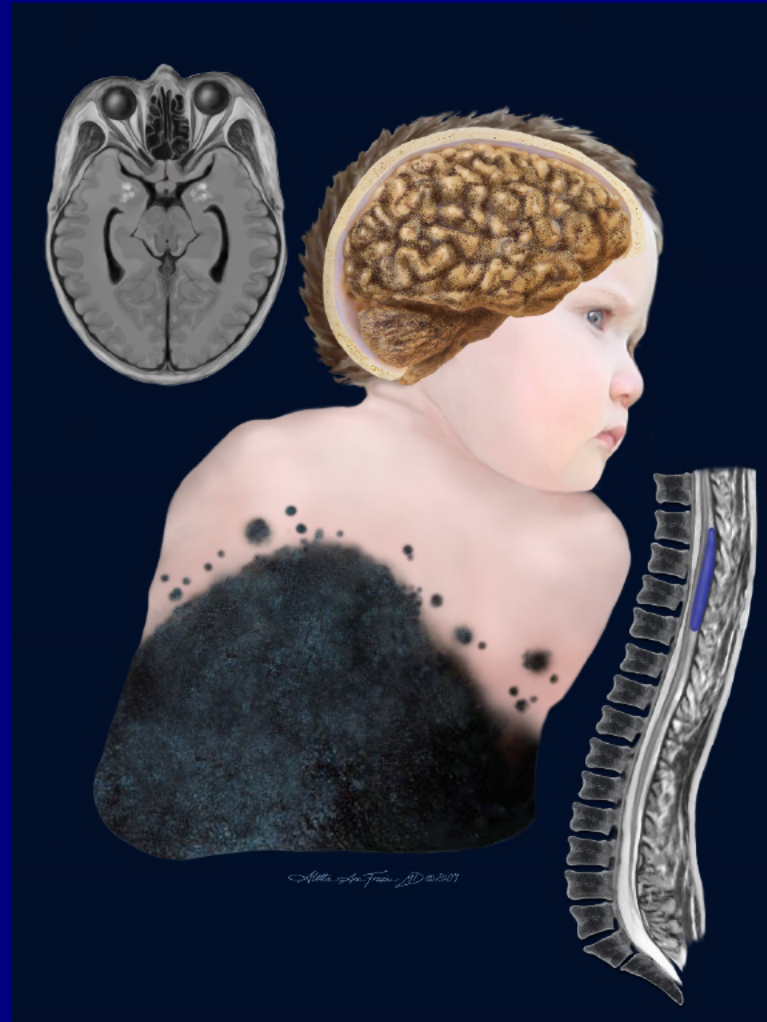

# Intraductal Papillary Mucinous Neoplasm of the Bile Ducts (IPMN-BD)

**Francisco Carrasco, MD**  
**Universidad De Los Andes**  
**Santiago, Chile**

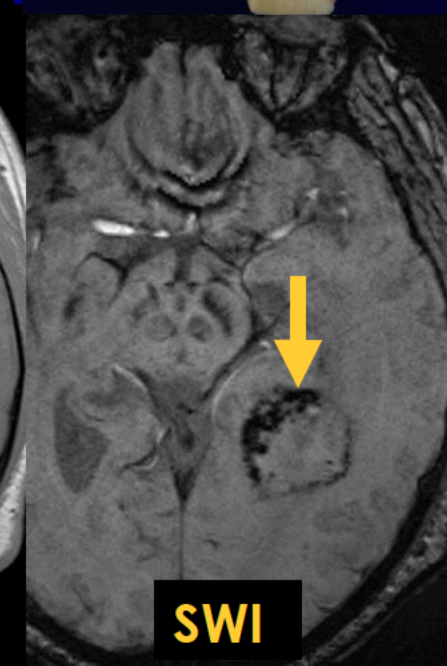
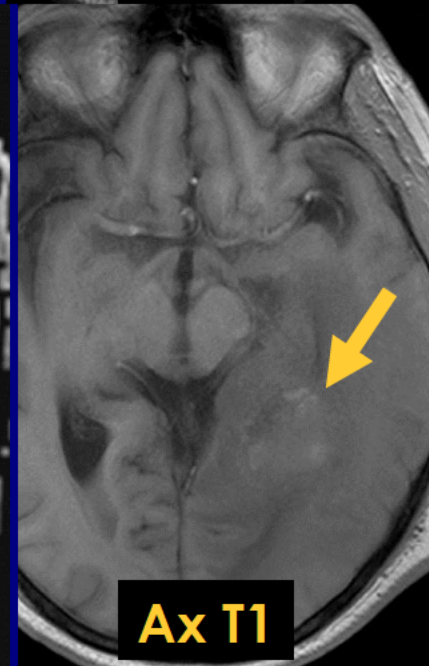
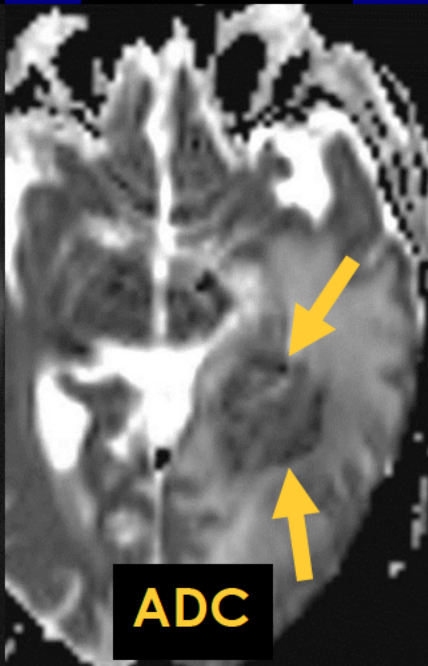
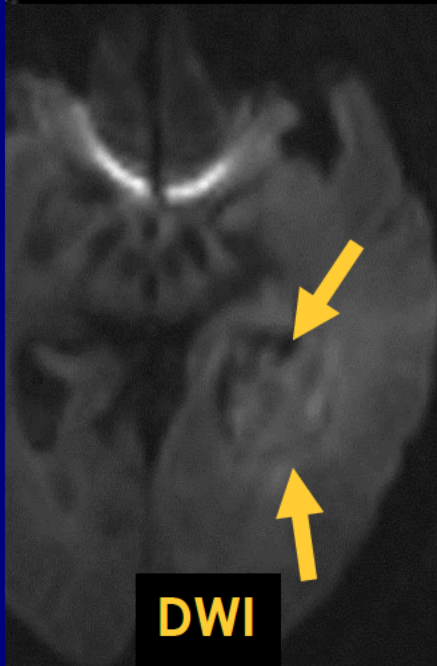
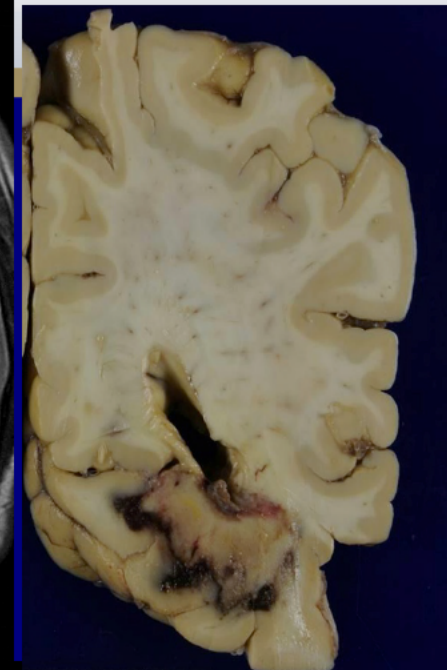
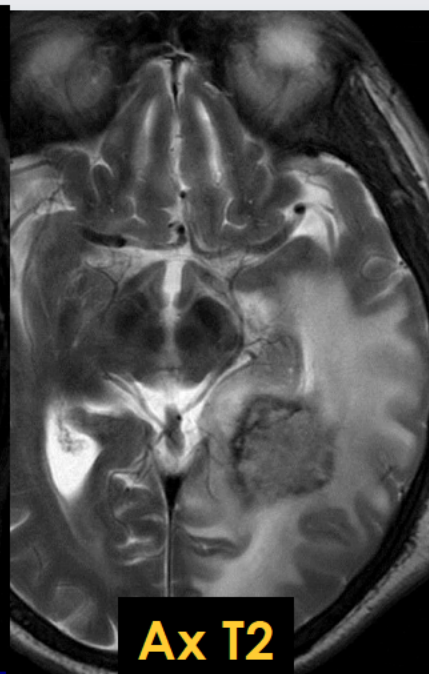
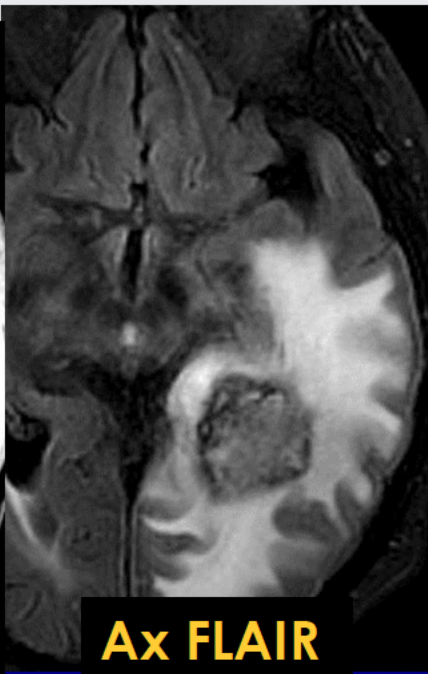
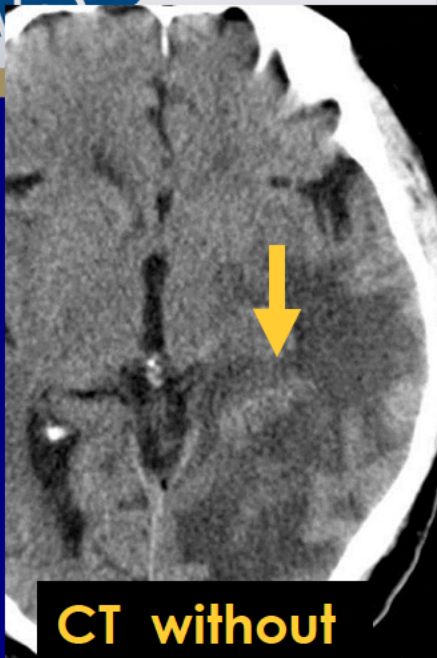


# Neuroradiology Best Case

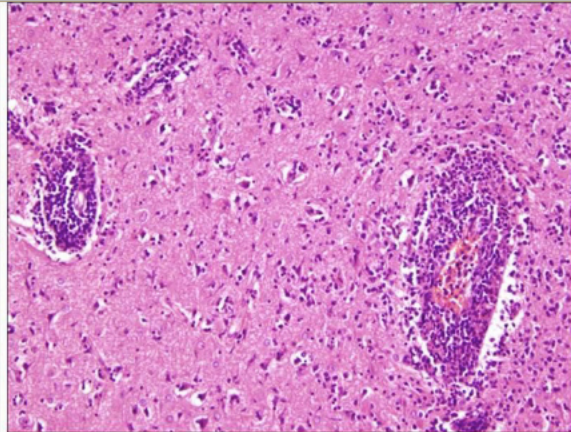
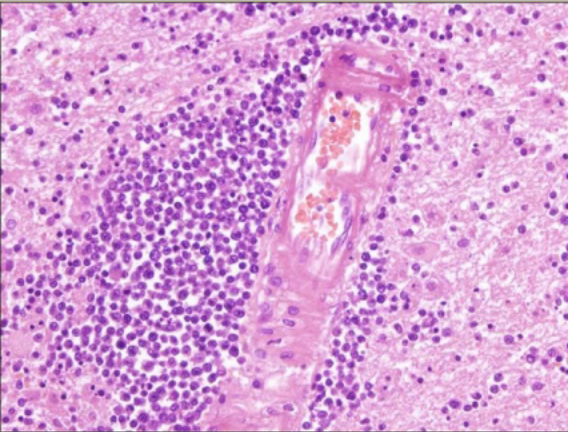


**69-year-old immunosuppressed male with  
acute superimposed increasing headache,  
disorientation, and depression**

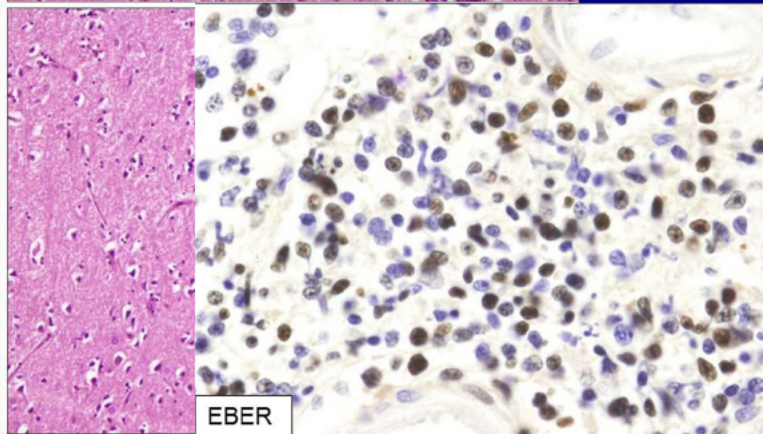
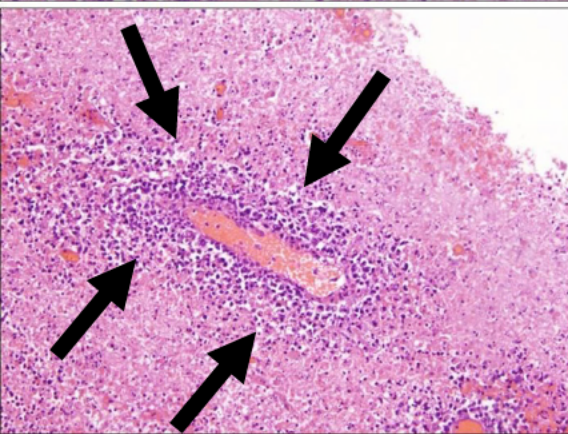




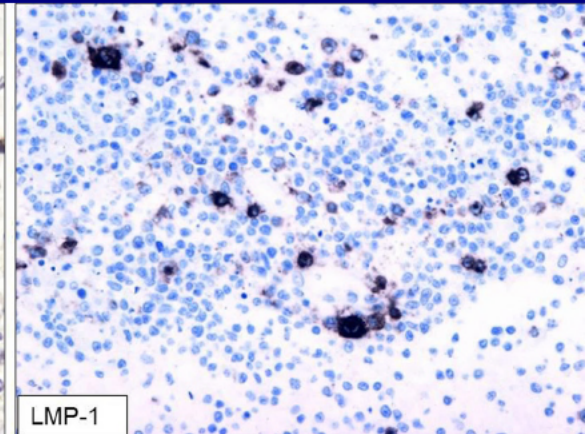




**Special immunohisto  
stains – all positive  
for EBV**

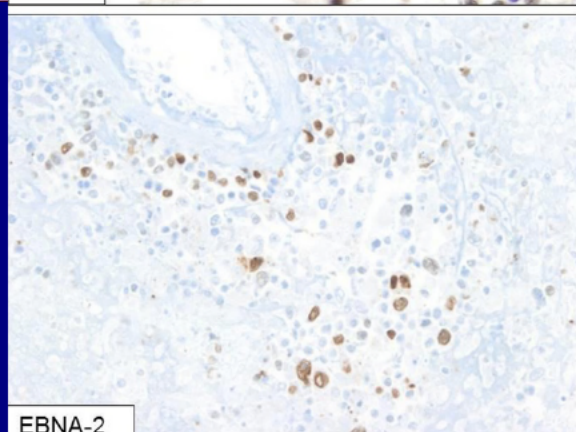


EBER

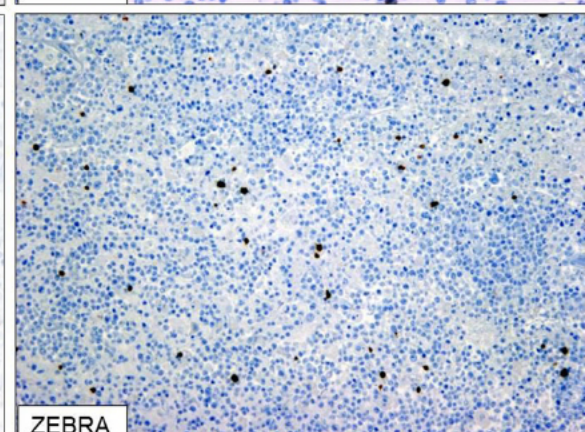


LMP-1

**Numerous  
lymphocytes  
predominating in  
perivascular regions**



EBNA-2



ZEBRA



# CNS Lymphoma

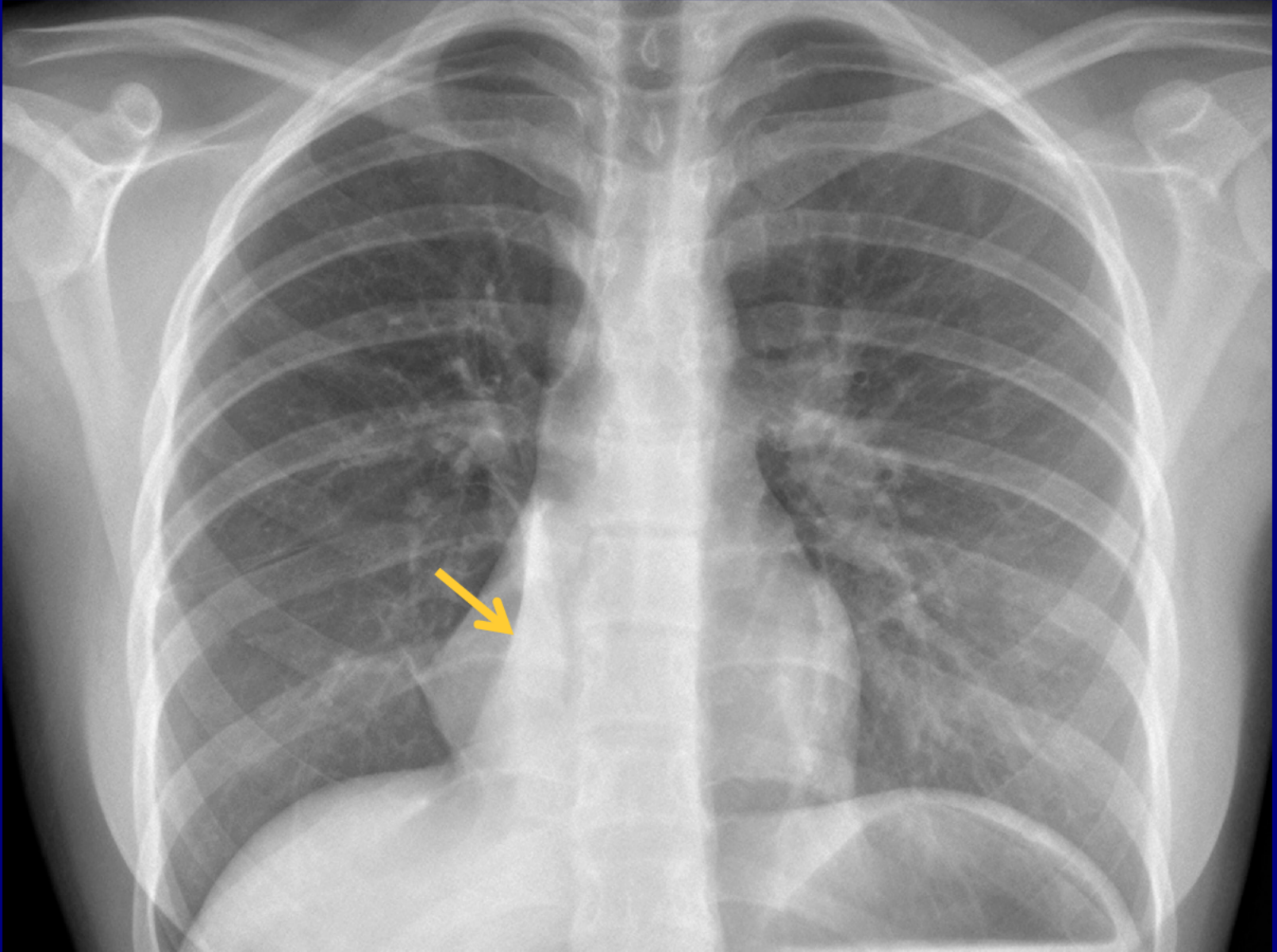
**Enric Ripoli, MD**  
**Hospital Clinic de Barcelona**  
**Barcelona, Spain**





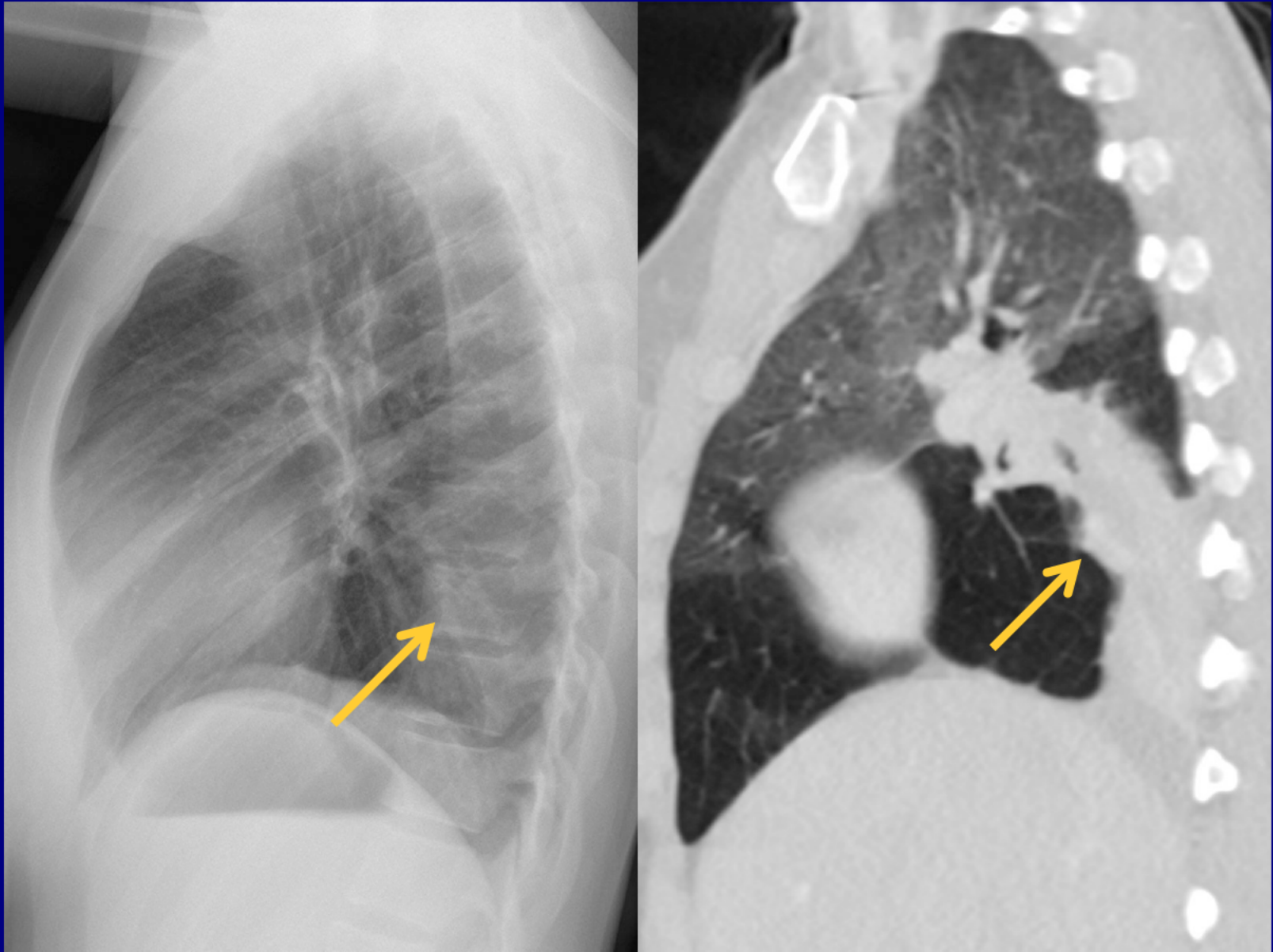
**18 year old female with 10 months  
of intermittent hemoptysis.  
Episodes of flushing, headaches  
and palpitations.**

# Lower lobe collapse

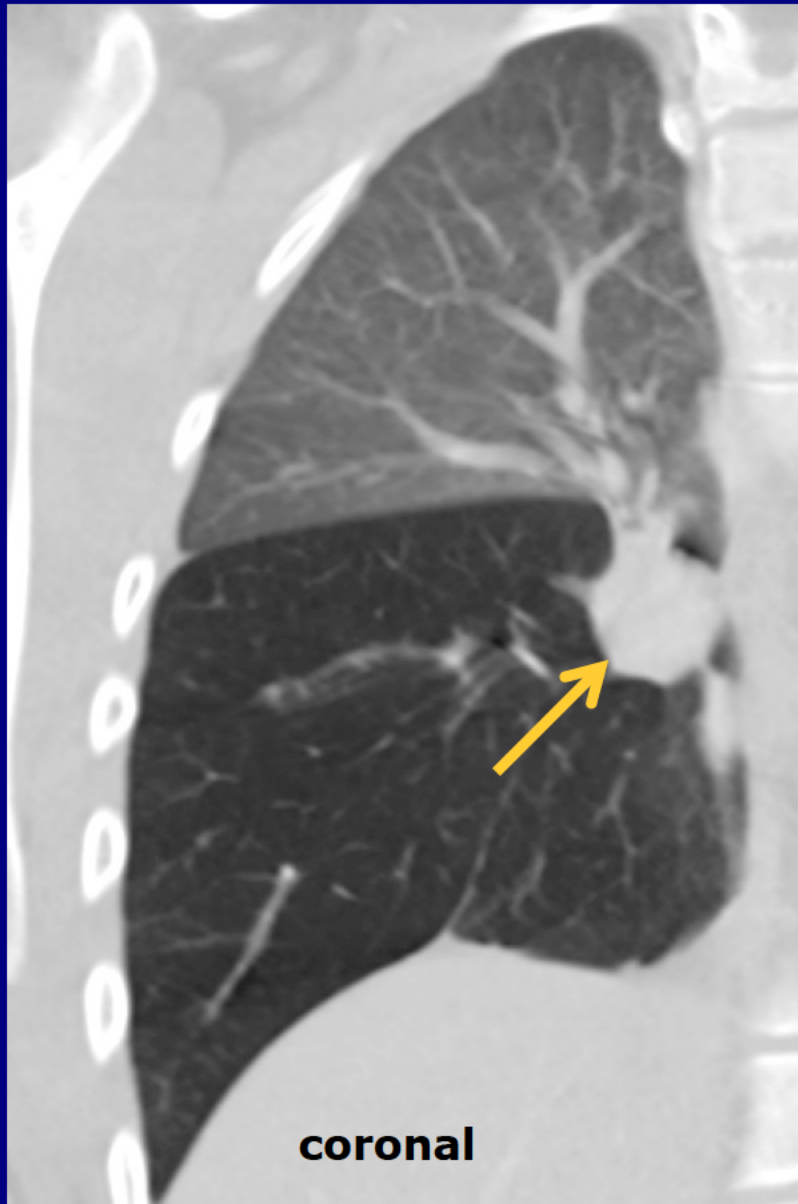




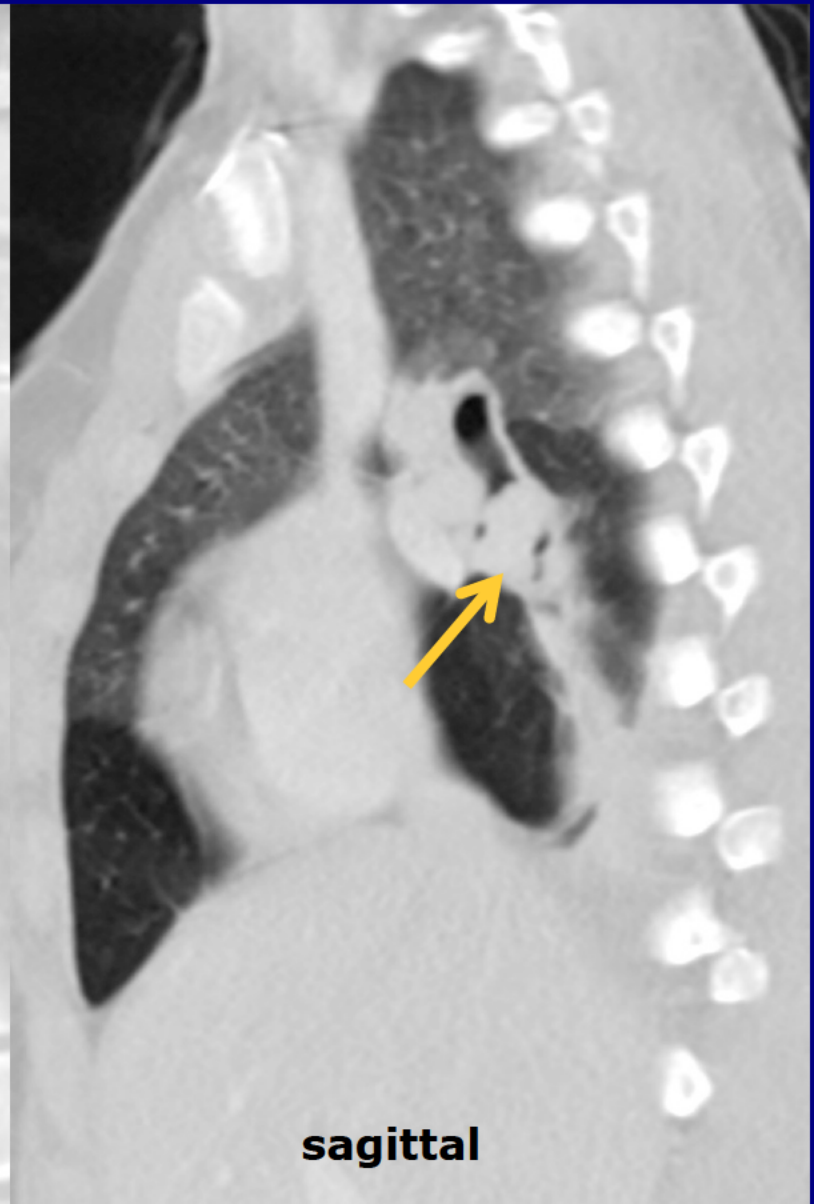# Lower lobe collapse



# Endobronchial nodule

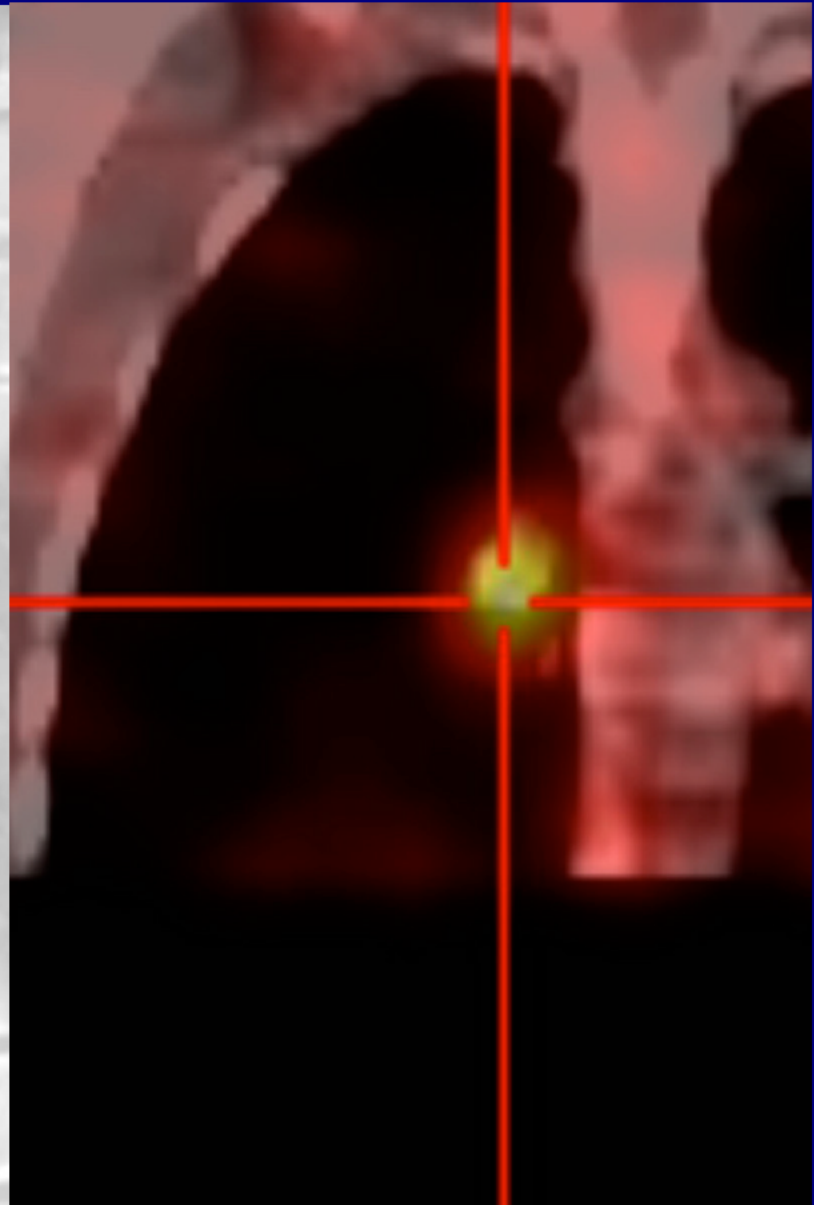
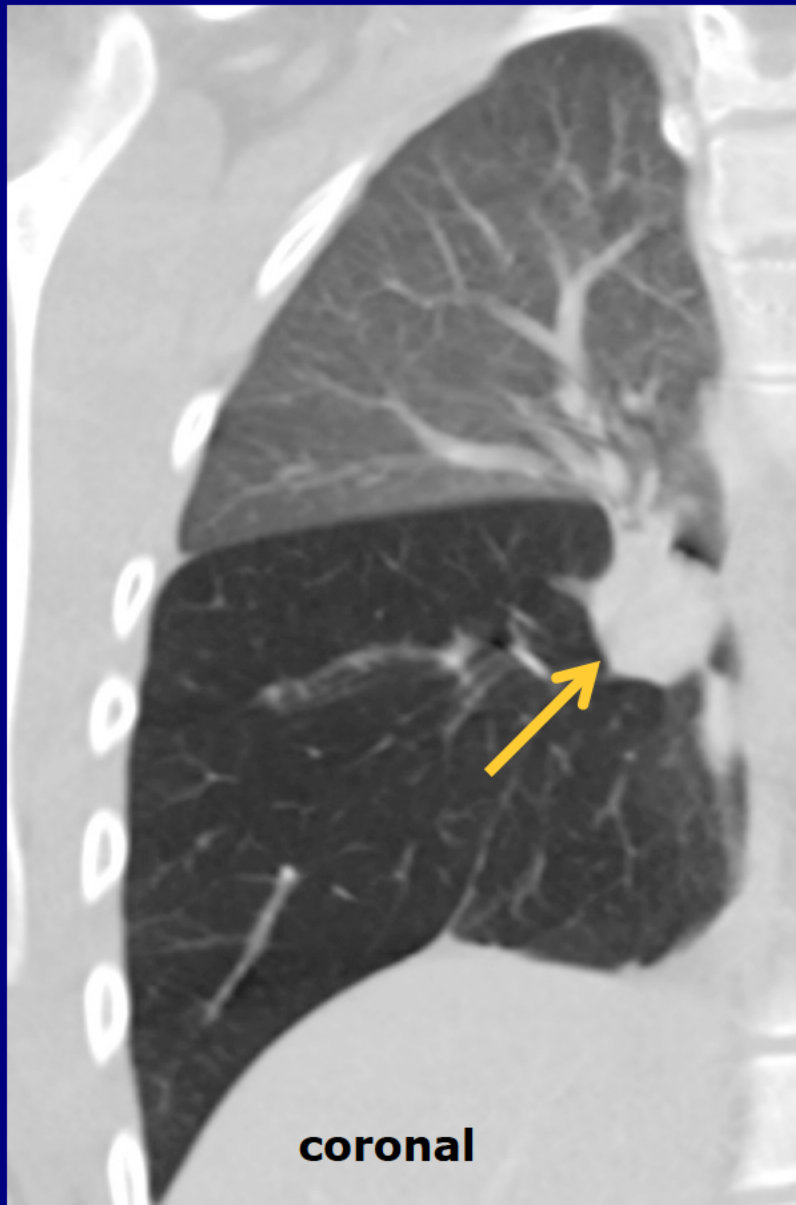

**coronal**

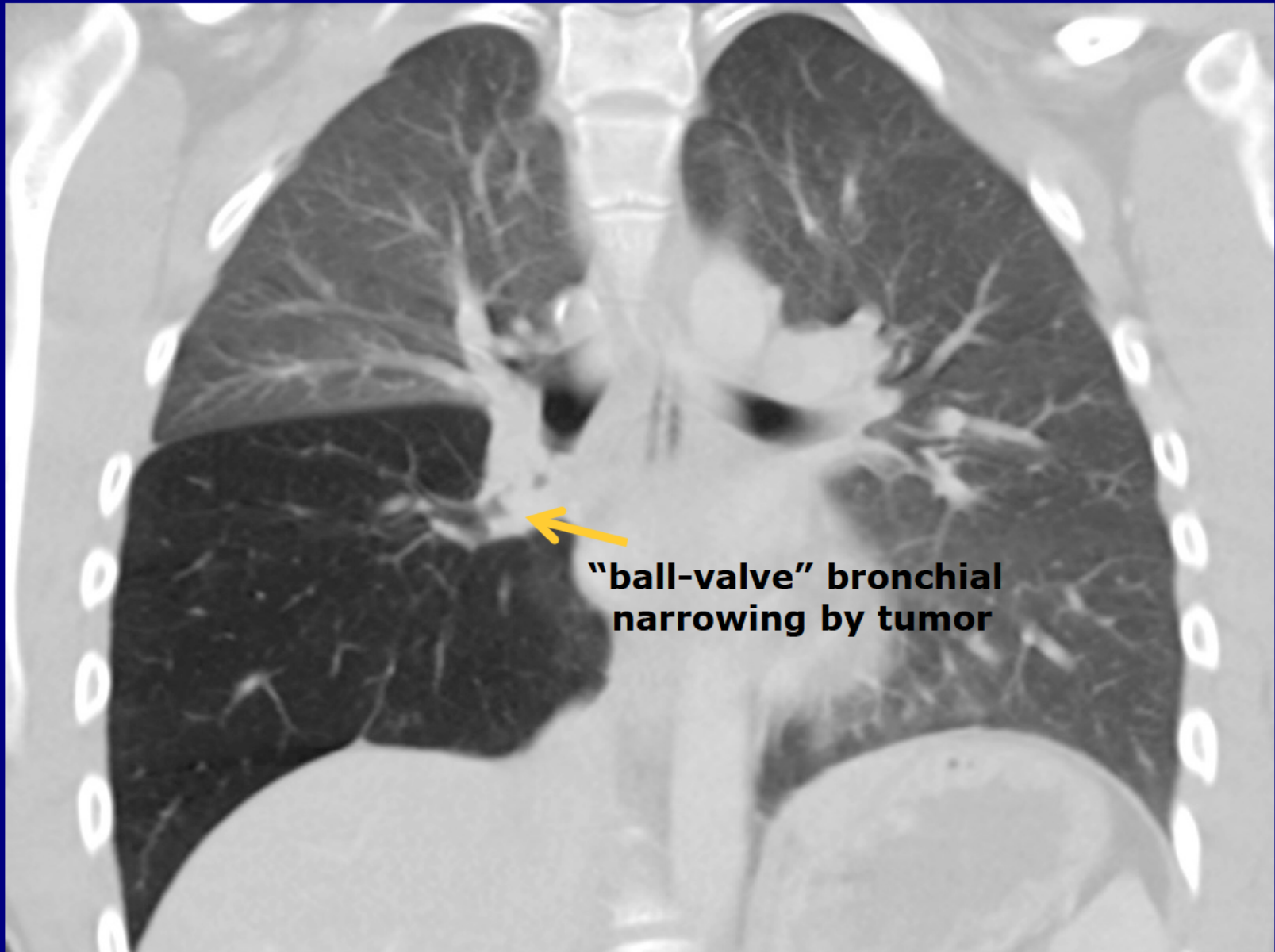


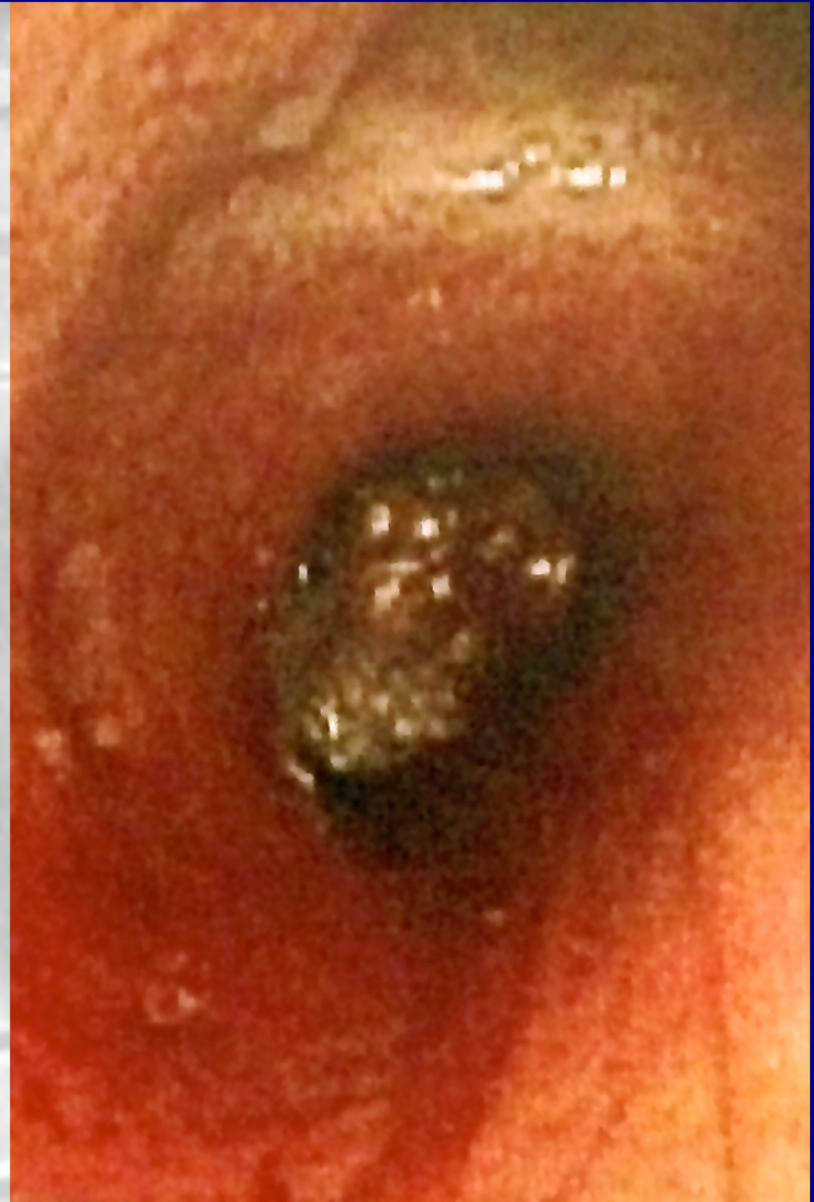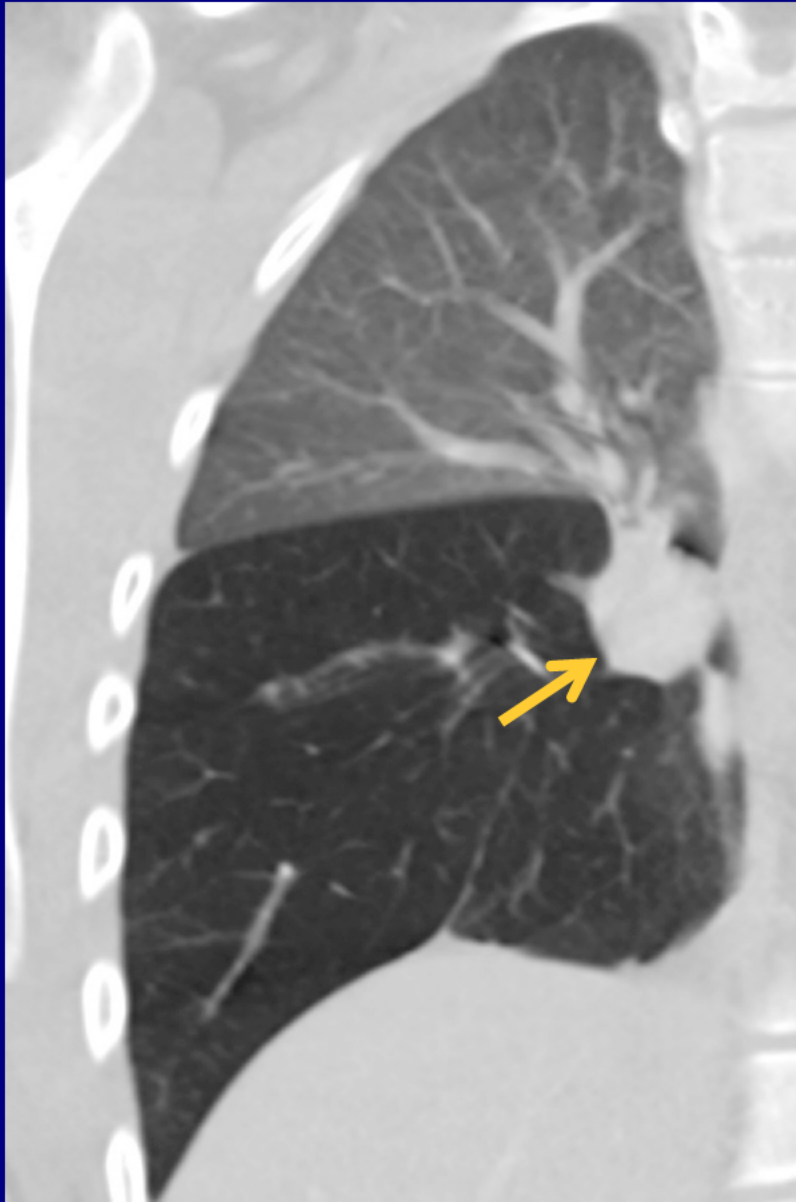**sagittal**





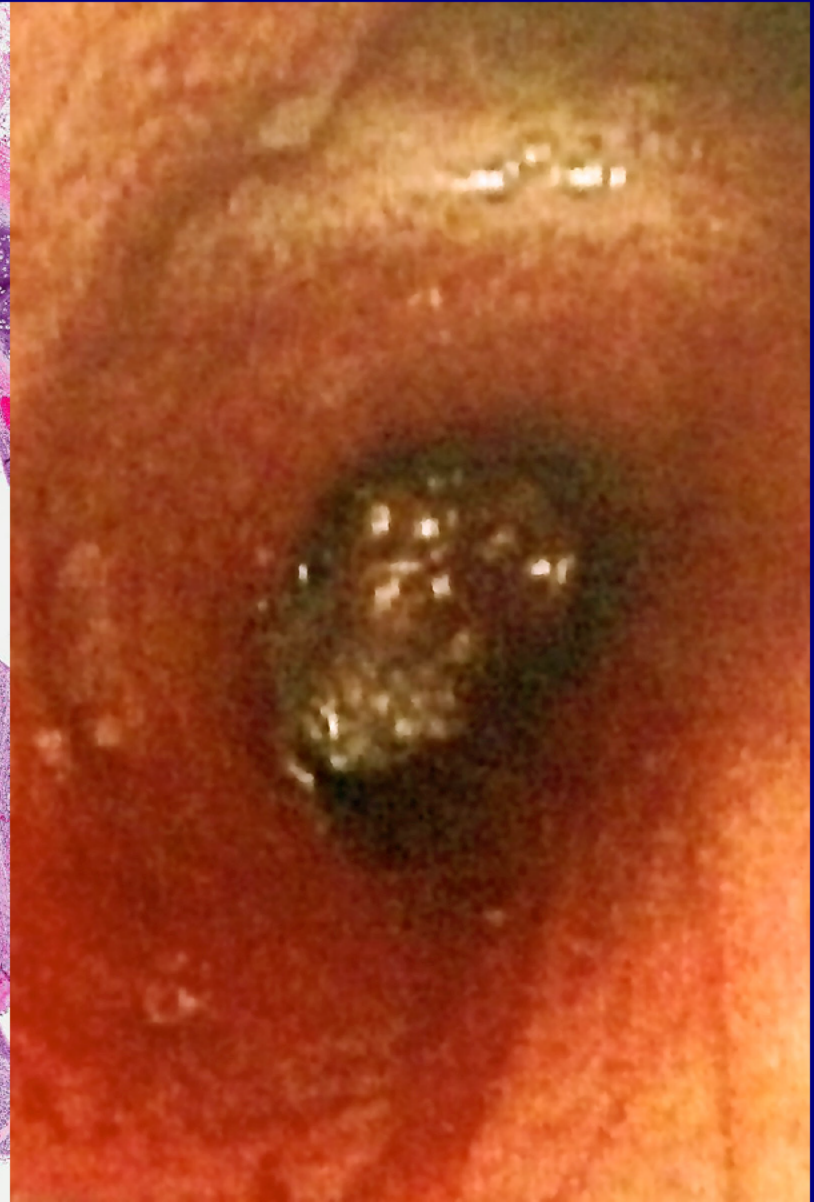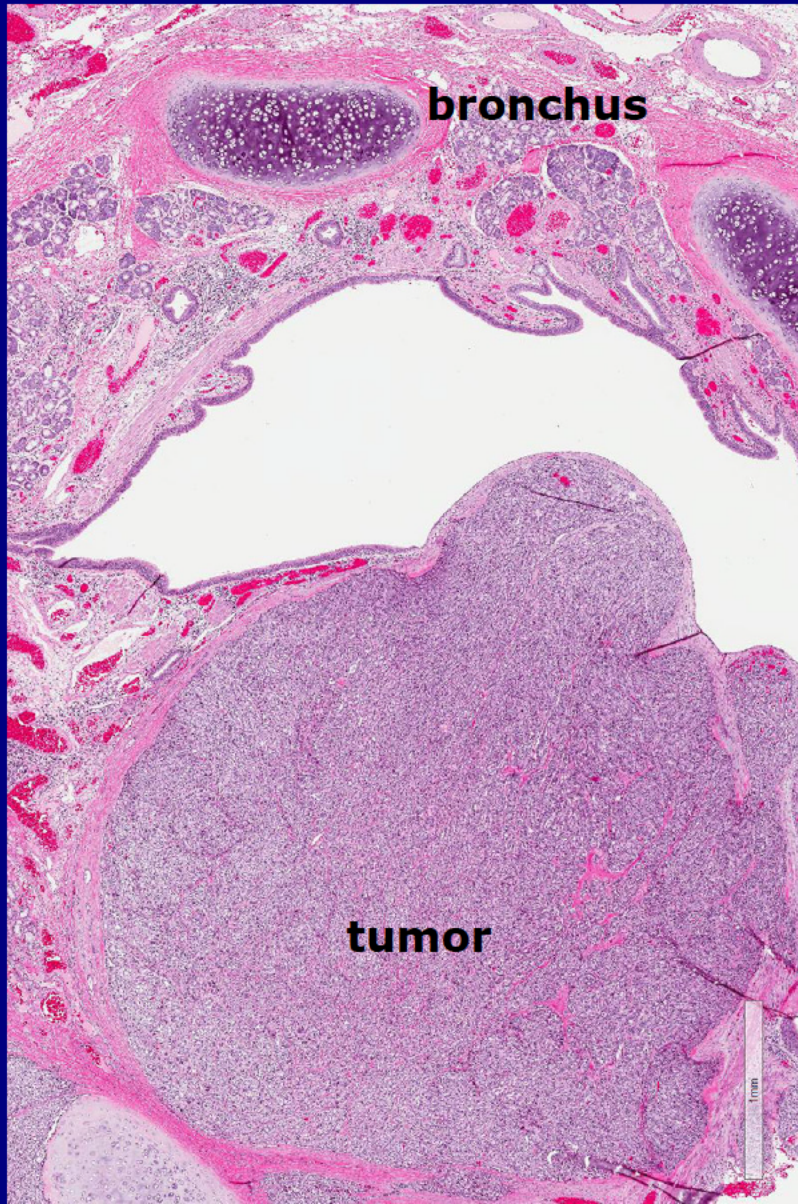
# Hyperinflated middle lobe







# Bronchial Carcinoid



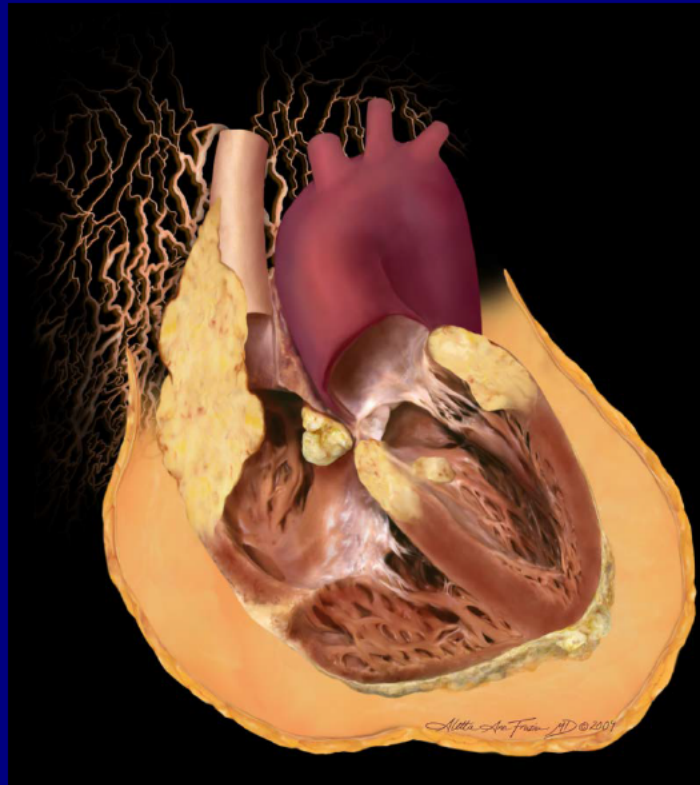# Bronchial Carcinoid

**Melanie Stenback, MD**

**Memorial University of Newfoundland**

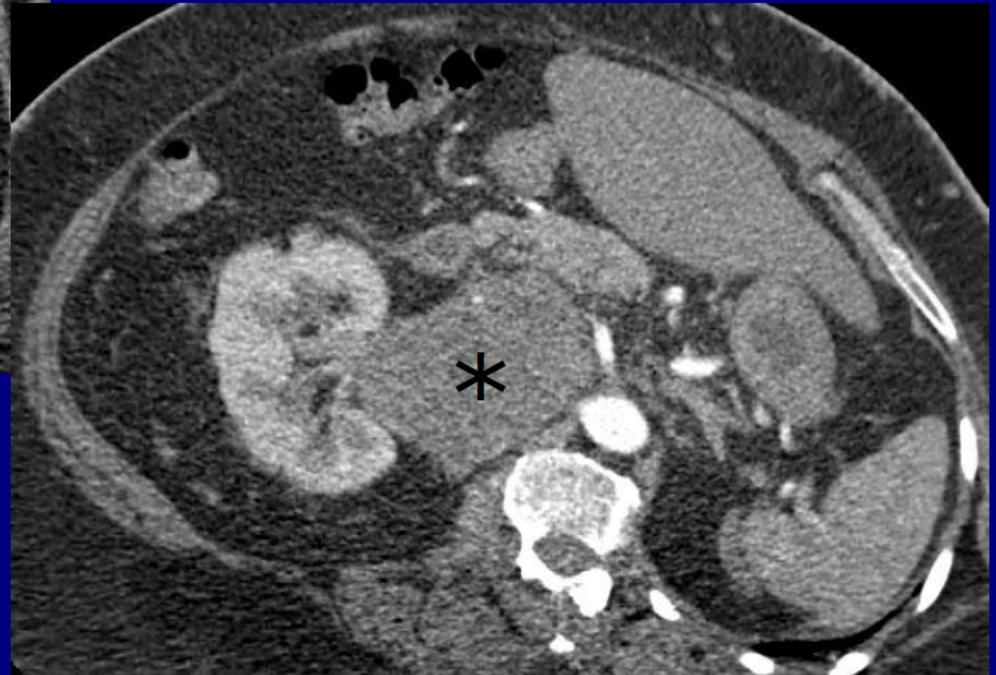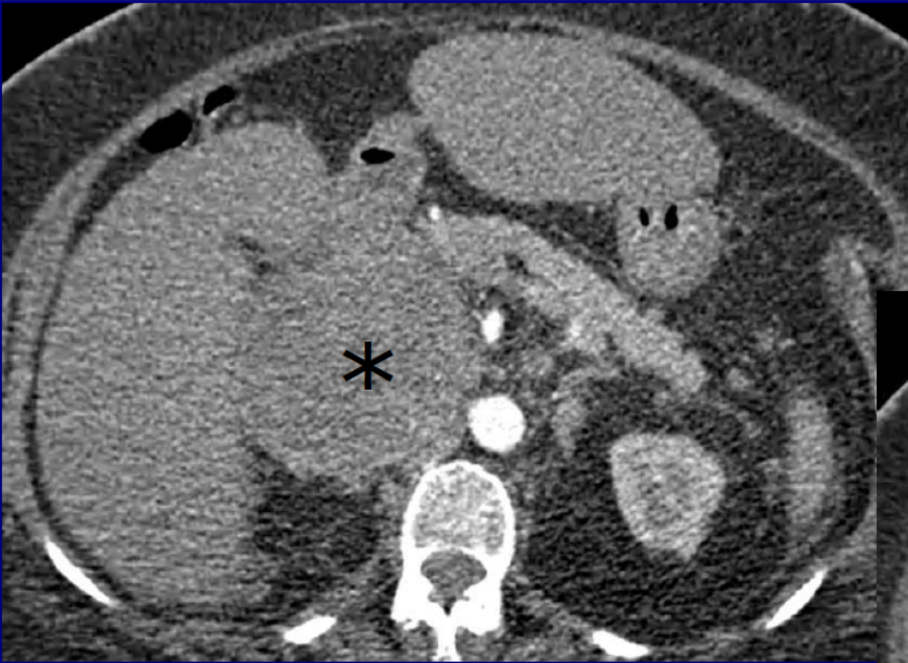**St. John's, Canada**

# Cardiovascular Best Case

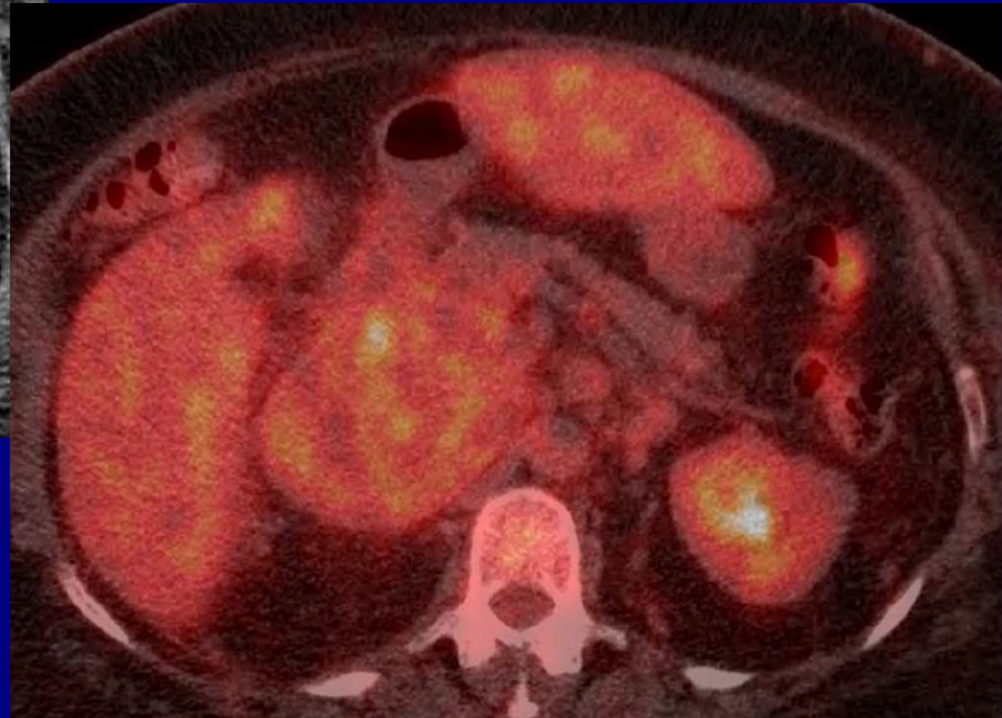
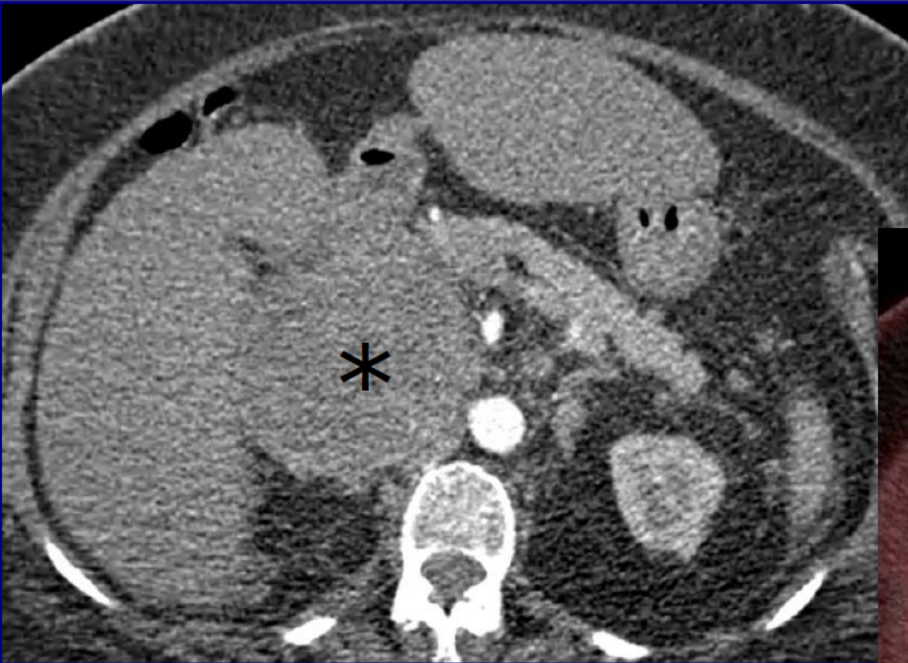



56 year old female with two week  
history of increasing abdominal pain,  
nausea and vomiting

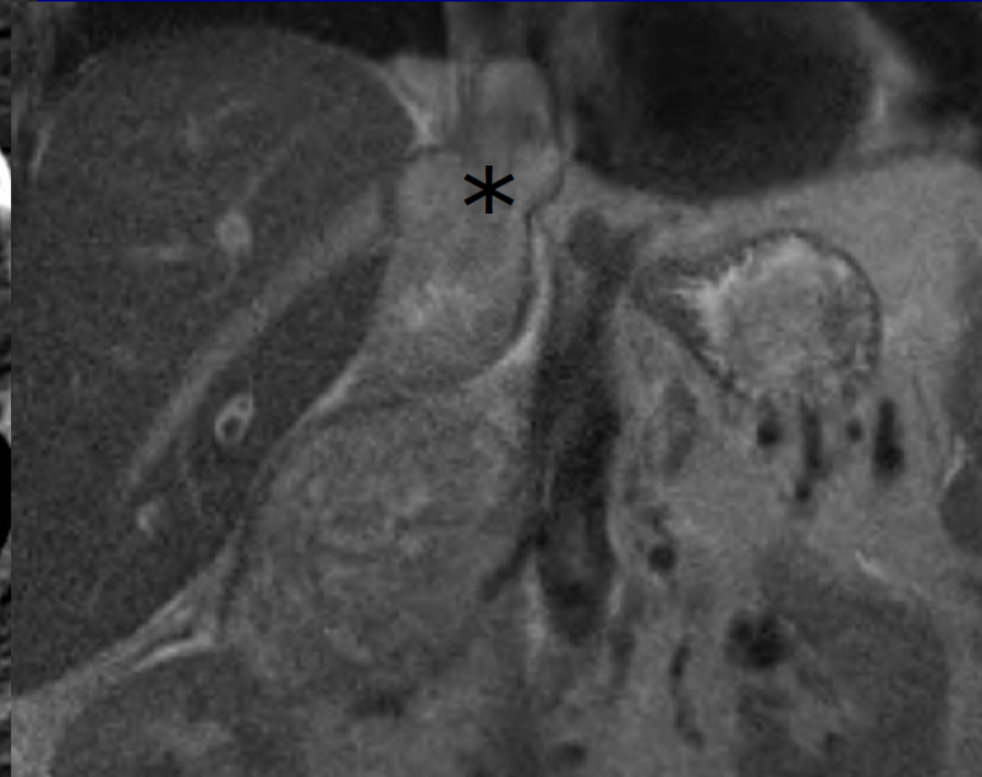
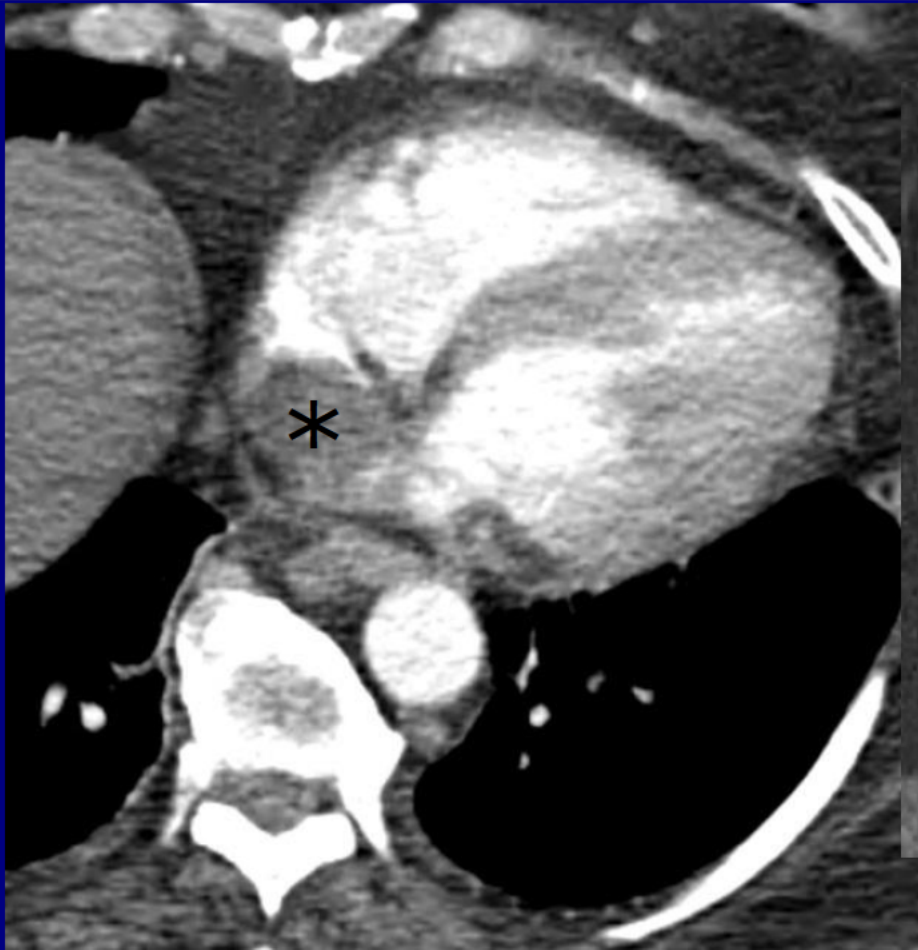

**Post-contrast abdominal CT imaging shows a soft tissue mass filling and expanding the IVC with contiguous invasion of the right renal vein.**



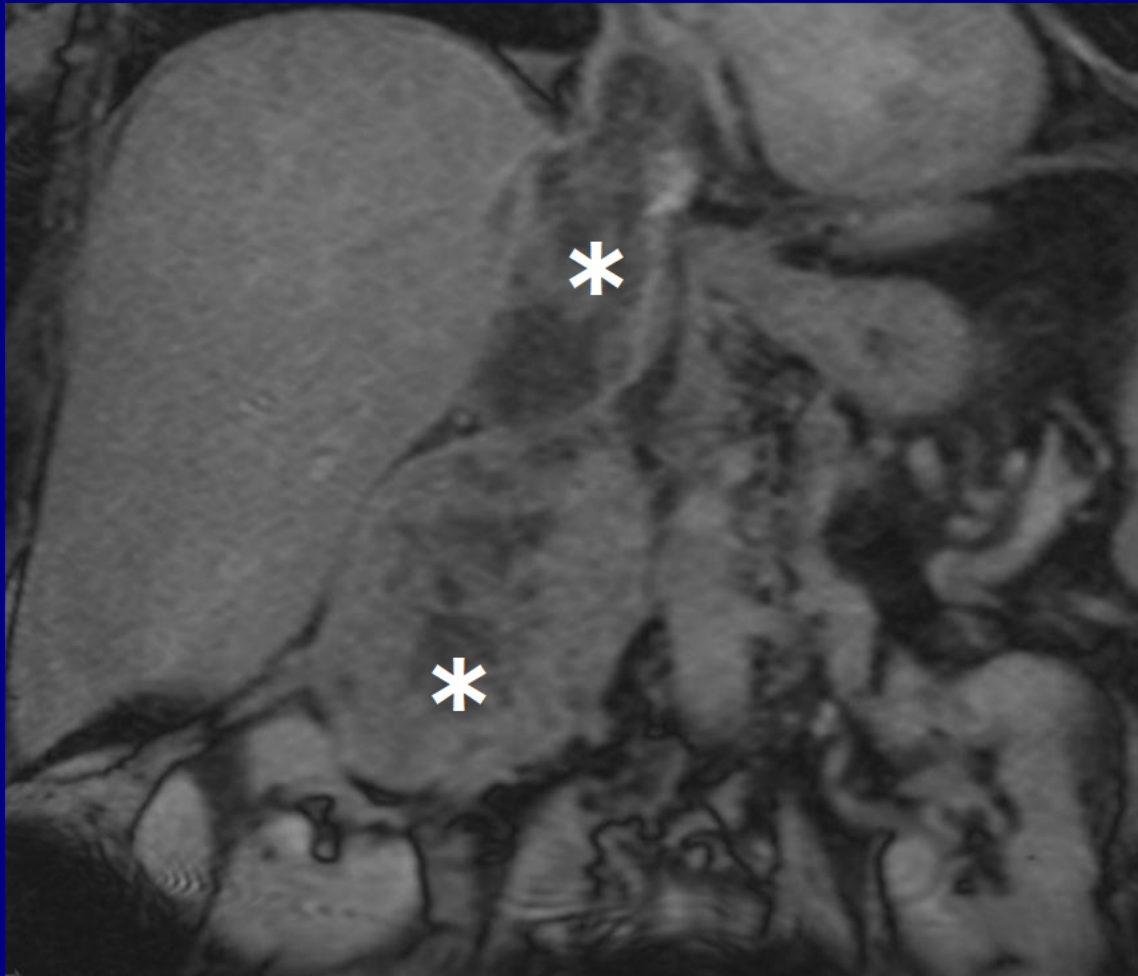
**PET-FDG fused CT image shows moderate FDG uptake within the IVC mass, slightly greater than blood pool.**





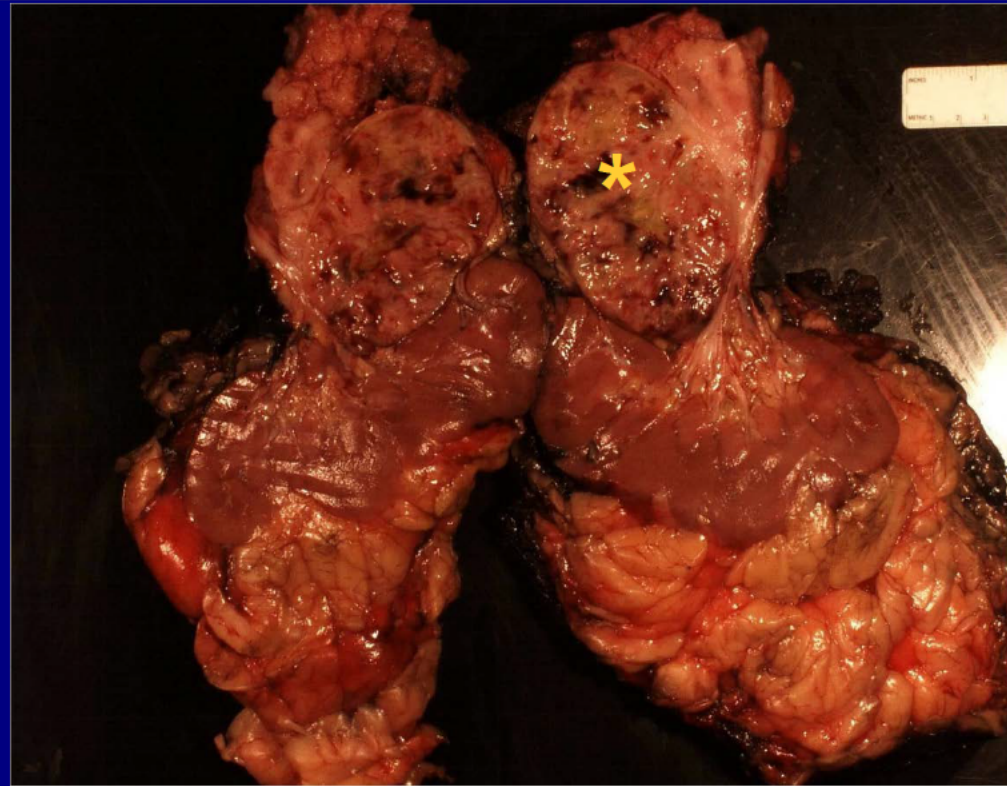
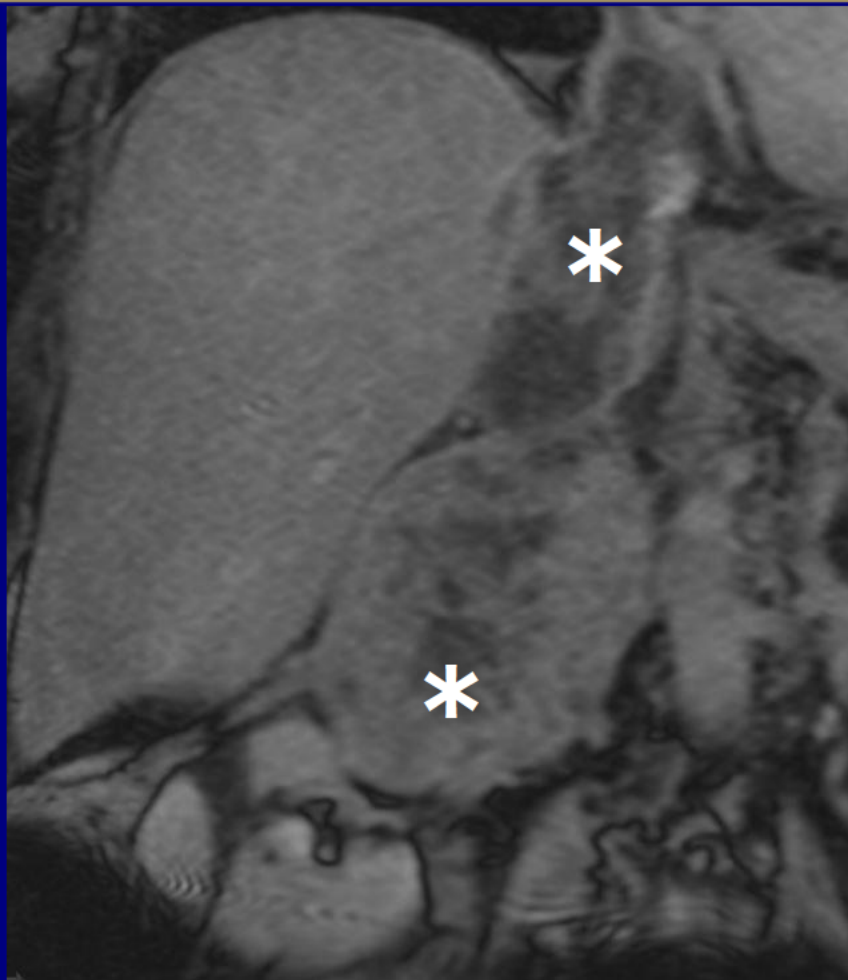
**T2W Coronal MRI**

**IVC mass extends into the inferior right atrium.**



T1W Coronal MRI, post gad

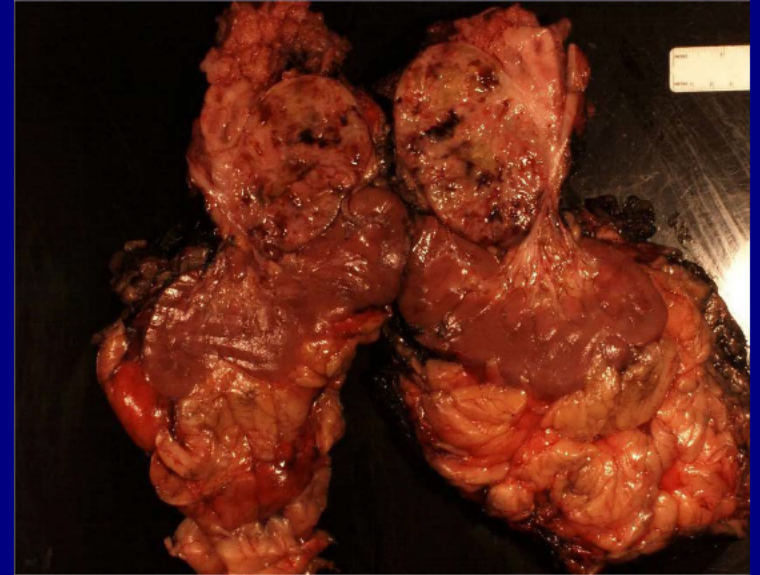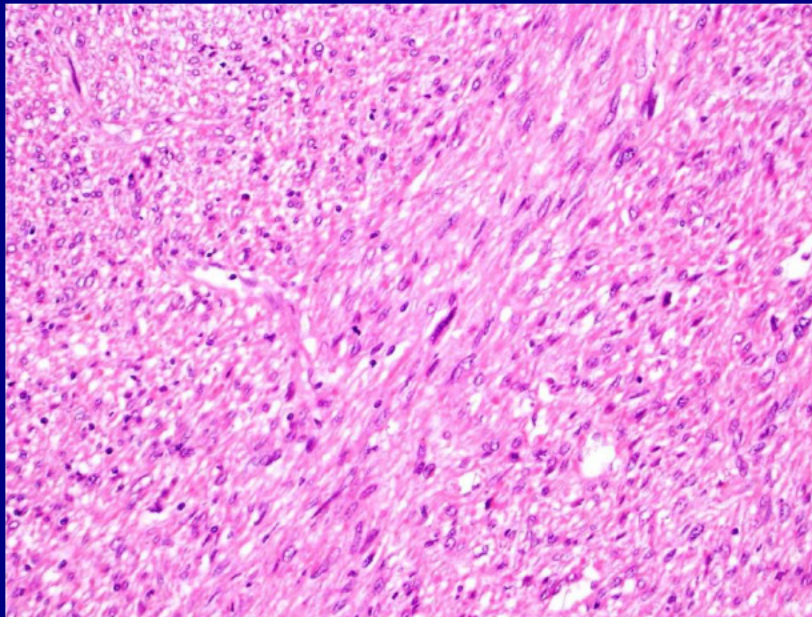
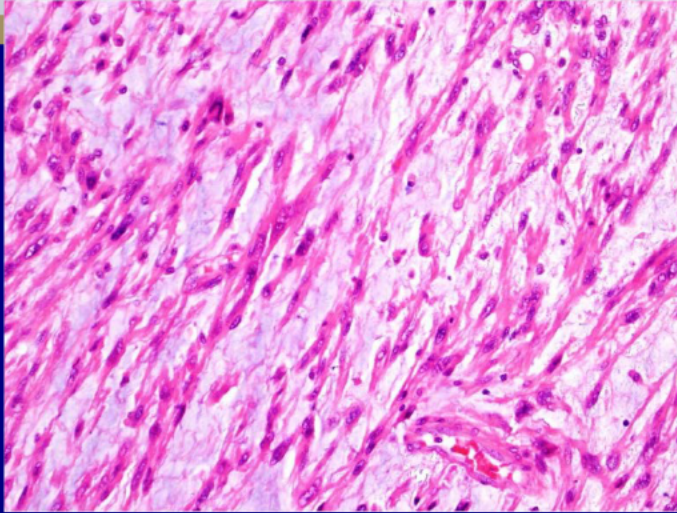
**Mass demonstrates heterogeneous enhancement on T1W post contrast study.**



**T1W Coronal MRI, post gad**

**Resected, bi-valved specimen ( including IVC mass and cut right kidney) appears multilobulated and partly hemorrhagic.**



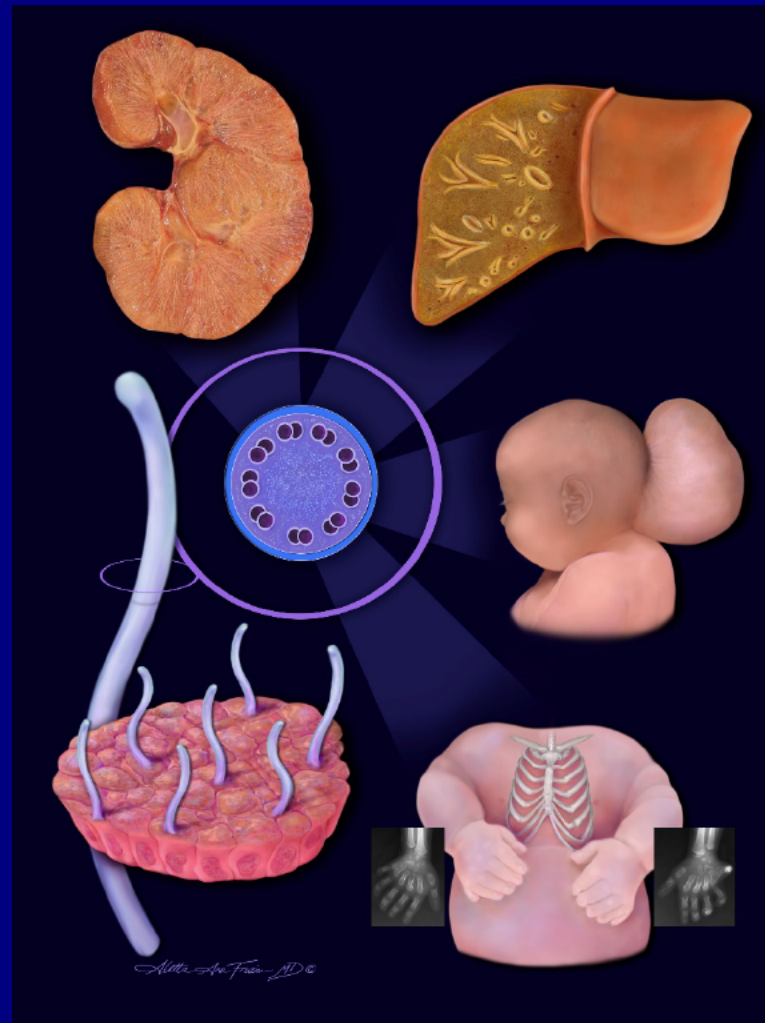


**Histology reveals fascicles of spindle cells with multiple mitotic figures.**

# Leiomyosarcoma of the inferior vena cava

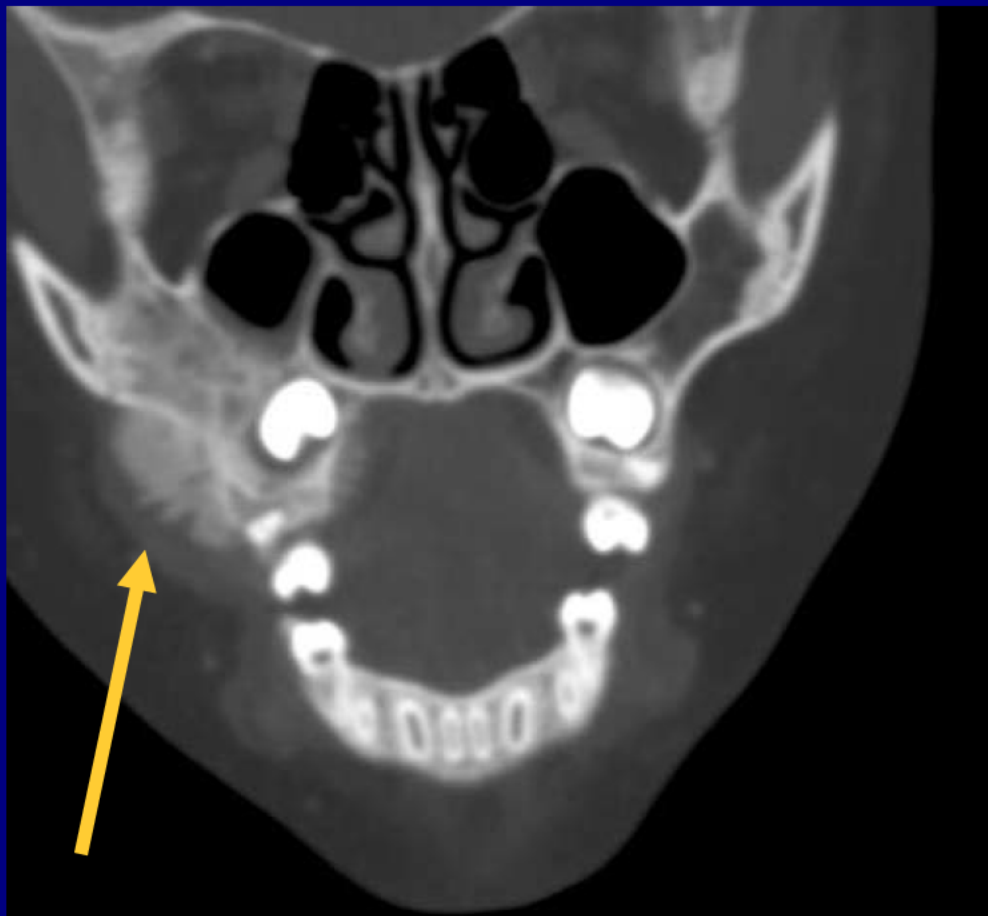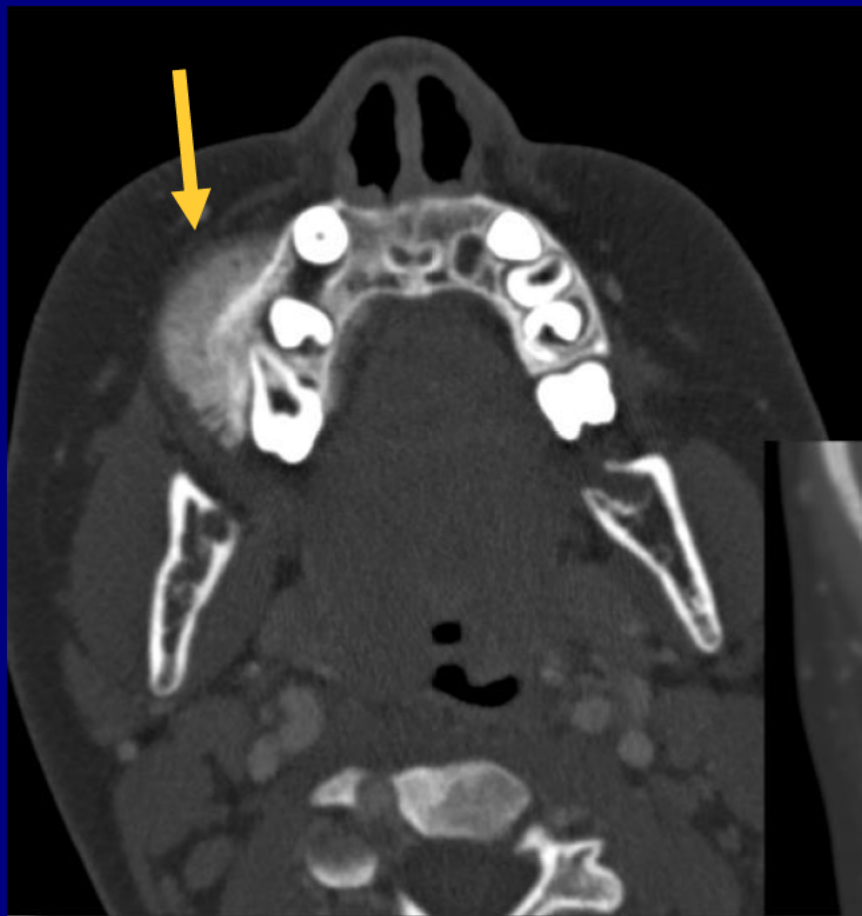Lauren Saling, MD  
Washington University  
School of Medicine  
St. Louis, Missouri

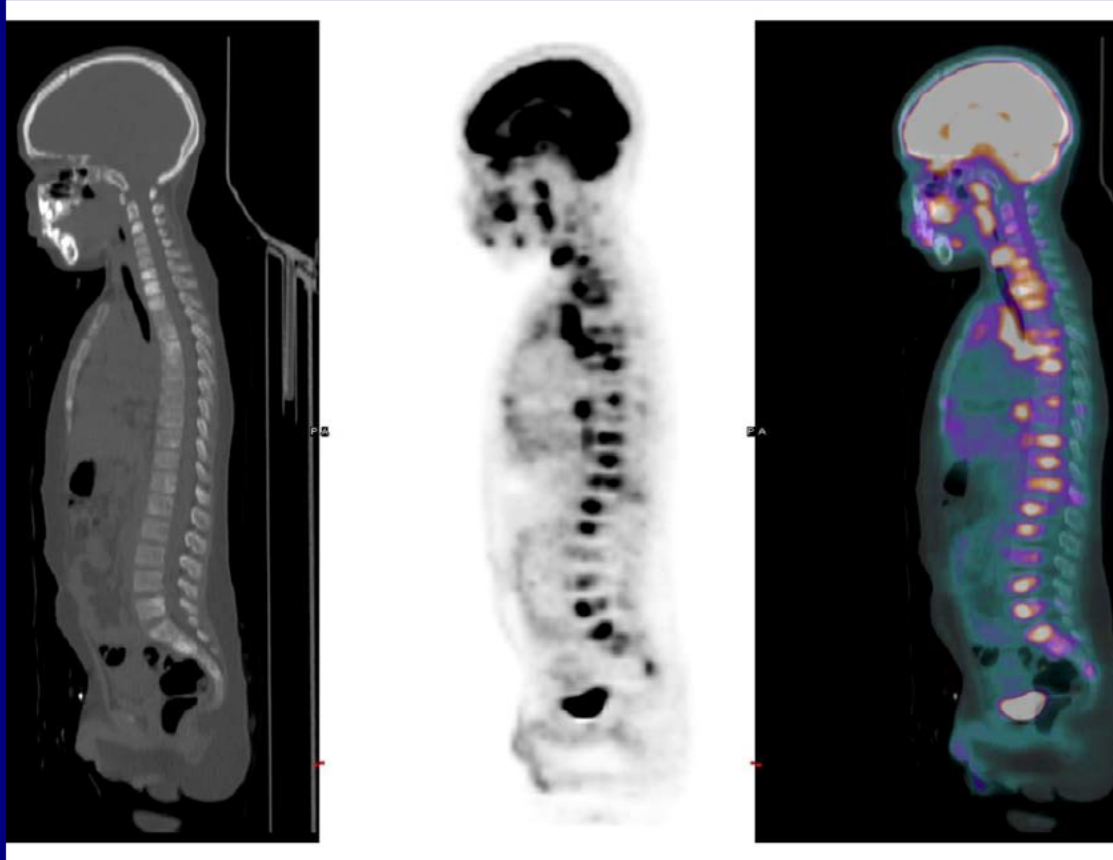
# Pediatric Best Case



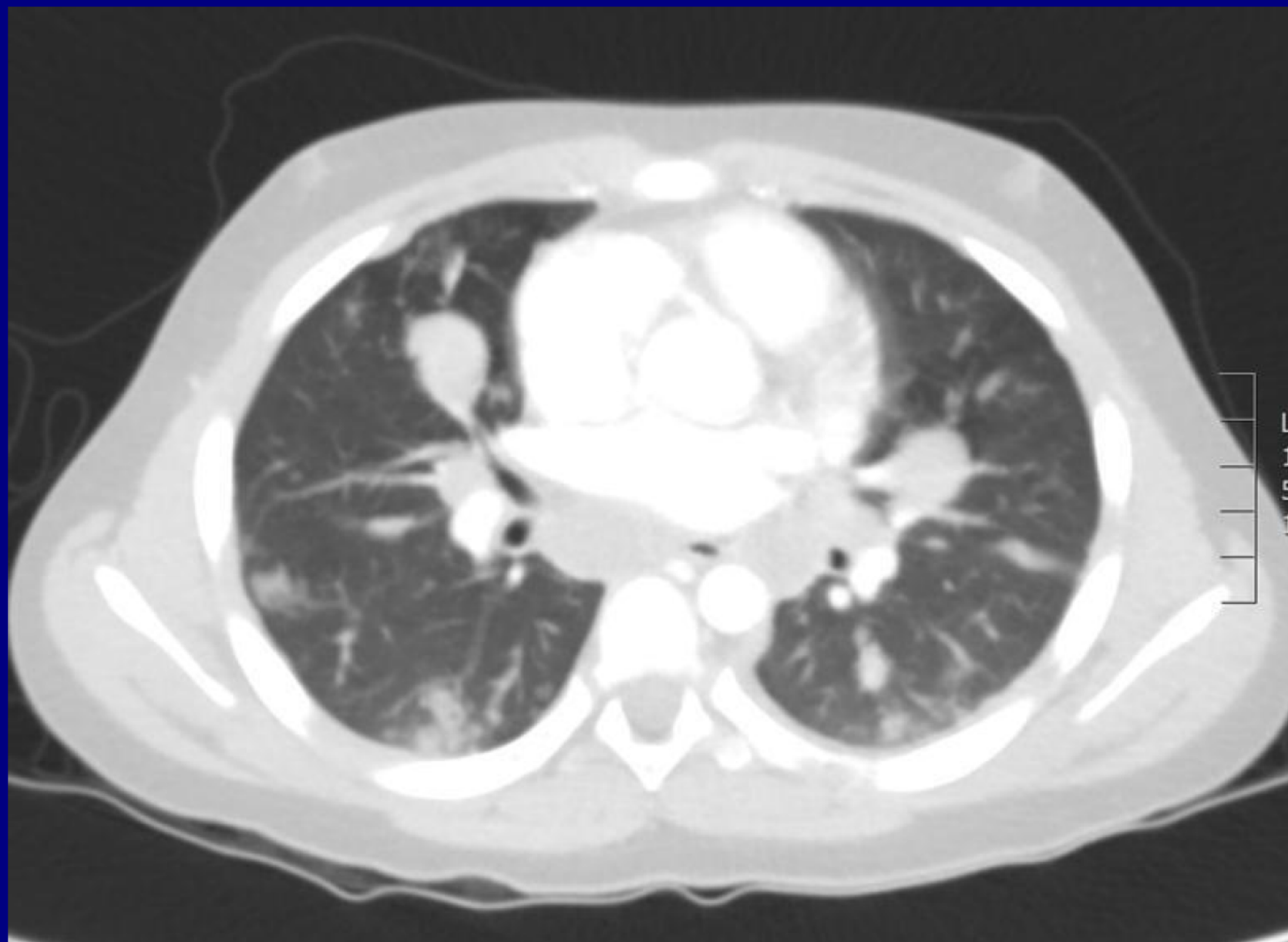


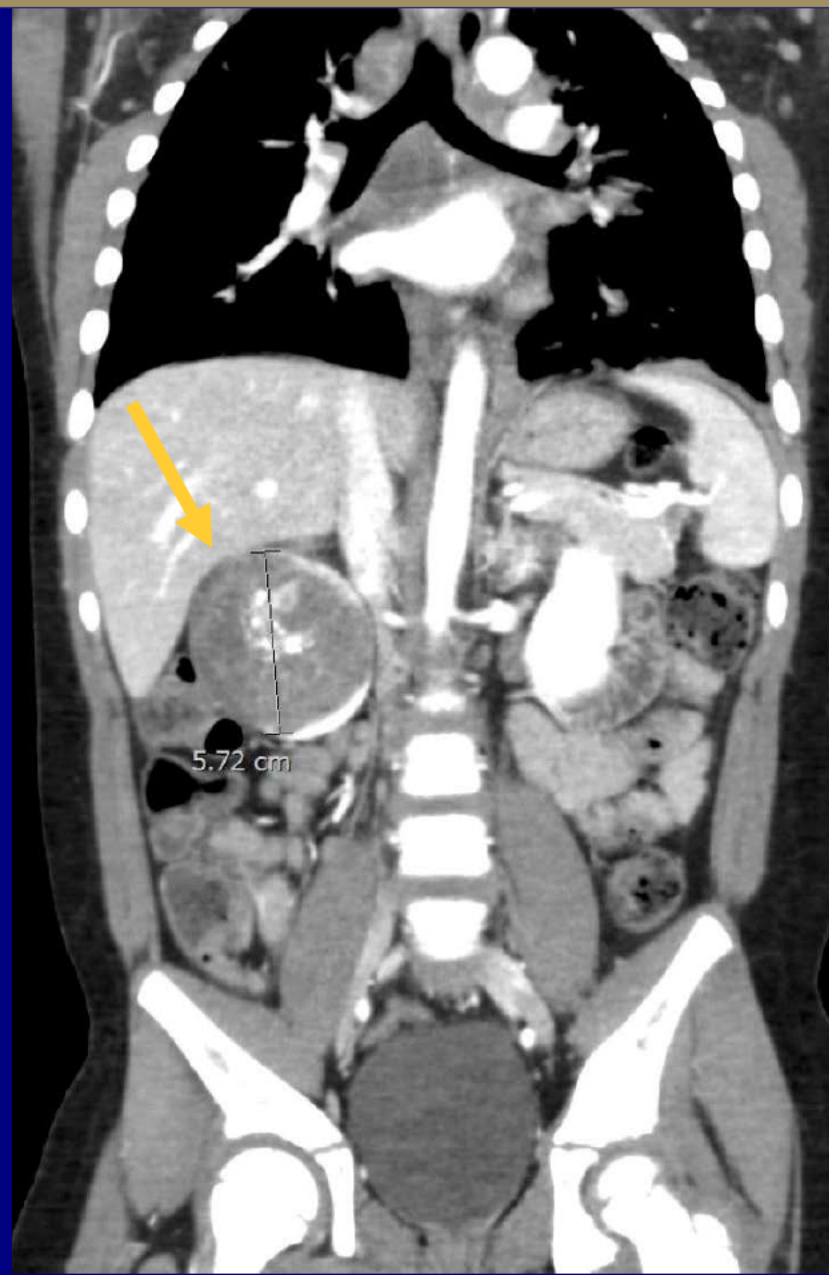
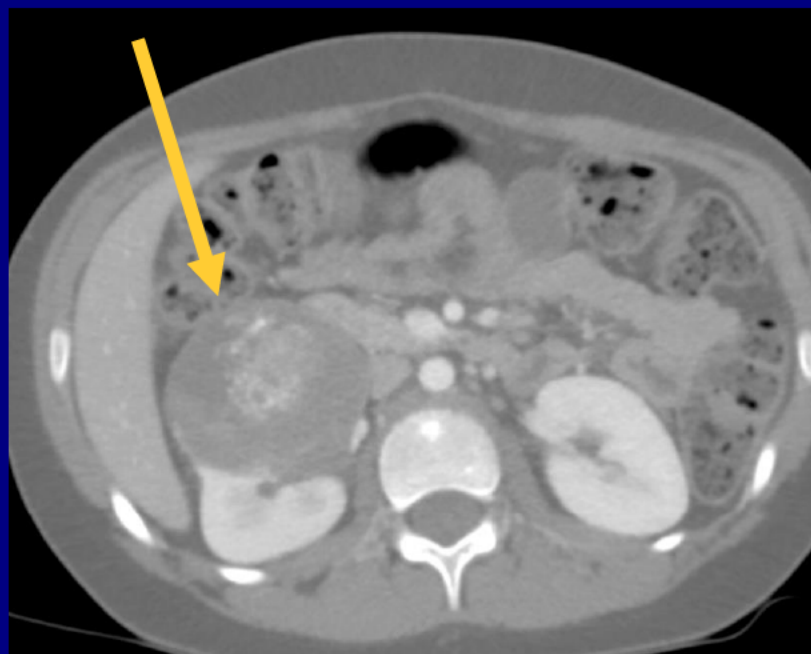
**6 year old African American male  
presents with right jaw pain,  
dysphagia, and facial swelling.**

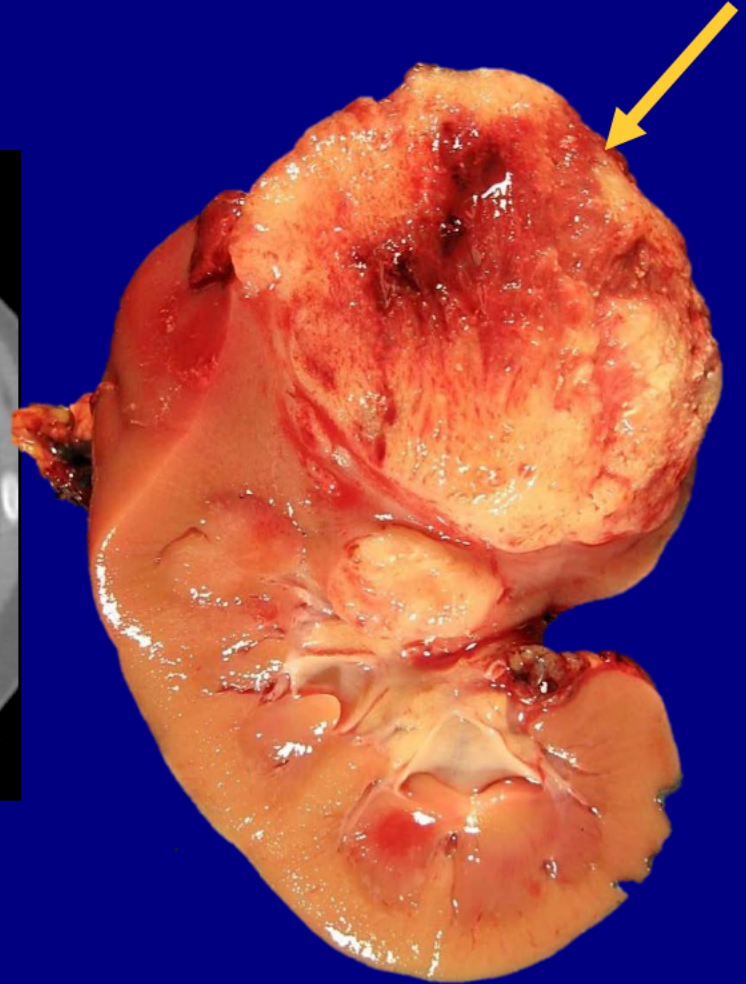
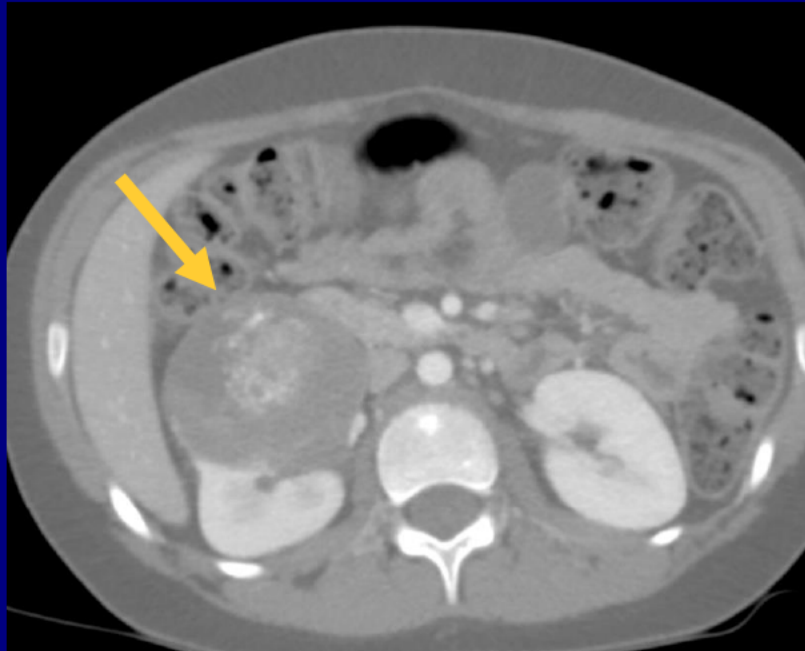









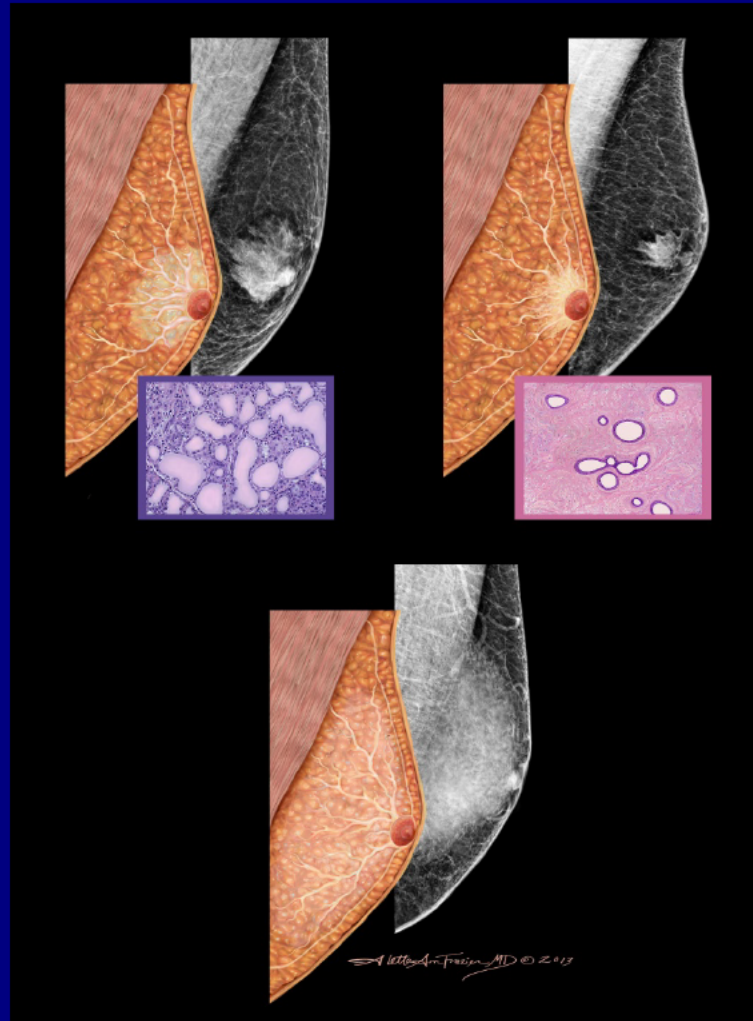




# Desmoplastic Small Round Cell Tumor (DSRCT) of the Kidney

**William Walton, MD**  
**Vanderbilt University**  
**Nashville, Tennessee**

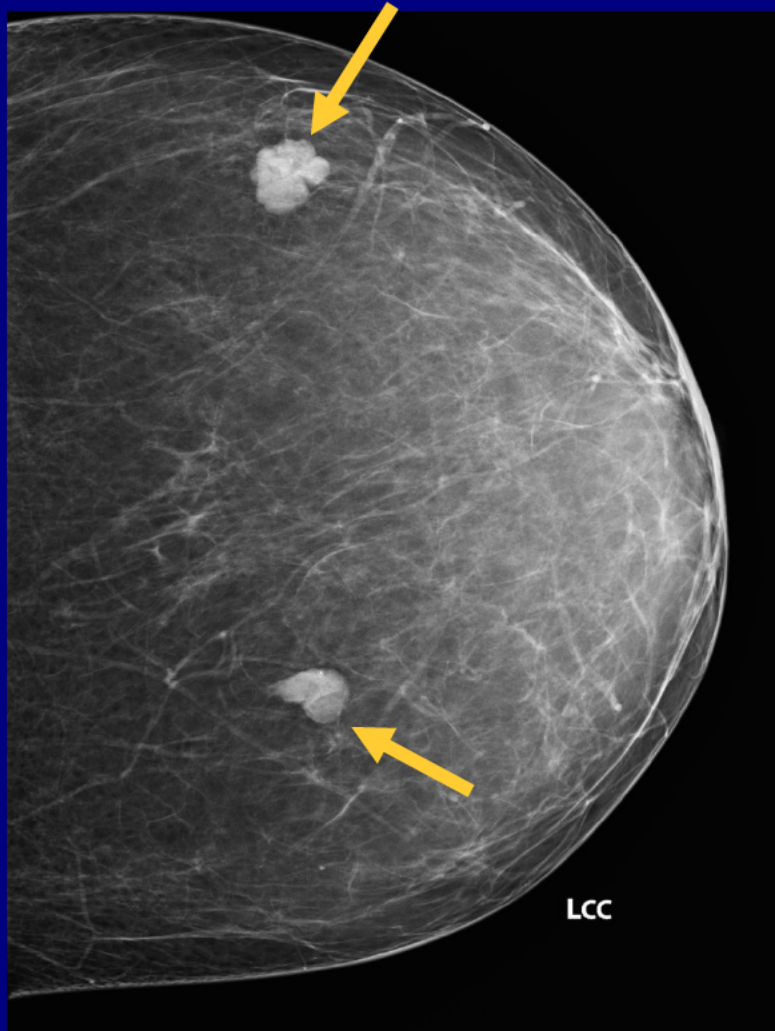
# Breast Best Case



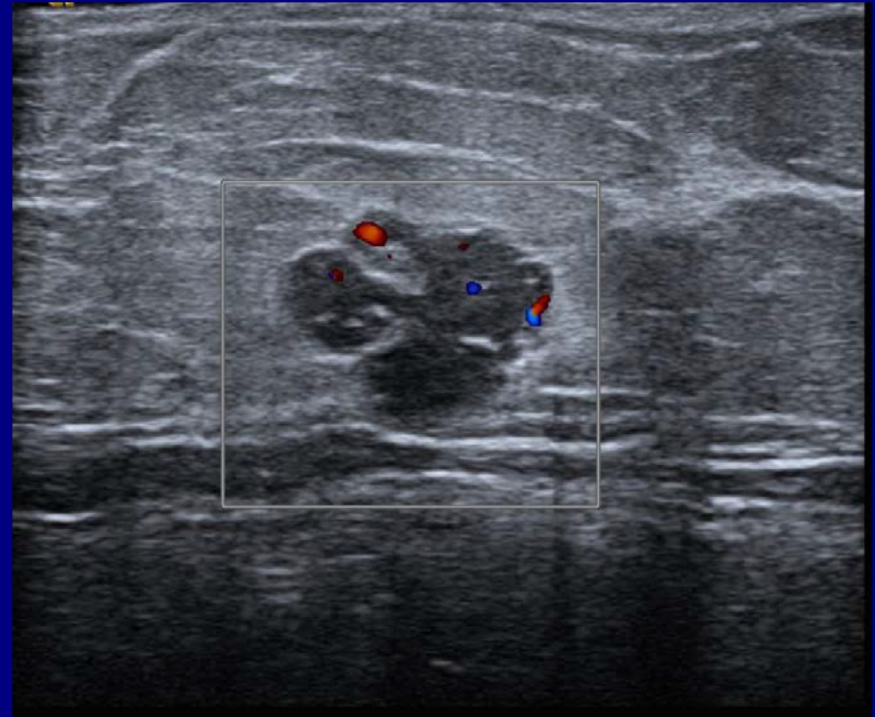
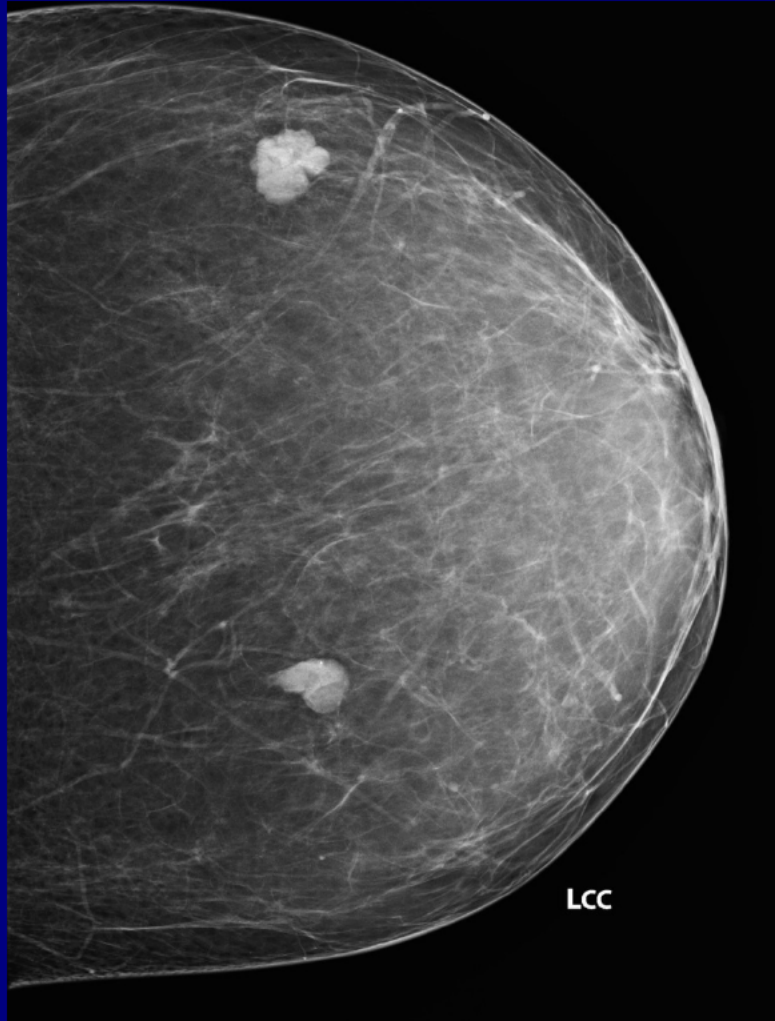
**43 yo female with two masses  
detected on screening  
mammography**

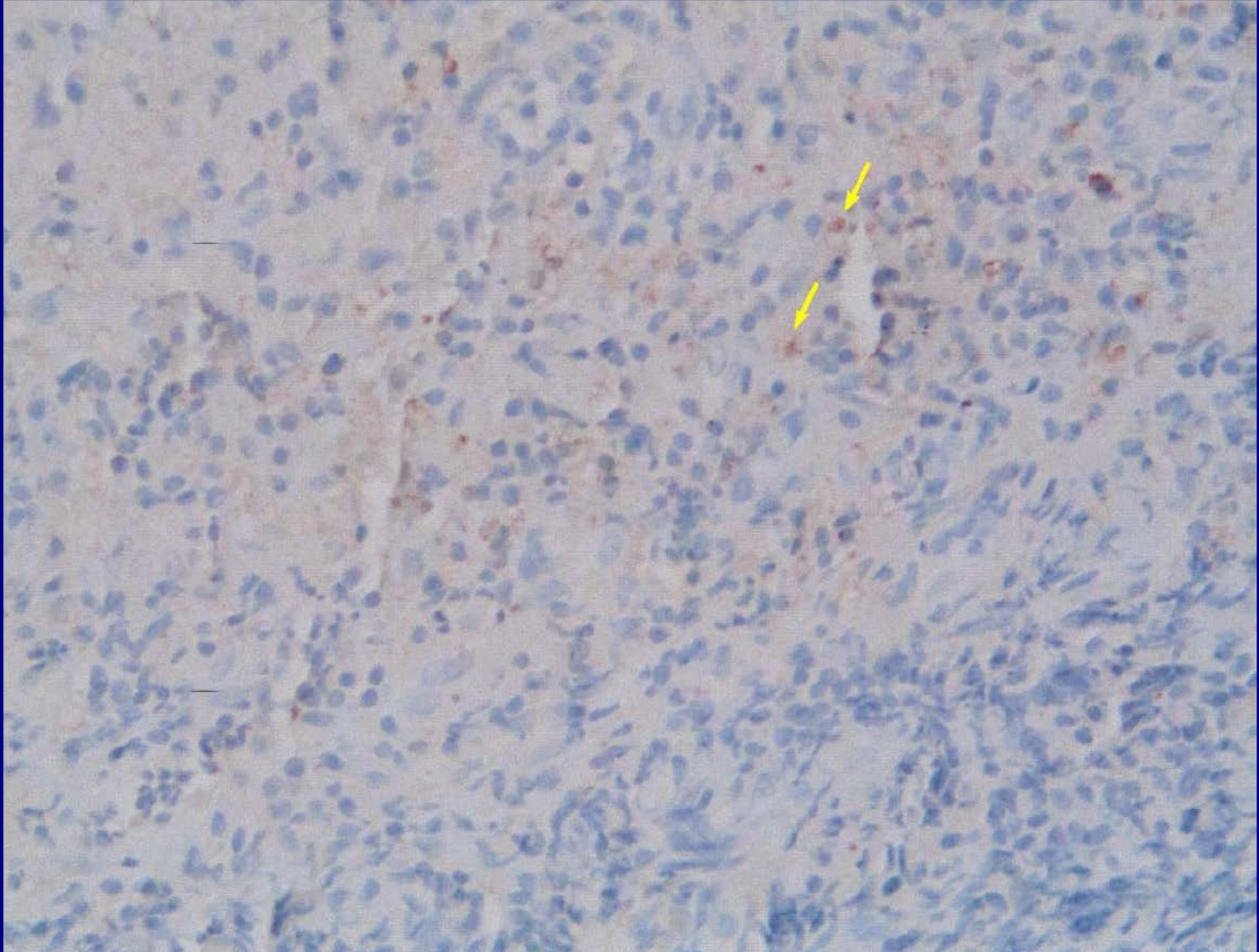


# Left Mammogram



# Ultrasound



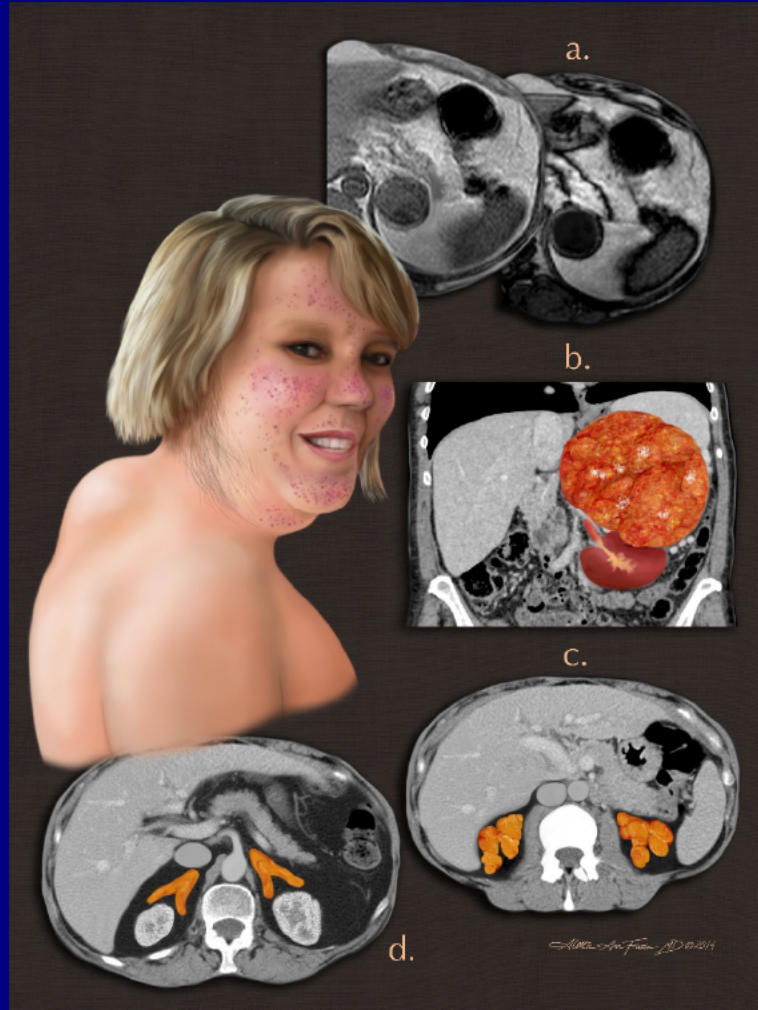




**Rosai-Dorfman  
(sinus histiocytosis with massive  
adenopathy)**

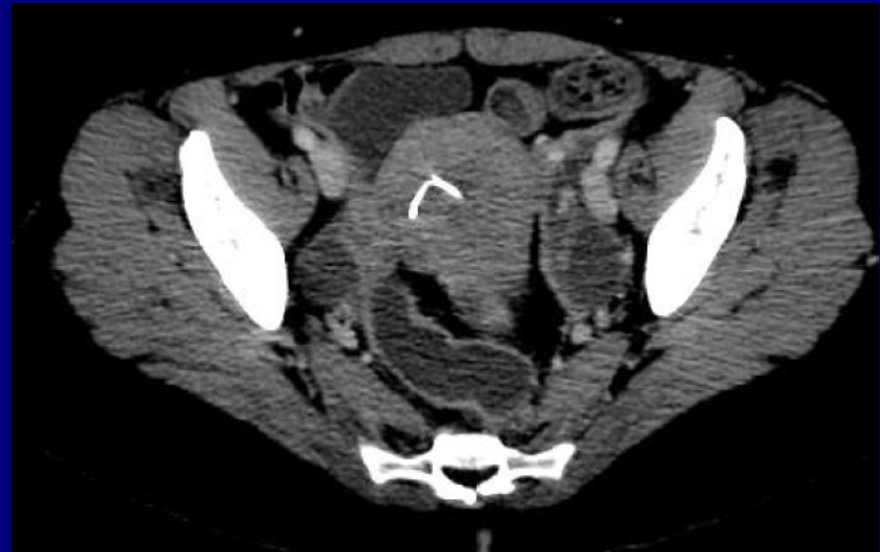
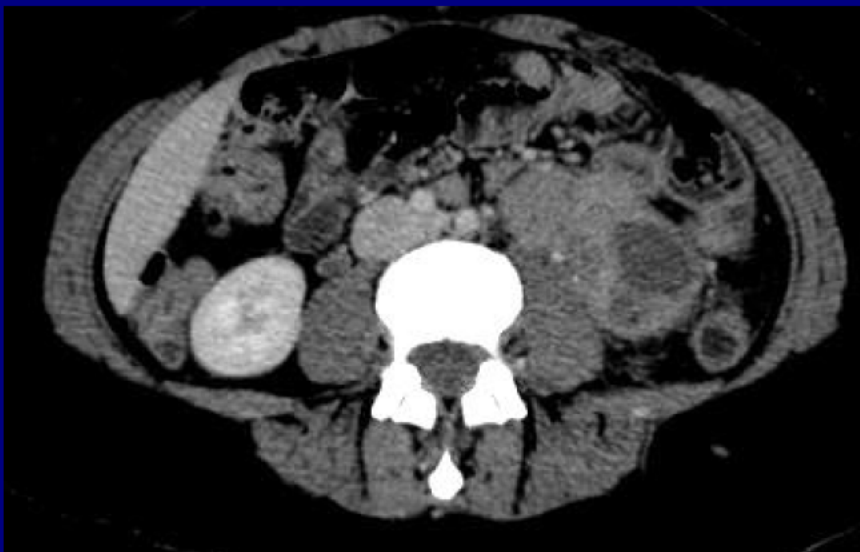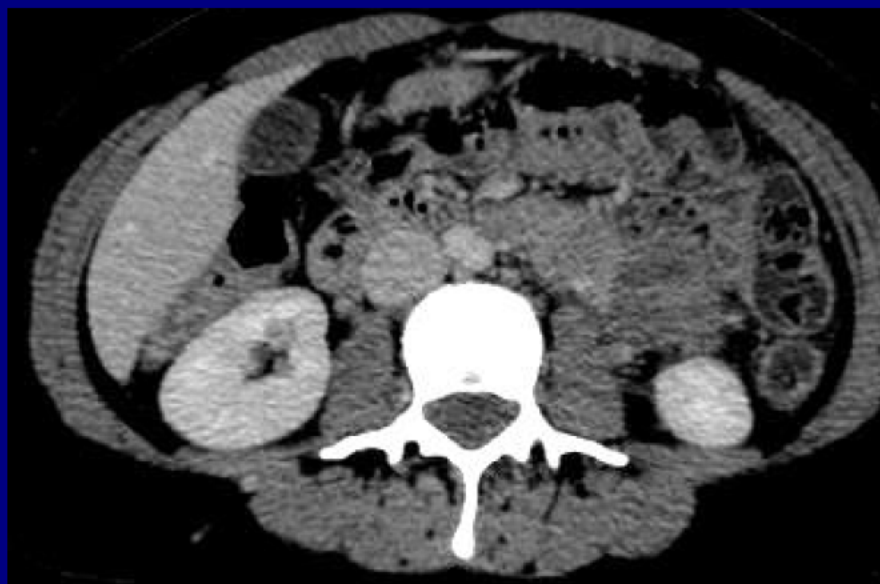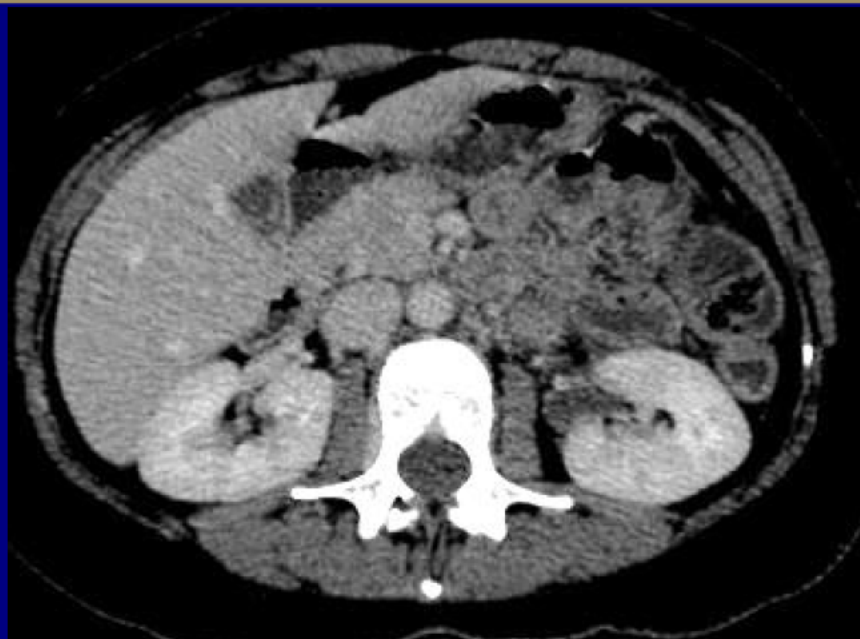**Mohammad Gharavi, MD  
Aultman/Mercy Medical Center  
Canton, Ohio**

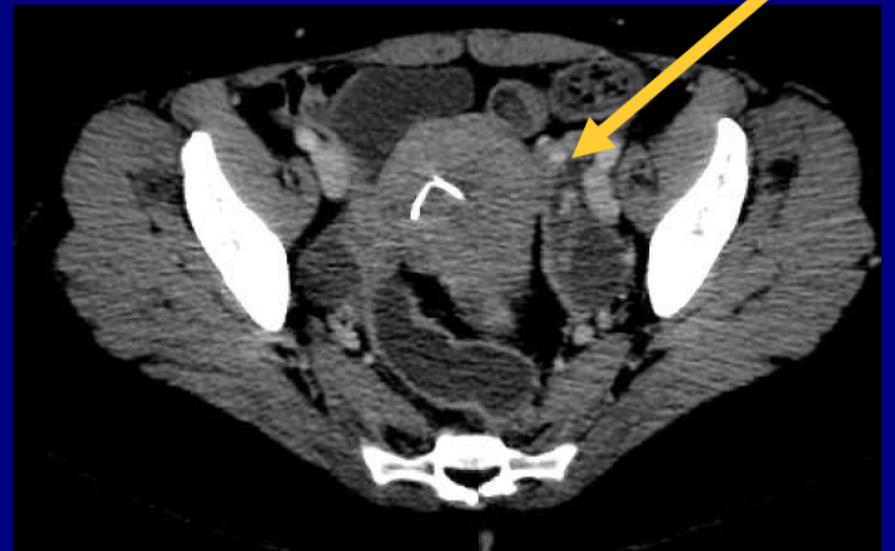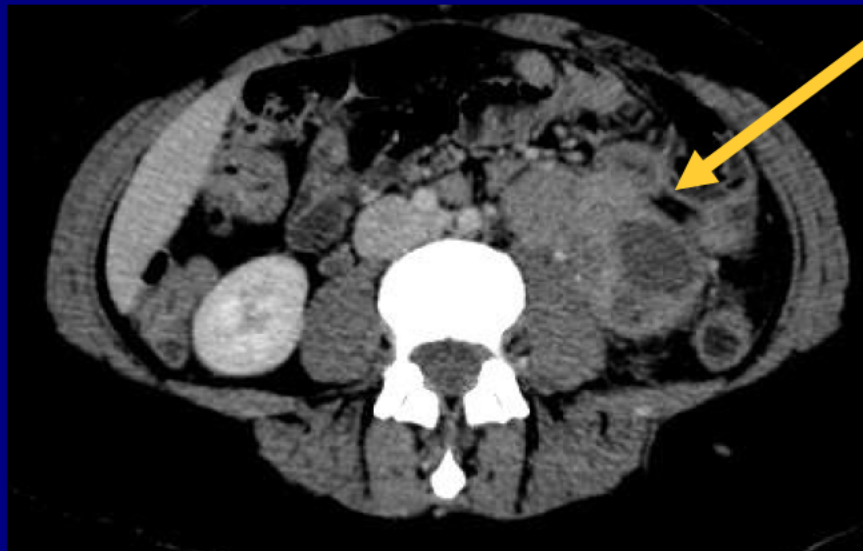
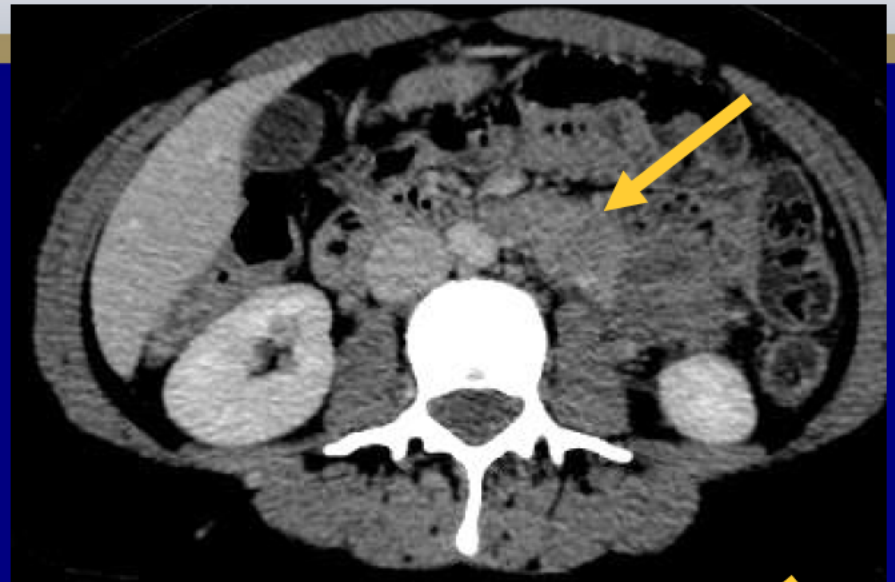
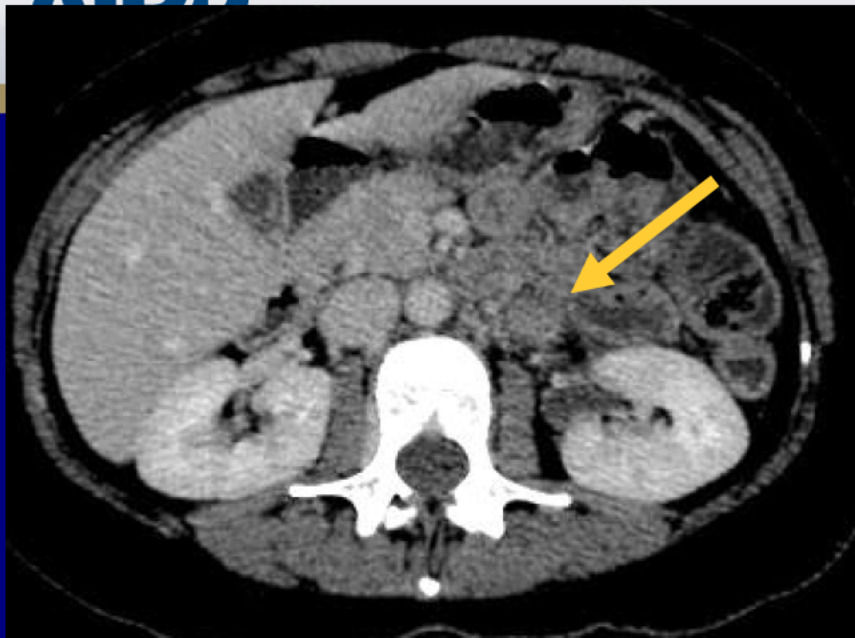
# Genitourinary Best Case

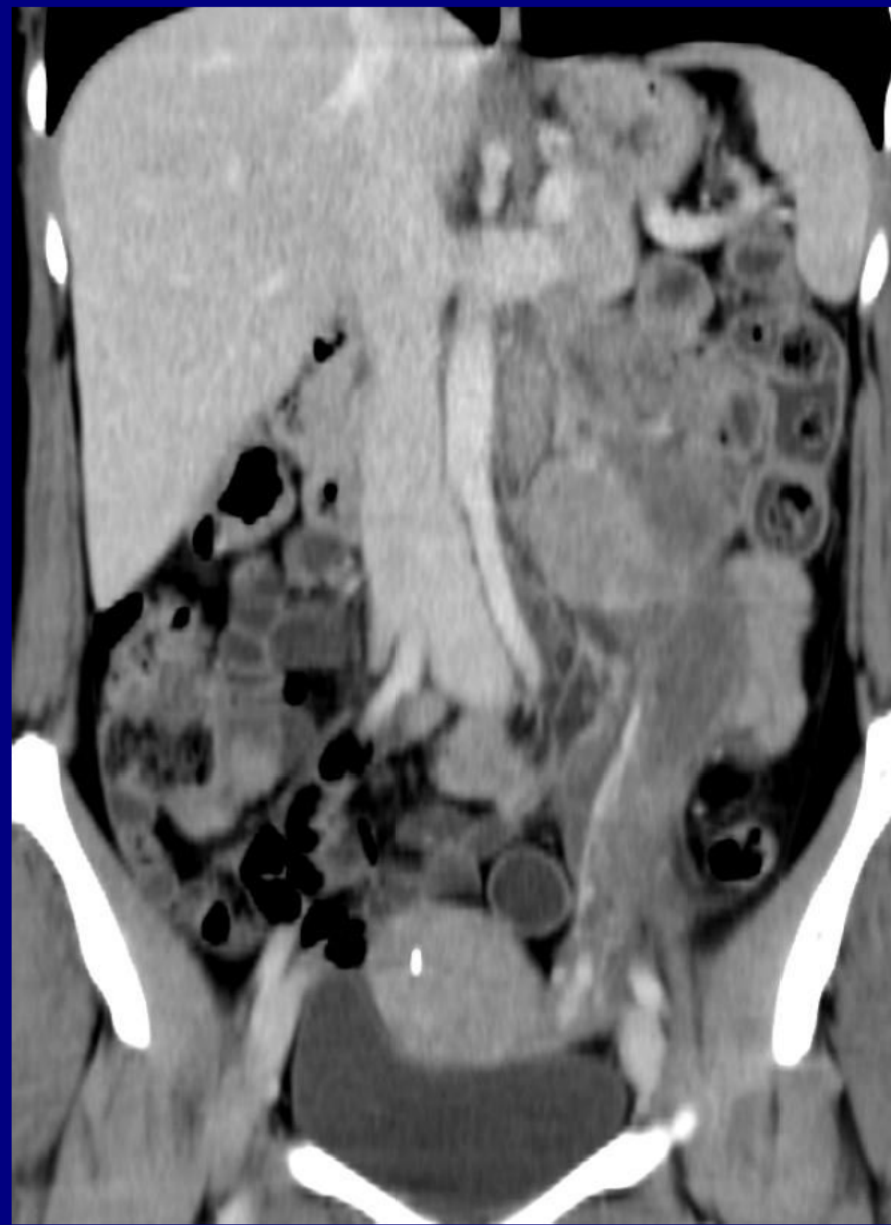
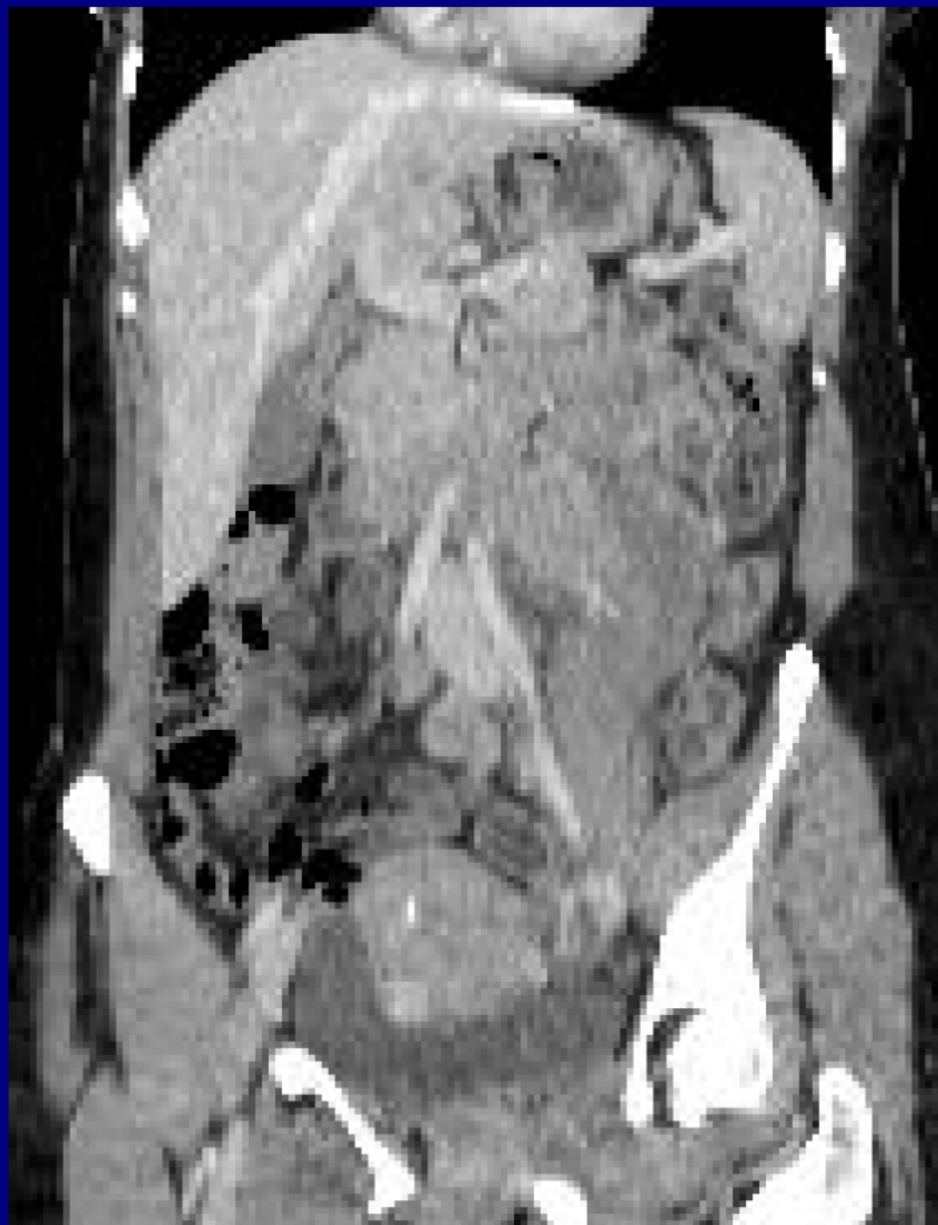

**49 yo female with left lower quadrant  
pain**

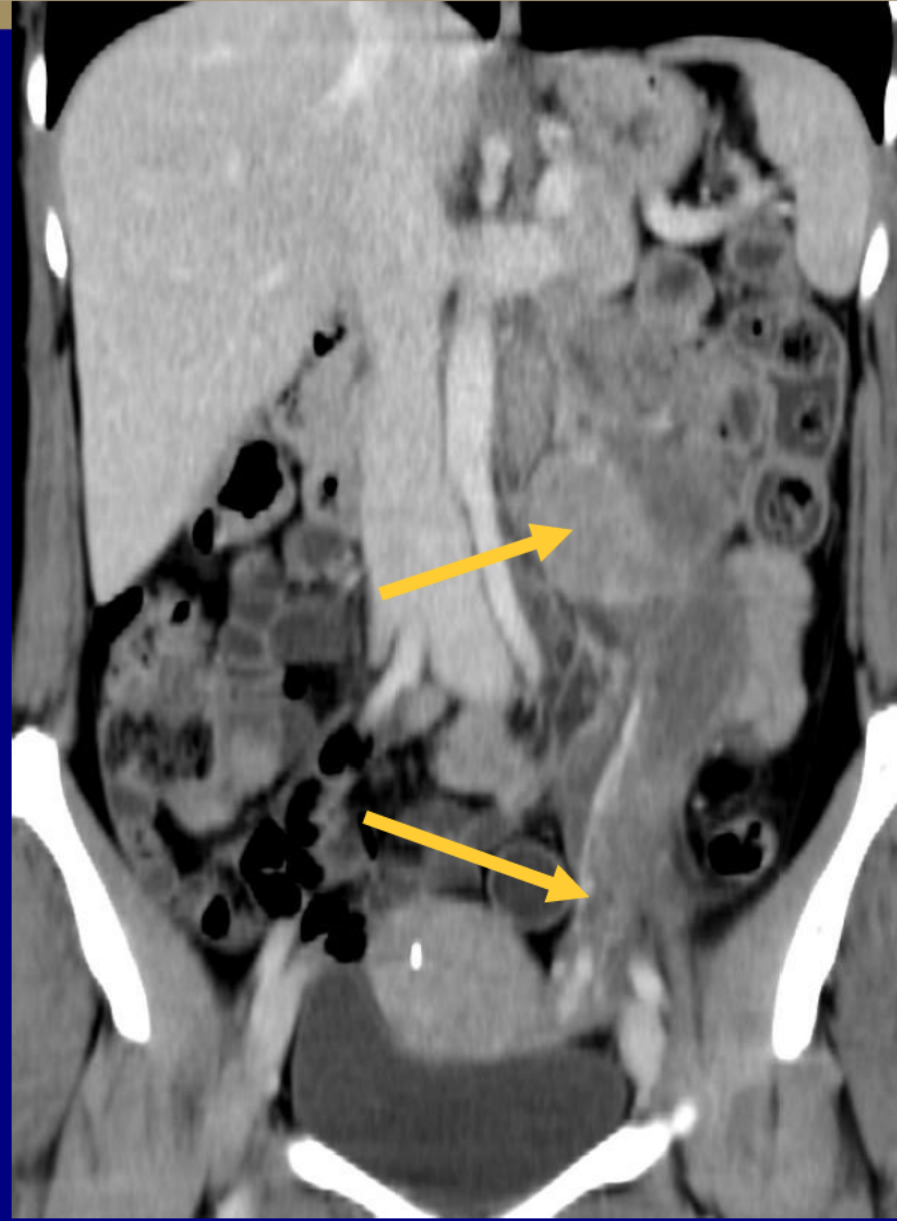
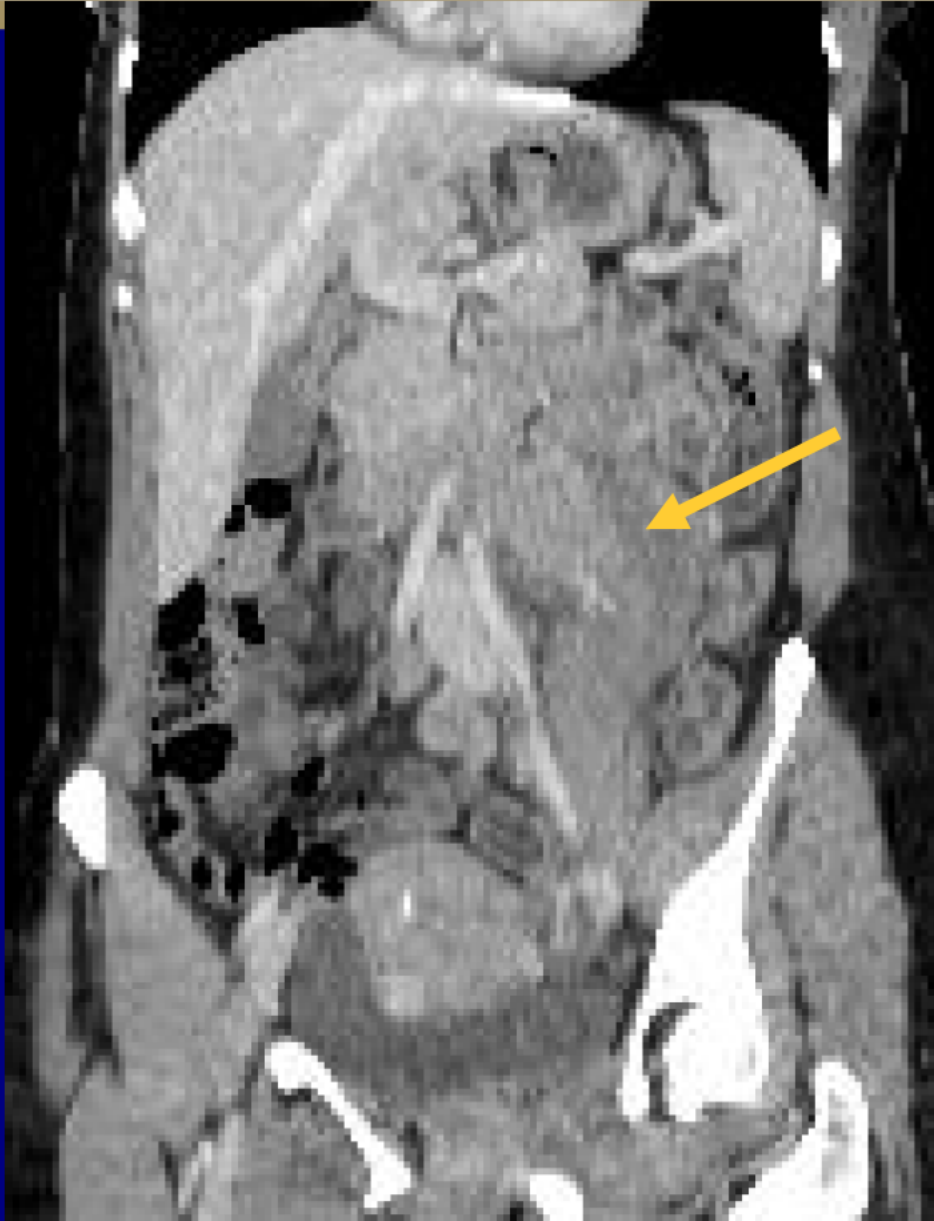

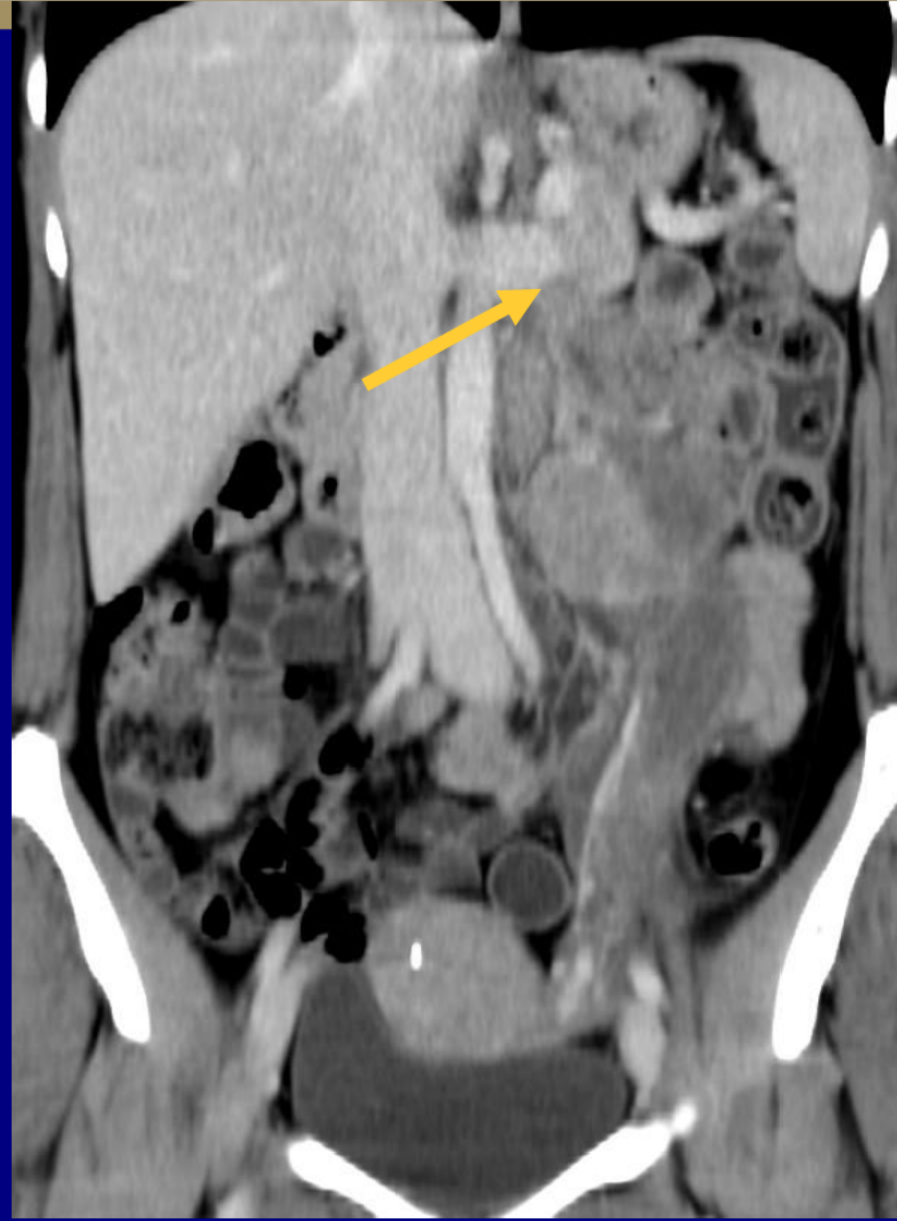

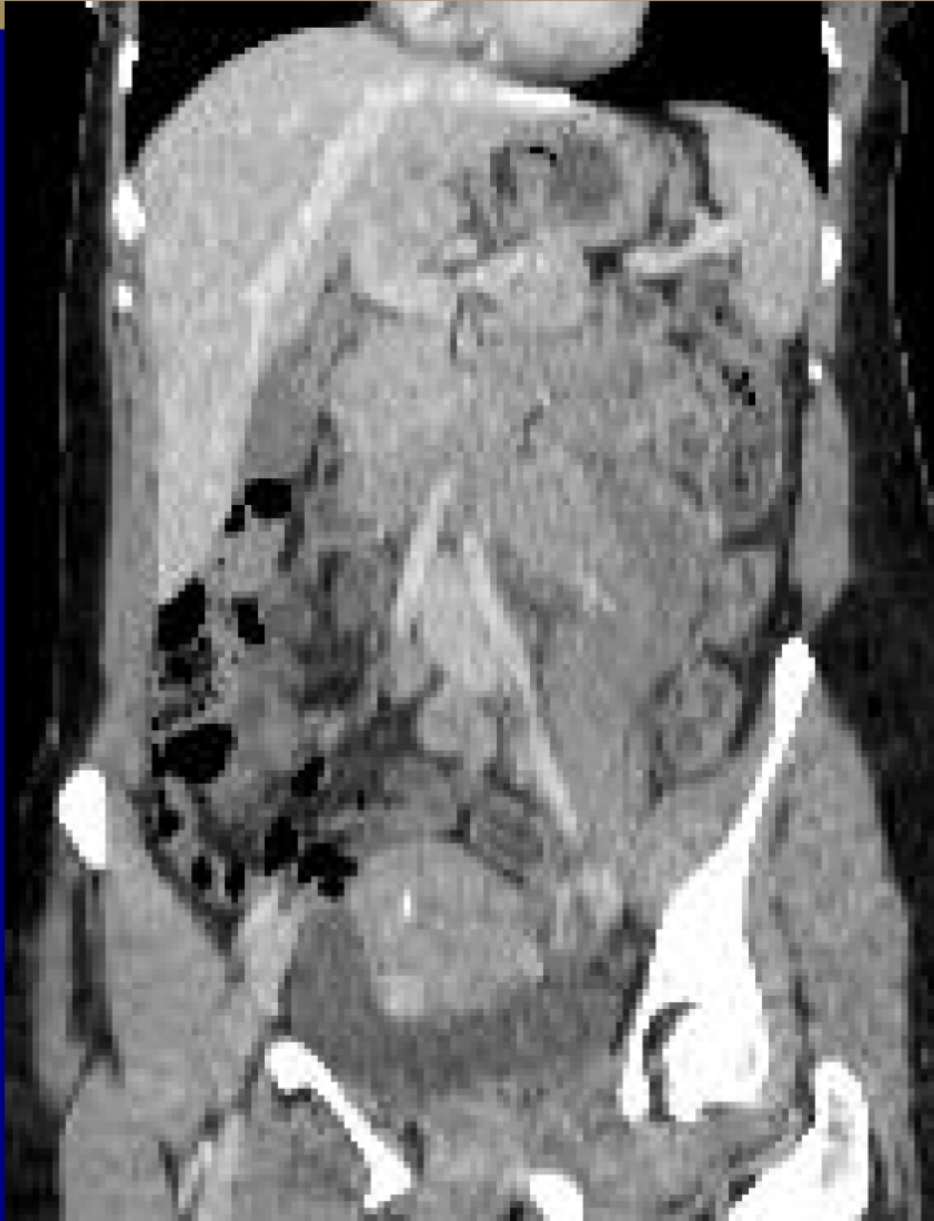
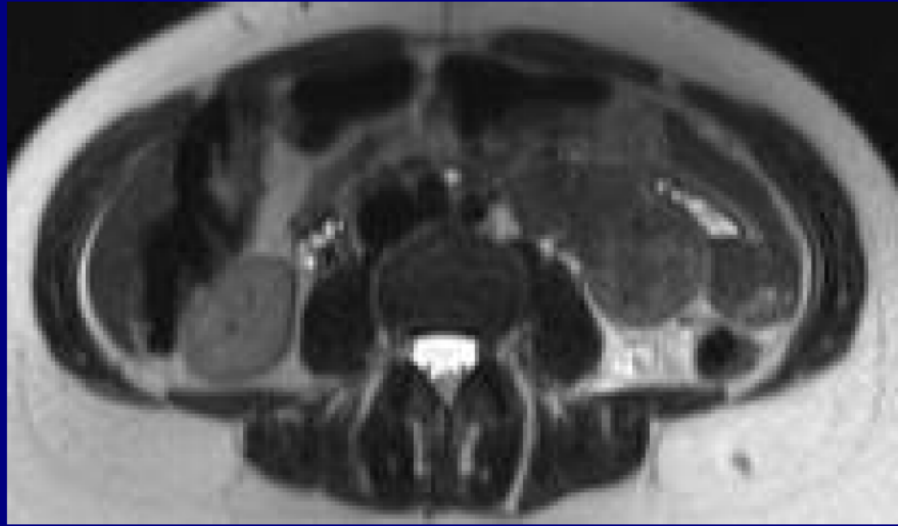




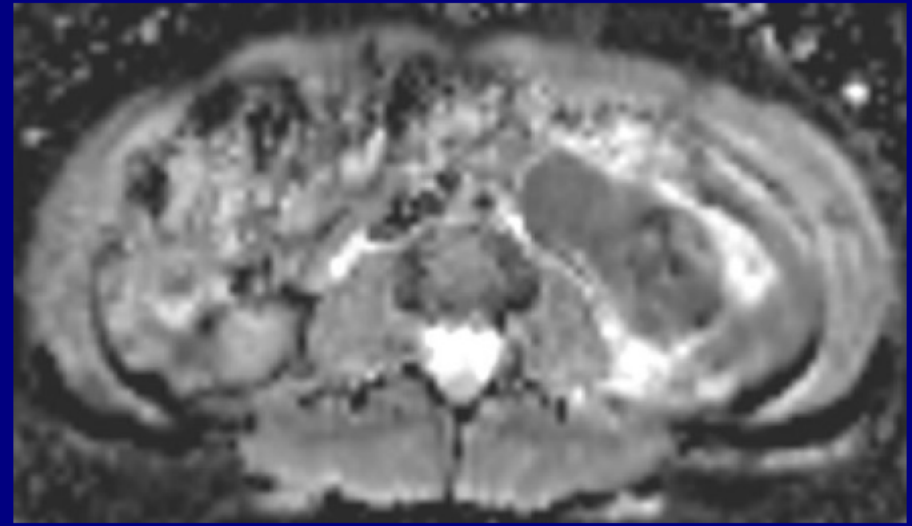






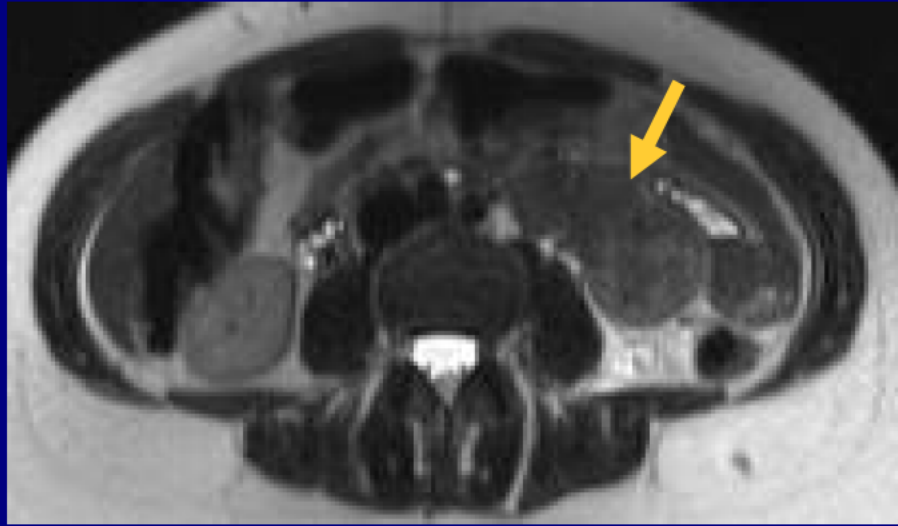


**HASTE**

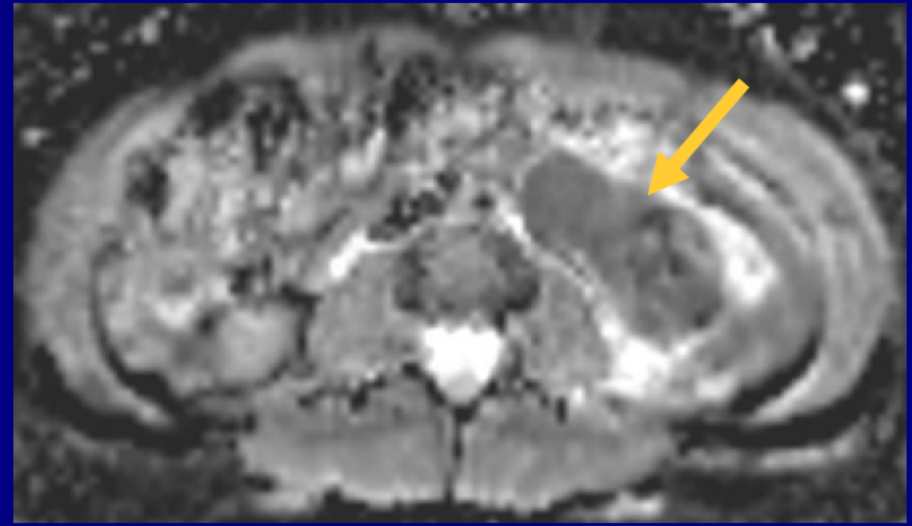


**ADC**

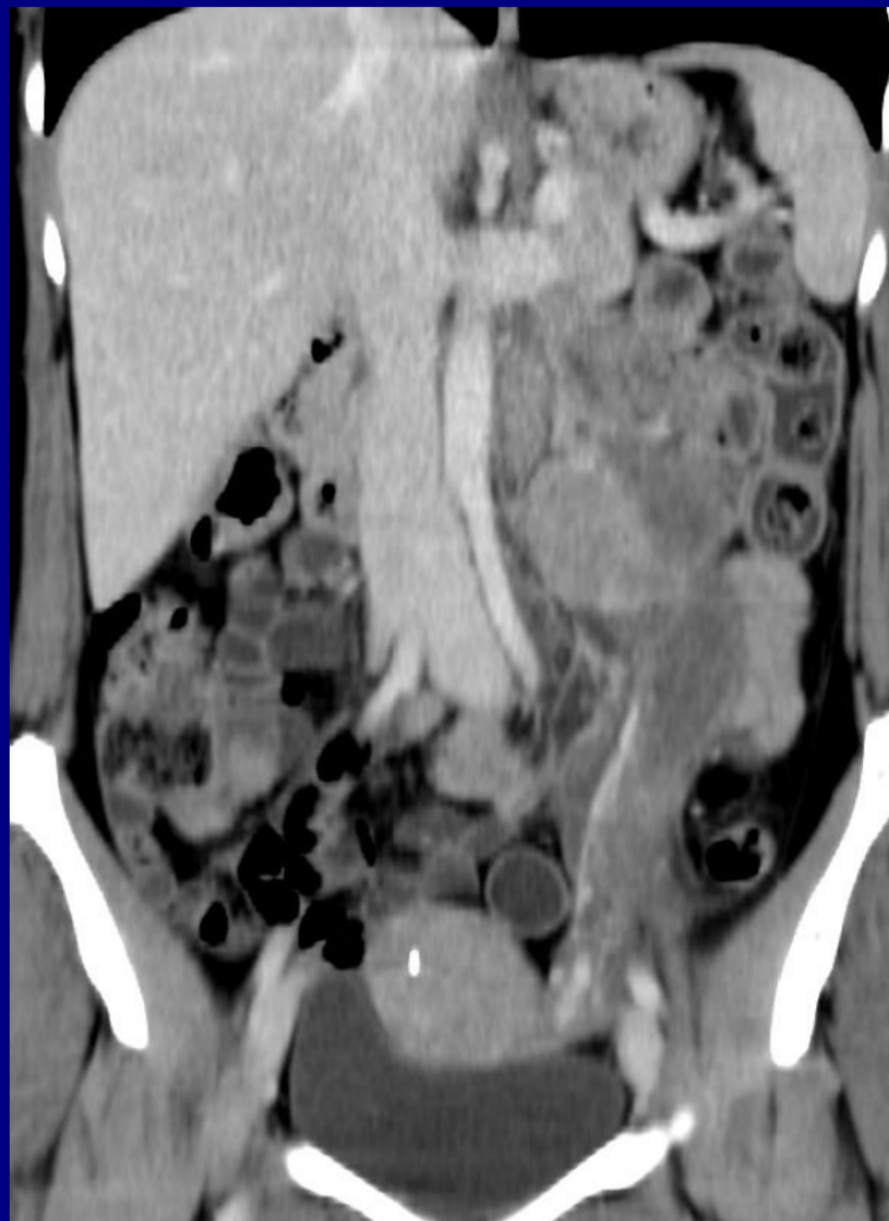
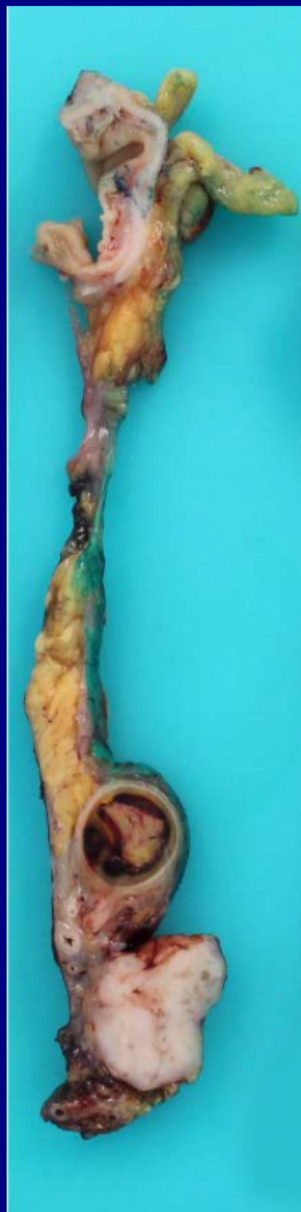

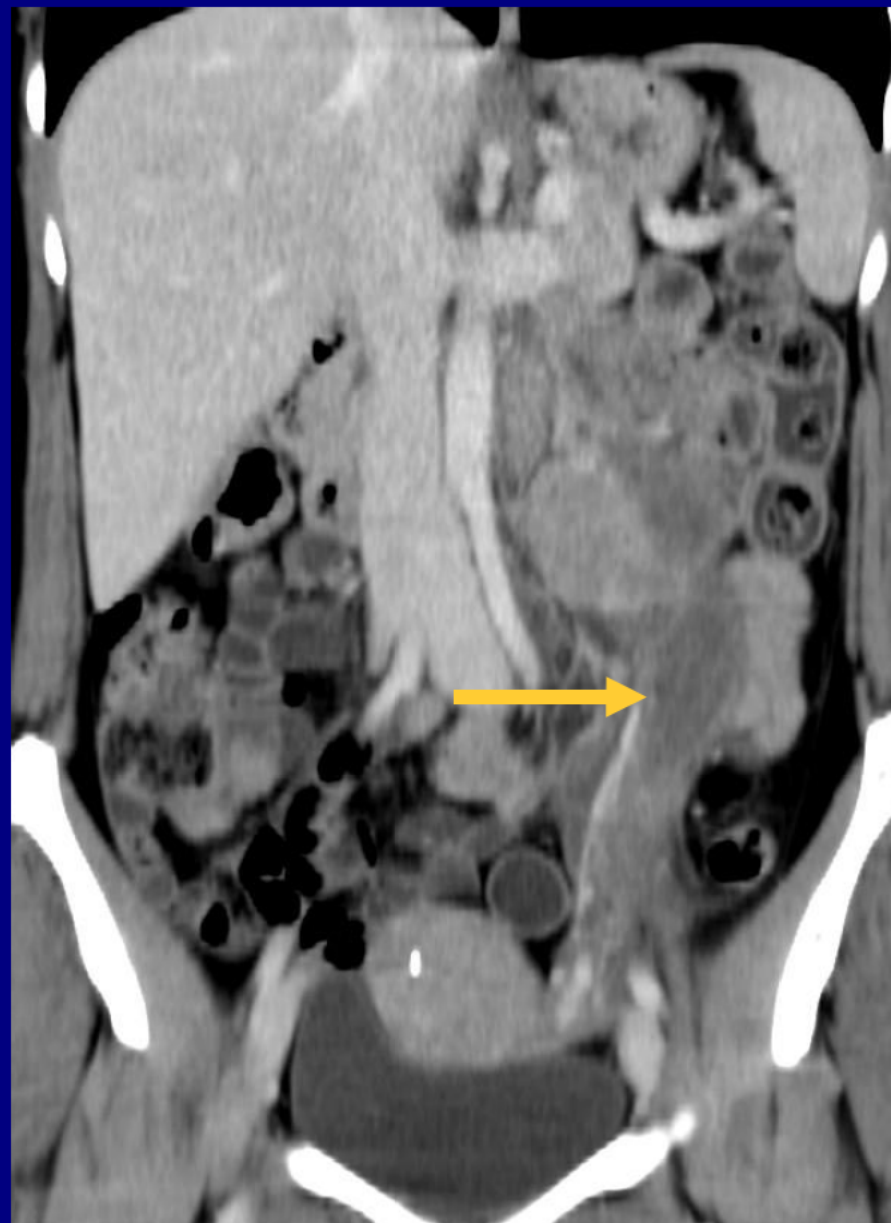
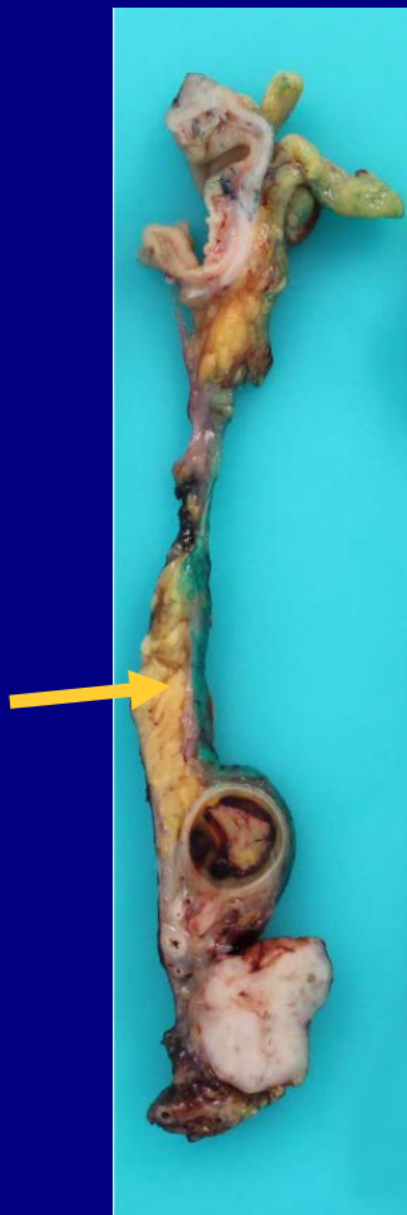


**HASTE**

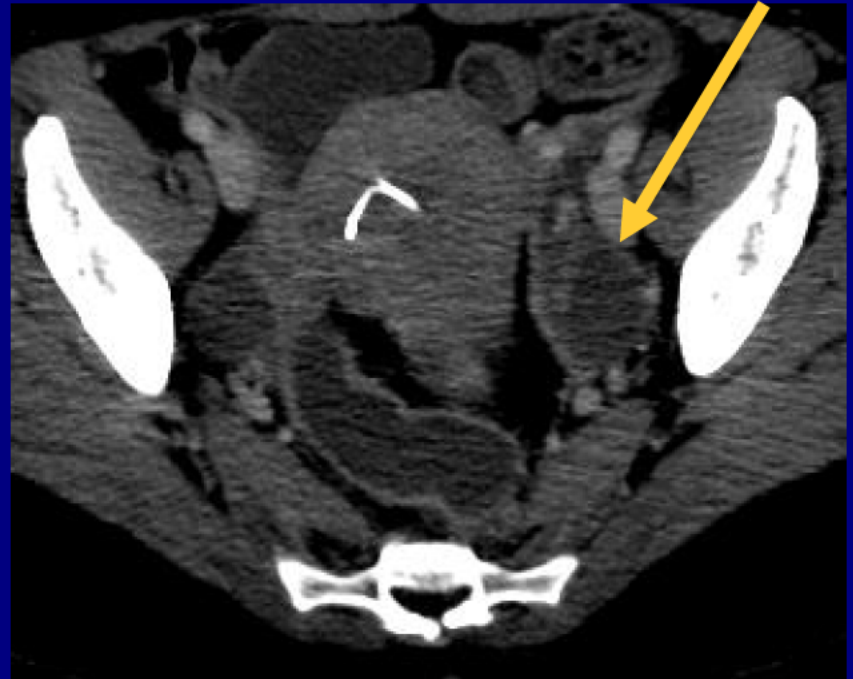
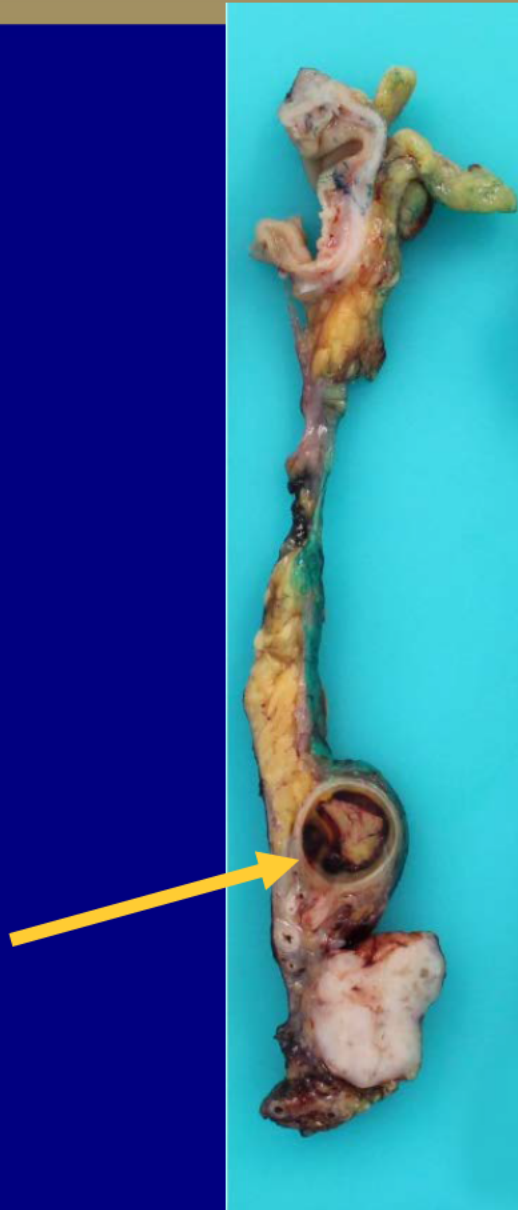


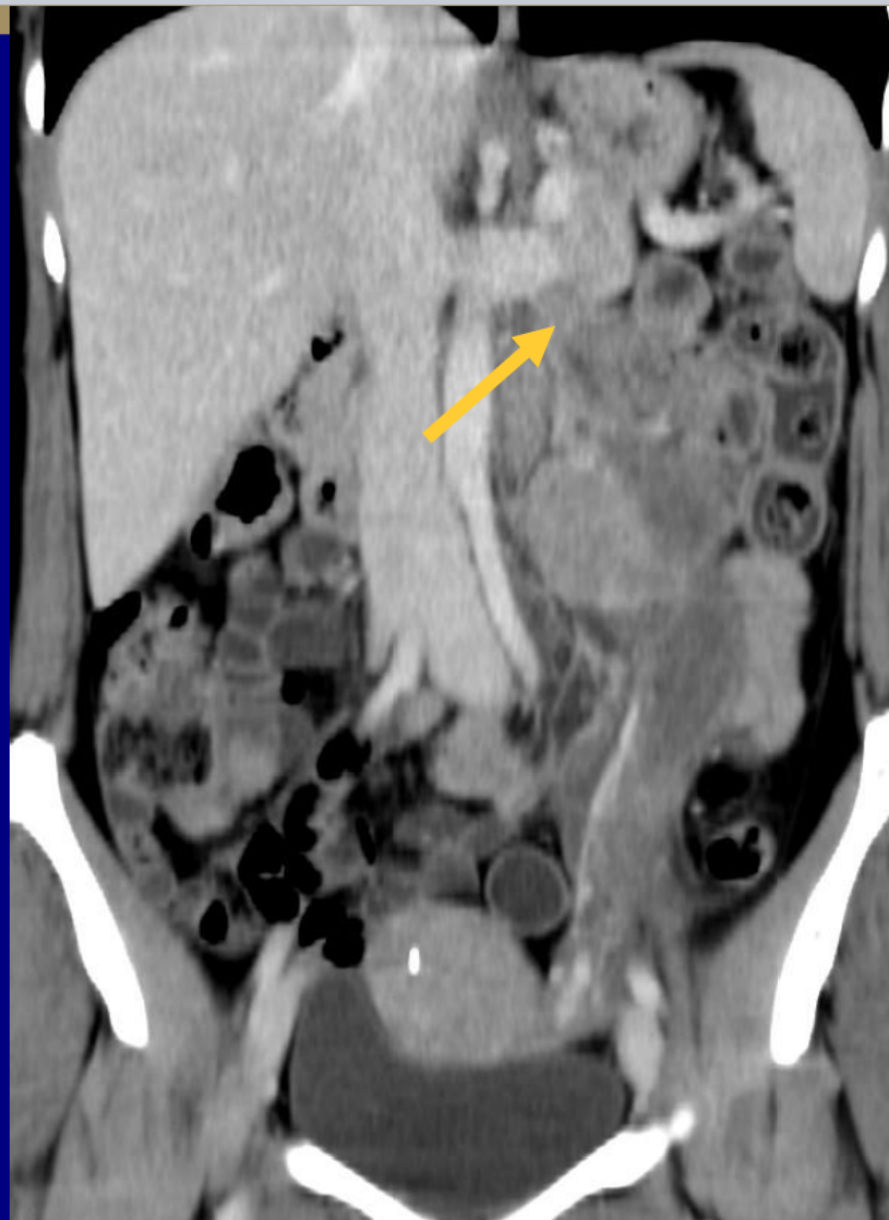
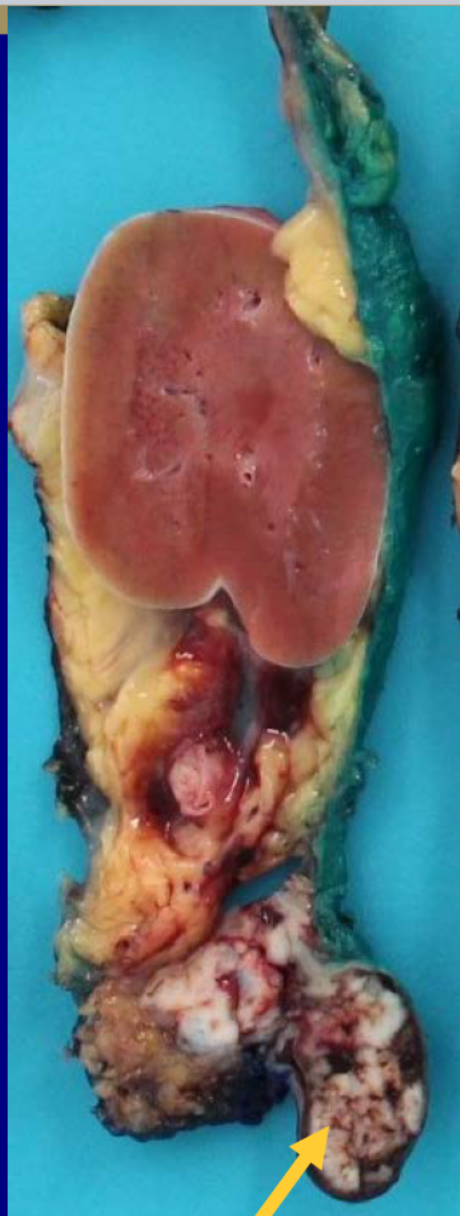**ADC**



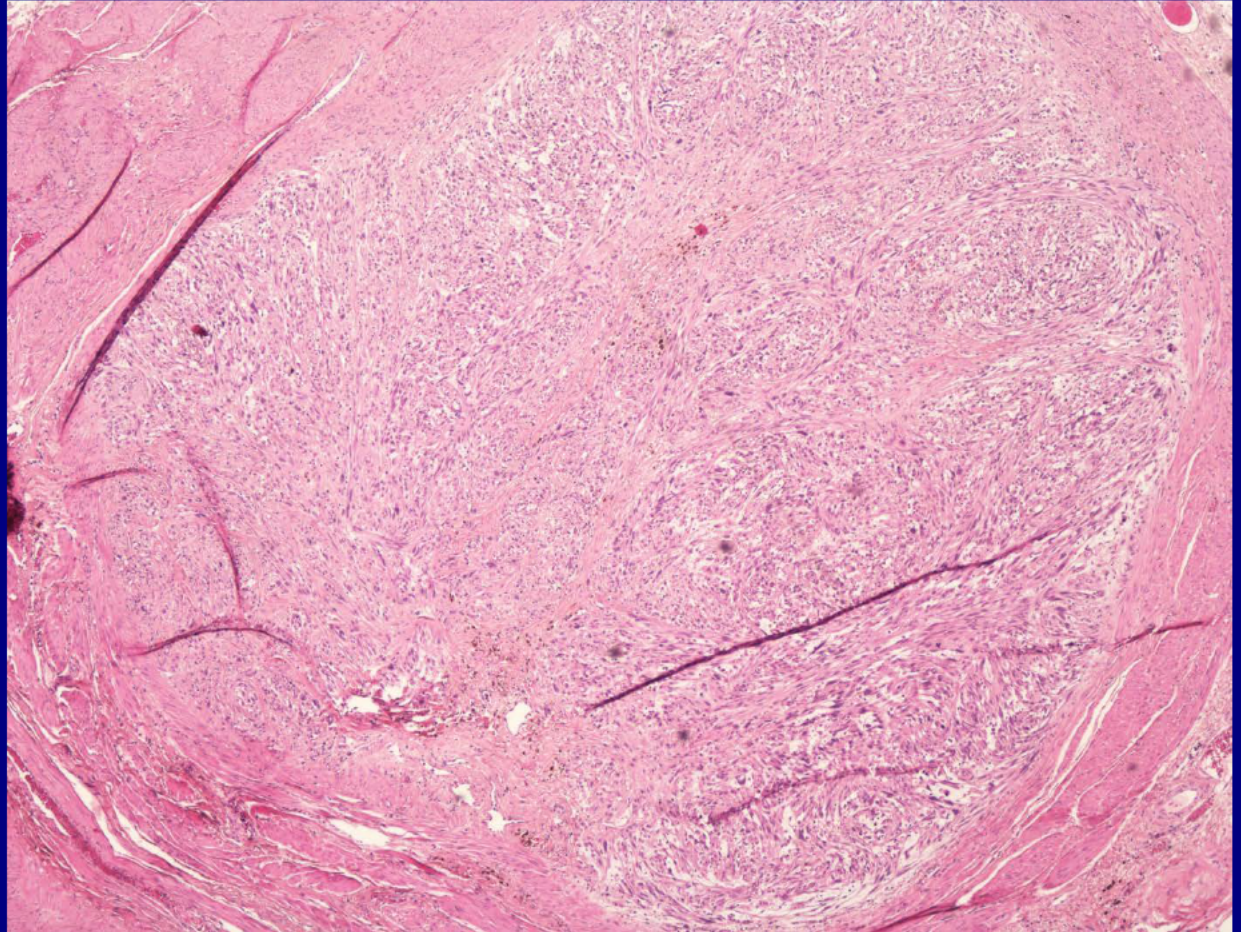
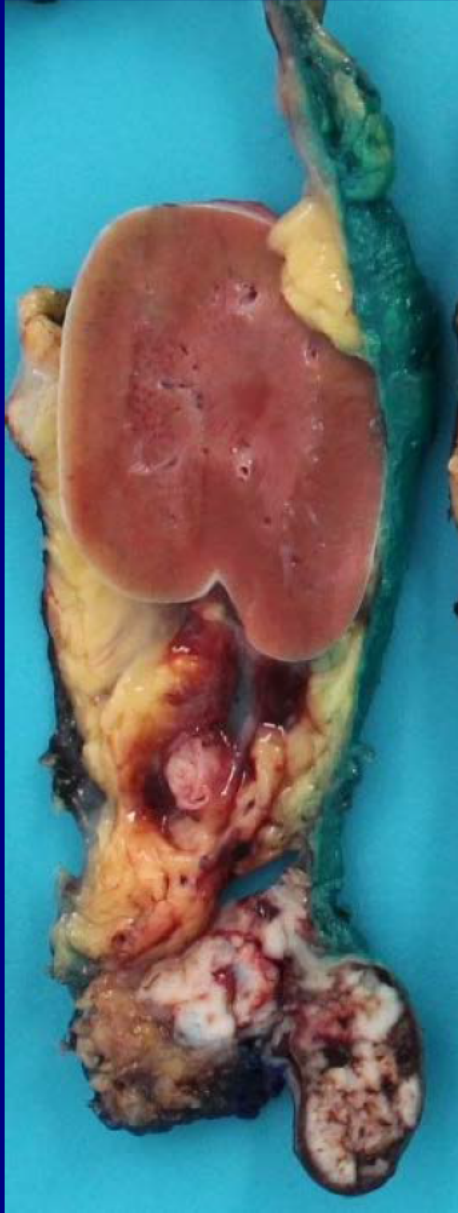



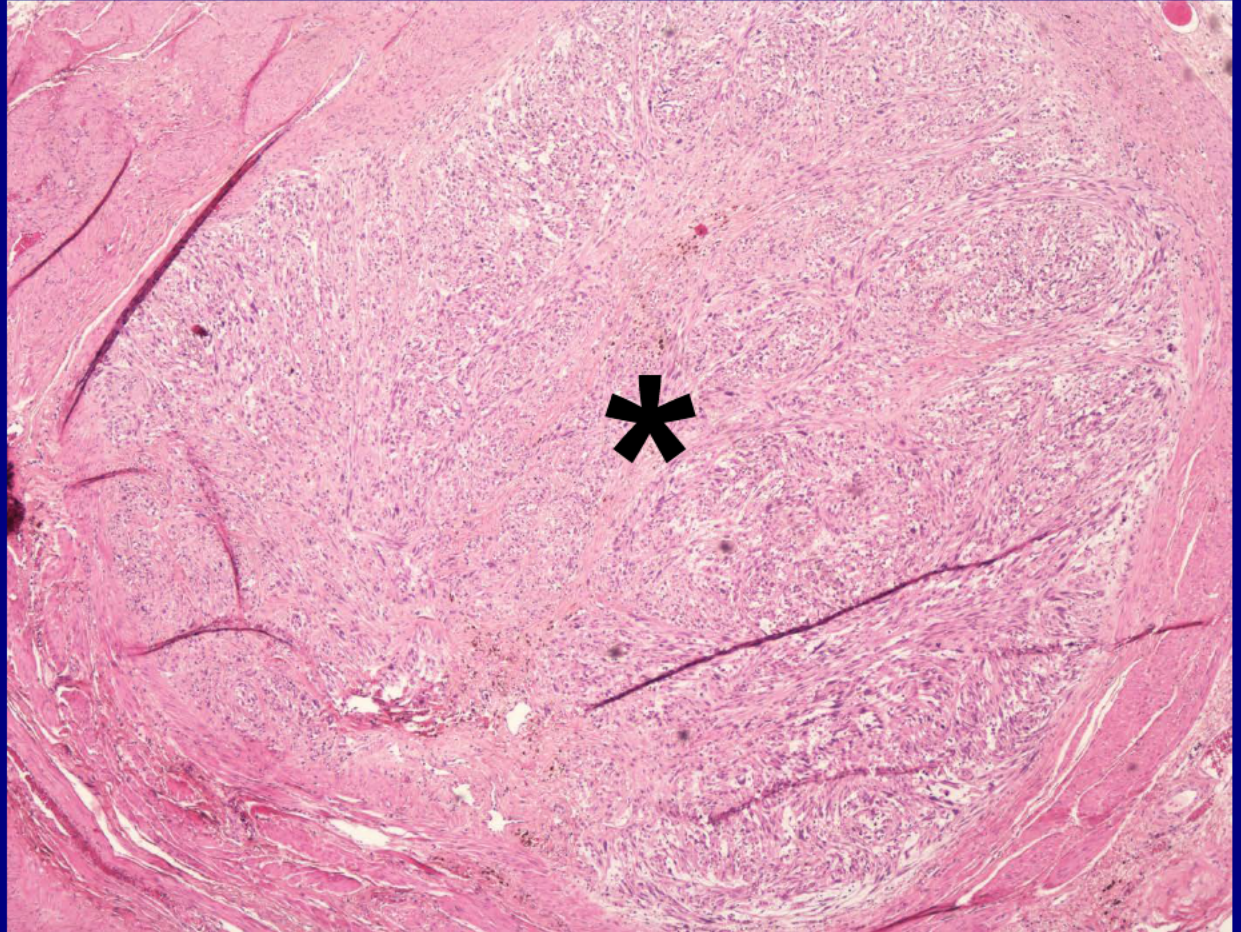

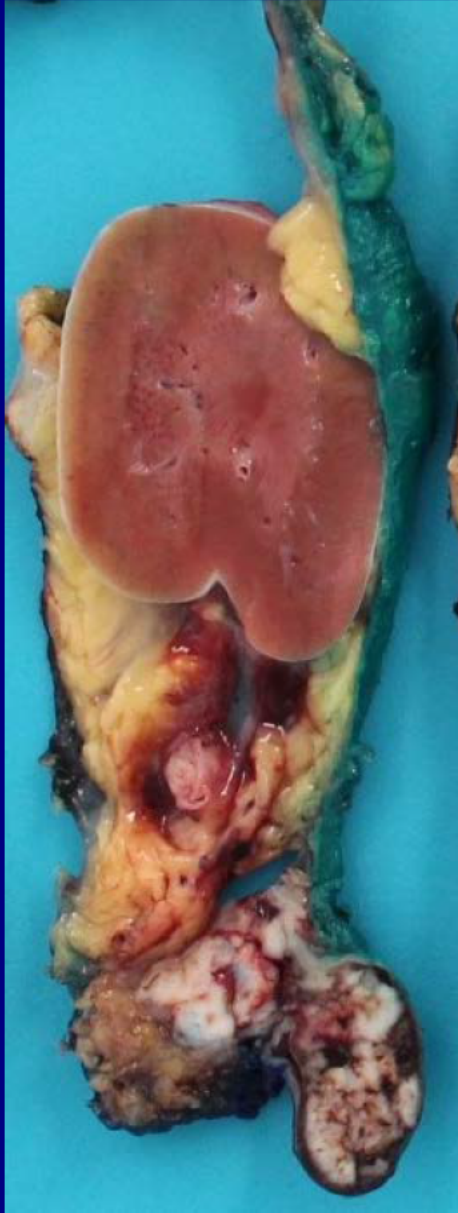


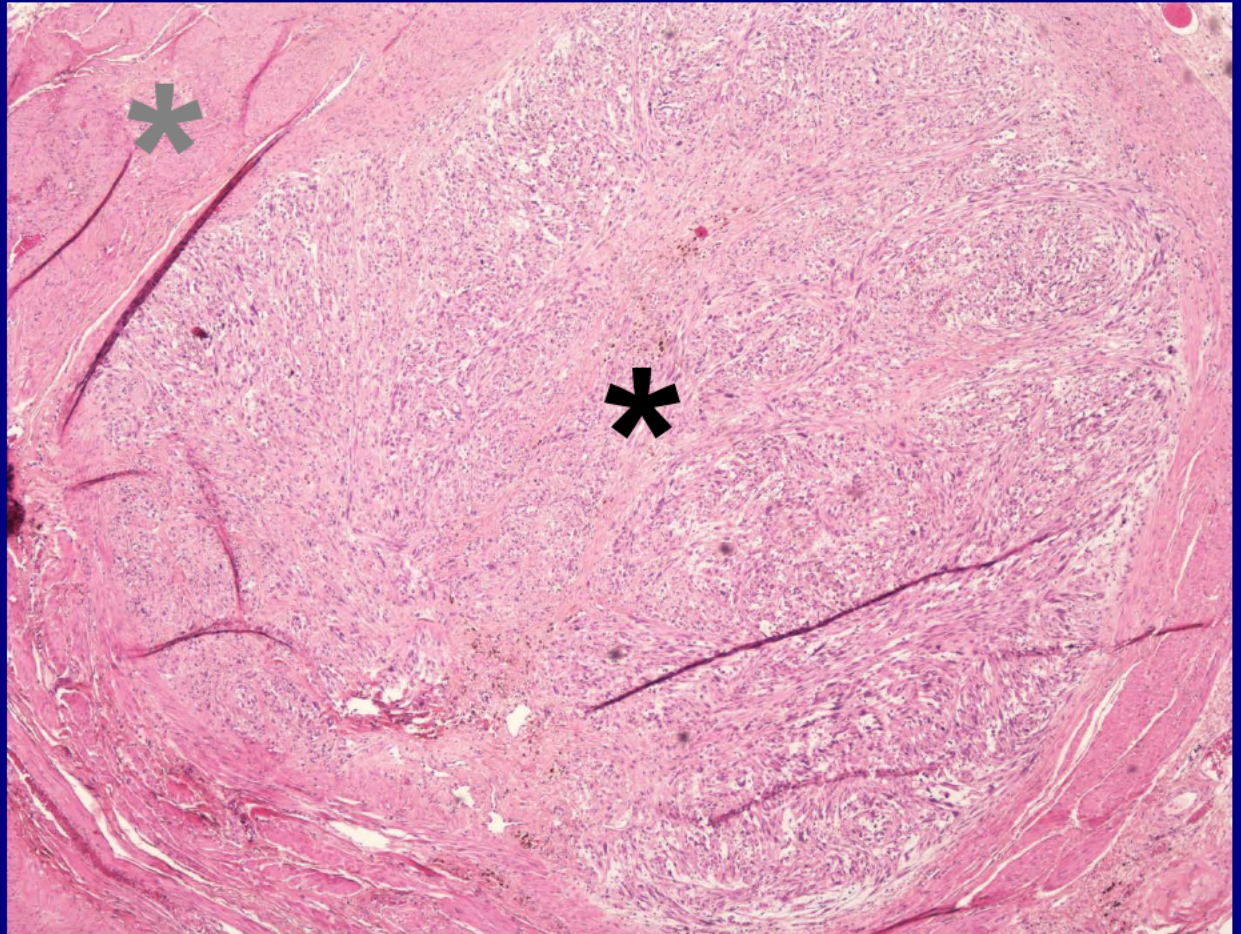


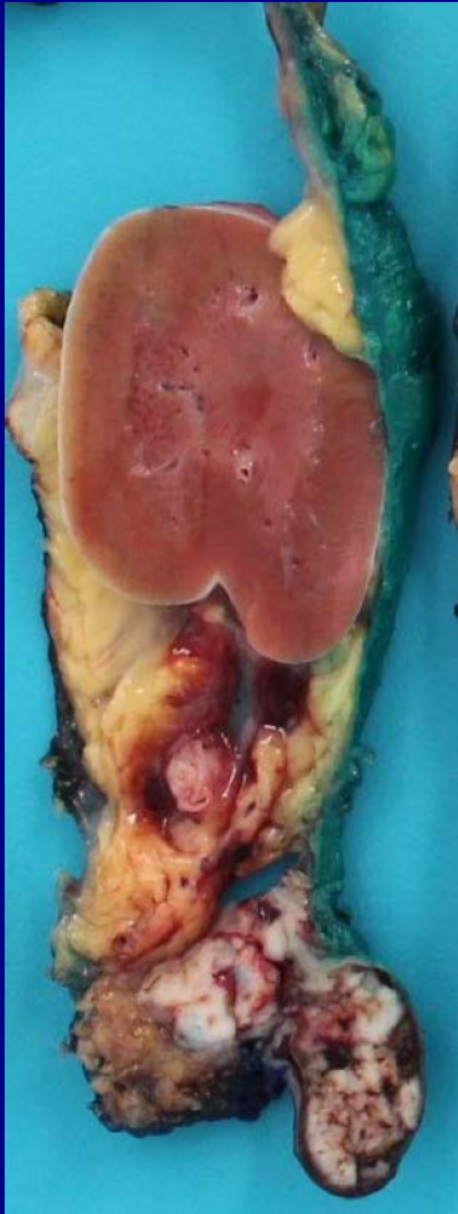

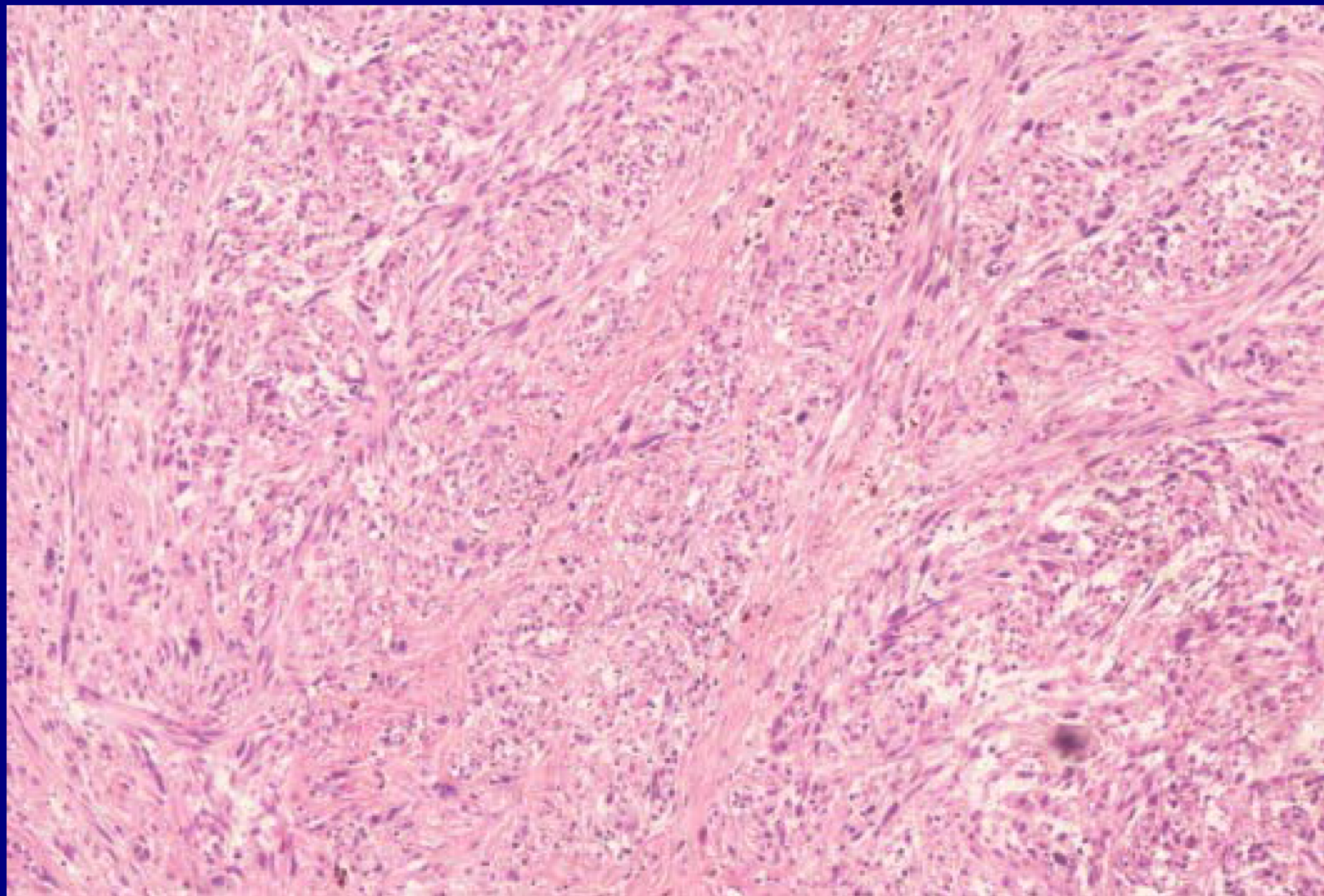




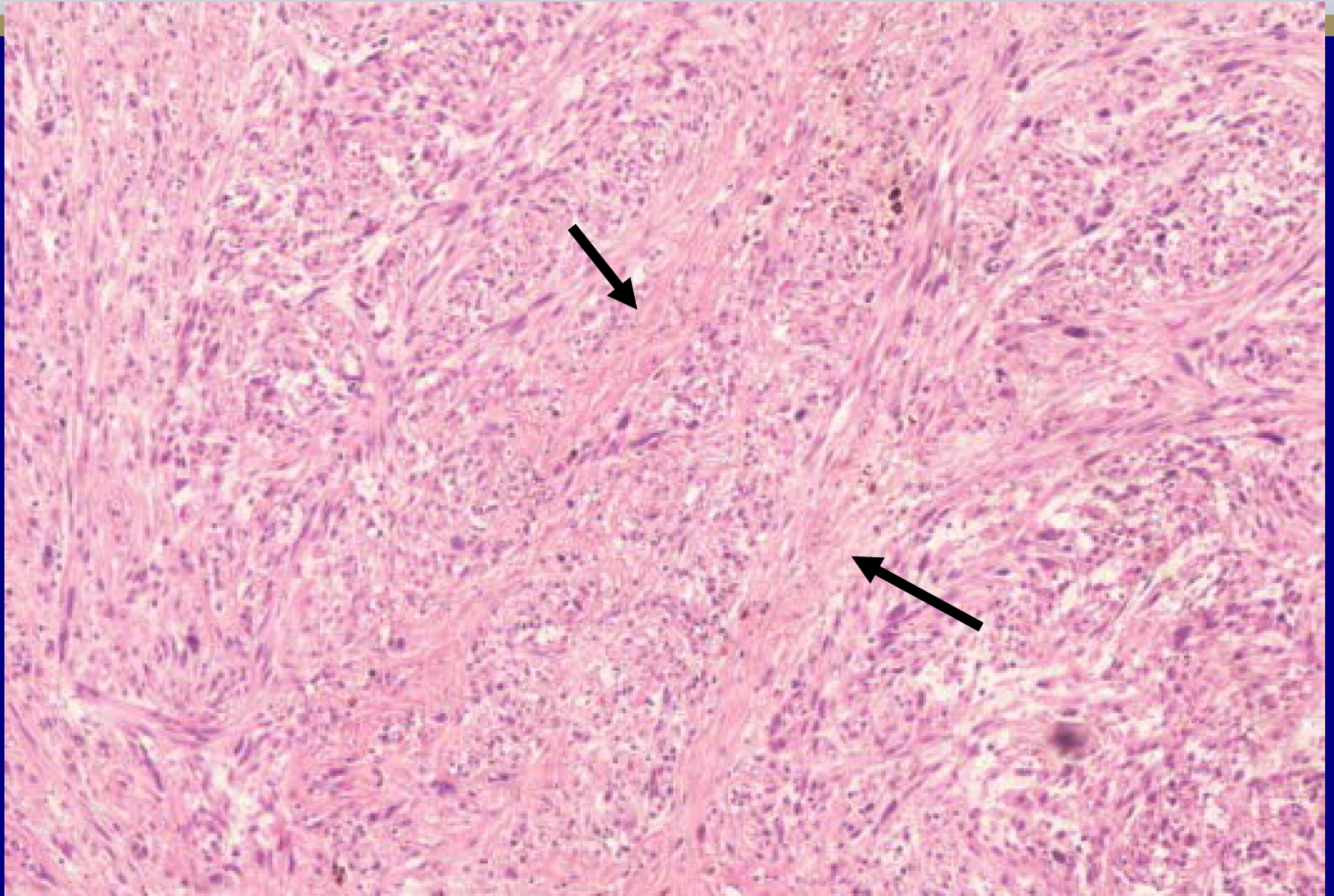




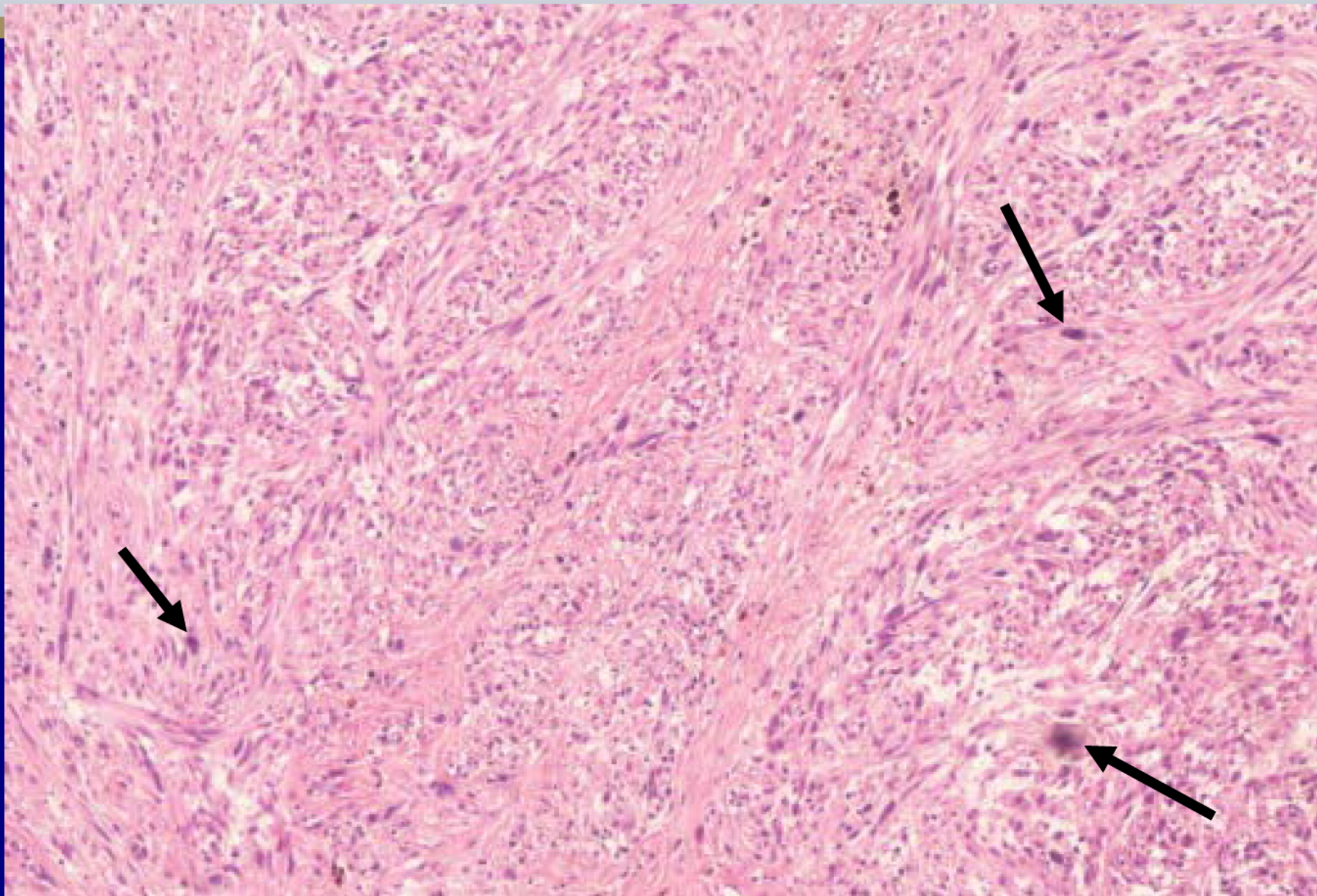












# **Leiomyosarcoma of the left ovarian vein**

**David Rotzinger, MD**

**Centre Hospitalier Universitaire  
Vaudois**

**Lausanne, Switzerland**



**Many thanks to all of you for  
submitting such great cases!  
Have a safe trip home**

**From the staff of the  
American Institute for Radiologic Pathology**