

# Best Cases of the AIRP

July-August, 2019

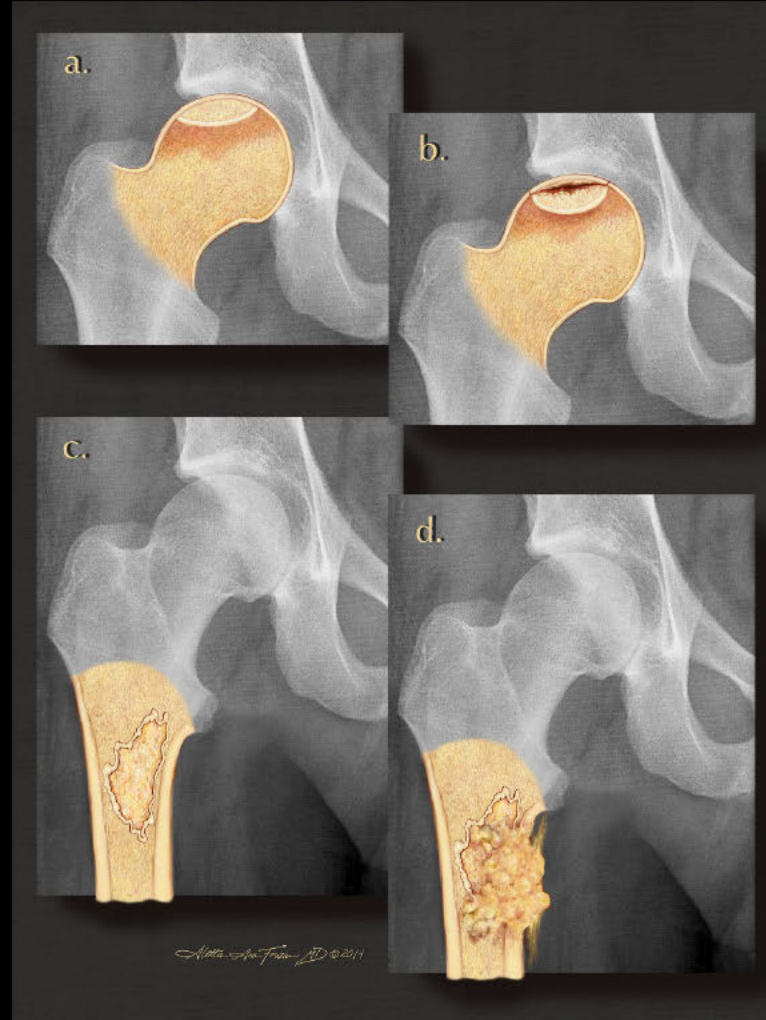
**AIRP**<sup>TM</sup>

AMERICAN INSTITUTE FOR  
RADIOLOGIC PATHOLOGY

---

A PROGRAM OF THE  
AMERICAN COLLEGE OF RADIOLOGY

# Musculoskeletal Best Case



**AIRP**<sup>TM</sup>

AMERICAN INSTITUTE FOR  
RADIOLOGIC PATHOLOGY

A PROGRAM OF THE  
AMERICAN COLLEGE OF RADIOLOGY

# Clinical information

**47-year-old male with left hip pain and  
limp of four-weeks' duration**

**AIRP**<sup>TM</sup>

AMERICAN INSTITUTE FOR  
RADIOLOGIC PATHOLOGY

A PROGRAM OF THE  
AMERICAN COLLEGE OF RADIOLOGY

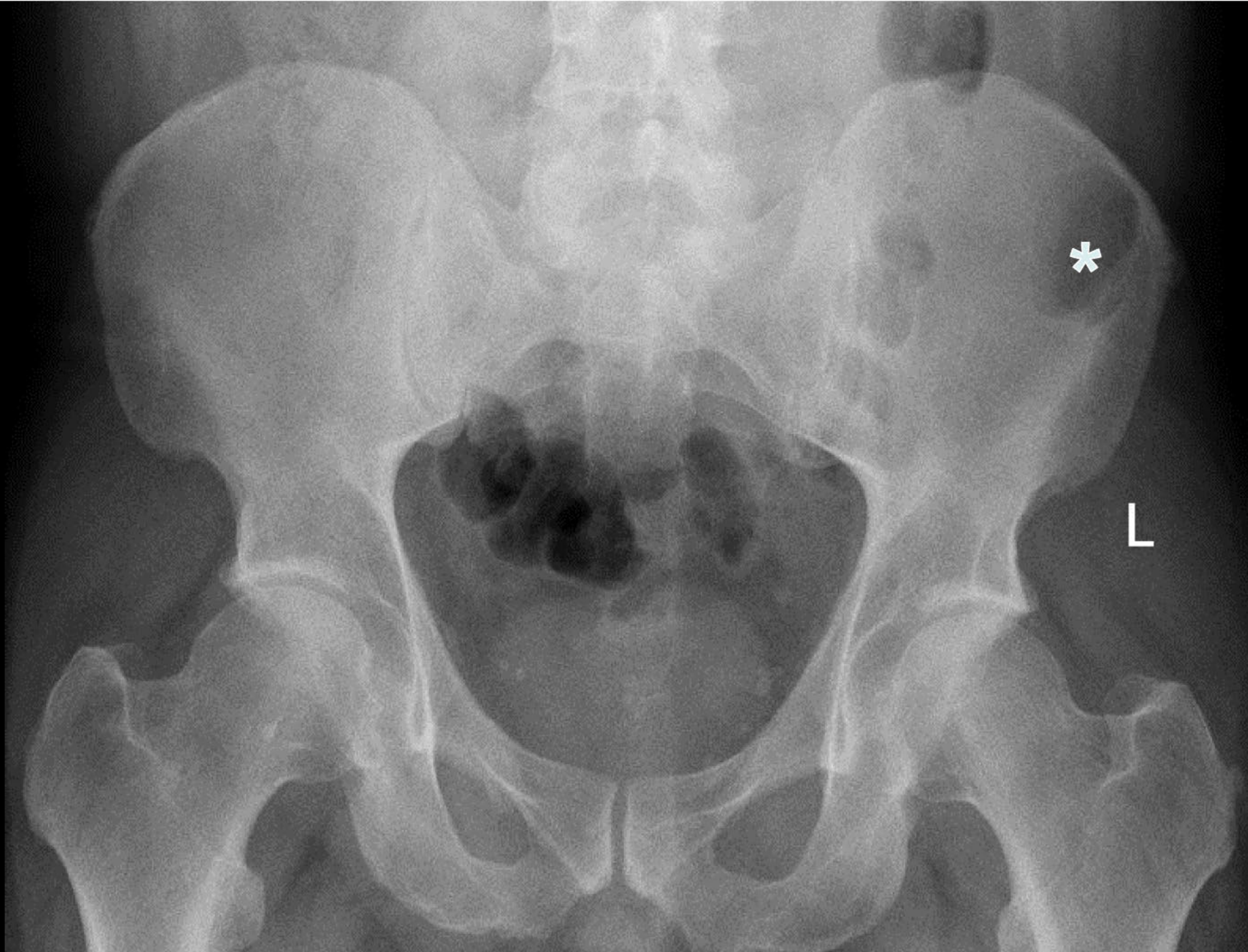


**AIRP**<sup>TM</sup>

AMERICAN INSTITUTE FOR  
RADIOLOGIC PATHOLOGY

A PROGRAM OF THE  
AMERICAN COLLEGE OF RADIOLOGY

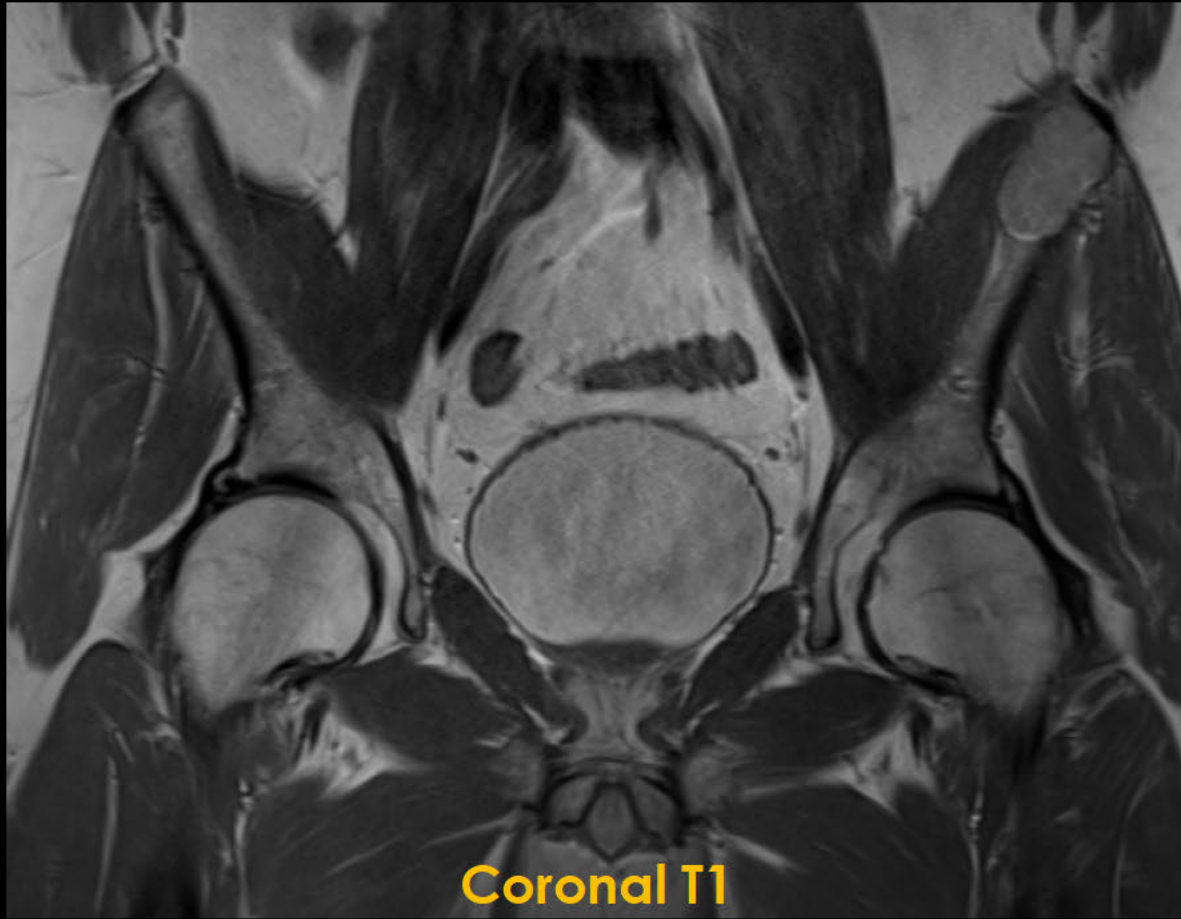




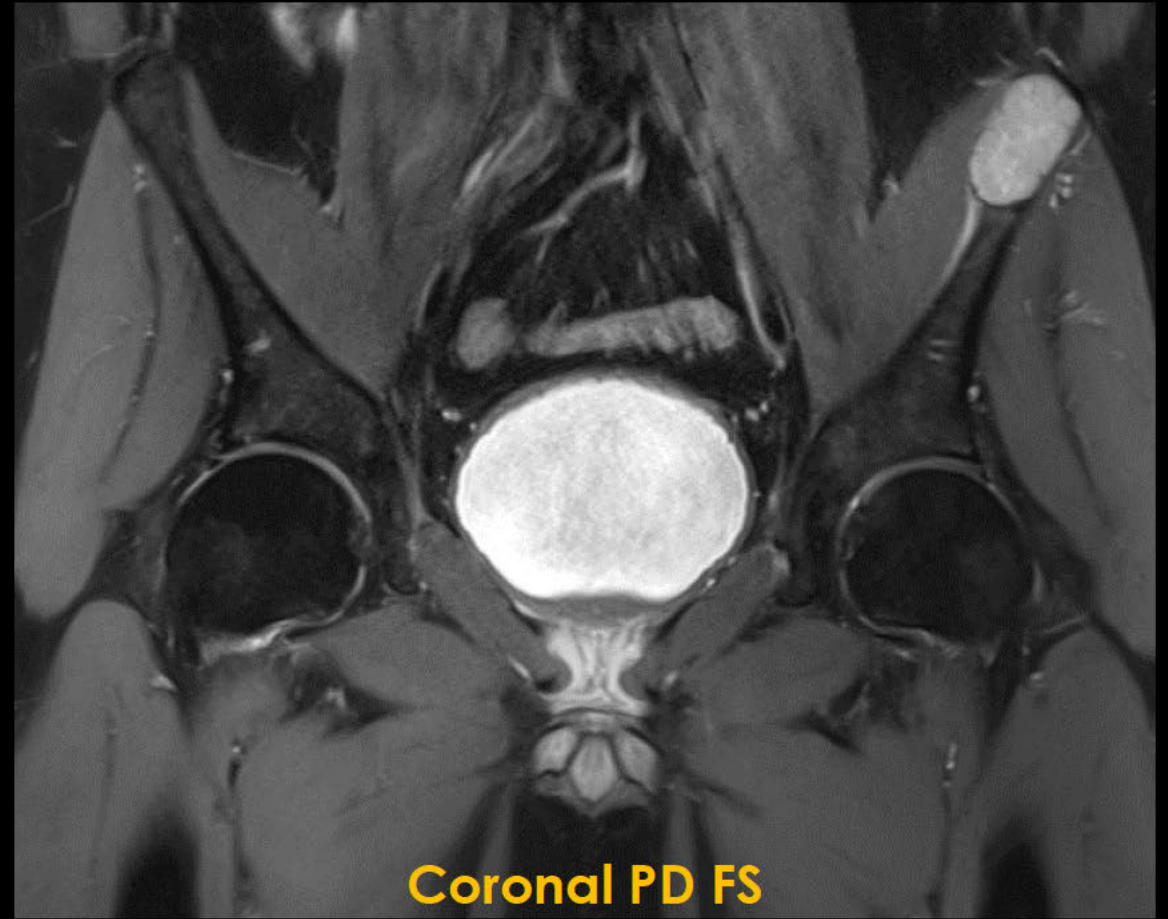
**AIRP**<sup>TM</sup>

AMERICAN INSTITUTE FOR  
RADIOLOGIC PATHOLOGY

A PROGRAM OF THE  
AMERICAN COLLEGE OF RADIOLOGY



Coronal T1



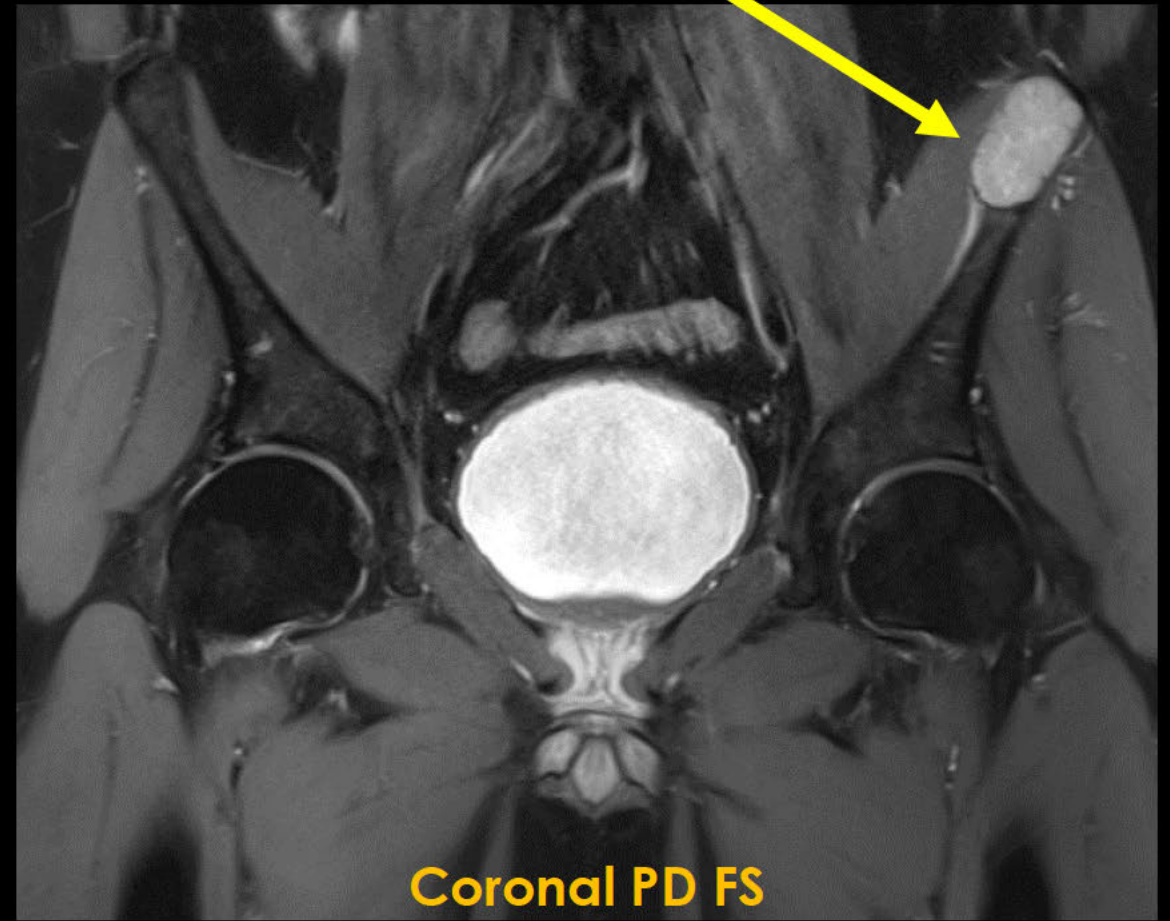
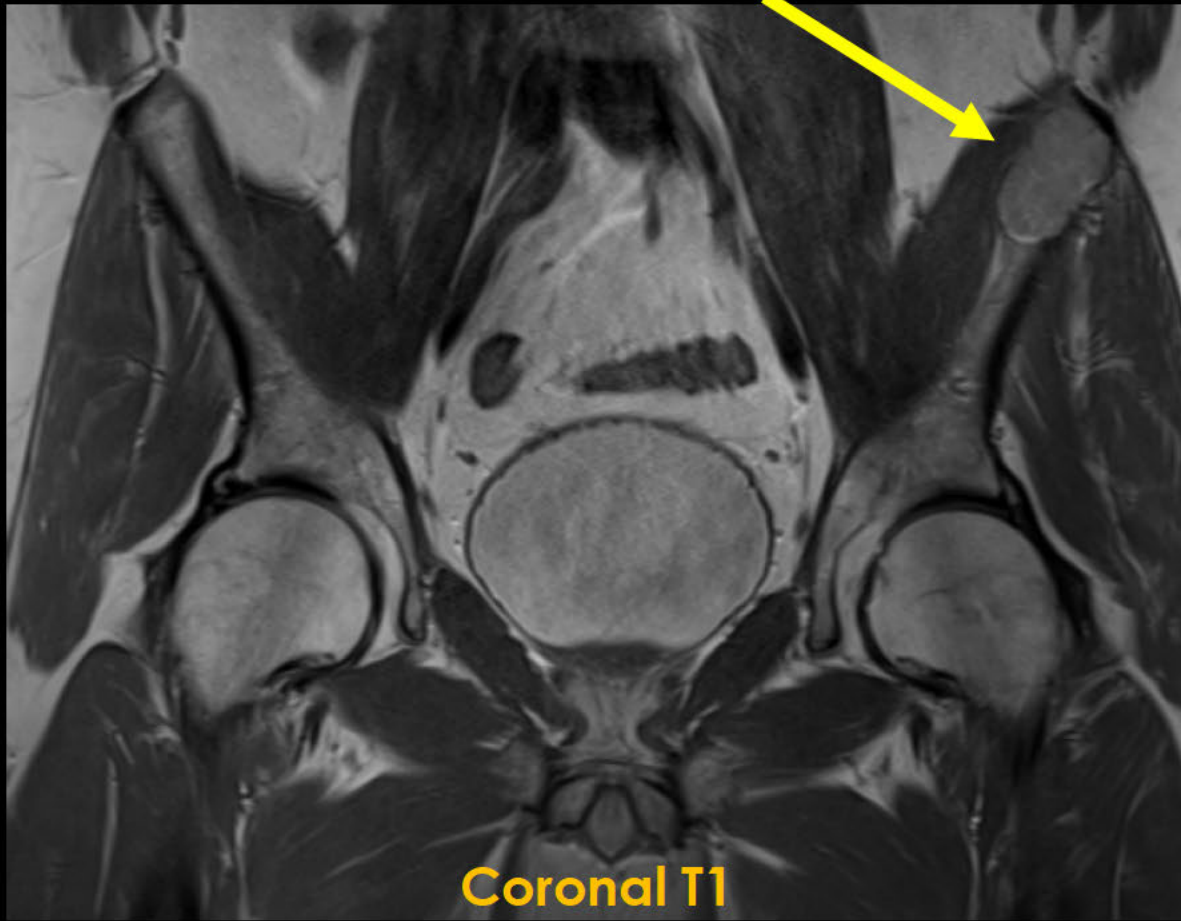
Coronal PD FS

**AIRP**<sup>TM</sup>

AMERICAN INSTITUTE FOR  
RADIOLOGIC PATHOLOGY

A PROGRAM OF THE  
AMERICAN COLLEGE OF RADIOLOGY

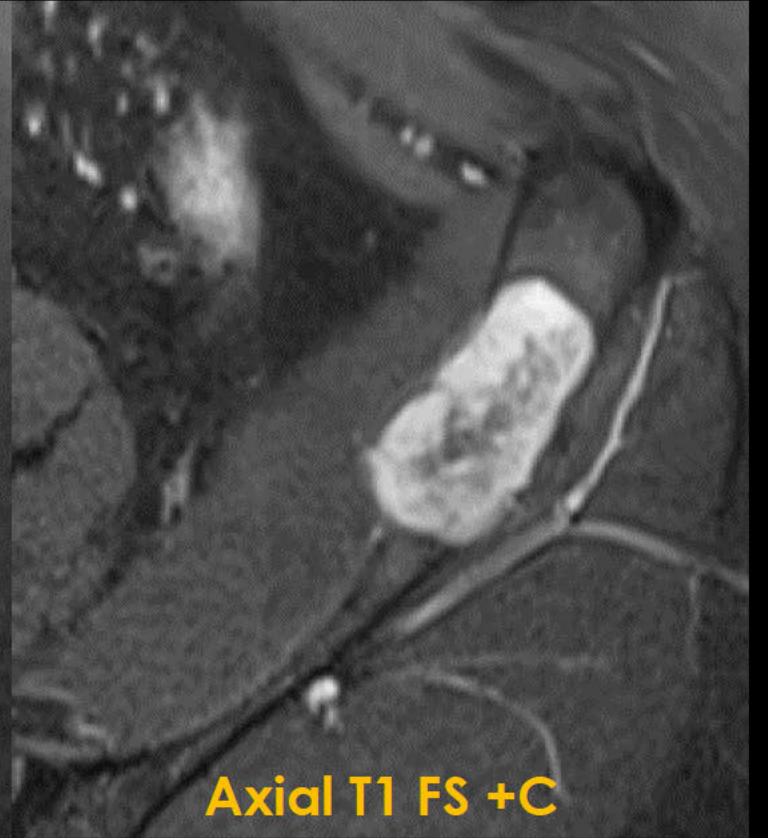
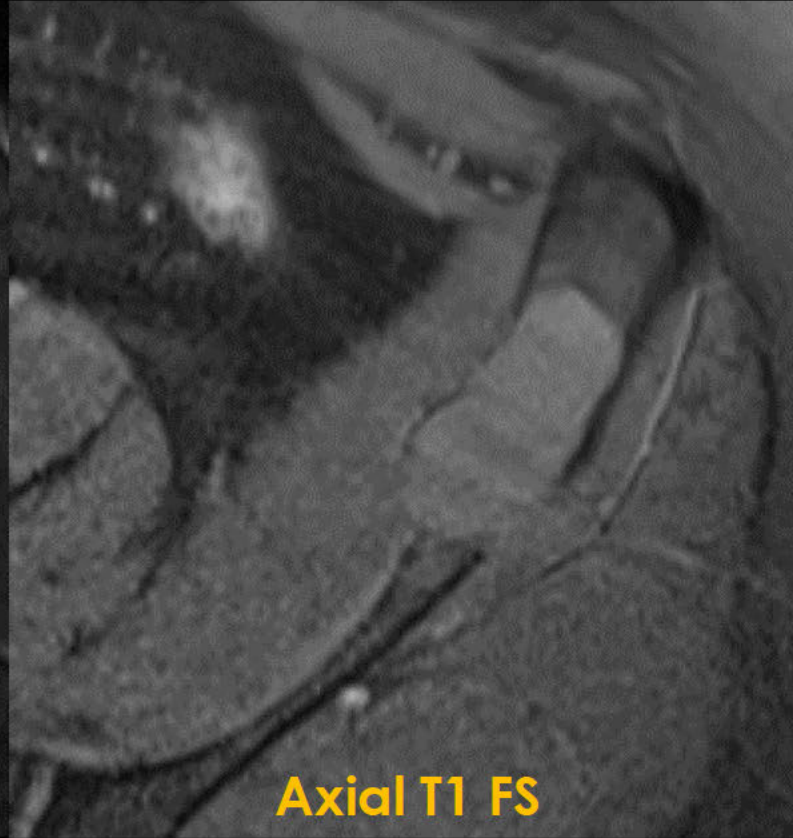
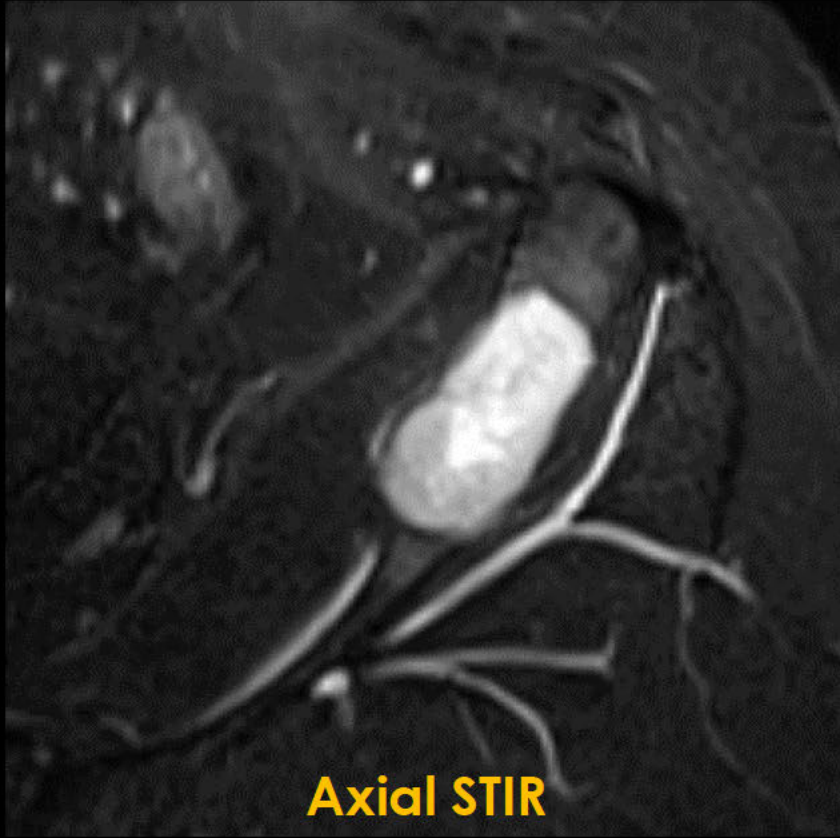


**AIRP**<sup>TM</sup>

AMERICAN INSTITUTE FOR  
RADIOLOGIC PATHOLOGY

A PROGRAM OF THE  
AMERICAN COLLEGE OF RADIOLOGY

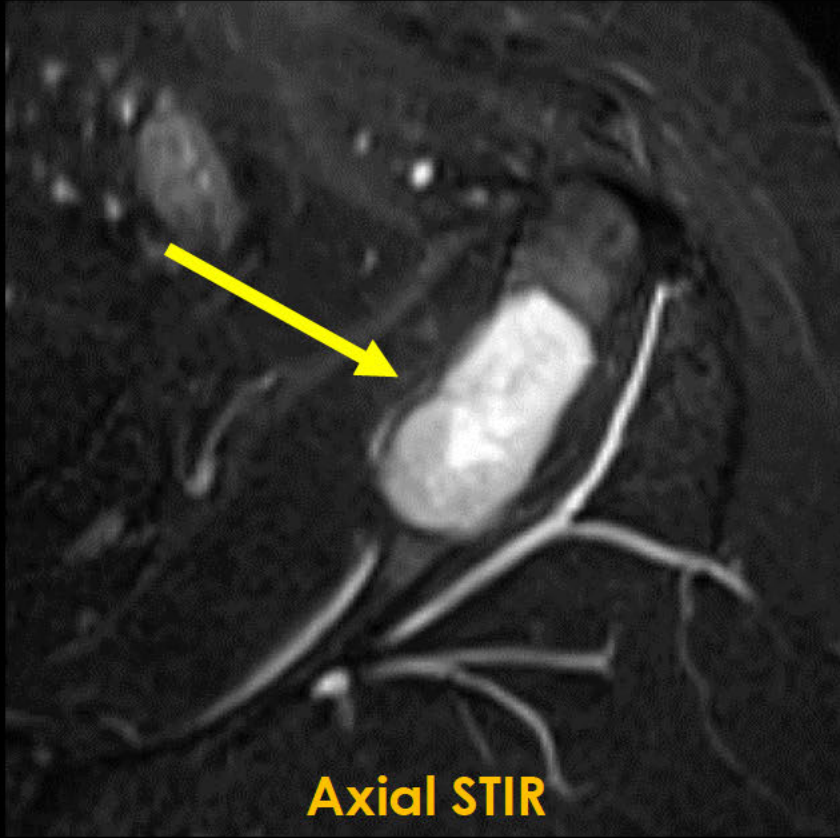


**AIRP**<sup>TM</sup>

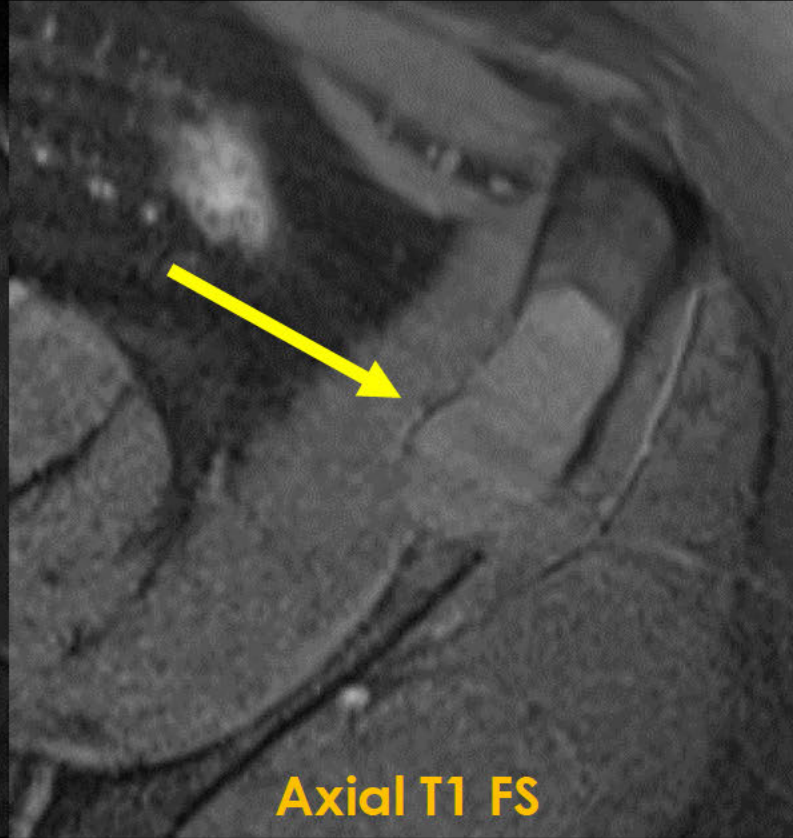
AMERICAN INSTITUTE FOR  
RADIOLOGIC PATHOLOGY

A PROGRAM OF THE  
AMERICAN COLLEGE OF RADIOLOGY

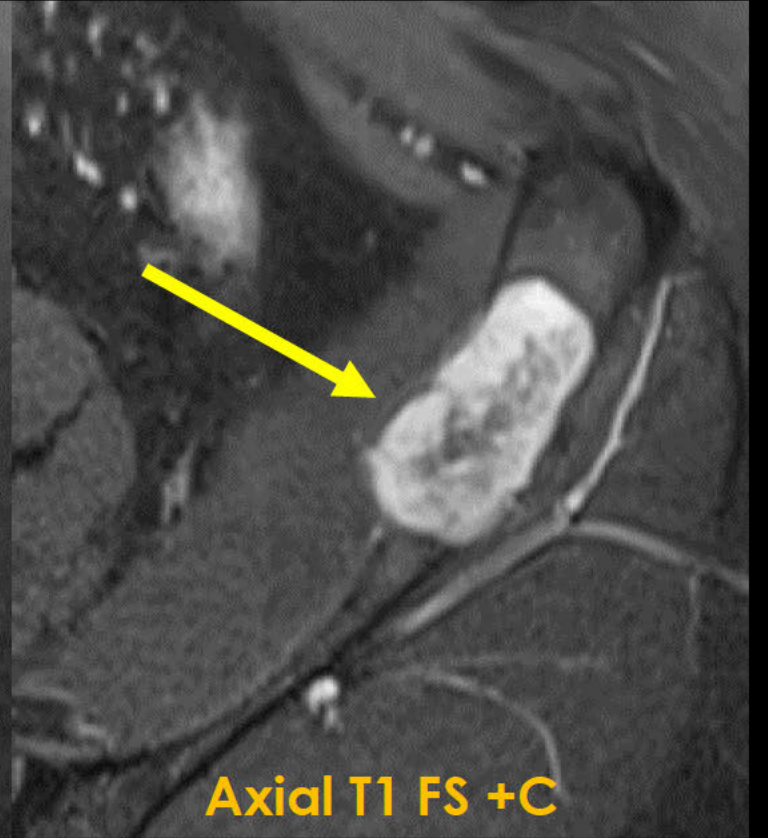



**Axial STIR**



**Axial T1 FS**



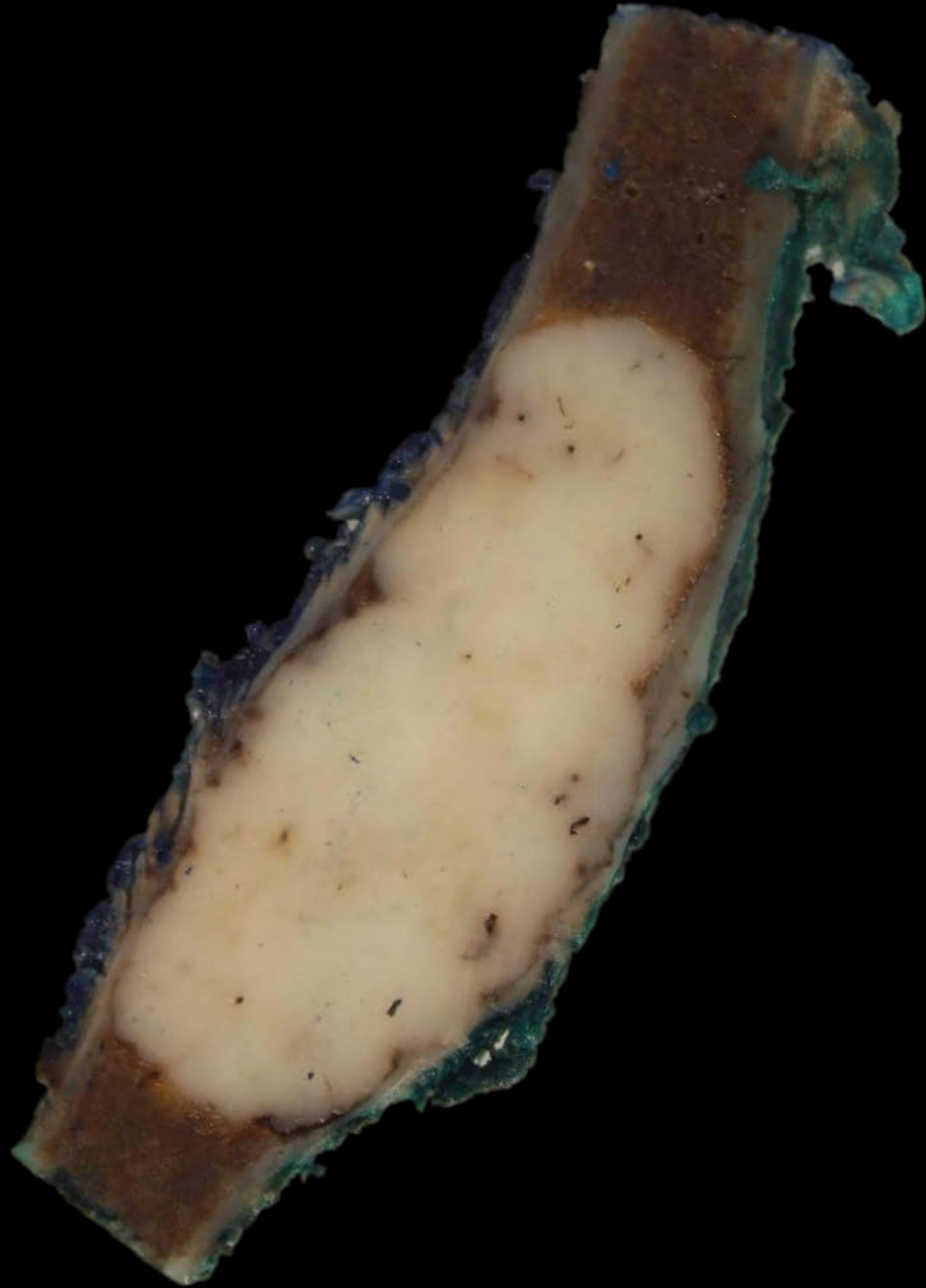**Axial T1 FS +C**

**AIRP**<sup>TM</sup>

AMERICAN INSTITUTE FOR  
RADIOLOGIC PATHOLOGY

A PROGRAM OF THE  
AMERICAN COLLEGE OF RADIOLOGY

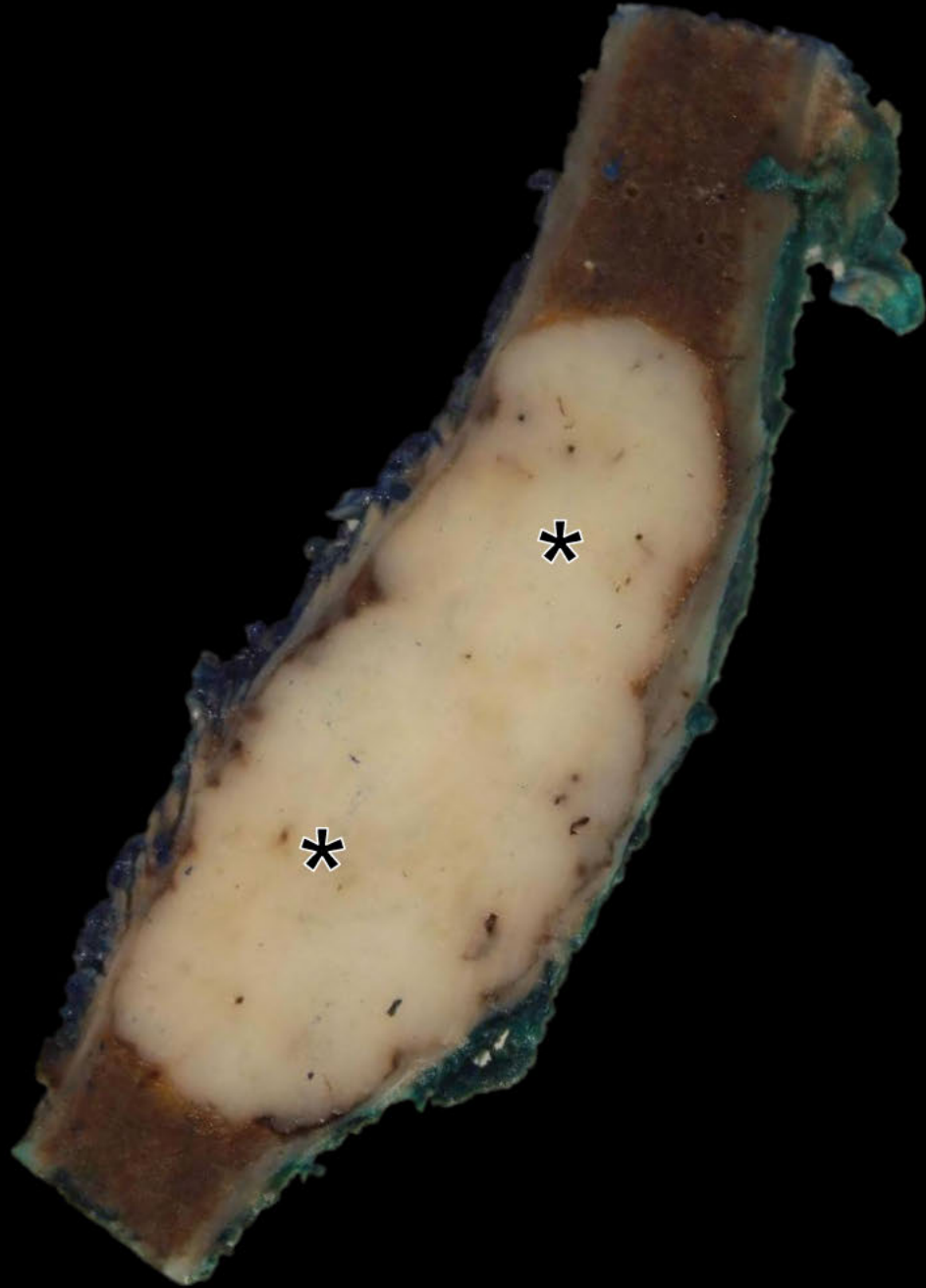



**AIRP**<sup>TM</sup>

AMERICAN INSTITUTE FOR  
RADIOLOGIC PATHOLOGY

A PROGRAM OF THE  
AMERICAN COLLEGE OF RADIOLOGY

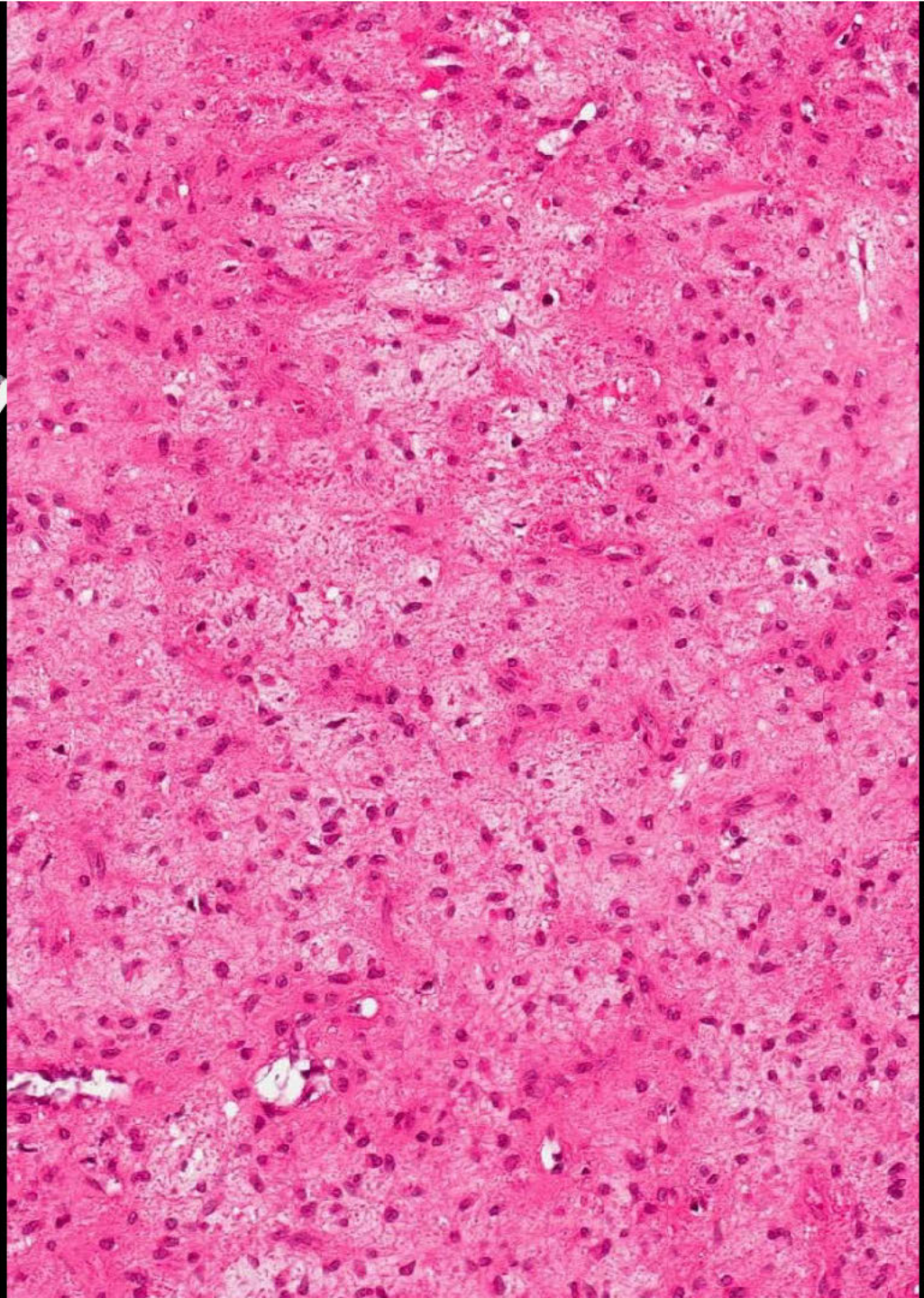
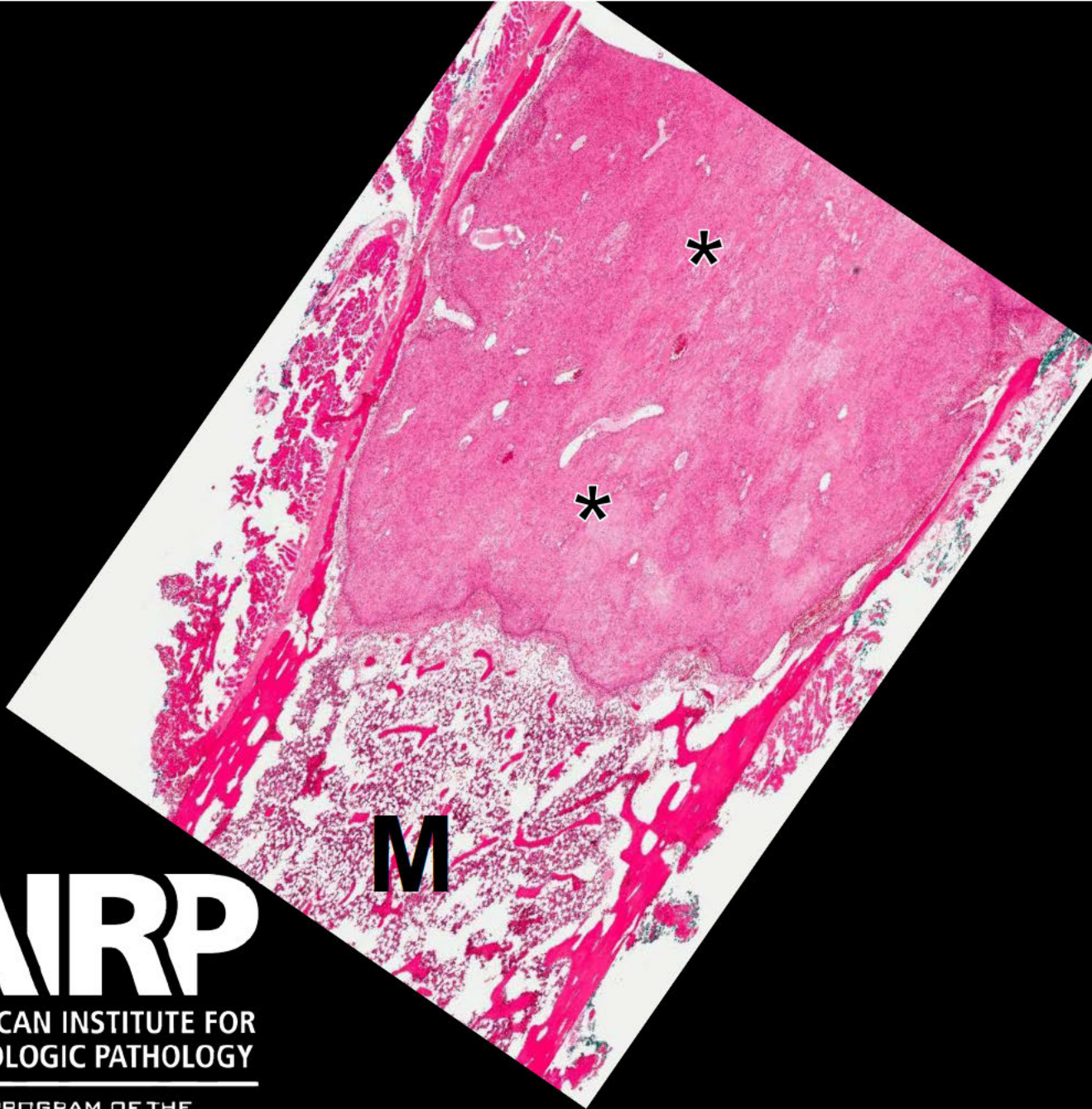


**AIRP**<sup>TM</sup>

AMERICAN INSTITUTE FOR  
RADIOLOGIC PATHOLOGY

A PROGRAM OF THE  
AMERICAN COLLEGE OF RADIOLOGY



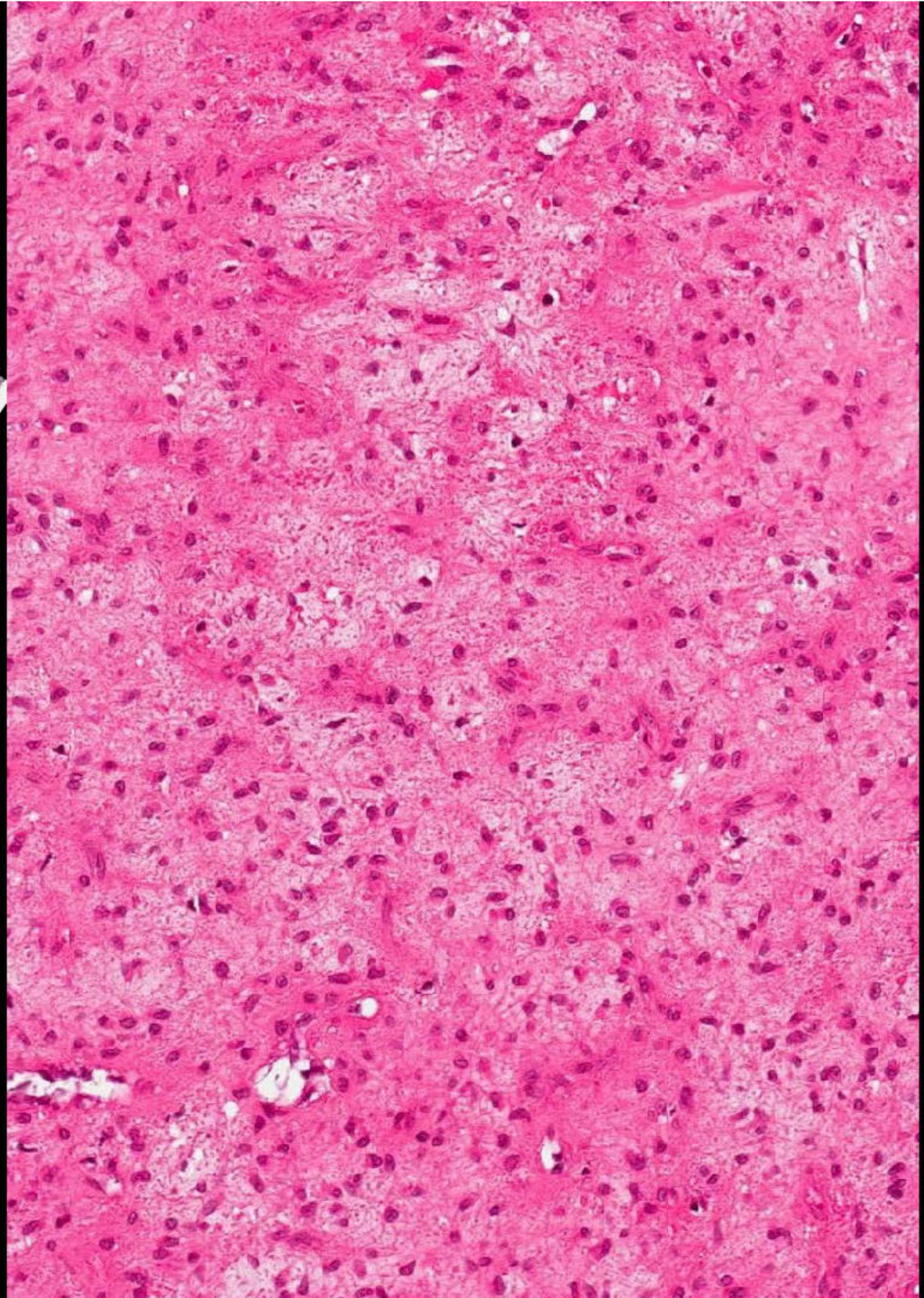
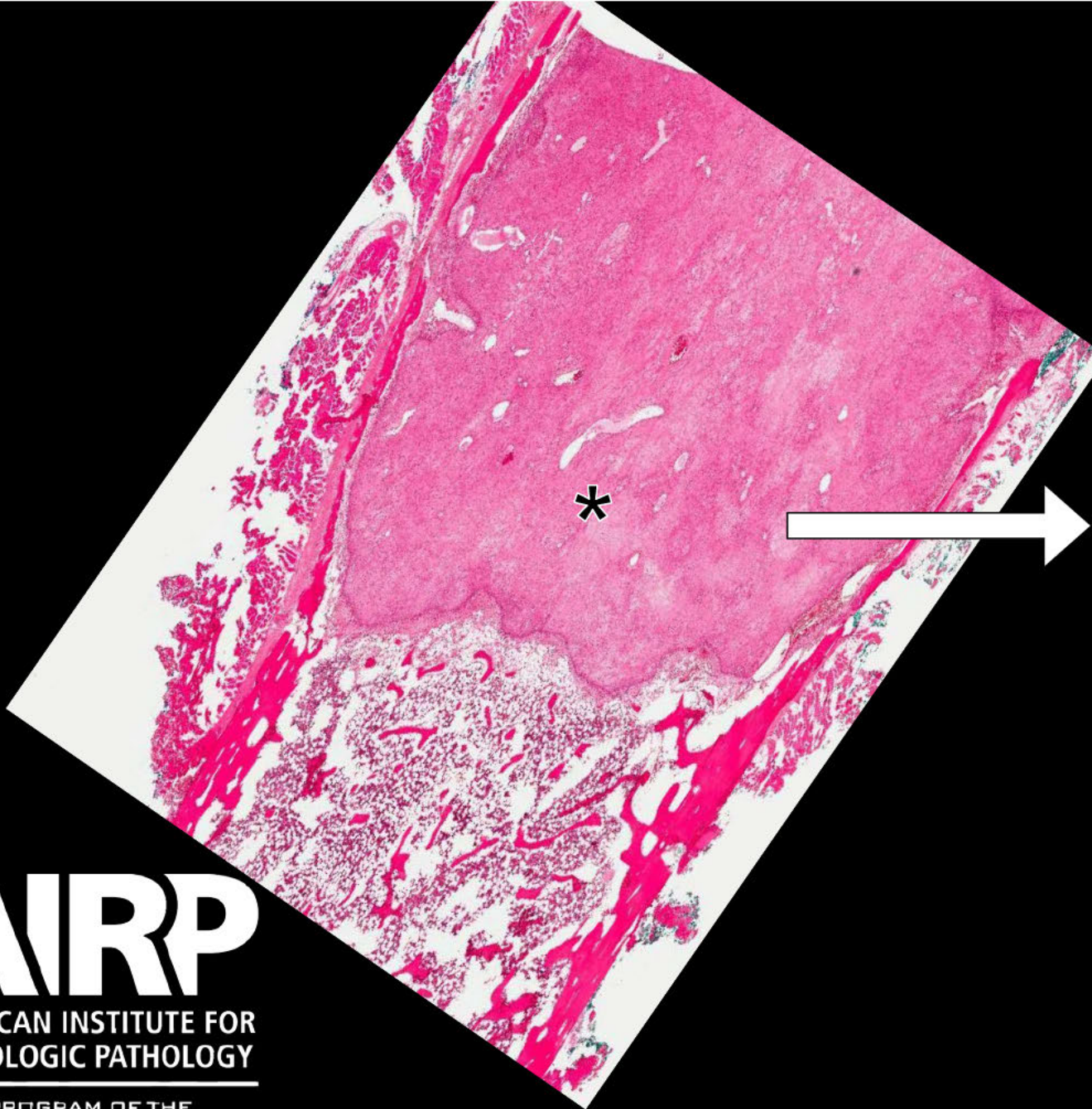


**AIRP**

AMERICAN INSTITUTE FOR  
RADIOLOGIC PATHOLOGY

A PROGRAM OF THE  
AMERICAN COLLEGE OF RADIOLOGY



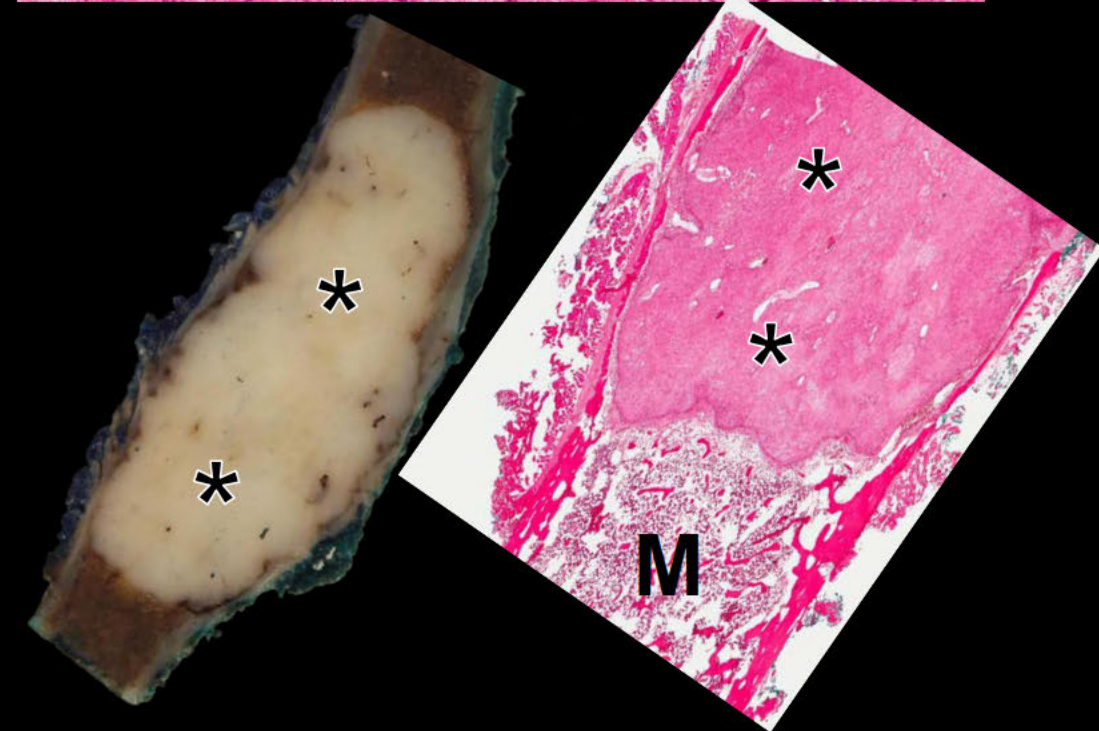
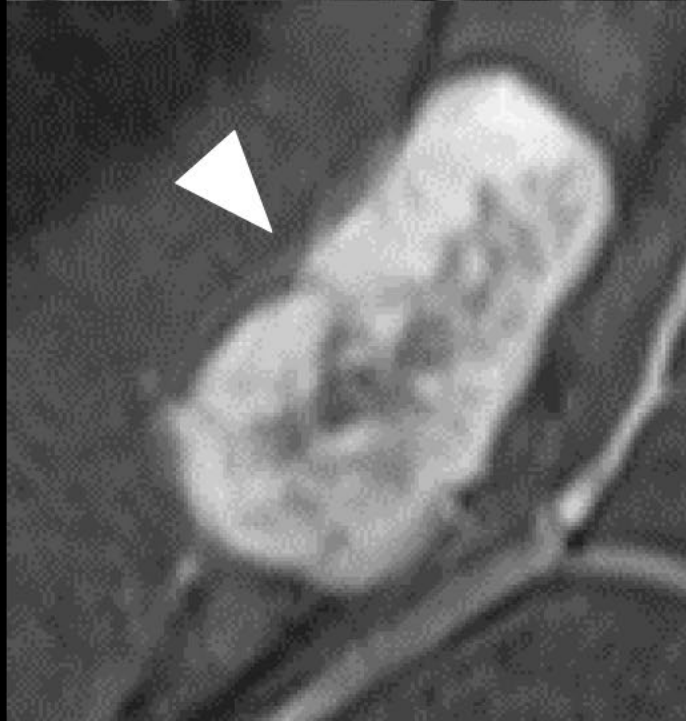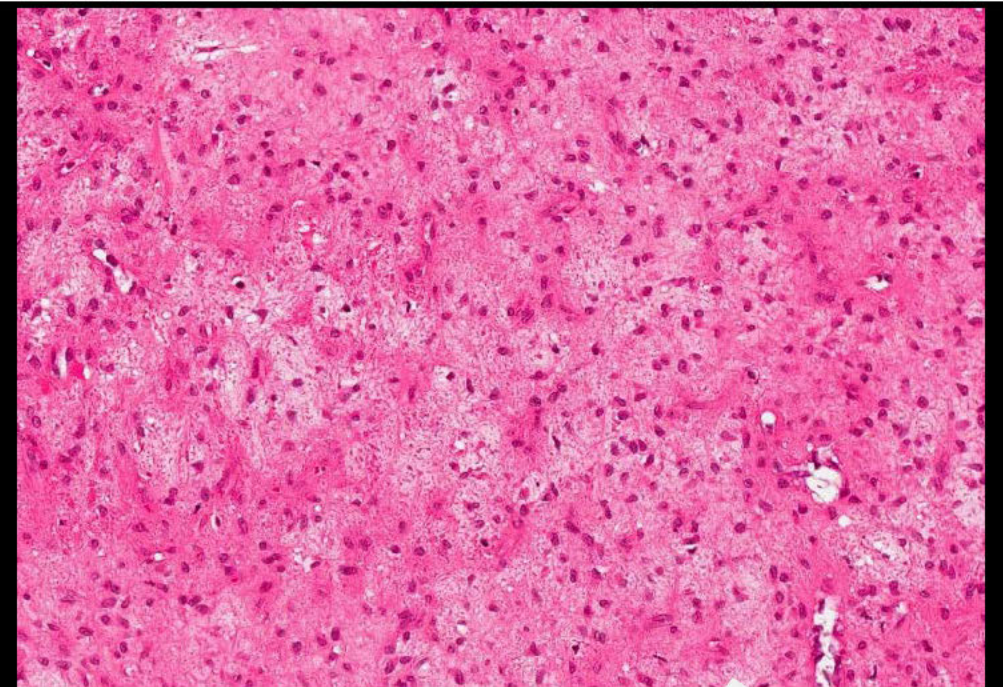

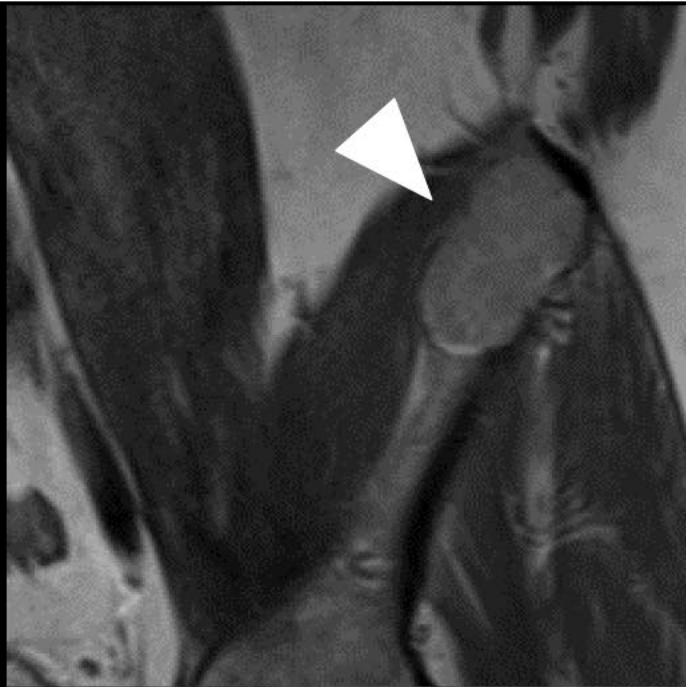
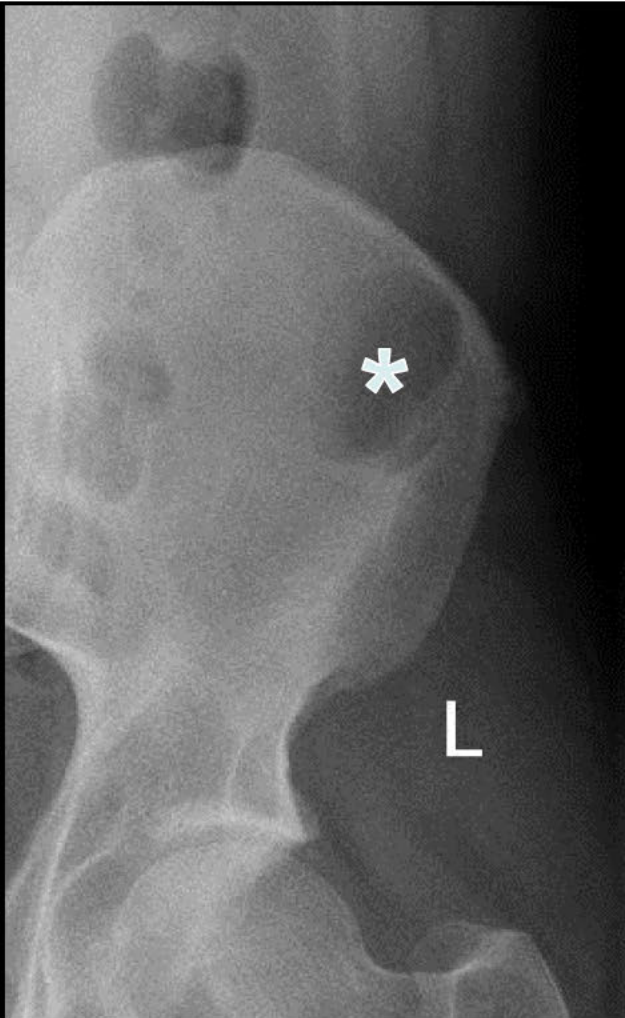# AIRP

AMERICAN INSTITUTE FOR  
RADIOLOGIC PATHOLOGY

A PROGRAM OF THE  
AMERICAN COLLEGE OF RADIOLOGY





**AIRP**<sup>TM</sup>

AMERICAN INSTITUTE FOR  
RADIOLOGIC PATHOLOGY

A PROGRAM OF THE  
AMERICAN COLLEGE OF RADIOLOGY



# Chondromyxoid Fibroma

**Dr. Anton Lavell**

**Western Australia Radiology Training Scheme**

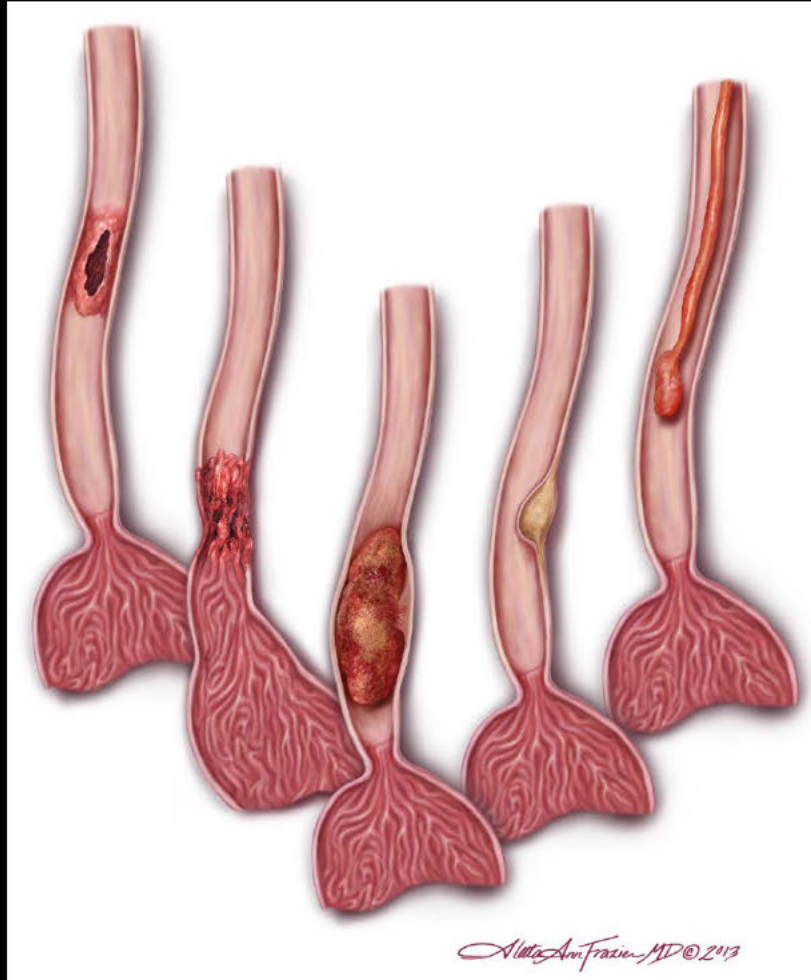
**Perth, Australia**

**AIRP**<sup>TM</sup>

AMERICAN INSTITUTE FOR  
RADIOLOGIC PATHOLOGY

A PROGRAM OF THE  
AMERICAN COLLEGE OF RADIOLOGY

# Gastrointestinal Best Case



**AIRP**<sup>TM</sup>

AMERICAN INSTITUTE FOR  
RADIOLOGIC PATHOLOGY

A PROGRAM OF THE  
AMERICAN COLLEGE OF RADIOLOGY

# Clinical information

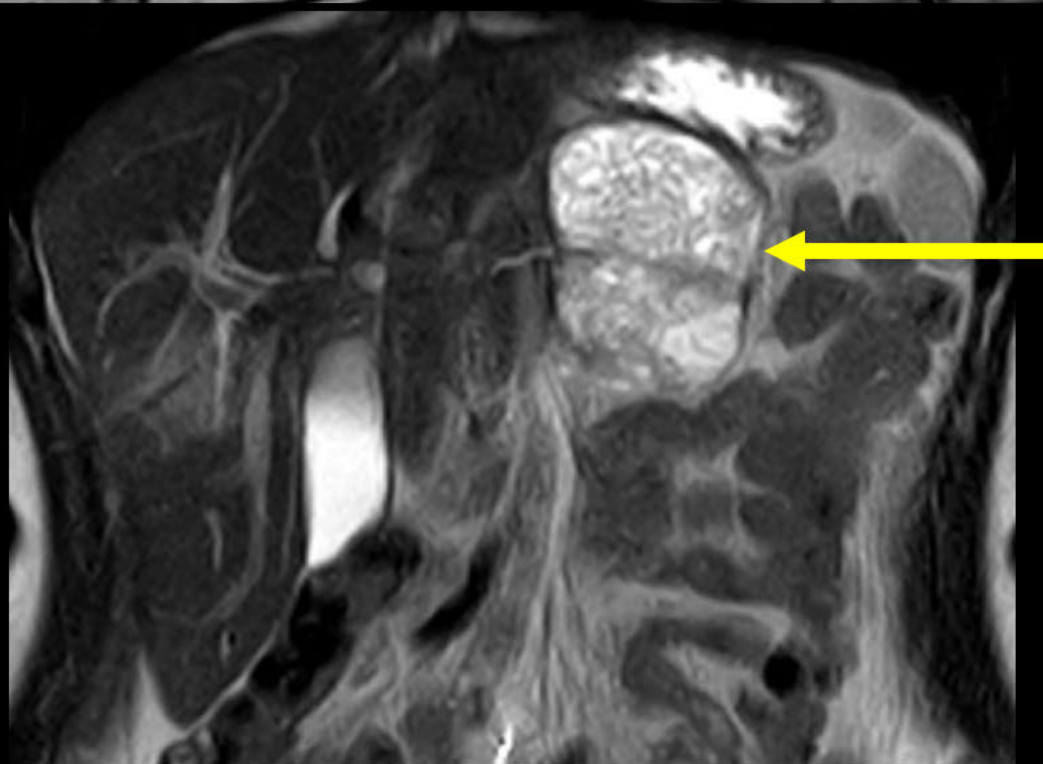
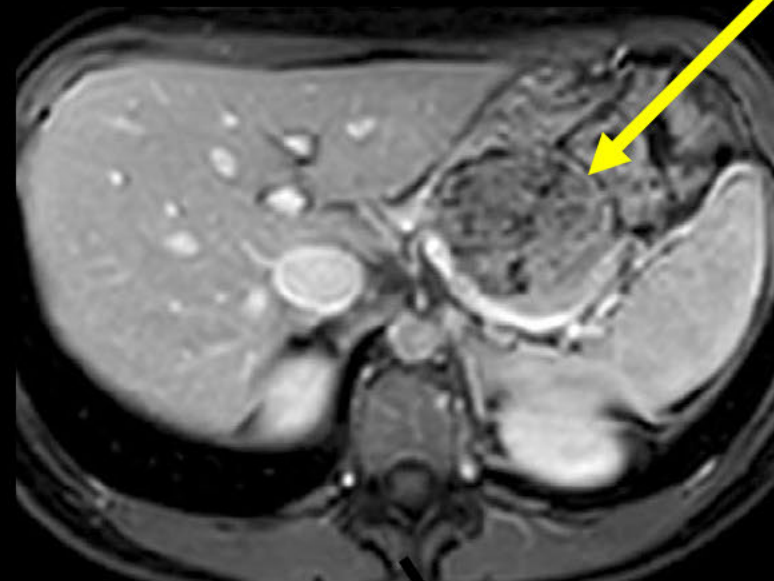
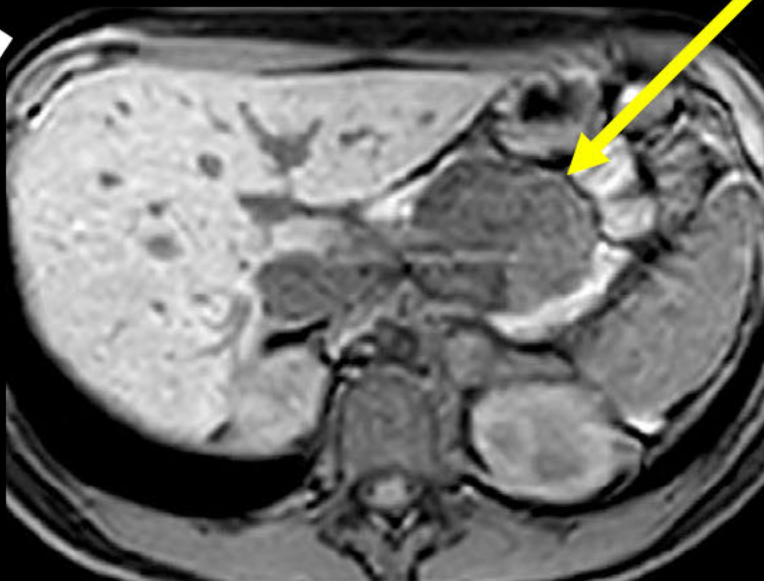
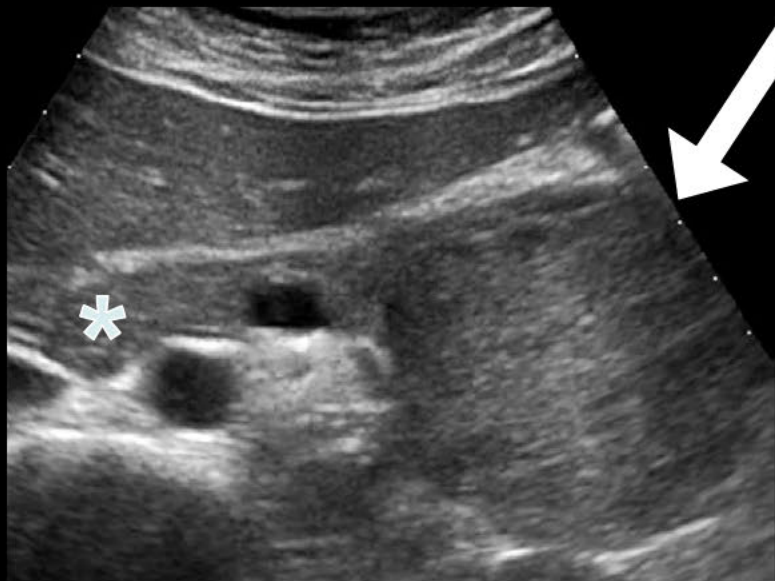**41-year-old woman with 1 month of intermittent epigastric pain.**



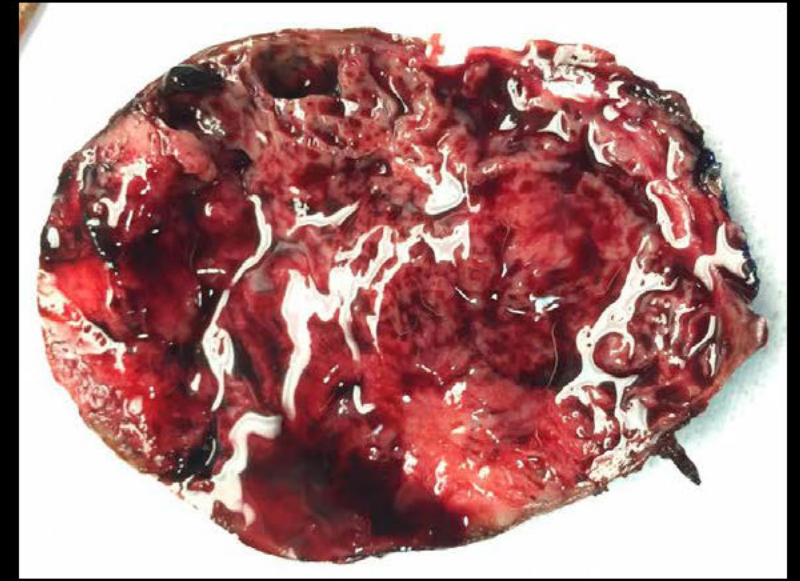
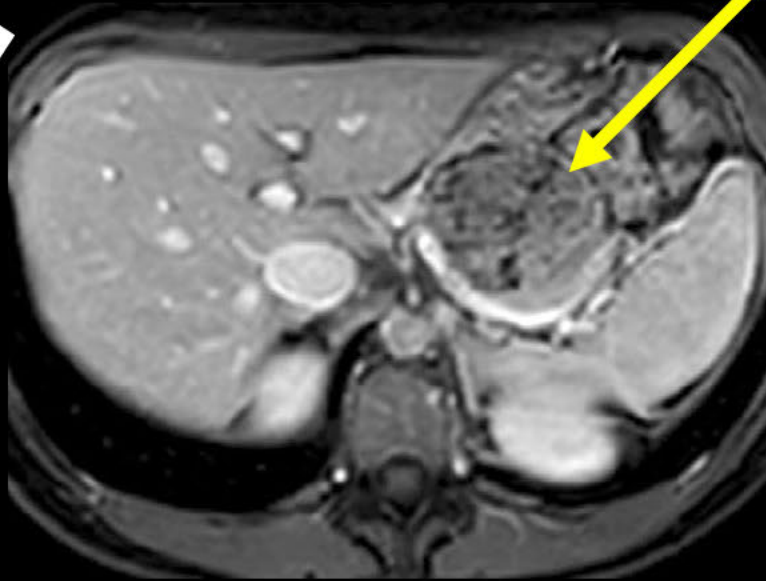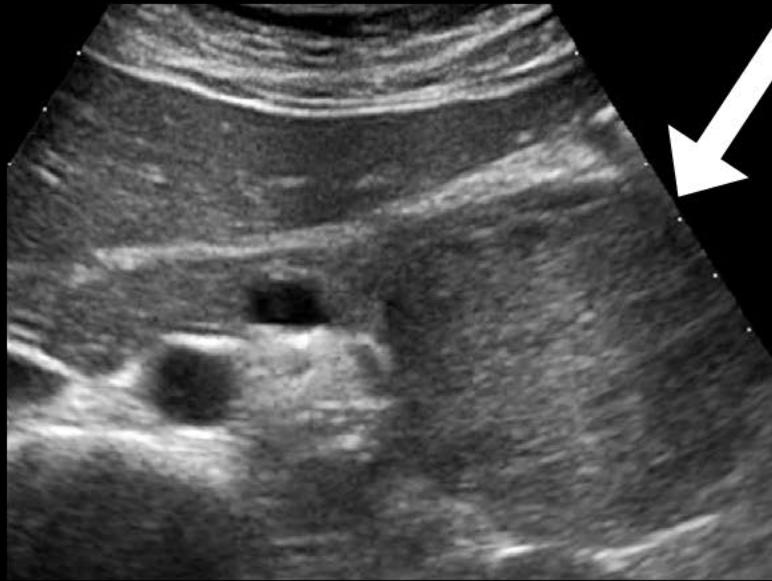AMERICAN INSTITUTE FOR  
RADIOLOGIC PATHOLOGY

---

A PROGRAM OF THE  
AMERICAN COLLEGE OF RADIOLOGY





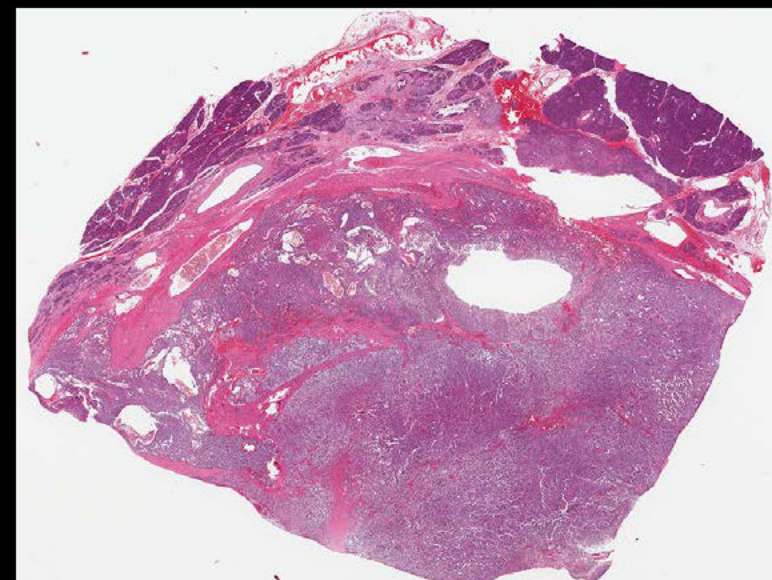
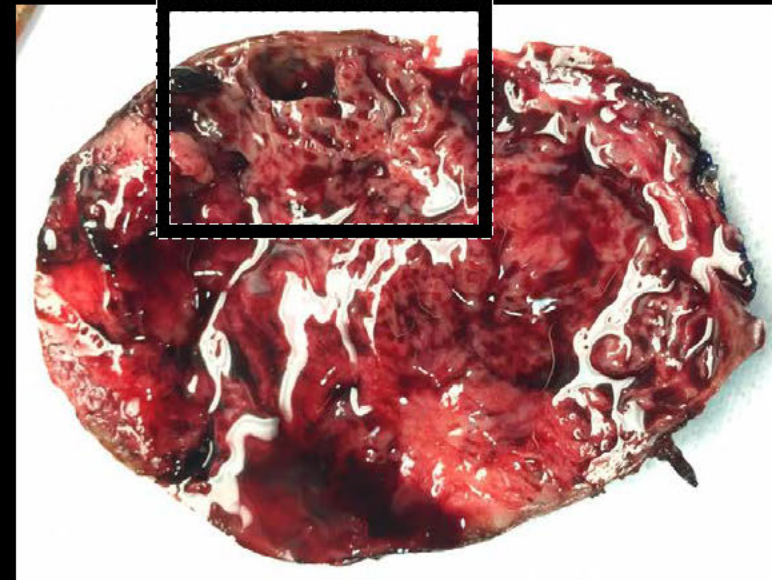
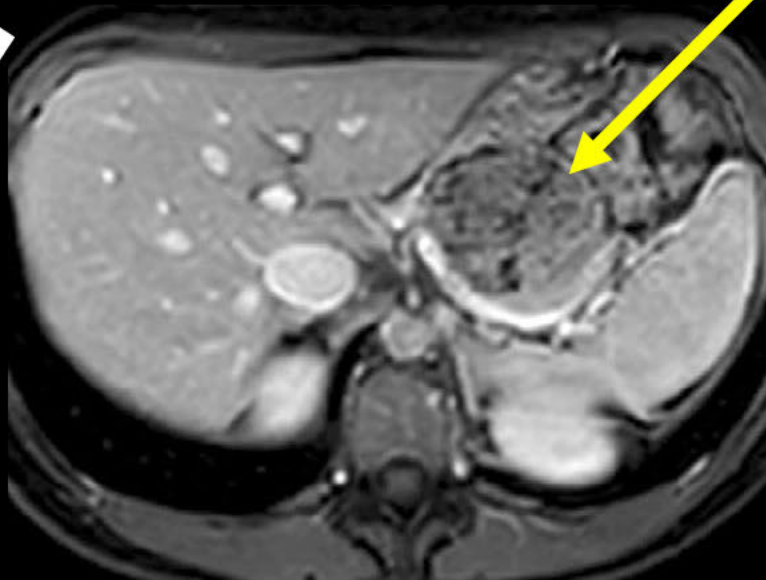
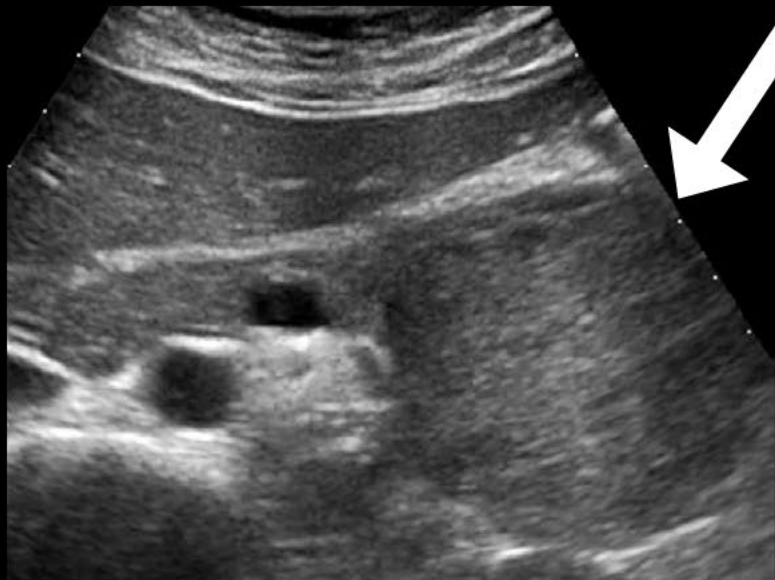

**AIRP**<sup>TM</sup>

AMERICAN INSTITUTE FOR  
RADIOLOGIC PATHOLOGY

A PROGRAM OF THE  
AMERICAN COLLEGE OF RADIOLOGY

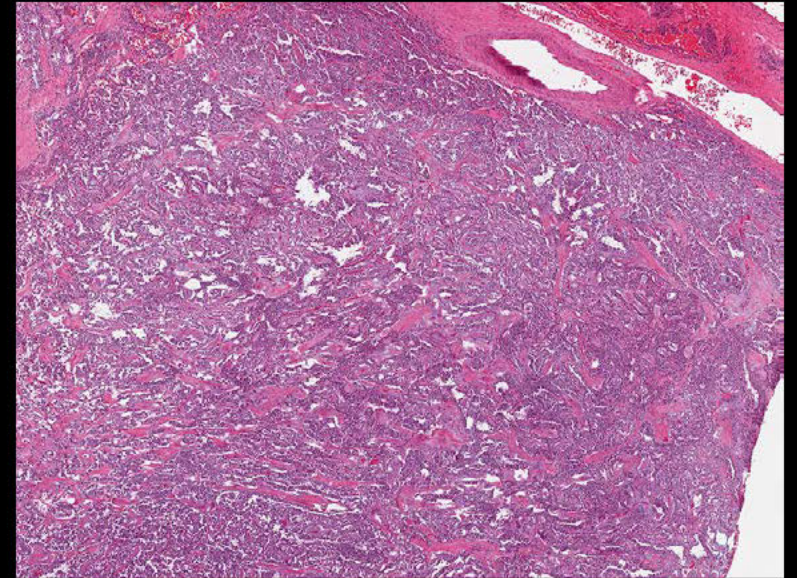
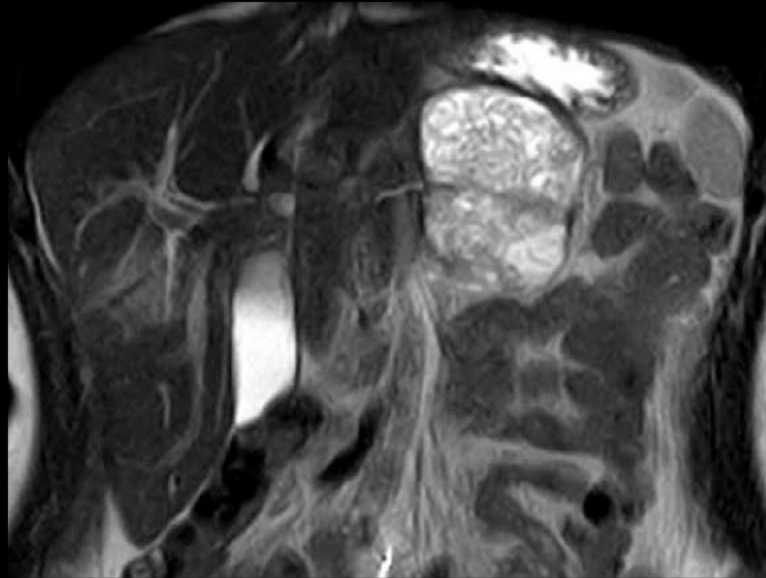
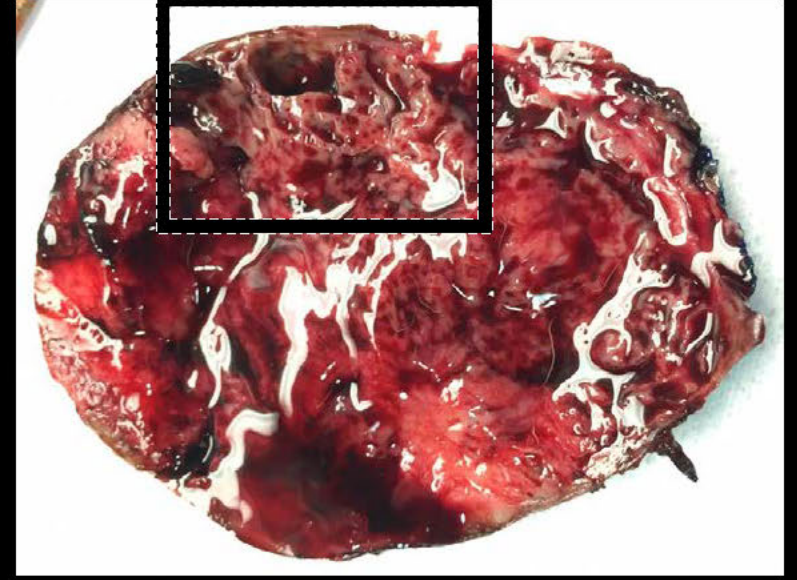
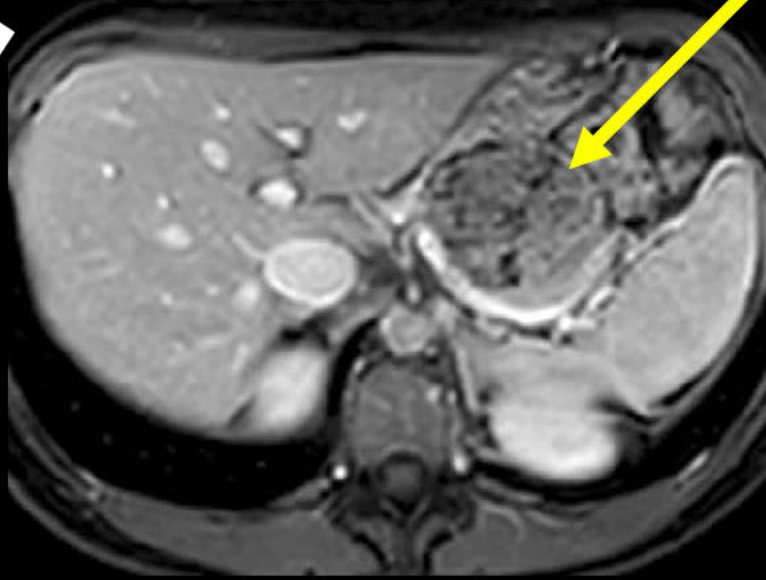
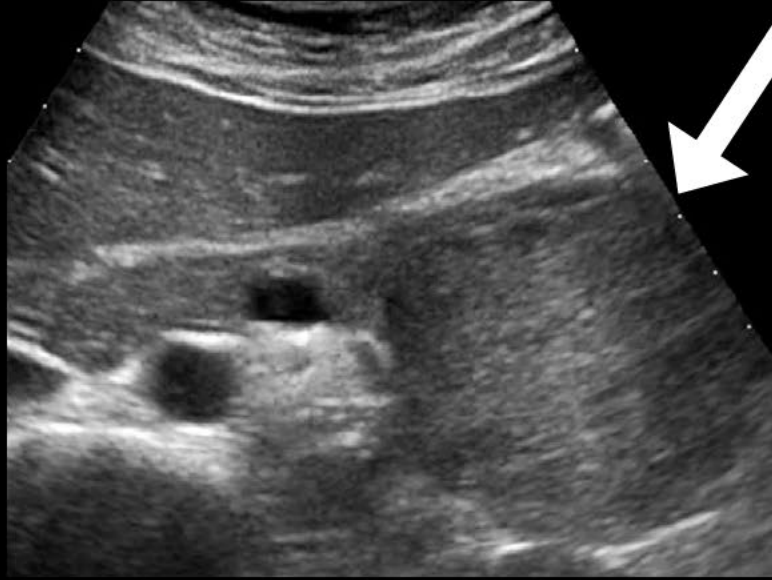



**AIRP**<sup>TM</sup>  
AMERICAN INSTITUTE FOR  
RADIOLOGIC PATHOLOGY

A PROGRAM OF THE  
AMERICAN COLLEGE OF RADIOLOGY

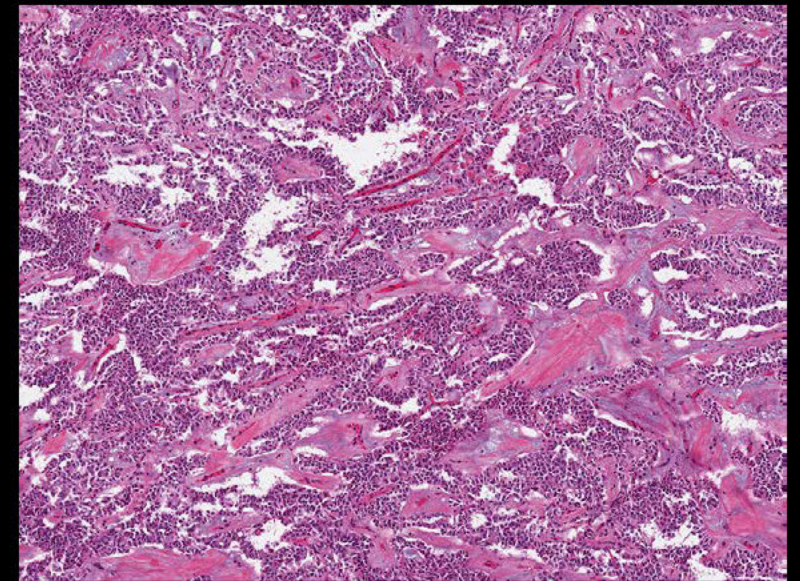
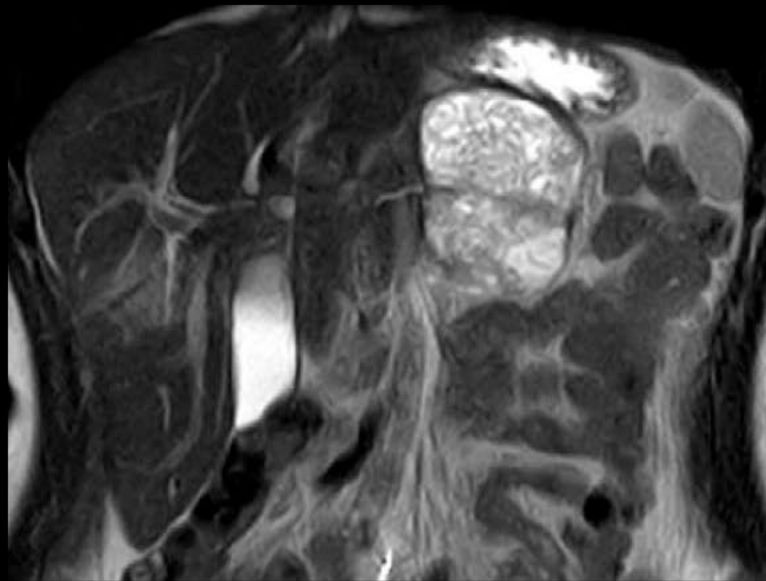
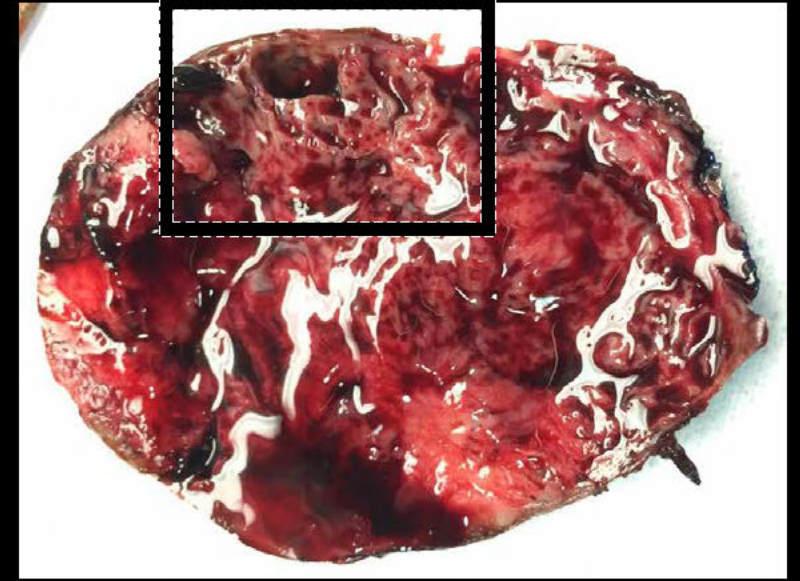




**AIRP**<sup>TM</sup>  
AMERICAN INSTITUTE FOR  
RADIOLOGIC PATHOLOGY

A PROGRAM OF THE  
AMERICAN COLLEGE OF RADIOLOGY





**AIRP**<sup>TM</sup>  
AMERICAN INSTITUTE FOR  
RADIOLOGIC PATHOLOGY

A PROGRAM OF THE  
AMERICAN COLLEGE OF RADIOLOGY

# Solid pseudopapillary neoplasm

Javiera Vásquez Poblete

Clinica Davila

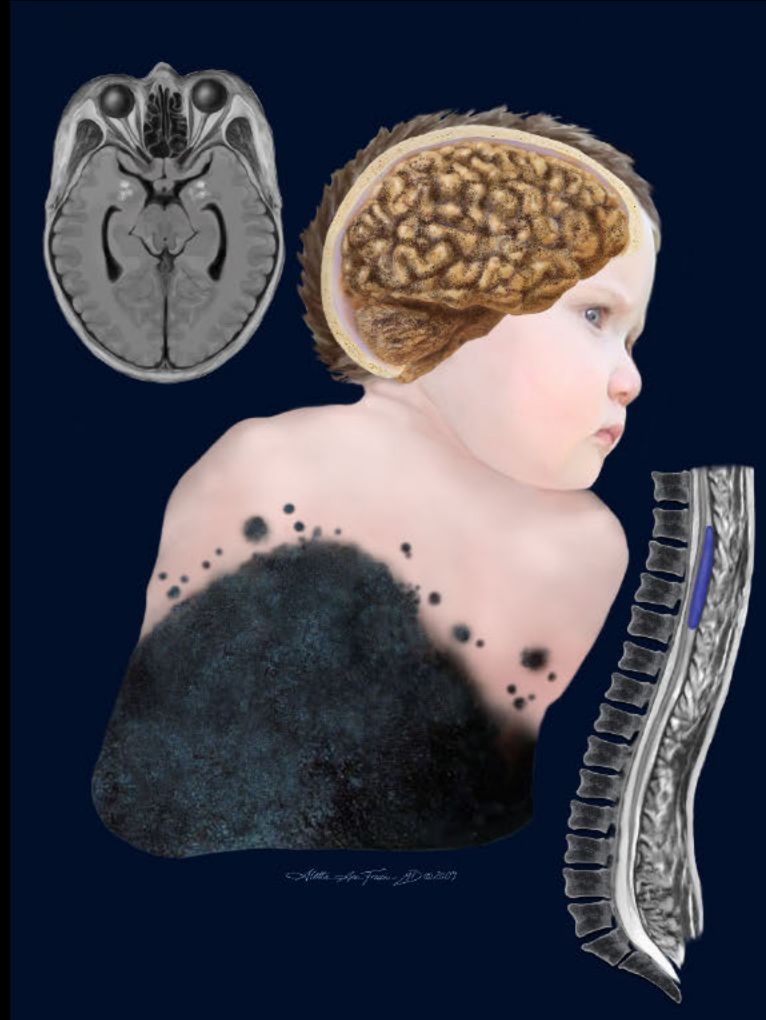Santiago, Chile



AMERICAN INSTITUTE FOR  
RADIOLOGIC PATHOLOGY

A PROGRAM OF THE  
AMERICAN COLLEGE OF RADIOLOGY

# Neuroradiology Best Case



**AIRP**<sup>TM</sup>

AMERICAN INSTITUTE FOR  
RADIOLOGIC PATHOLOGY

A PROGRAM OF THE  
AMERICAN COLLEGE OF RADIOLOGY



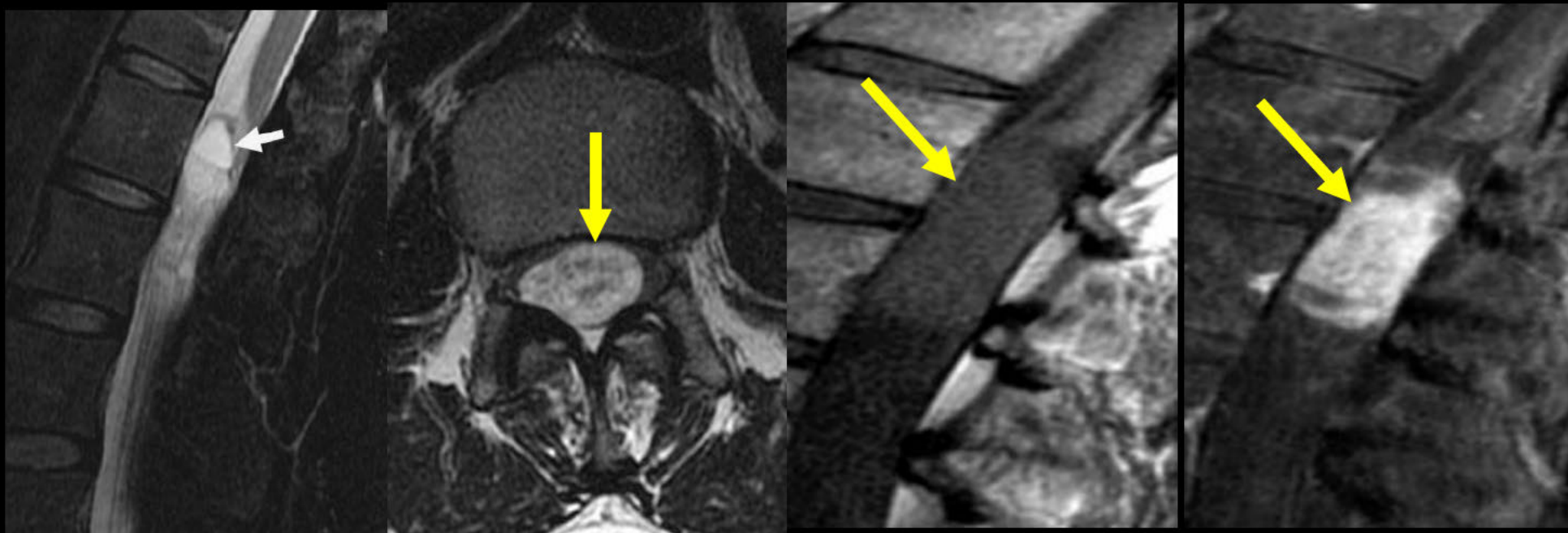
# Clinical information

**41-year-old female with 7 months of increasing back and bilateral lower extremity pain, tingling, and numbness. No weakness but some urinary incontinence. No fecal incontinence. Prior papillary thyroid carcinoma 8 months earlier. Normal physical exam.**



**AMERICAN INSTITUTE FOR  
RADIOLOGIC PATHOLOGY**

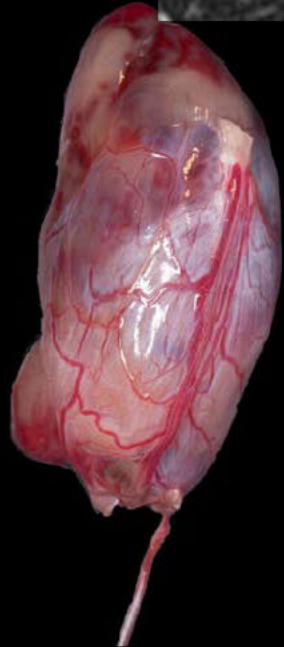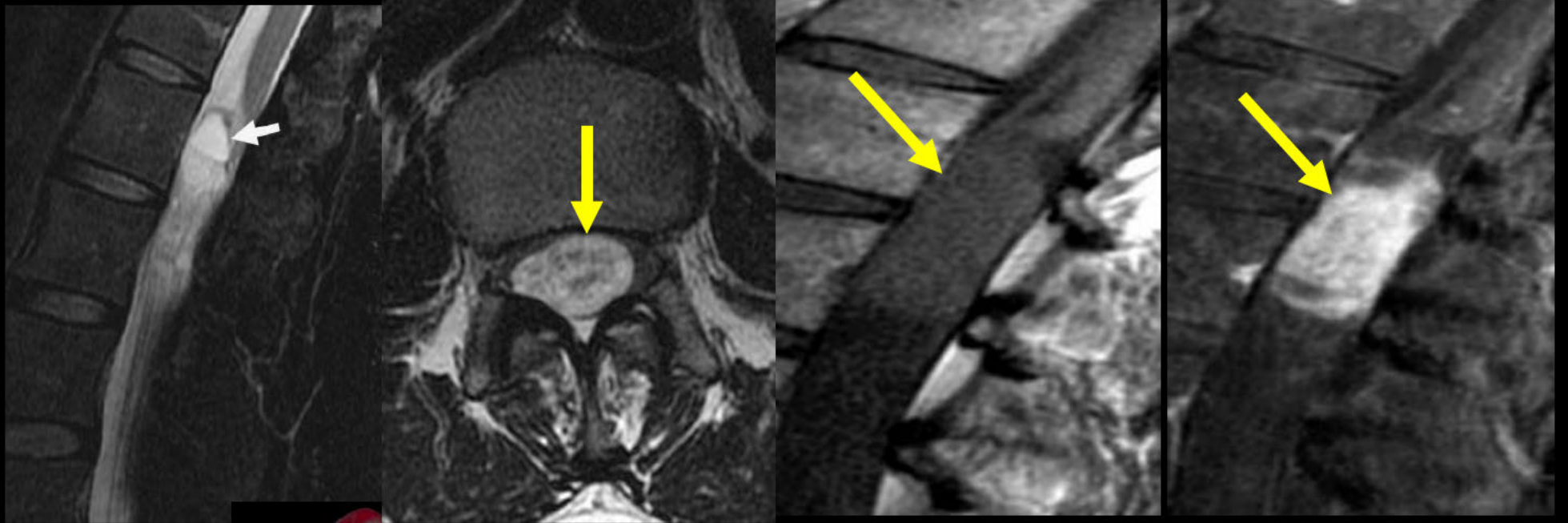
**A PROGRAM OF THE  
AMERICAN COLLEGE OF RADIOLOGY**



**AIRP**<sup>TM</sup>

AMERICAN INSTITUTE FOR  
RADIOLOGIC PATHOLOGY

A PROGRAM OF THE  
AMERICAN COLLEGE OF RADIOLOGY

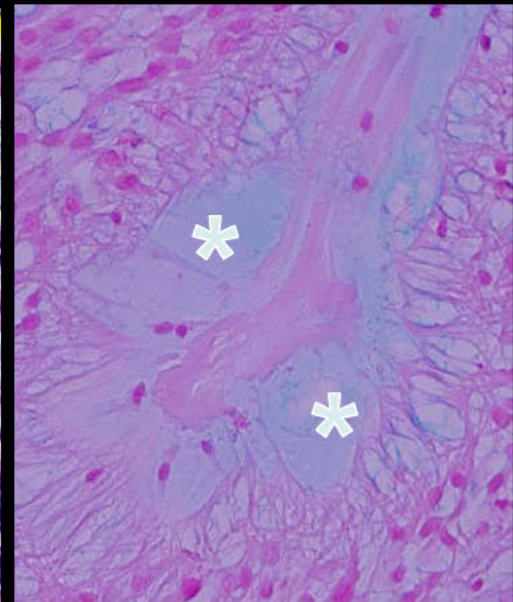
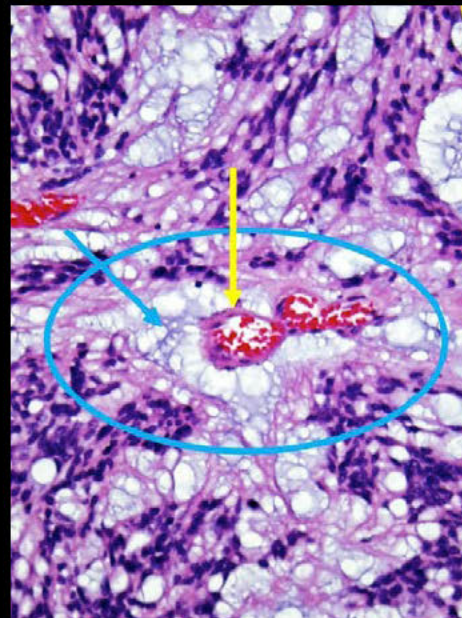
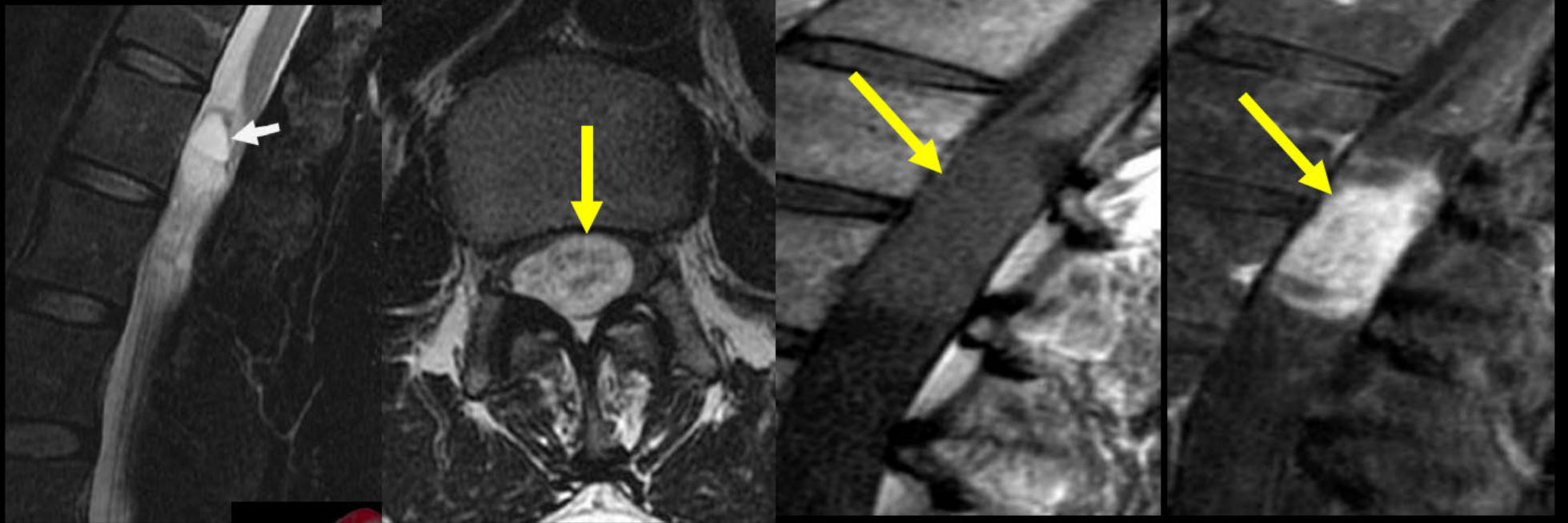


**AIRP**<sup>TM</sup>

AMERICAN INSTITUTE FOR  
RADIOLOGIC PATHOLOGY

A PROGRAM OF THE  
AMERICAN COLLEGE OF RADIOLOGY





**AIRP**<sup>TM</sup>

AMERICAN INSTITUTE FOR  
RADIOLOGIC PATHOLOGY

A PROGRAM OF THE  
AMERICAN COLLEGE OF RADIOLOGY

# Myxopapillary Ependymoma

Fehme Ucisk Keser

University of Texas M. D. Anderson Cancer Center

Houston, Texas

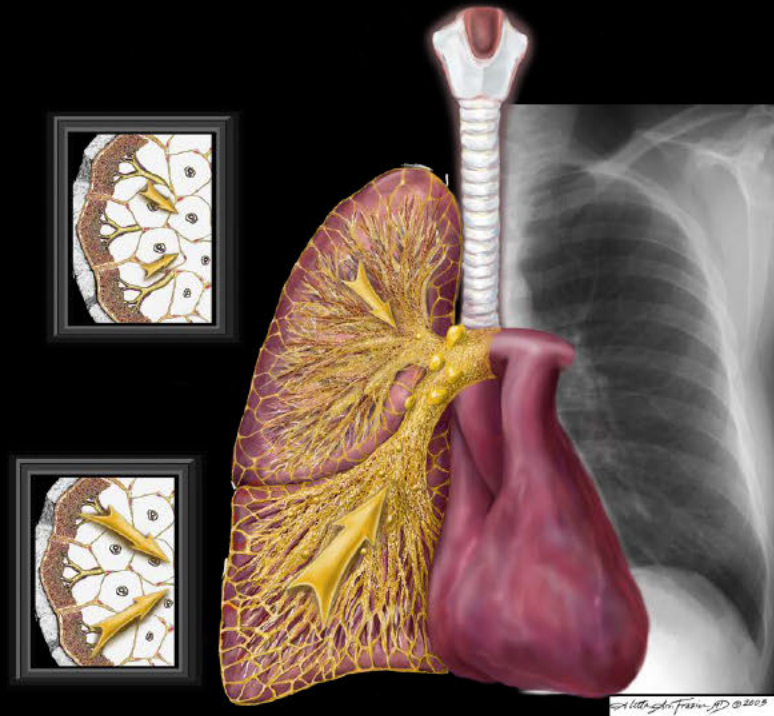
**AIRP**<sup>TM</sup>

AMERICAN INSTITUTE FOR  
RADIOLOGIC PATHOLOGY

A PROGRAM OF THE  
AMERICAN COLLEGE OF RADIOLOGY



# Pulmonary and Mediastinal Best Case



**AIRP**™

AMERICAN INSTITUTE FOR  
RADIOLOGIC PATHOLOGY

A PROGRAM OF THE  
AMERICAN COLLEGE OF RADIOLOGY

# Clinical information

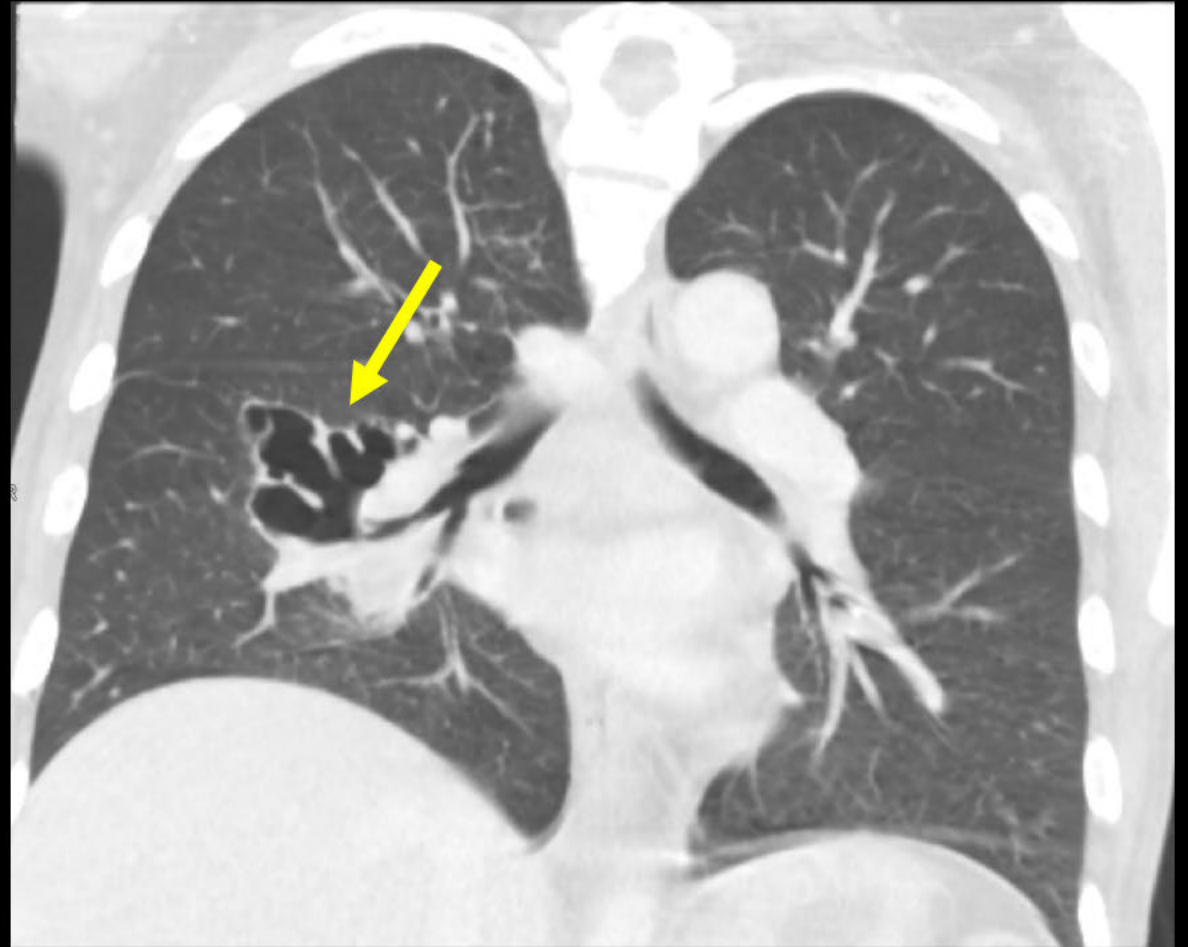
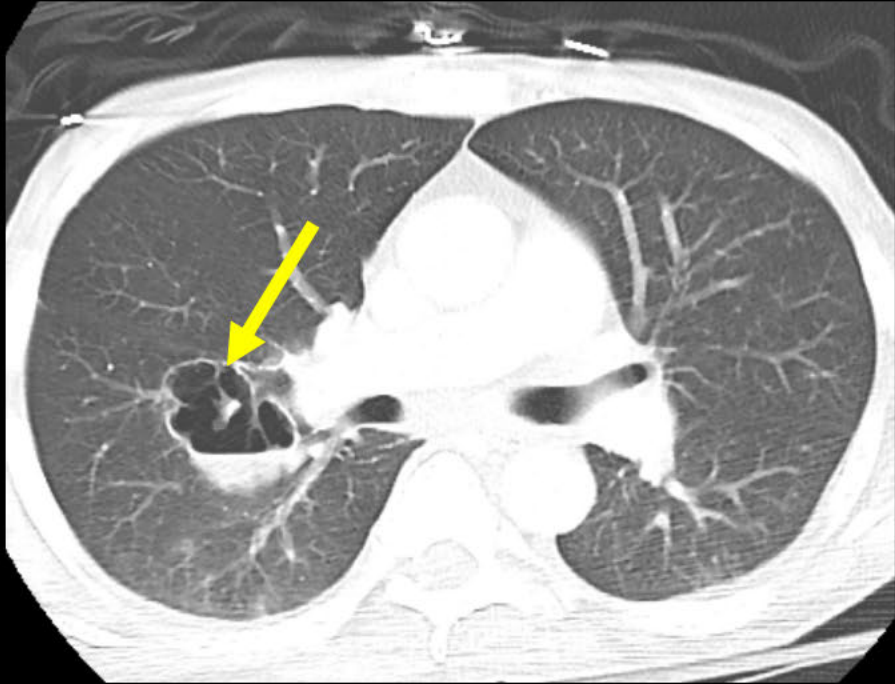
**50-year-old Laotian male with generalized weakness with decreased appetite and unintentional weight loss of 50lbs for 3 months**



AMERICAN INSTITUTE FOR  
RADIOLOGIC PATHOLOGY

A PROGRAM OF THE  
AMERICAN COLLEGE OF RADIOLOGY

# Admission

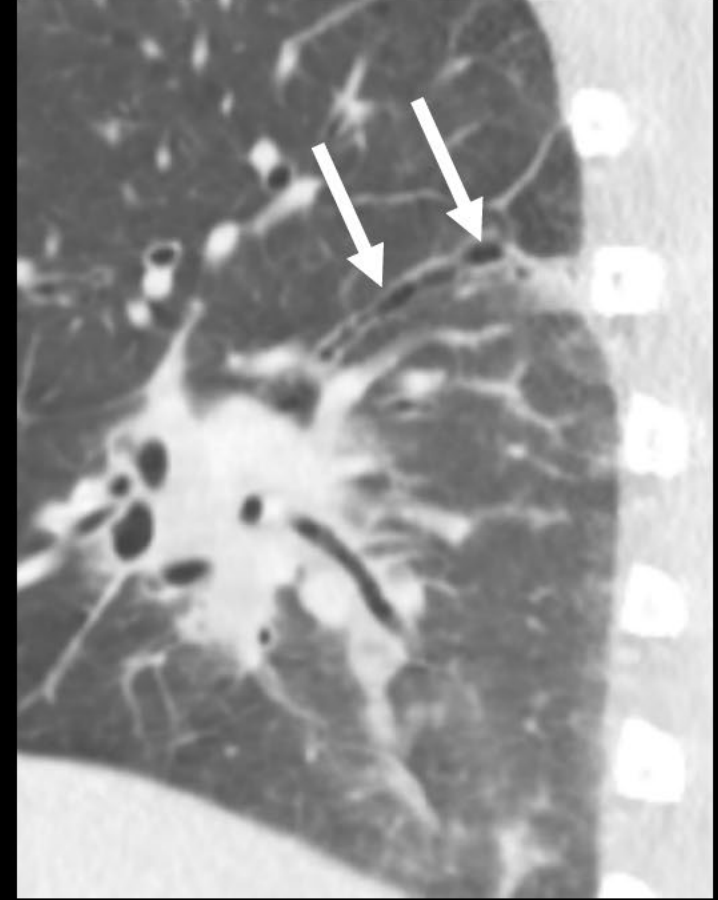
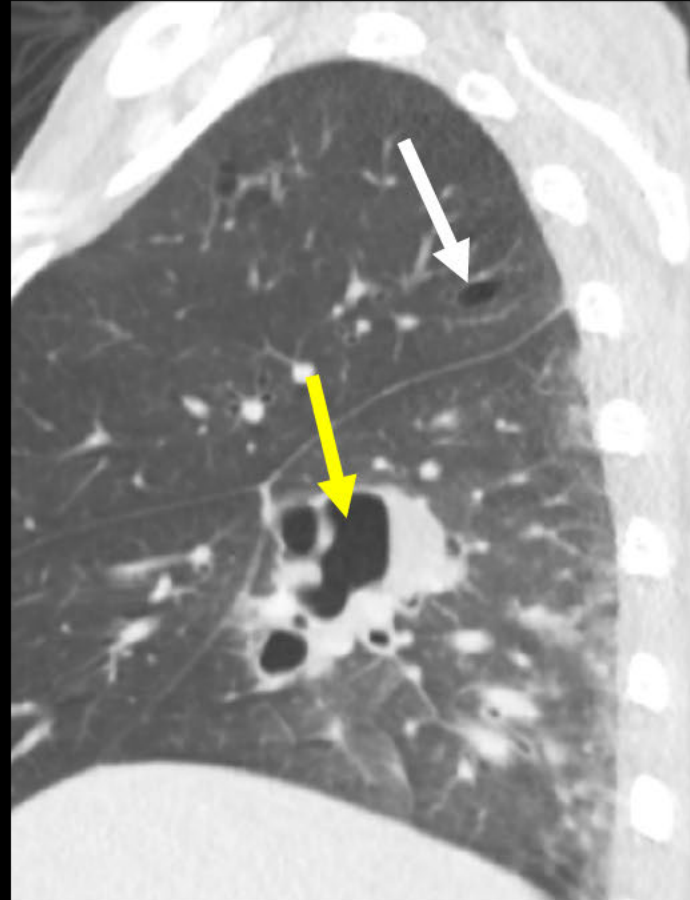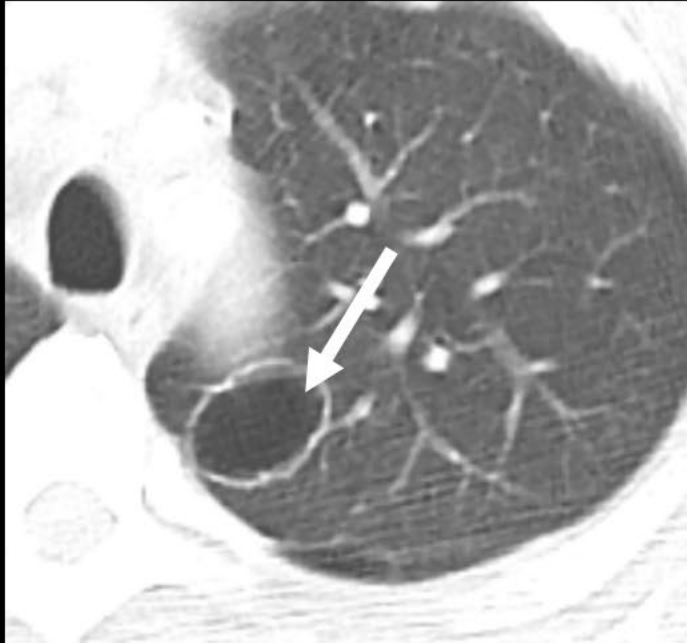


**AIRP**<sup>TM</sup>

AMERICAN INSTITUTE FOR  
RADIOLOGIC PATHOLOGY

A PROGRAM OF THE  
AMERICAN COLLEGE OF RADIOLOGY



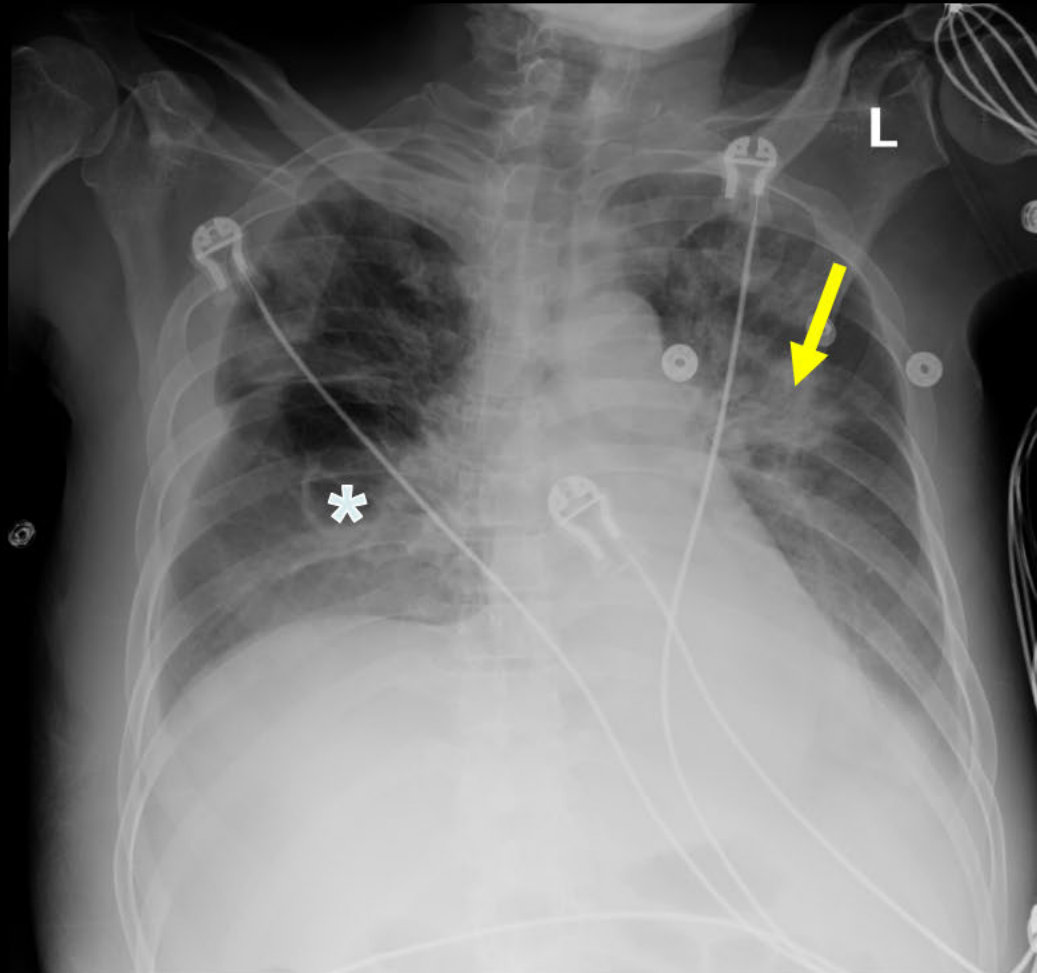


**AIRP**<sup>TM</sup>

AMERICAN INSTITUTE FOR  
RADIOLOGIC PATHOLOGY

A PROGRAM OF THE  
AMERICAN COLLEGE OF RADIOLOGY

# Admission +5 days



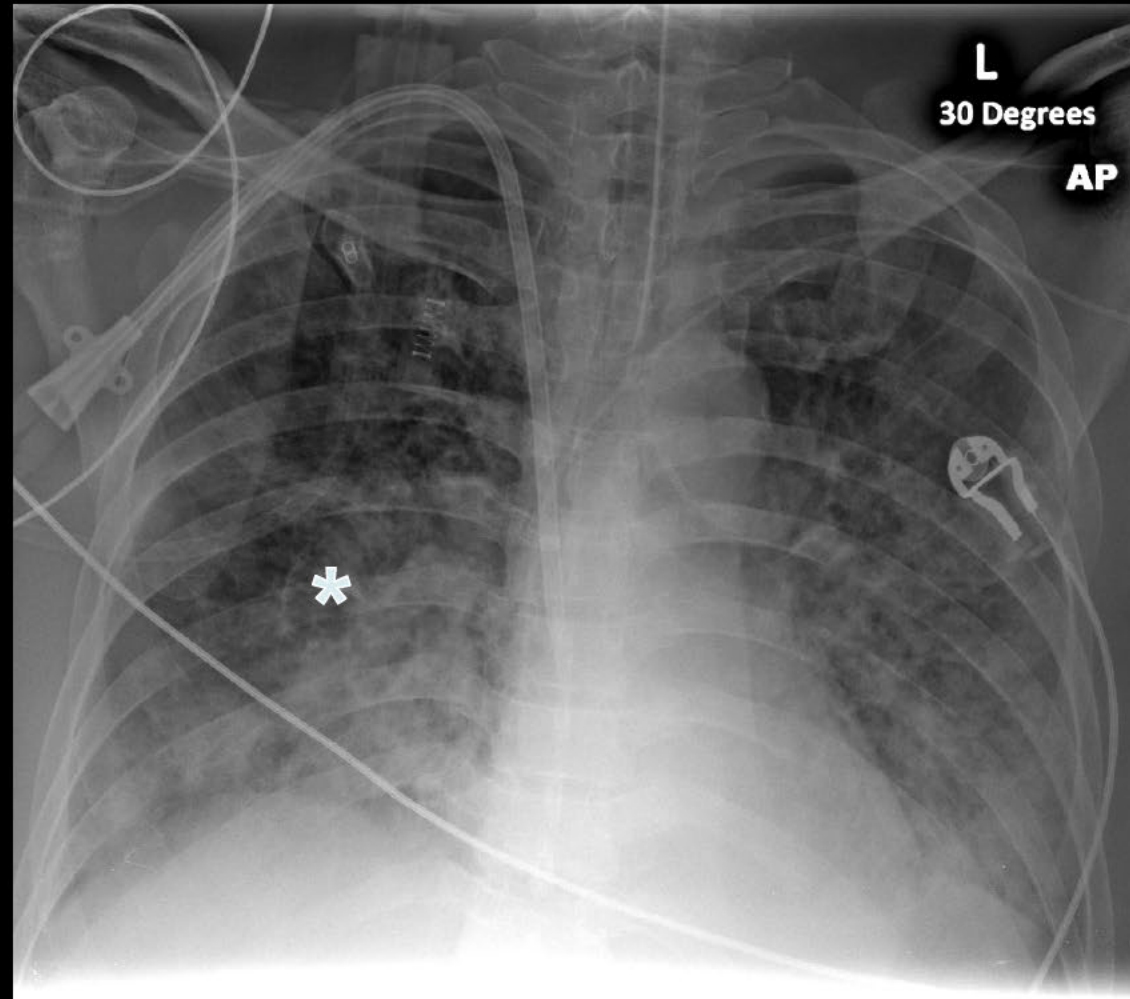
# AIRP™

AMERICAN INSTITUTE FOR  
RADIOLOGIC PATHOLOGY

A PROGRAM OF THE  
AMERICAN COLLEGE OF RADIOLOGY



# Admission +9 days

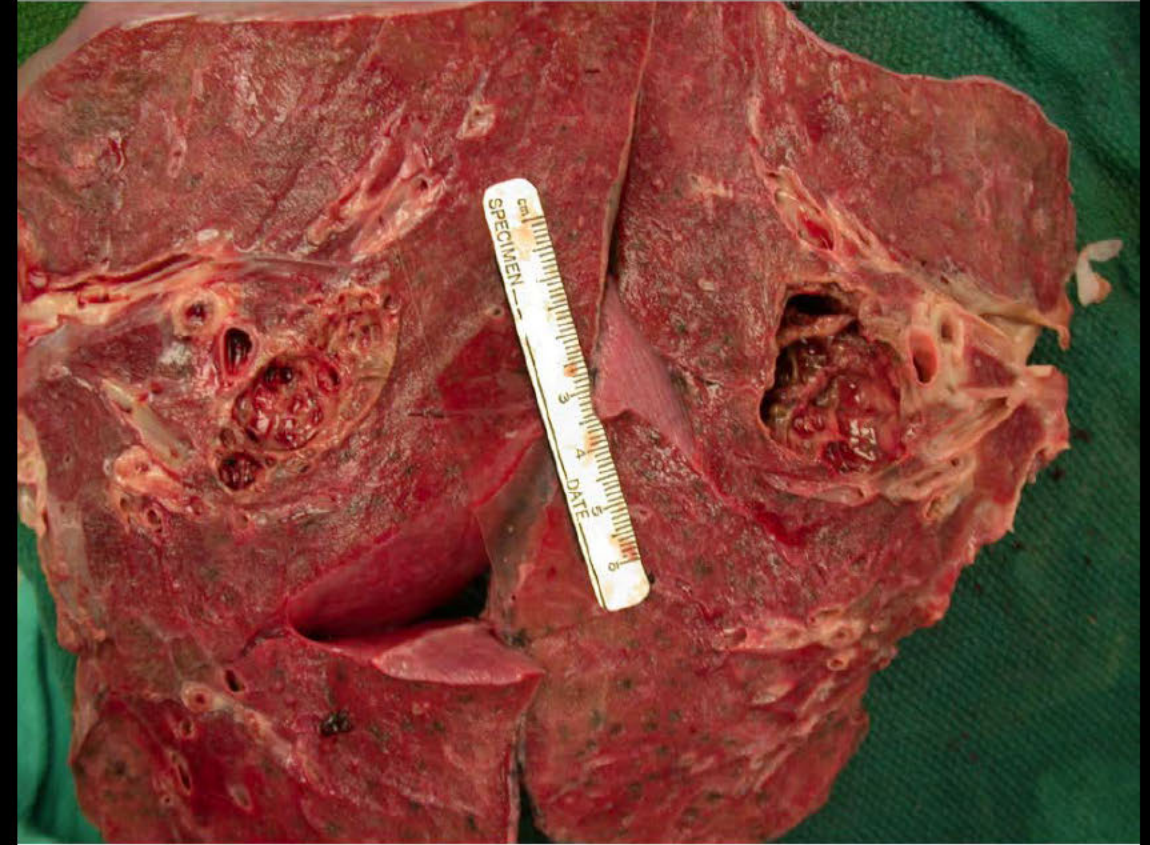
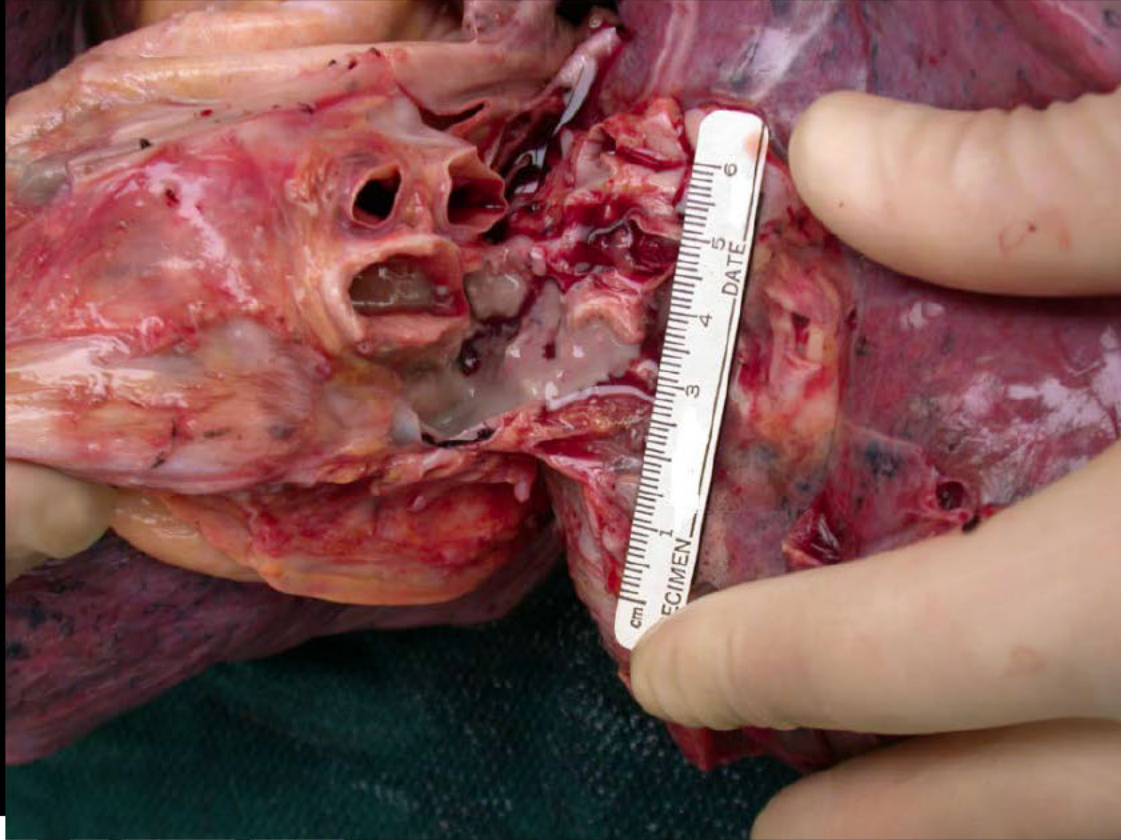


**AIRP**<sup>TM</sup>

AMERICAN INSTITUTE FOR  
RADIOLOGIC PATHOLOGY

A PROGRAM OF THE  
AMERICAN COLLEGE OF RADIOLOGY

# Gross



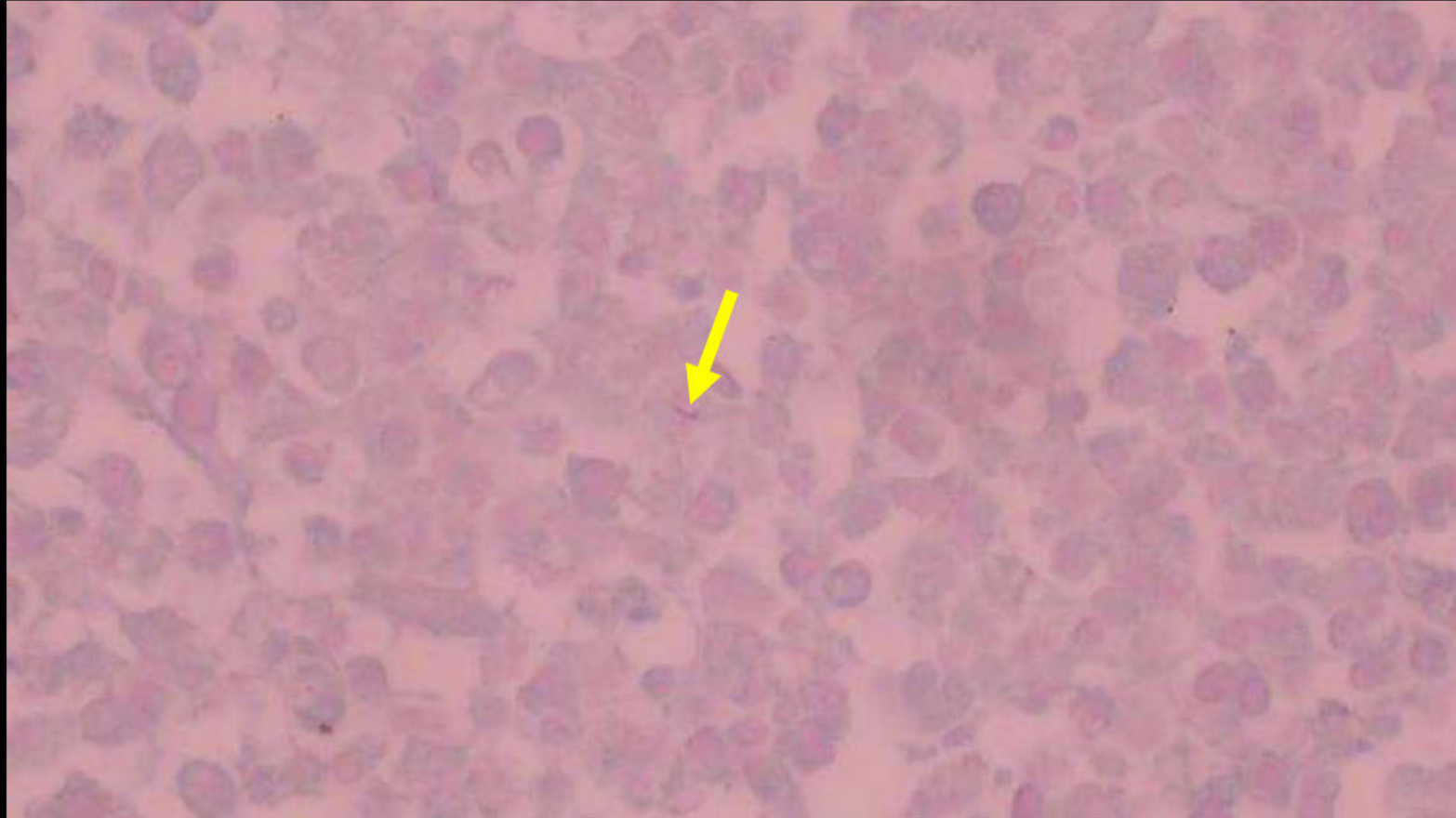# AIRP

AMERICAN INSTITUTE FOR  
RADIOLOGIC PATHOLOGY

A PROGRAM OF THE  
AMERICAN COLLEGE OF RADIOLOGY



# Acid Fast Stain

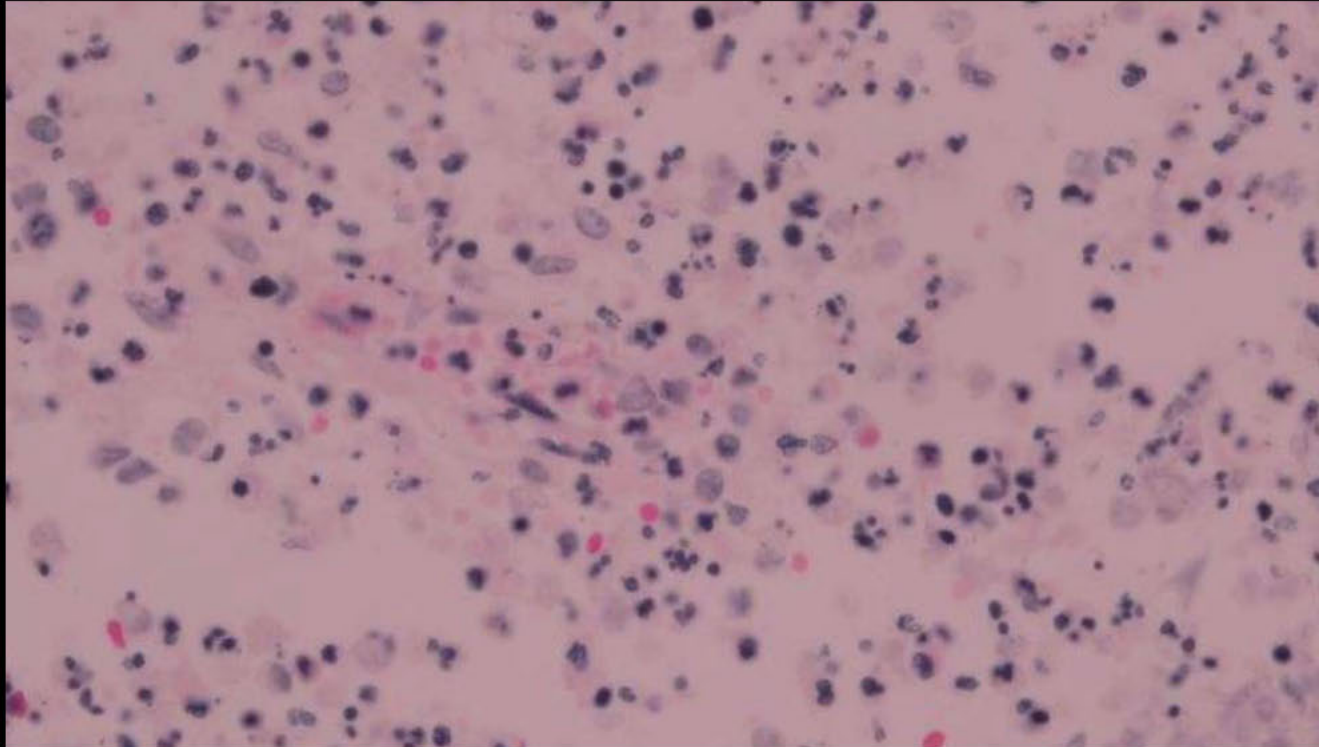


**AIRP**™

AMERICAN INSTITUTE FOR  
RADIOLOGIC PATHOLOGY

A PROGRAM OF THE  
AMERICAN COLLEGE OF RADIOLOGY

# H&E



**H/E stain showed necrotic cells mixed with neutrophils, monocytes and lymphocytes.**

**AIRP**<sup>TM</sup>

AMERICAN INSTITUTE FOR  
RADIOLOGIC PATHOLOGY

A PROGRAM OF THE  
AMERICAN COLLEGE OF RADIOLOGY



# **Mycobacterium Kansasii infection with abscess formation**

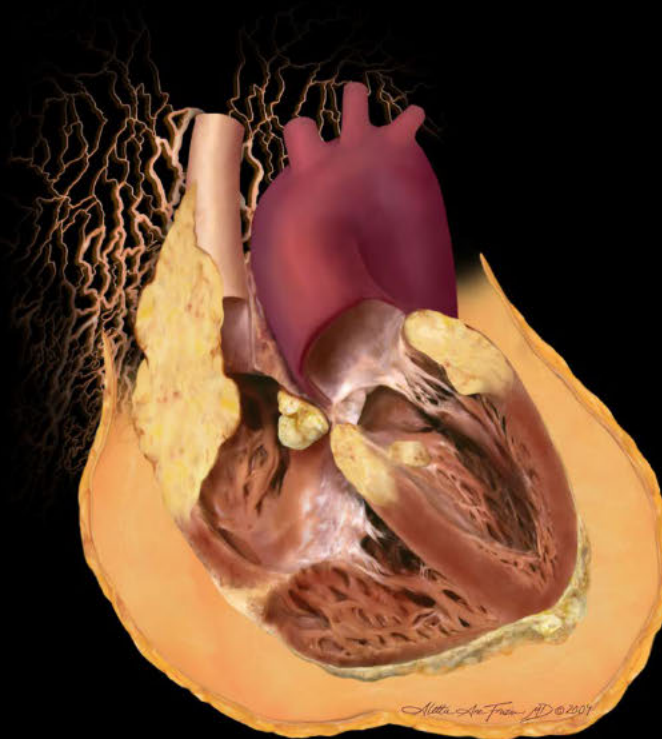
Lohitha Kolli, MD  
Wesley Medical Center  
Wichita, KS

**AIRP**<sup>TM</sup>

AMERICAN INSTITUTE FOR  
RADIOLOGIC PATHOLOGY

A PROGRAM OF THE  
AMERICAN COLLEGE OF RADIOLOGY

# Cardiovascular Best Case



**AIRP**™

AMERICAN INSTITUTE FOR  
RADIOLOGIC PATHOLOGY

A PROGRAM OF THE  
AMERICAN COLLEGE OF RADIOLOGY



# Clinical information

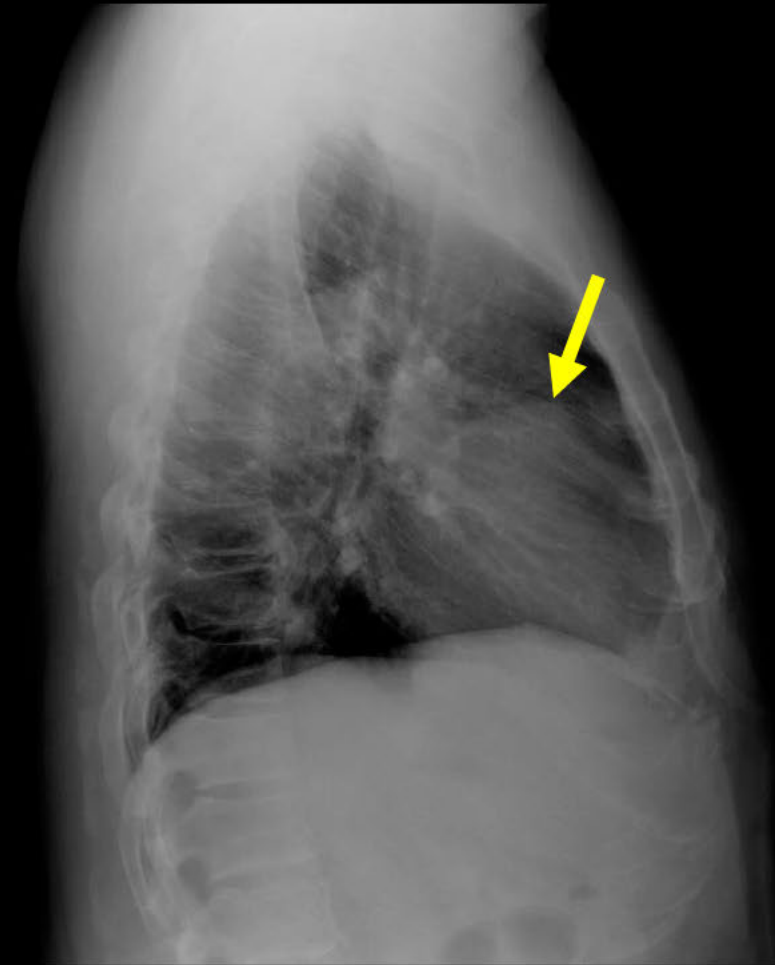
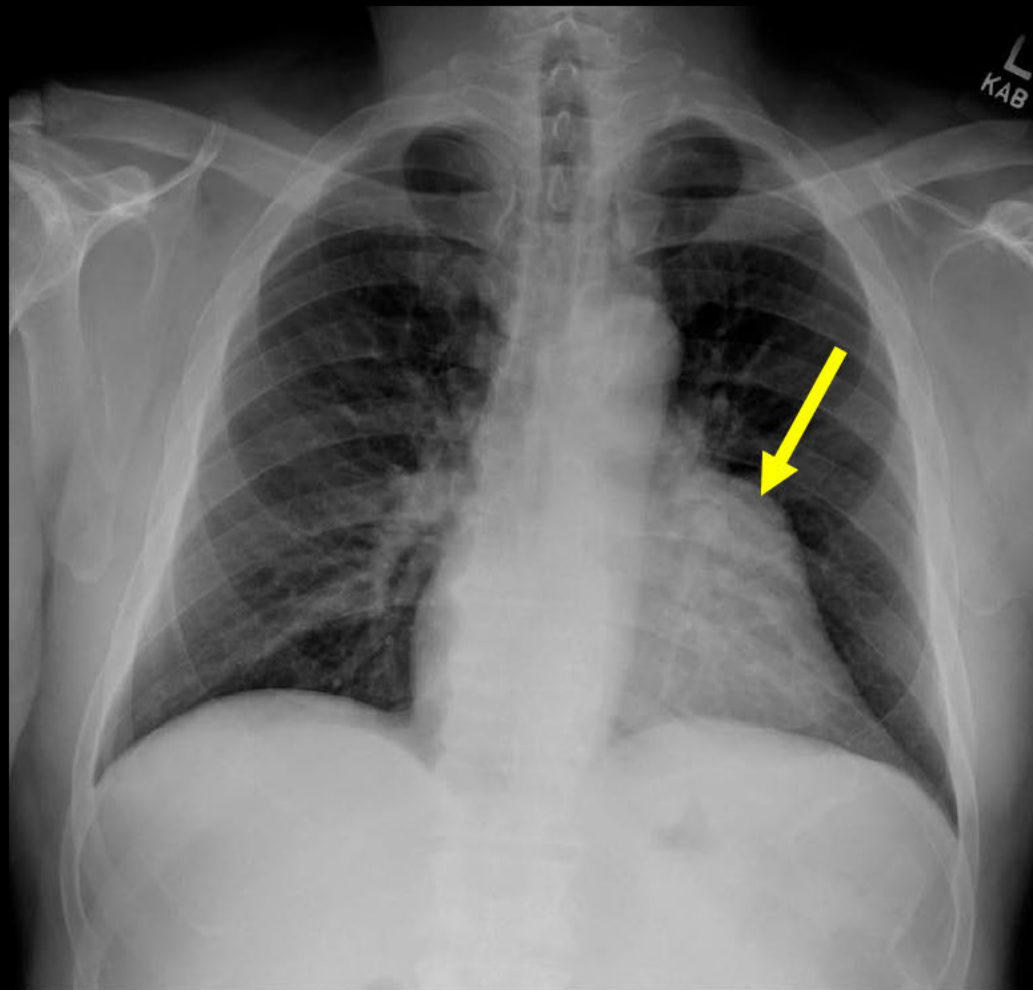
**61 y/o African American man with hx of HTN and HLD presents with months of worsening cough, back pain, and shortness of breath.**



AMERICAN INSTITUTE FOR  
RADIOLOGIC PATHOLOGY

---

A PROGRAM OF THE  
AMERICAN COLLEGE OF RADIOLOGY

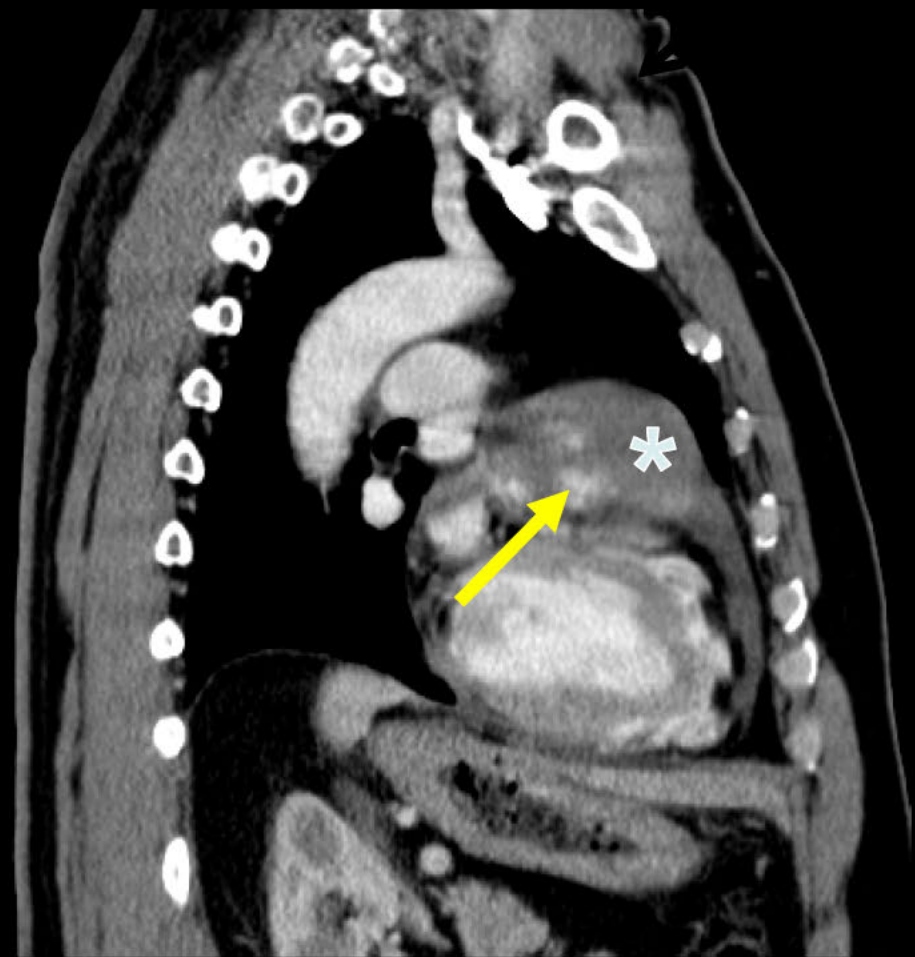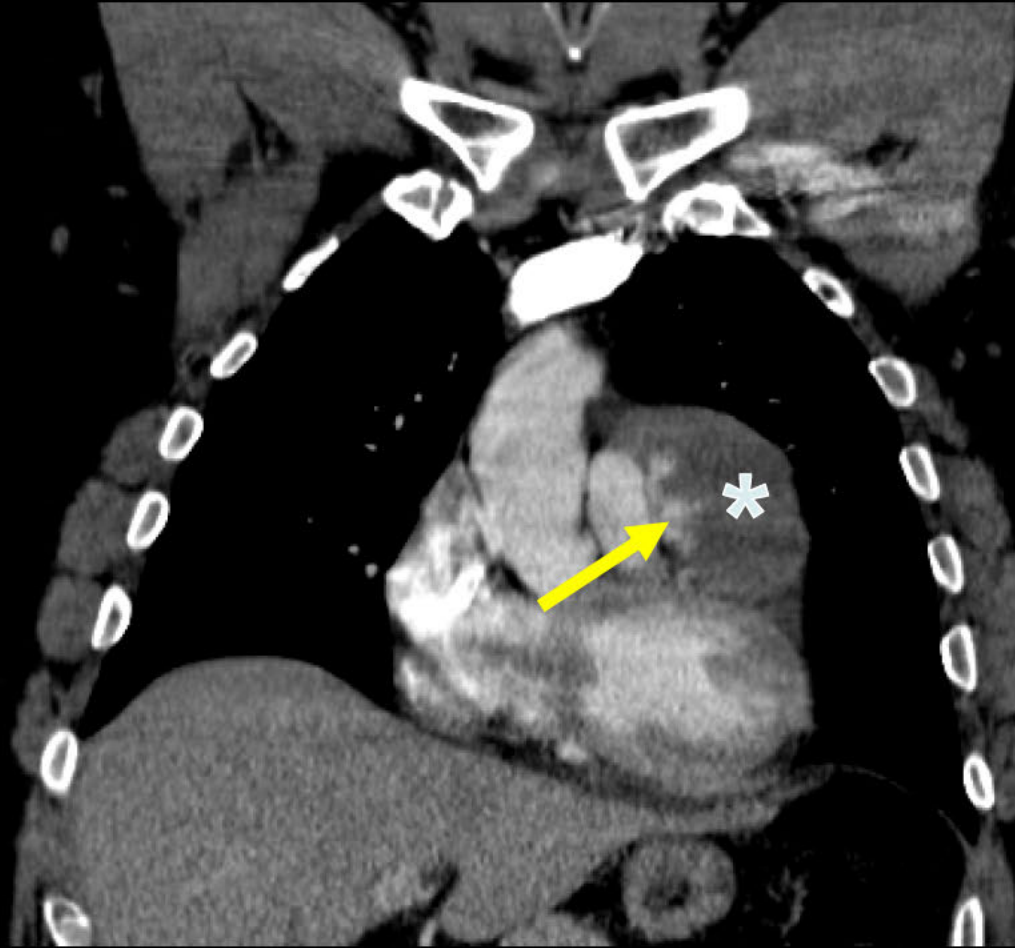


**AIRP**<sup>TM</sup>

AMERICAN INSTITUTE FOR  
RADIOLOGIC PATHOLOGY

A PROGRAM OF THE  
AMERICAN COLLEGE OF RADIOLOGY

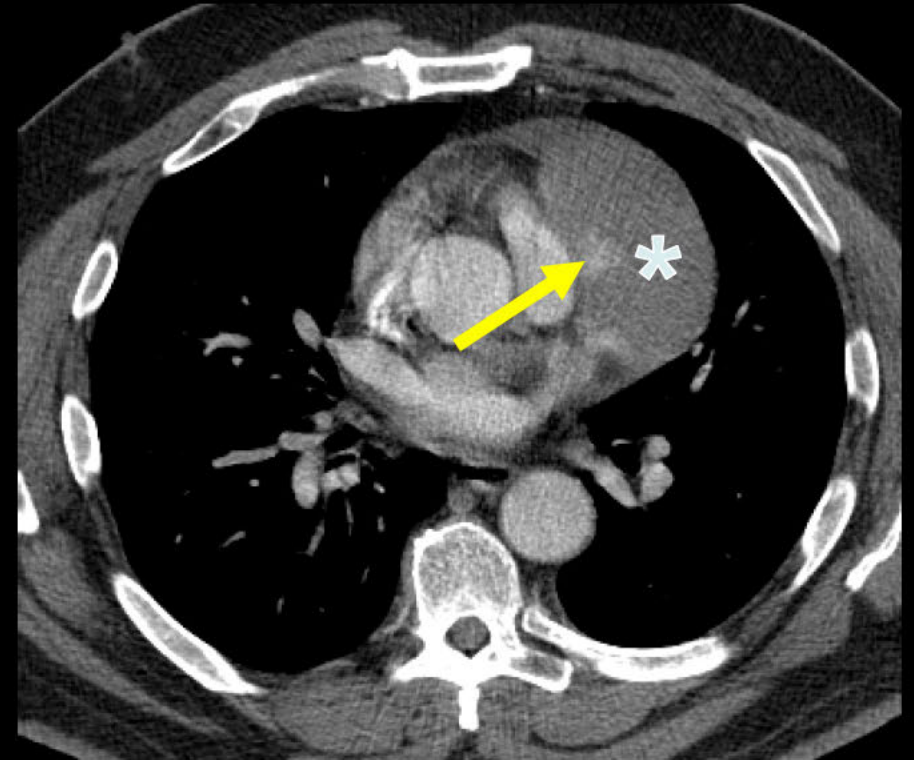
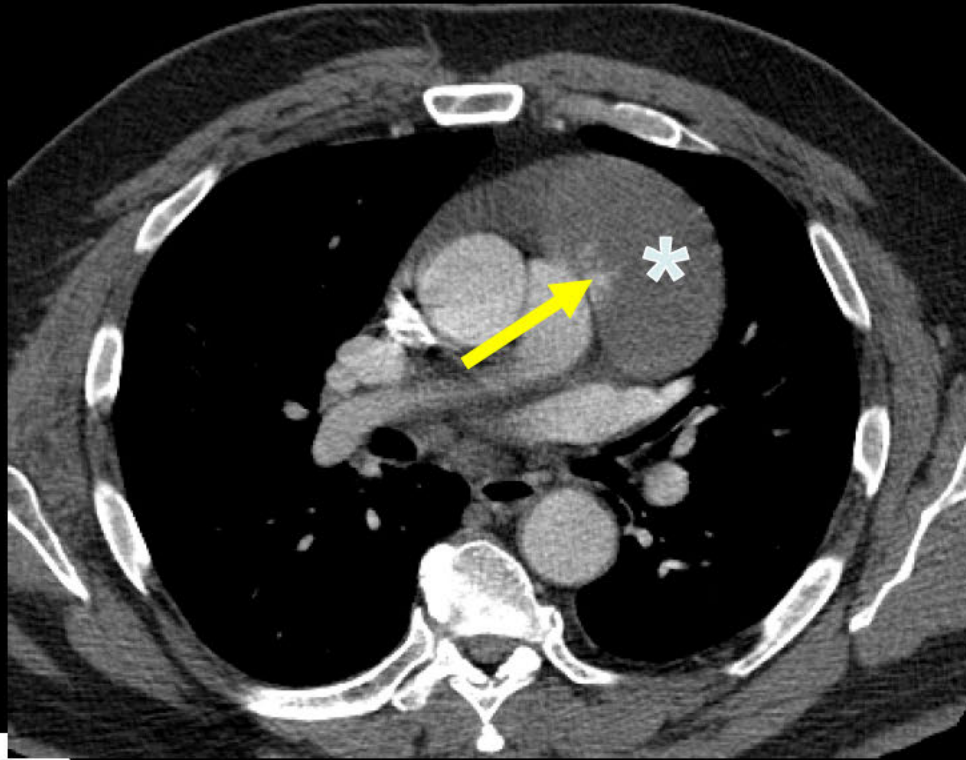




**AIRP**<sup>TM</sup>

AMERICAN INSTITUTE FOR  
RADIOLOGIC PATHOLOGY

A PROGRAM OF THE  
AMERICAN COLLEGE OF RADIOLOGY



**AIRP**

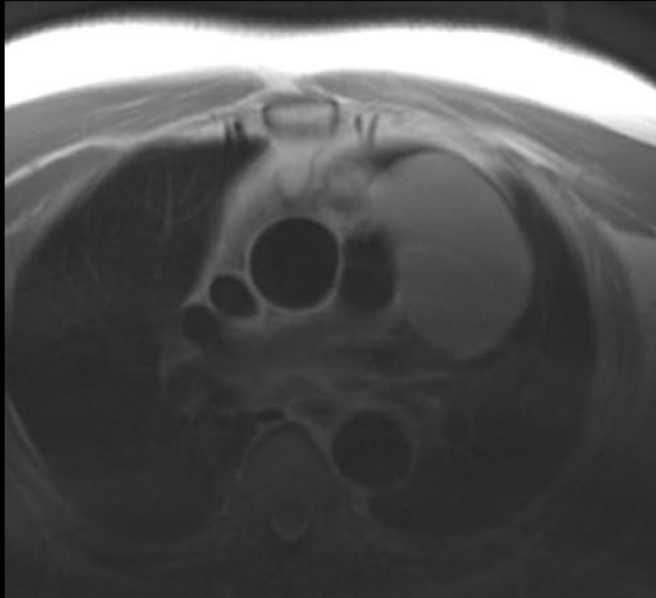
AMERICAN INSTITUTE FOR  
RADIOLOGIC PATHOLOGY

A PROGRAM OF THE  
AMERICAN COLLEGE OF RADIOLOGY

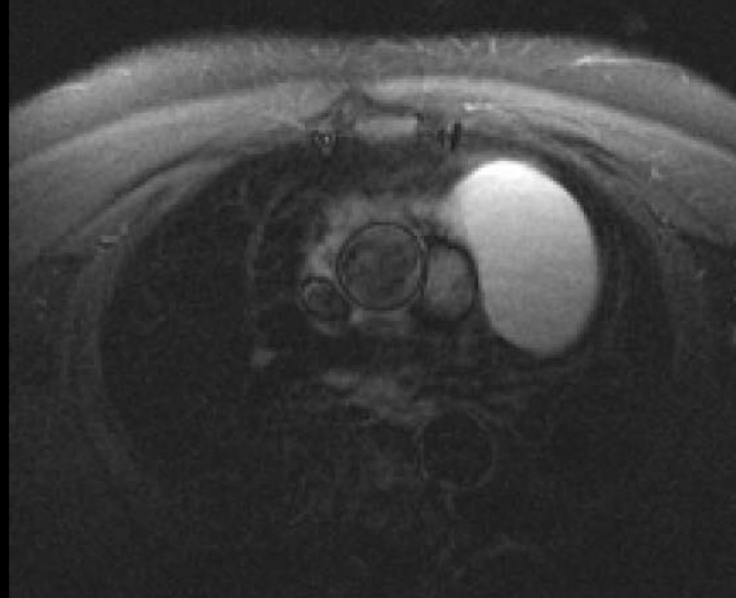


# MRI

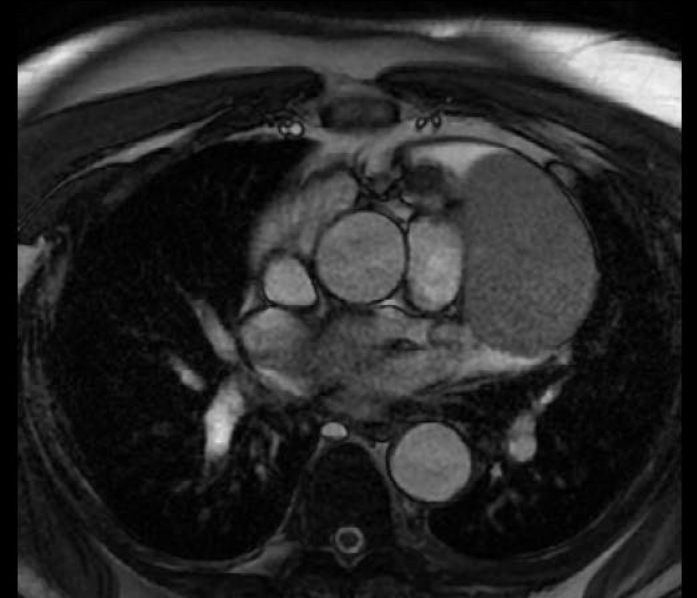T1W



T2W



SSFP

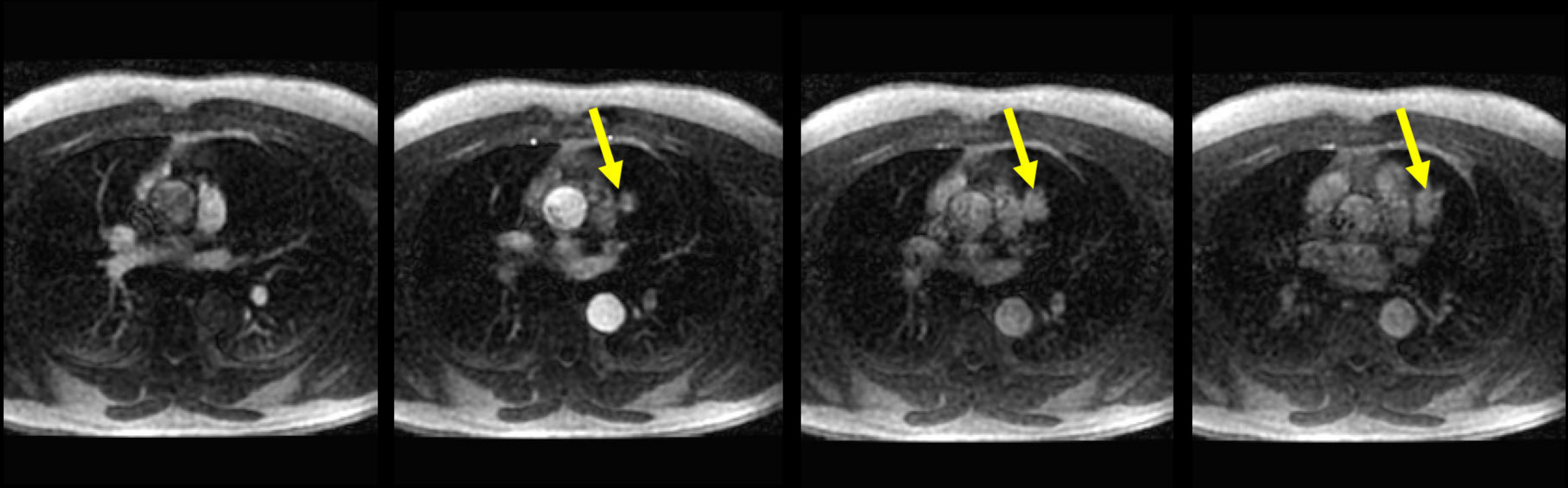


**AIRP**<sup>TM</sup>

AMERICAN INSTITUTE FOR  
RADIOLOGIC PATHOLOGY

A PROGRAM OF THE  
AMERICAN COLLEGE OF RADIOLOGY

# MR First Pass Perfusion

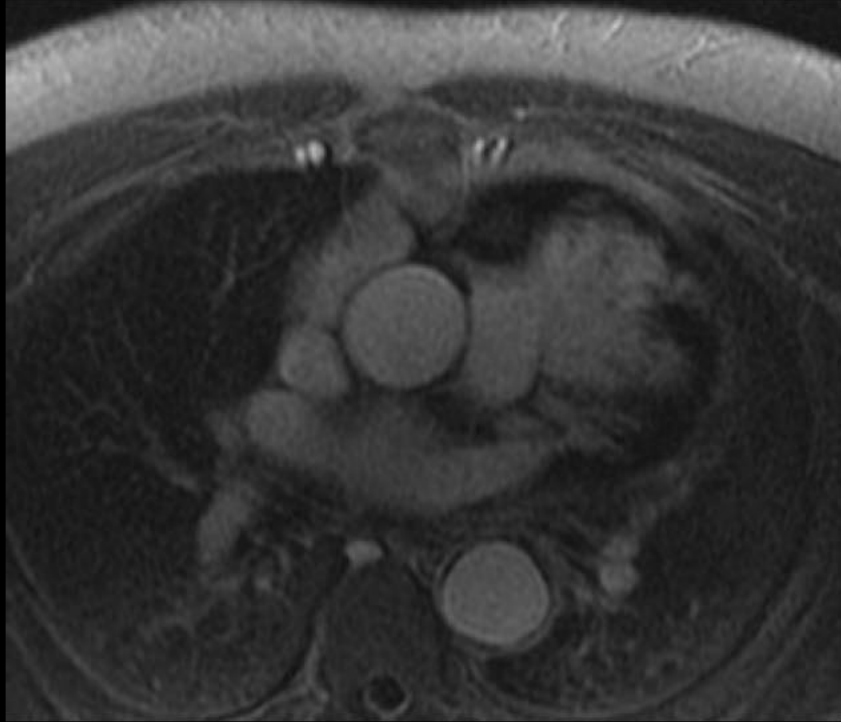


**AIRP**<sup>TM</sup>

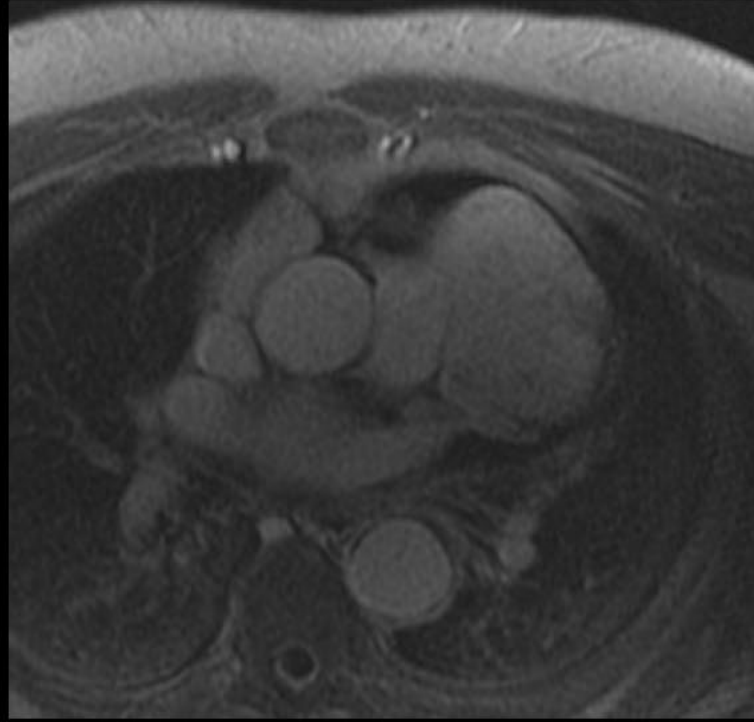
AMERICAN INSTITUTE FOR  
RADIOLOGIC PATHOLOGY

A PROGRAM OF THE  
AMERICAN COLLEGE OF RADIOLOGY

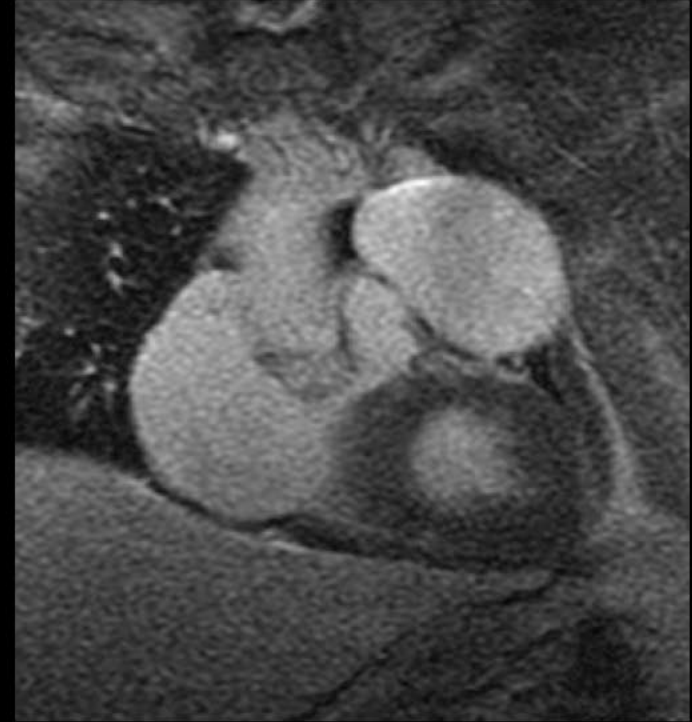
# T1W post contrast



1 min post



2 min post



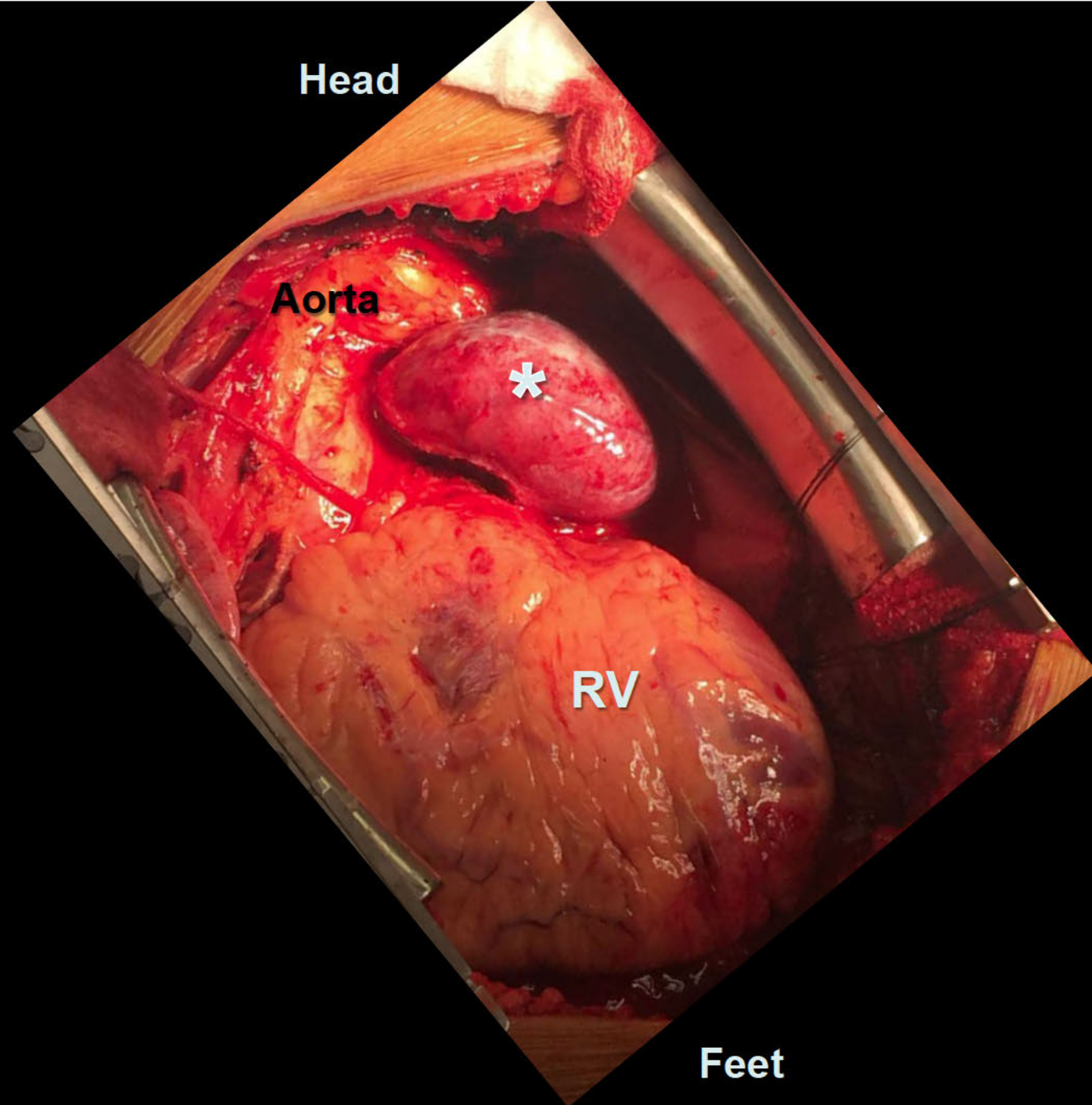
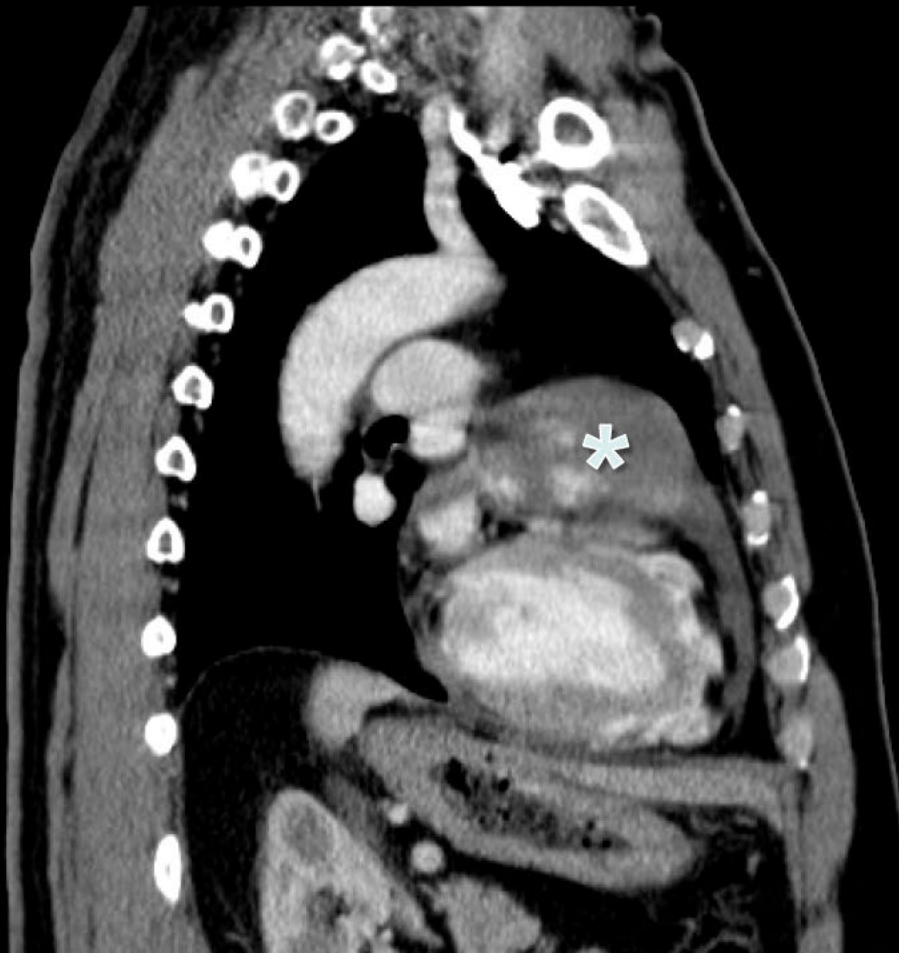4 min post

**AIRP**<sup>TM</sup>

AMERICAN INSTITUTE FOR  
RADIOLOGIC PATHOLOGY

A PROGRAM OF THE  
AMERICAN COLLEGE OF RADIOLOGY





**AIRP**<sup>TM</sup>

AMERICAN INSTITUTE FOR  
RADIOLOGIC PATHOLOGY

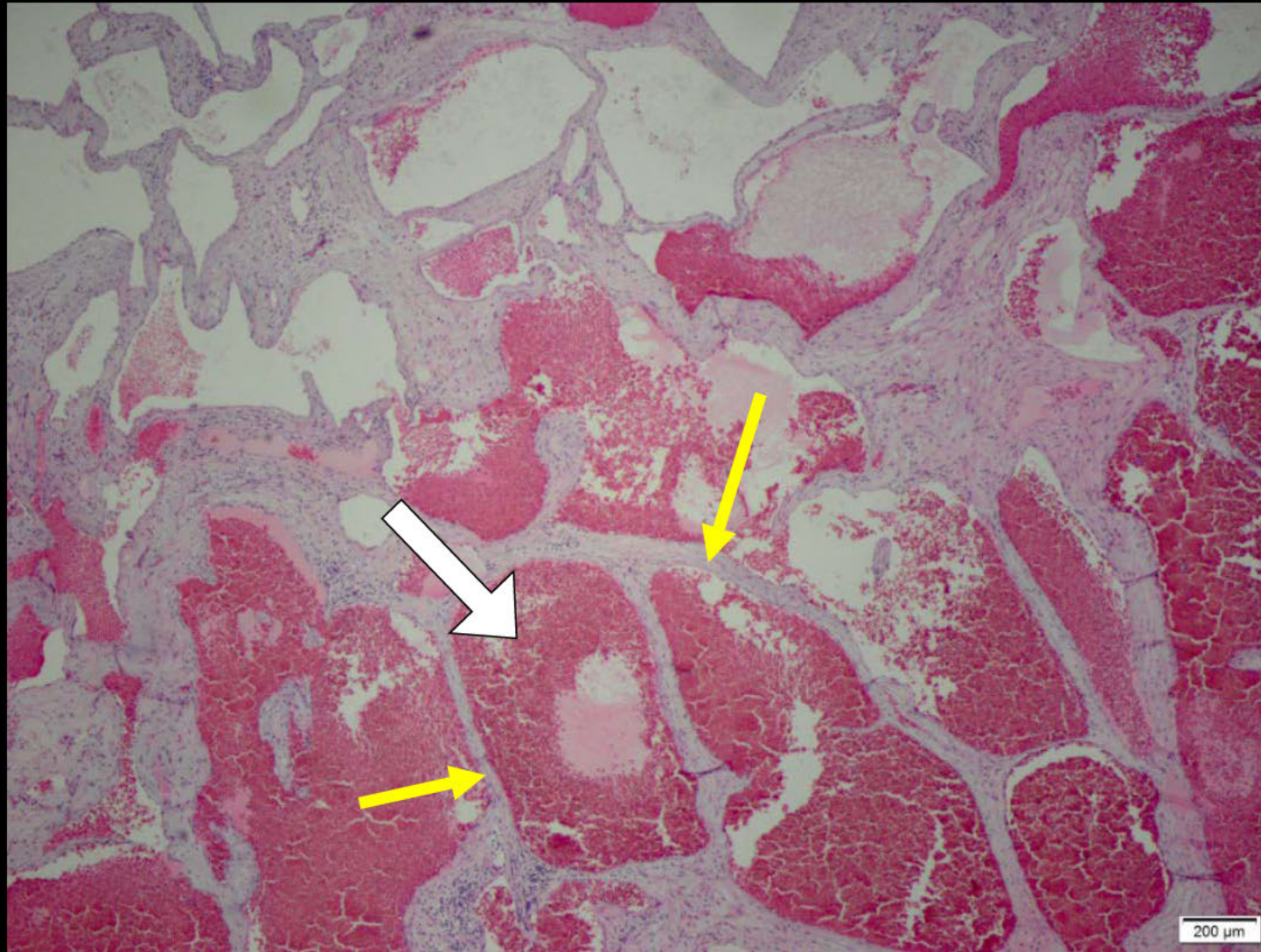
A PROGRAM OF THE  
AMERICAN COLLEGE OF RADIOLOGY



**AIRP**<sup>TM</sup>

AMERICAN INSTITUTE FOR  
RADIOLOGIC PATHOLOGY

A PROGRAM OF THE  
AMERICAN COLLEGE OF RADIOLOGY



**Low power view shows blood filled cystic spaces (white arrow) lined by capillary endothelium (yellow arrow)**

# Pericardial Hemangioma

Kartik Kansagra, MD  
Kaiser Permanente  
Los Angeles, CA

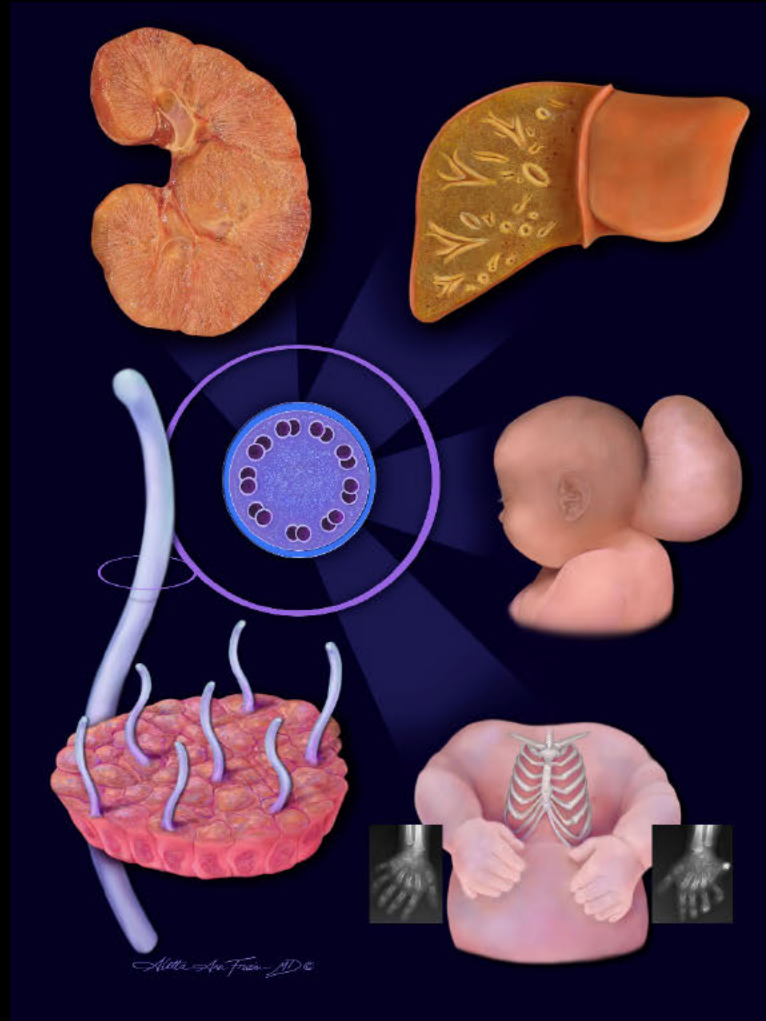


AMERICAN INSTITUTE FOR  
RADIOLOGIC PATHOLOGY

A PROGRAM OF THE  
AMERICAN COLLEGE OF RADIOLOGY



# Pediatric Best Case



**AIRP**<sup>TM</sup>

AMERICAN INSTITUTE FOR  
RADIOLOGIC PATHOLOGY

A PROGRAM OF THE  
AMERICAN COLLEGE OF RADIOLOGY

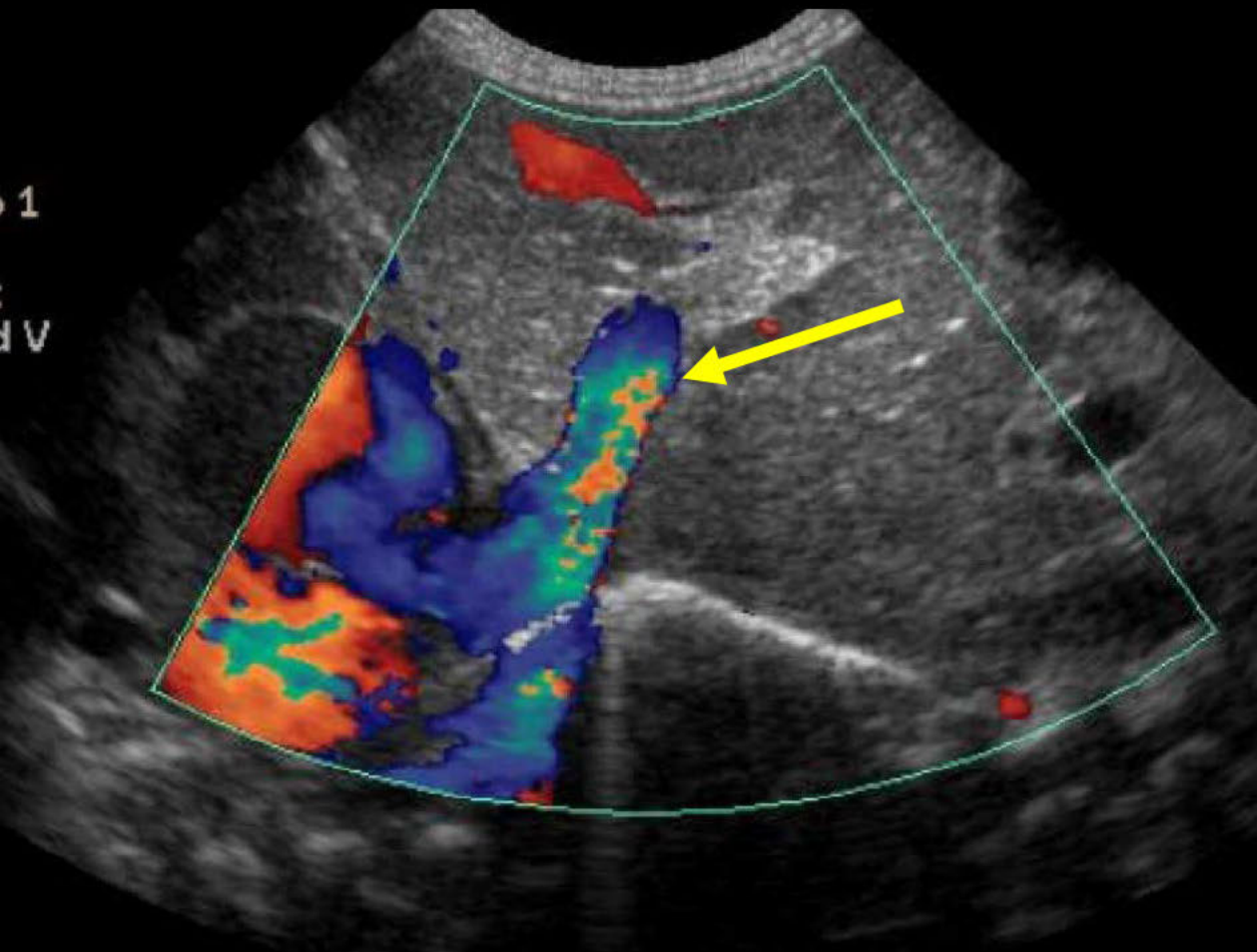
# Clinical information

**9 year old female with developmental delay, protein S deficiency, hepatic vein ectasia, portosystemic shunting, in utero portal venous thrombosis, and a left hepatic mass presumed to be focal nodular hyperplasia (FNH) presented to clinic with a declining appetite and weight loss.**



AMERICAN INSTITUTE FOR  
RADIOLOGIC PATHOLOGY

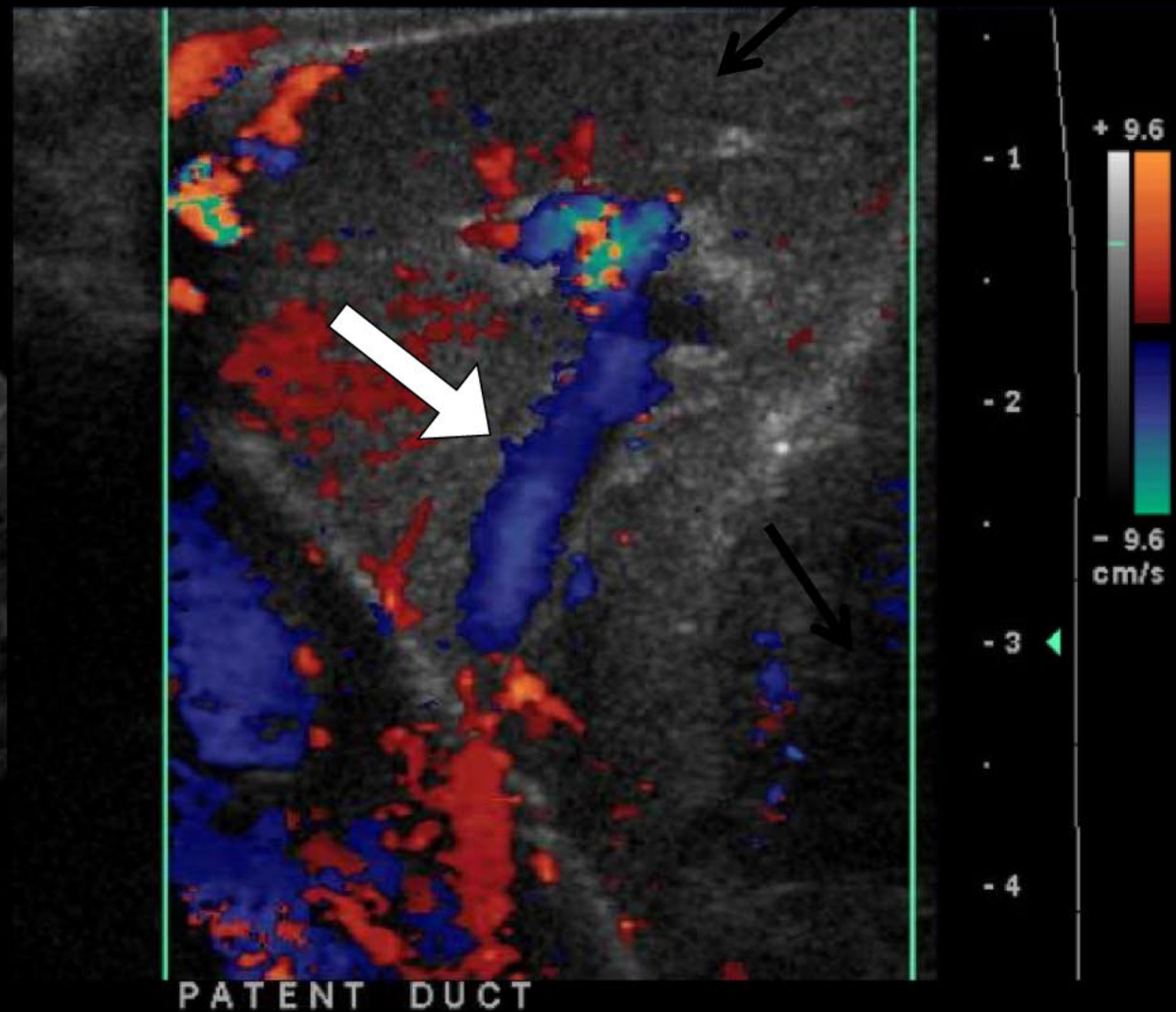
A PROGRAM OF THE  
AMERICAN COLLEGE OF RADIOLOGY



**AIRP**<sup>TM</sup>

AMERICAN INSTITUTE FOR  
RADIOLOGIC PATHOLOGY

A PROGRAM OF THE  
AMERICAN COLLEGE OF RADIOLOGY





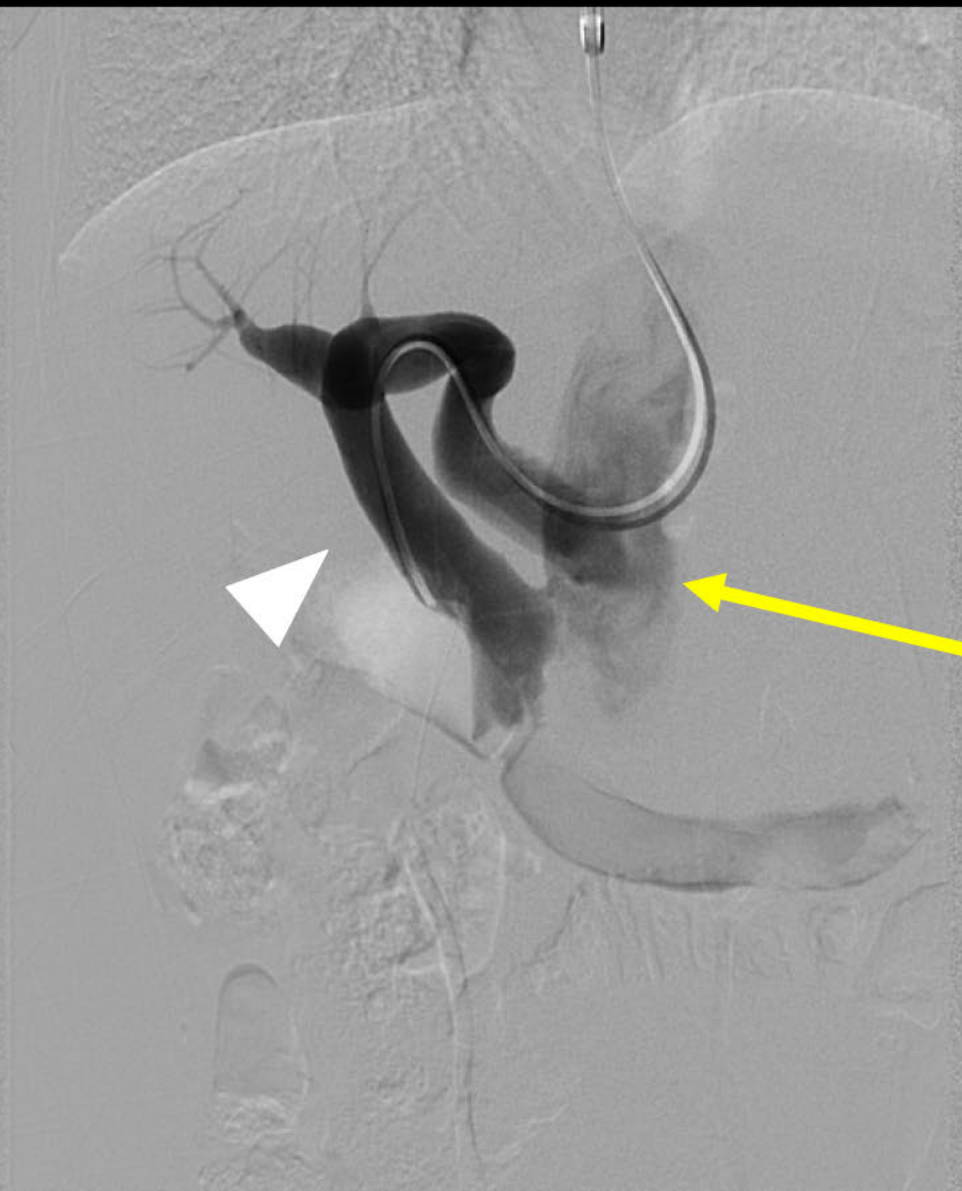# AIRP™

AMERICAN INSTITUTE FOR  
RADIOLOGIC PATHOLOGY

A PROGRAM OF THE  
AMERICAN COLLEGE OF RADIOLOGY

FOV: 32x32 cm  
RAO: 29.2 deg  
CRA: 0.6 deg  
L: 1.3 deg  
Tilt: 0 deg  
Mag = 1.00  
FL: ROT:

XA 800x800



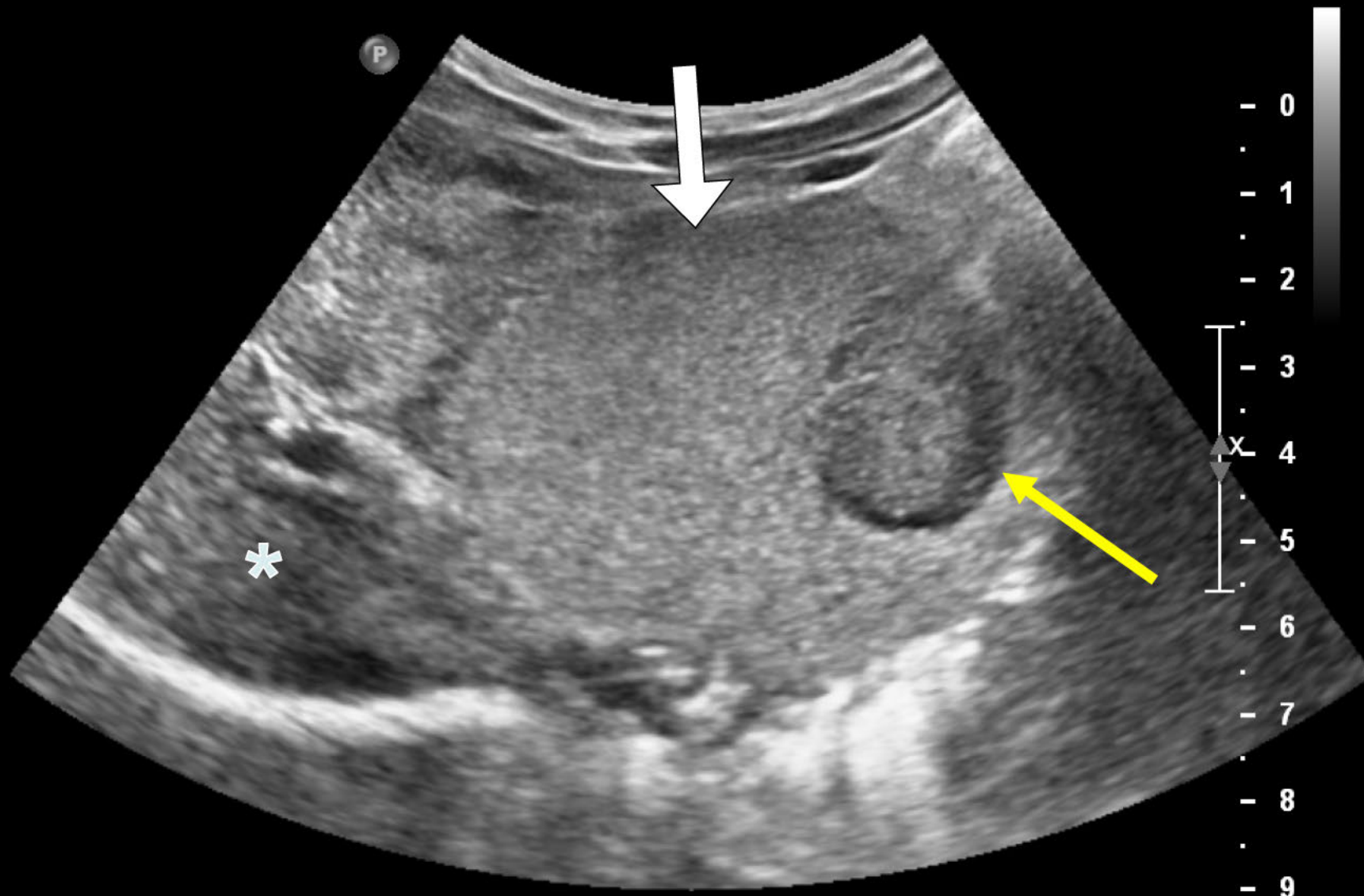
(Filt. 5)

Seq: 4  
FRAME = 12 / 25  
MASK = 3

FR 38Hz  
RS

2D  
41%  
C 50  
P Low  
Gen

M2

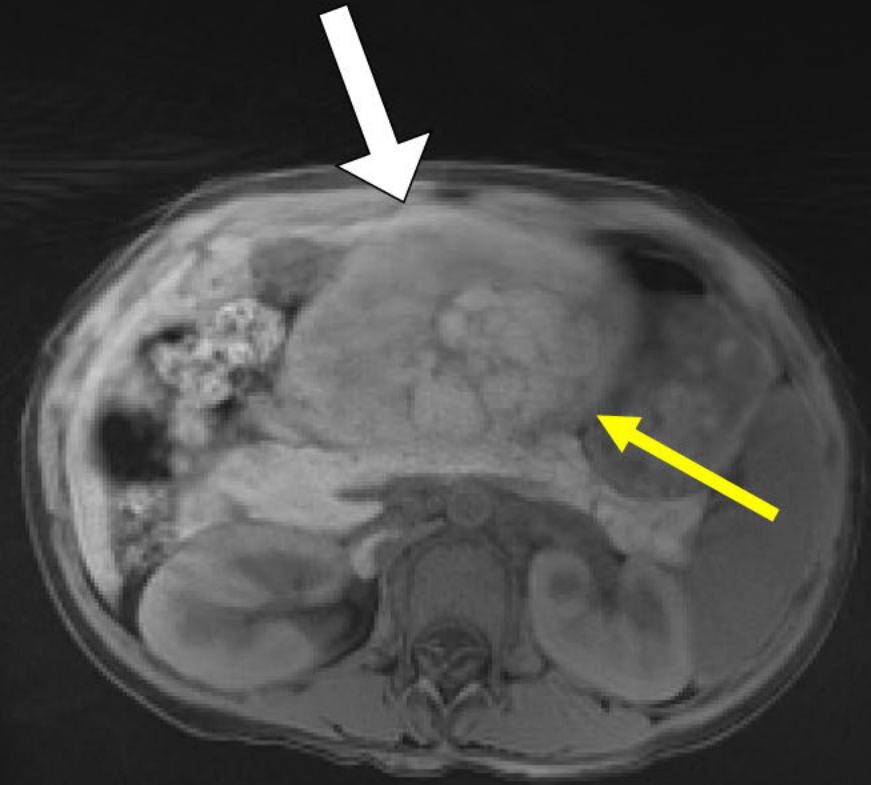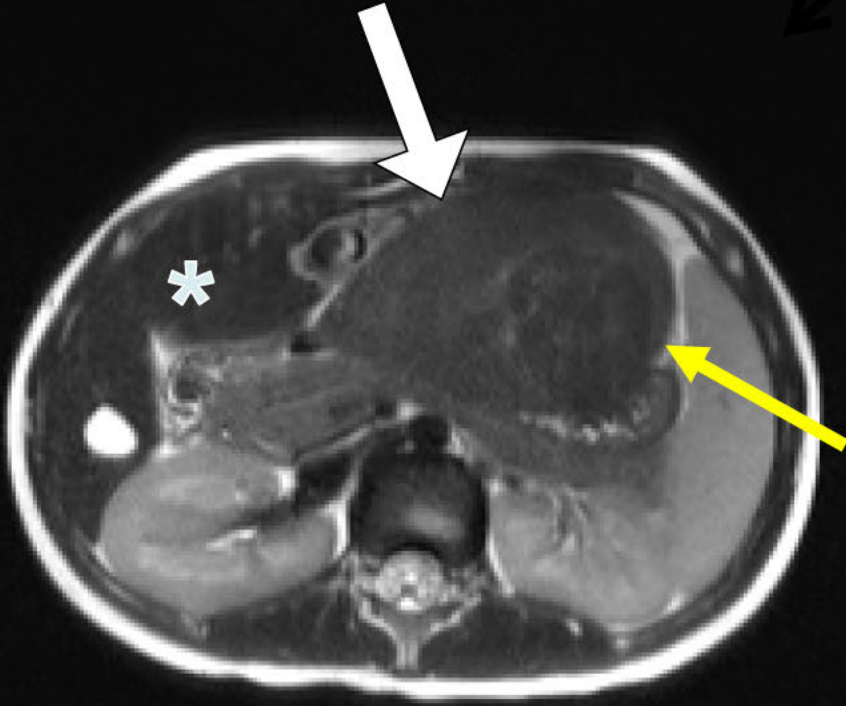


**AIRP**<sup>TM</sup>

AMERICAN INSTITUTE FOR  
RADIOLOGIC PATHOLOGY

A PROGRAM OF THE  
AMERICAN COLLEGE OF RADIOLOG

LIVER TRV

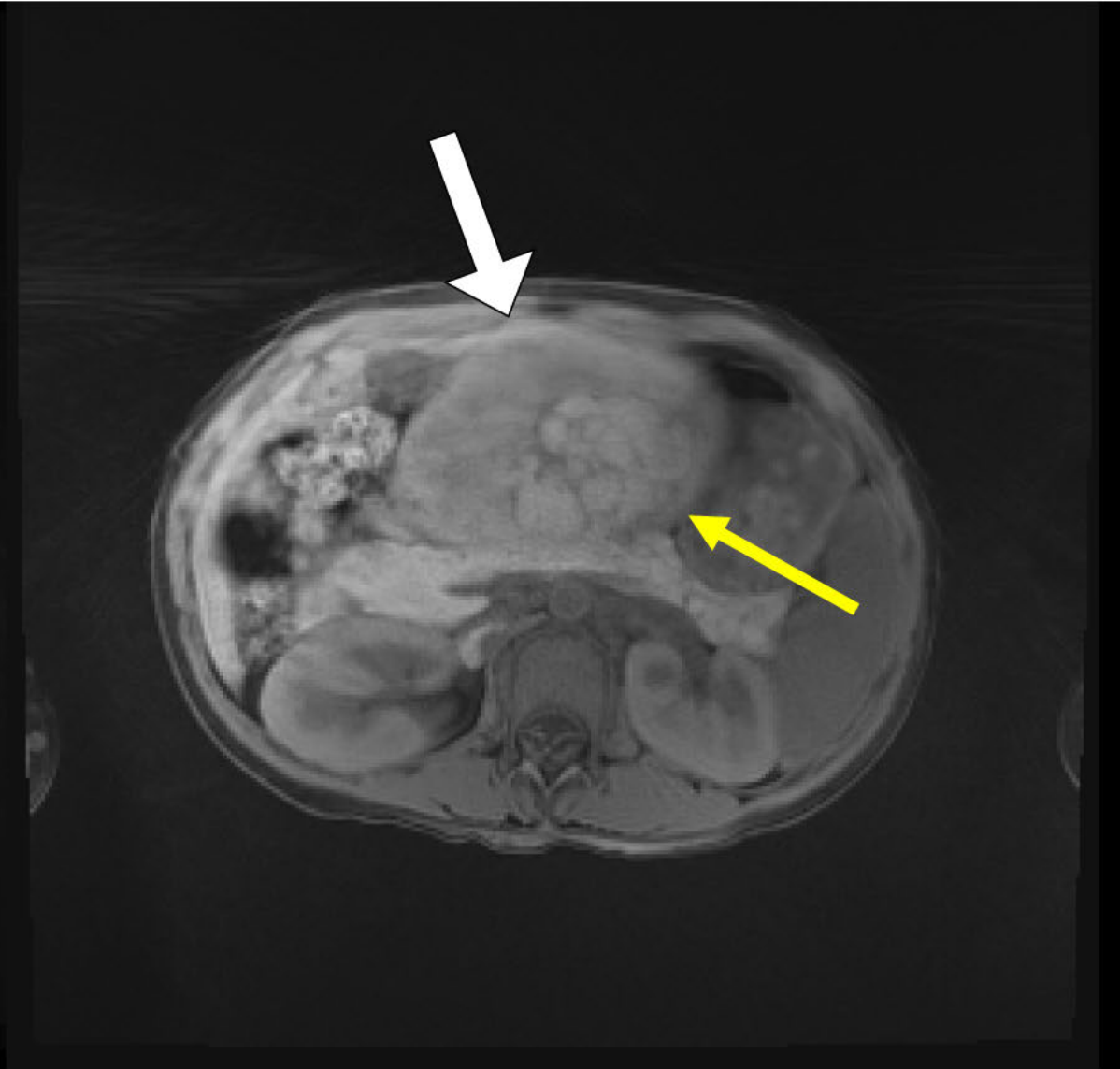
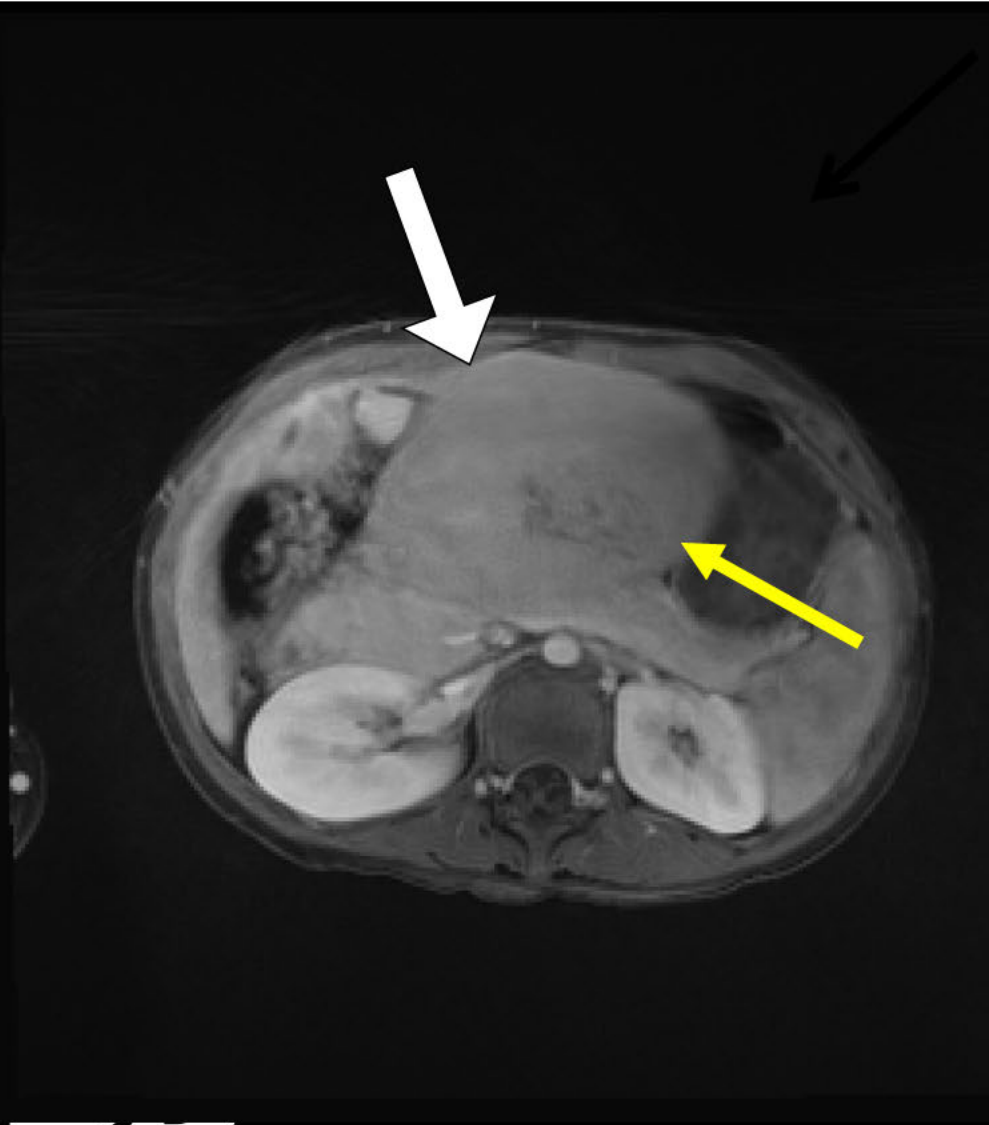

**AIRP**<sup>TM</sup>

AMERICAN INSTITUTE FOR  
RADIOLOGIC PATHOLOGY

A PROGRAM OF THE  
AMERICAN COLLEGE OF RADIOLOGY

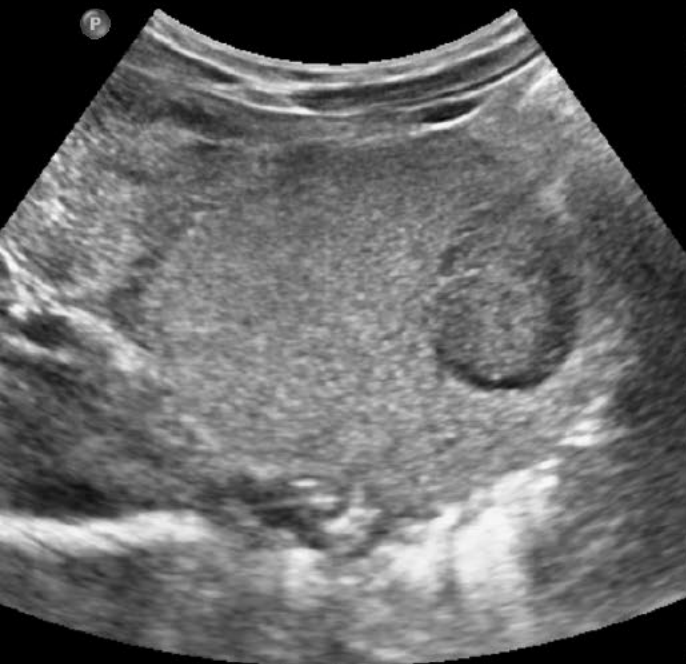



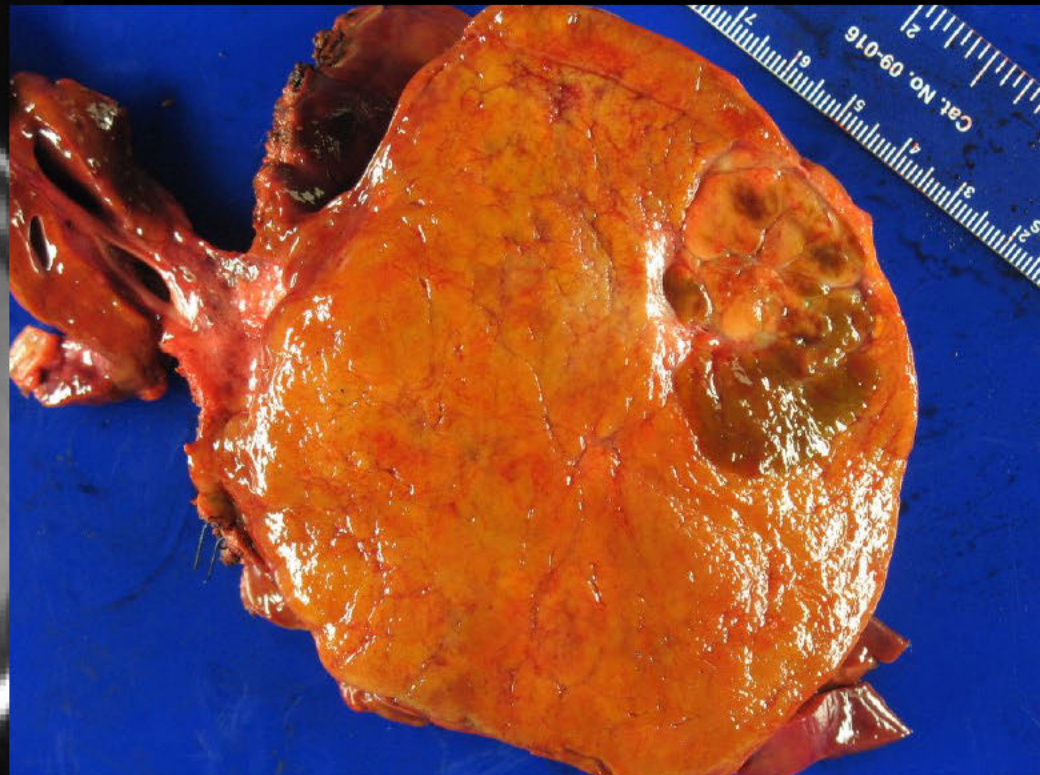
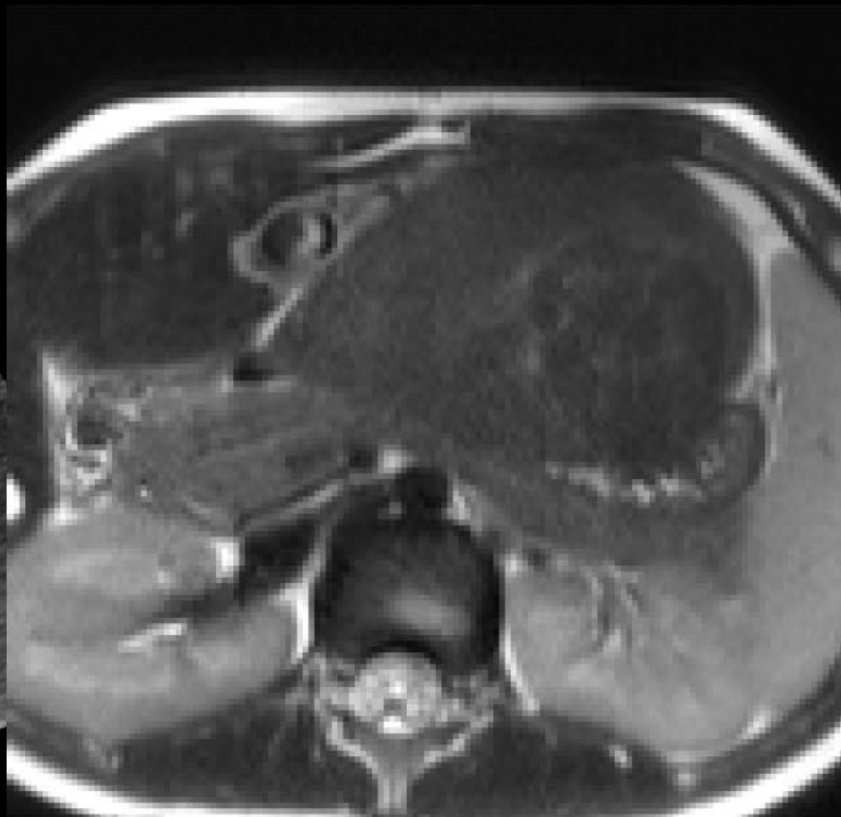**AI**

AMERICAN INSTITUTE FOR  
RADIOLOGIC PATHOLOGY

A PROGRAM OF THE  
AMERICAN COLLEGE OF RADIOLOGY



LIVER TRV

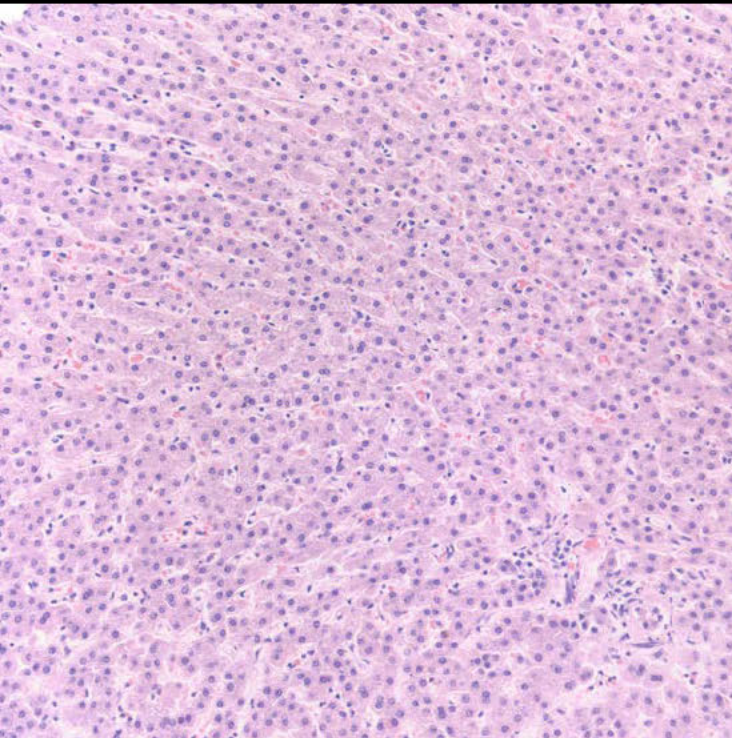


**AIRP**<sup>TM</sup>

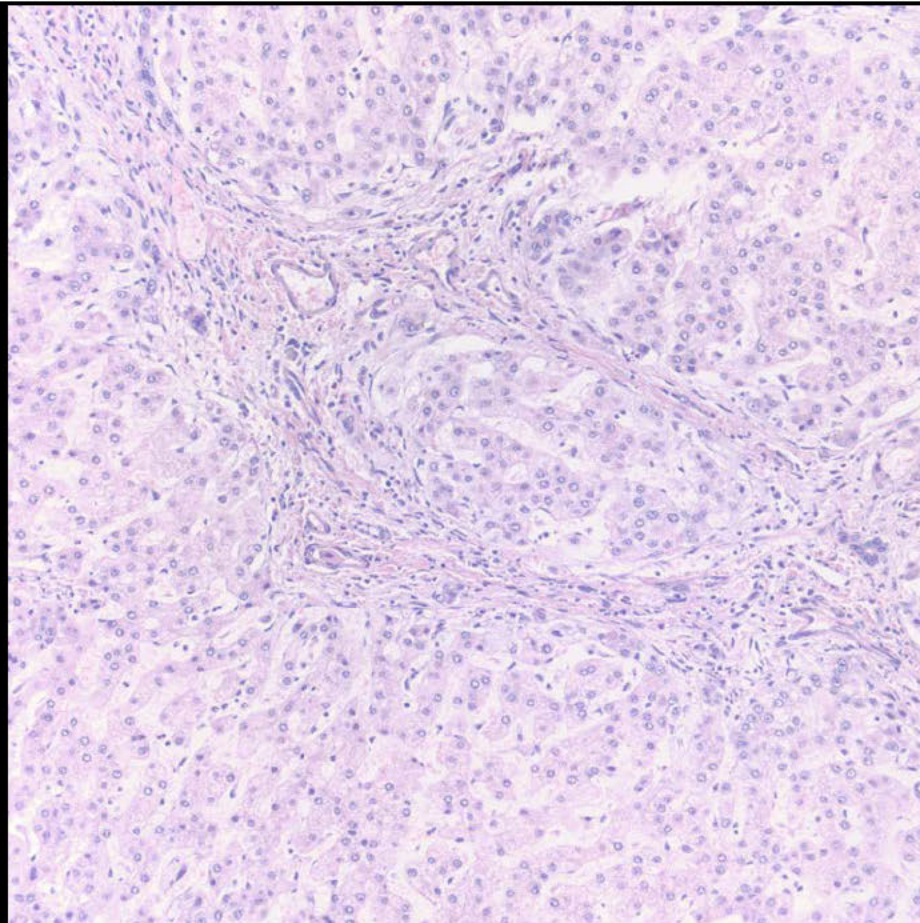
AMERICAN INSTITUTE FOR  
RADIOLOGIC PATHOLOGY

A PROGRAM OF THE  
AMERICAN COLLEGE OF RADIOLOGY

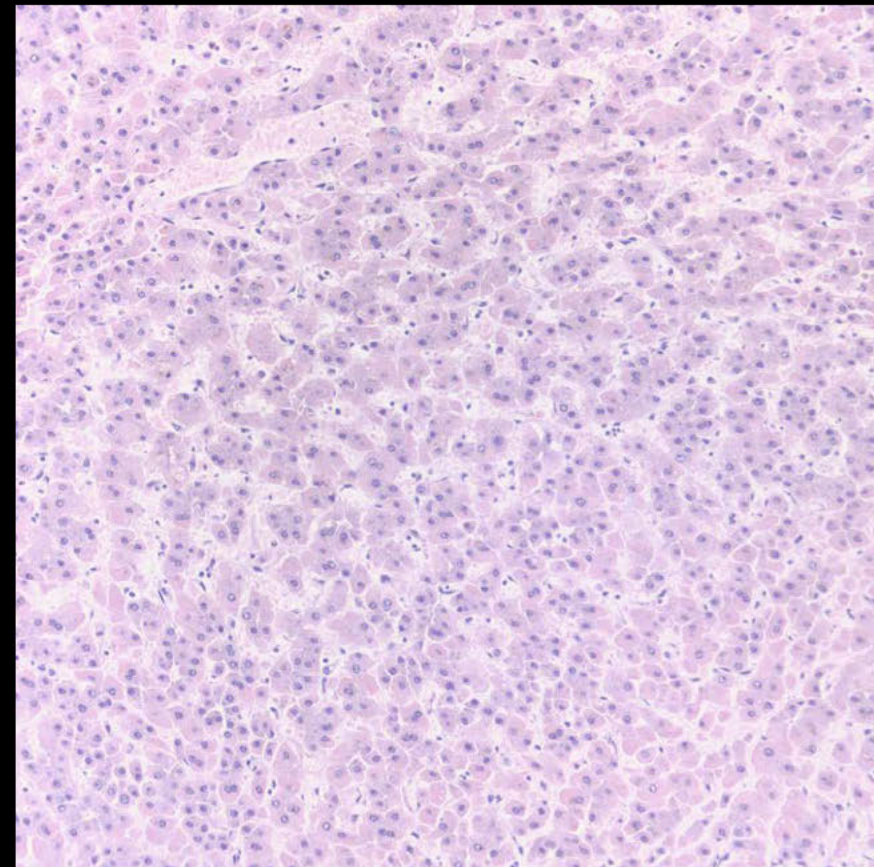




Liver



Adenoma



WD -  
Carcinoma

**AIRP**<sup>TM</sup>

AMERICAN INSTITUTE FOR  
RADIOLOGIC PATHOLOGY

A PROGRAM OF THE  
AMERICAN COLLEGE OF RADIOLOGY



# Well-differentiated hepatocellular carcinoma arising in a Beta-catenin-mutated hepatic adenoma in the setting of Abernethy malformation

Junaid Raja

Yale New Haven Hospital

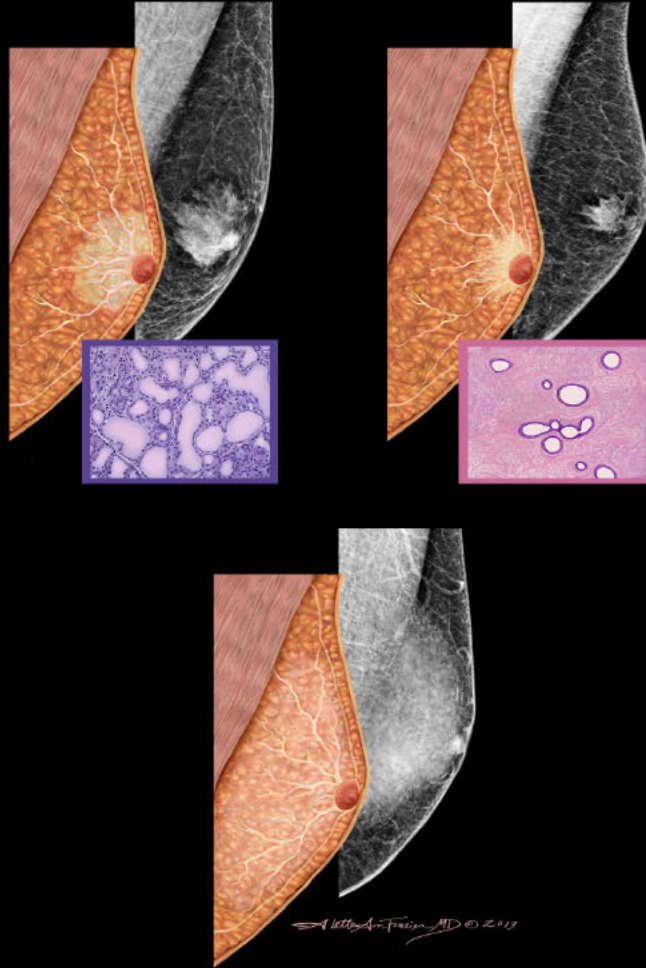
New Haven, CT

**AIRP**<sup>TM</sup>

AMERICAN INSTITUTE FOR  
RADIOLOGIC PATHOLOGY

A PROGRAM OF THE  
AMERICAN COLLEGE OF RADIOLOGY

# Breast Best Case



**AIRP**<sup>TM</sup>

AMERICAN INSTITUTE FOR  
RADIOLOGIC PATHOLOGY

A PROGRAM OF THE  
AMERICAN COLLEGE OF RADIOLOGY

# Clinical information

**77-year-old woman with enlarging mass in the left breast, ~8 cm in size, with overlying eczema. No family history of breast cancer.**

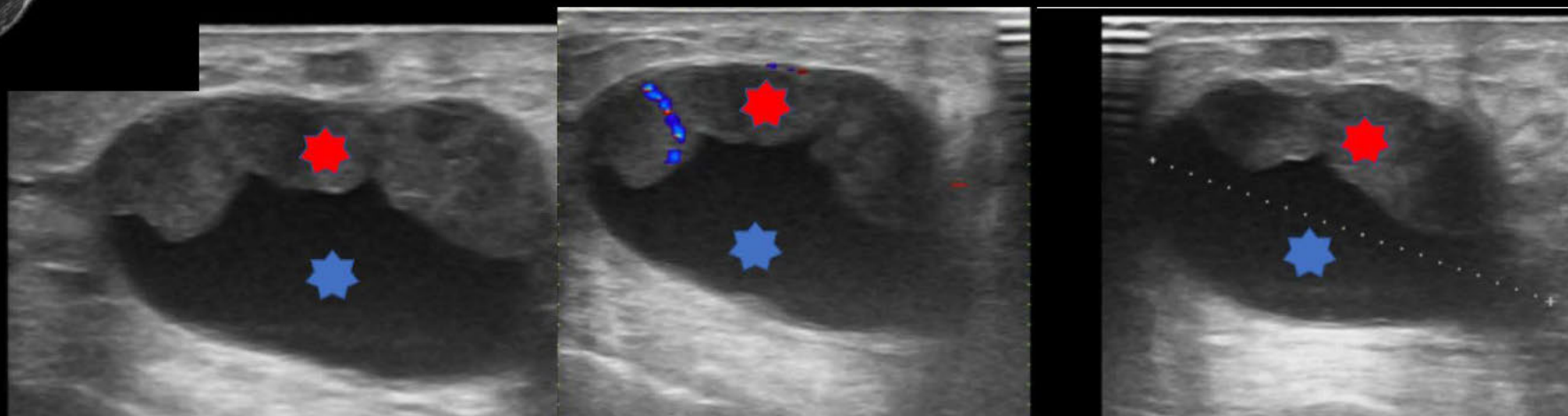
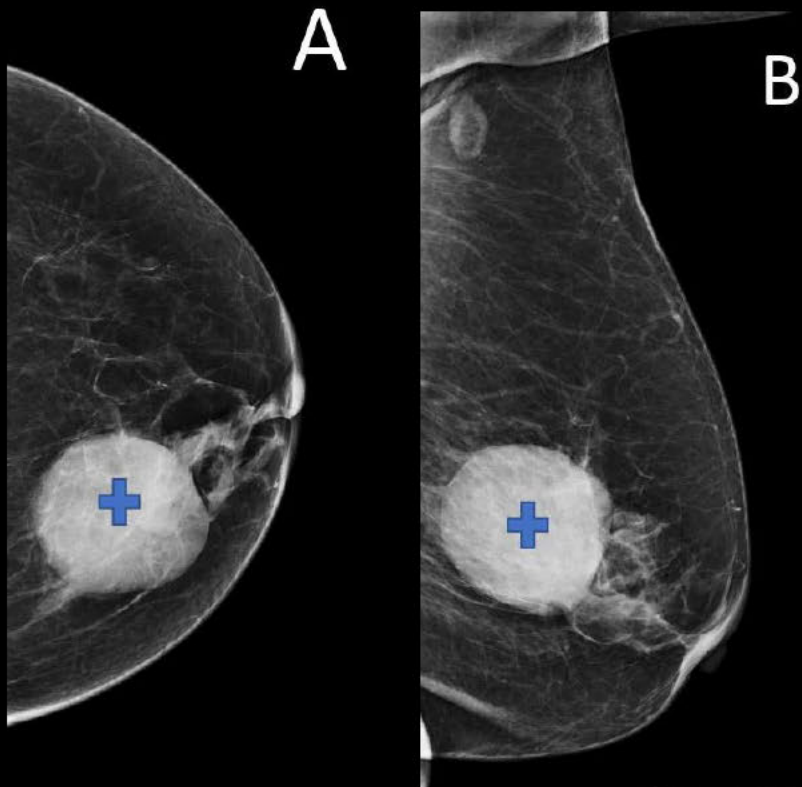


AMERICAN INSTITUTE FOR  
RADIOLOGIC PATHOLOGY

---

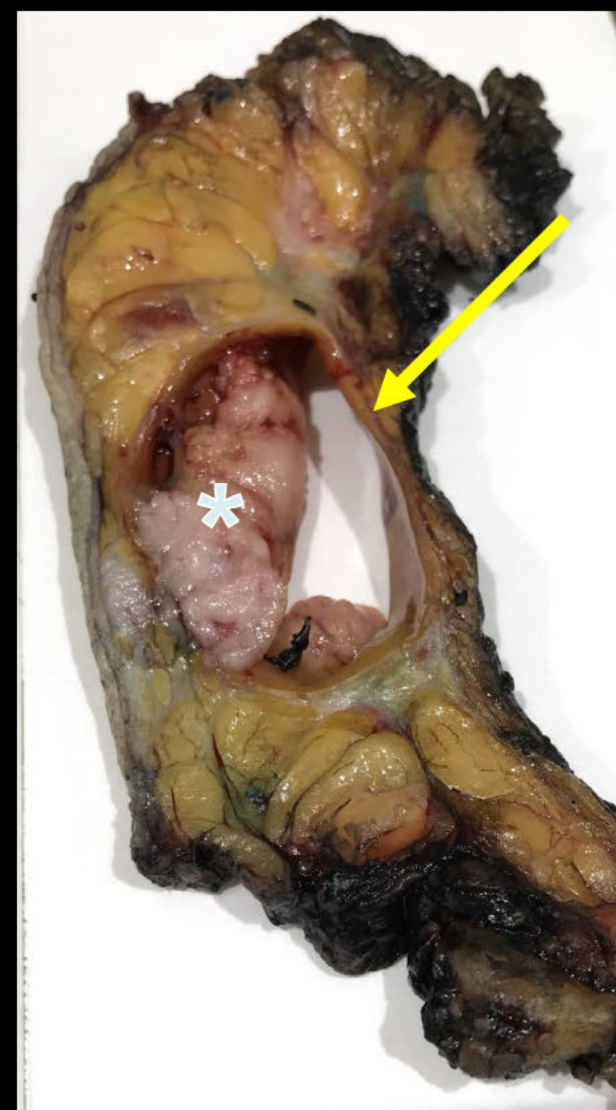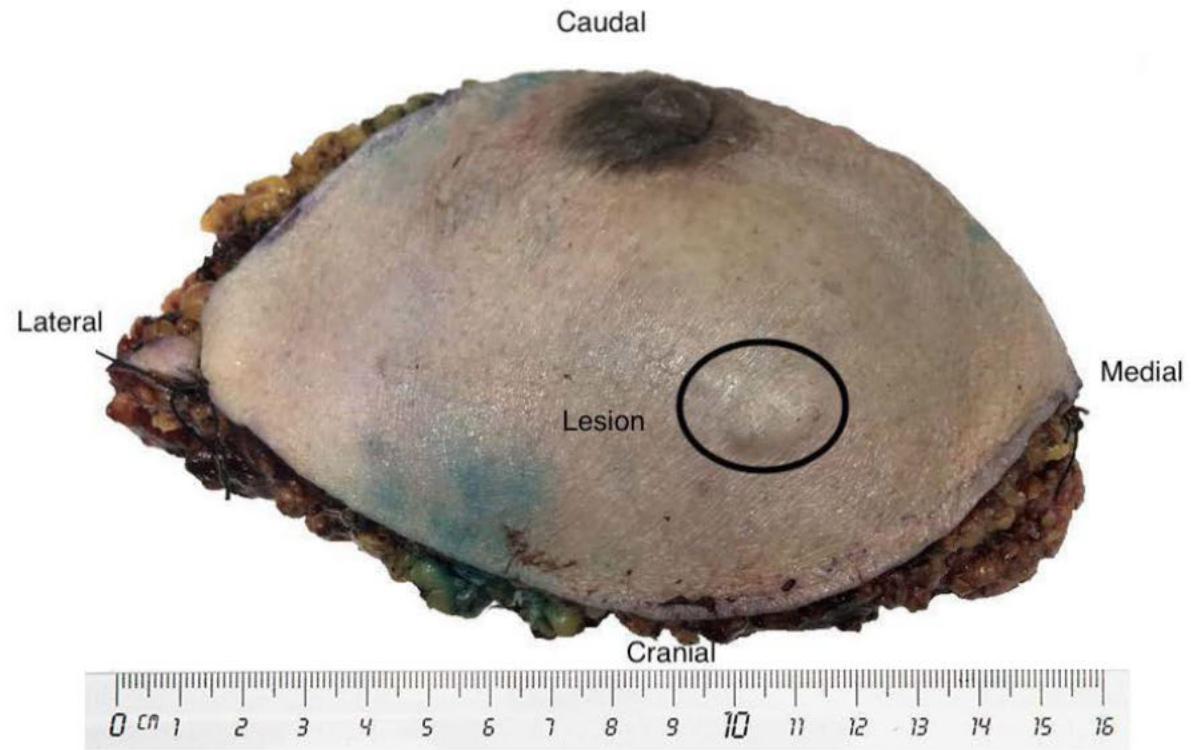
A PROGRAM OF THE  
AMERICAN COLLEGE OF RADIOLOGY





**AIRP**<sup>TM</sup>  
AMERICAN INSTITUTE FOR  
RADIOLOGIC PATHOLOGY

A PROGRAM OF THE  
AMERICAN COLLEGE OF RADIOLOGY



**AIRP**<sup>TM</sup>

AMERICAN INSTITUTE FOR  
RADIOLOGIC PATHOLOGY

A PROGRAM OF THE  
AMERICAN COLLEGE OF RADIOLOGY

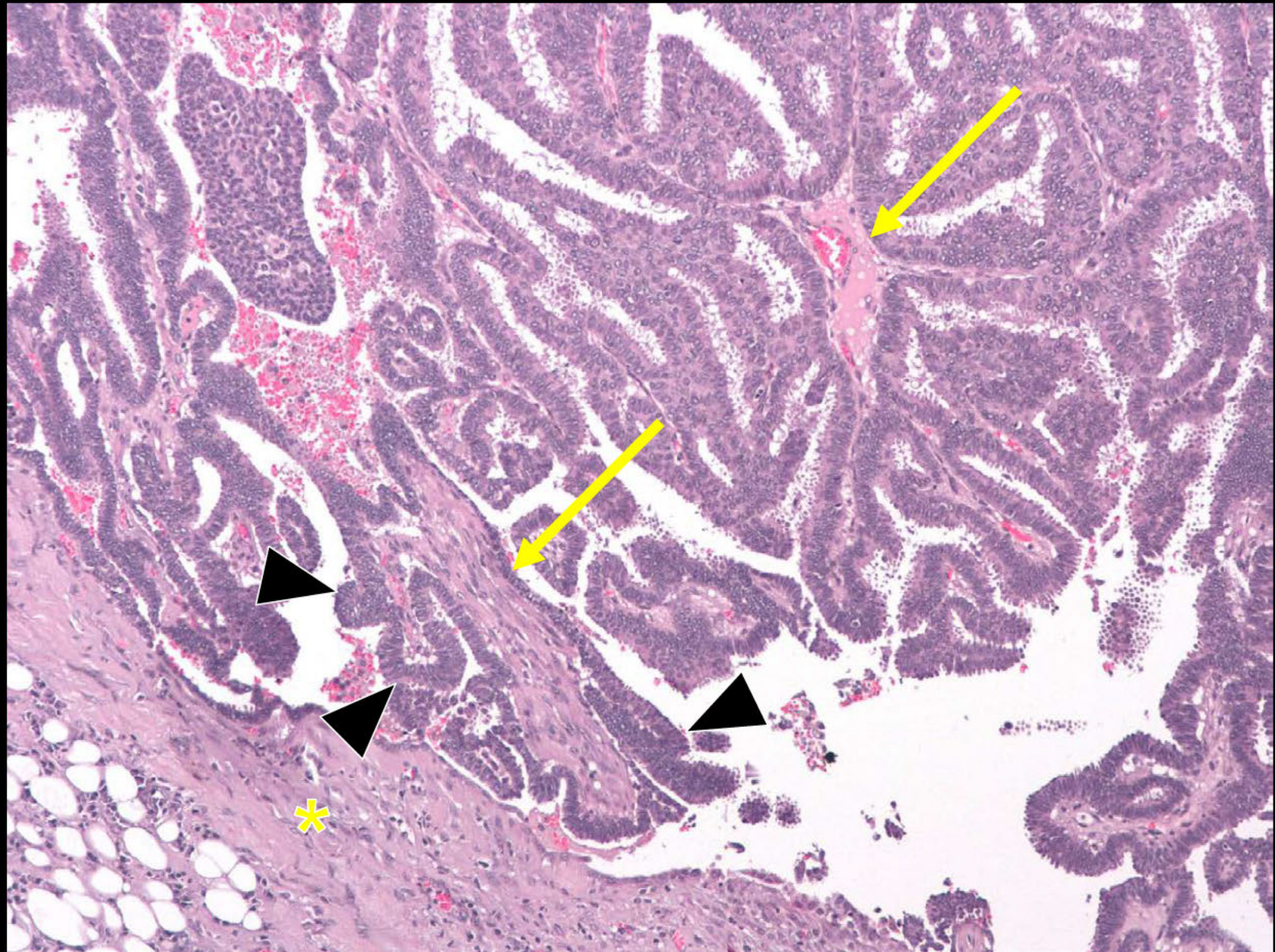




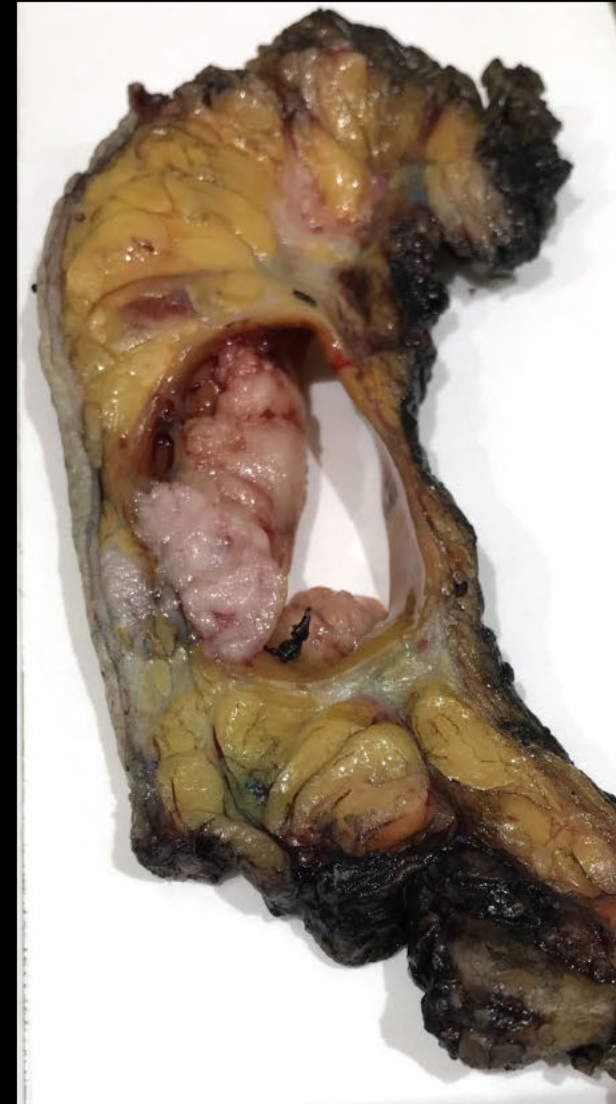
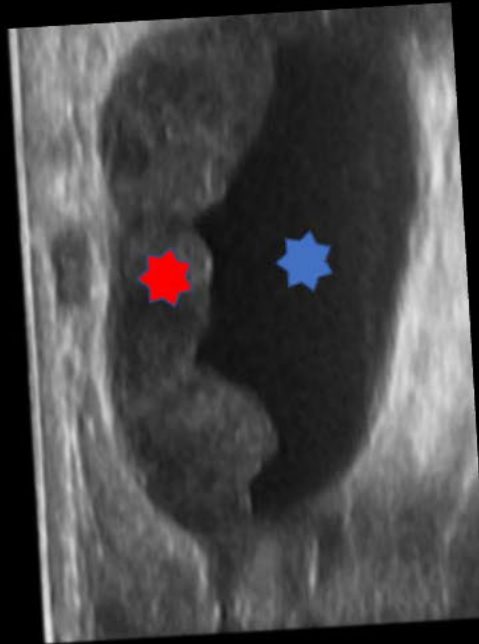
**AIRP**<sup>TM</sup>

AMERICAN INSTITUTE FOR  
RADIOLOGIC PATHOLOGY

A PROGRAM OF THE  
AMERICAN COLLEGE OF RADIOLOGY







**AIRP**<sup>TM</sup>

AMERICAN INSTITUTE FOR  
RADIOLOGIC PATHOLOGY

A PROGRAM OF THE  
AMERICAN COLLEGE OF RADIOLOGY

# Intra-cystic Papillary Carcinoma

**Andrea Dominguez**

**HOSPITAL UNIVERSITARIO VIRGEN DE LA VICTORIA**

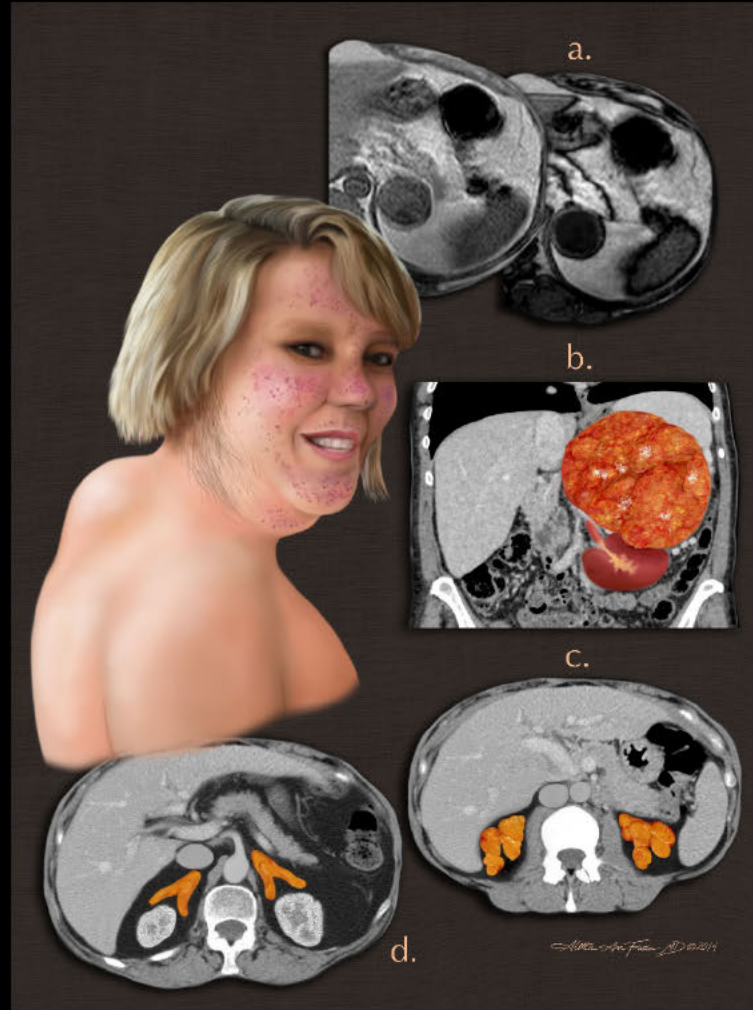**Malaga, Spain**

**AIRP**<sup>TM</sup>

AMERICAN INSTITUTE FOR  
RADIOLOGIC PATHOLOGY

A PROGRAM OF THE  
AMERICAN COLLEGE OF RADIOLOGY

# Genitourinary Best Case



**AIRP**<sup>TM</sup>

AMERICAN INSTITUTE FOR  
RADIOLOGIC PATHOLOGY

A PROGRAM OF THE  
AMERICAN COLLEGE OF RADIOLOGY



# Clinical information

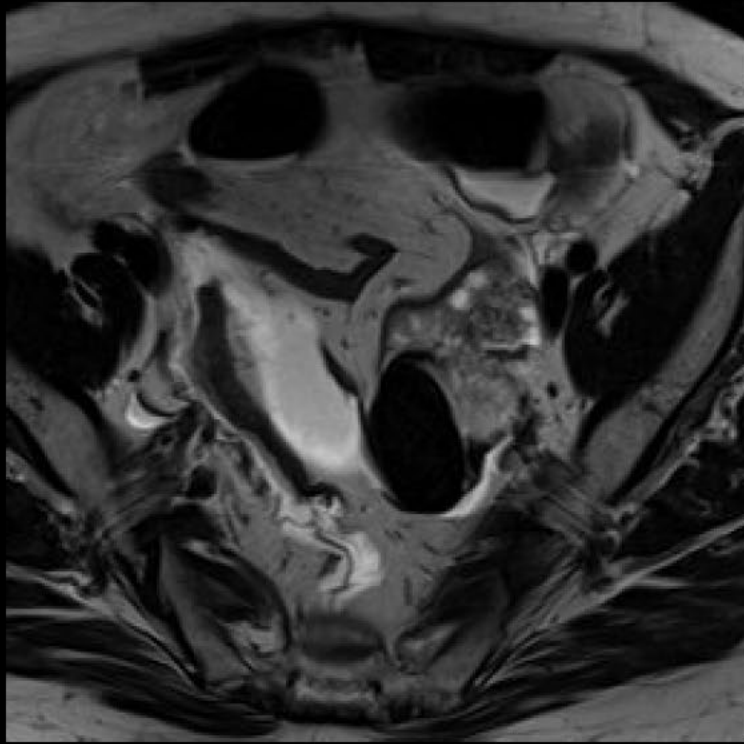
**66 years old female with 2 days of left lower back pain radiating to the left flank with associated with nausea and vomiting.**

**At physical examination, there was tenderness in the left adnexa.**

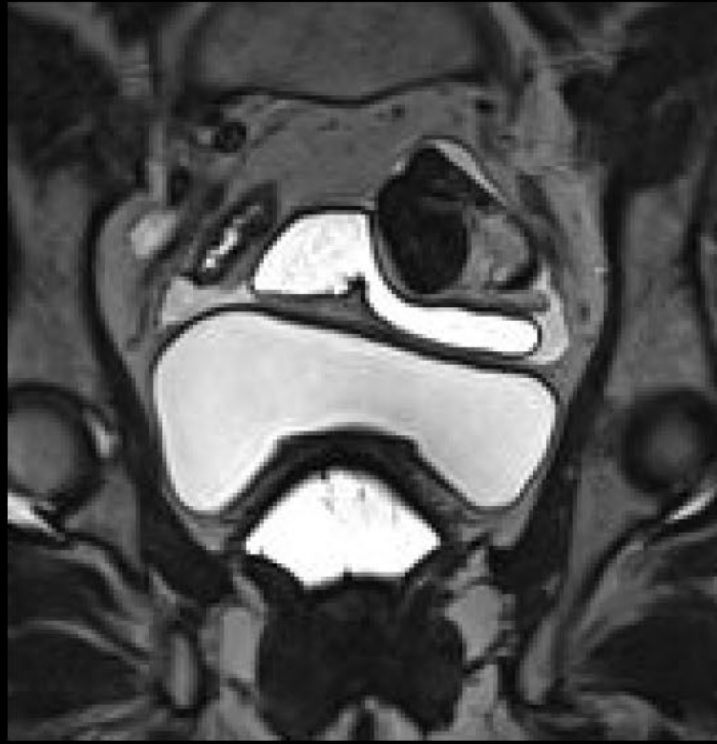


**AMERICAN INSTITUTE FOR  
RADIOLOGIC PATHOLOGY**

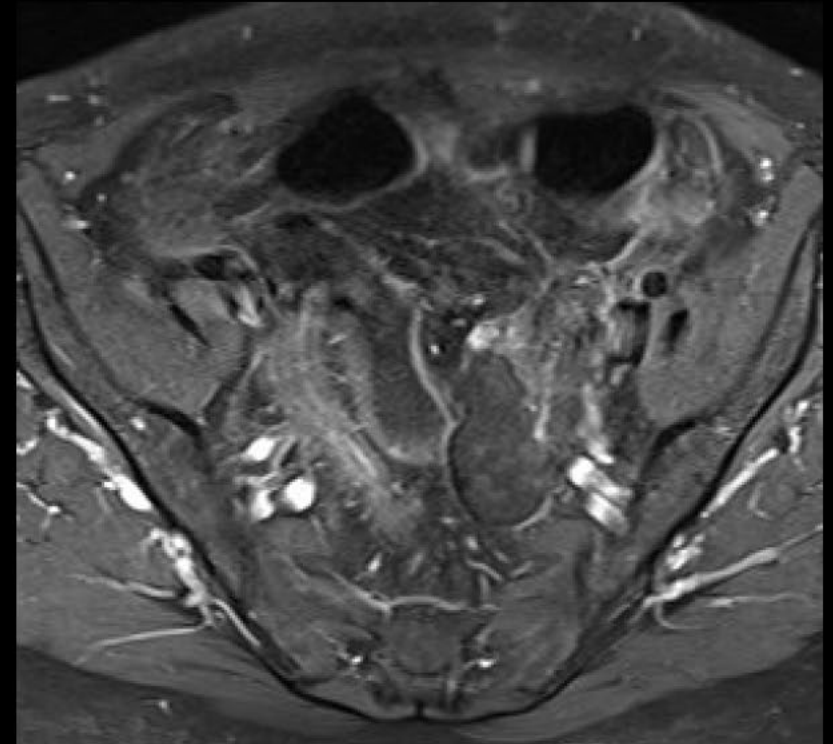
**A PROGRAM OF THE  
AMERICAN COLLEGE OF RADIOLOGY**



**Axial T2**



**Coronal T2**

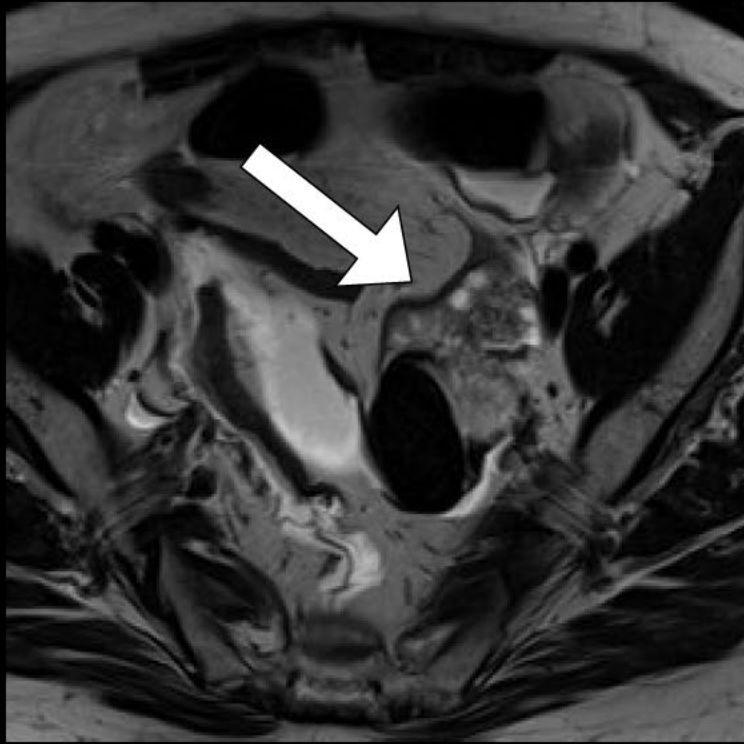


**Axial T1 fat sat post**

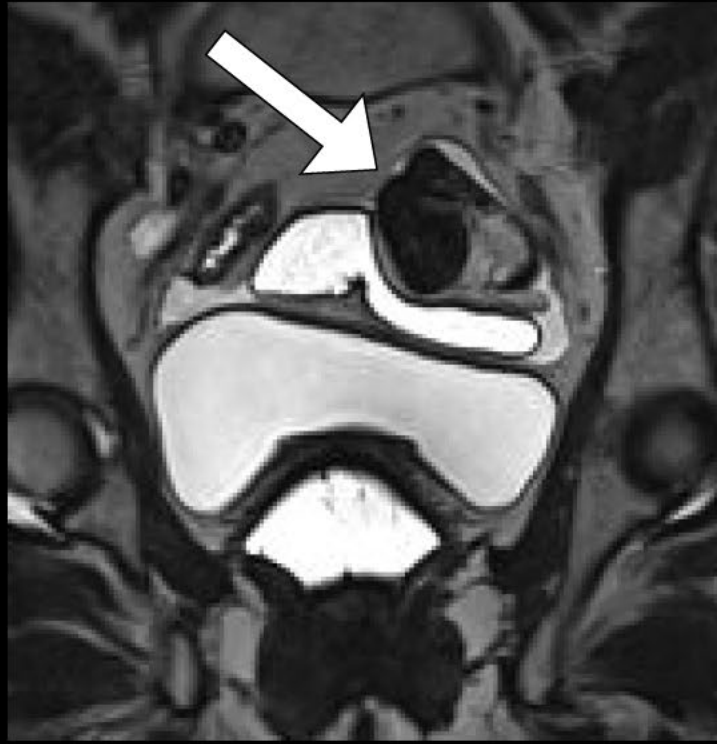**AIRP**<sup>TM</sup>

AMERICAN INSTITUTE FOR  
RADIOLOGIC PATHOLOGY

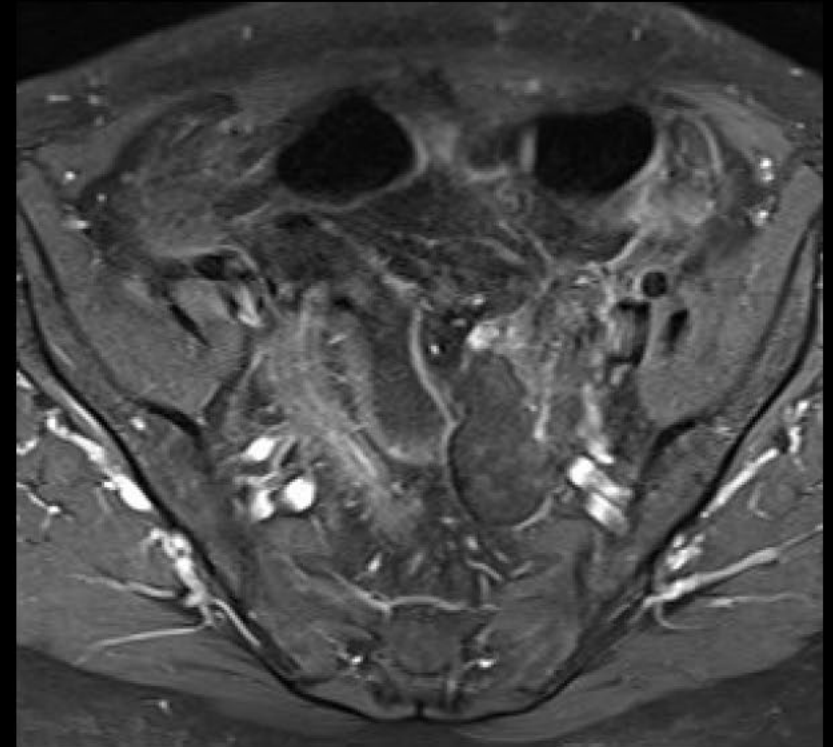
A PROGRAM OF THE  
AMERICAN COLLEGE OF RADIOLOGY



**Axial T2**



**Coronal T2**



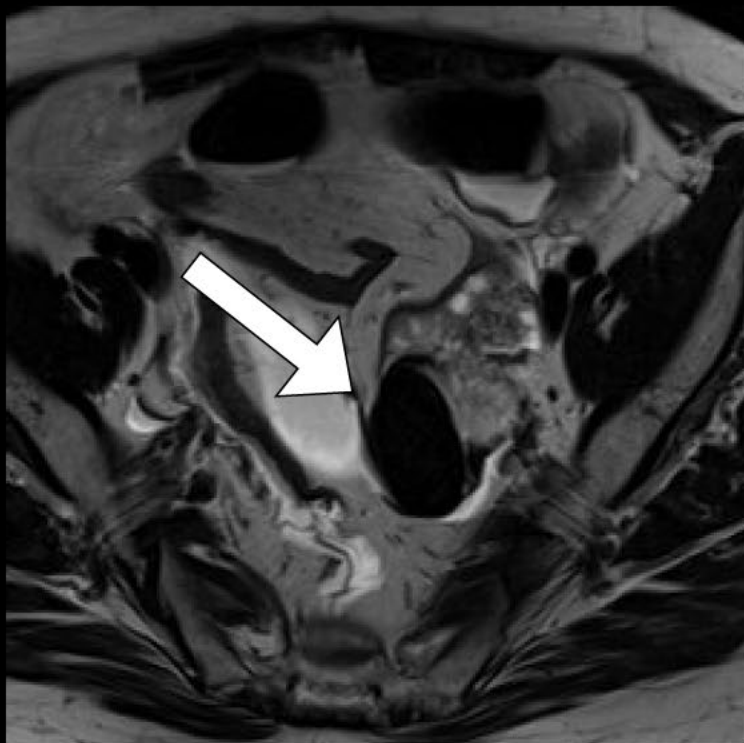
**Axial T1 fat sat post**

**AIRP**<sup>TM</sup>

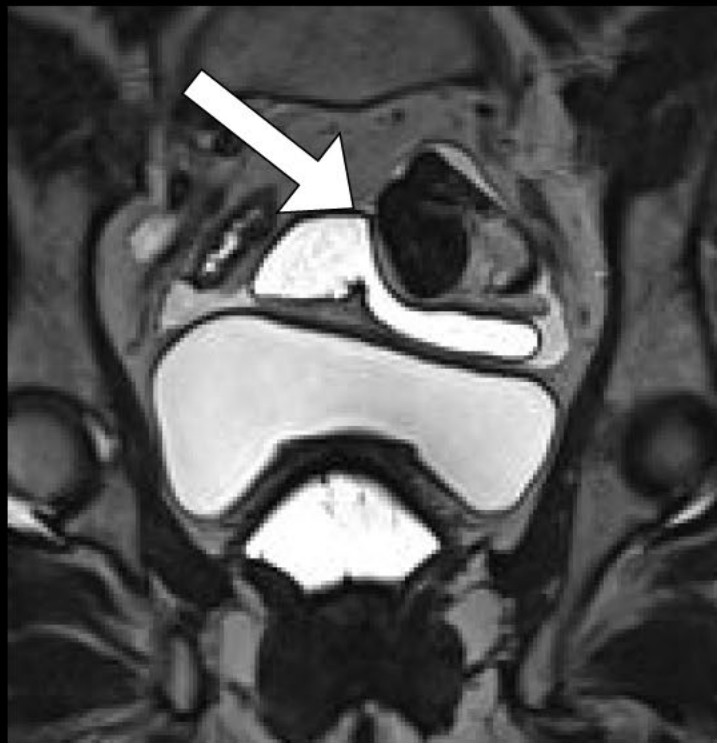
AMERICAN INSTITUTE FOR  
RADIOLOGIC PATHOLOGY

A PROGRAM OF THE  
AMERICAN COLLEGE OF RADIOLOGY

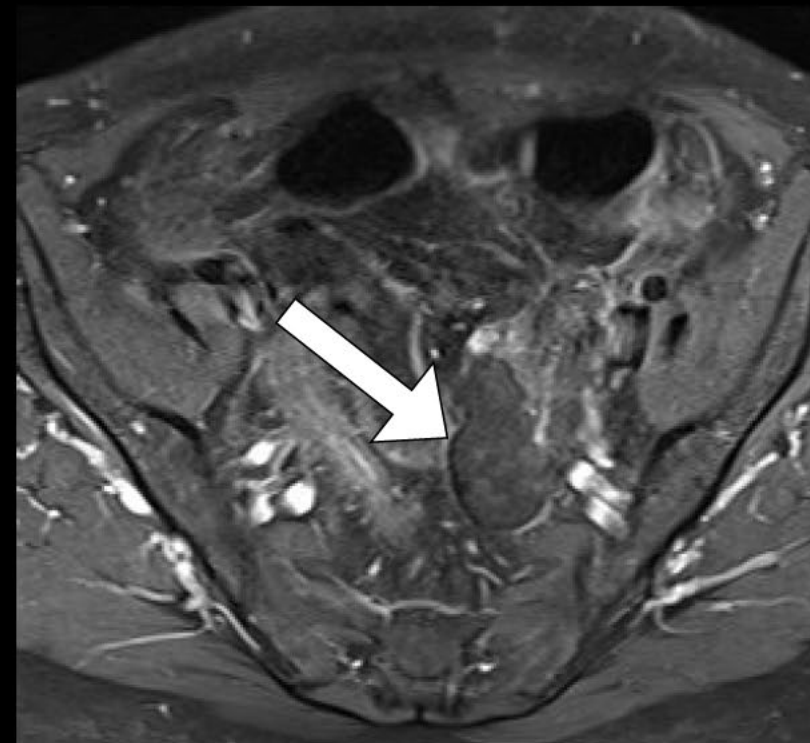




**Axial T2**



**Coronal T2**



**Axial T1 fat sat post**

**AIRP**<sup>TM</sup>

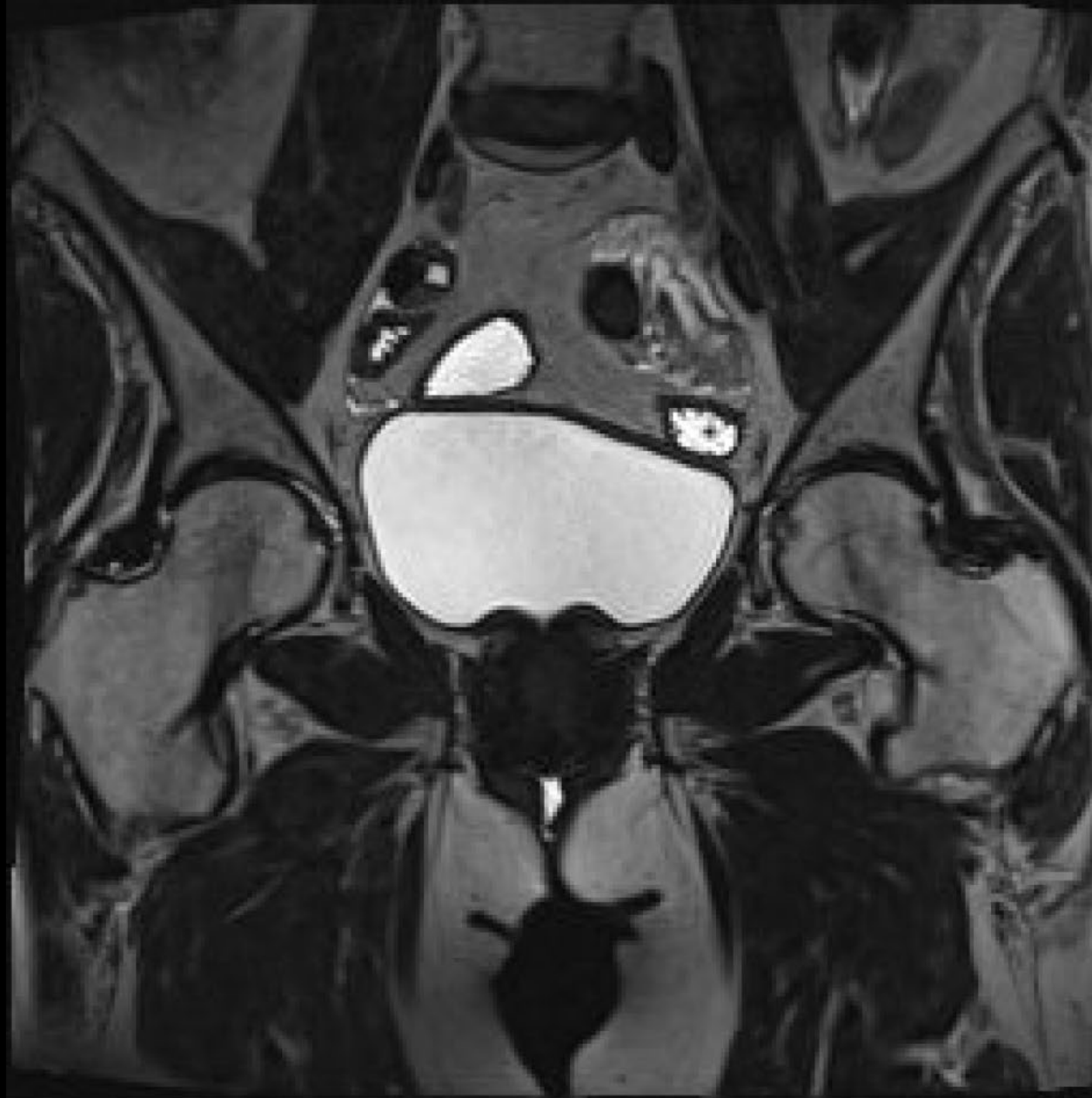
AMERICAN INSTITUTE FOR  
RADIOLOGIC PATHOLOGY

A PROGRAM OF THE  
AMERICAN COLLEGE OF RADIOLOGY

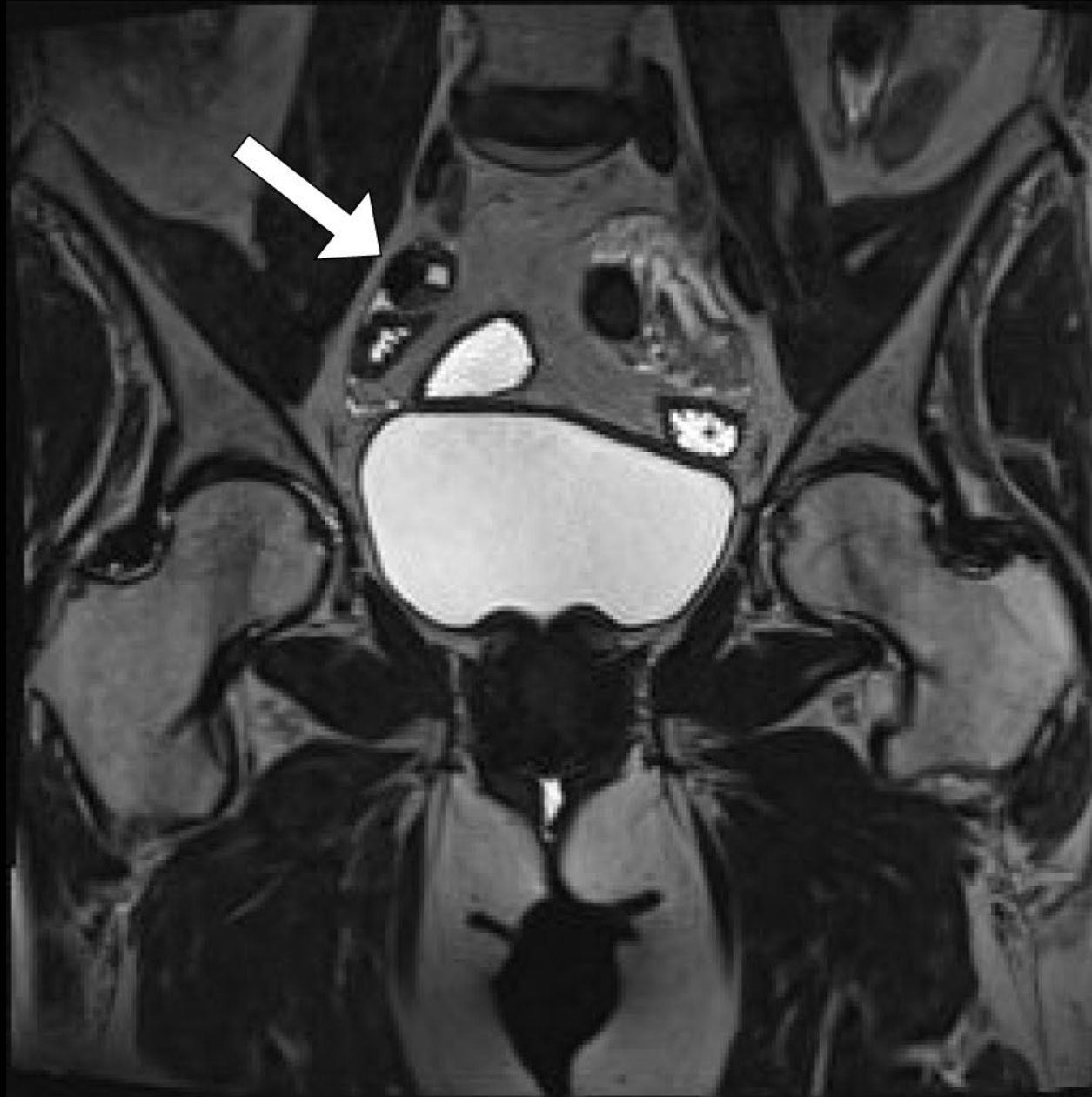**AIRP**<sup>TM</sup>

AMERICAN INSTITUTE FOR  
RADIOLOGIC PATHOLOGY

A PROGRAM OF THE  
AMERICAN COLLEGE OF RADIOLOGY



**Coronal T2**



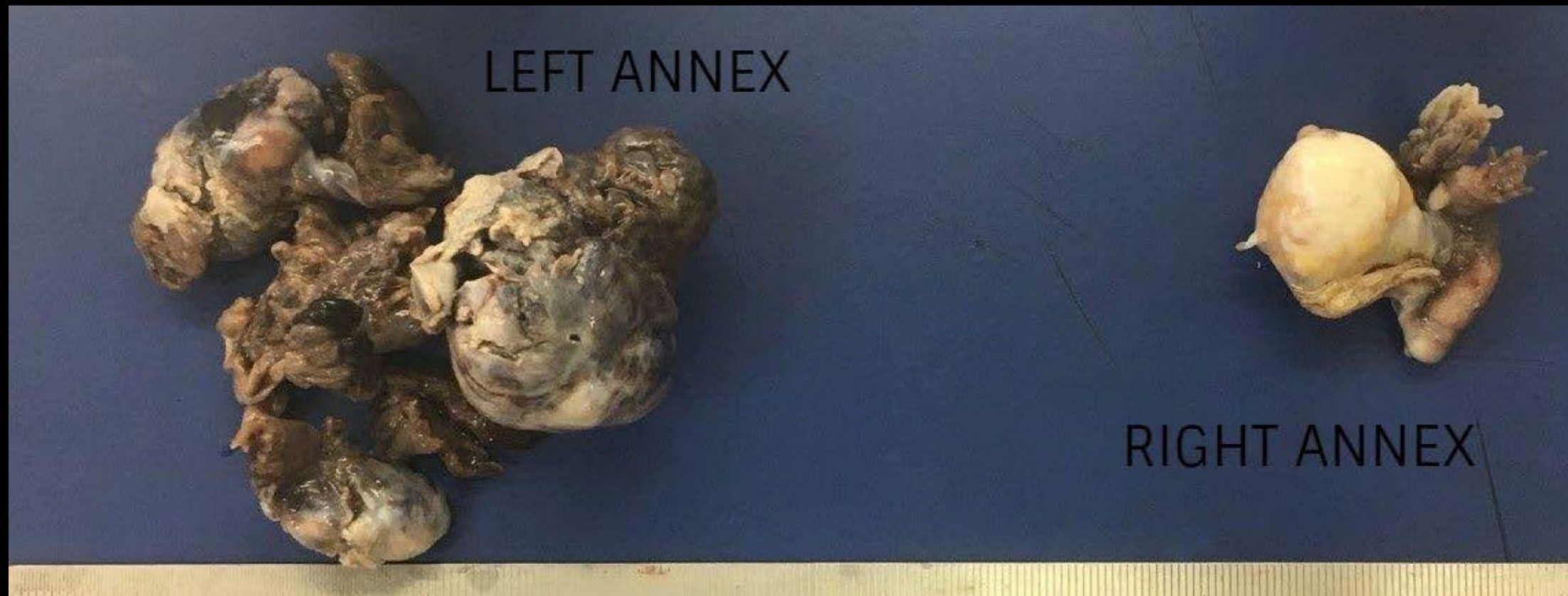**AIRP**<sup>TM</sup>

AMERICAN INSTITUTE FOR  
RADIOLOGIC PATHOLOGY

A PROGRAM OF THE  
AMERICAN COLLEGE OF RADIOLOGY

**Coronal T2**





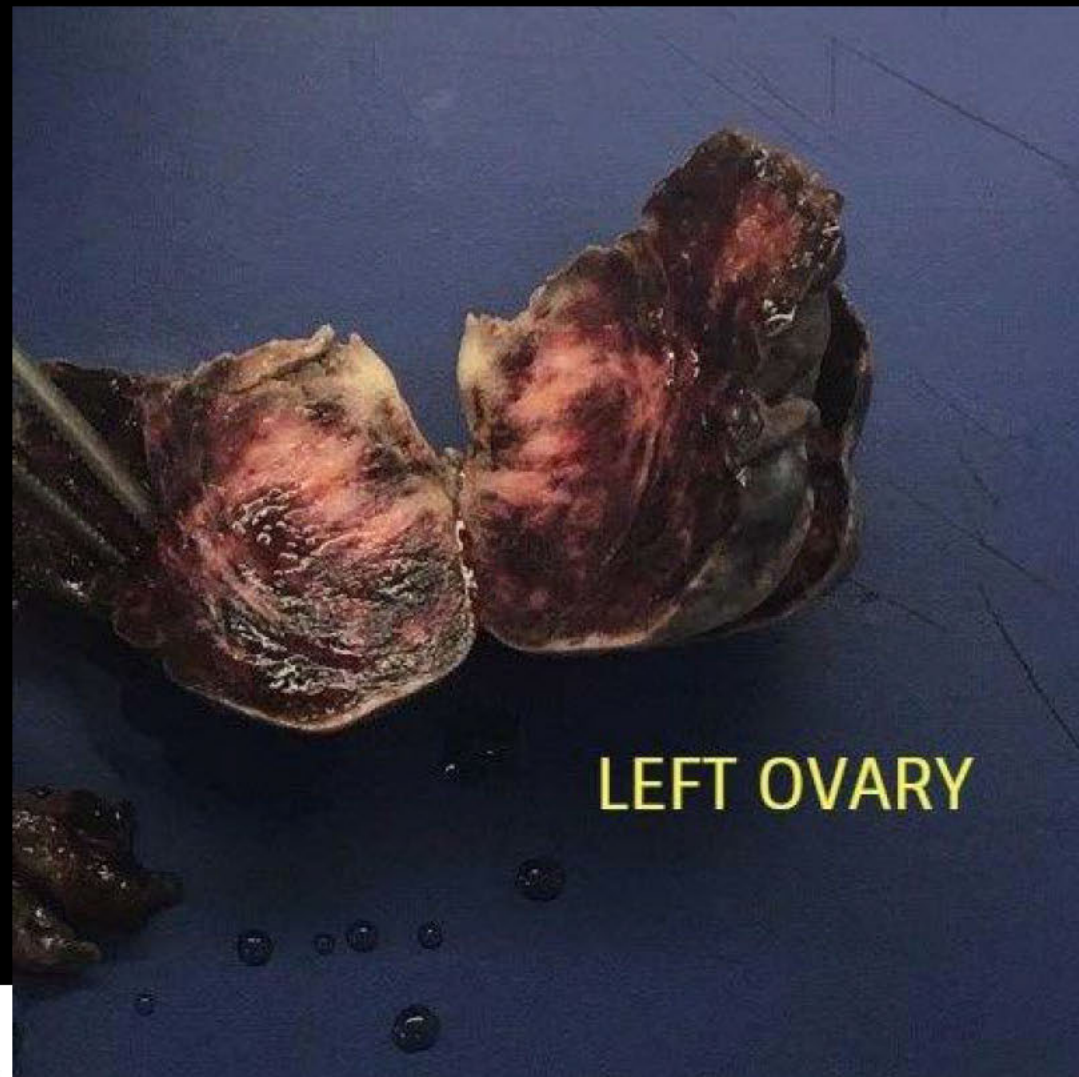LEFT ANNEX

RIGHT ANNEX

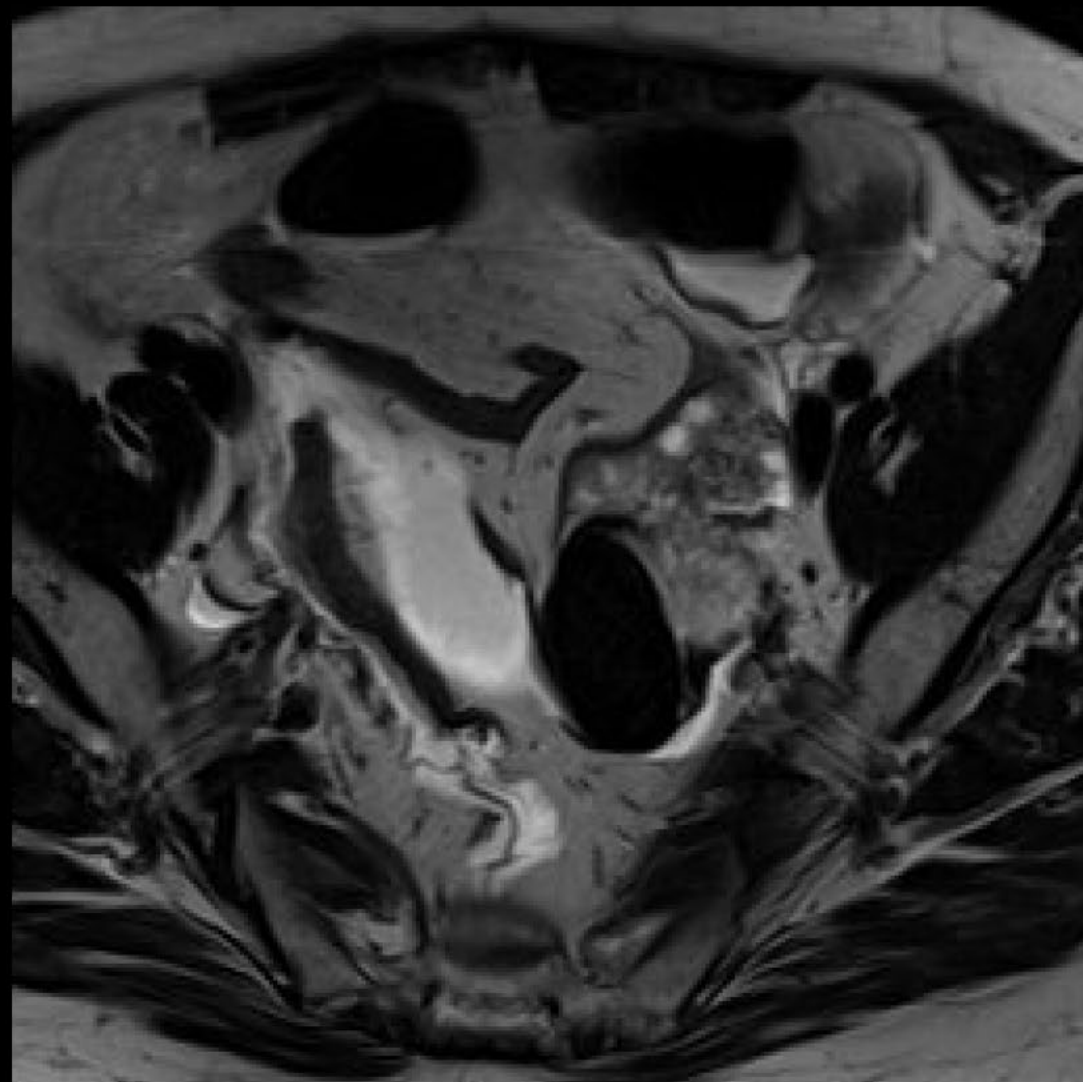
**AIRP**<sup>TM</sup>

AMERICAN INSTITUTE FOR  
RADIOLOGIC PATHOLOGY

A PROGRAM OF THE  
AMERICAN COLLEGE OF RADIOLOGY



LEFT OVARY

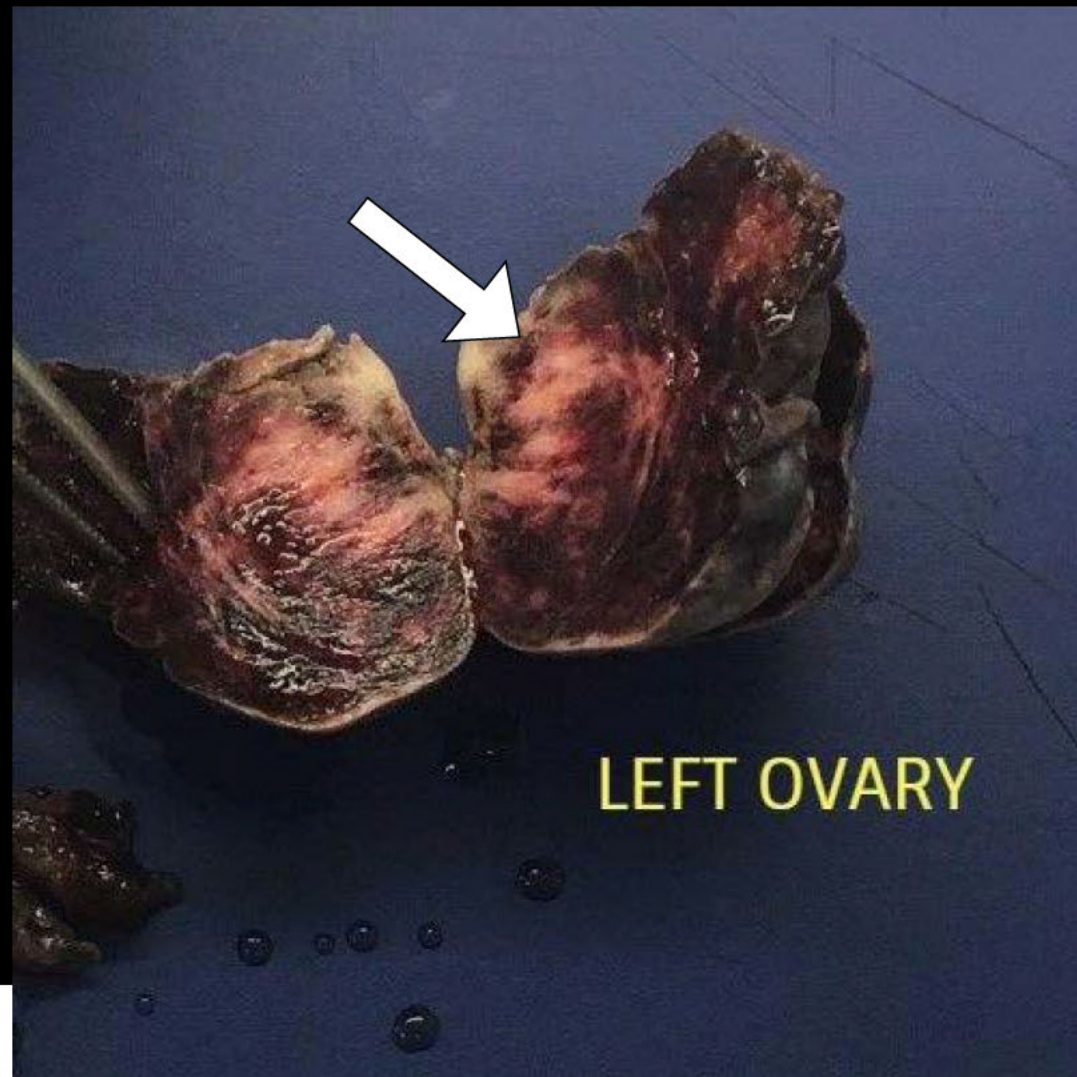


**AIR**

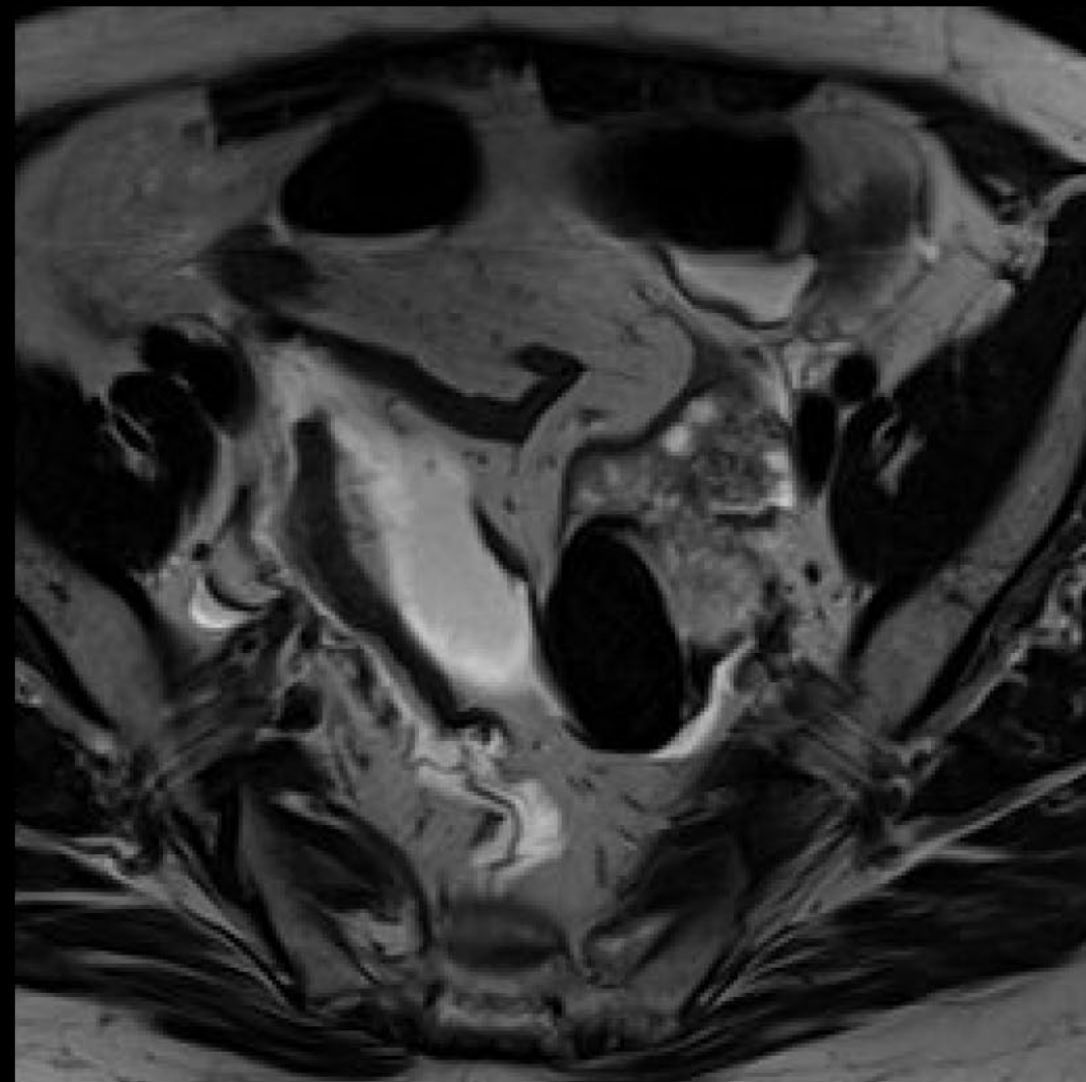
AMERICAN INSTITUTE FOR  
RADIOLOGIC PATHOLOGY

A PROGRAM OF THE  
AMERICAN COLLEGE OF RADIOLOGY





LEFT OVARY

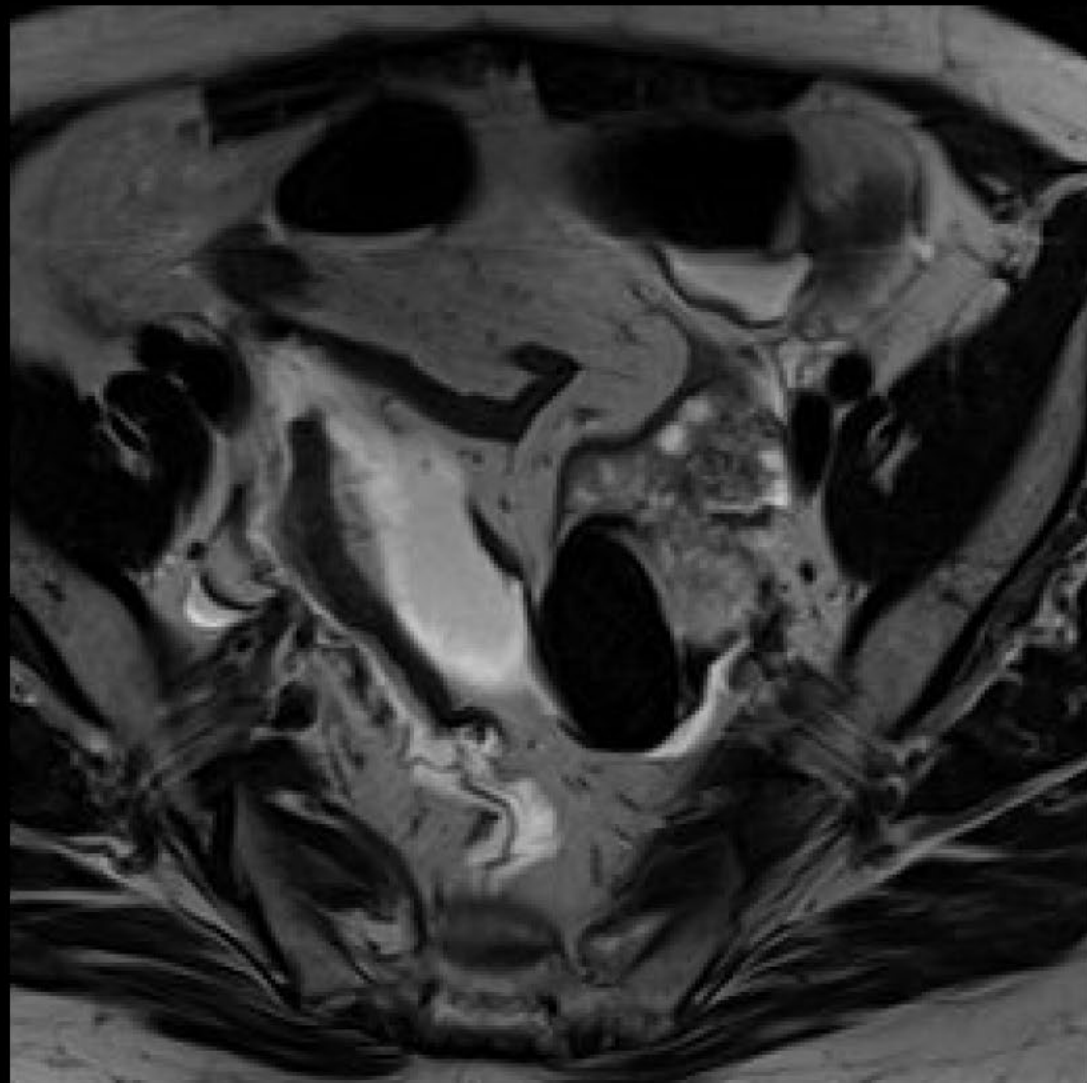
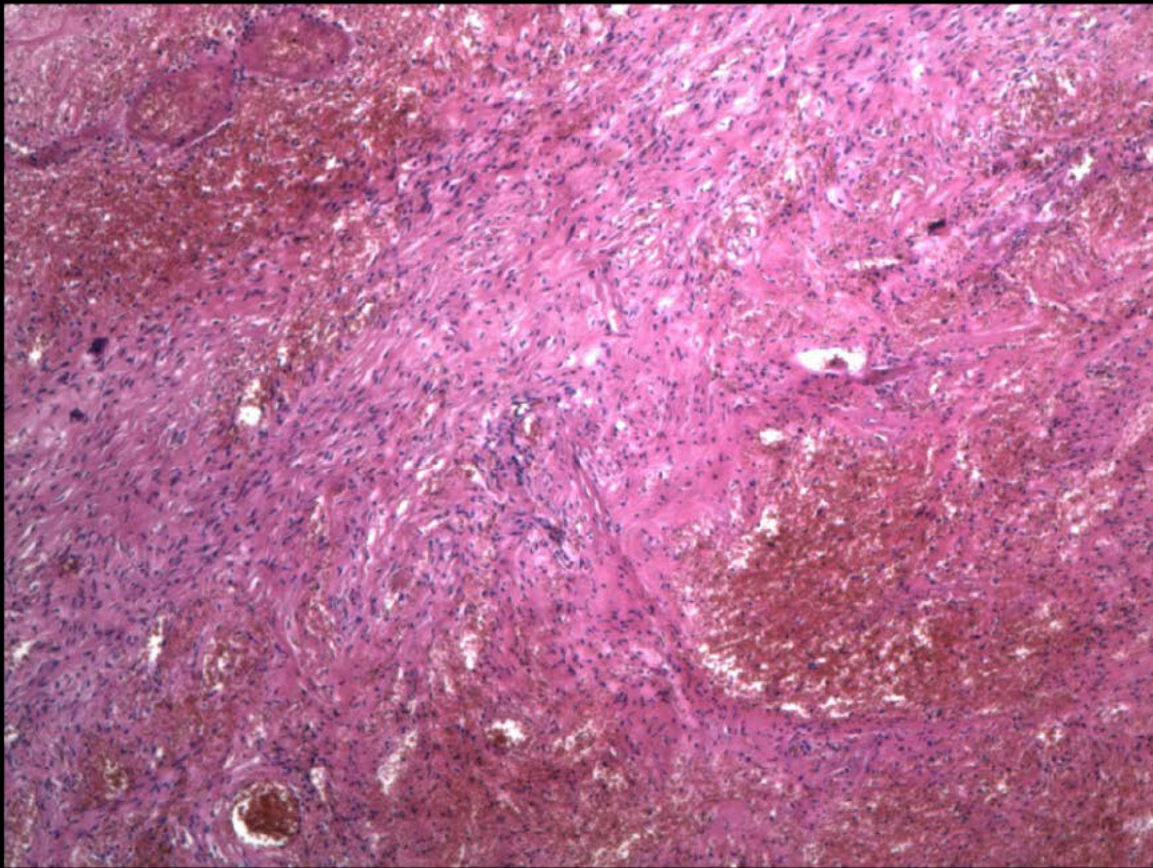


**AIR**

AMERICAN INSTITUTE FOR  
RADIOLOGIC PATHOLOGY

A PROGRAM OF THE  
AMERICAN COLLEGE OF RADIOLOGY



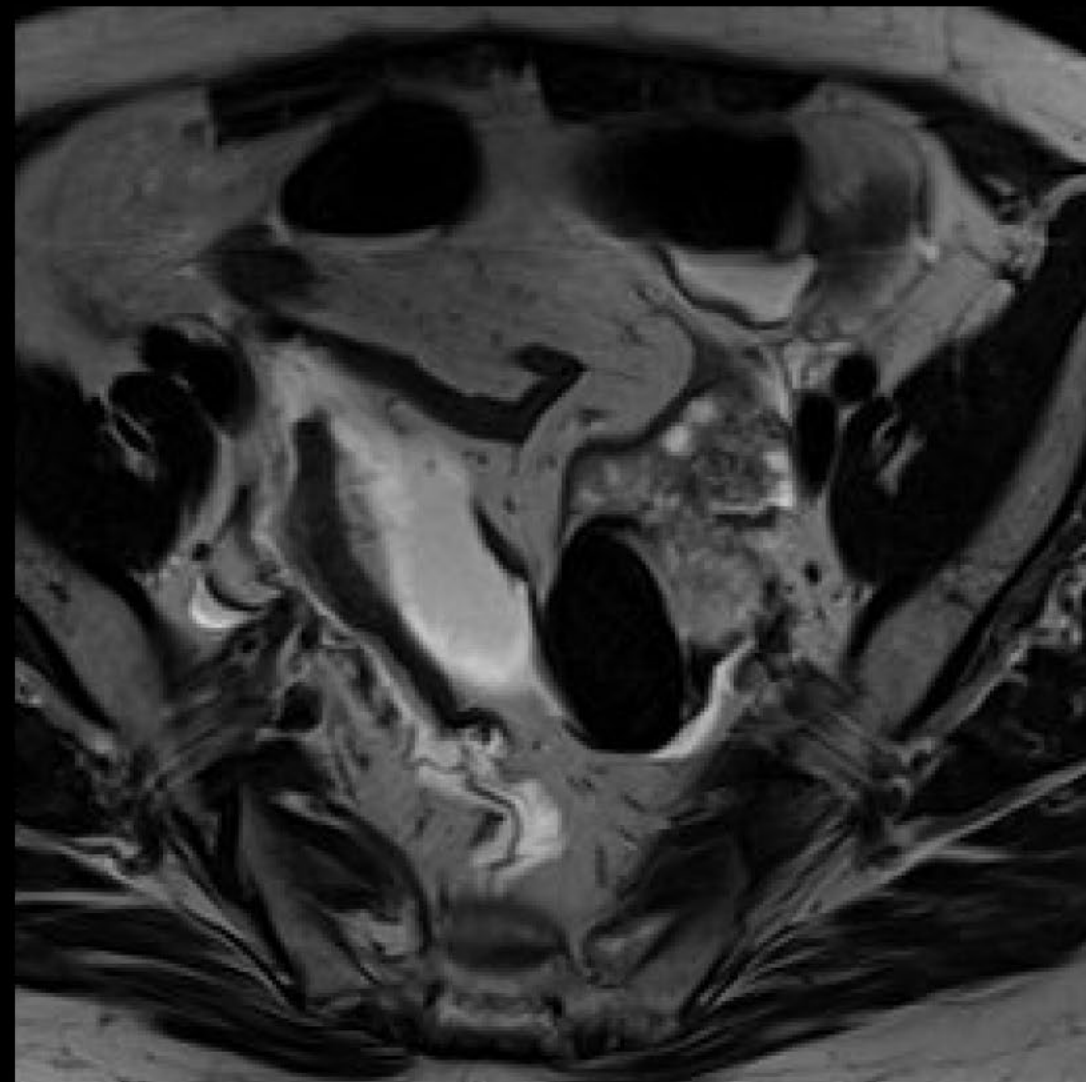
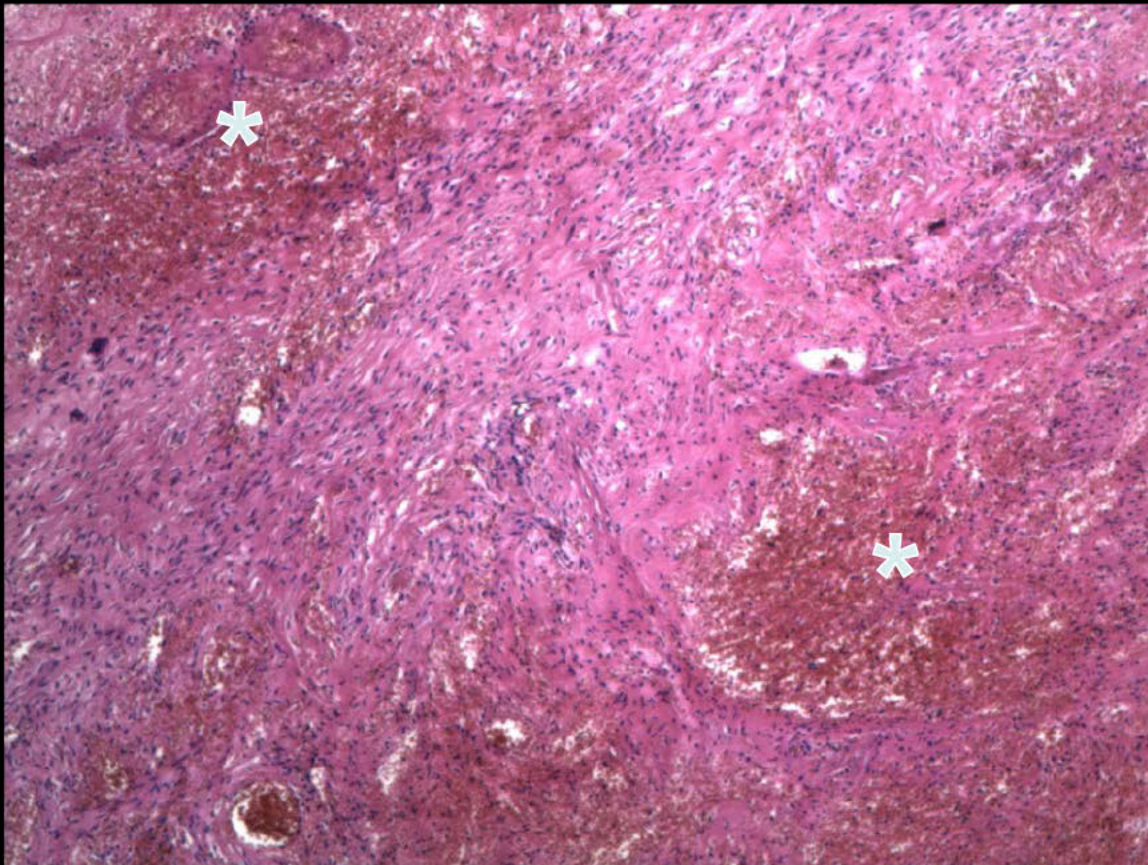


**AIRP**<sup>TM</sup>

AMERICAN INSTITUTE FOR  
RADIOLOGIC PATHOLOGY

A PROGRAM OF THE  
AMERICAN COLLEGE OF RADIOLOGY



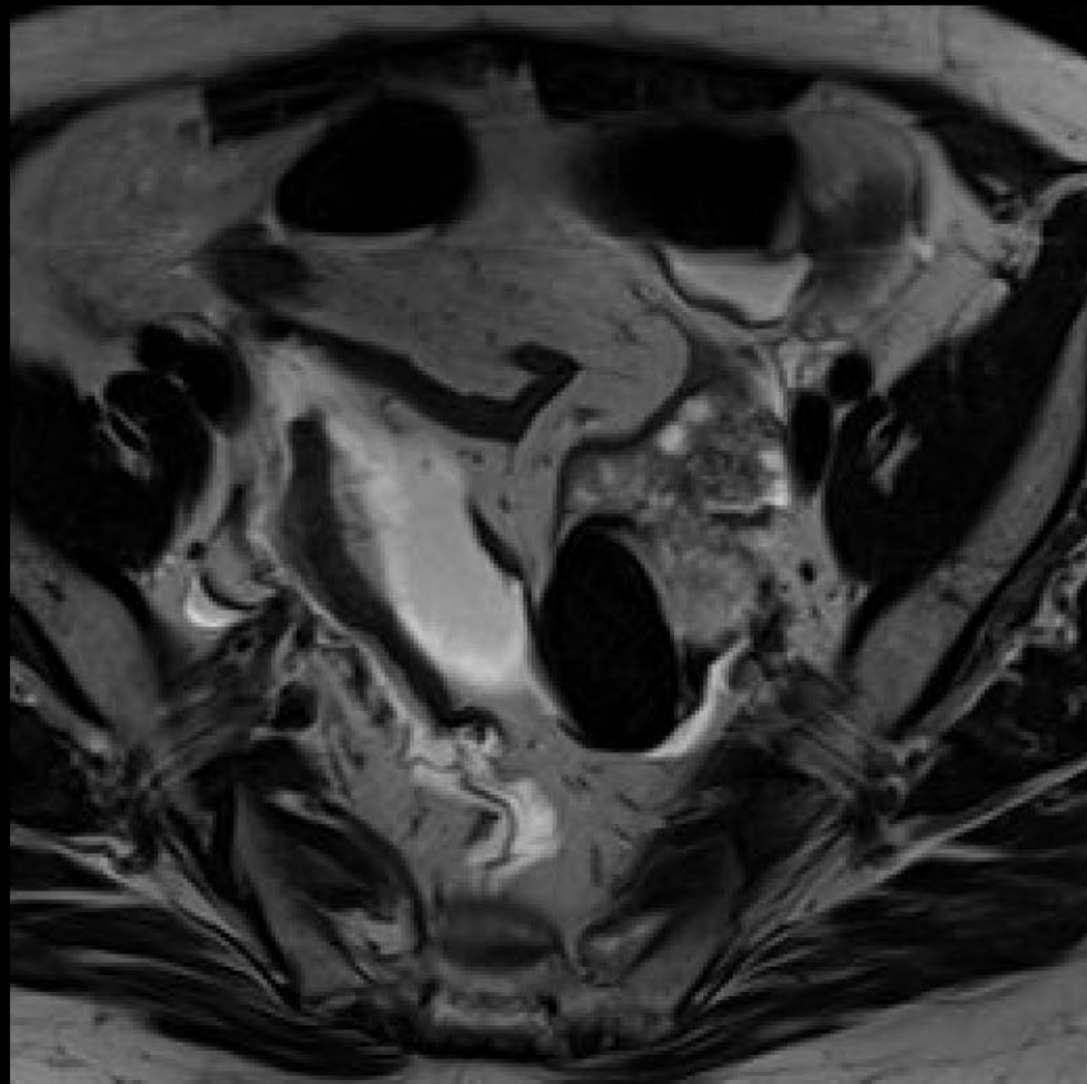
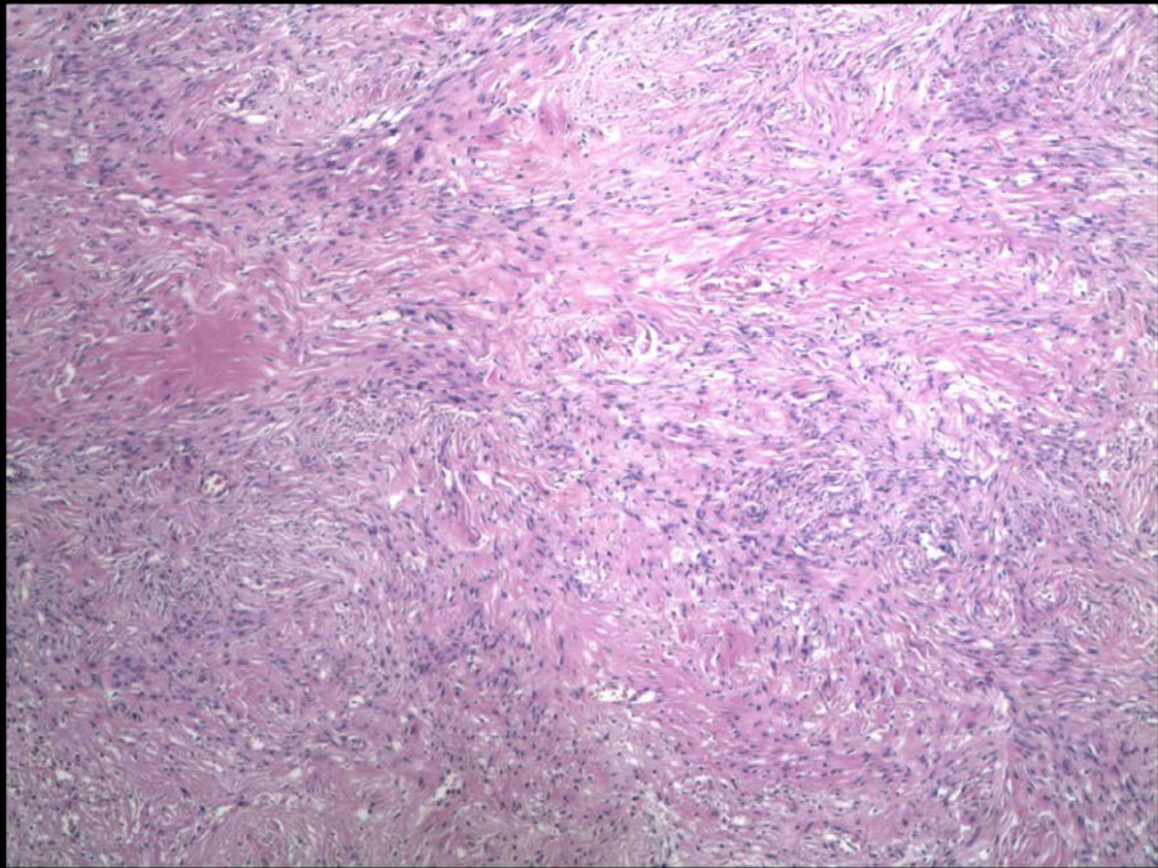


**AIRP**<sup>TM</sup>

AMERICAN INSTITUTE FOR  
RADIOLOGIC PATHOLOGY

A PROGRAM OF THE  
AMERICAN COLLEGE OF RADIOLOGY





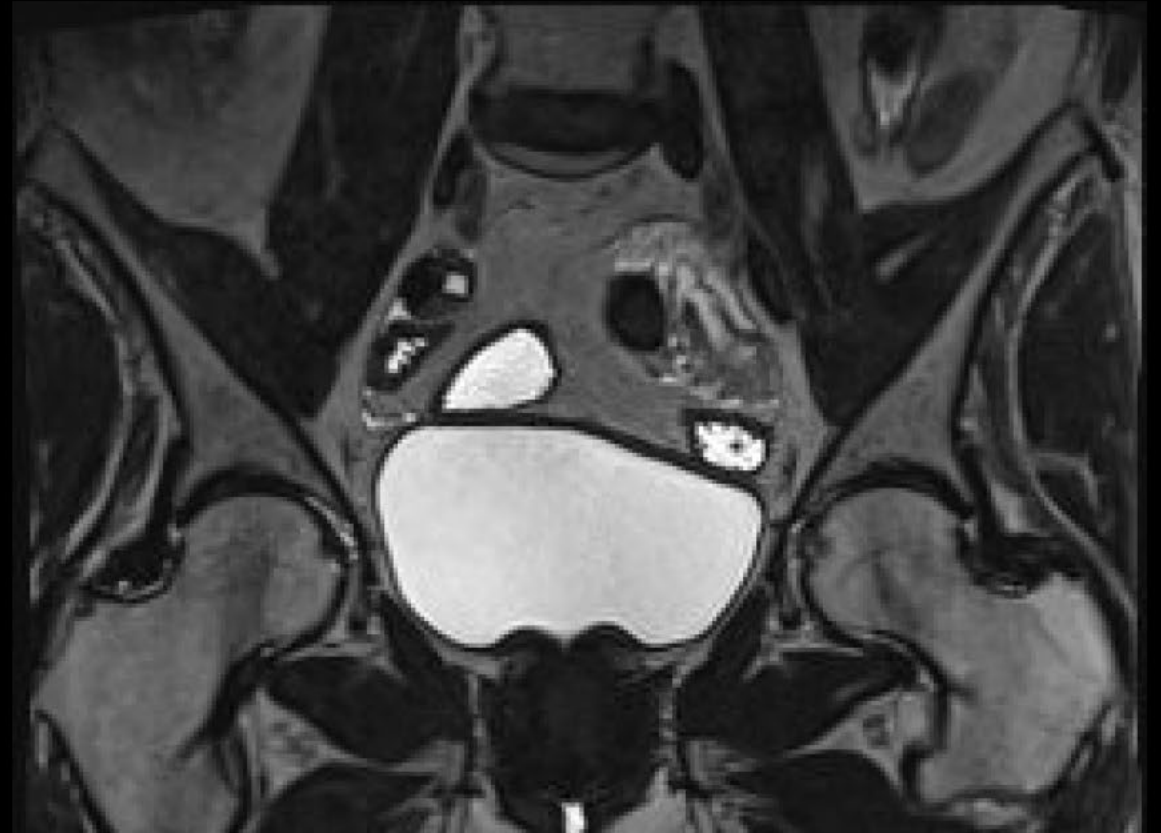
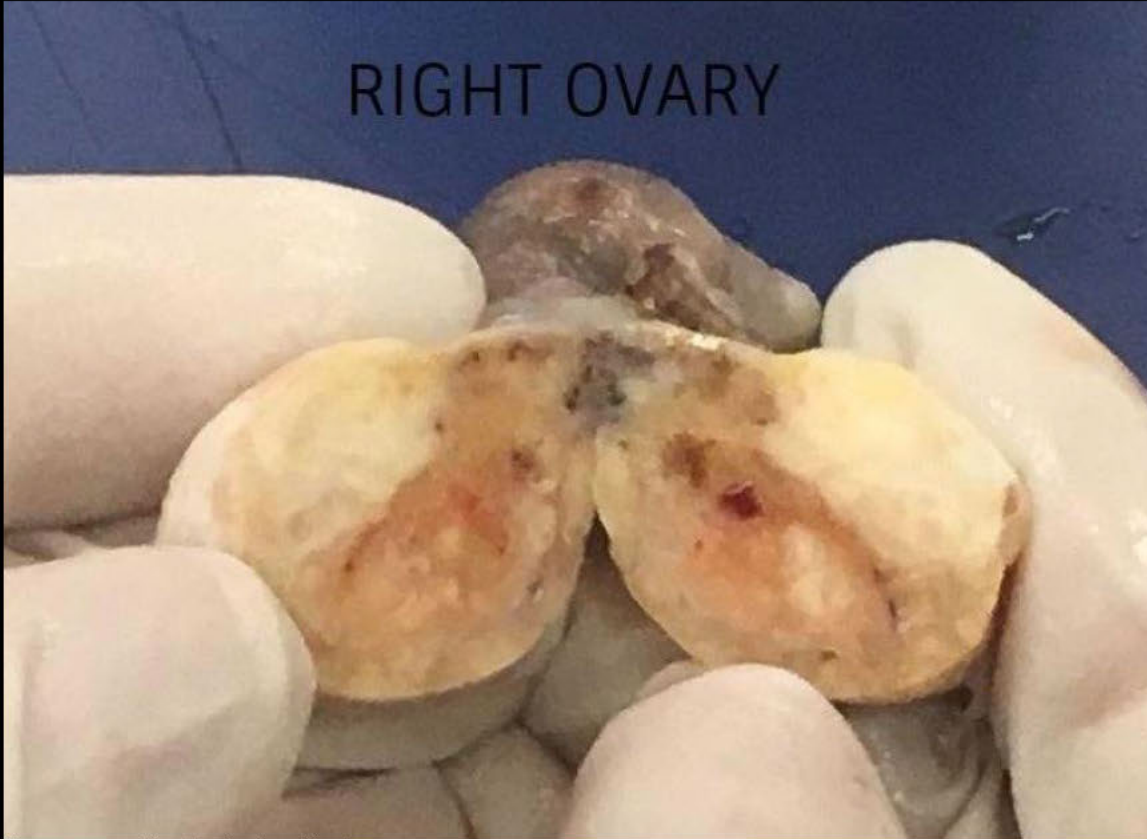**AIRP**<sup>TM</sup>

AMERICAN INSTITUTE FOR  
RADIOLOGIC PATHOLOGY

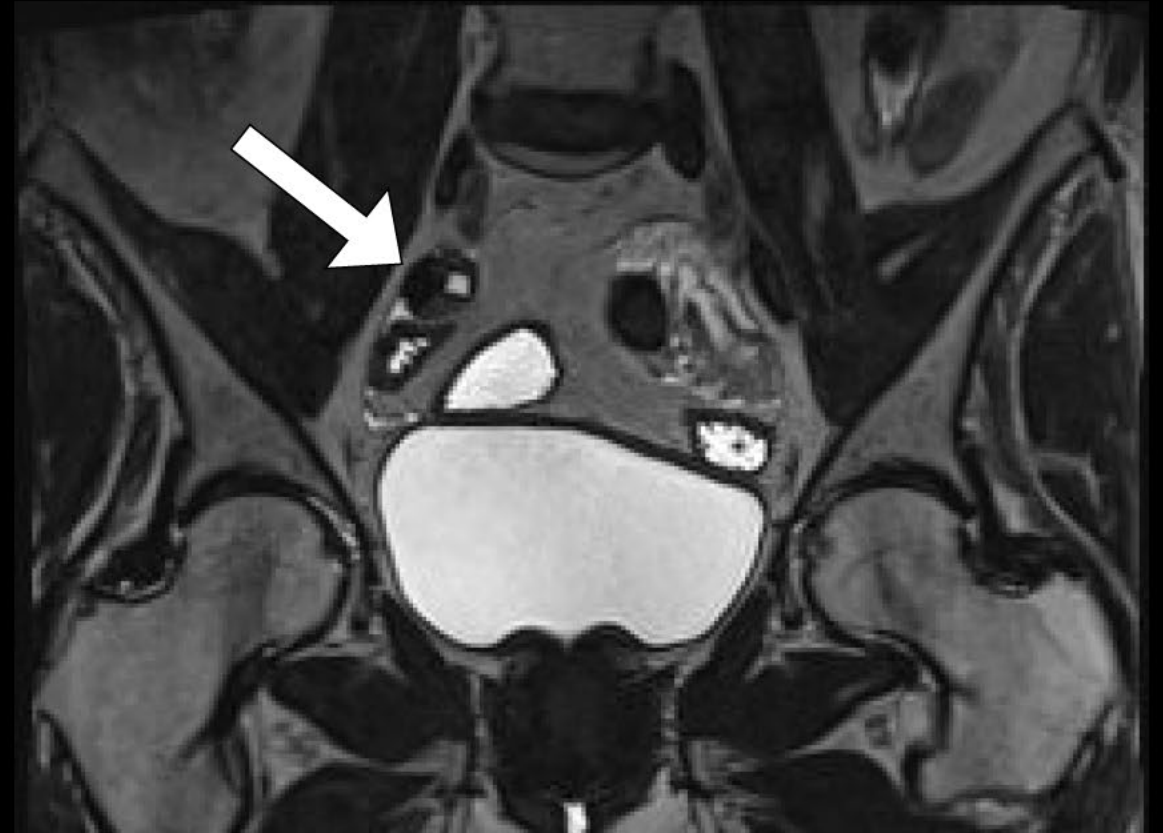
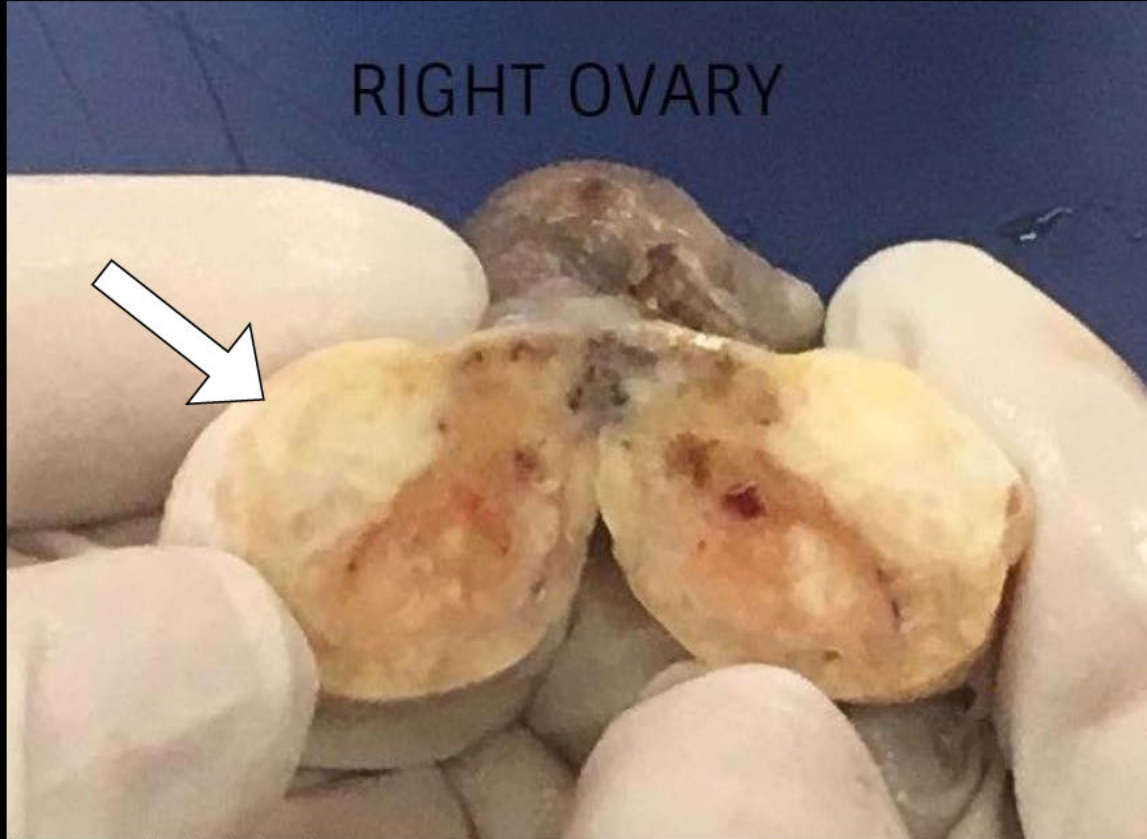
A PROGRAM OF THE  
AMERICAN COLLEGE OF RADIOLOGY



RIGHT OVARY



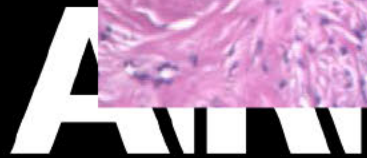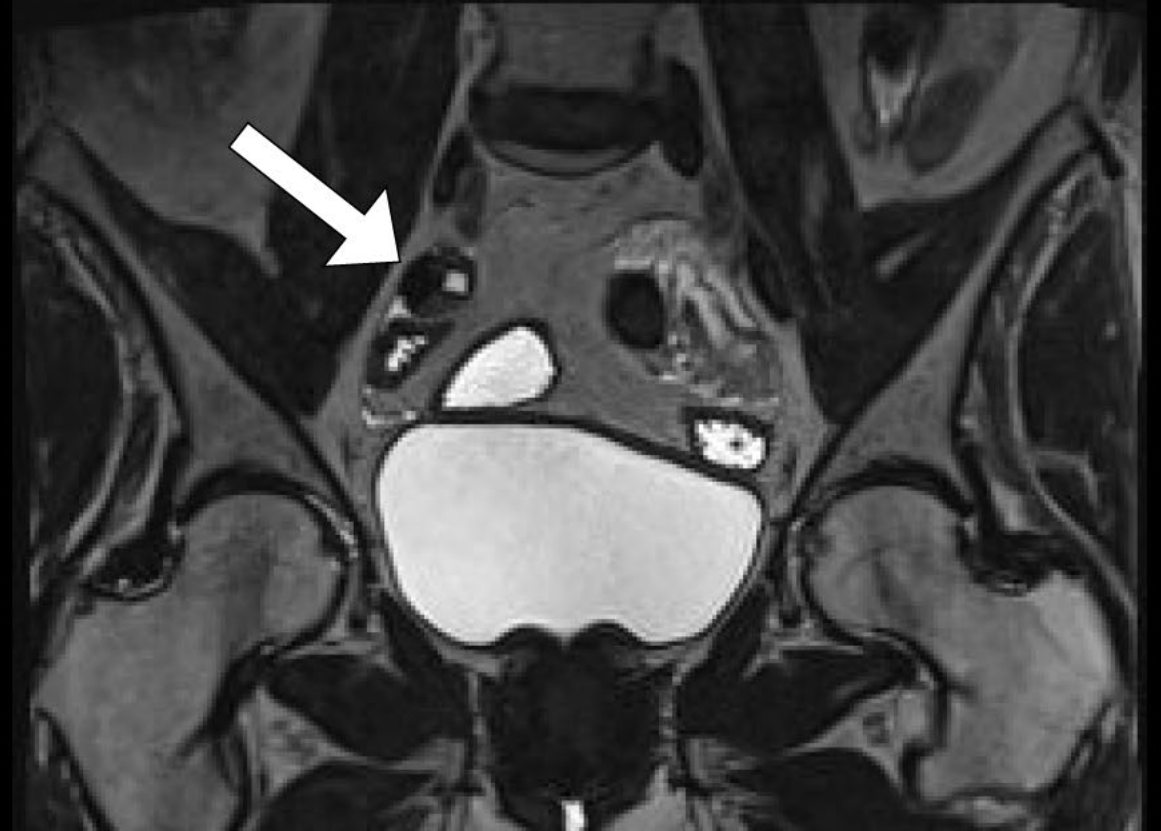
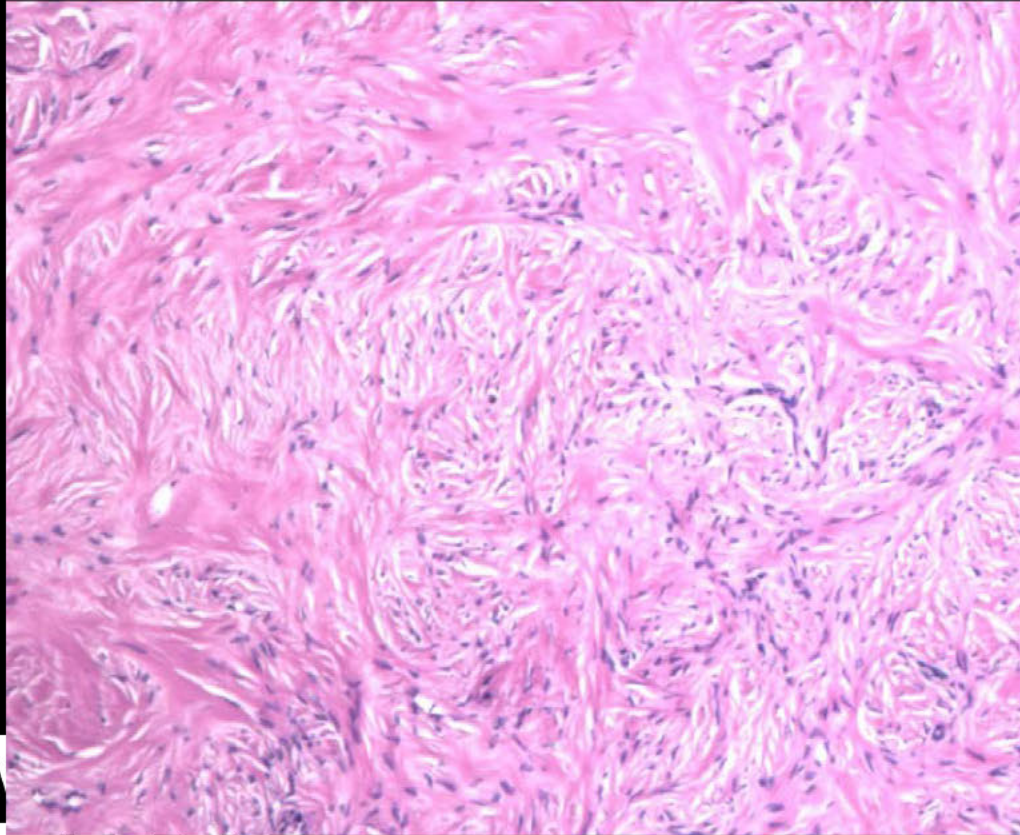
RIGHT OVARY



**AMERICAN INSTITUTE FOR  
RADIOLOGIC PATHOLOGY**

A PROGRAM OF THE  
AMERICAN COLLEGE OF RADIOLOGY

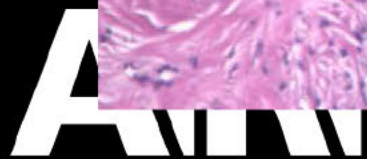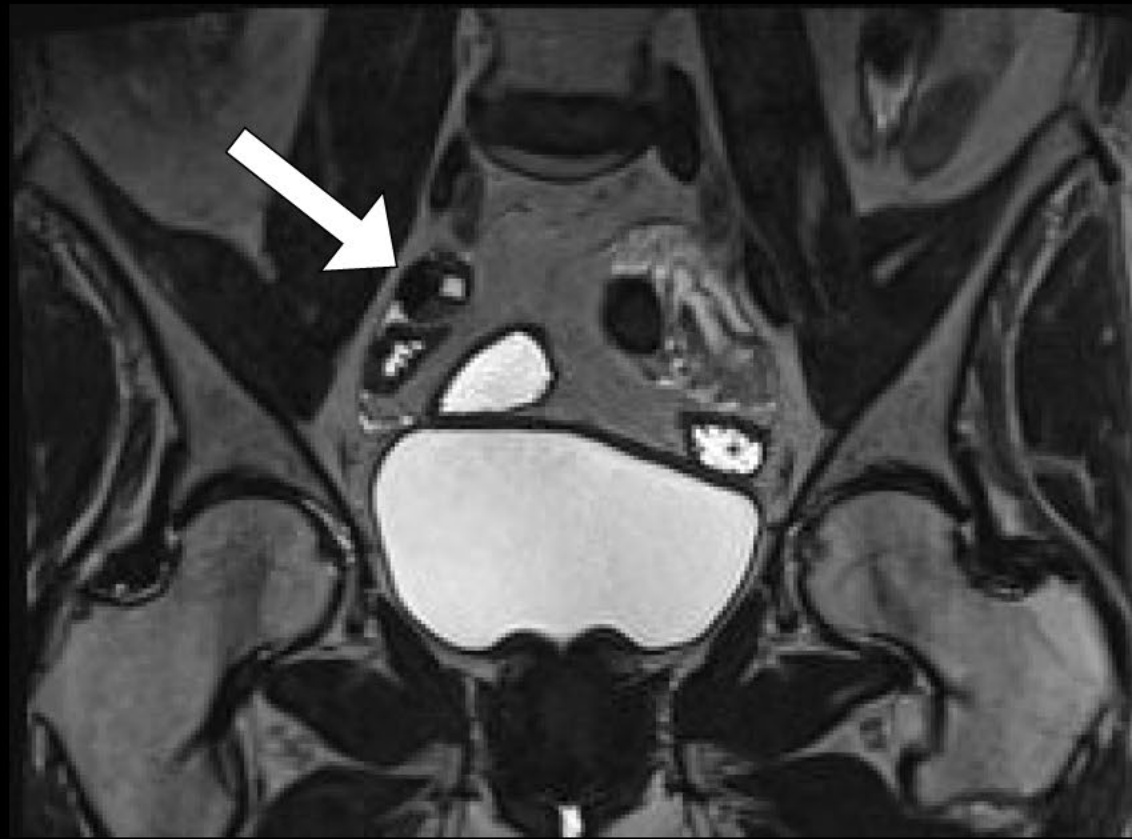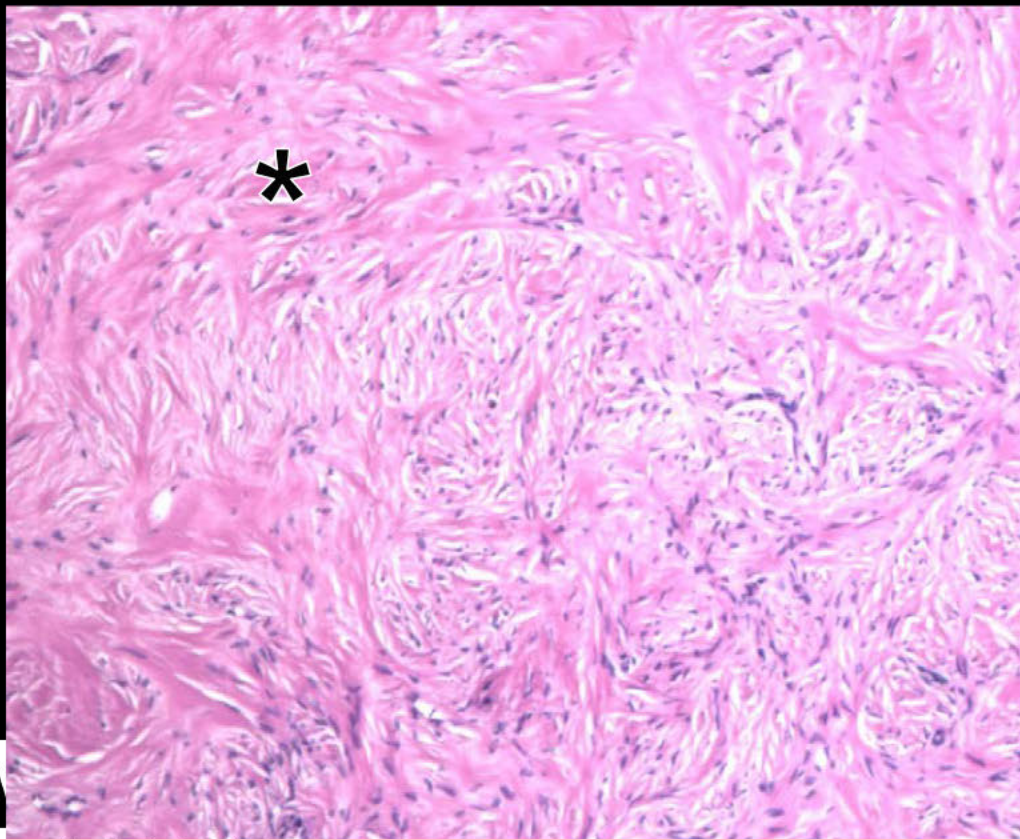




AMERICAN INSTITUTE FOR  
RADIOLOGIC PATHOLOGY

A PROGRAM OF THE  
AMERICAN COLLEGE OF RADIOLOGY





AMERICAN INSTITUTE FOR  
RADIOLOGIC PATHOLOGY

A PROGRAM OF THE  
AMERICAN COLLEGE OF RADIOLOGY

**Left ovarian torsion secondary to left  
ovarian fibroma**

**Right ovarian fibroma**

**Victor de Carvalha, MD**

**Radiologia e Diagnóstico por Imagem da Real e**

**Benemérita Associação Portuguesa de**

**Beneficência - Hospital São Joaquim**

**São Paulo, Brazil**

**AIRP**

**AMERICAN INSTITUTE FOR  
RADIOLOGIC PATHOLOGY**

**A PROGRAM OF THE  
AMERICAN COLLEGE OF RADIOLOGY**