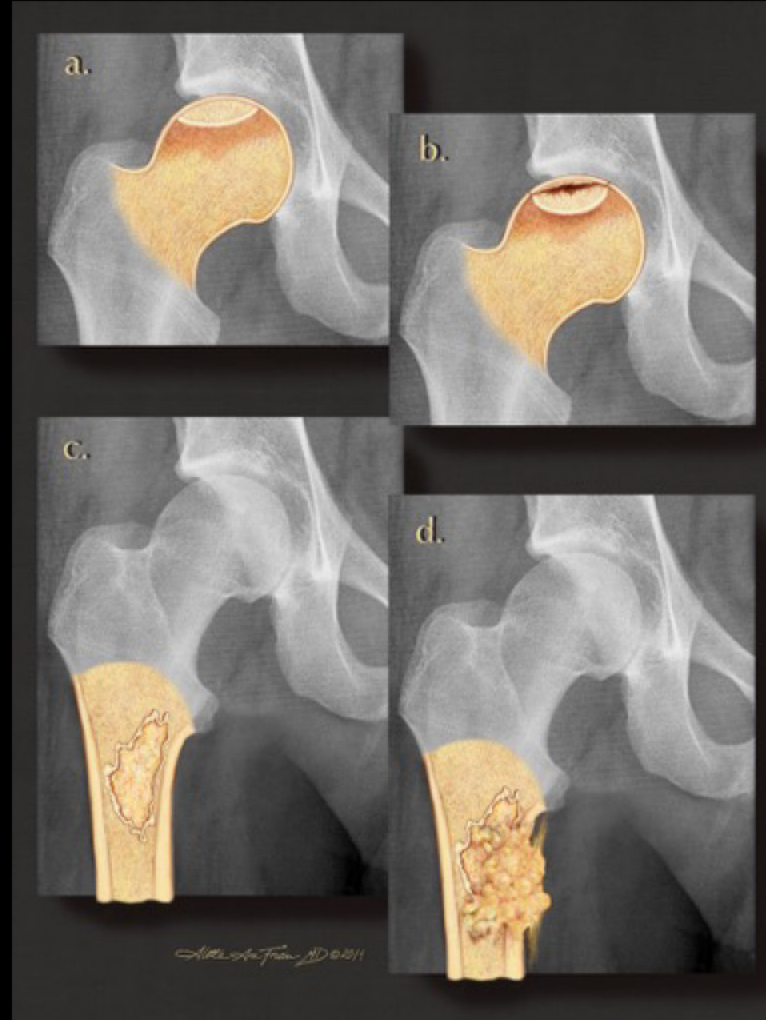


Best Cases of the AIRP

July-August, 2021

Musculoskeletal Best Case

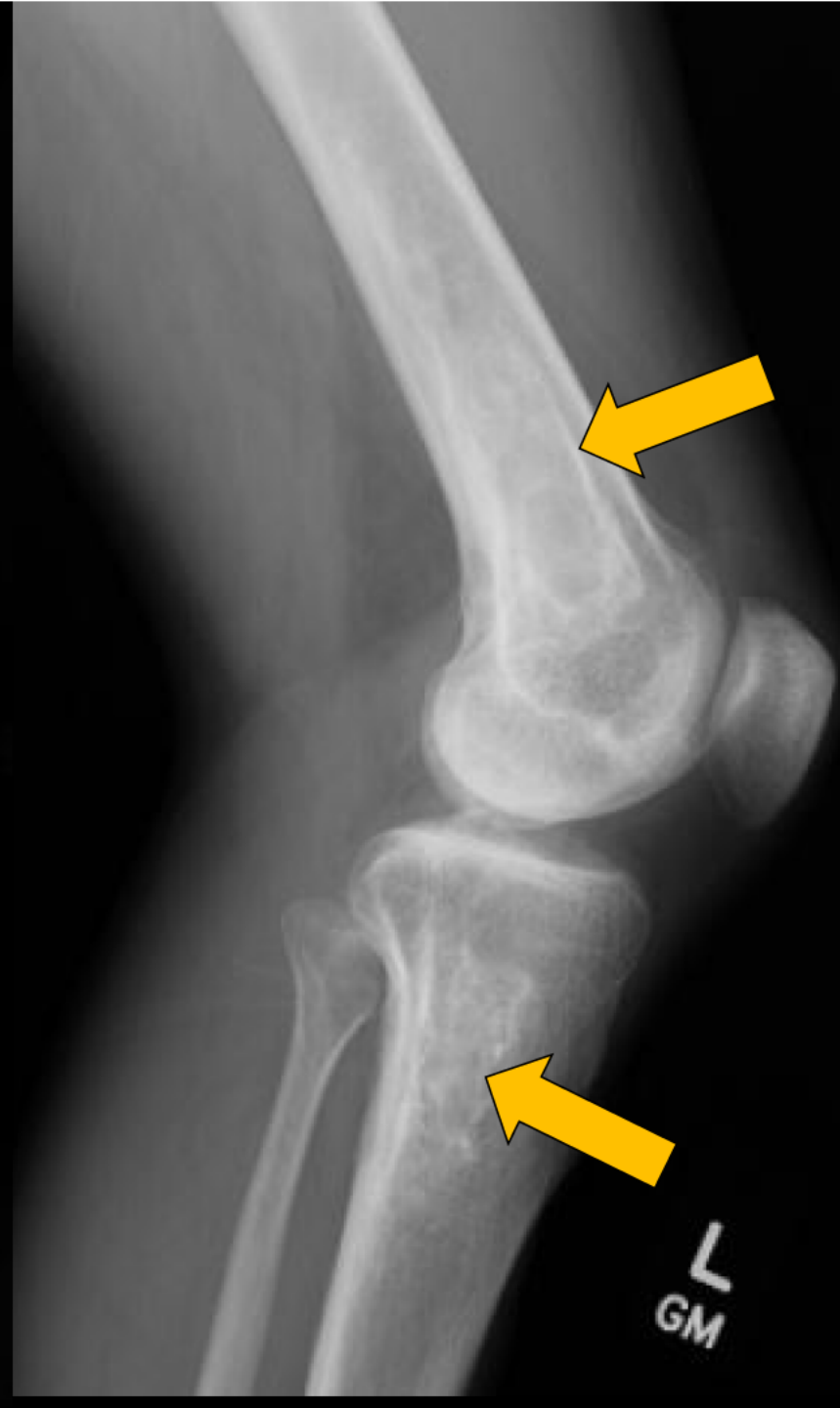
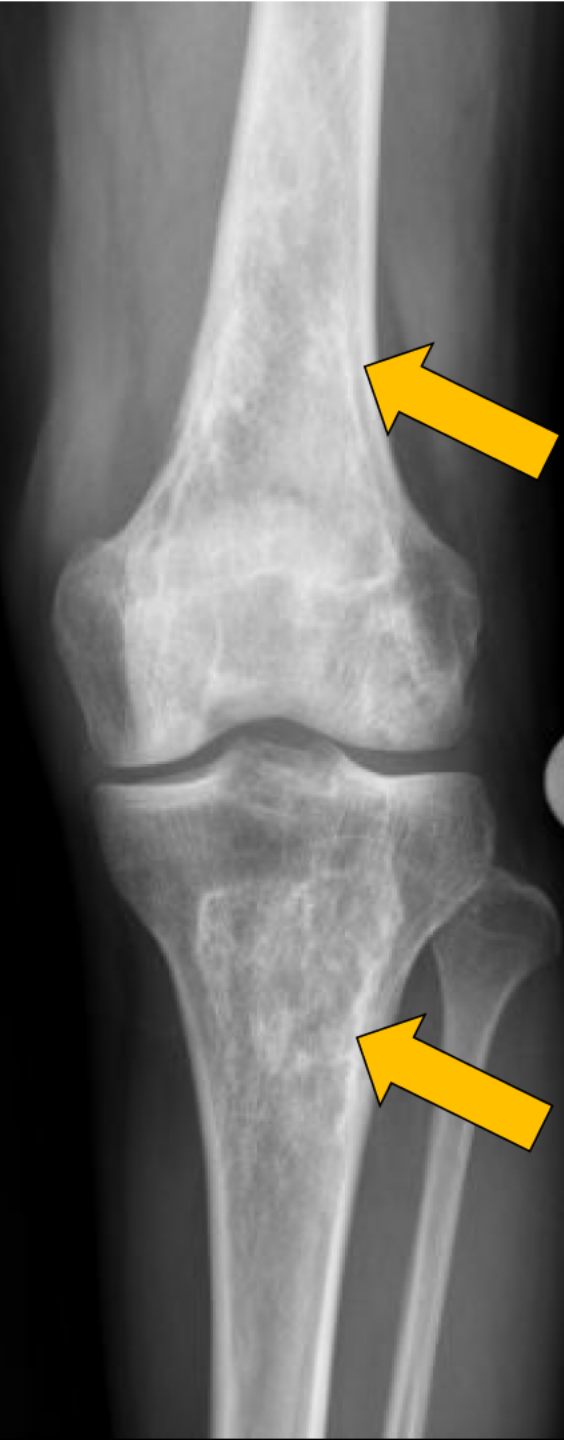
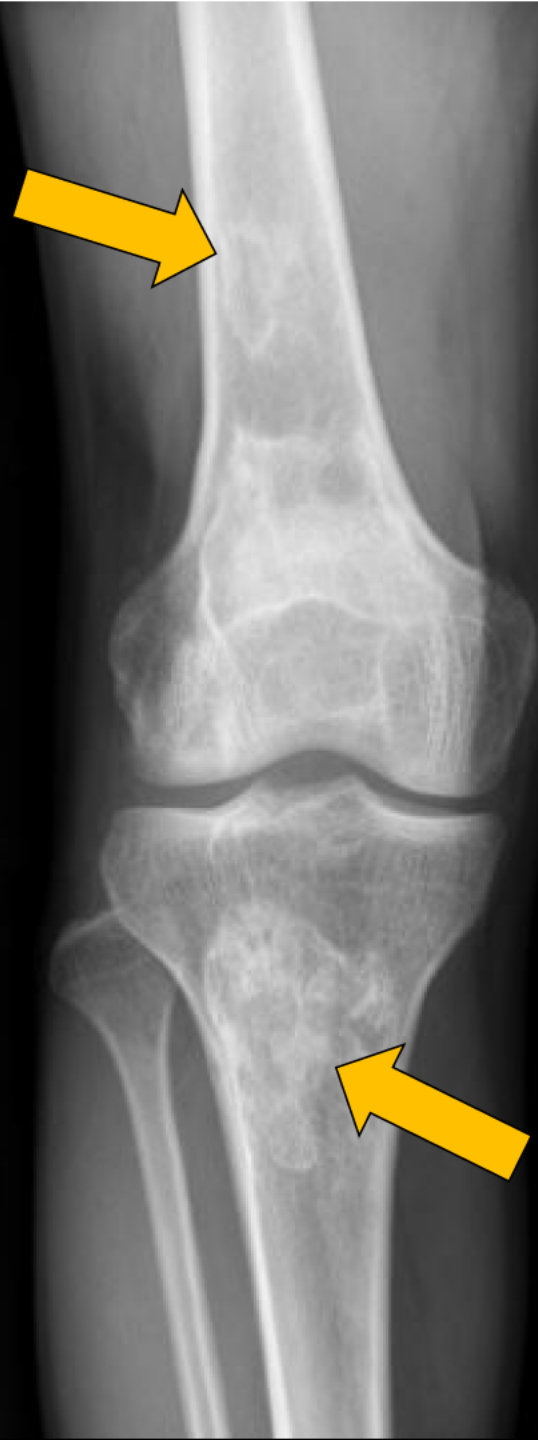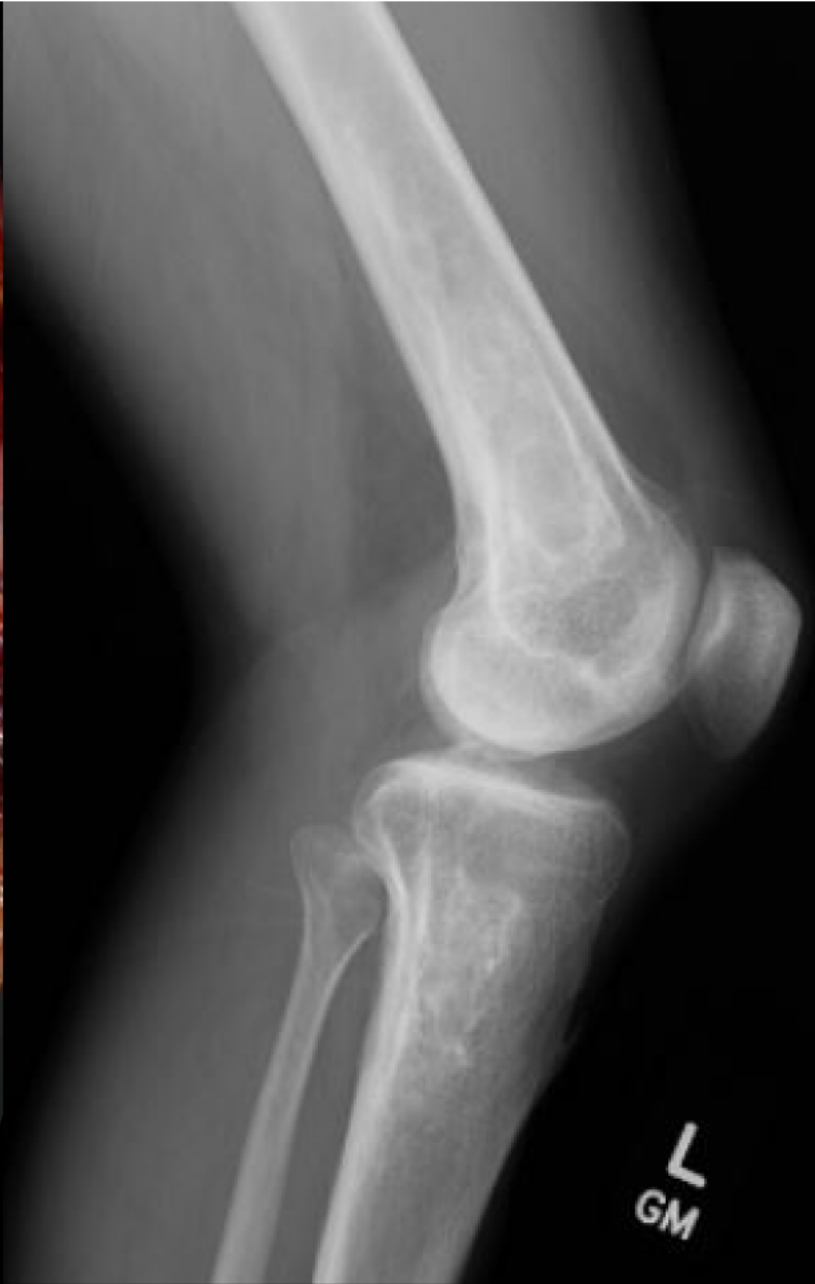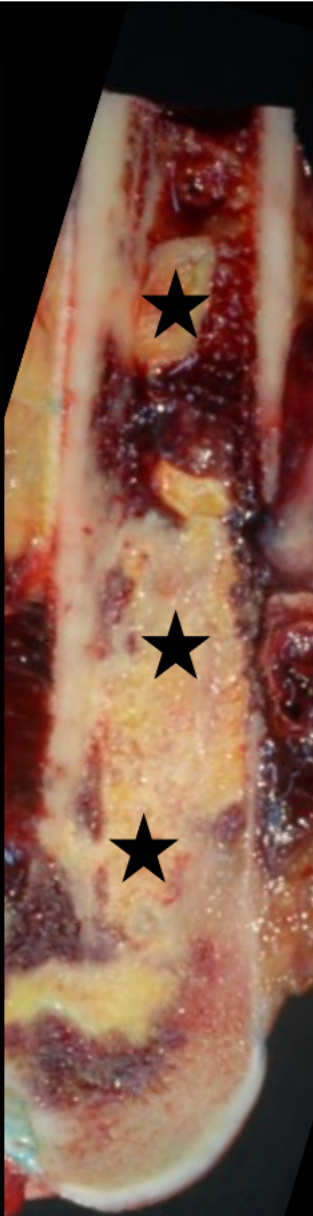
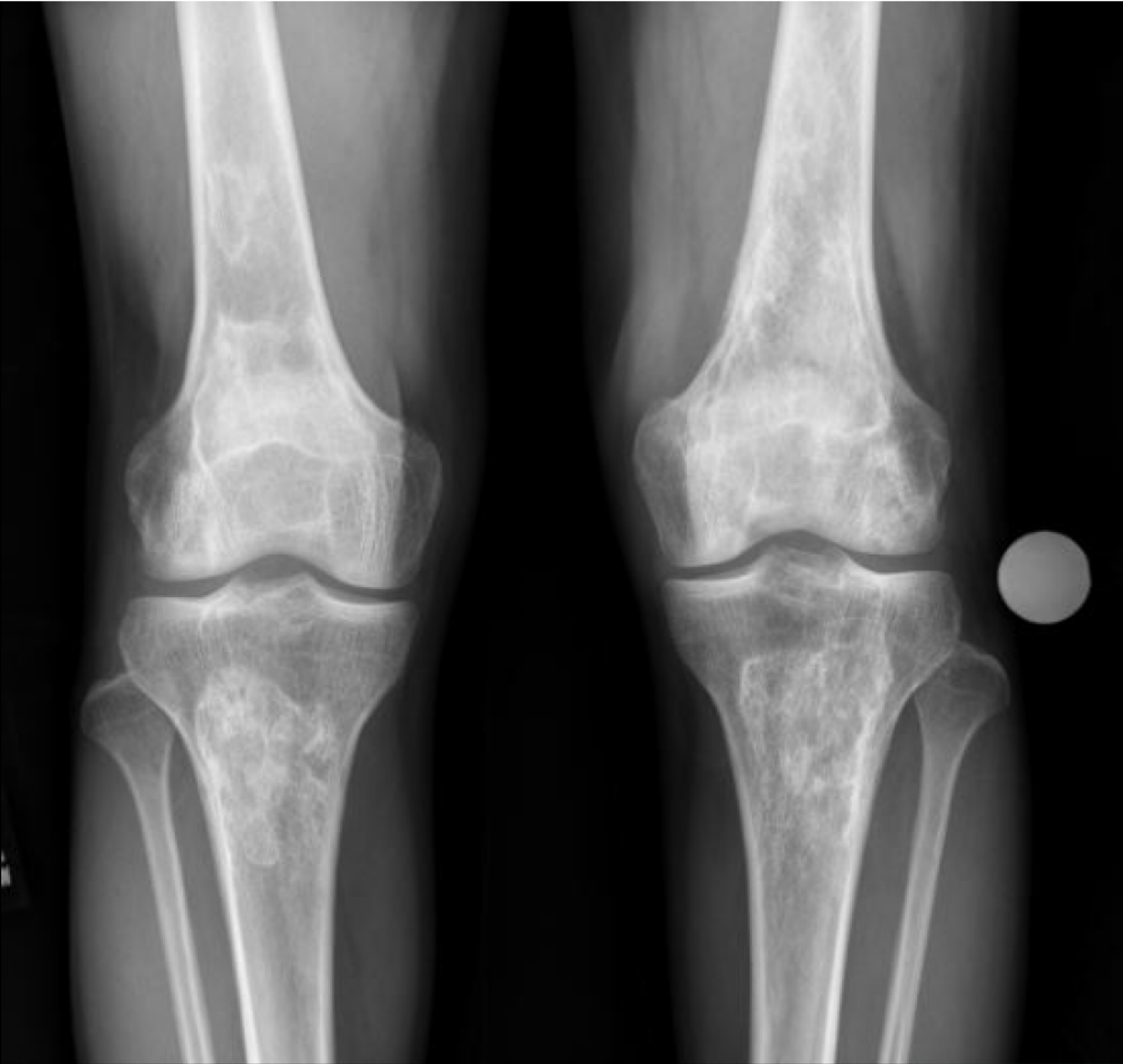
CLINICAL INFORMATION

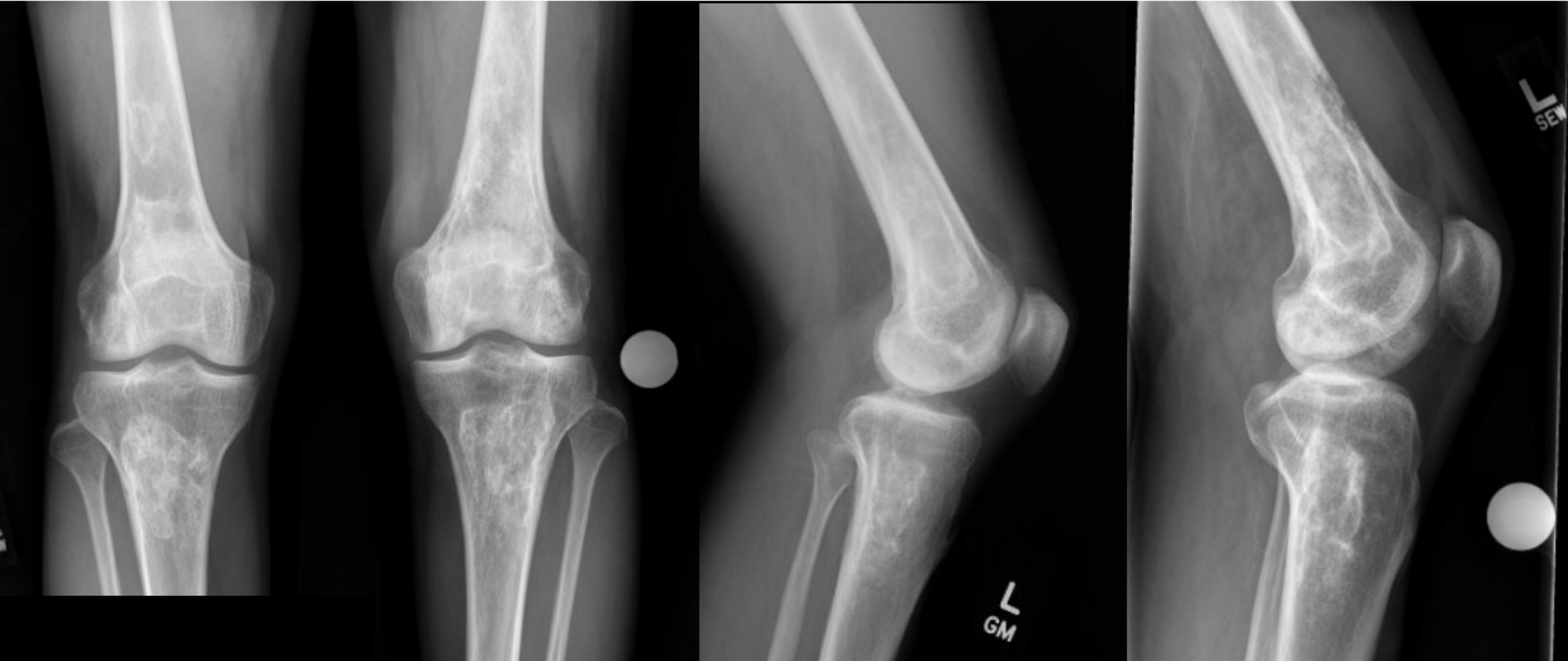
**46-year-old male with history of ALL in 2000,
status post chemoradiation therapy and bone
marrow transplant in 2005 with 3 months of
constant aching distal left thigh pain**



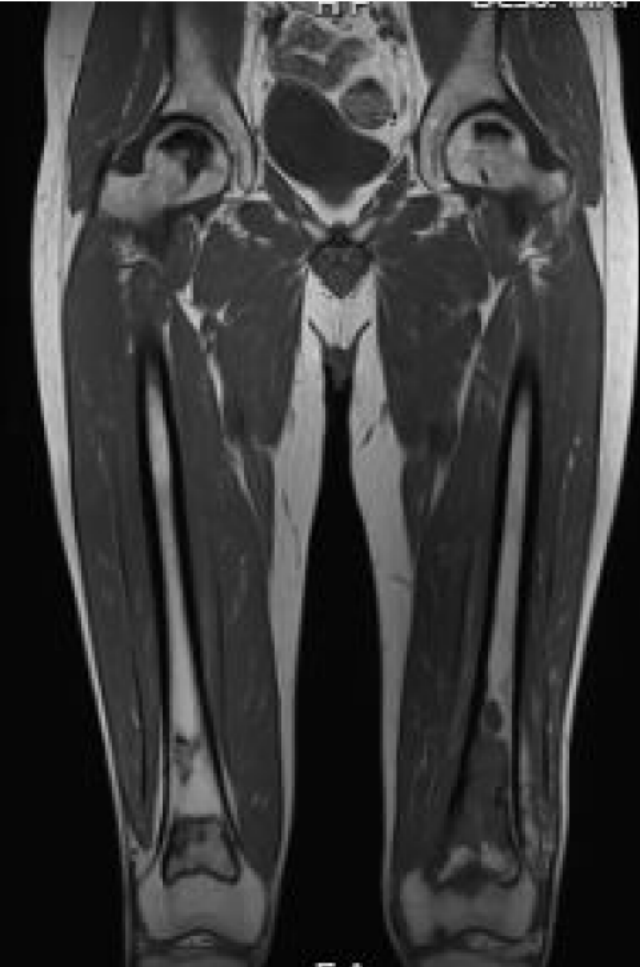
ACR INSTITUTE FOR
RADIOLOGIC PATHOLOGY





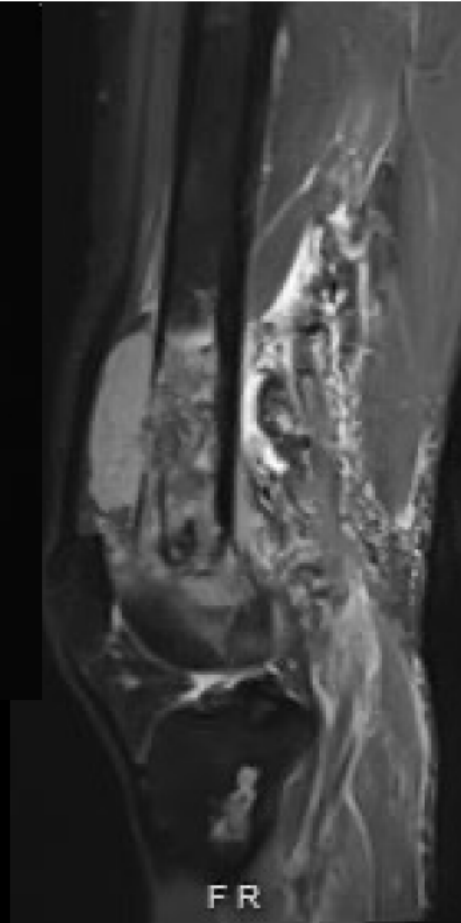
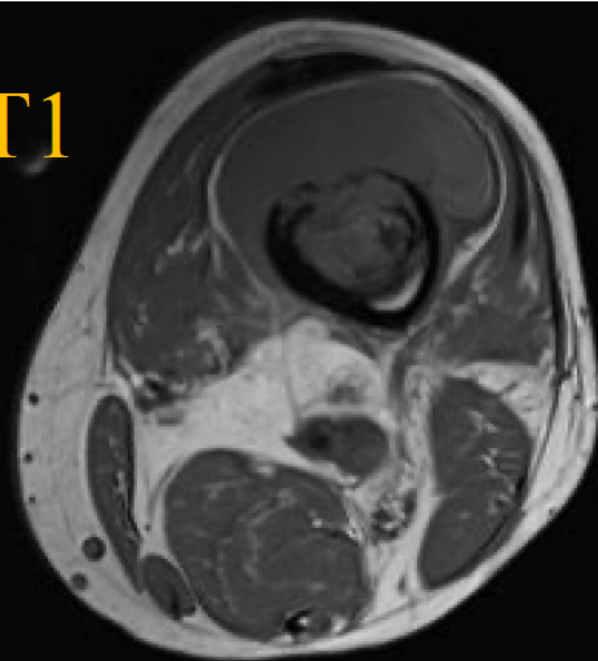


5 months later

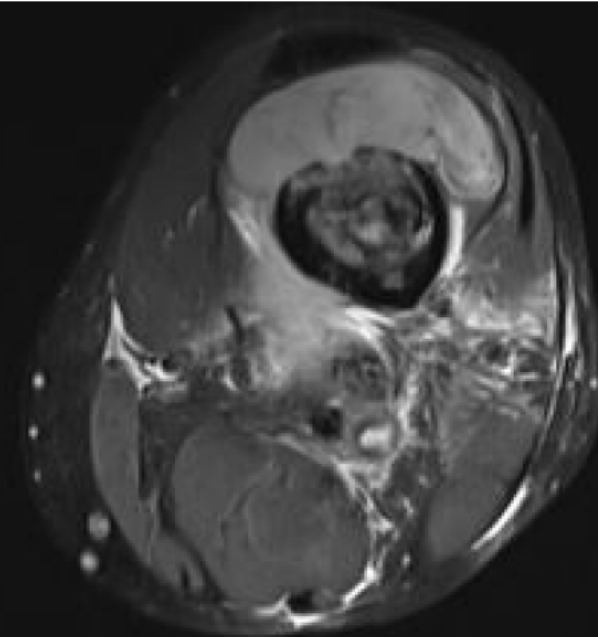


T1

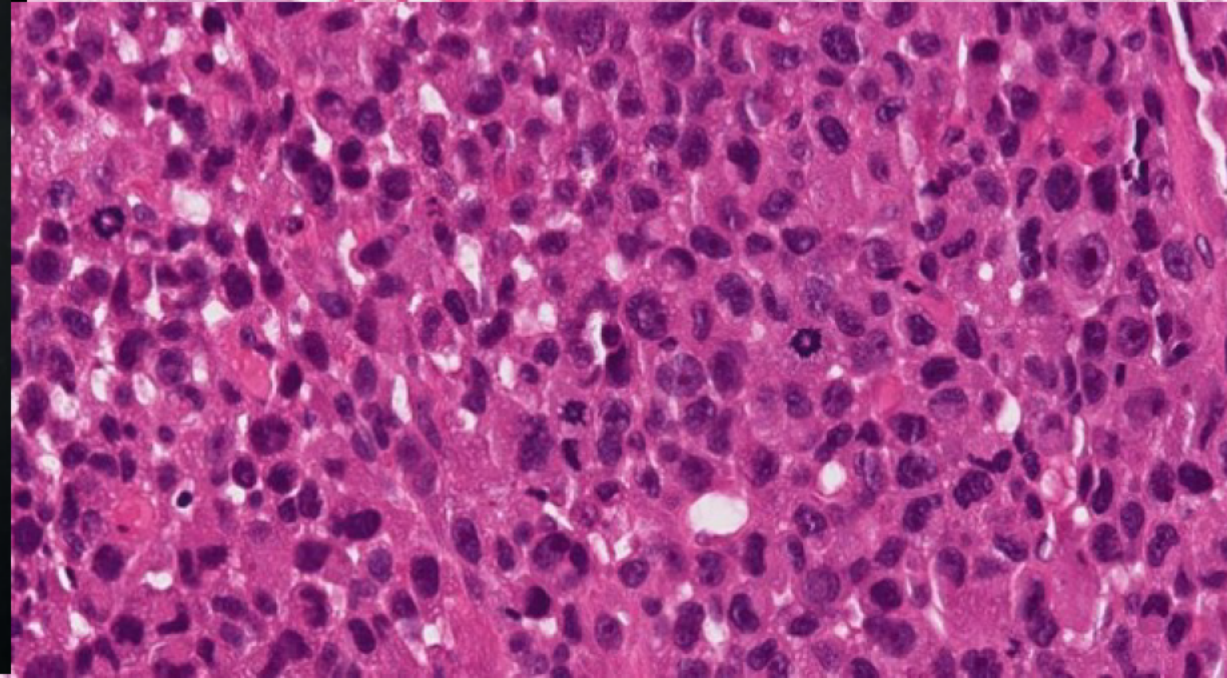
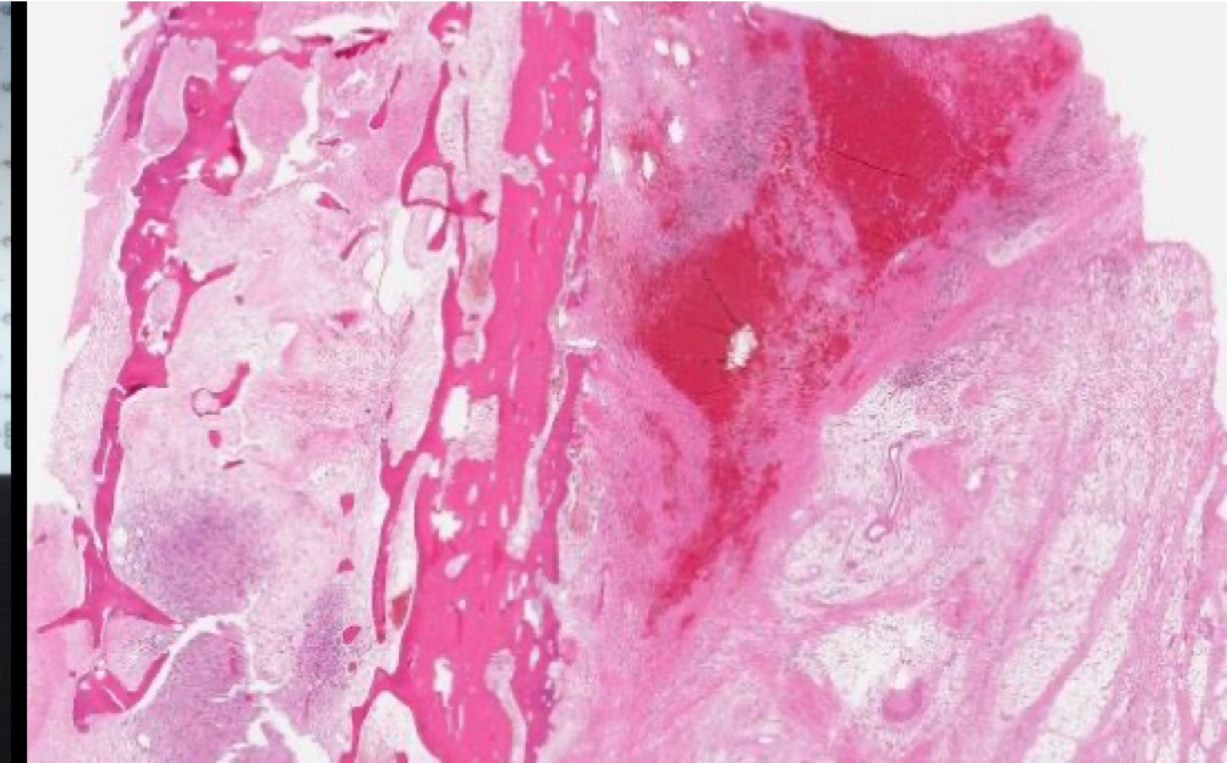
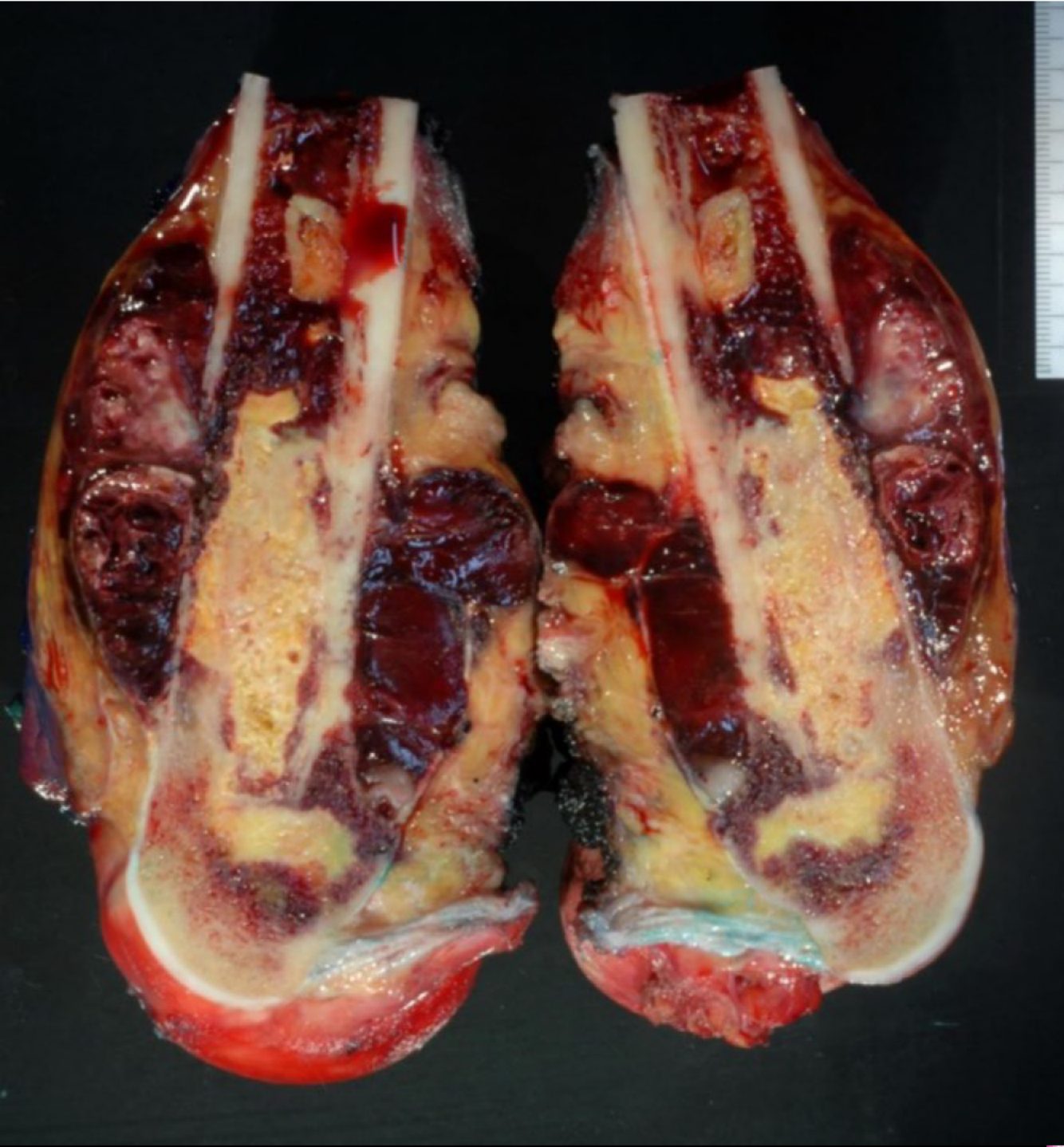
T1

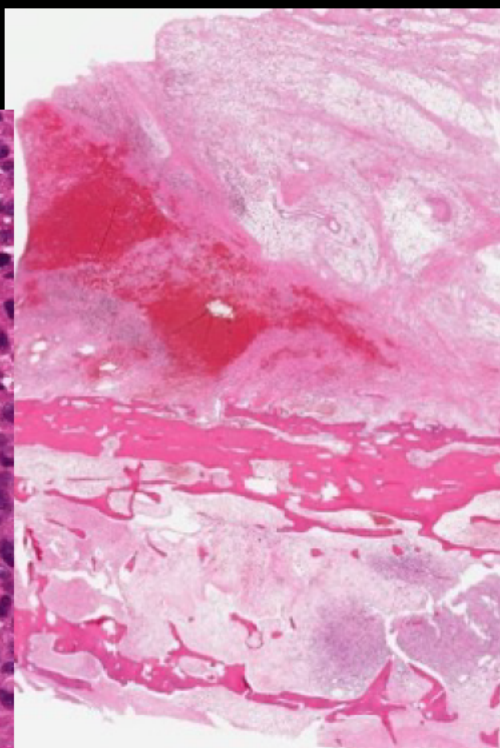
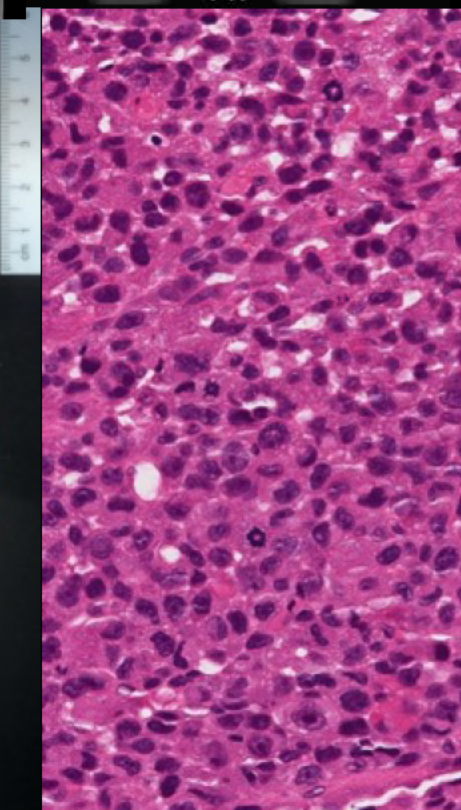
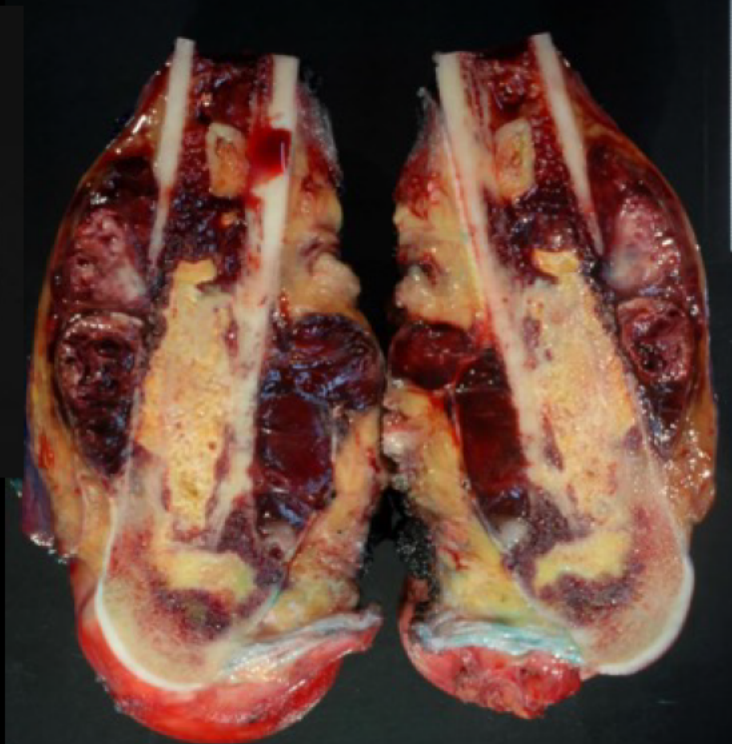
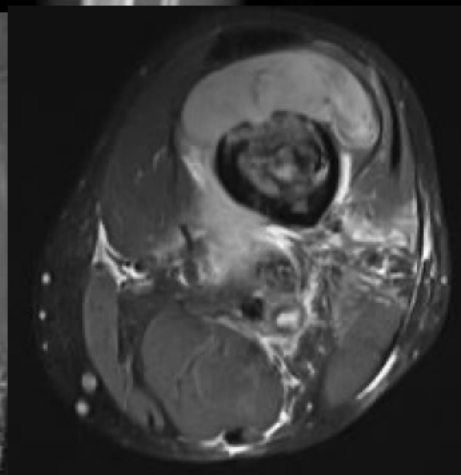
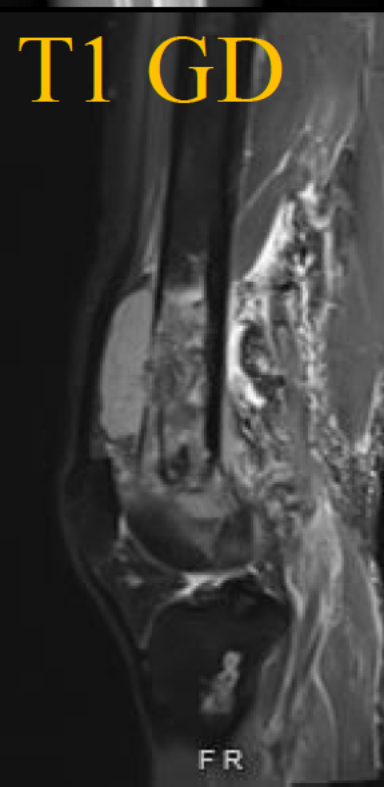
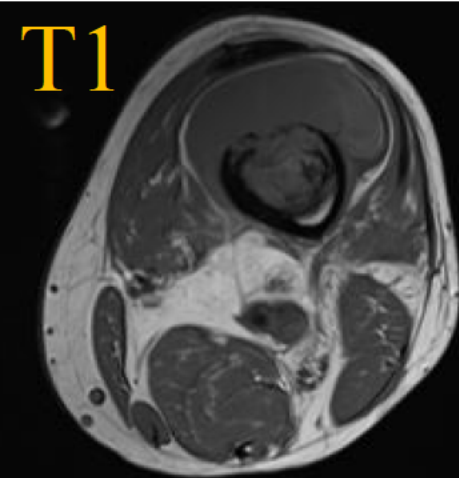
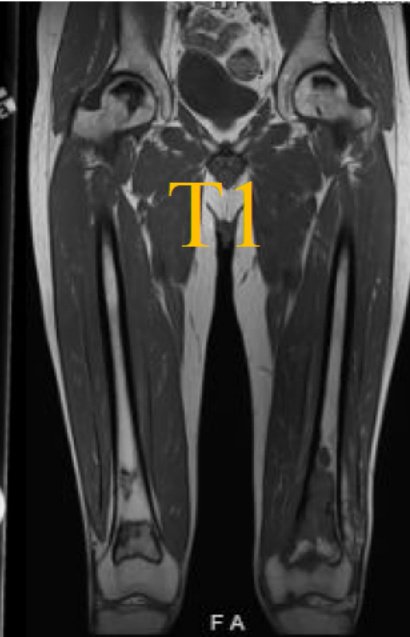
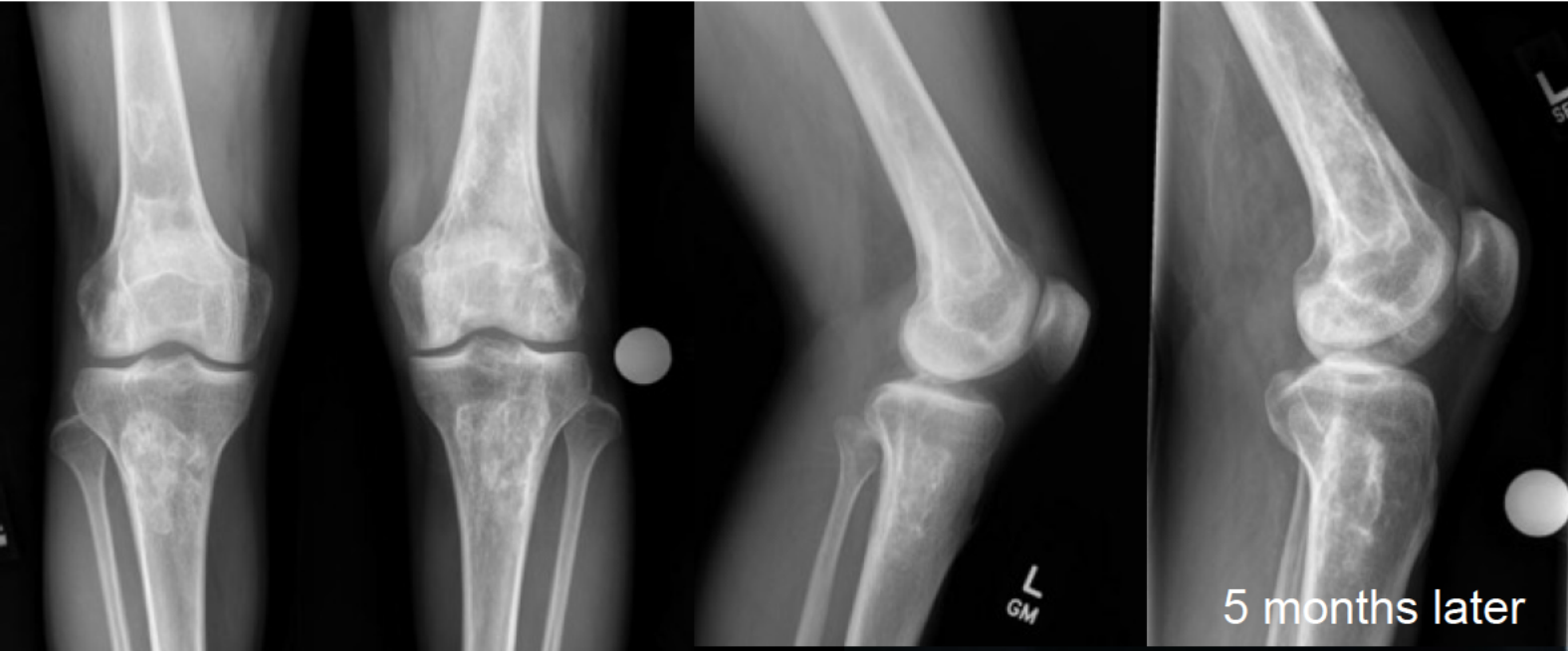

T1 GD



T2 FS

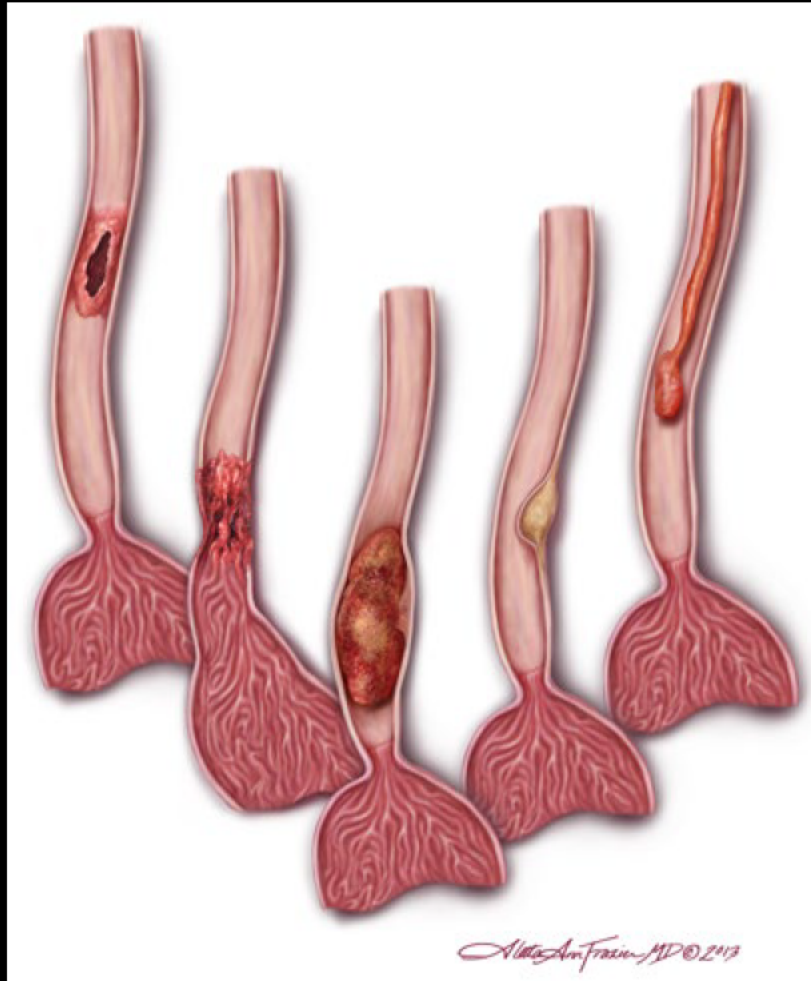



OSTEONECROSIS WITH MALIGNANT TRANSFORMATION TO UNDIFFERENTIATED PLEOMORPHIC SARCOMA (UPS)

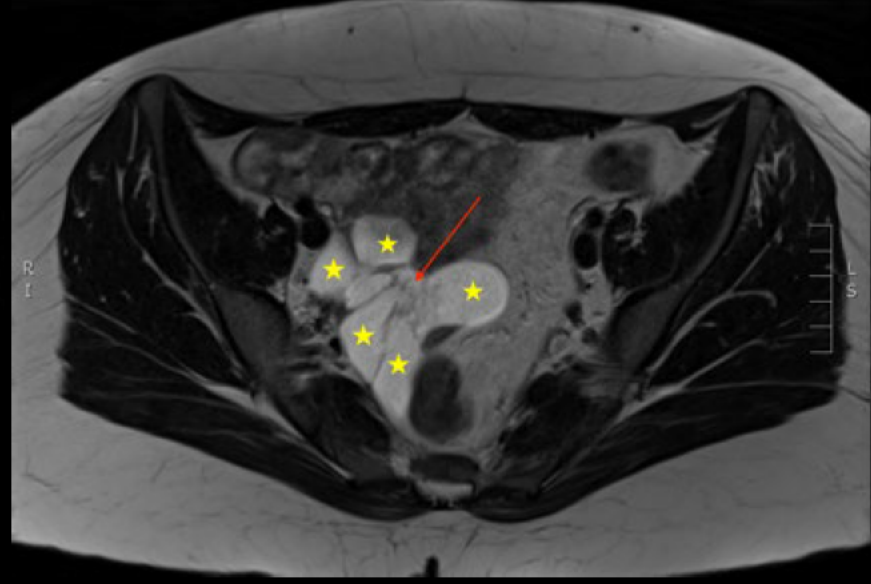
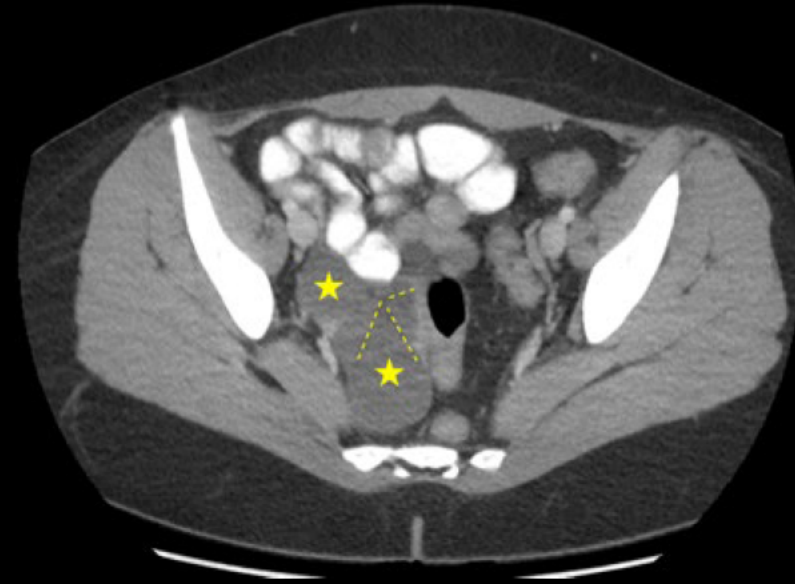
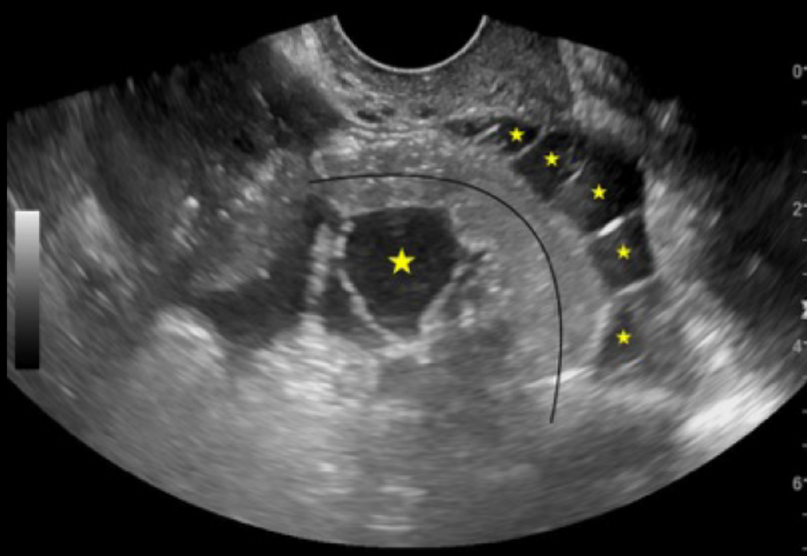
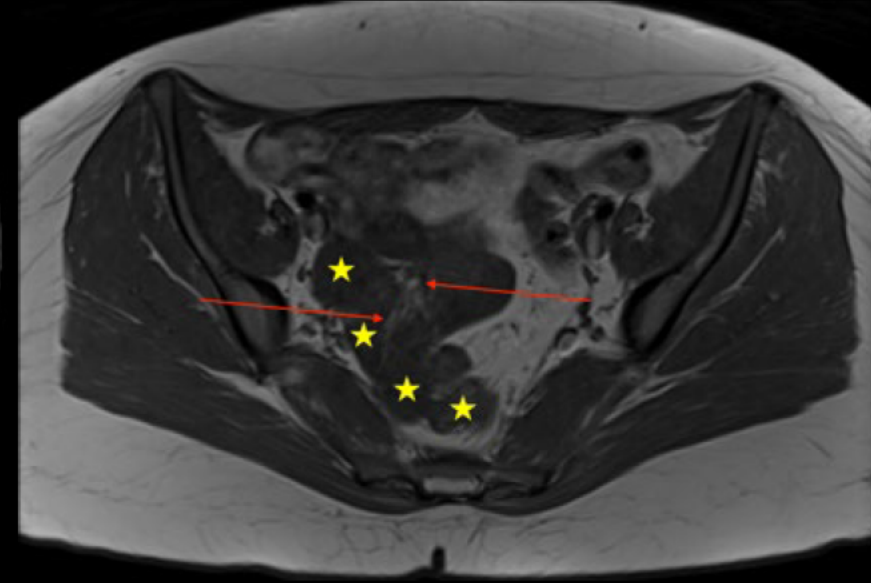
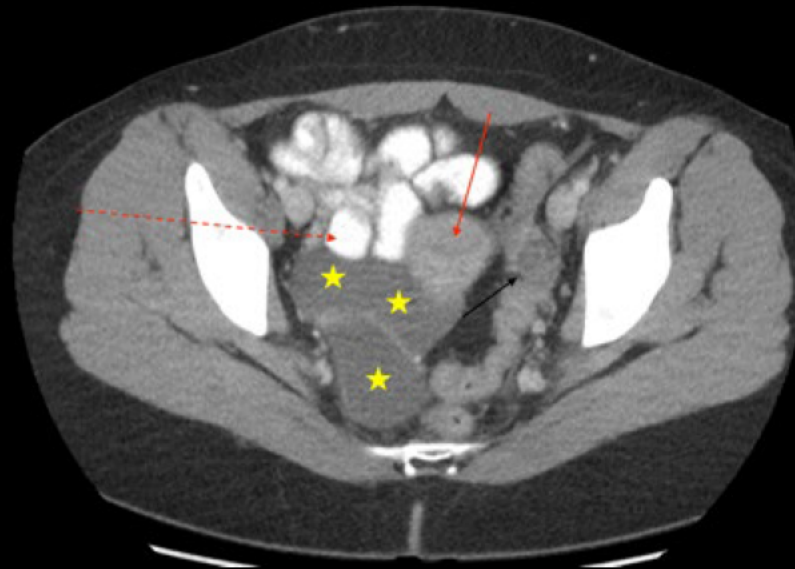
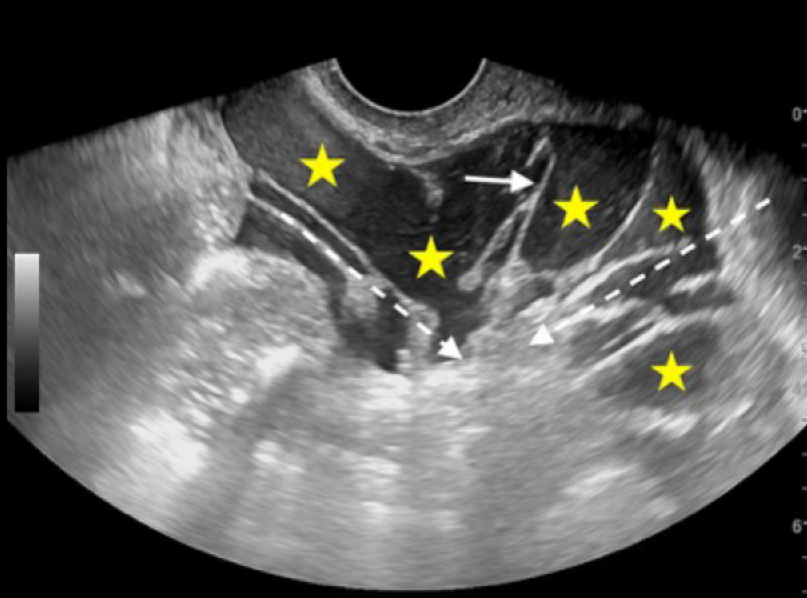
**Dr. Caitlin Ilkanich
Cleveland Clinic
Cleveland, OH**

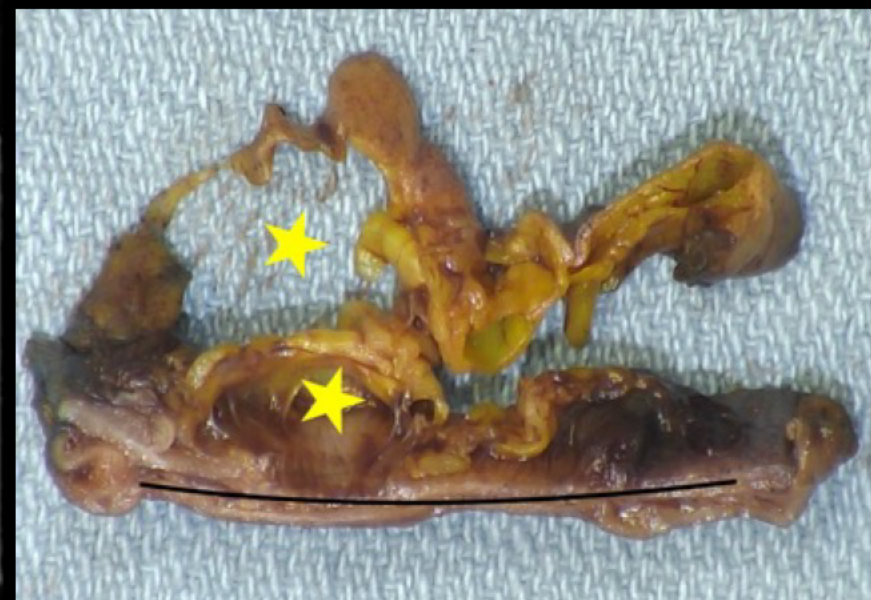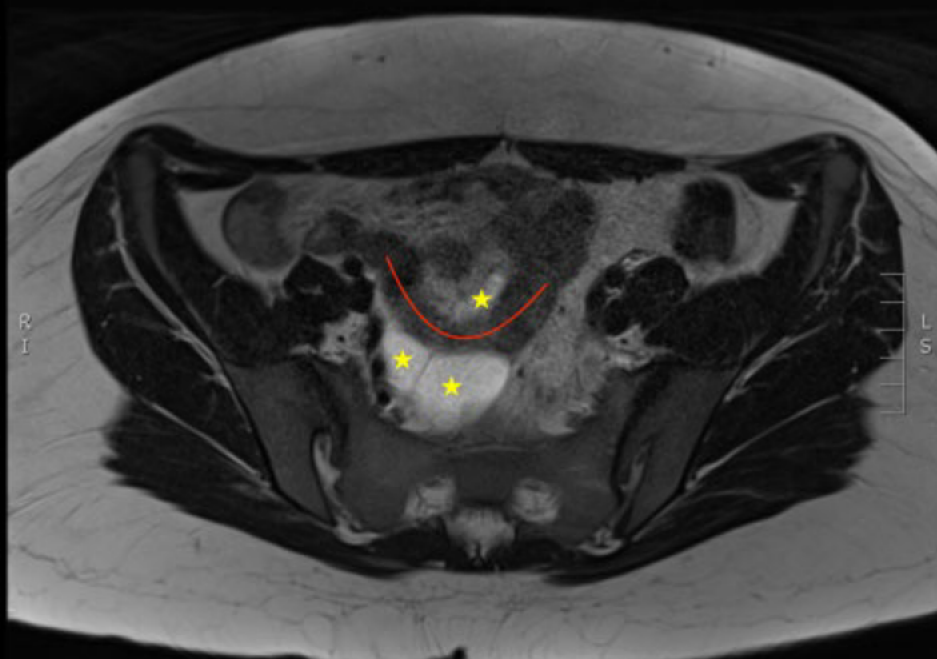
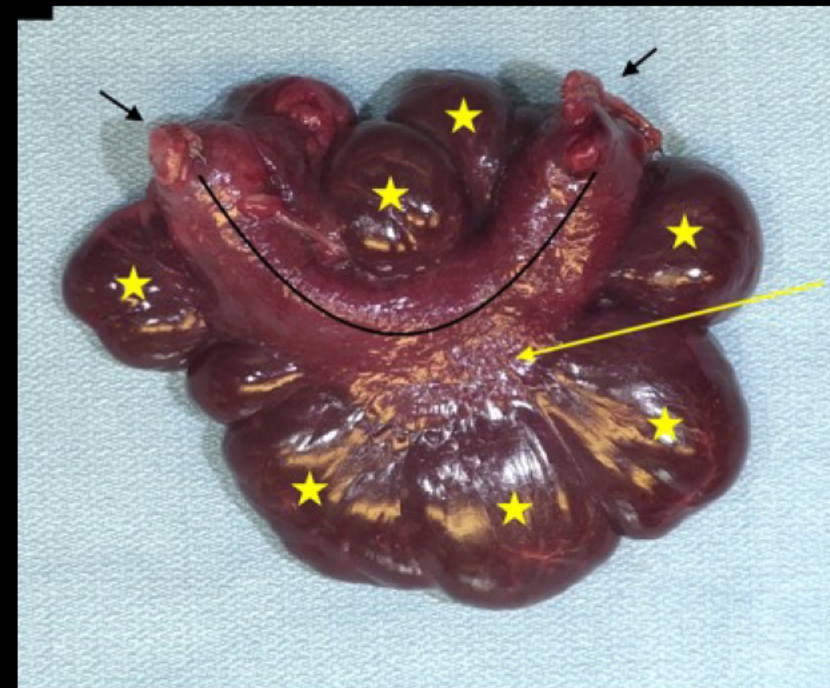
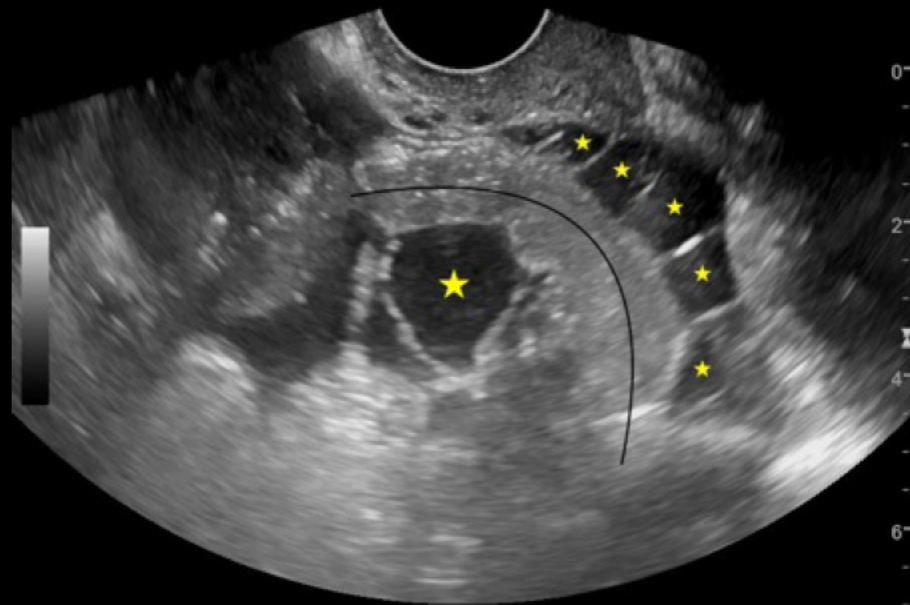
Gastrointestinal Best Case

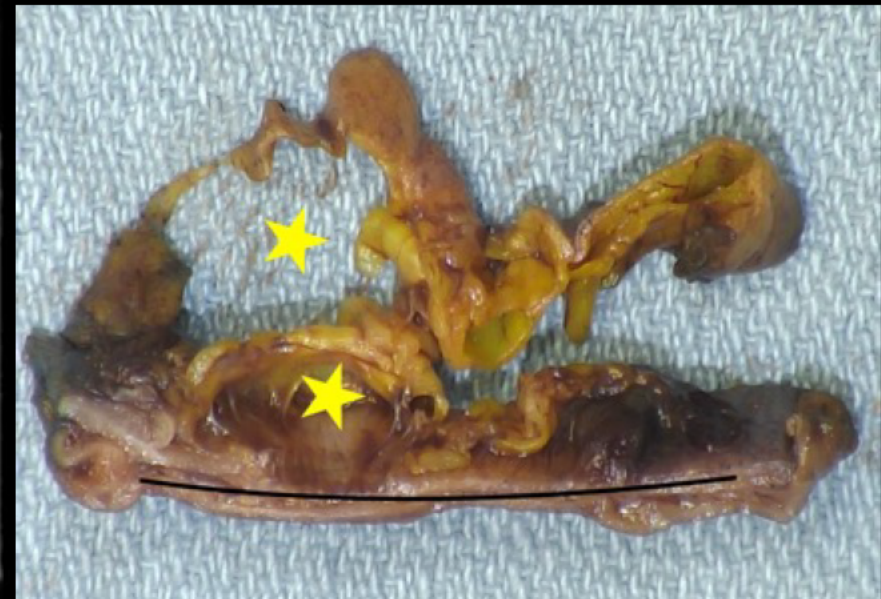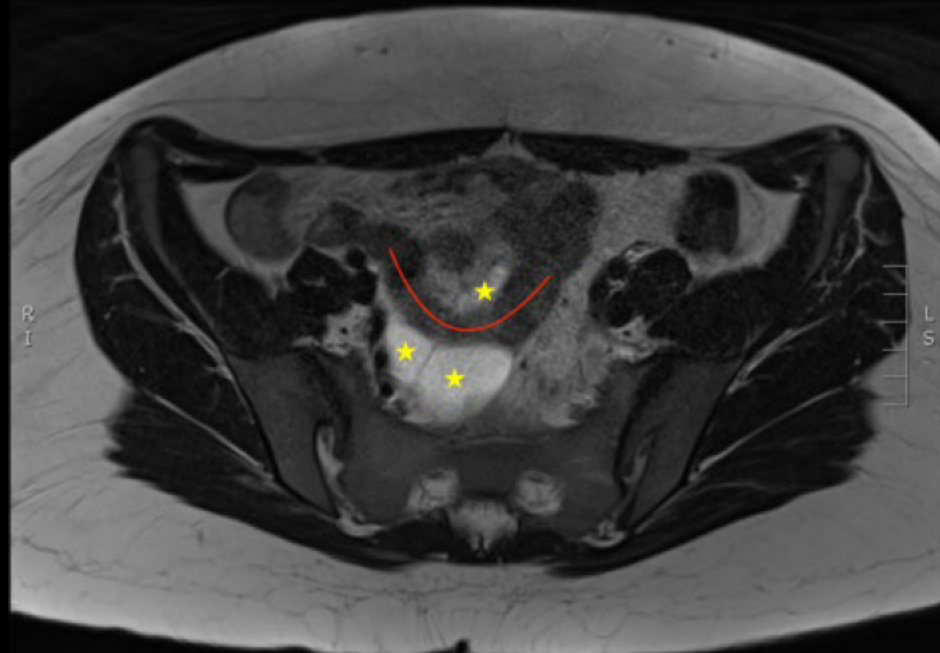
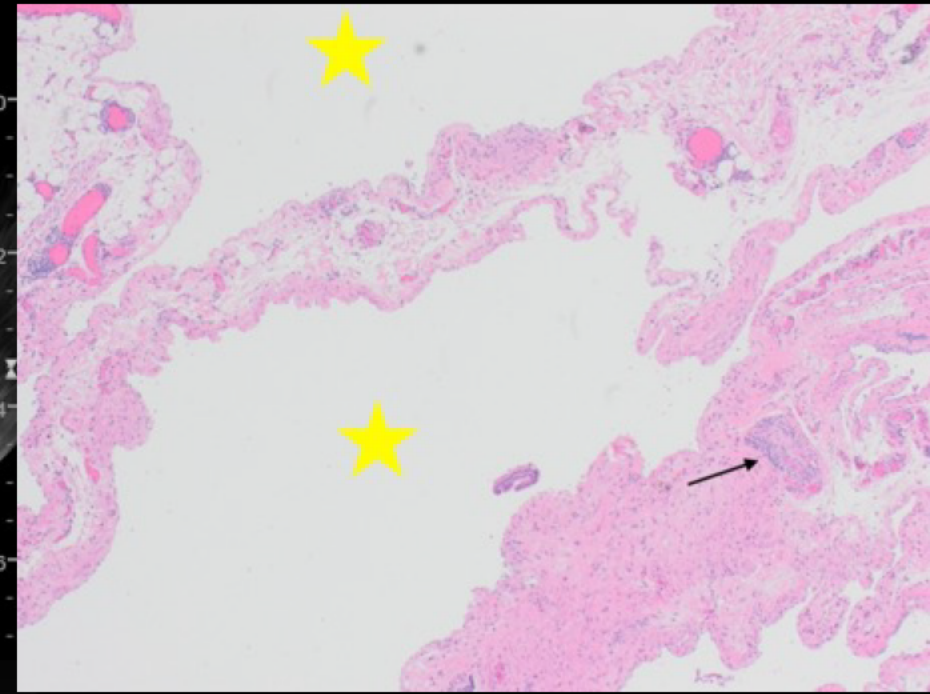
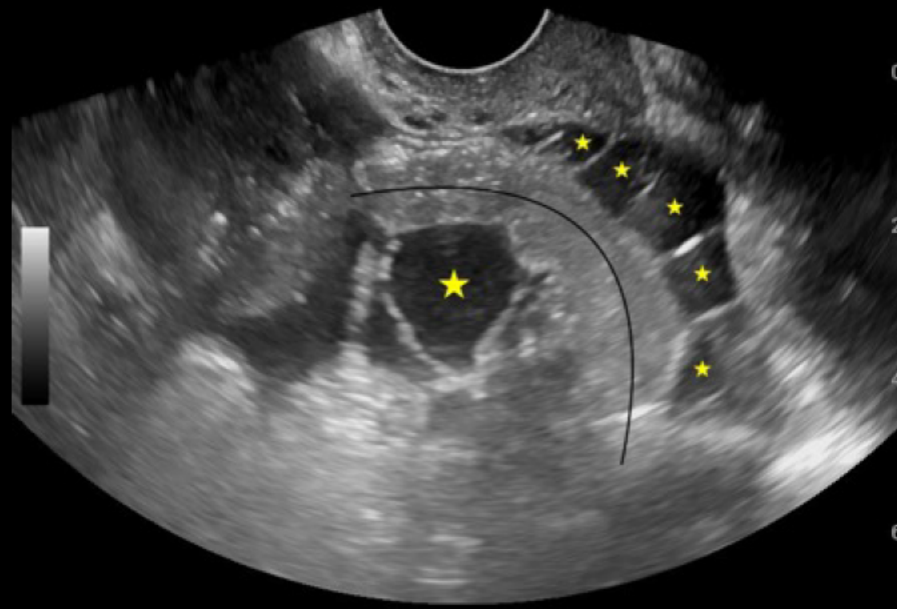


Clinical information

24-year-old female with 2 weeks of worsening abdominal pain.



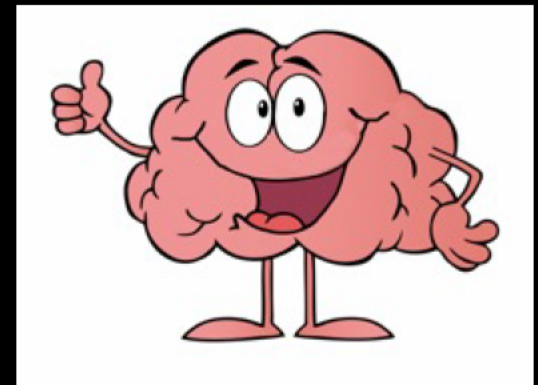
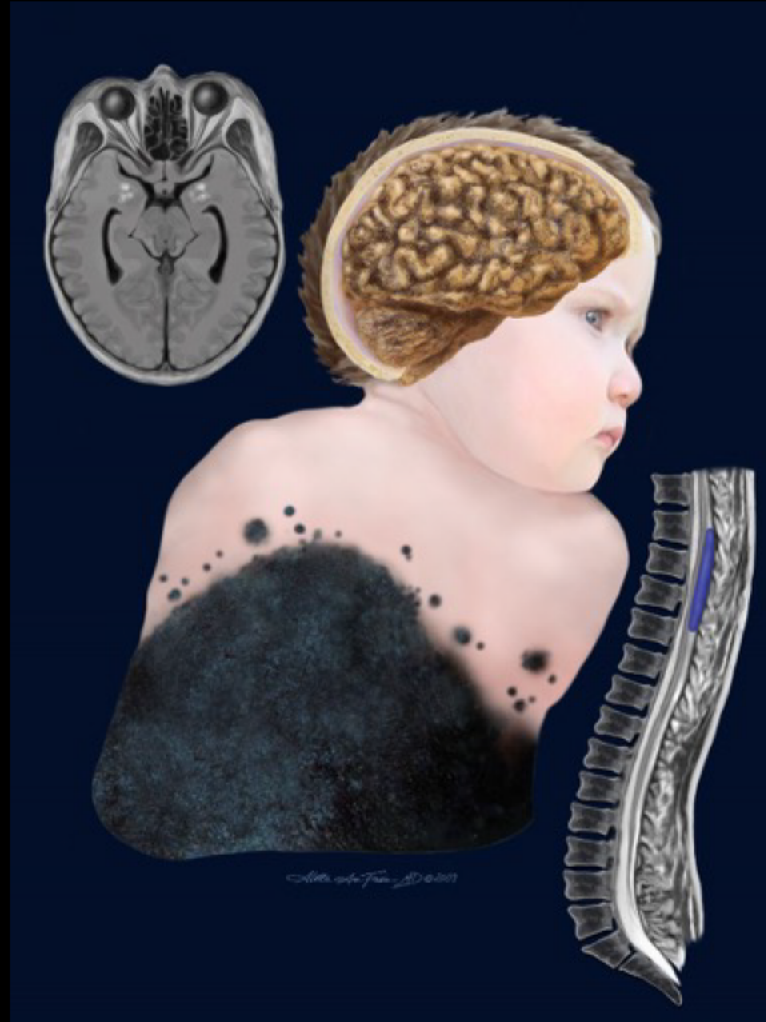



Subperitoneal Lymphangioma encasing Small Bowel

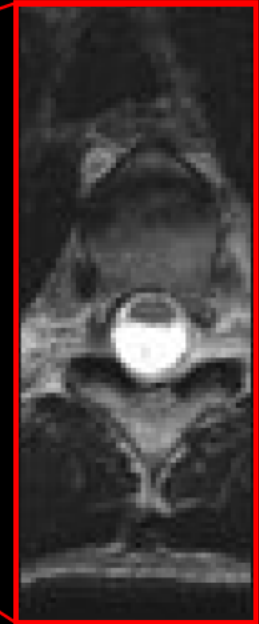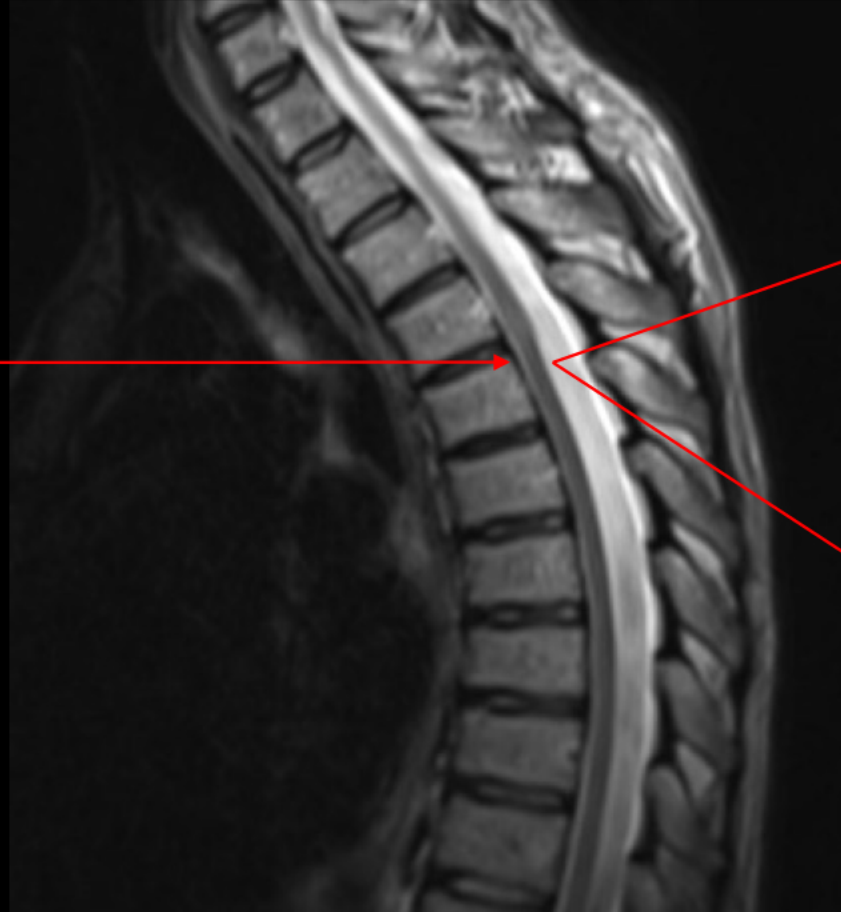**Dr. Ramin Hamidizadeh
Cumming School of Medicine
Calgary, Alberta**

Neuroradiology Best Case



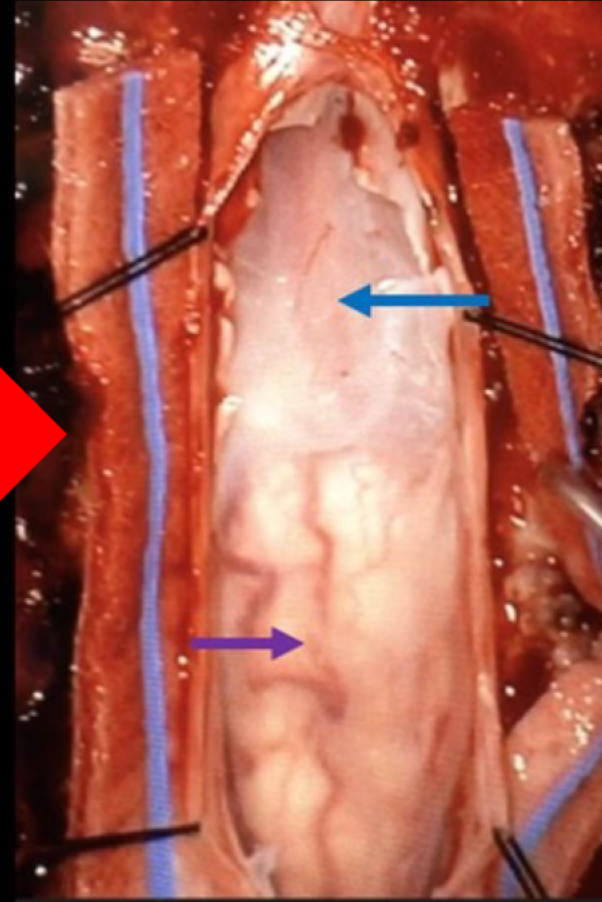
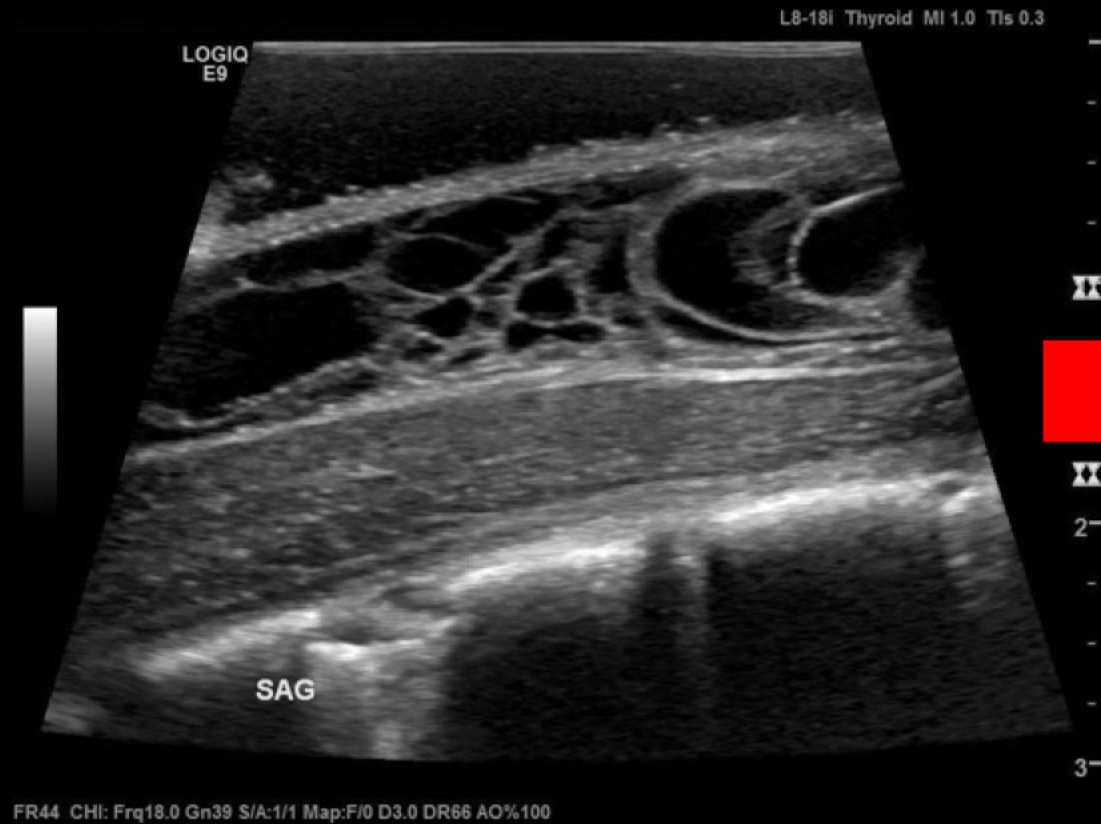44 y/o M with progressive back pain, gait instability, and lower extremity weakness

focal dorsal indentation in upper thoracic spinal cord (i.e. "scalpel sign")

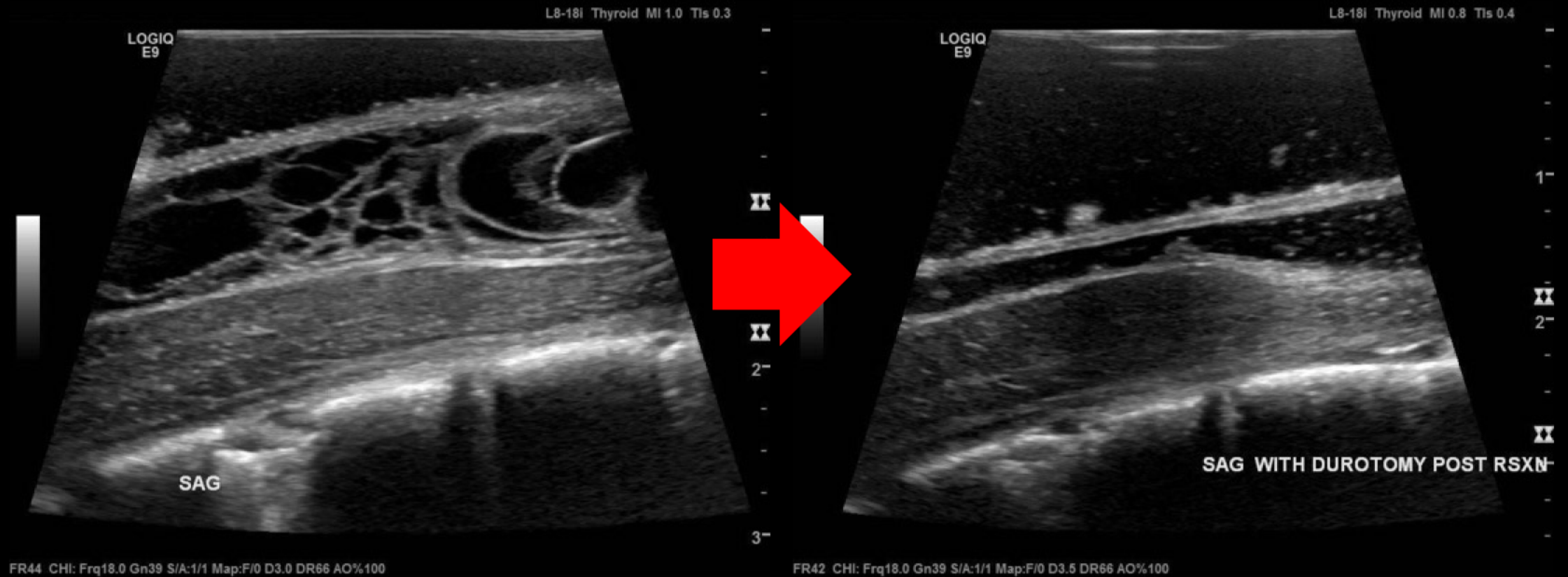


differential diagnosis = ventral cord herniation (through dural defect) vs dorsal arachnoid cyst/web (from septum posticum)

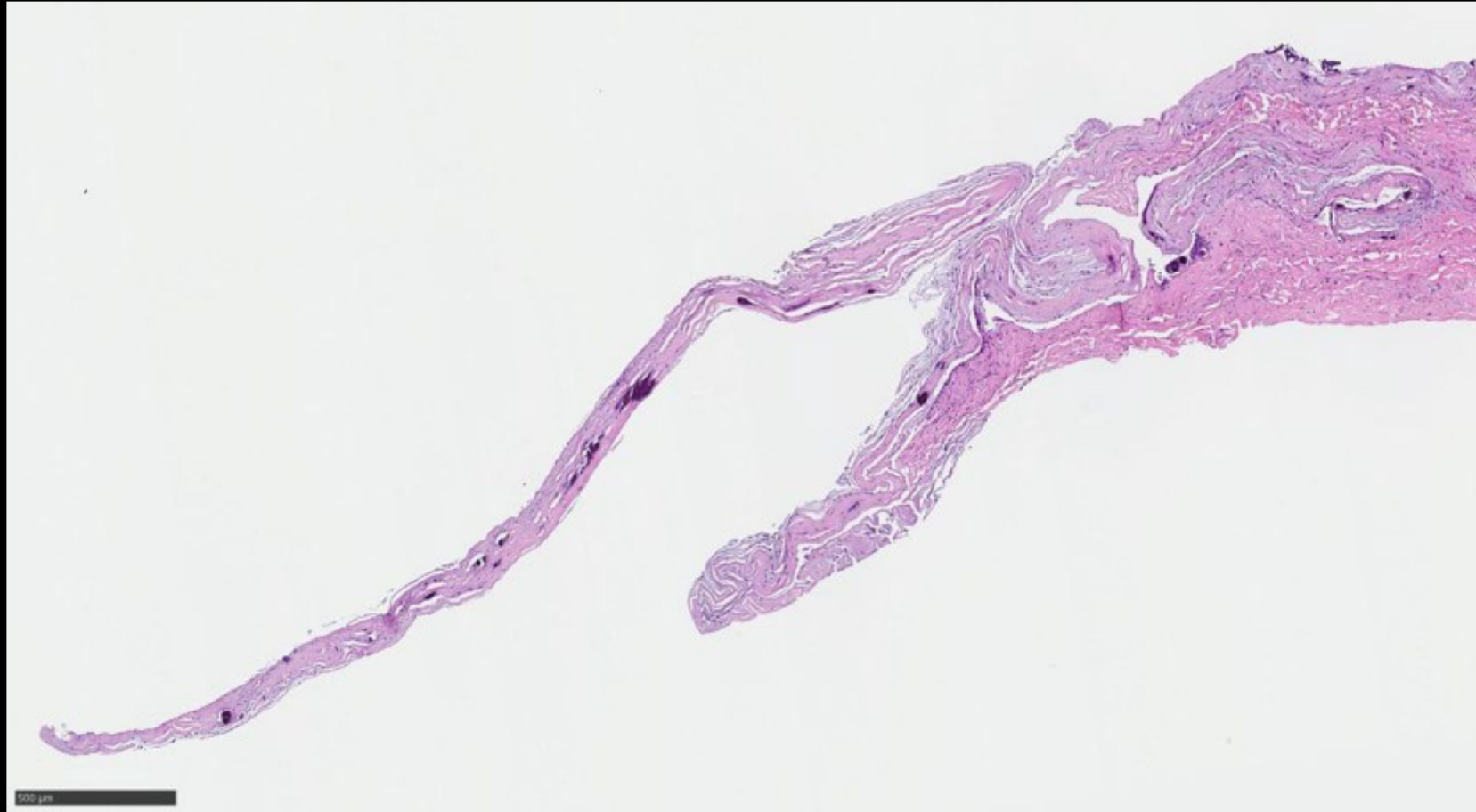Excision of Dorsal Arachnoid Web at T4-T5



Intraoperative Ultrasound: Before & After

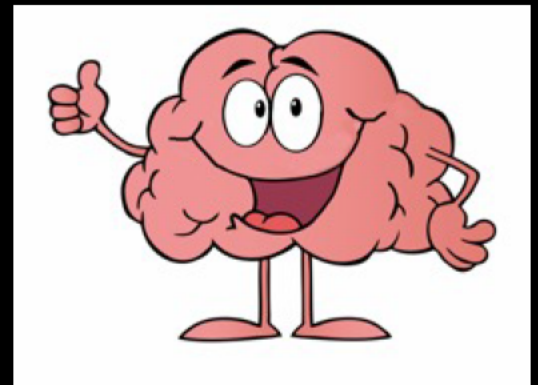


Meningothelial Cells + Calcifications + Fibrosis

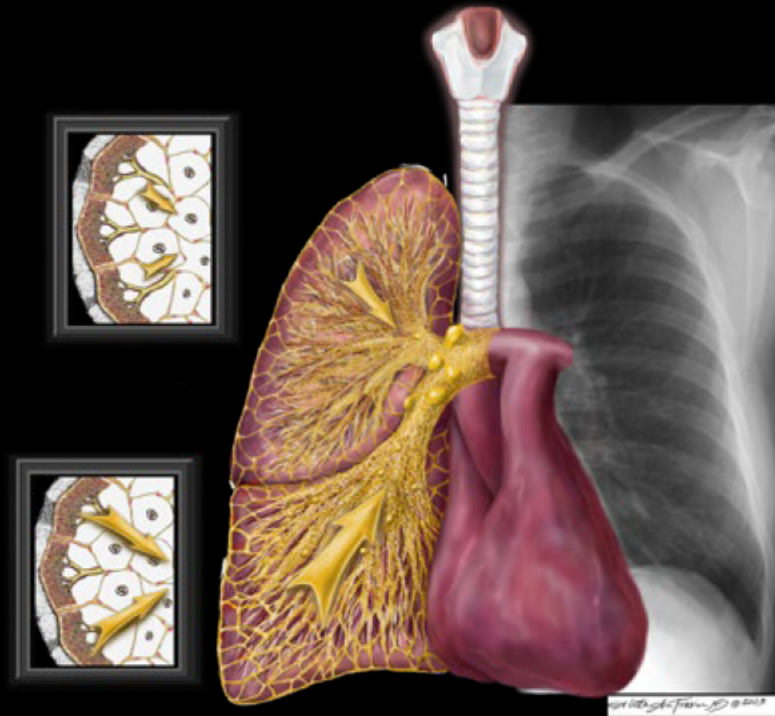


Dorsal Arachnoid Web

Dr. Jennifer Clark
Georgetown University
Washington, DC

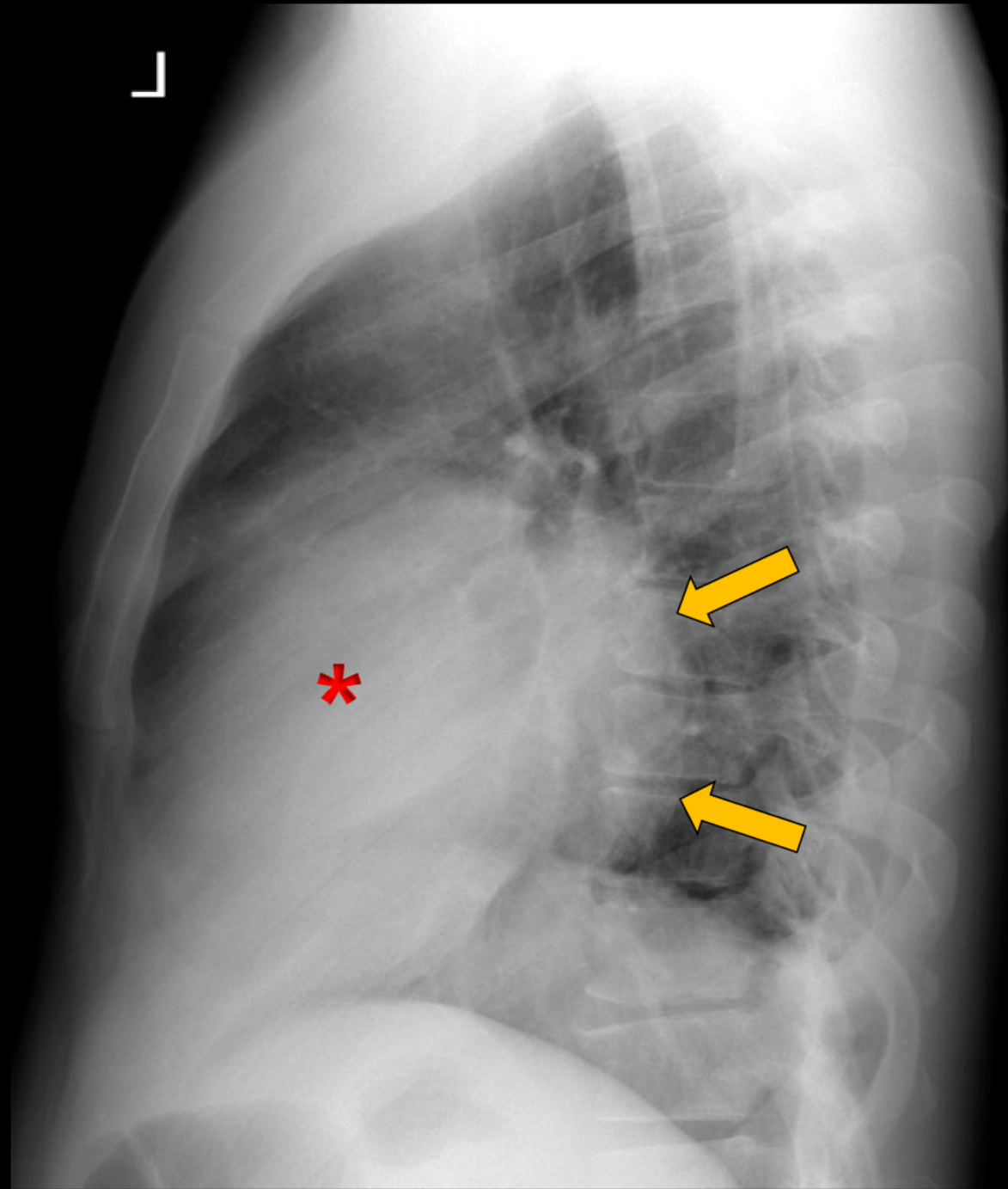
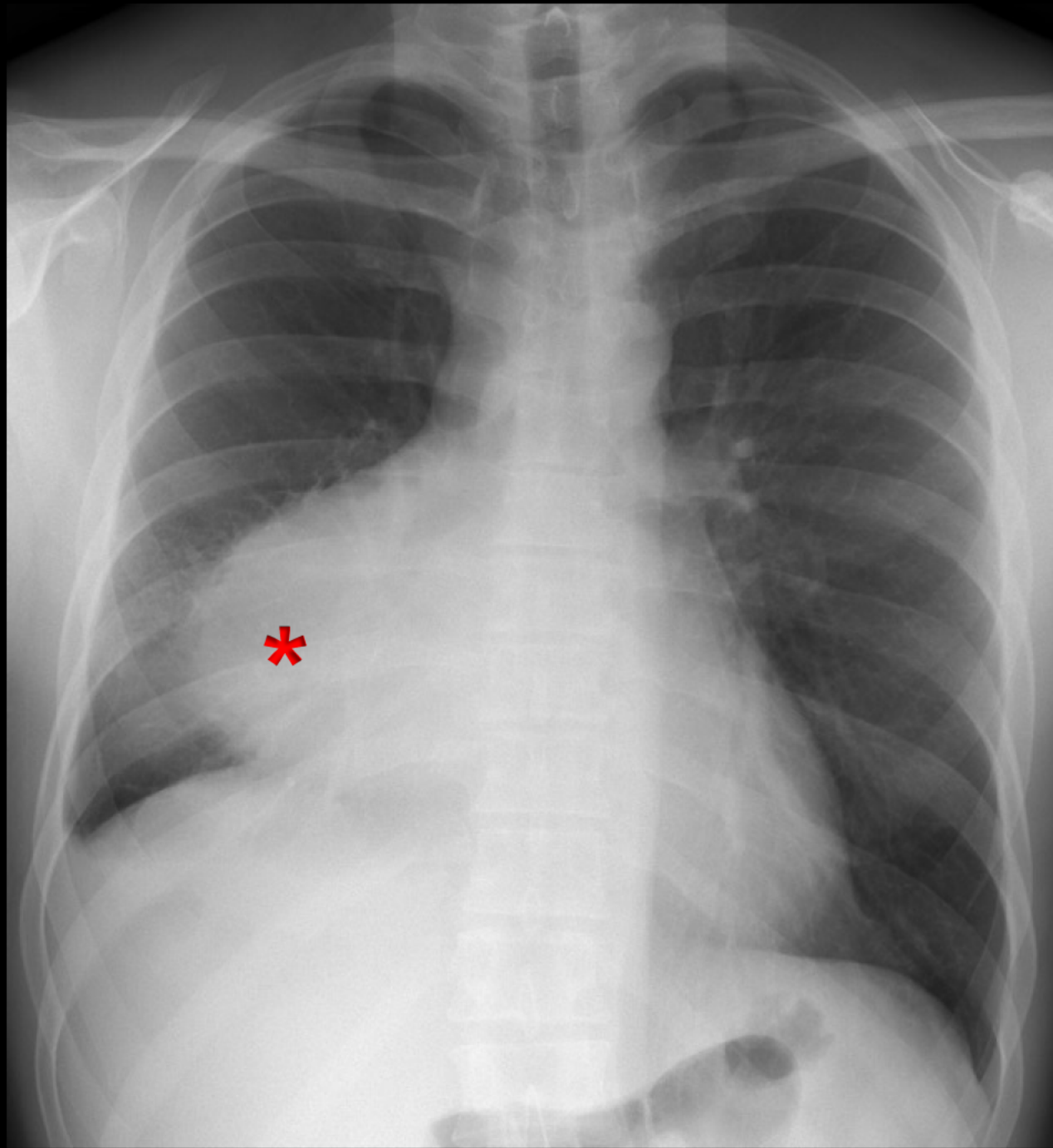


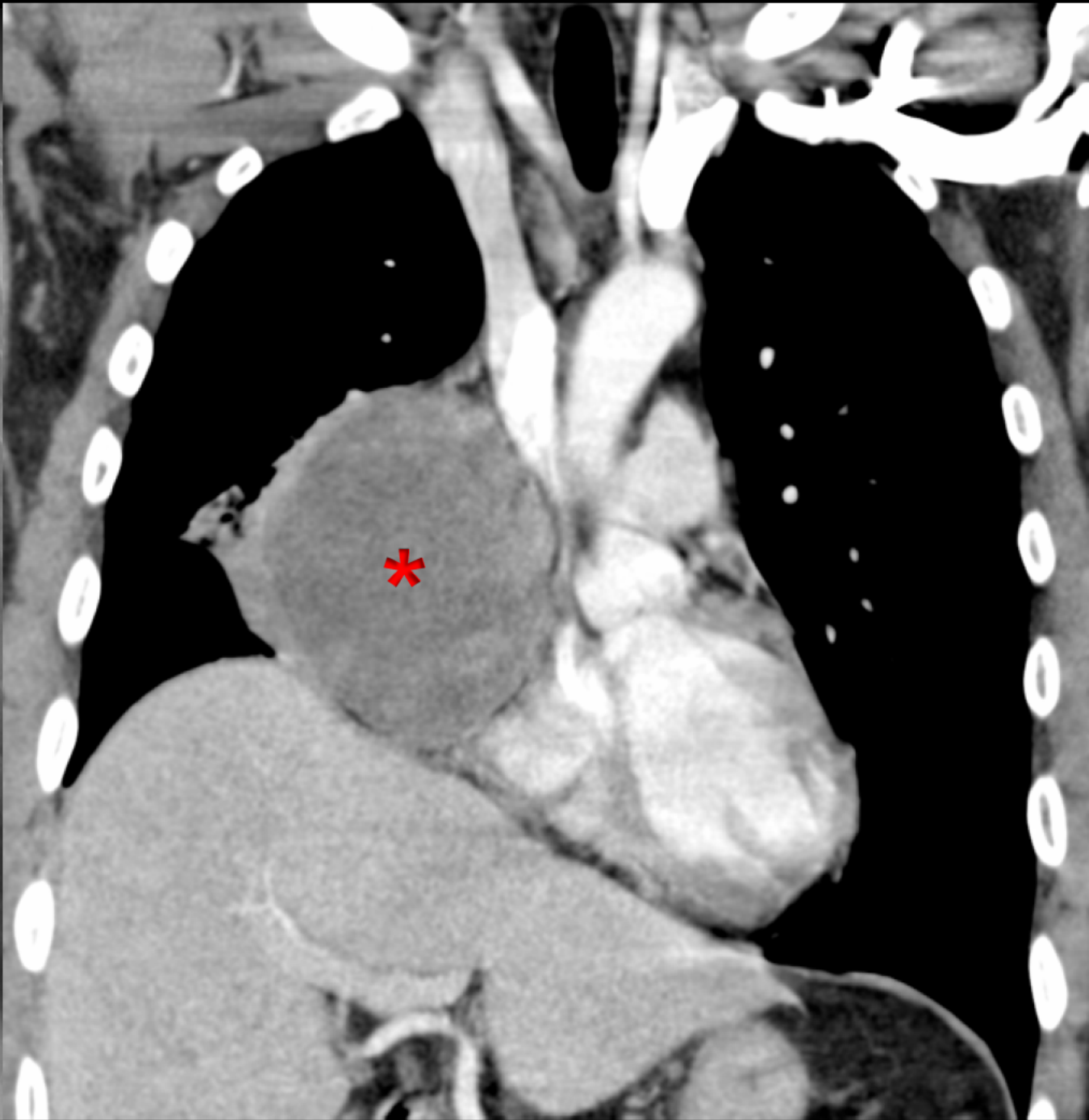
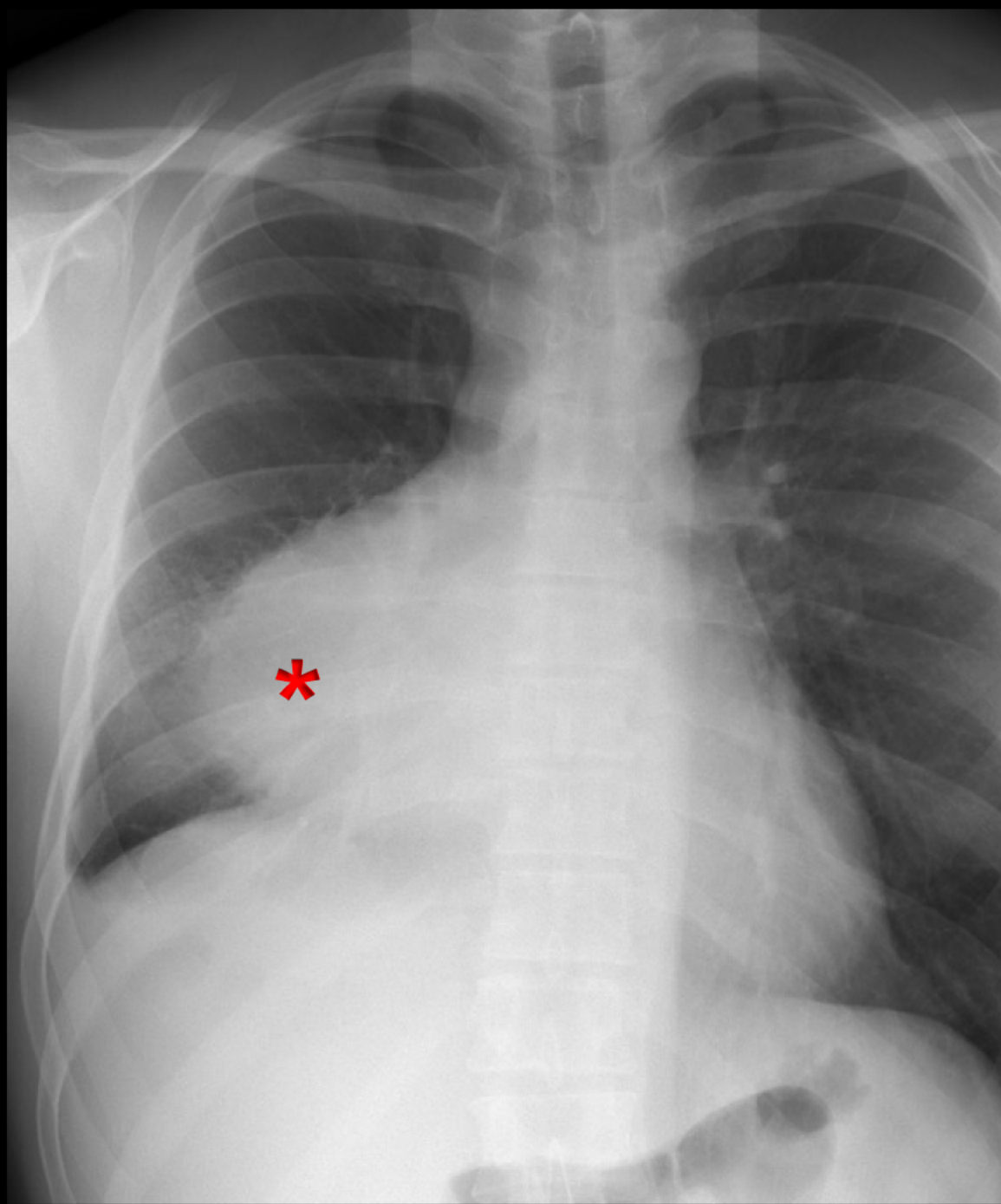
Pulmonary and Mediastinal Best Case

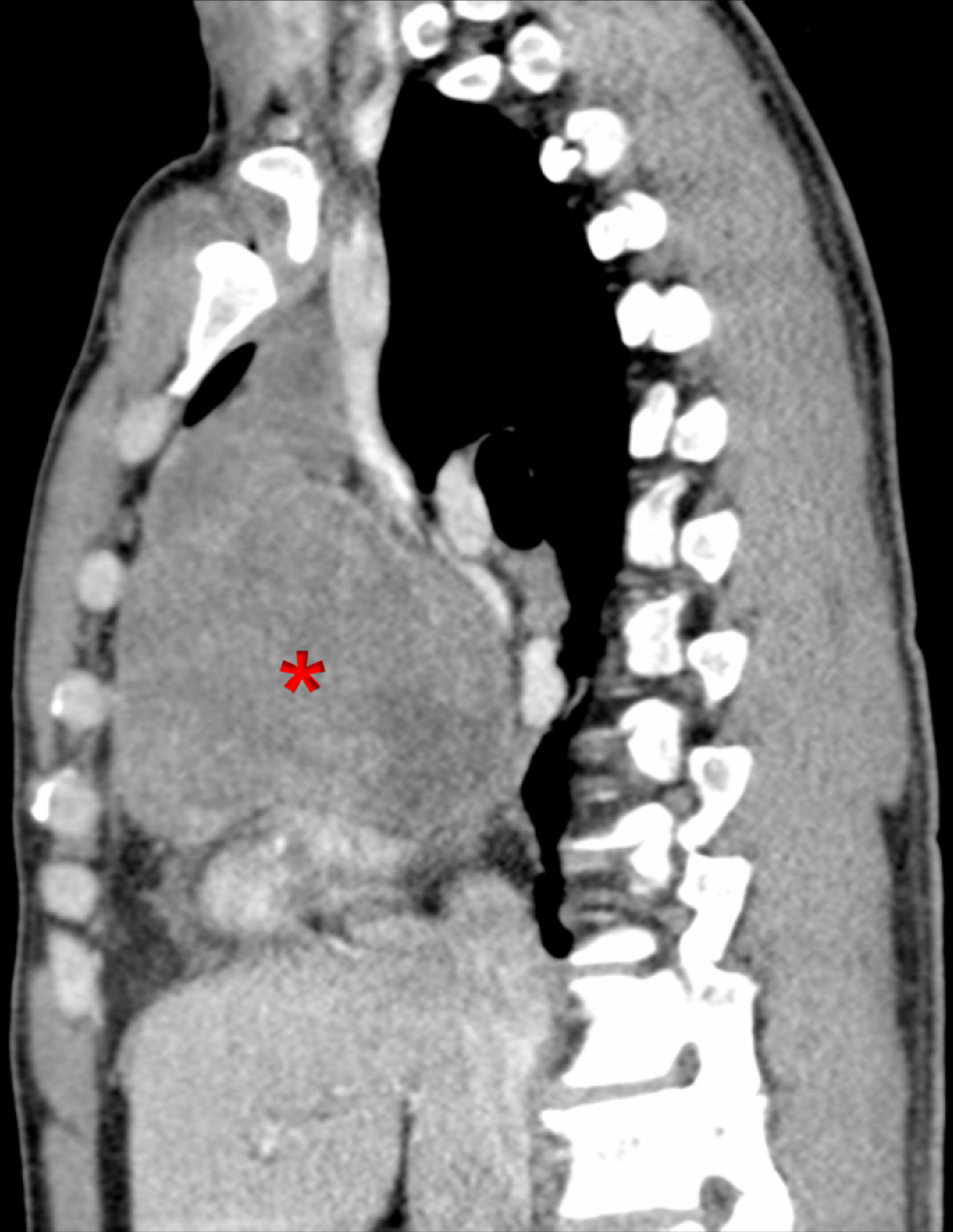
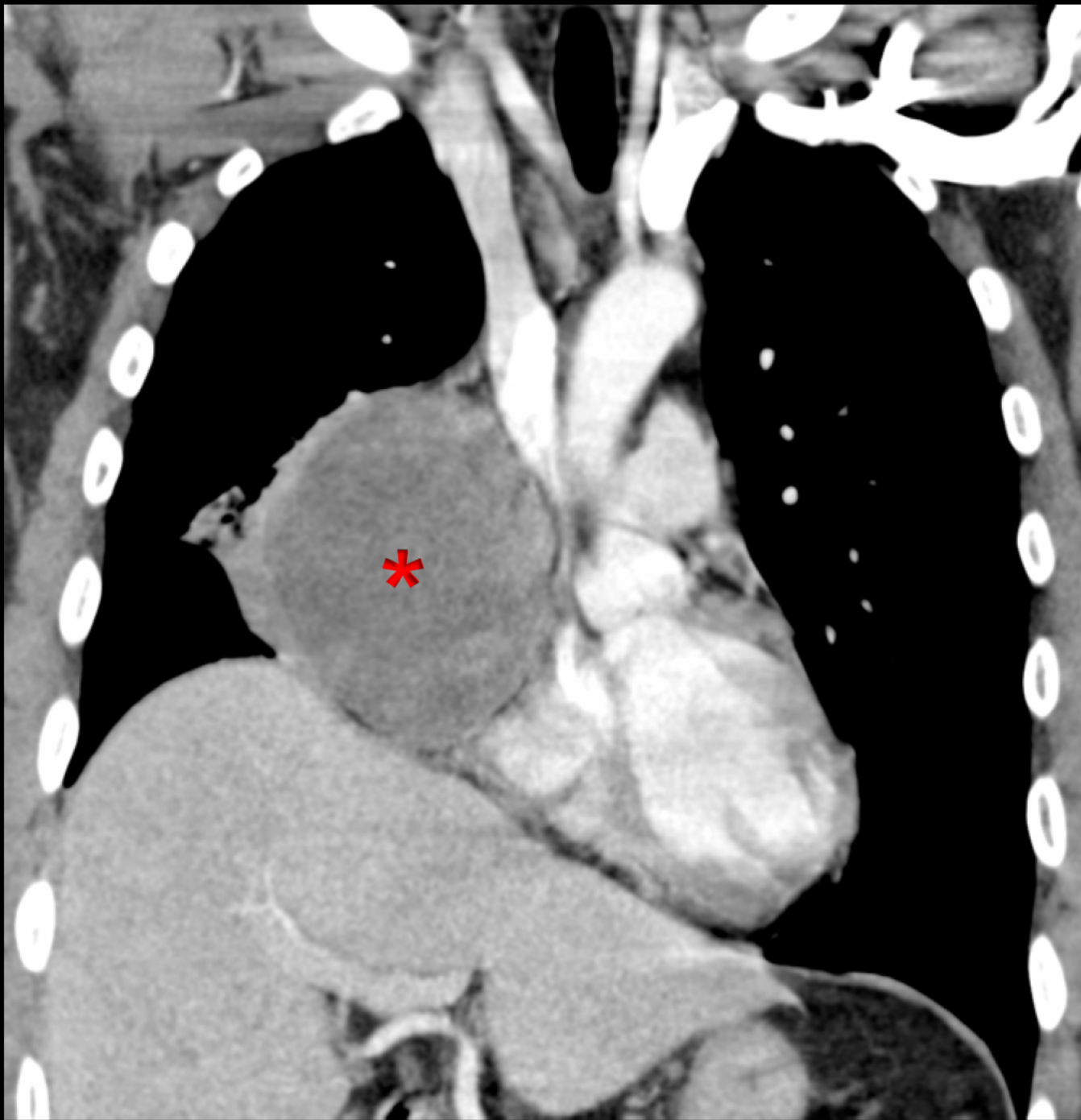
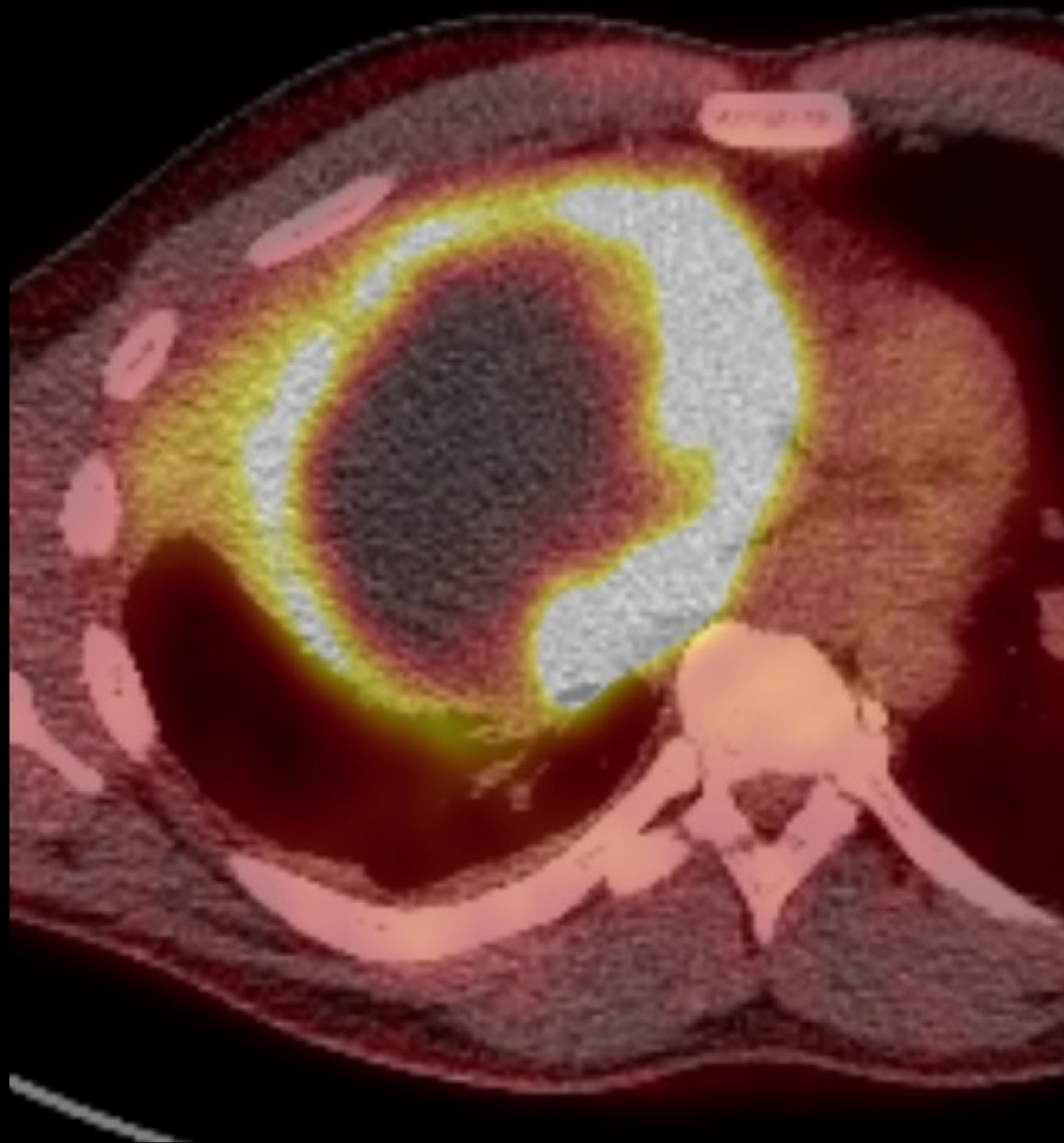
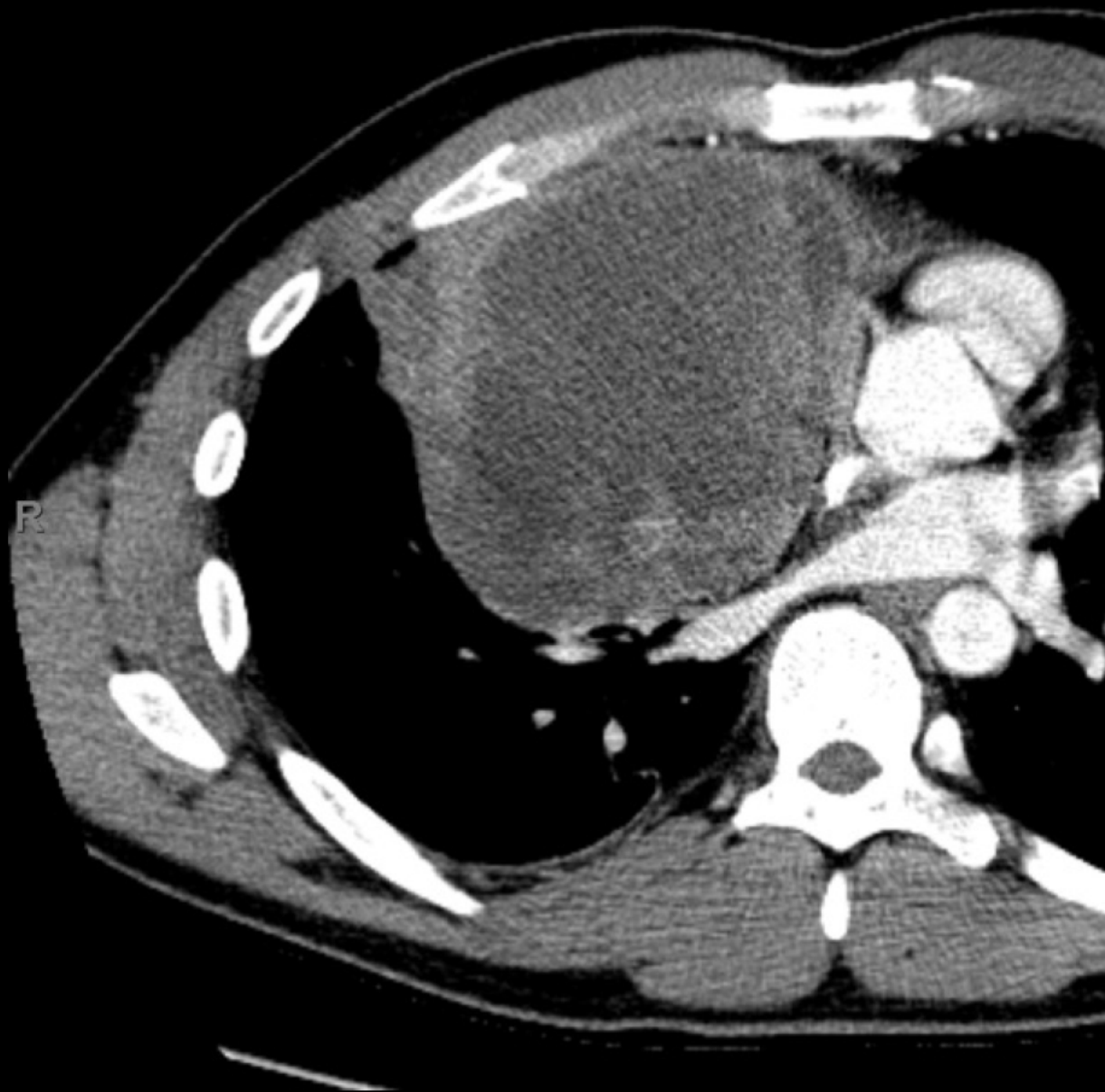
Clinical information

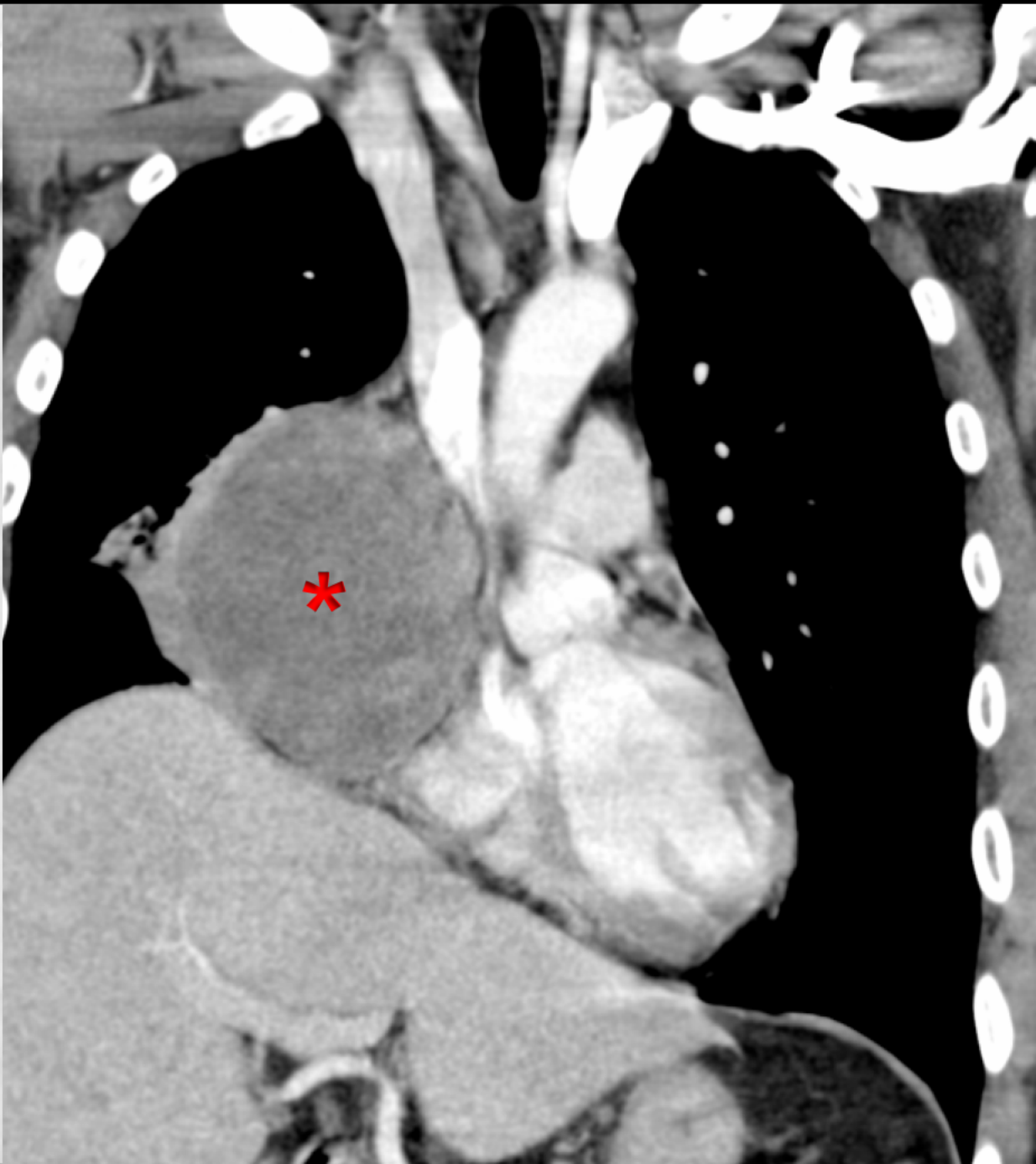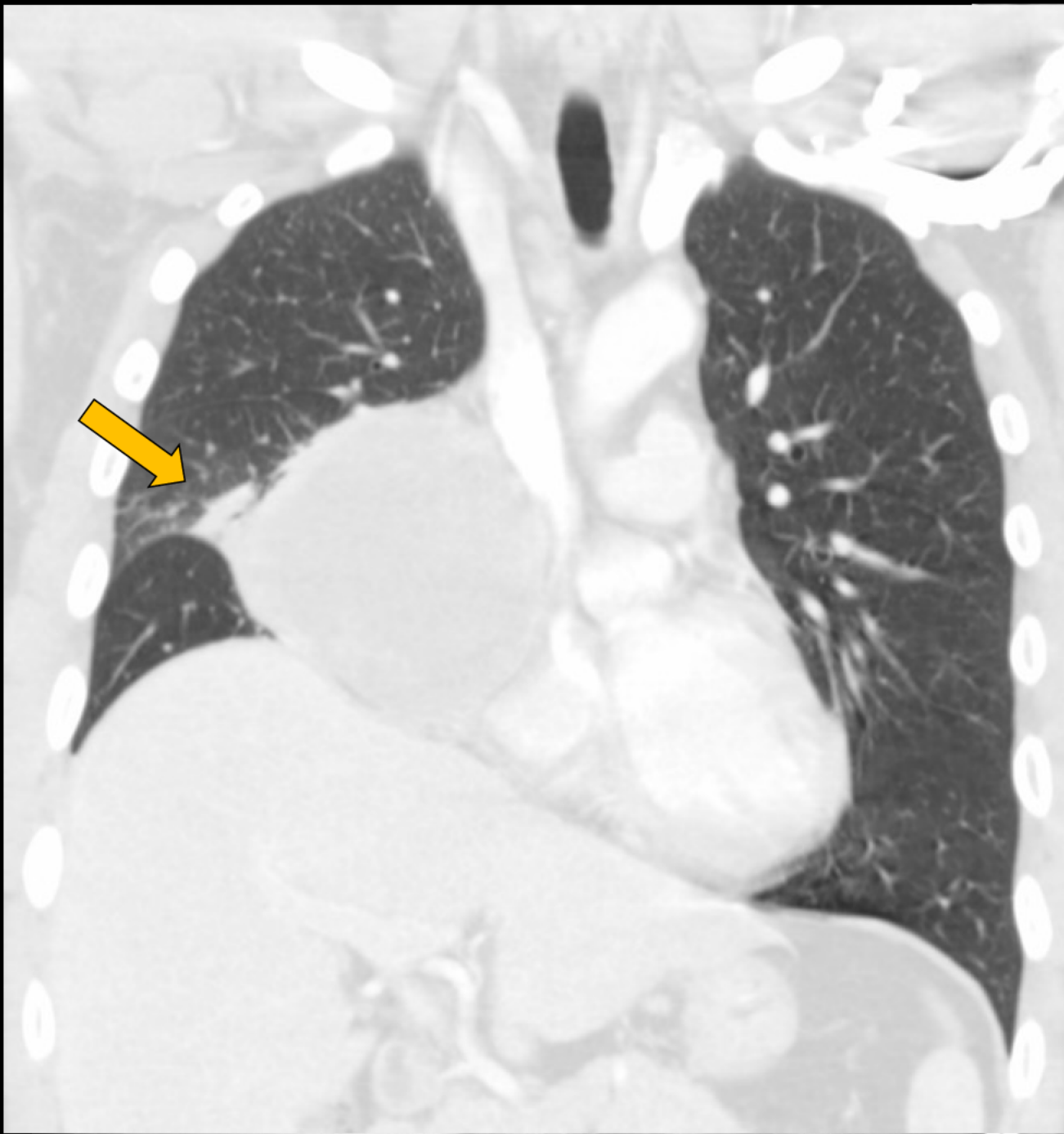
**41-year-old male with one month of
dyspnea on exertion and non-productive
cough.**

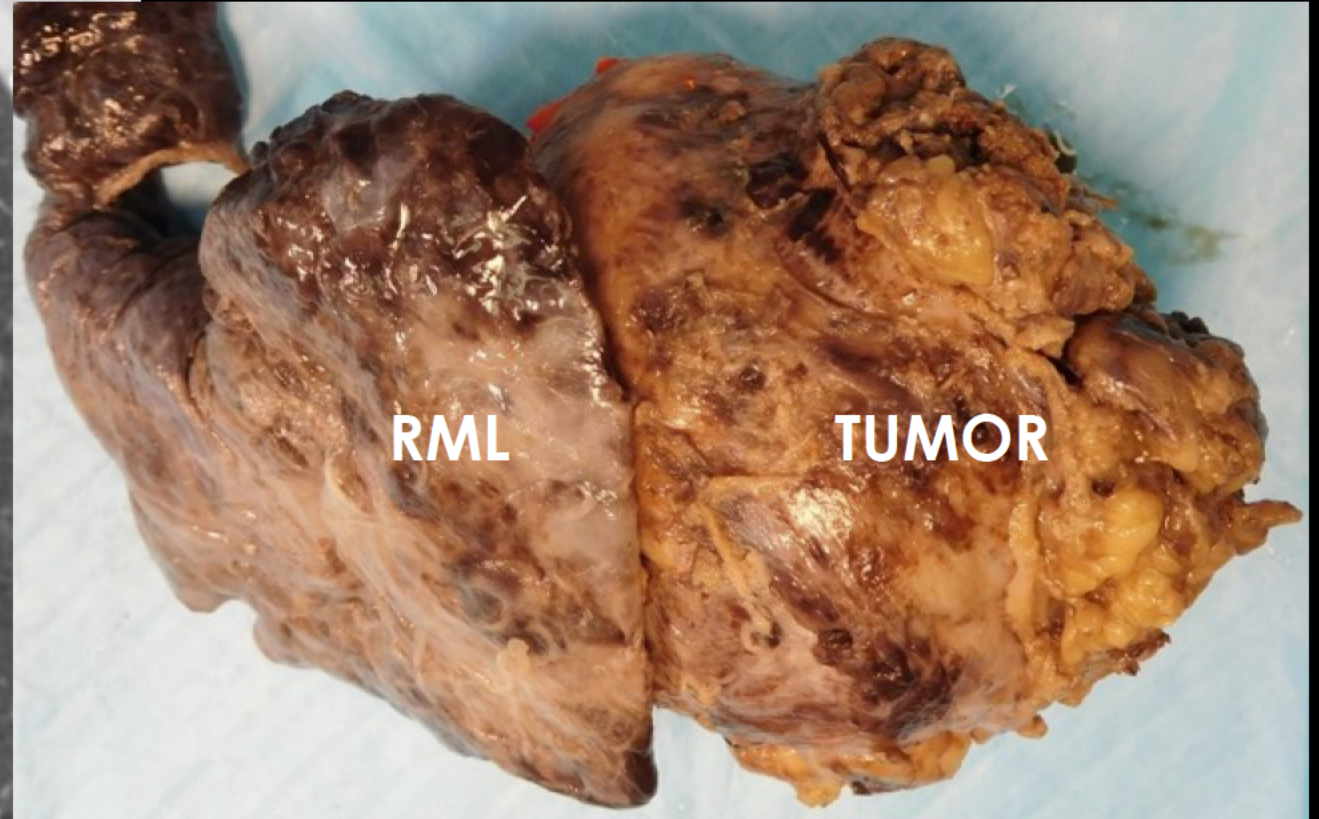
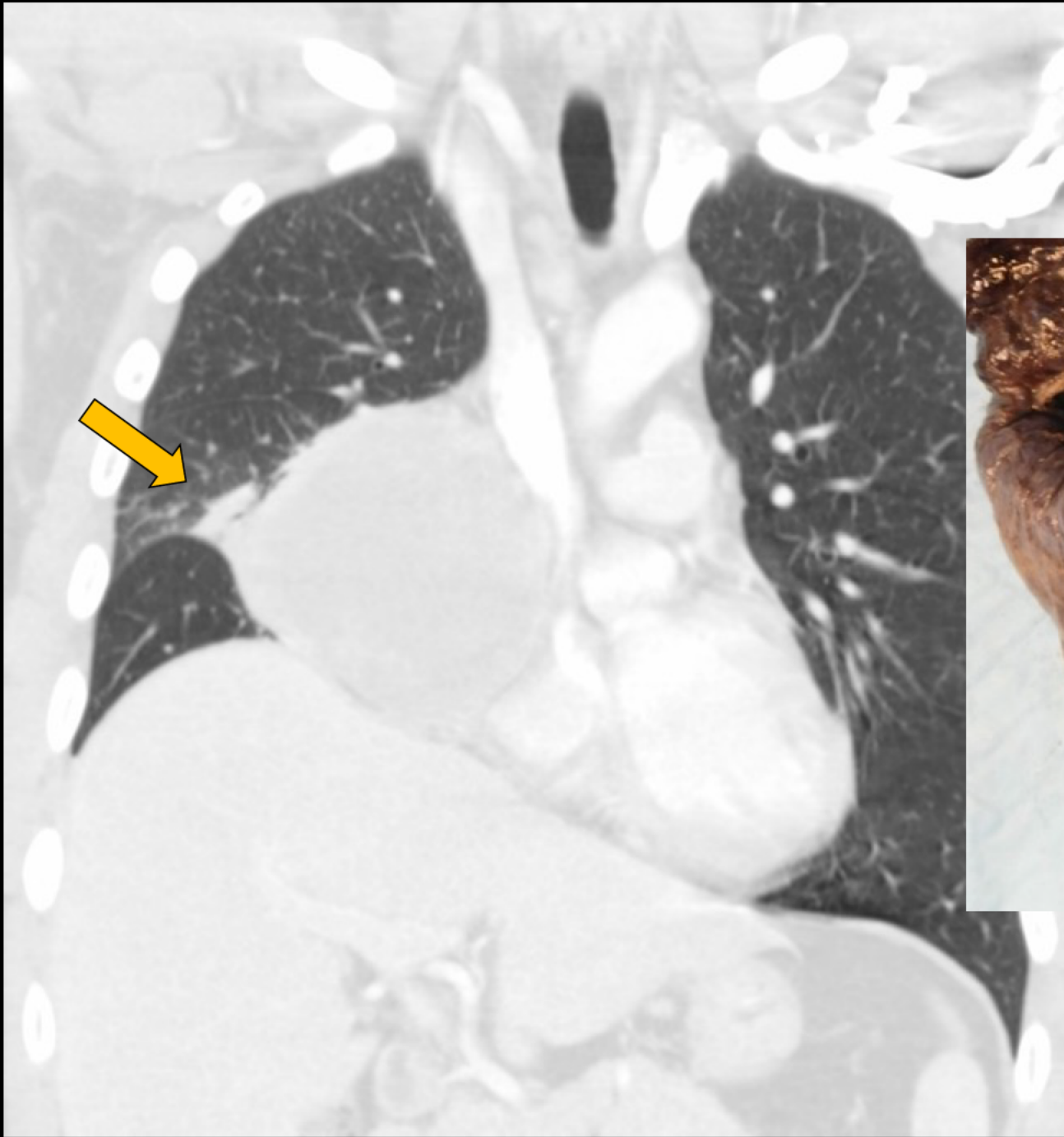


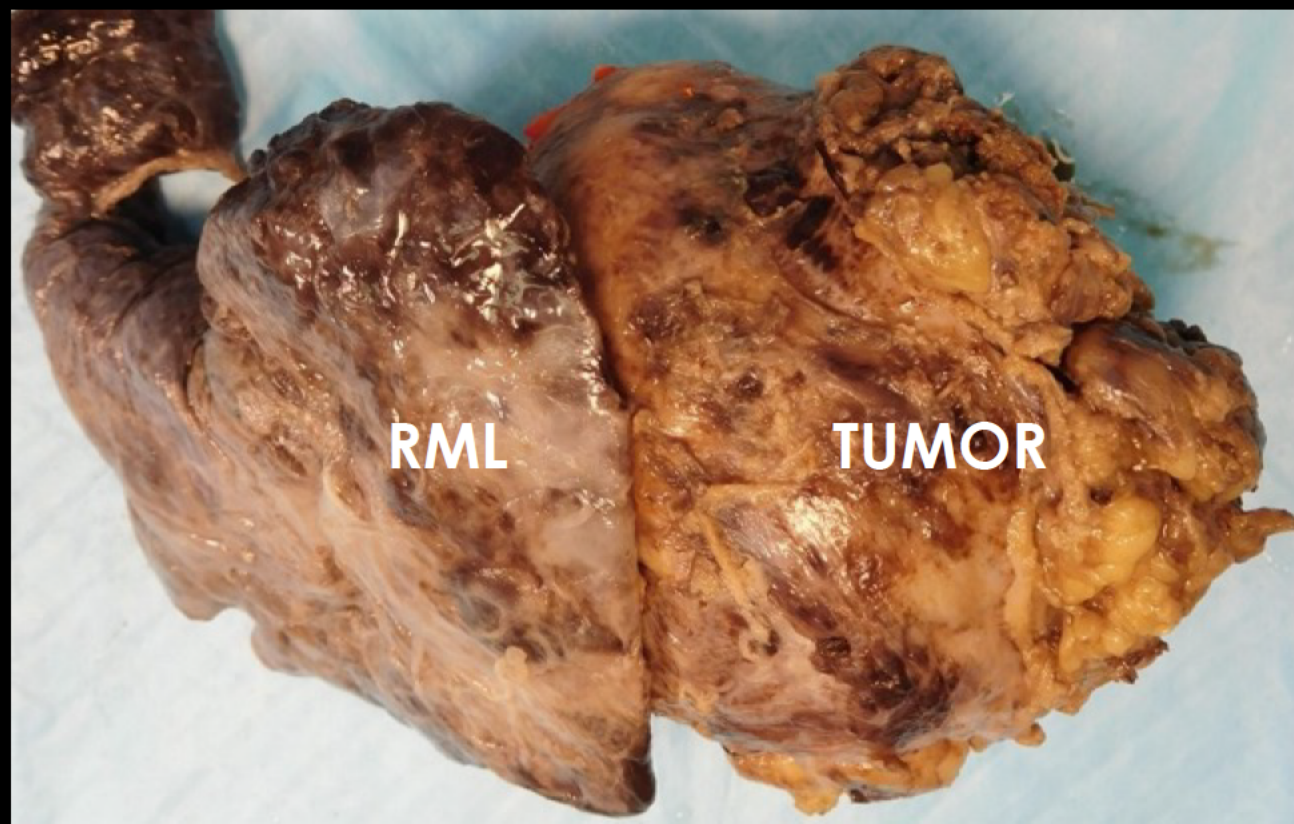
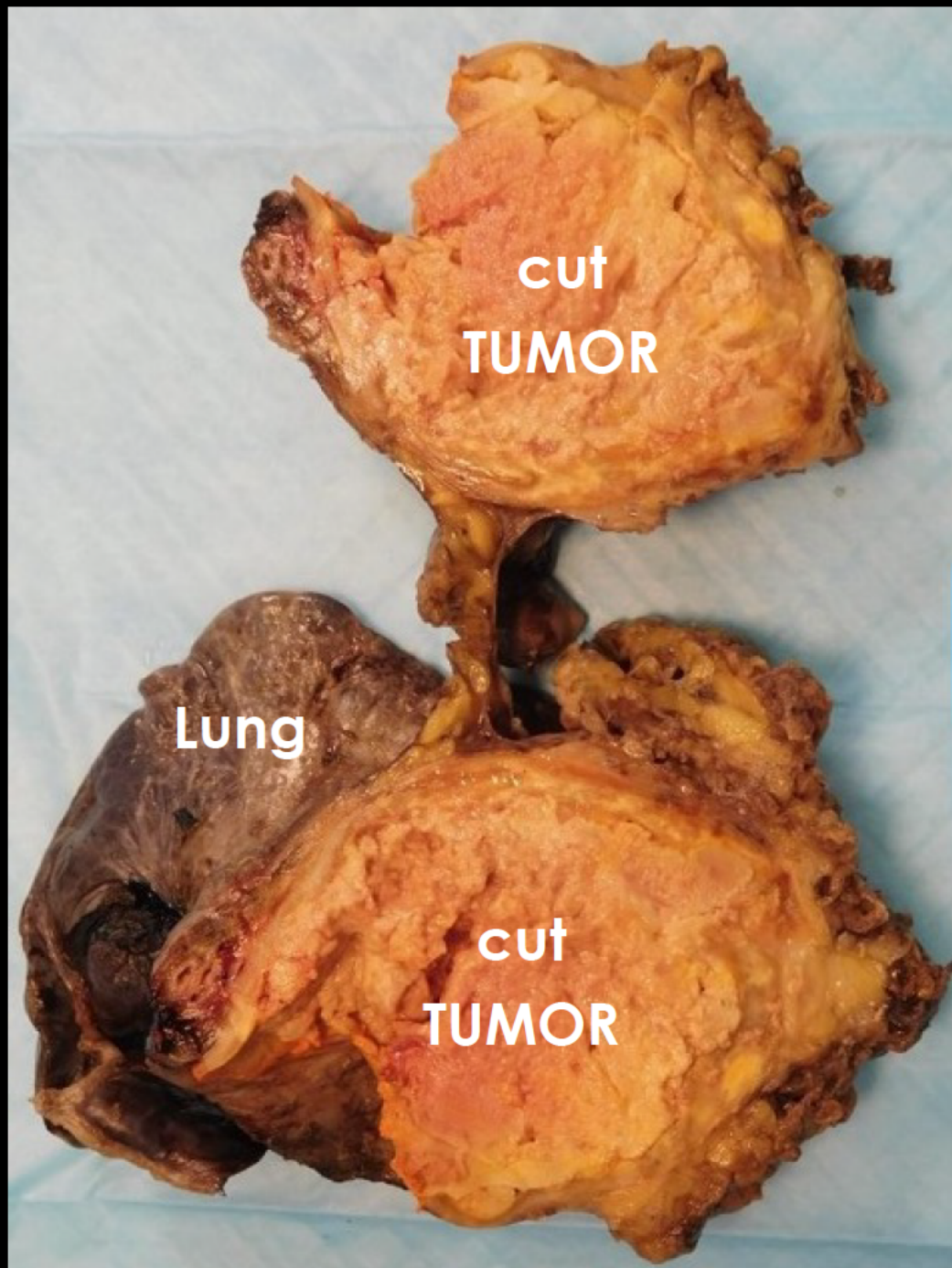


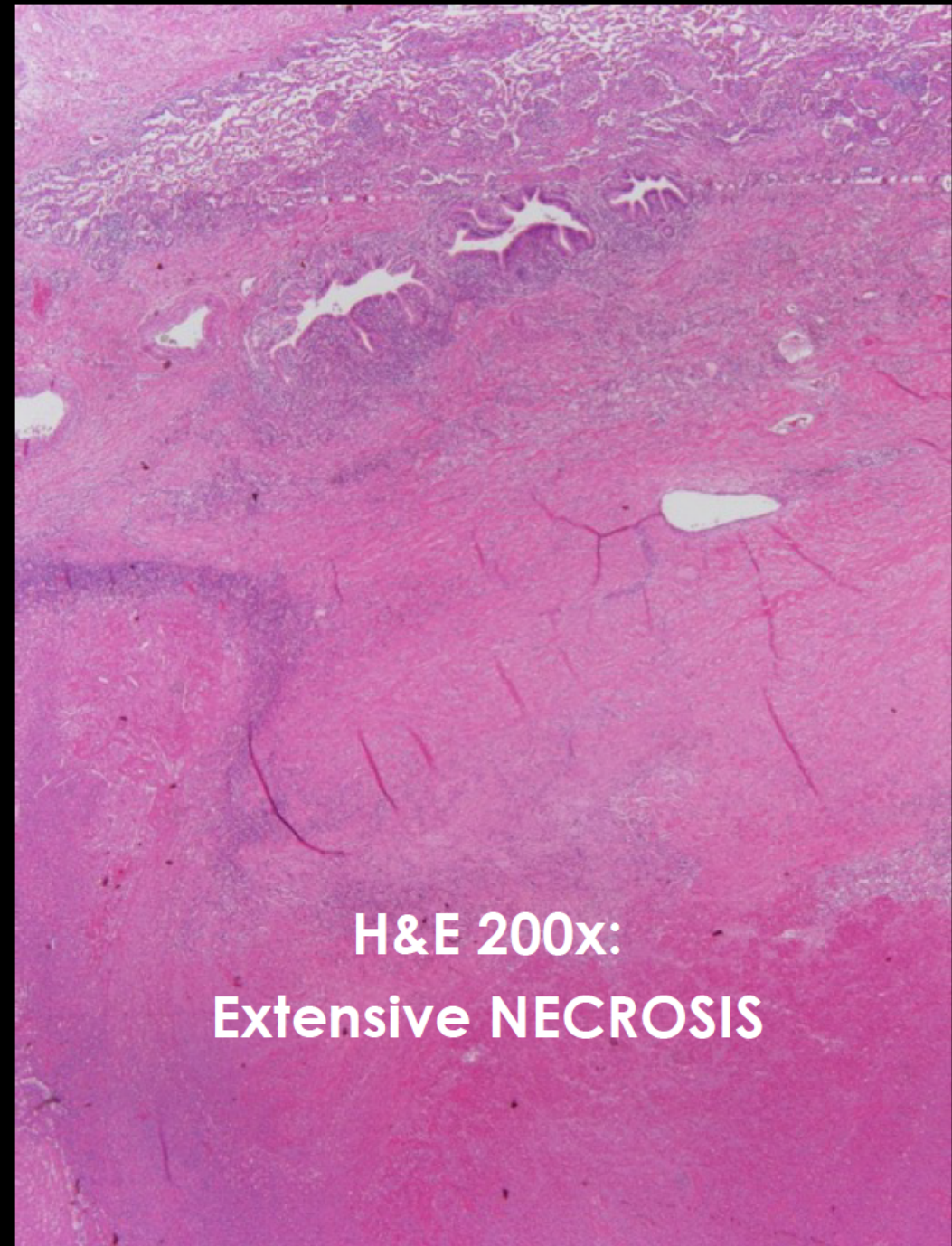
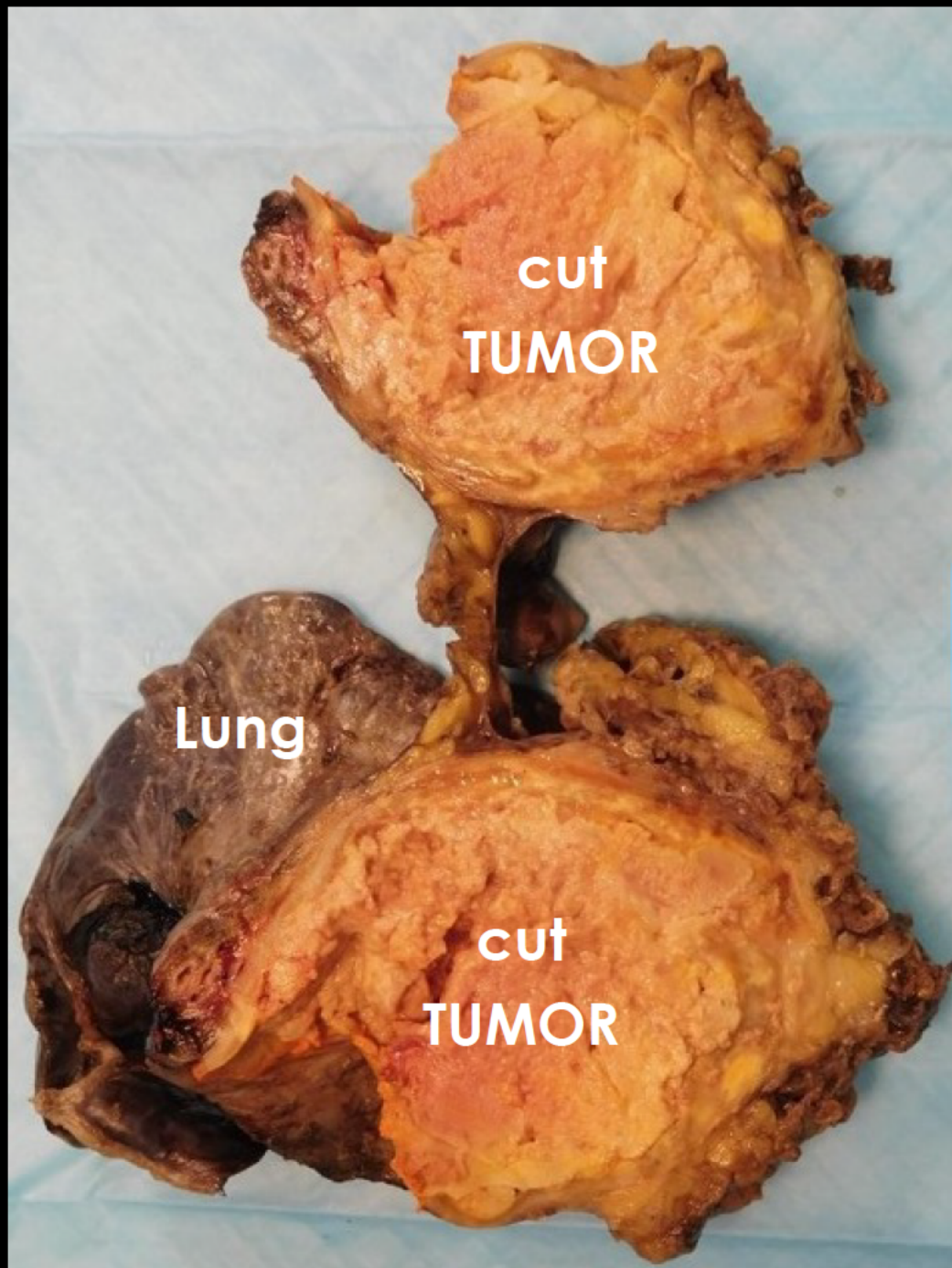




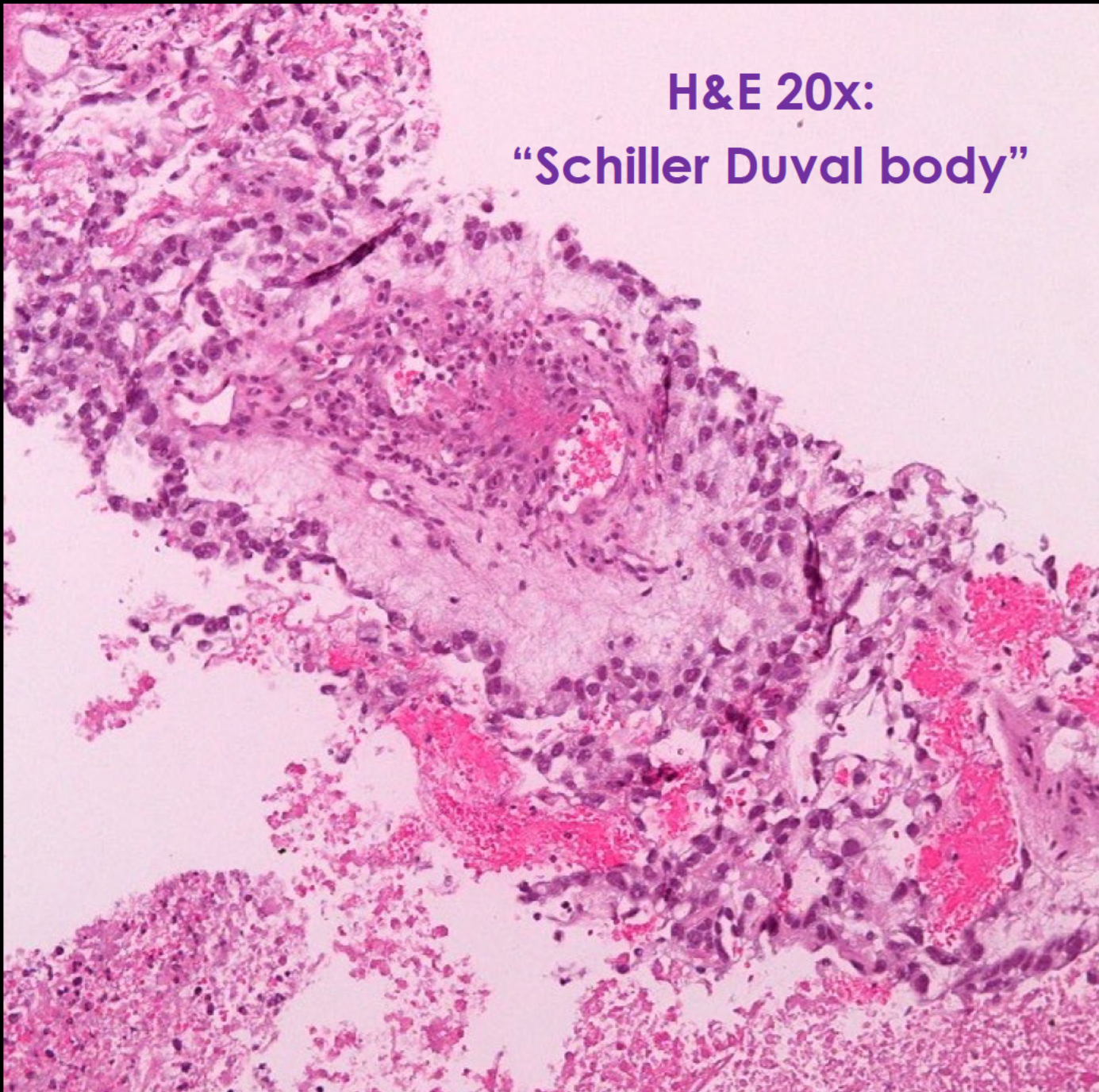




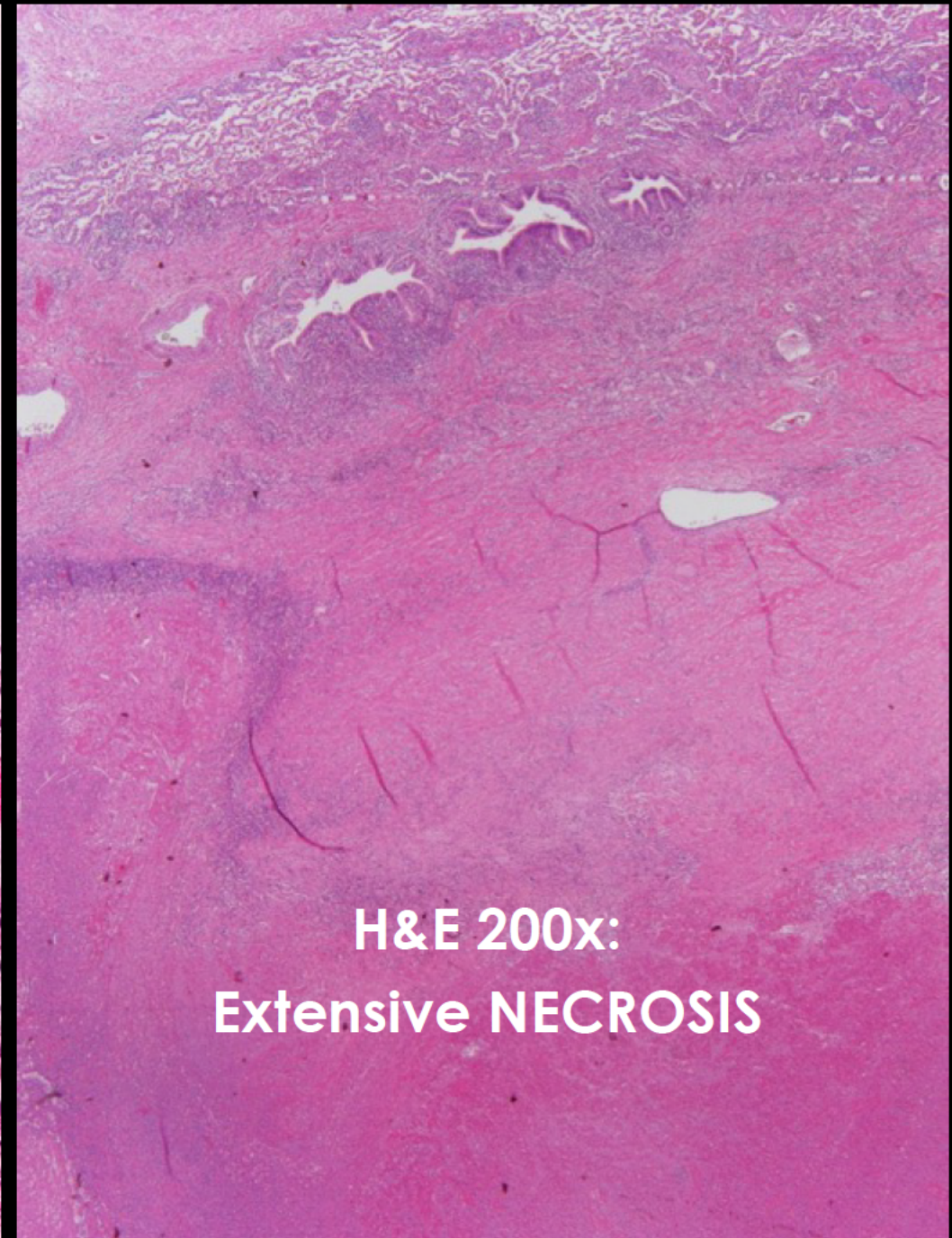




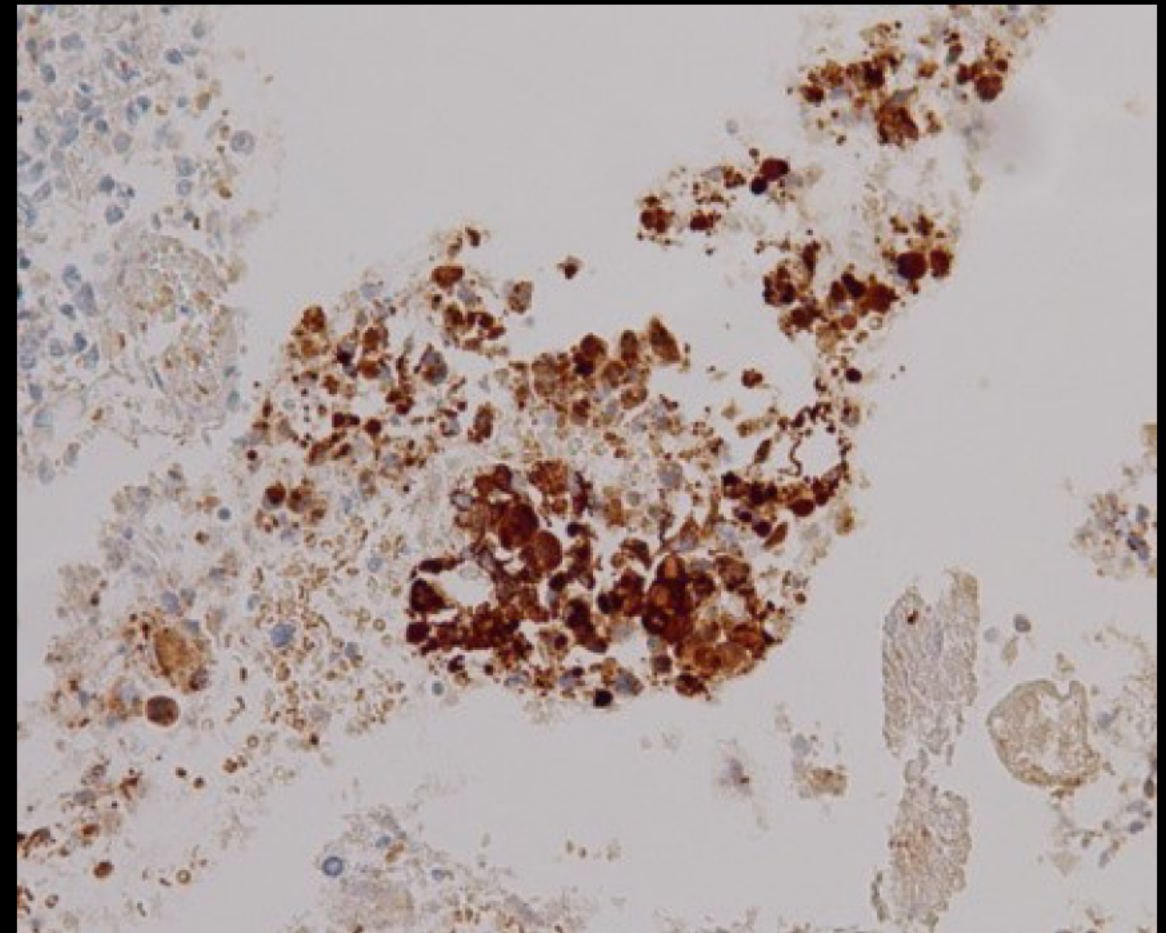
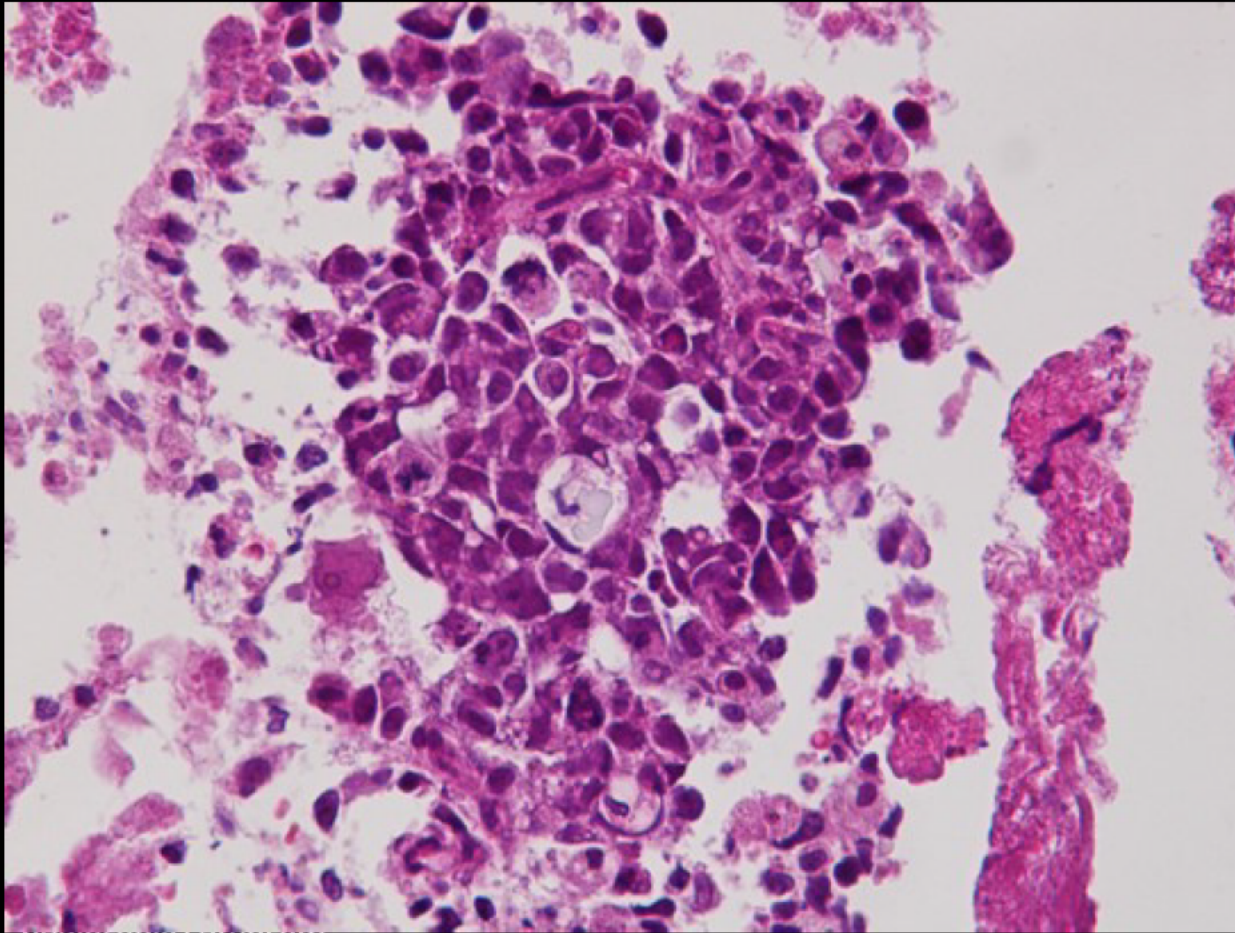
H&E 20x:
"Schiller Duval body"



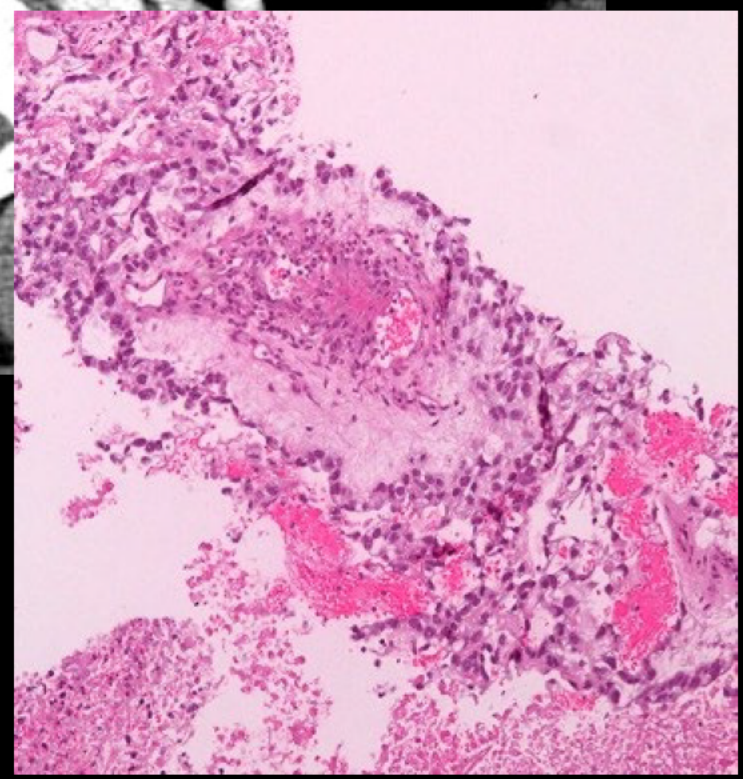
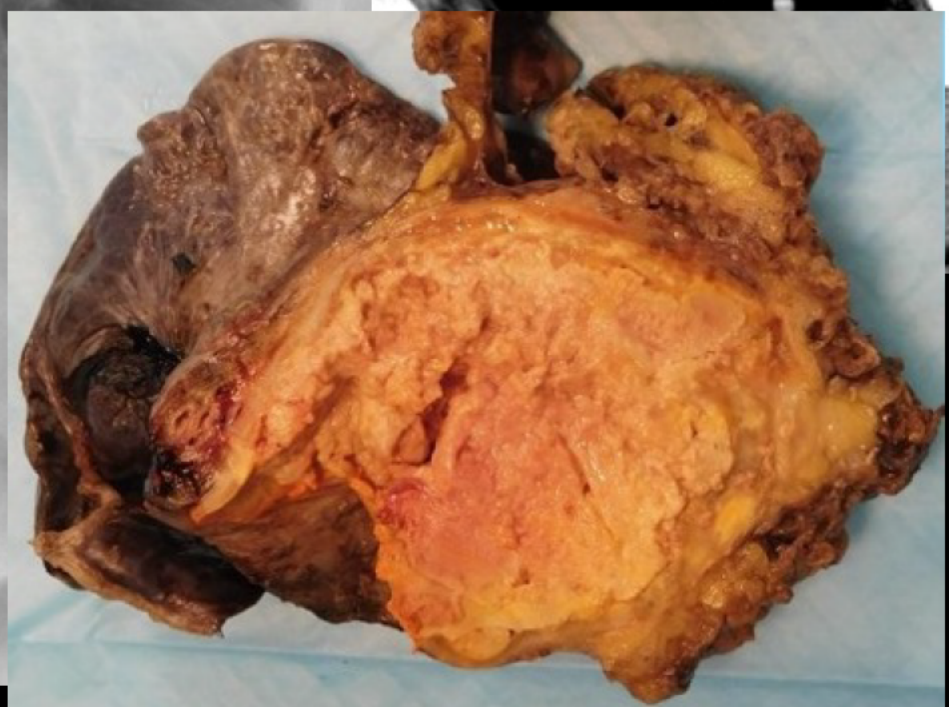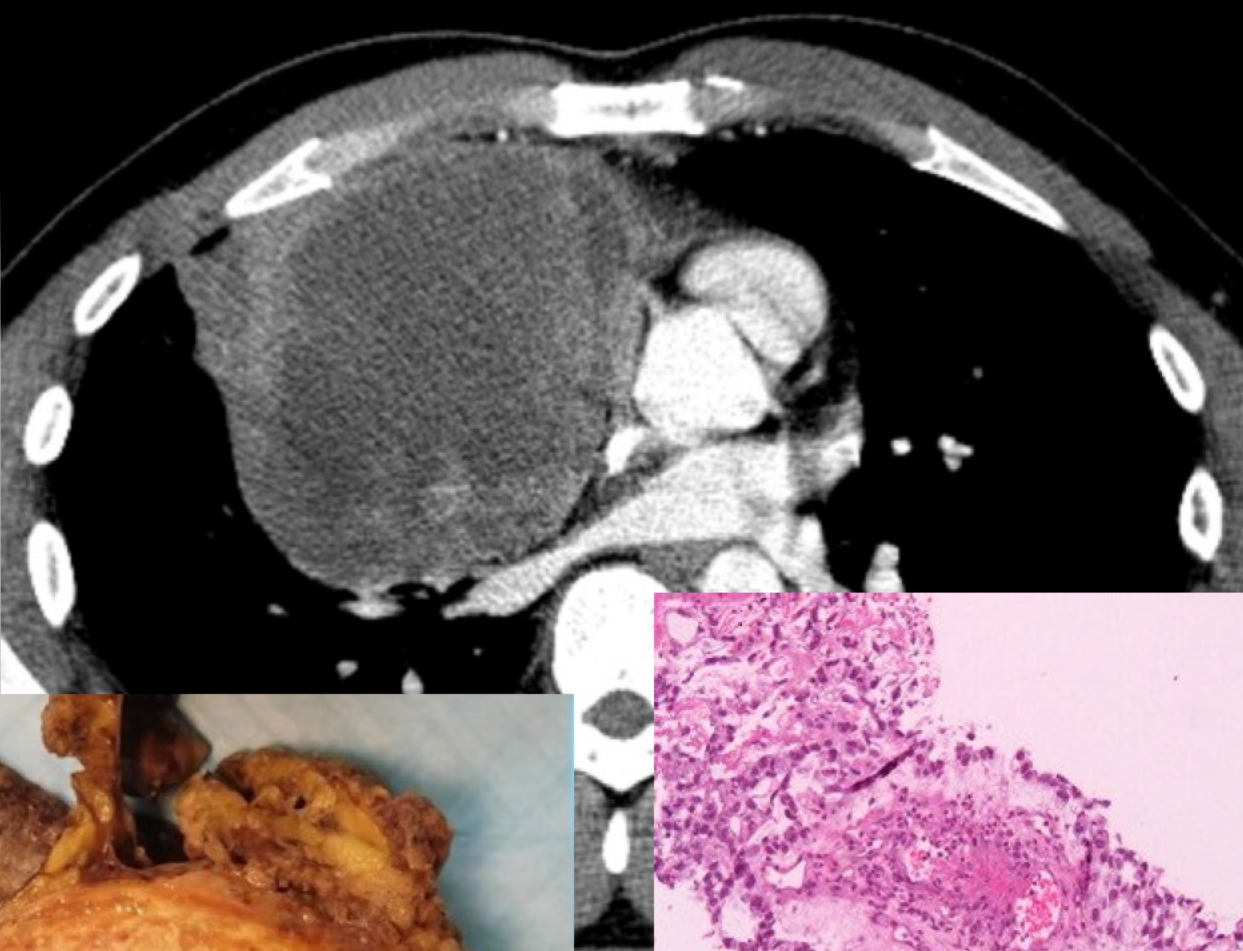
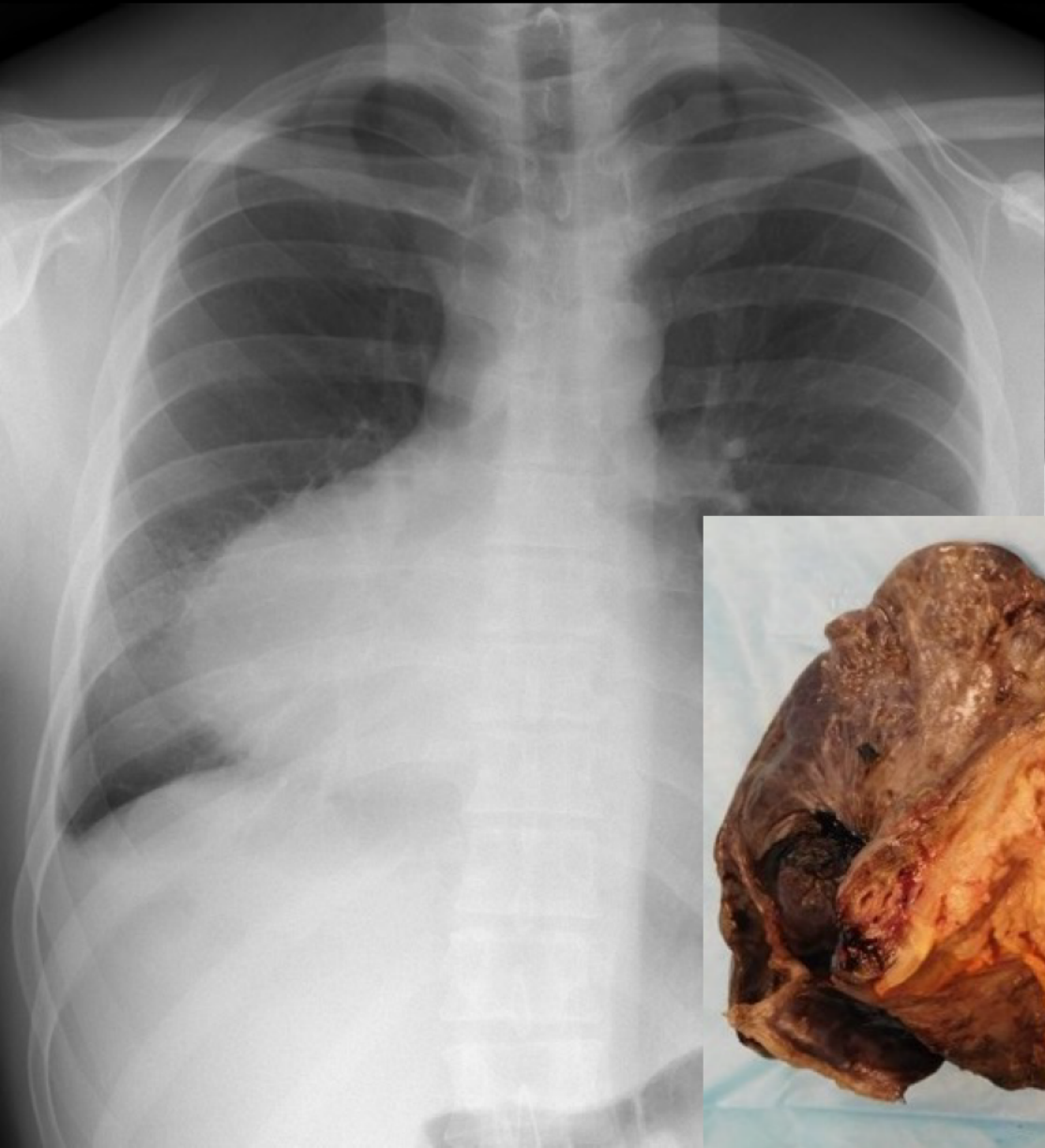H&E 200x:
Extensive NECROSIS



**H&E 400x:
Poorly differentiated GERM CELLS**



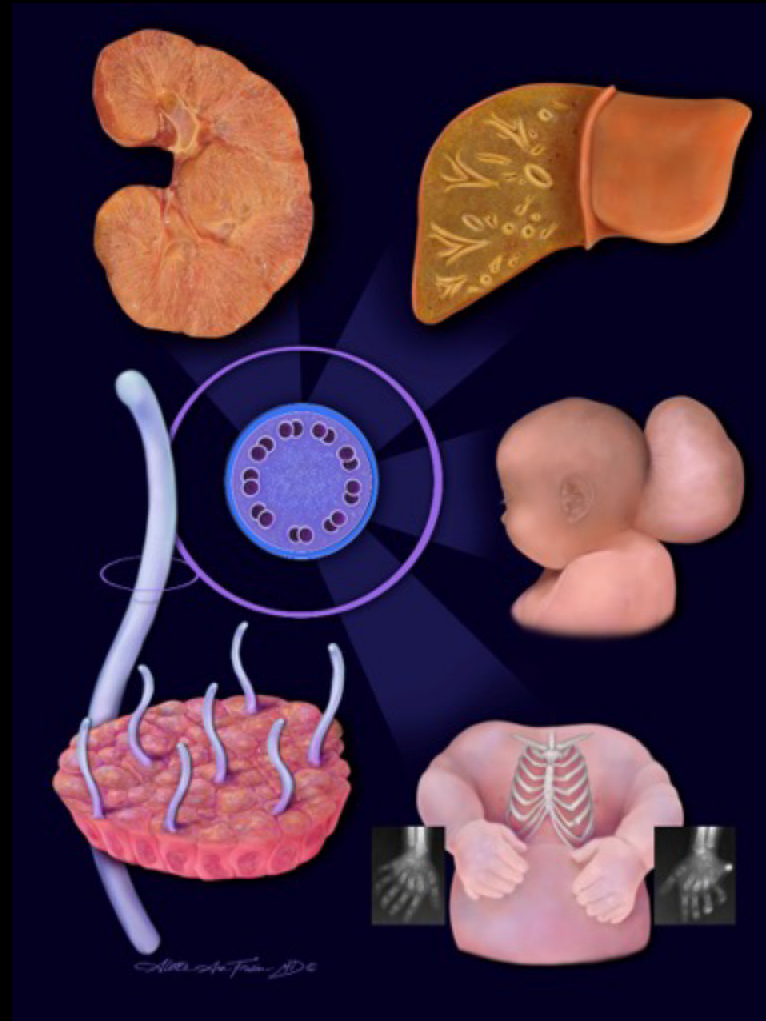
**AFP immunohistochemical stain 400x:
Positive uptake**



Yolk Sac Tumor (Post-pubertal Extragonal GCT)

**Dr. Stephen Veideman
Christiana Care Hospital
Newark, Delaware**

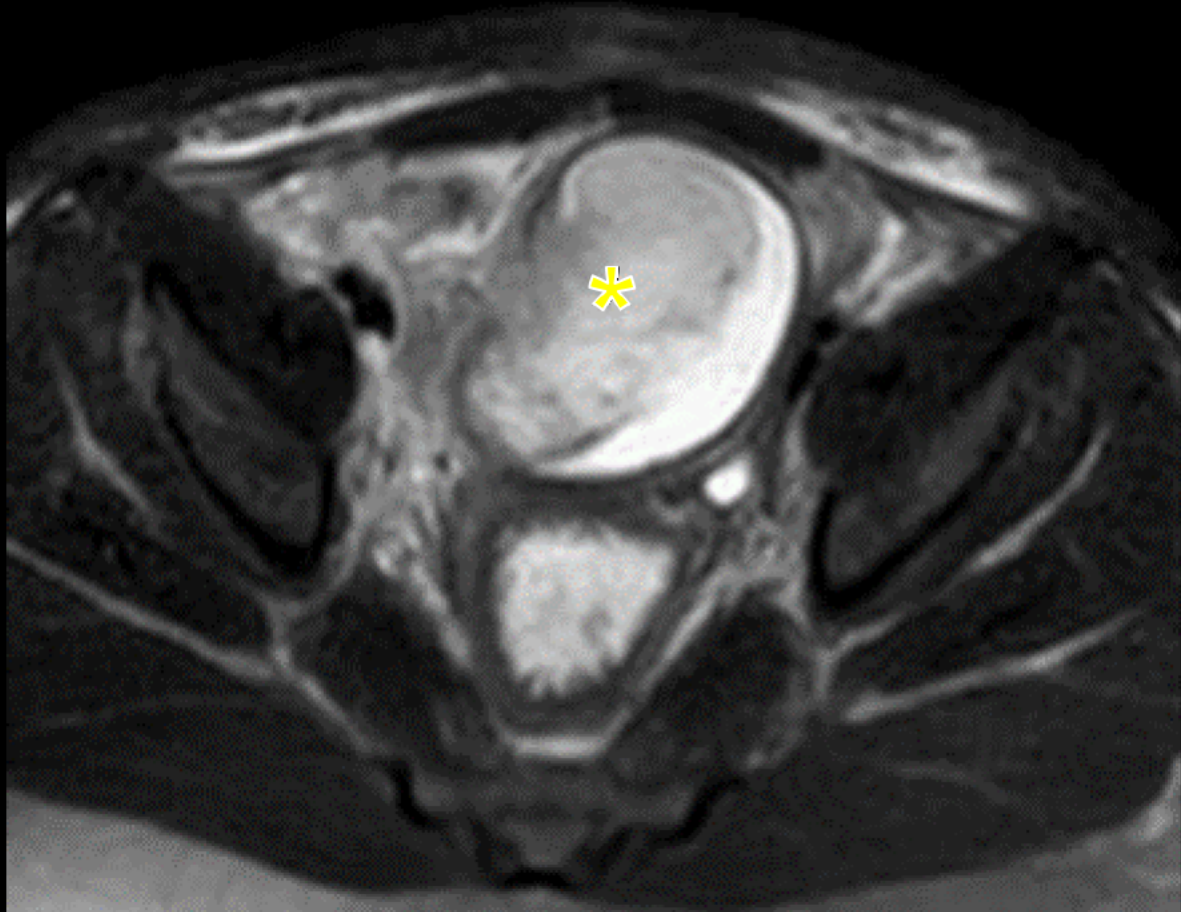
Pediatric Best Case



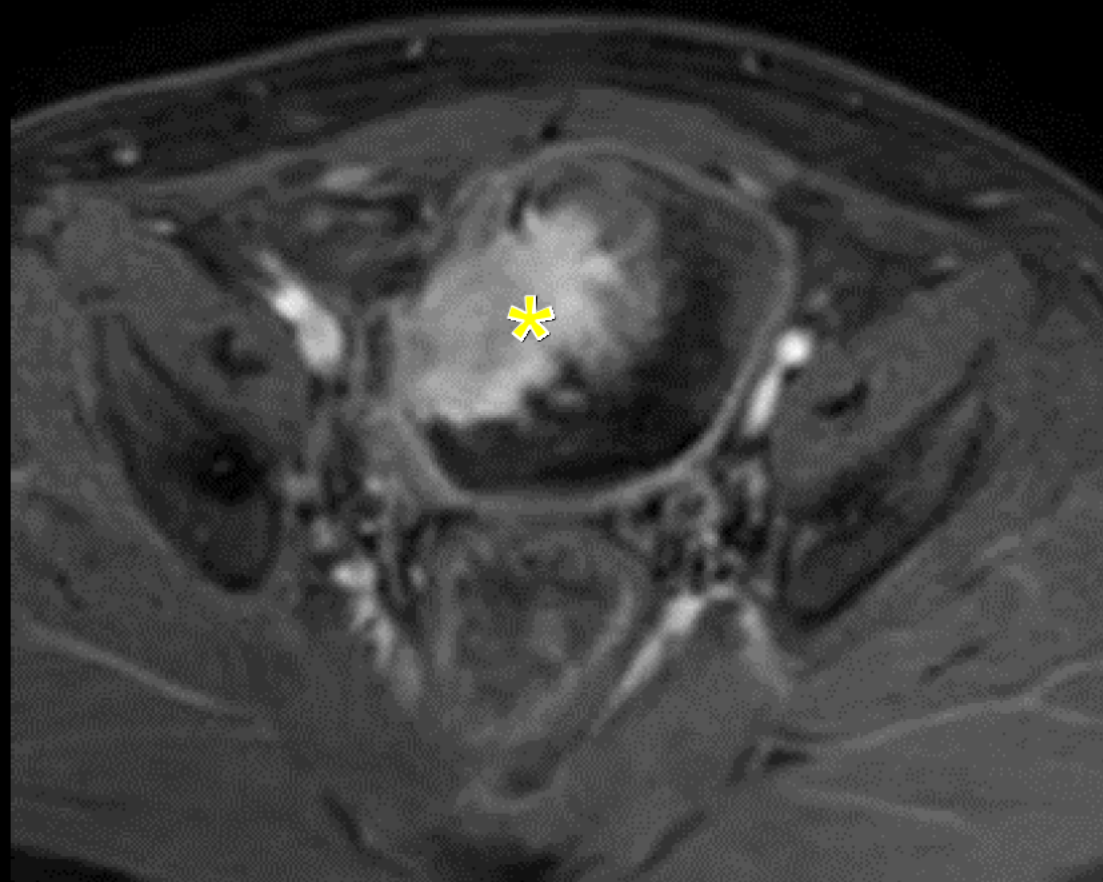
Clinical information

10-year-old male with history of constipation who presented with 1 week of hematuria.

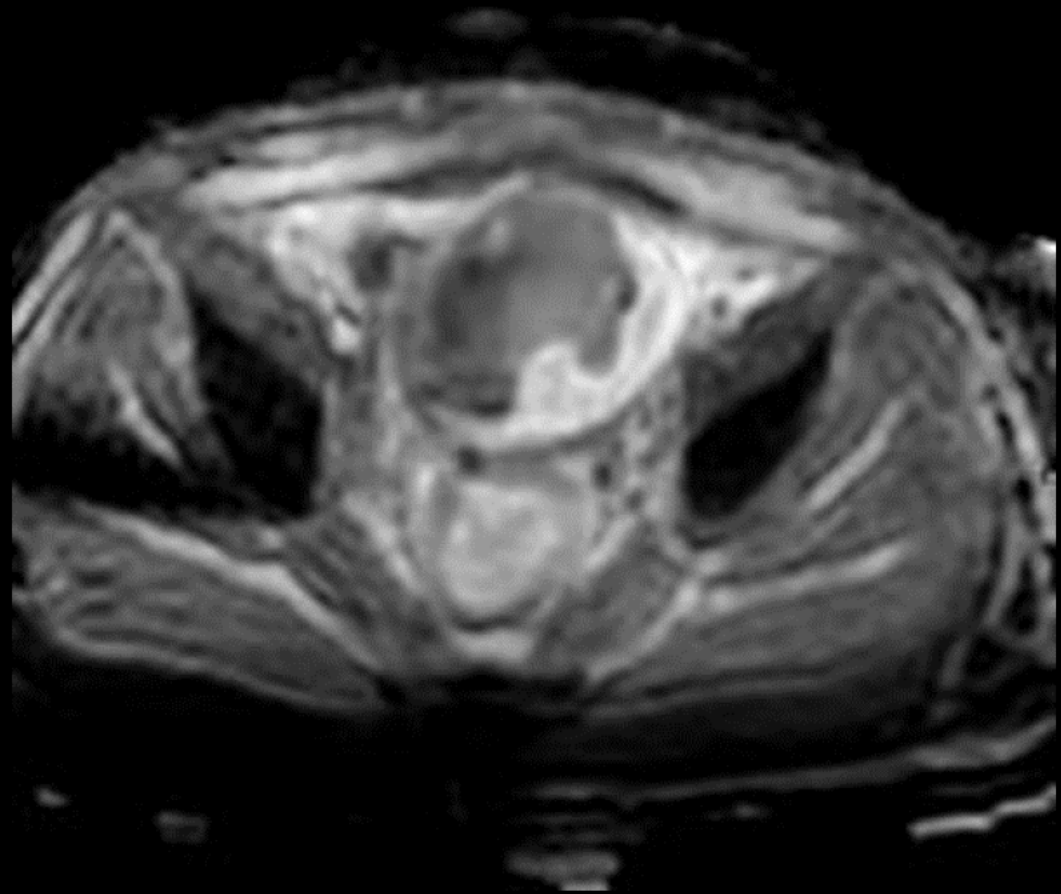
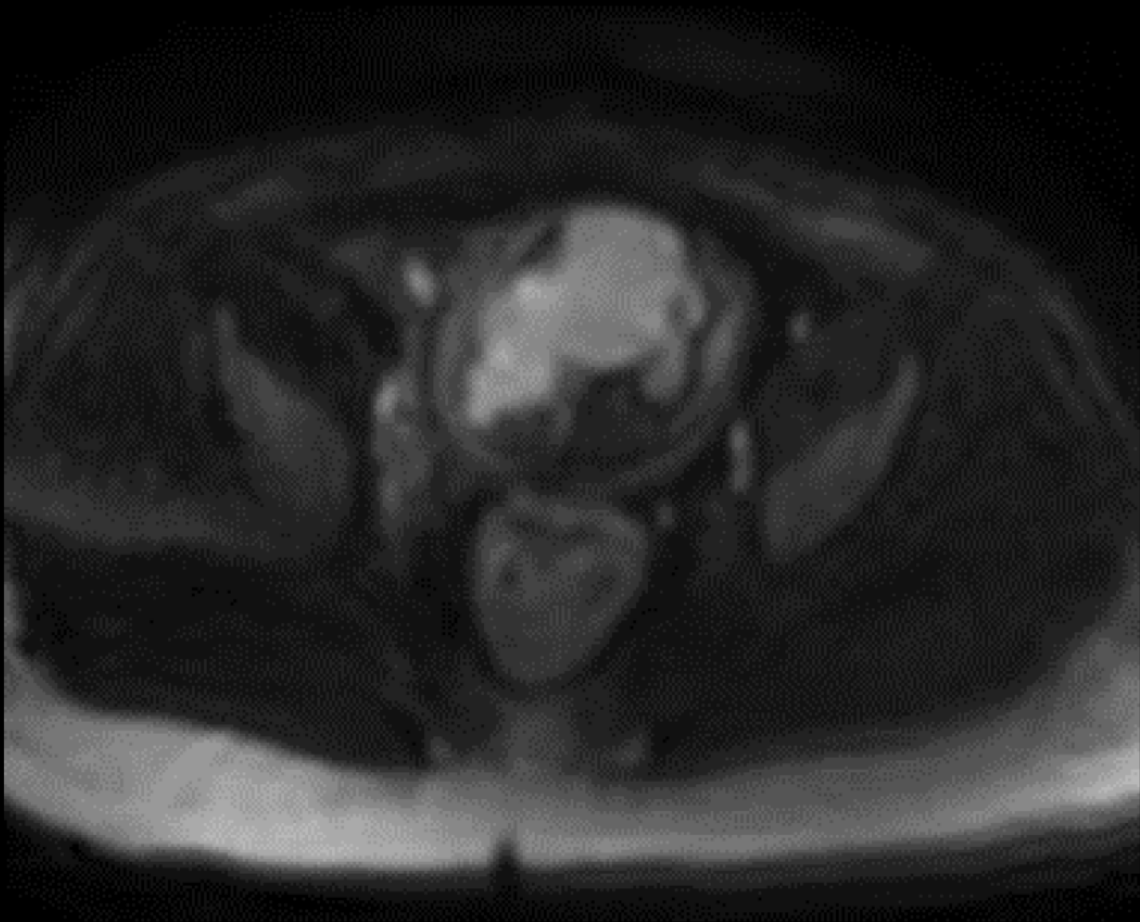
Following a limited ultrasound revealing a bladder mass, an MRI of the pelvis was performed.



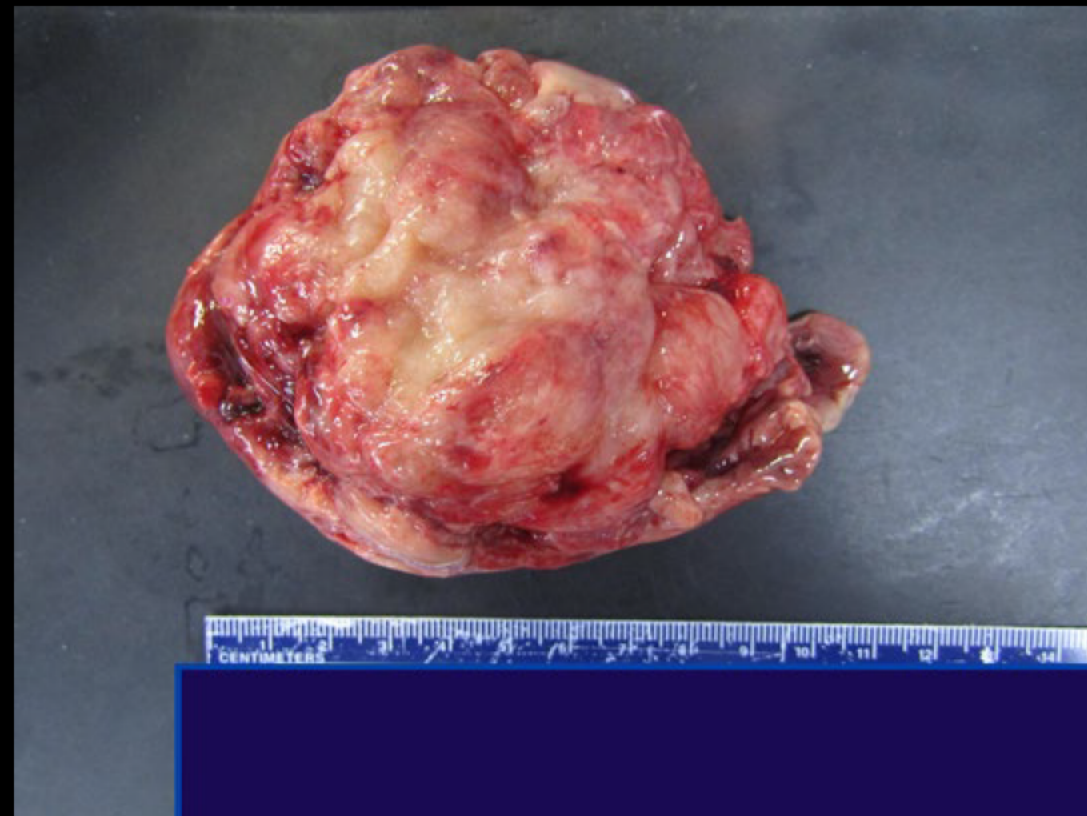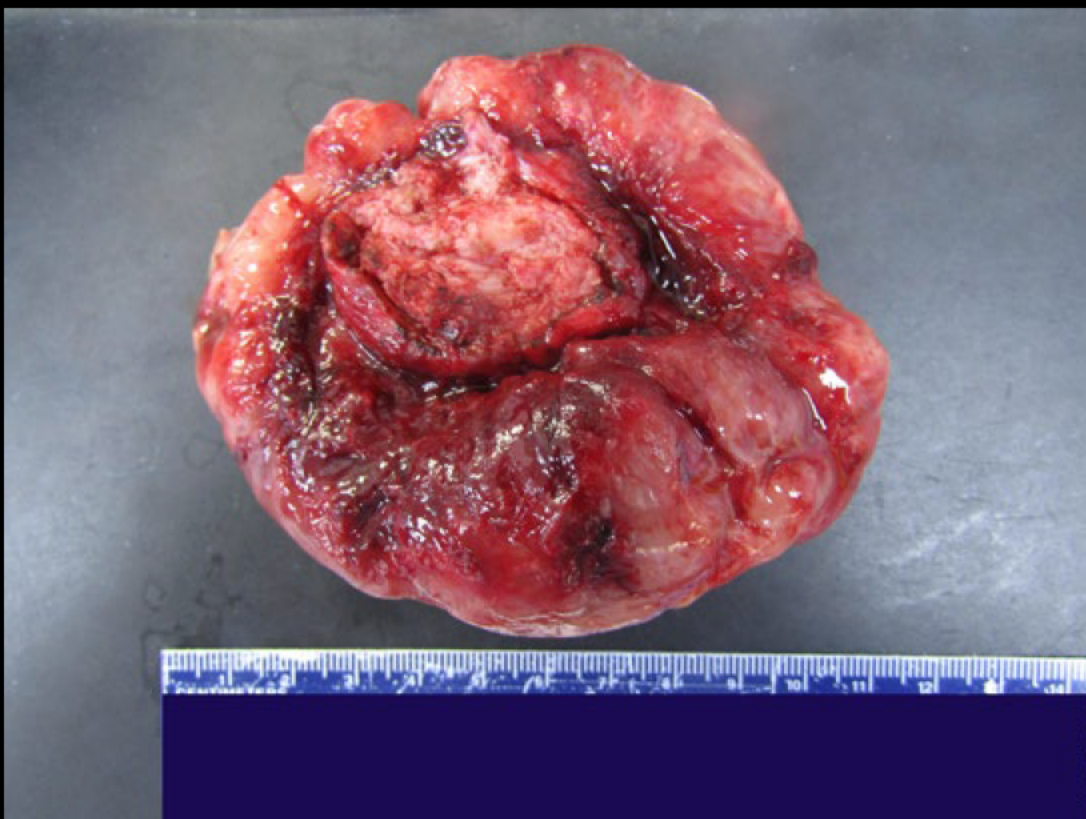T2 fat sat



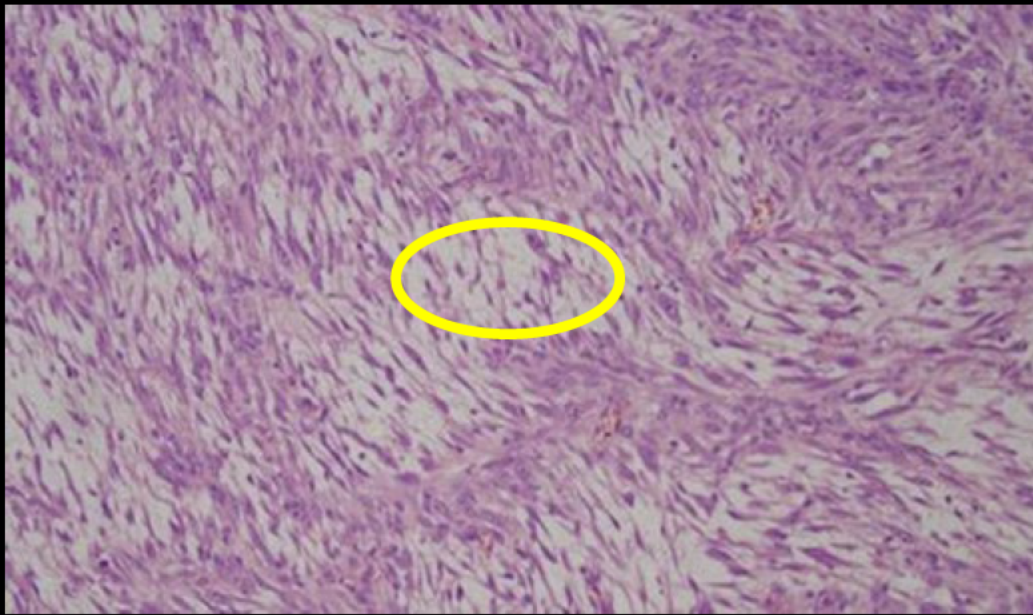T1 post contrast



DWI and ADC

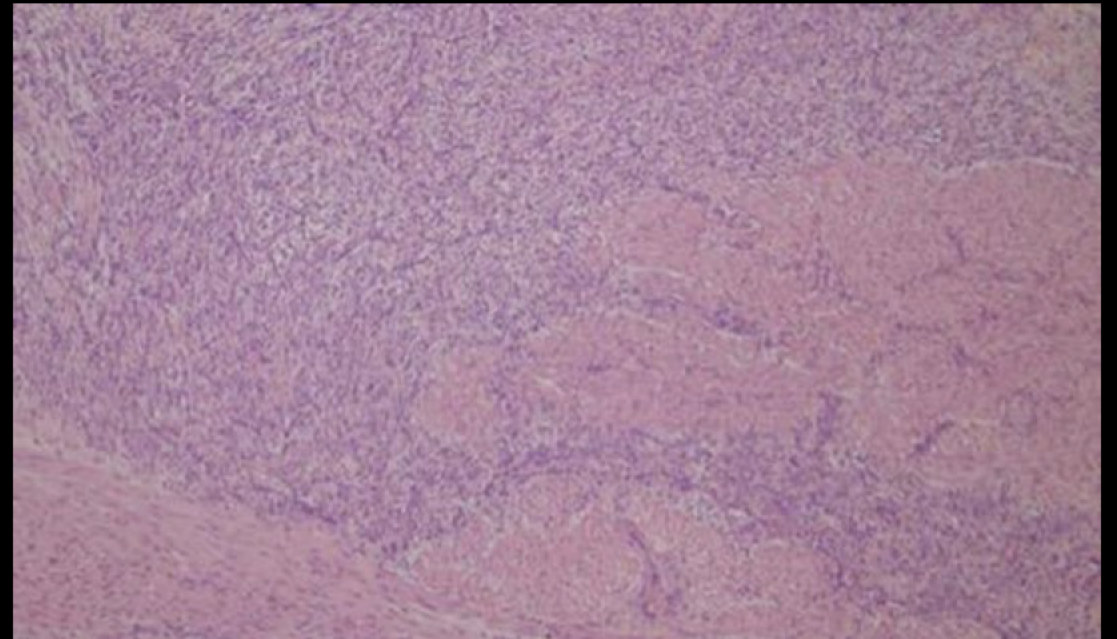


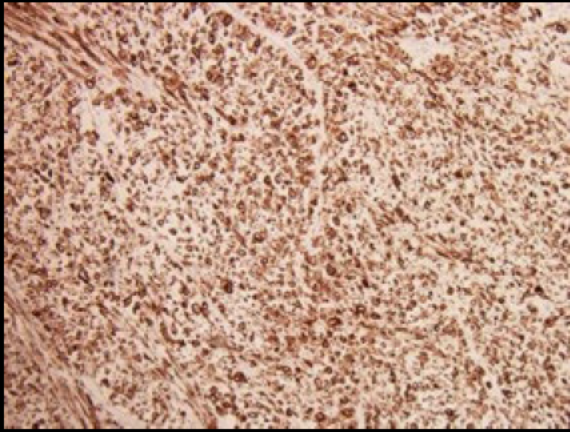
**Tan pink gelatinous well circumscribed
polypoid mass**



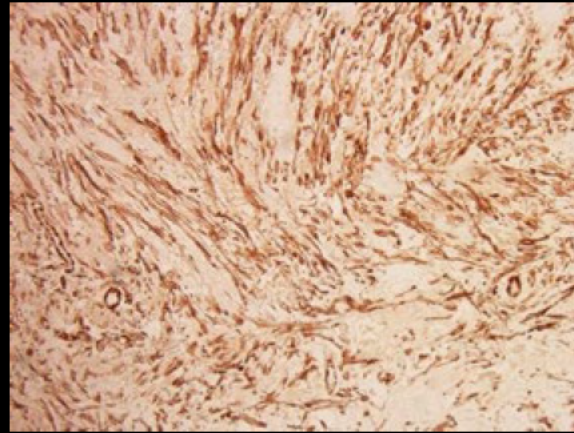
**Spindle cells within
loose myxoid
stroma**

**Infiltration of the
smooth muscle of
the bladder**

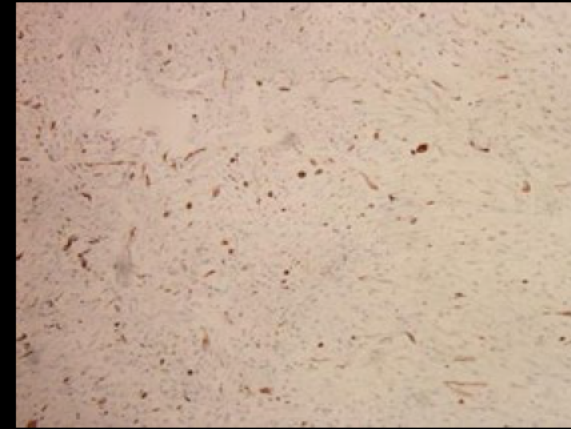




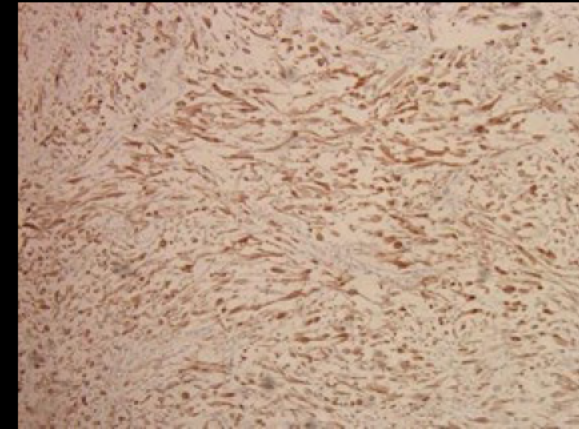
ALK-1



SMA



Desmin



**Cytokeratin
(AE1/AE3)**

**Immunohistochemical Stains
positive for ALK-1, SMA,
Desmin, and Cytokeratin**

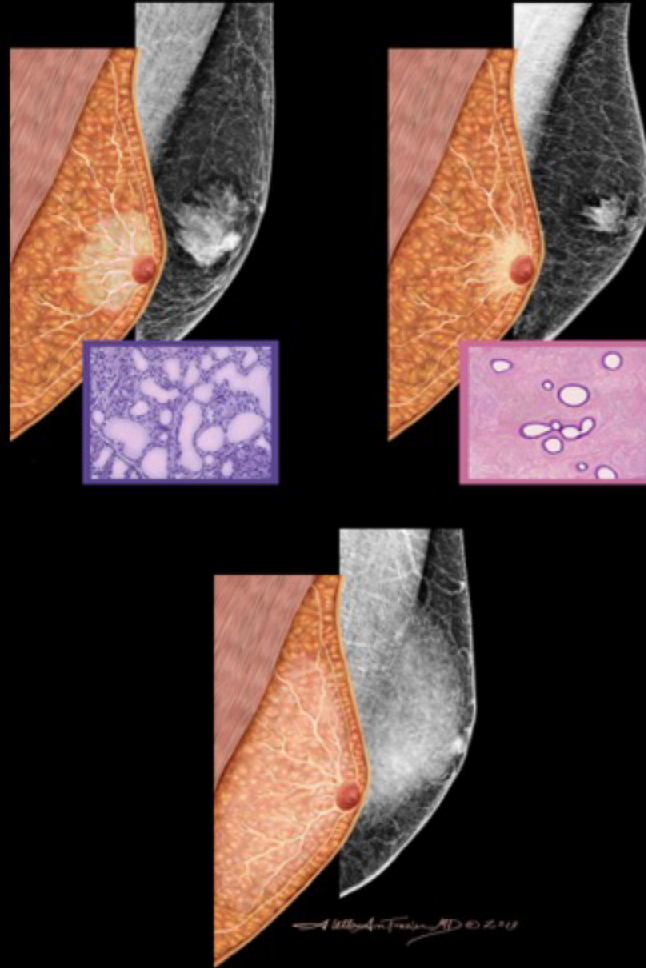
Inflammatory Myofibroblastic Tumor of the Bladder

Alexandra Reis

Montefiore Medical Center

Bronx, NY

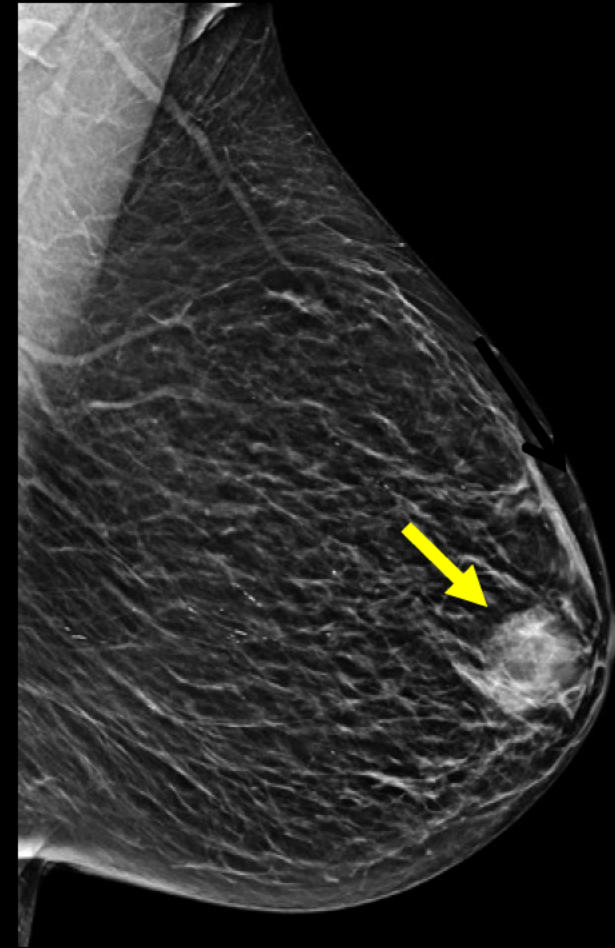
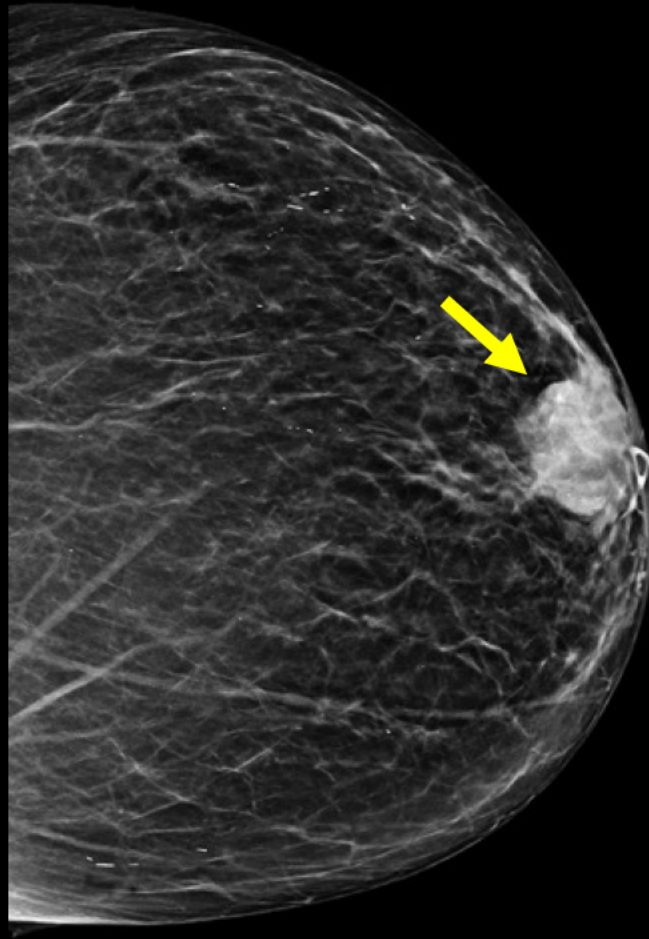
Breast Best Case



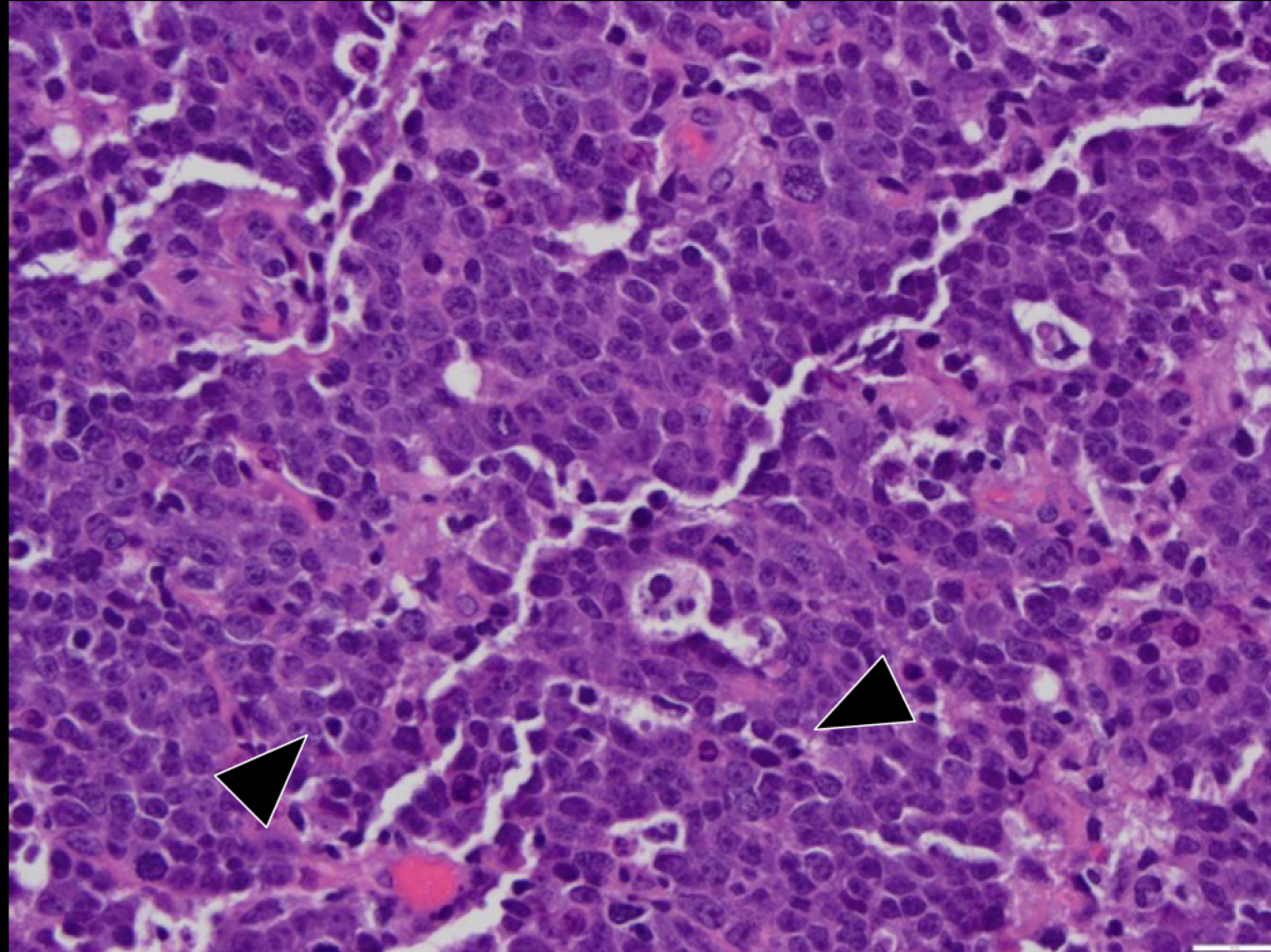
Clinical information

An 82-year-old woman noticed a lump in her left breast. She has long-standing history of rheumatoid arthritis treated with methotrexate and adalimumab.

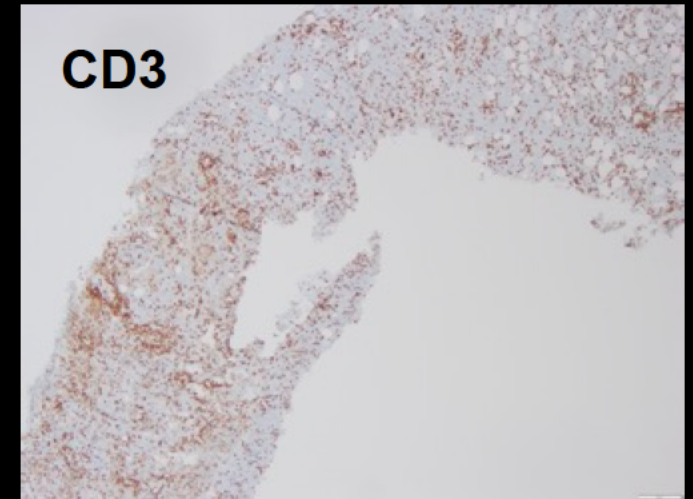
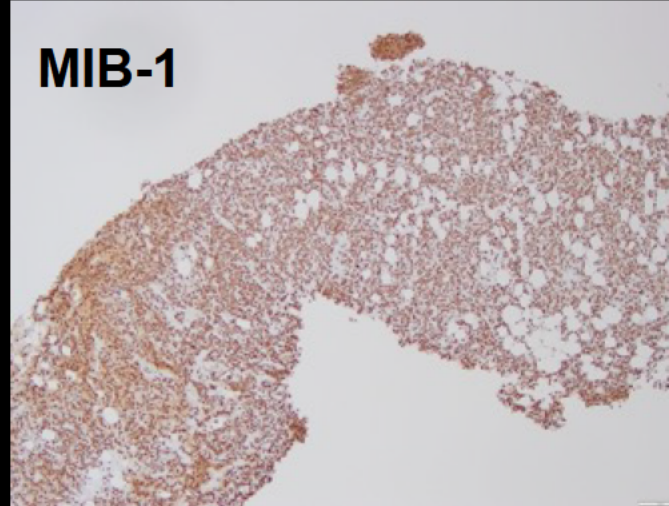
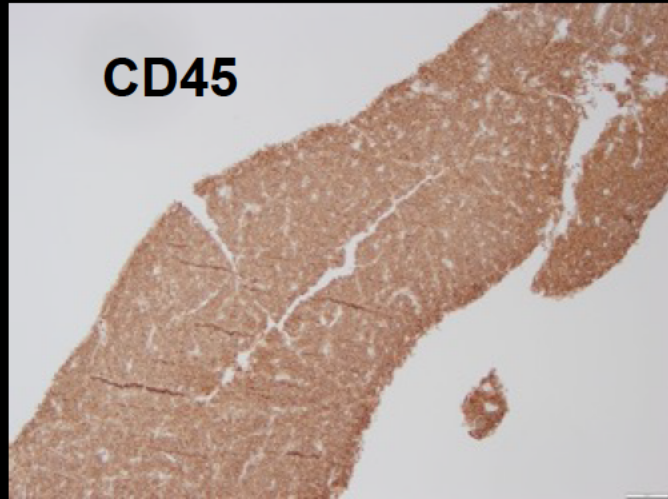
Diagnostic Left Mammogram



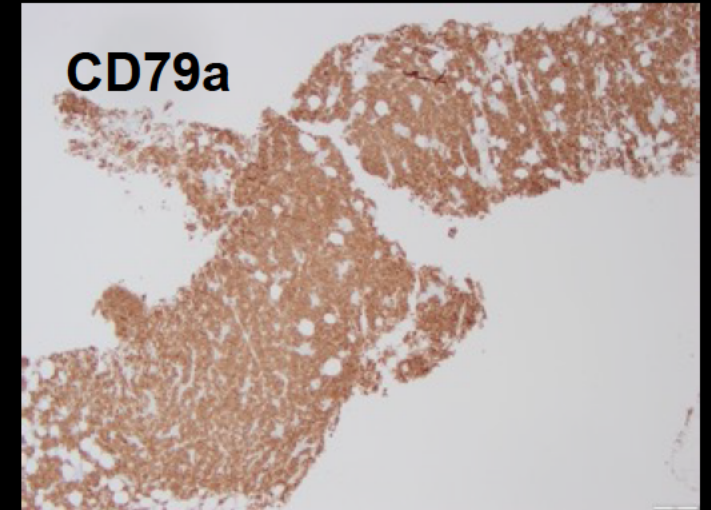
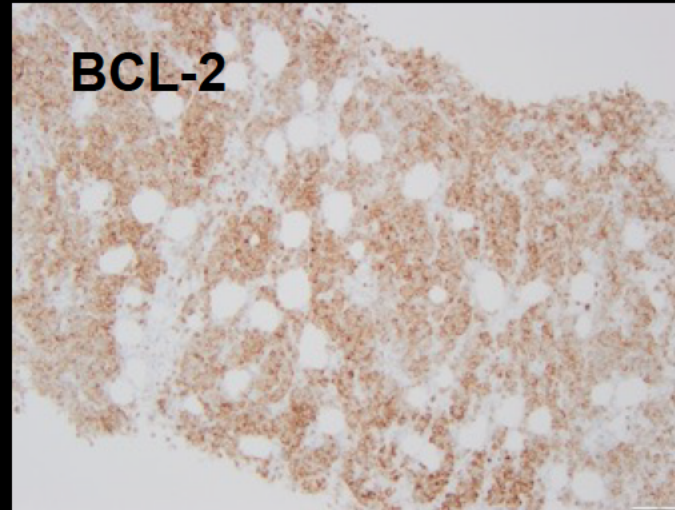
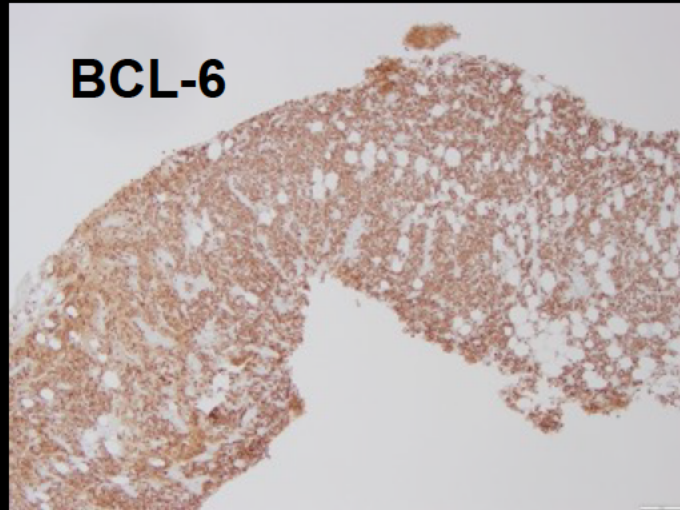
Histology



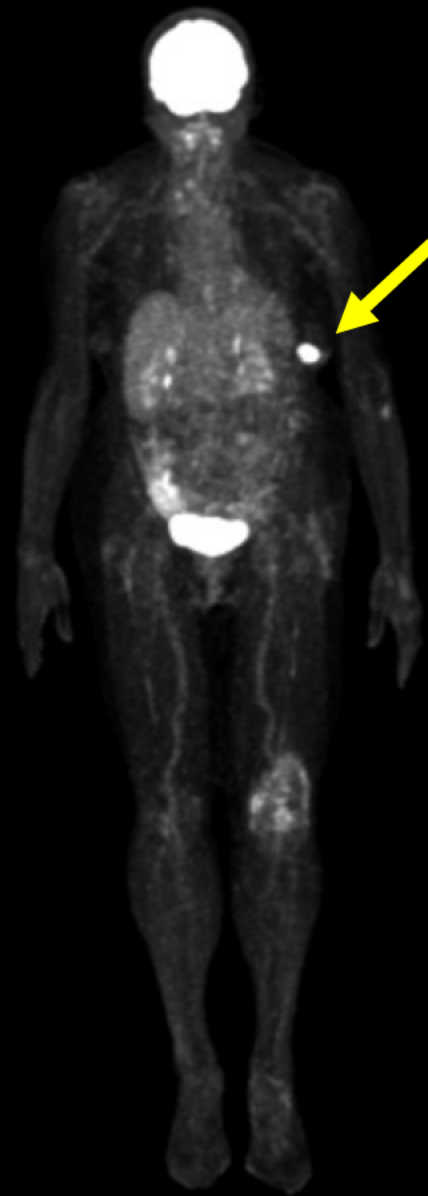
Immunohistochemistry



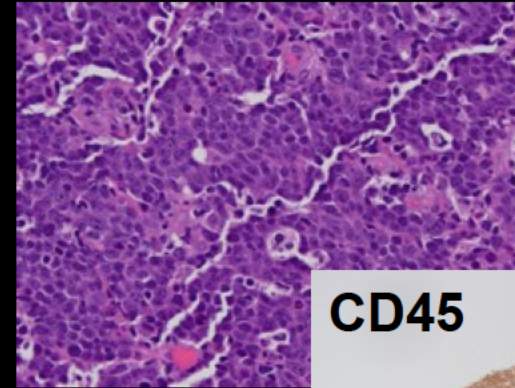
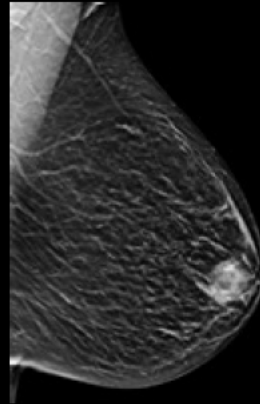
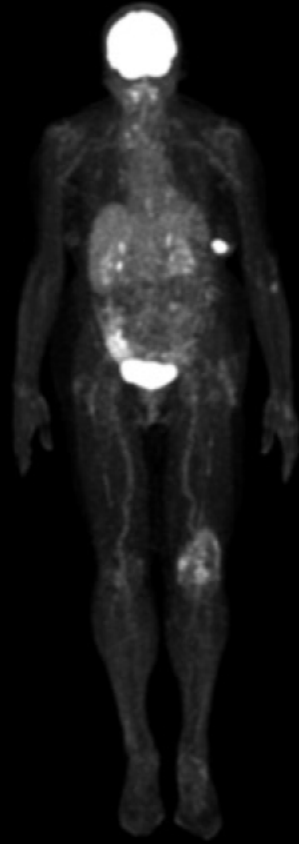
Immunohistochemistry



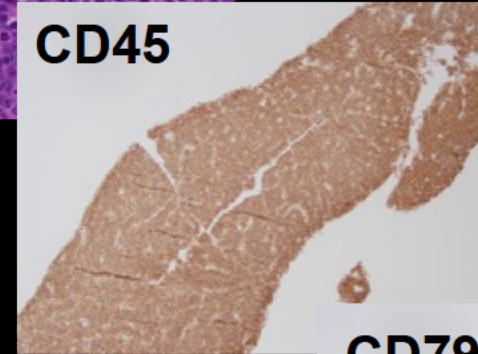
Staging PET



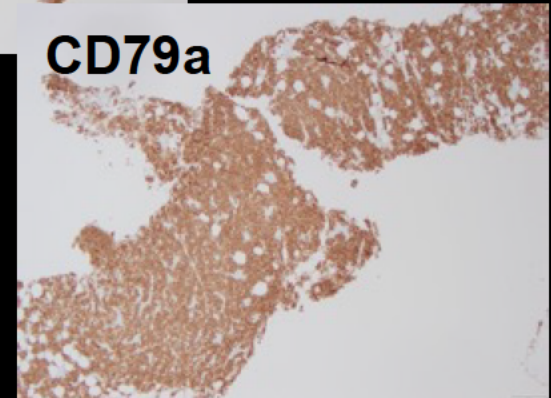
Rad-Path Correlation



CD45



CD79a



Primary B-cell Lymphoma of the Breast

Jing Chen, MD

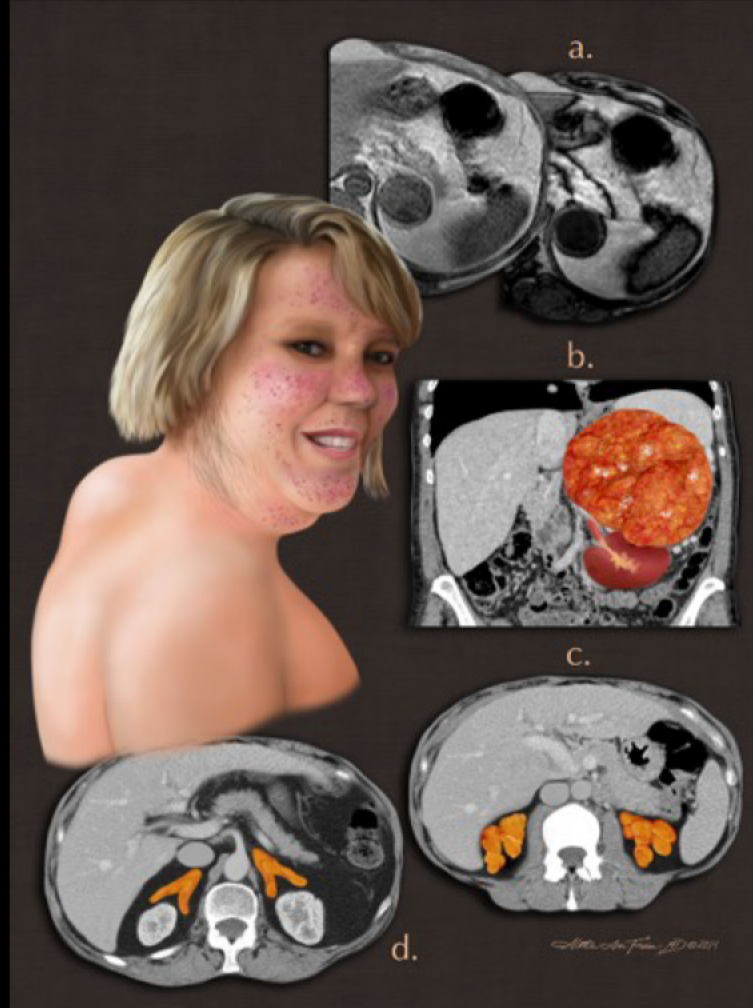Penn State Hershey Medical Center

Hershey, PA



ACR INSTITUTE FOR
RADIOLOGIC PATHOLOGY

Genitourinary Best Case



Clinical information

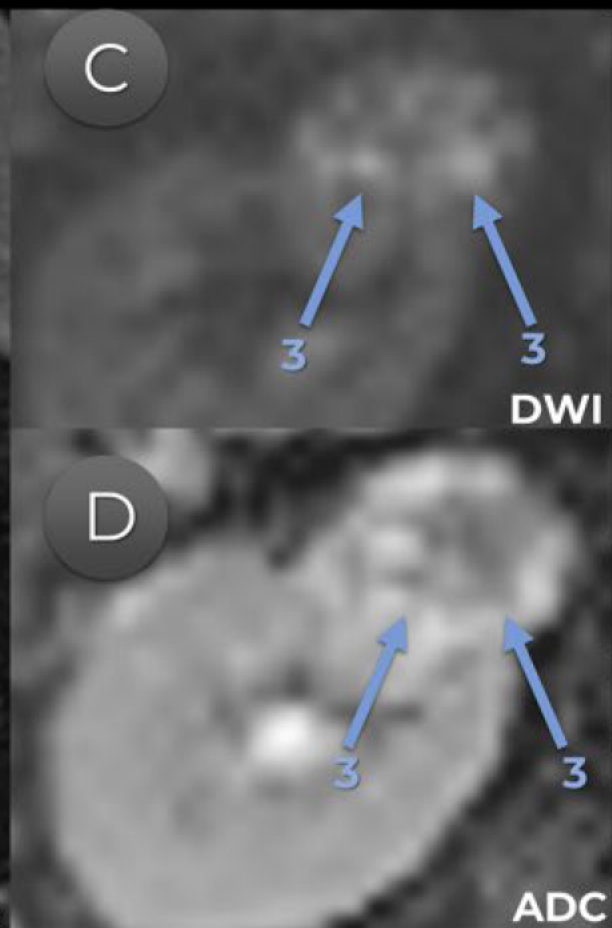
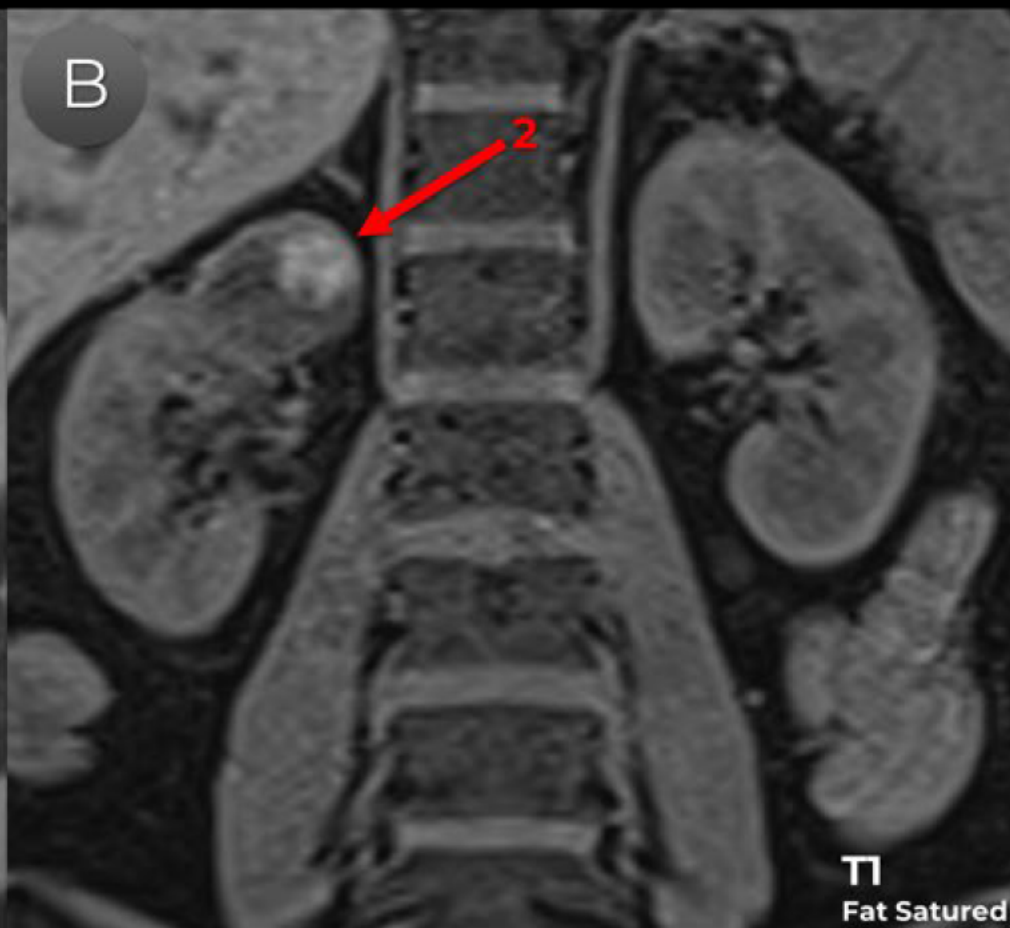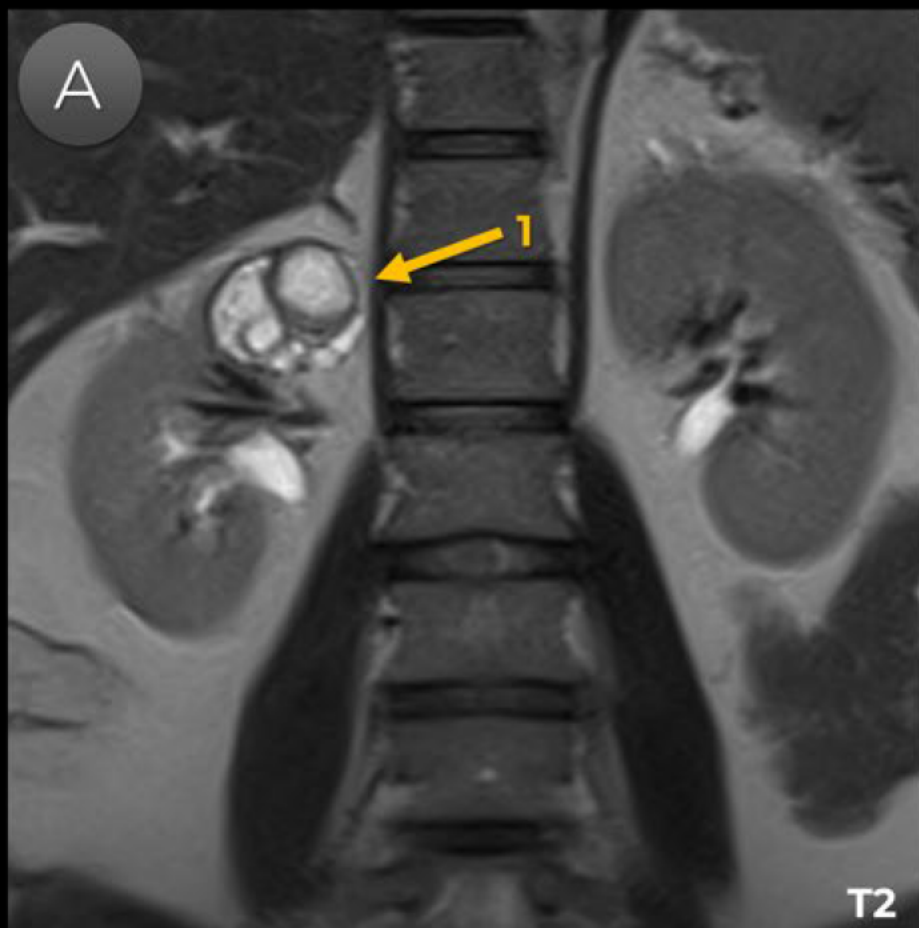A previously healthy 39-yo male who presented with clinical worsening on 10th day of Covid-19 symptoms, with no abdominal complaints.

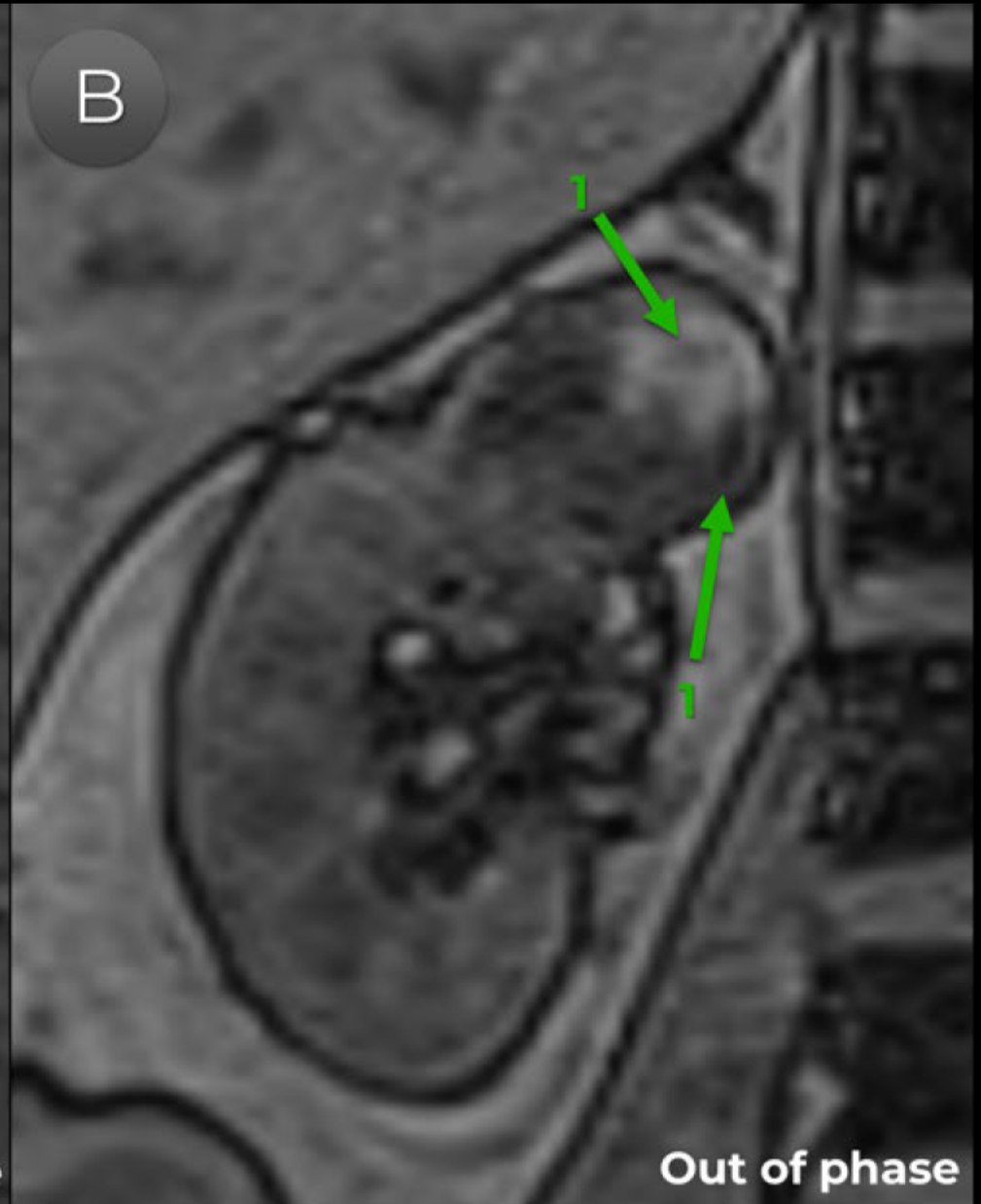
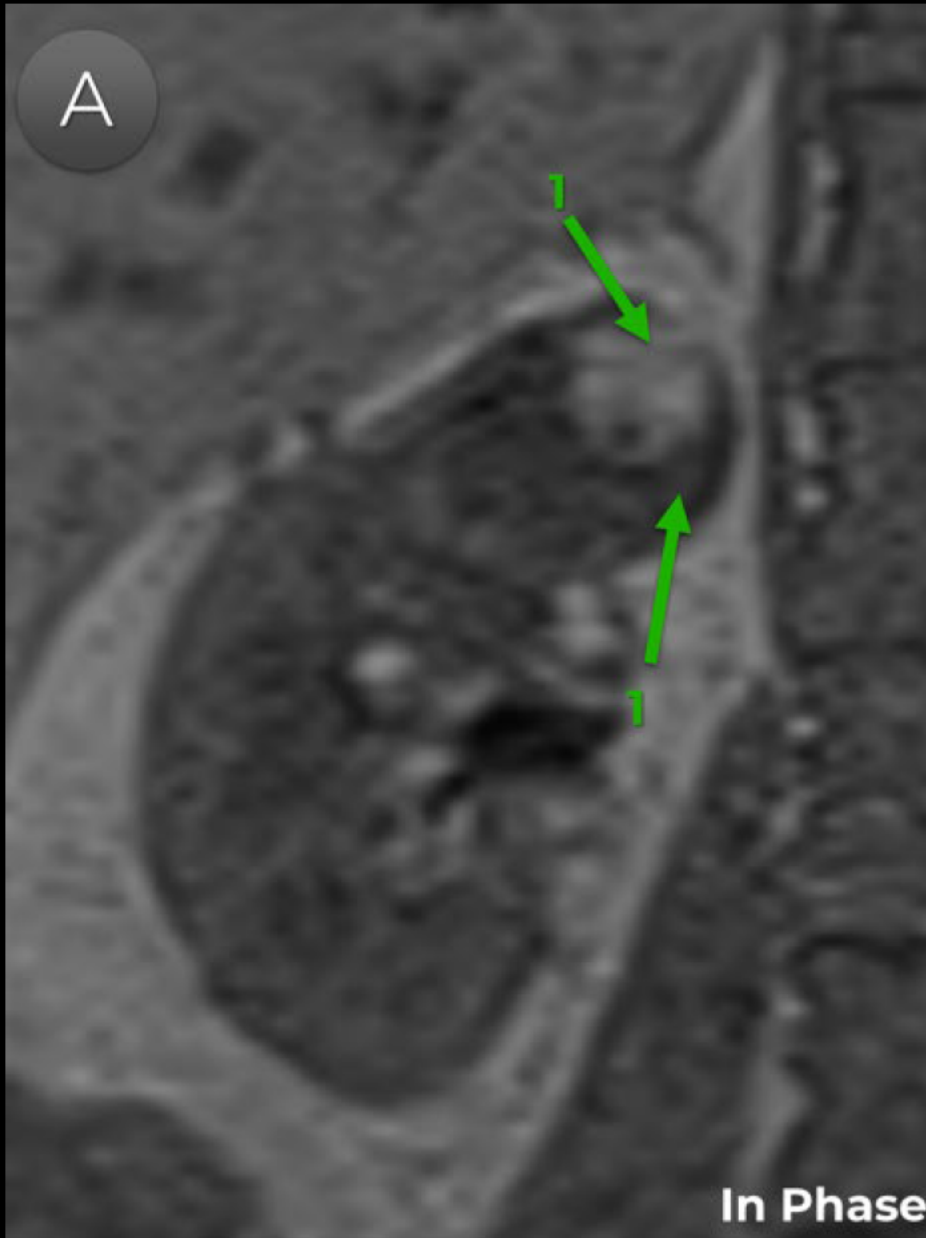
A Chest CT was performed and a lesion in the right kidney was identified in the superior abdominal images.



AMERICAN INSTITUTE FOR
RADIOLOGIC PATHOLOGY

A PROGRAM OF THE
AMERICAN COLLEGE OF RADIOLOGY

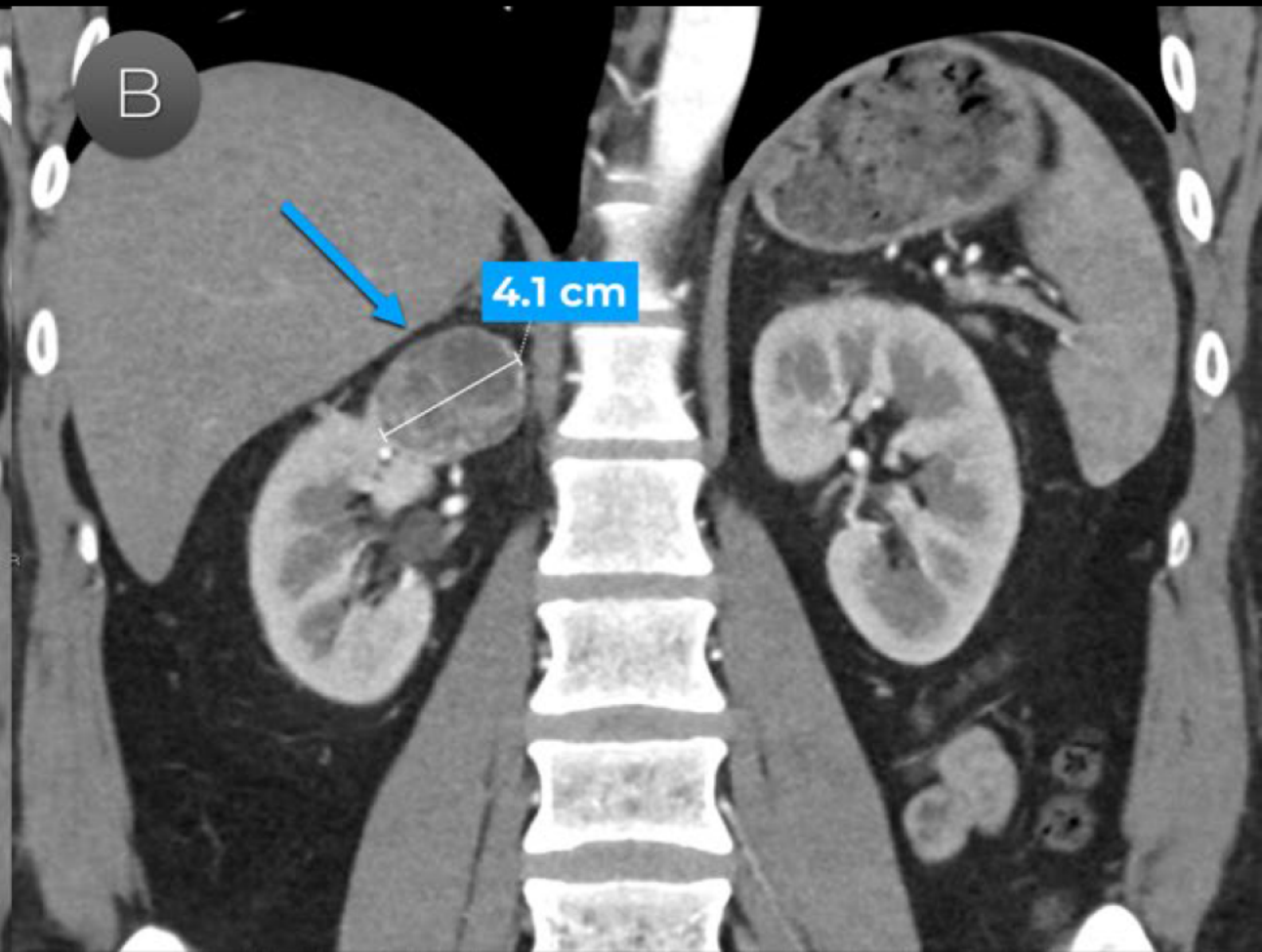
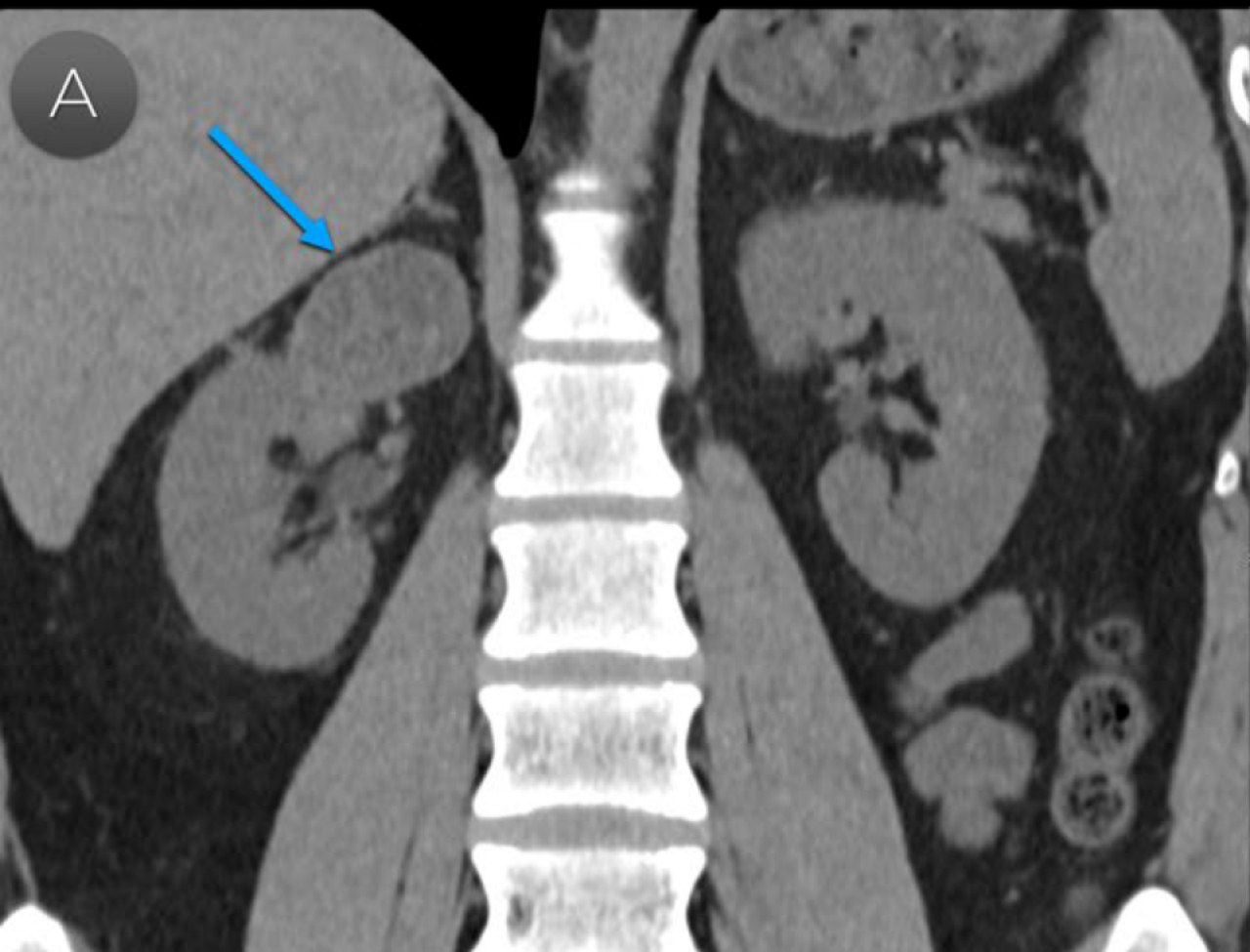




AIRPTM

AMERICAN INSTITUTE FOR
RADIOLOGIC PATHOLOGY

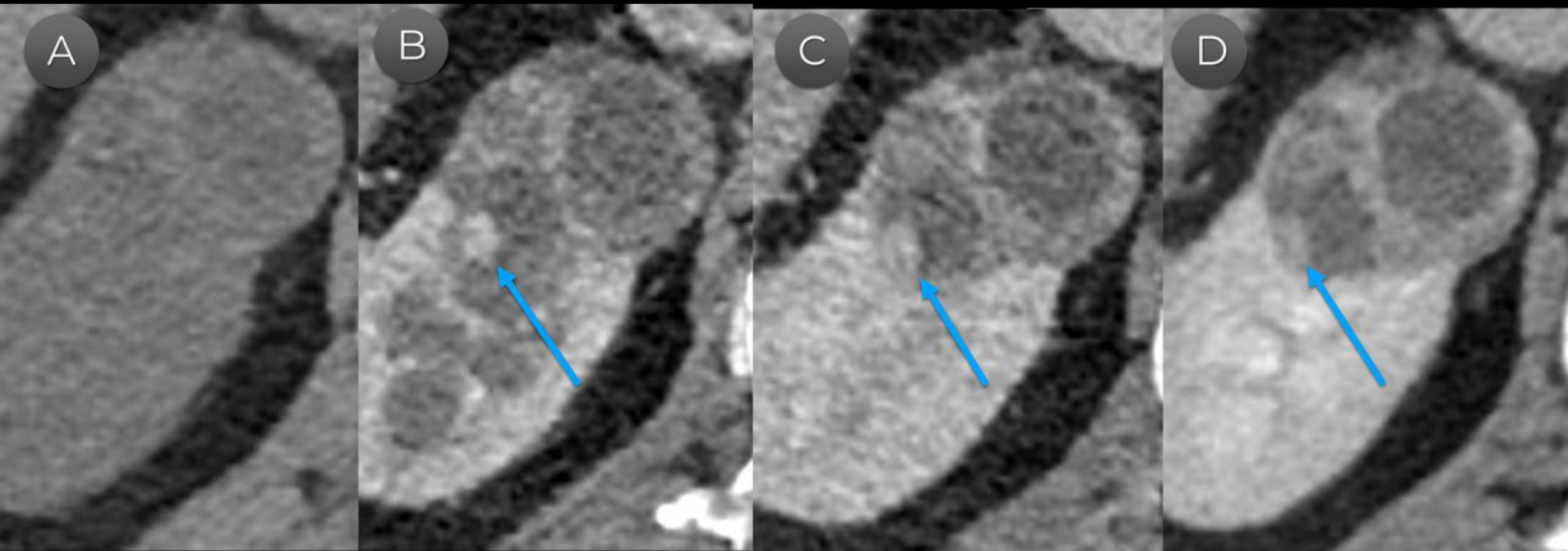
A PROGRAM OF THE
AMERICAN COLLEGE OF RADIOLOGY



AIRPTM

AMERICAN INSTITUTE FOR
RADIOLOGIC PATHOLOGY

A PROGRAM OF THE
AMERICAN COLLEGE OF RADIOLOGY

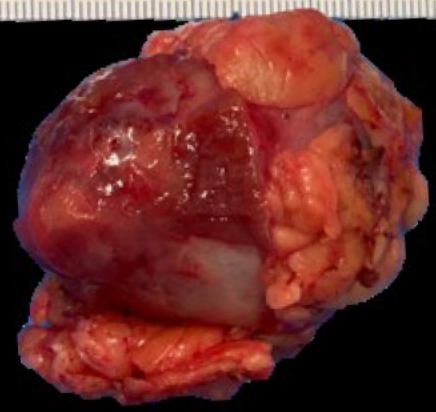


AIRPTM

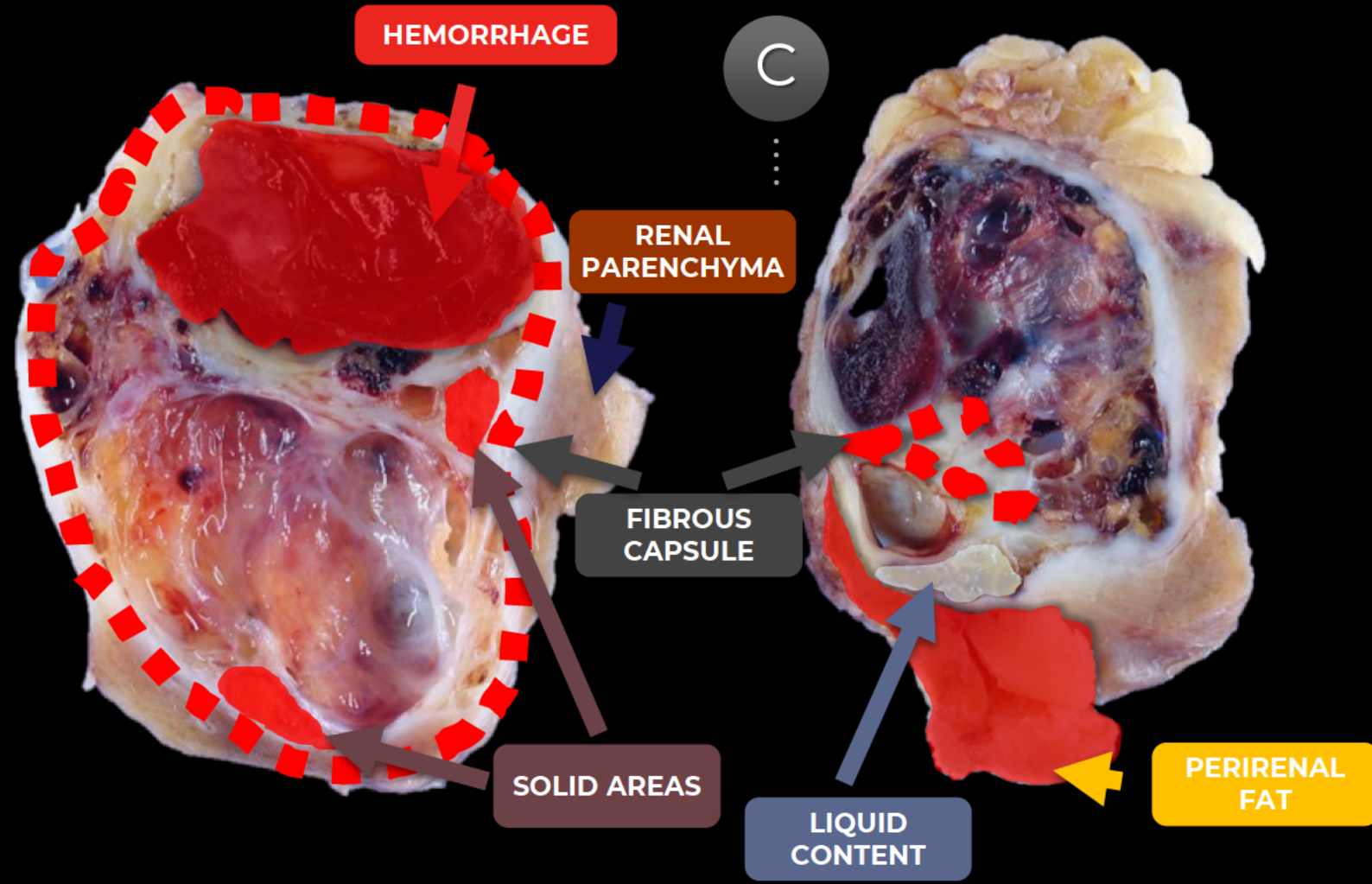
AMERICAN INSTITUTE FOR
RADIOLOGIC PATHOLOGY

A PROGRAM OF THE
AMERICAN COLLEGE OF RADIOLOGY

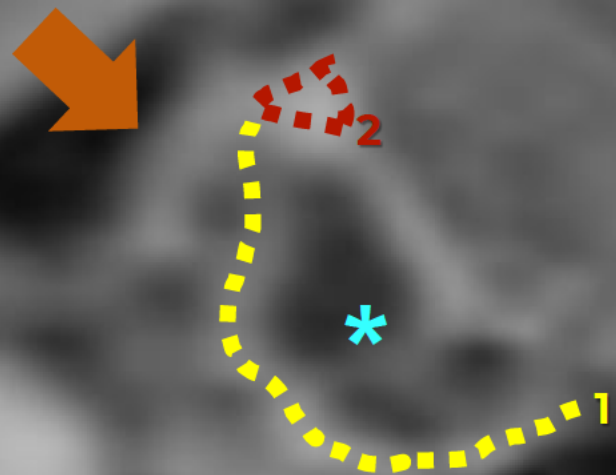
A



B

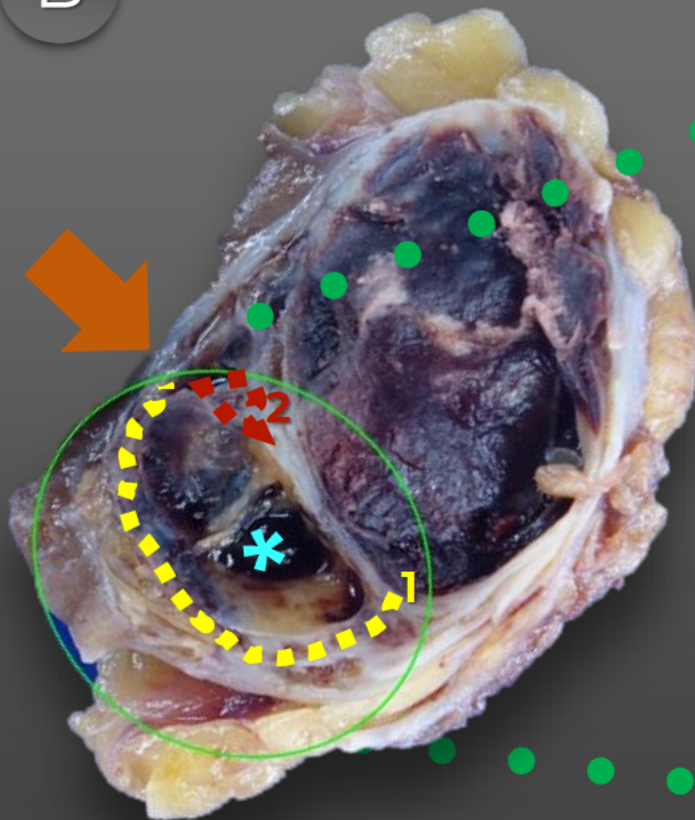


A

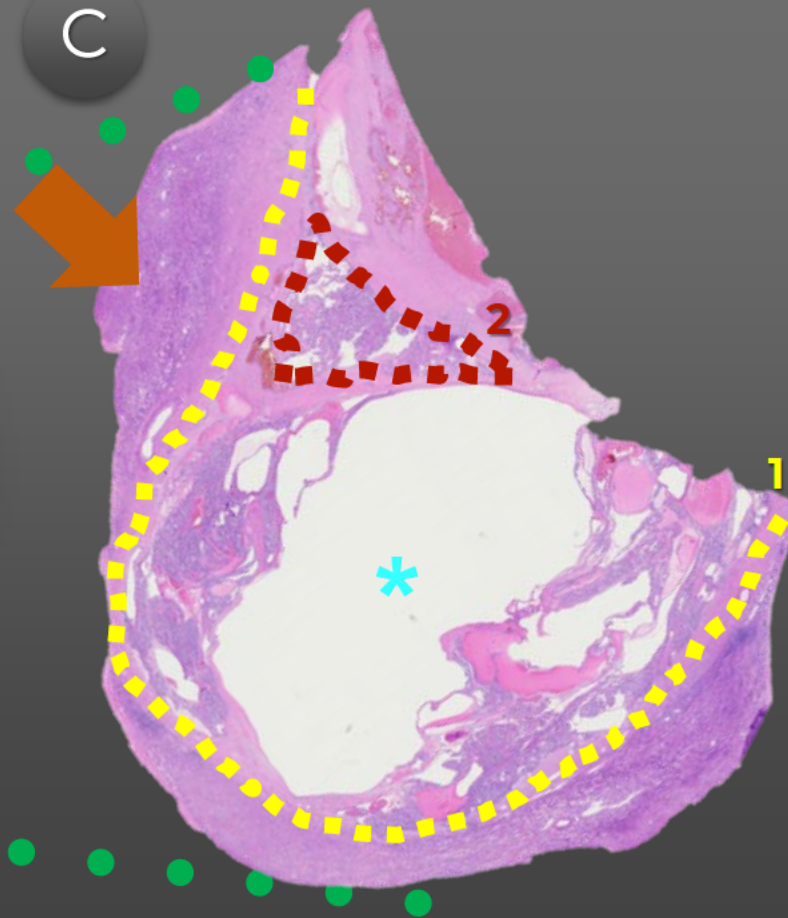


Π
Fat Saturated

B



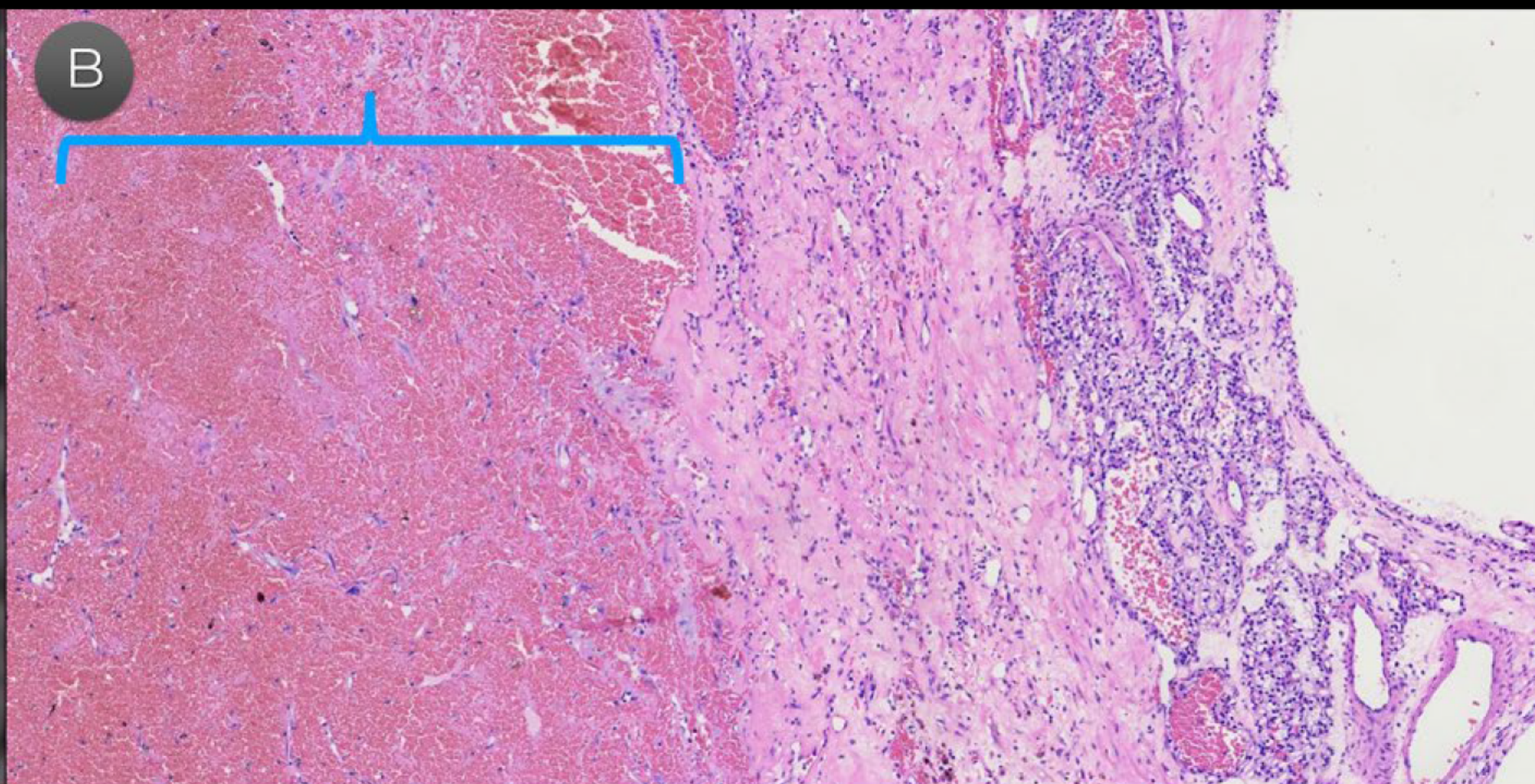
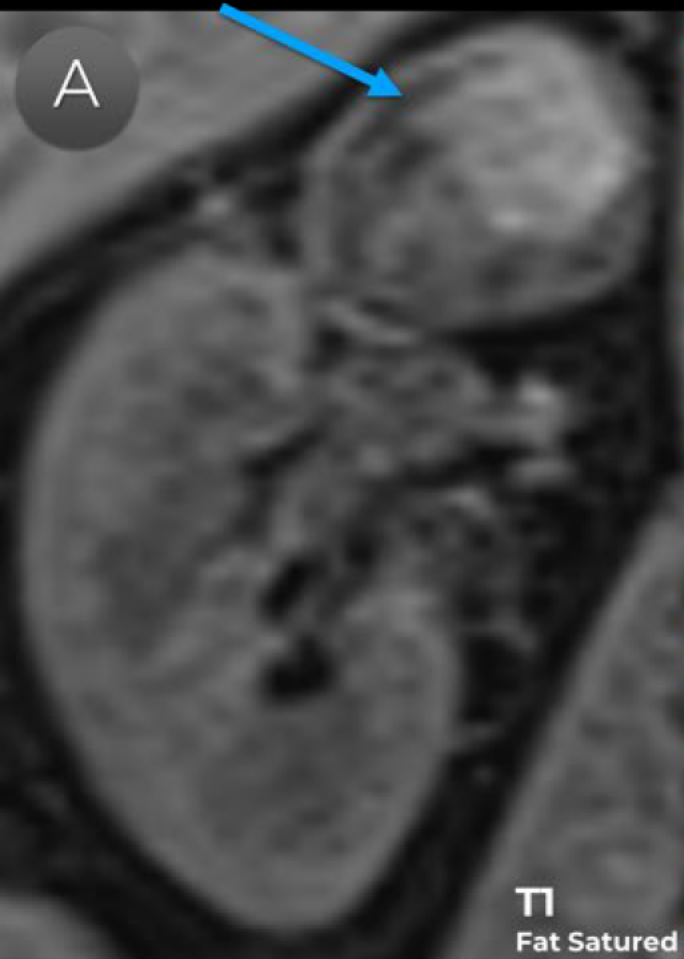
C



AIRPTM

AMERICAN INSTITUTE FOR
RADIOLOGIC PATHOLOGY

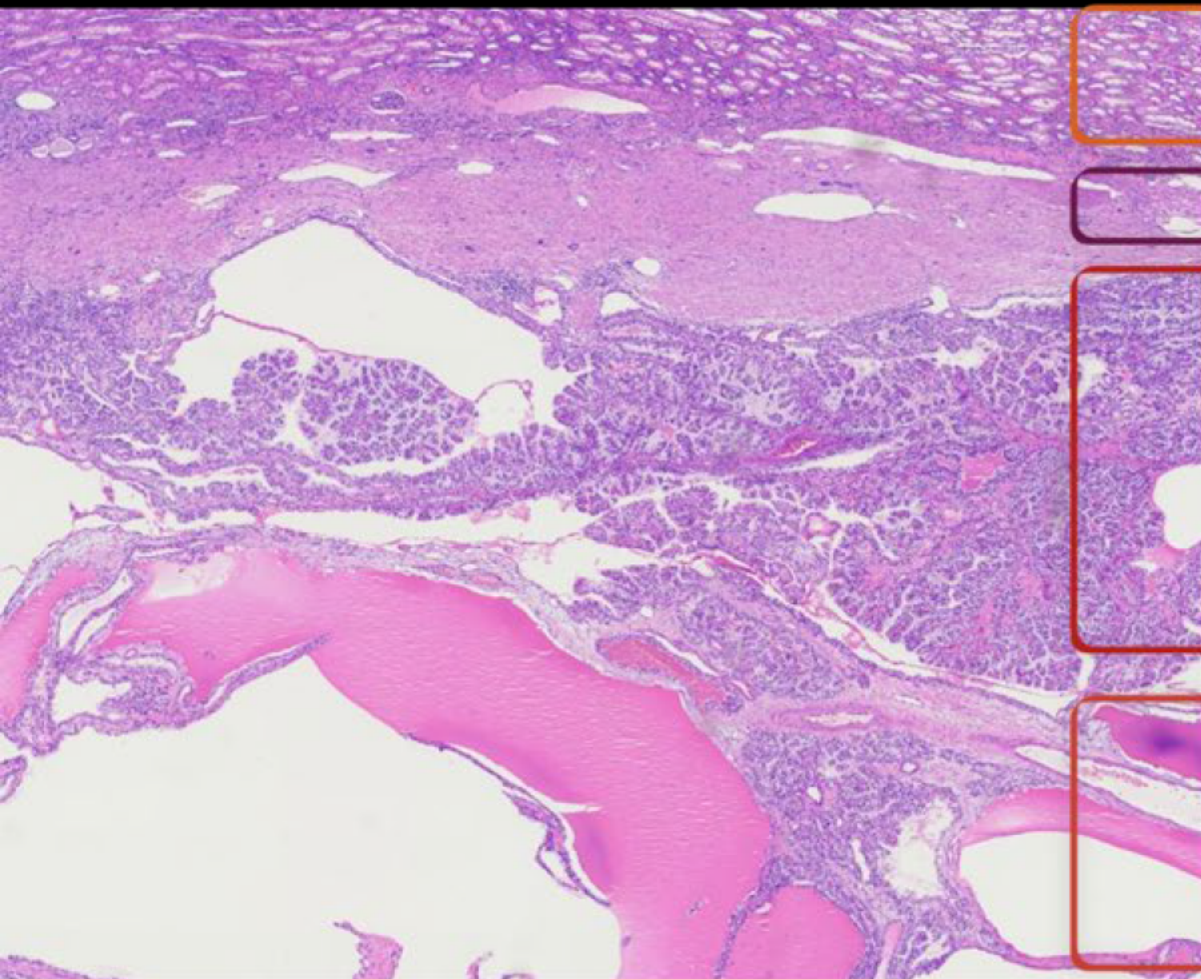
A PROGRAM OF THE
AMERICAN COLLEGE OF RADIOLOGY



AIRPTM

AMERICAN INSTITUTE FOR
RADIOLOGIC PATHOLOGY

A PROGRAM OF THE
AMERICAN COLLEGE OF RADIOLOGY



RENAL PARENCHYMA

**FIBROUS CAPSULE/
CONNECTIVE TISSUE**

**SOLID AREAS/
PAPILLAE**

LIQUID CONTENT

AIRPTM

**AMERICAN INSTITUTE FOR
RADIOLOGIC PATHOLOGY**

A PROGRAM OF THE
AMERICAN COLLEGE OF RADIOLOGY

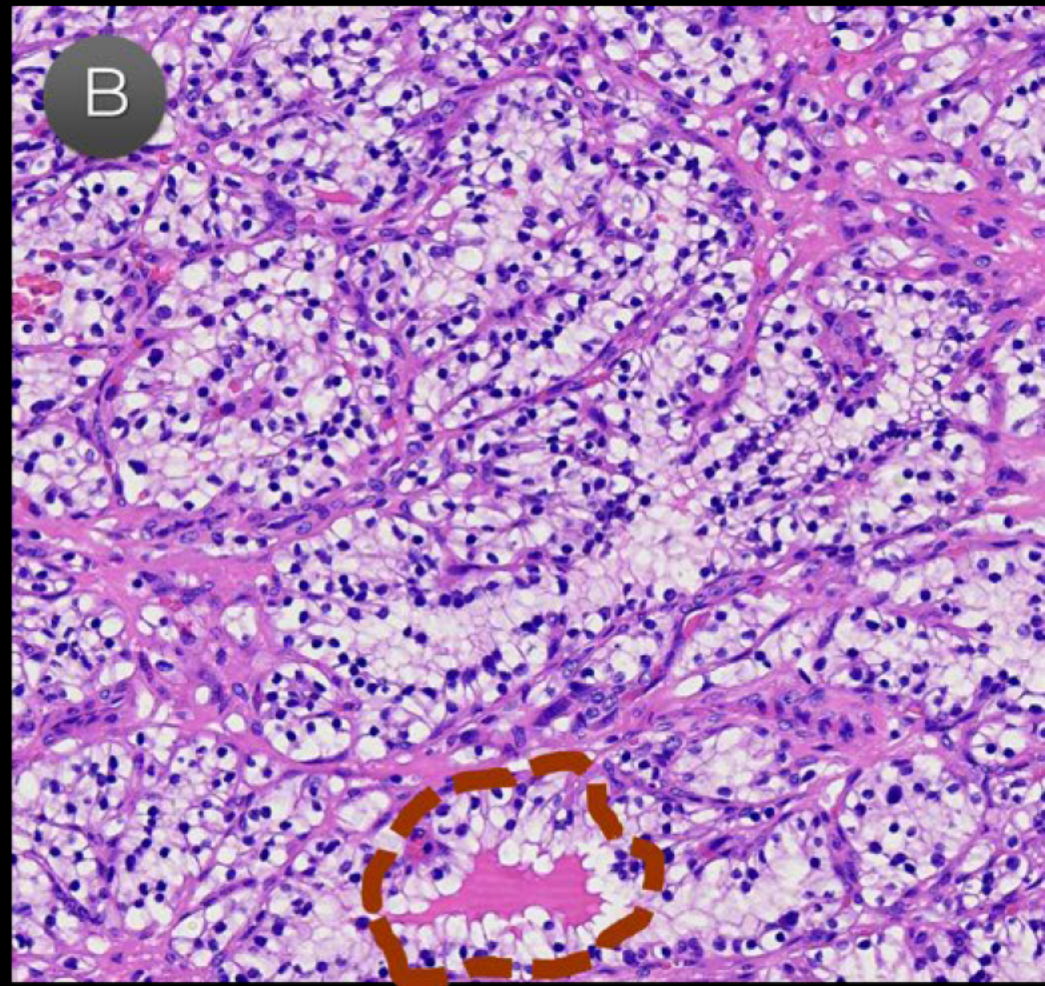
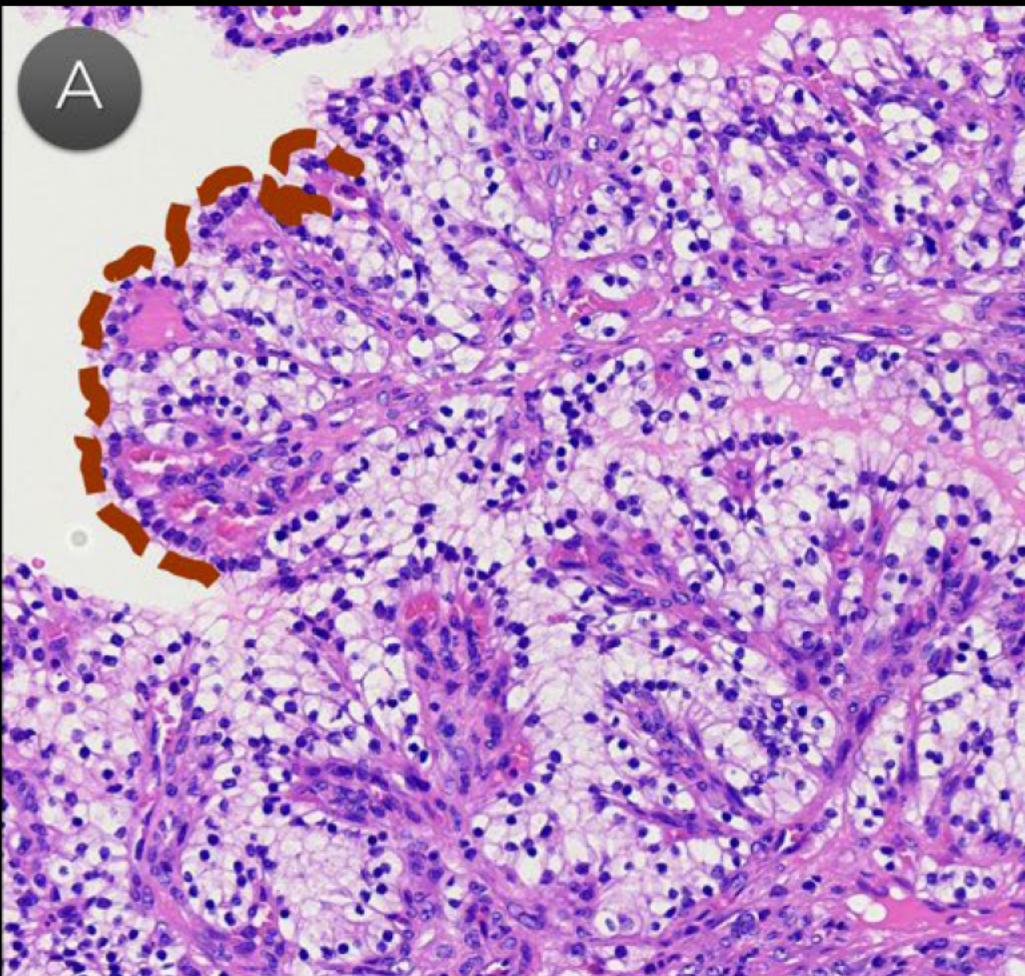
CLEAR CELL

+

PAPILLARY
ARCHITECTURE



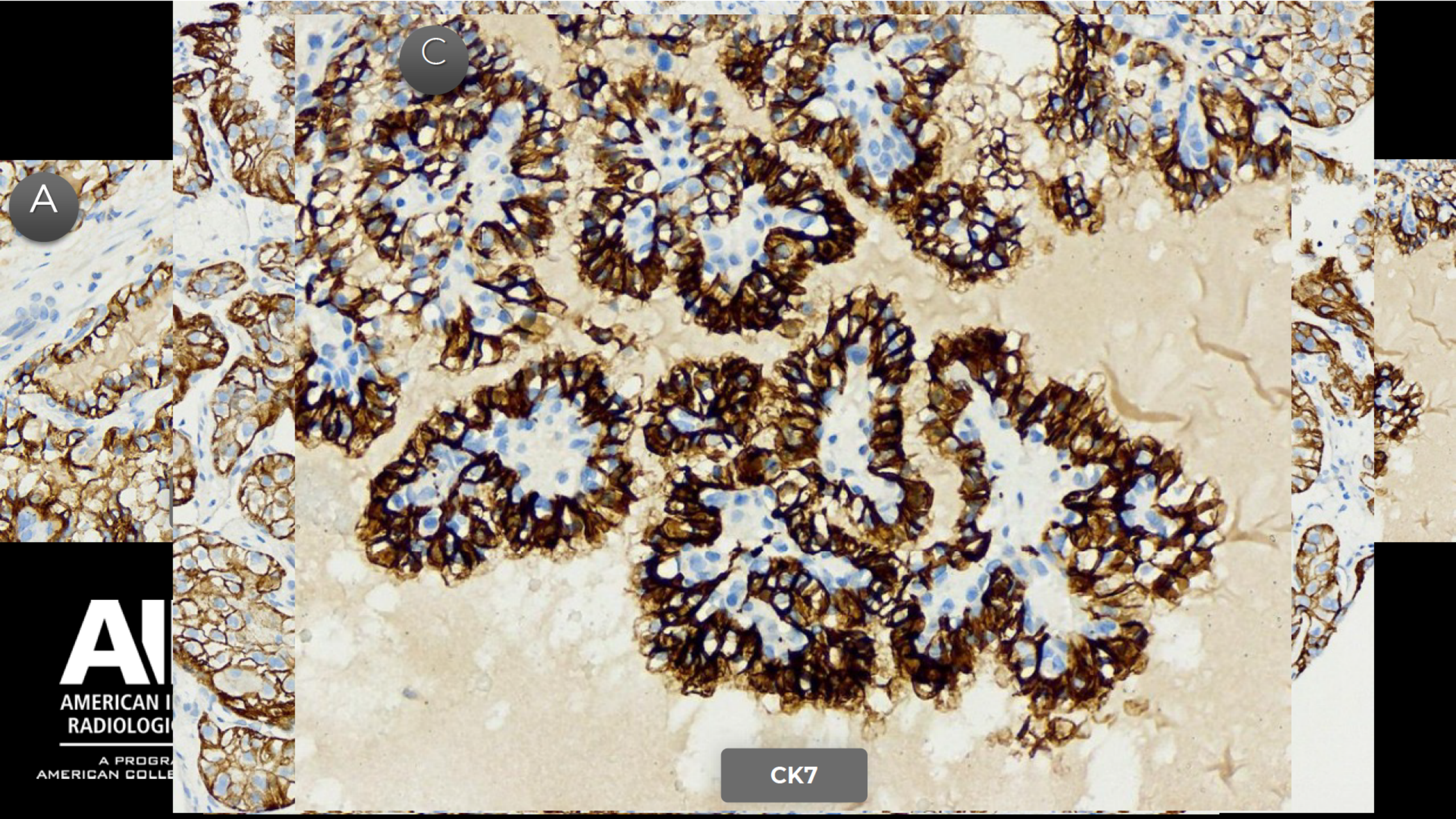?



AIRPTM

AMERICAN INSTITUTE FOR
RADIOLOGIC PATHOLOGY

A PROGRAM OF THE
AMERICAN COLLEGE OF RADIOLOGY



C

A

CK7

AI

AMERICAN
RADIOLOGICAL

A PROGRAM OF
THE AMERICAN COLLEGE

CLEAR CELL PAPILLARY RENAL CELL CARCINOMA

**Camila Silva Barbosa
Sírio Libanês Hospital
São Paulo-SP, Brazil**



**AMERICAN INSTITUTE FOR
RADIOLOGIC PATHOLOGY**

**A PROGRAM OF THE
AMERICAN COLLEGE OF RADIOLOGY**