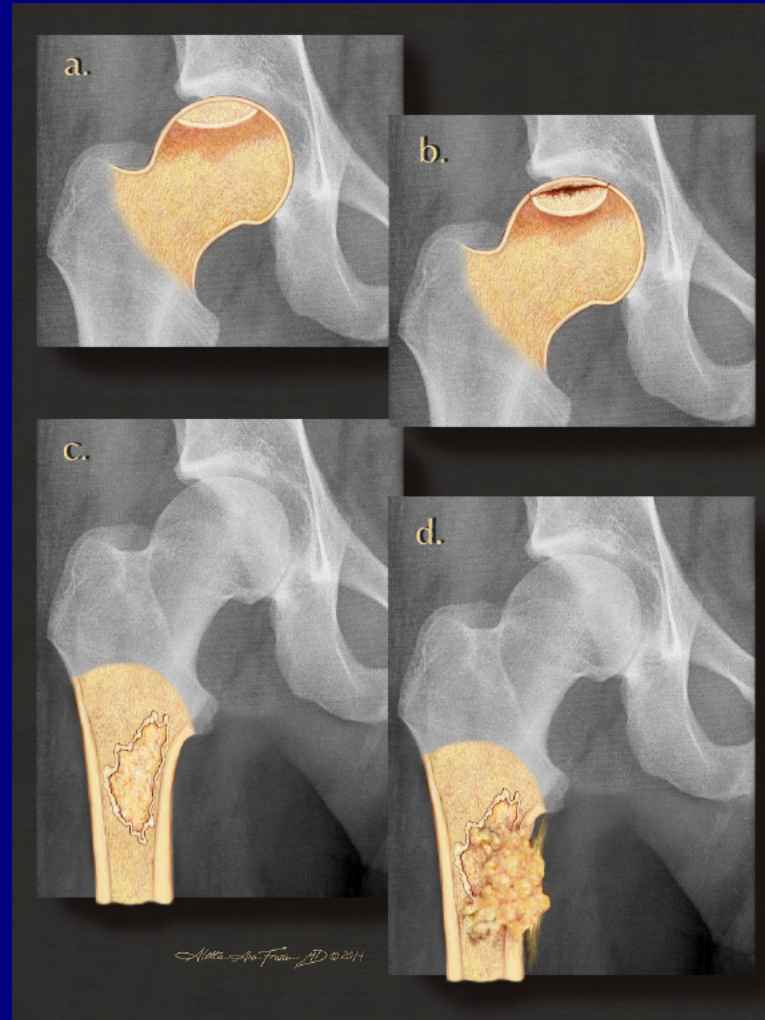


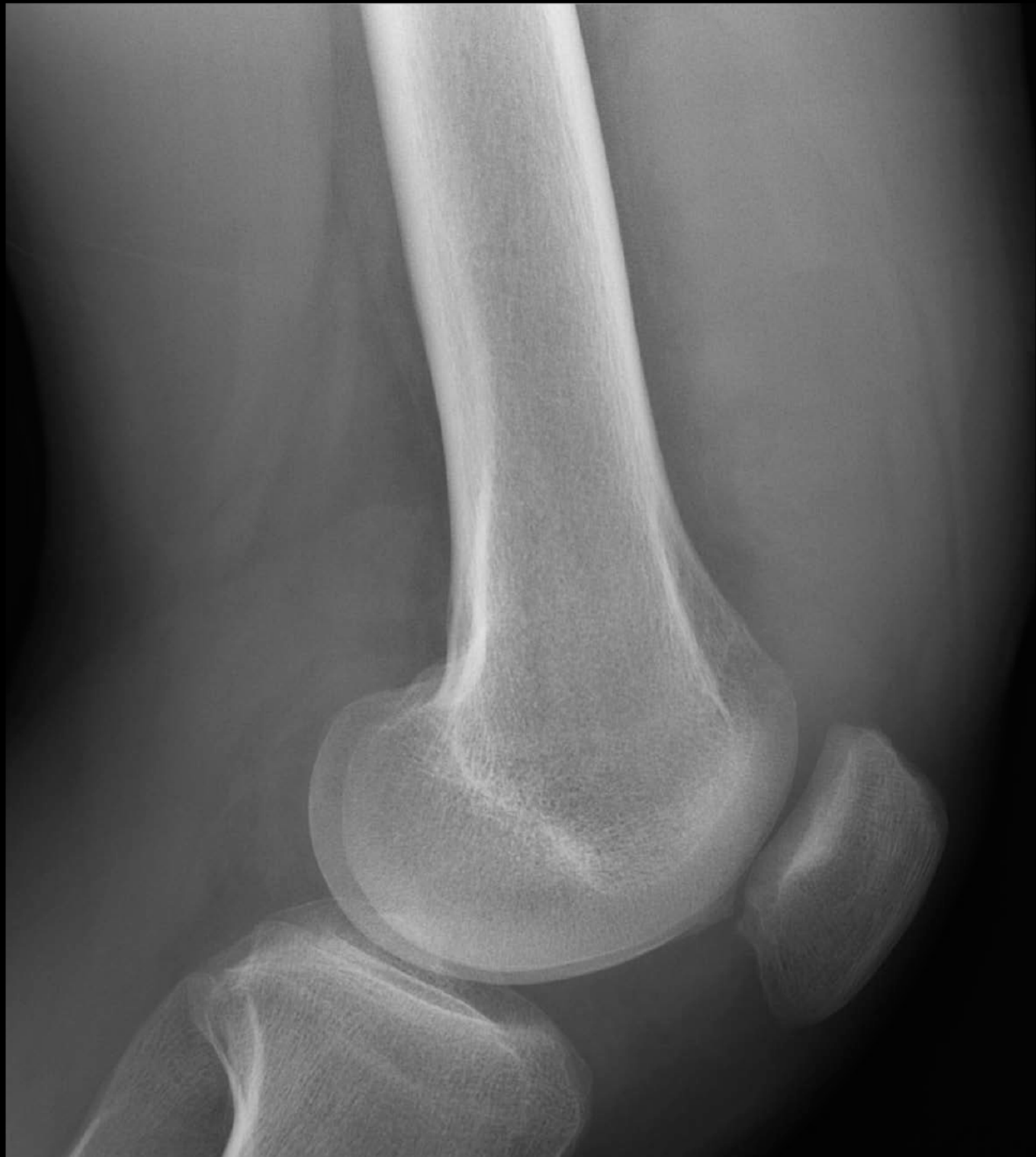Best Cases of the AIRP

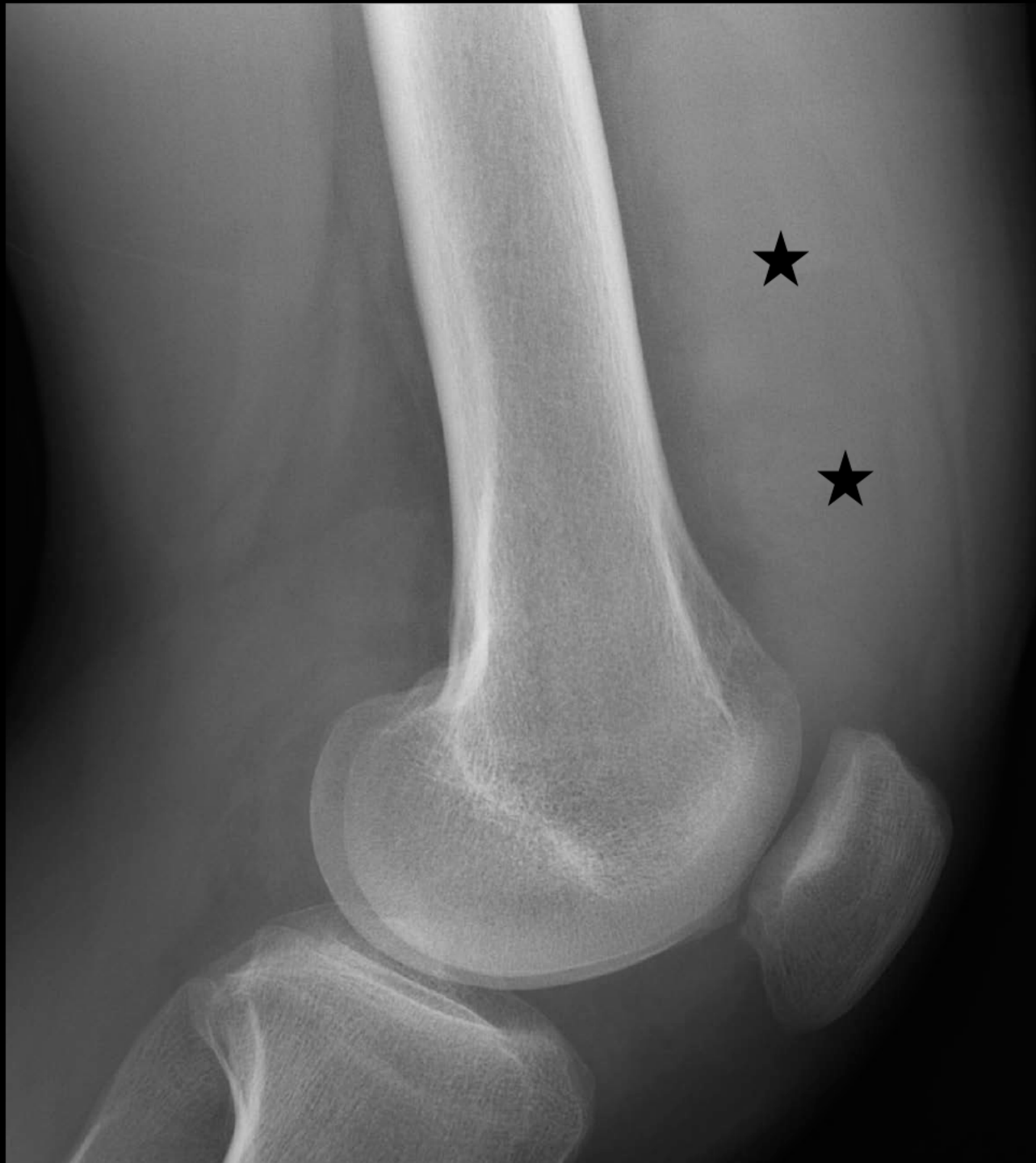August 2016

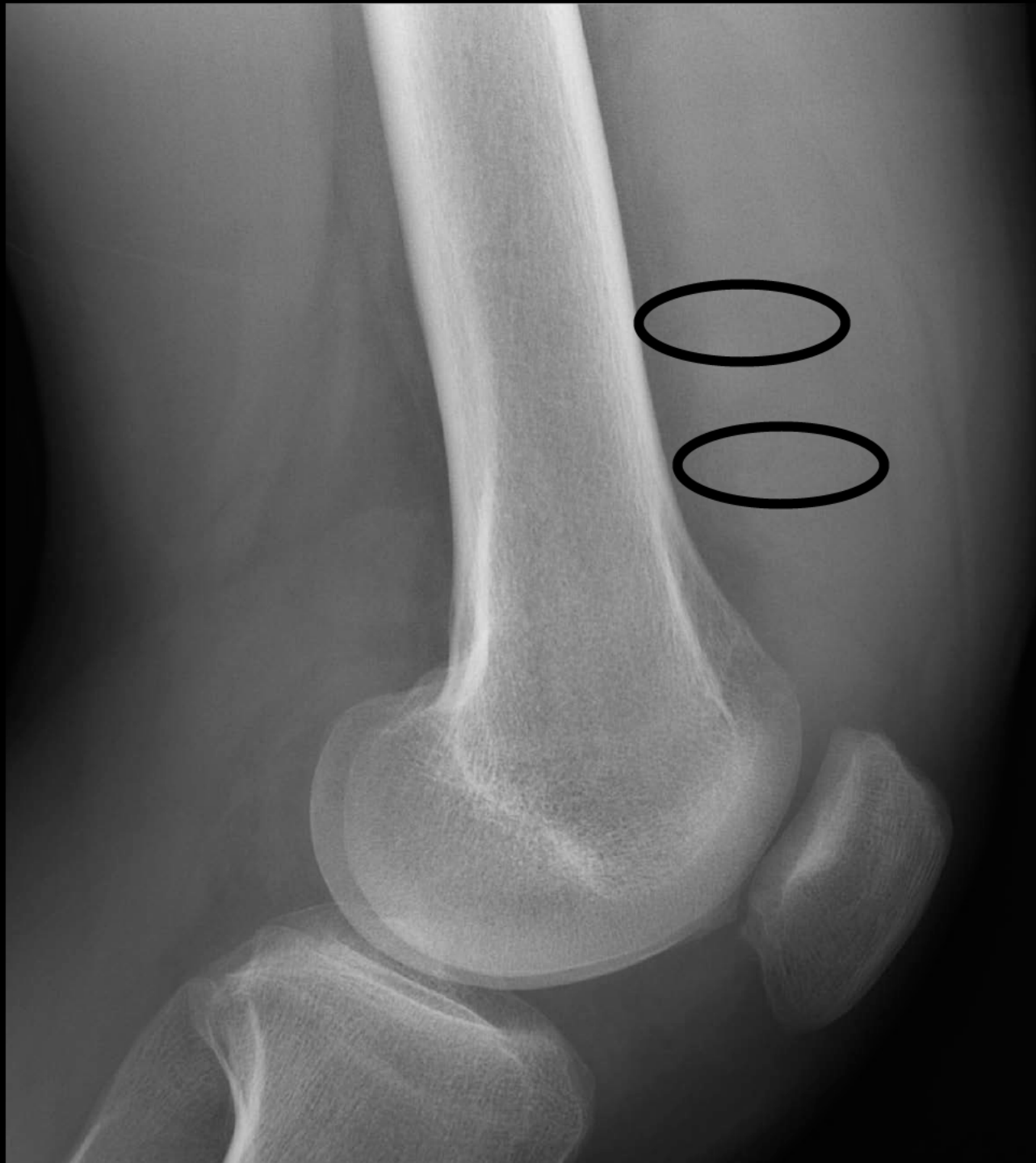
Musculoskeletal Best Case

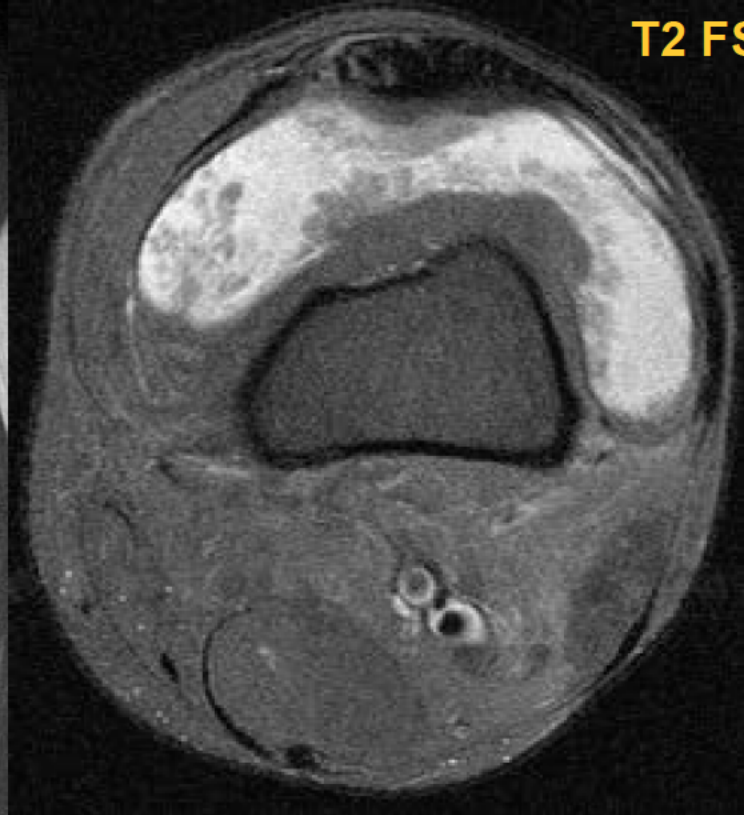
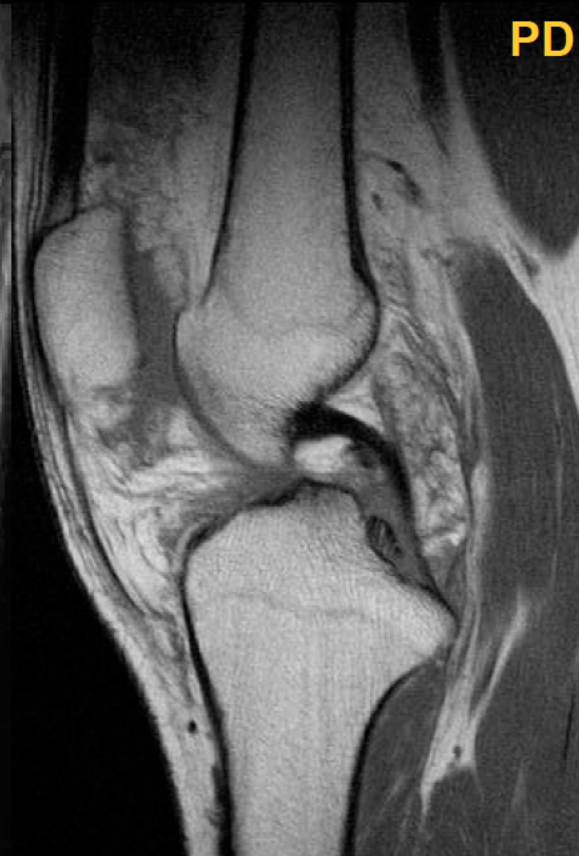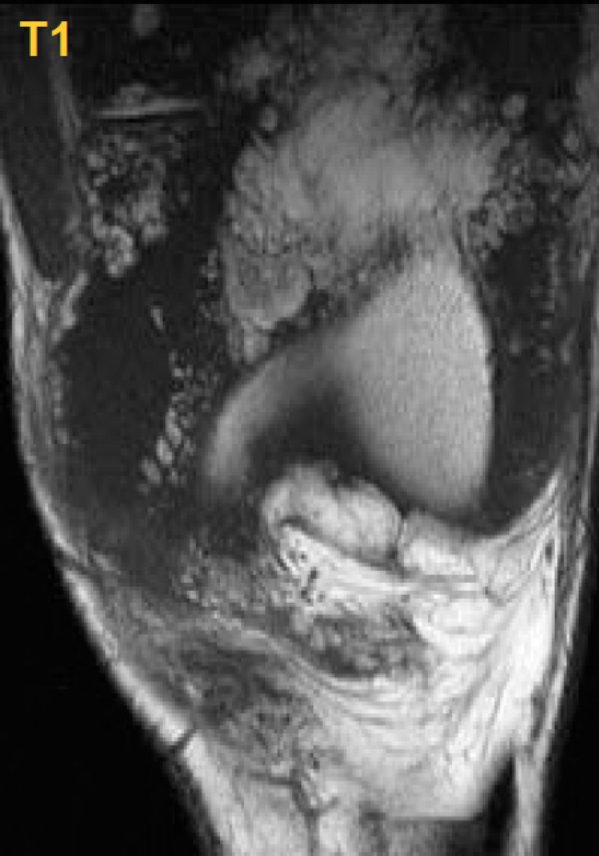


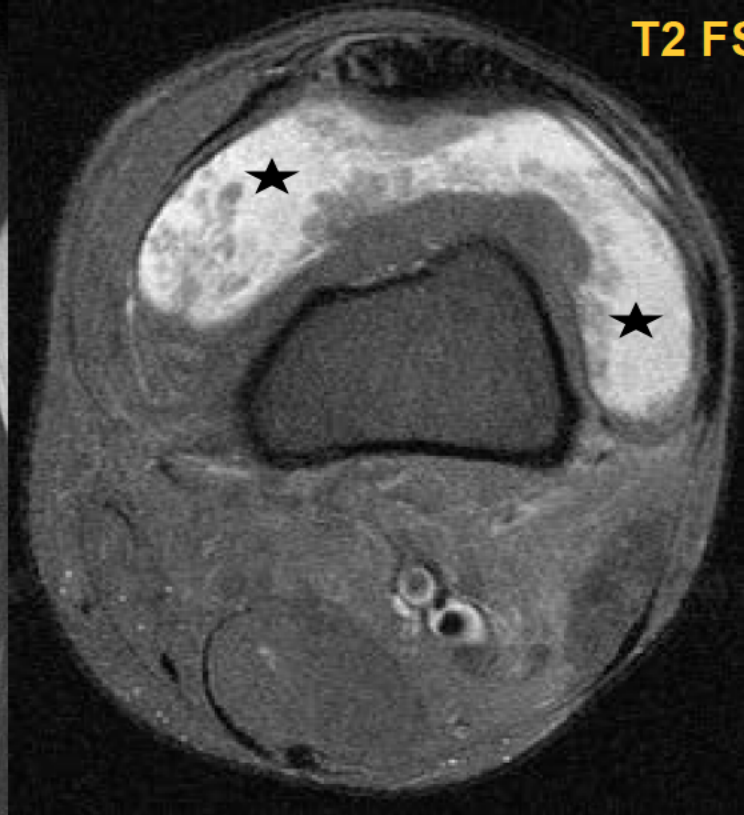
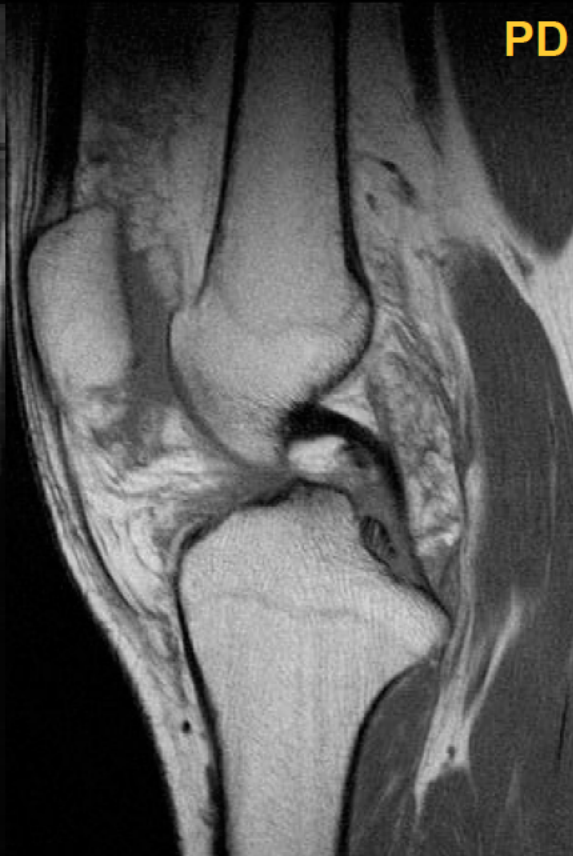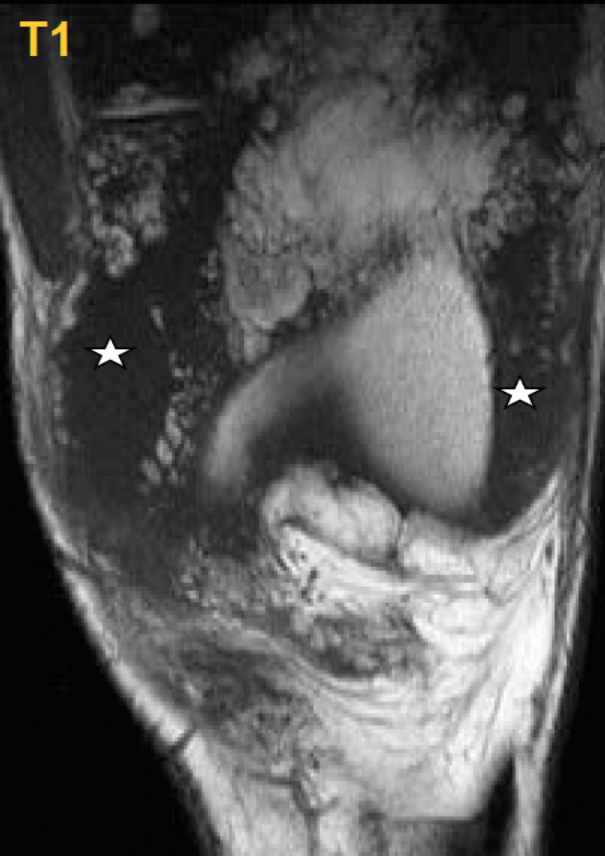
32 year-old man with 2 years
of left knee pain, swelling and
stiffness exacerbated by
activity.

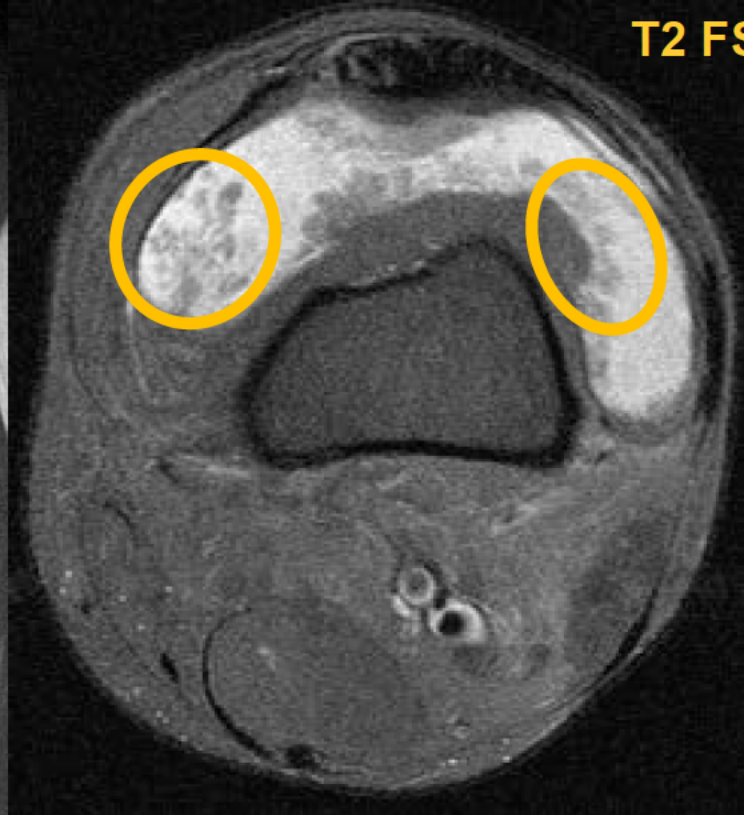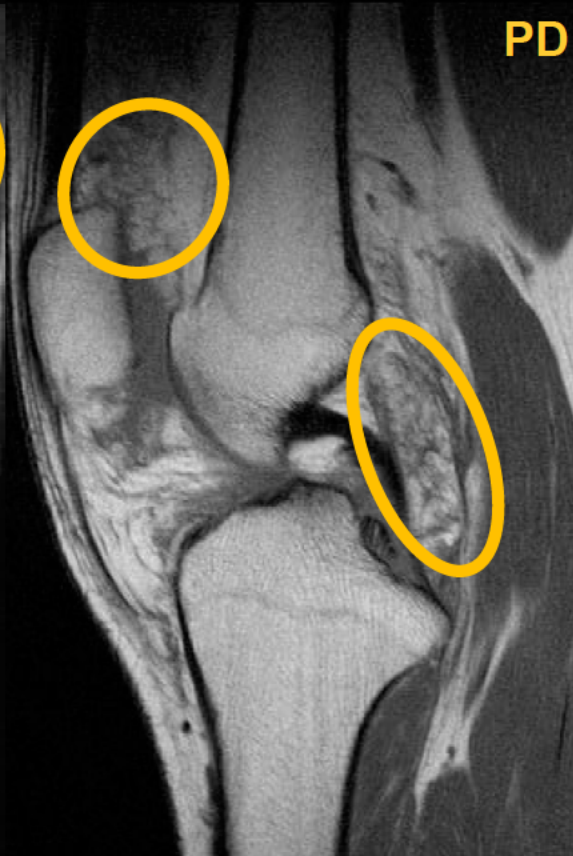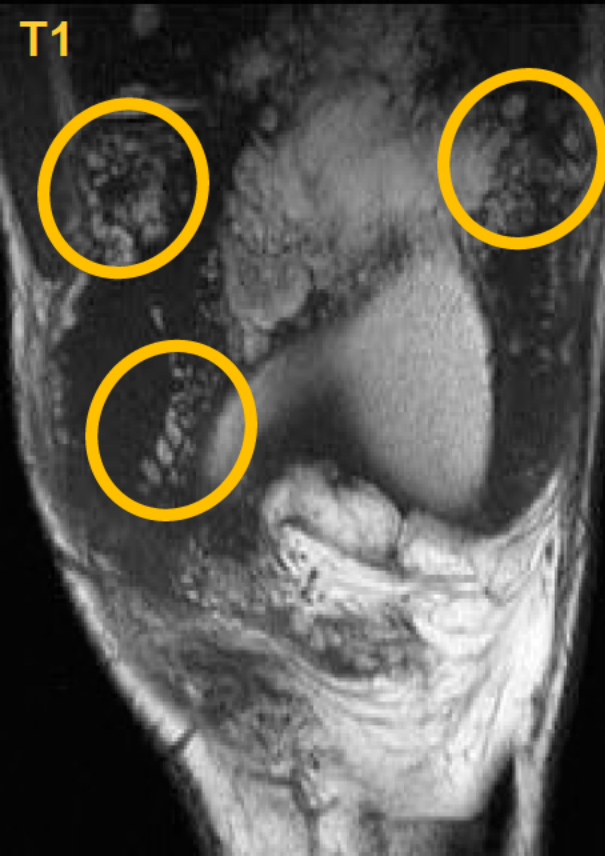


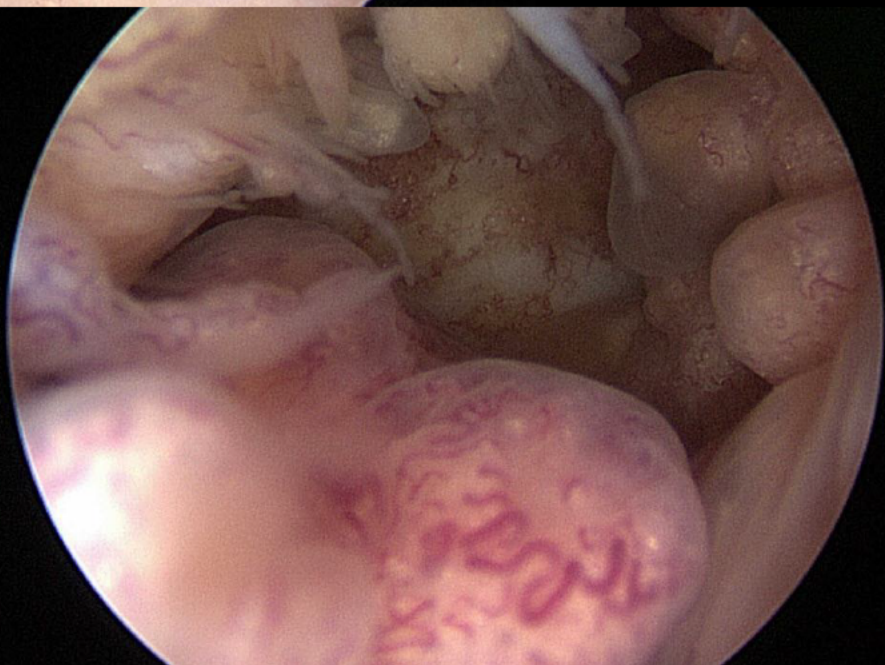
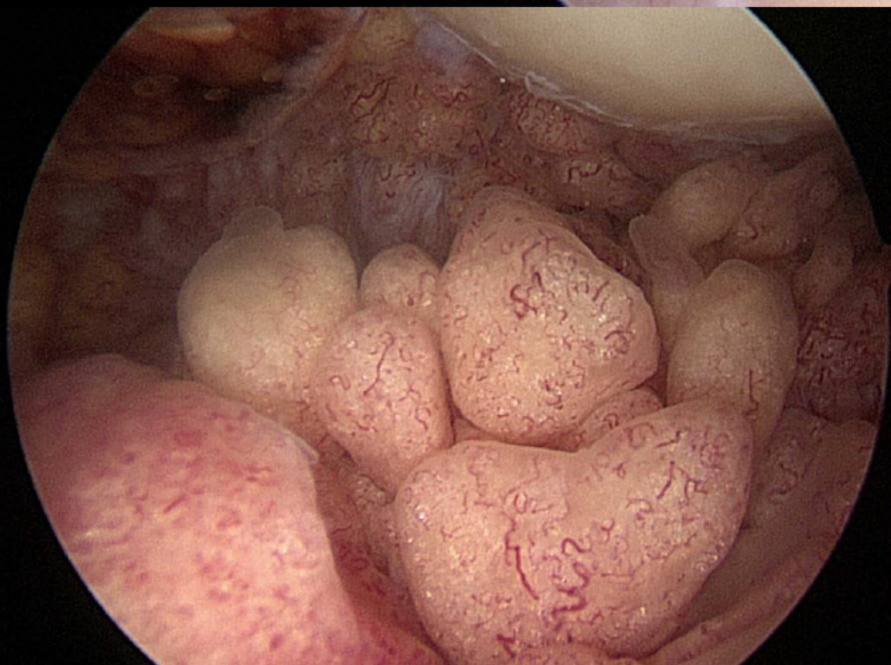
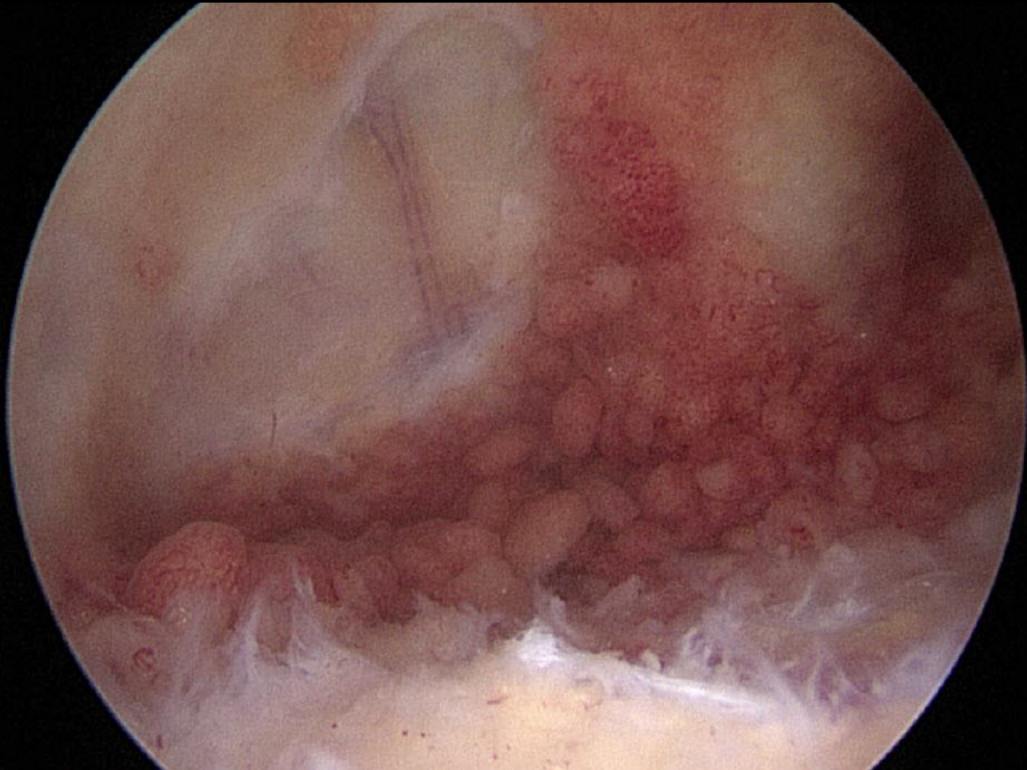


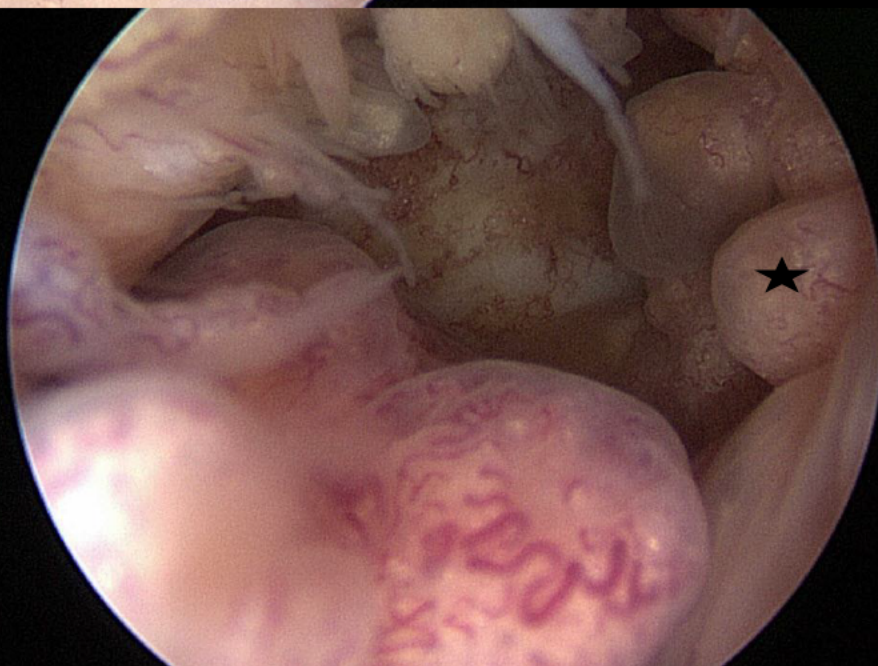
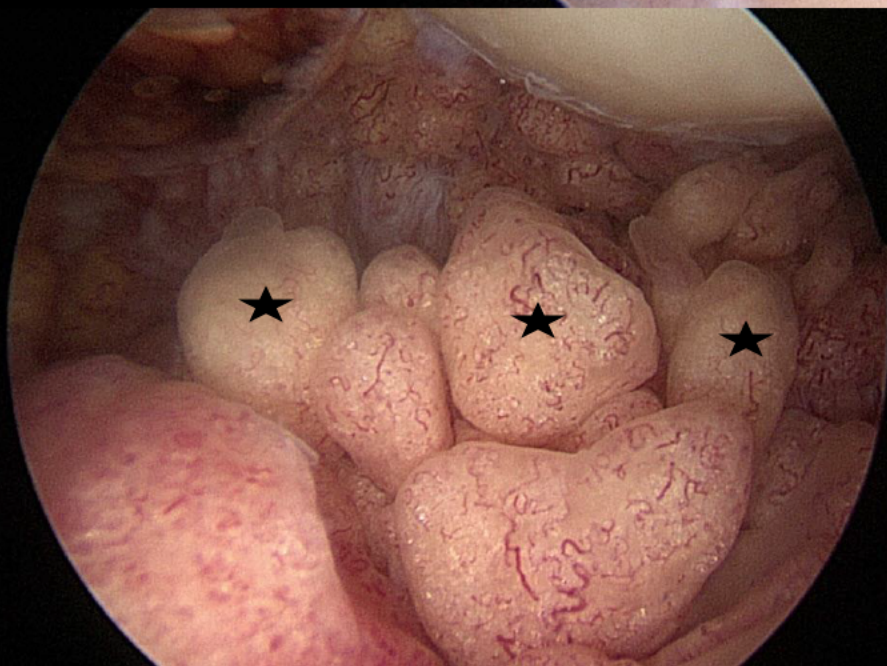
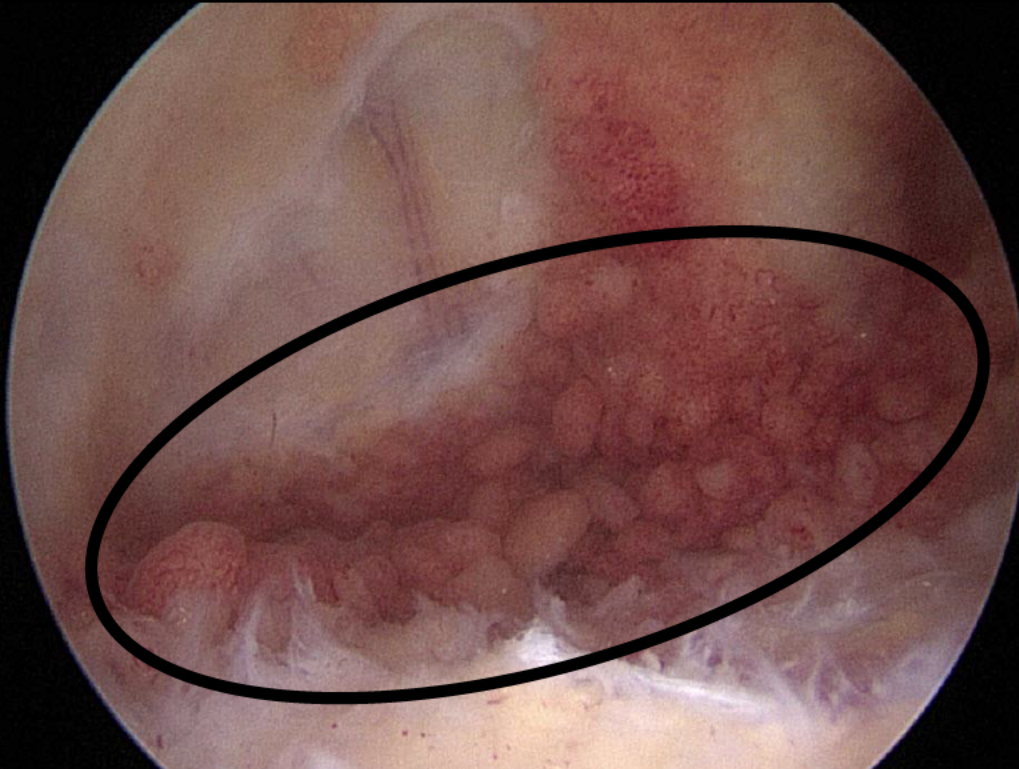


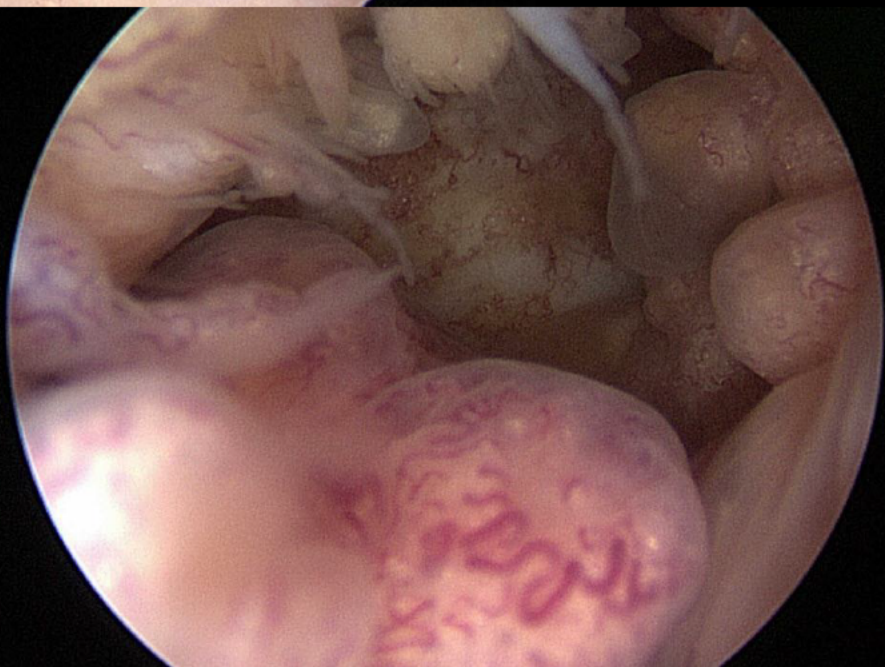
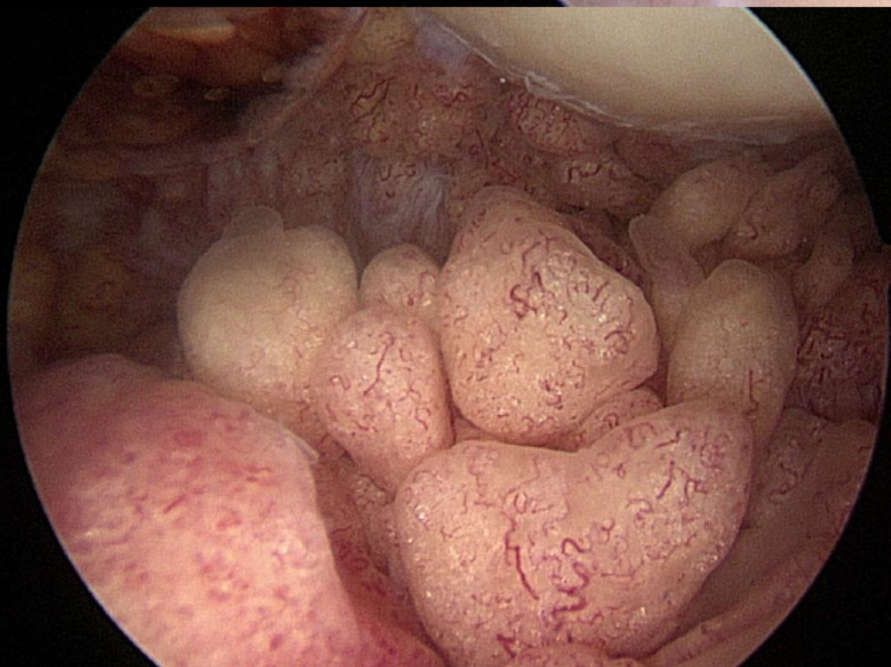
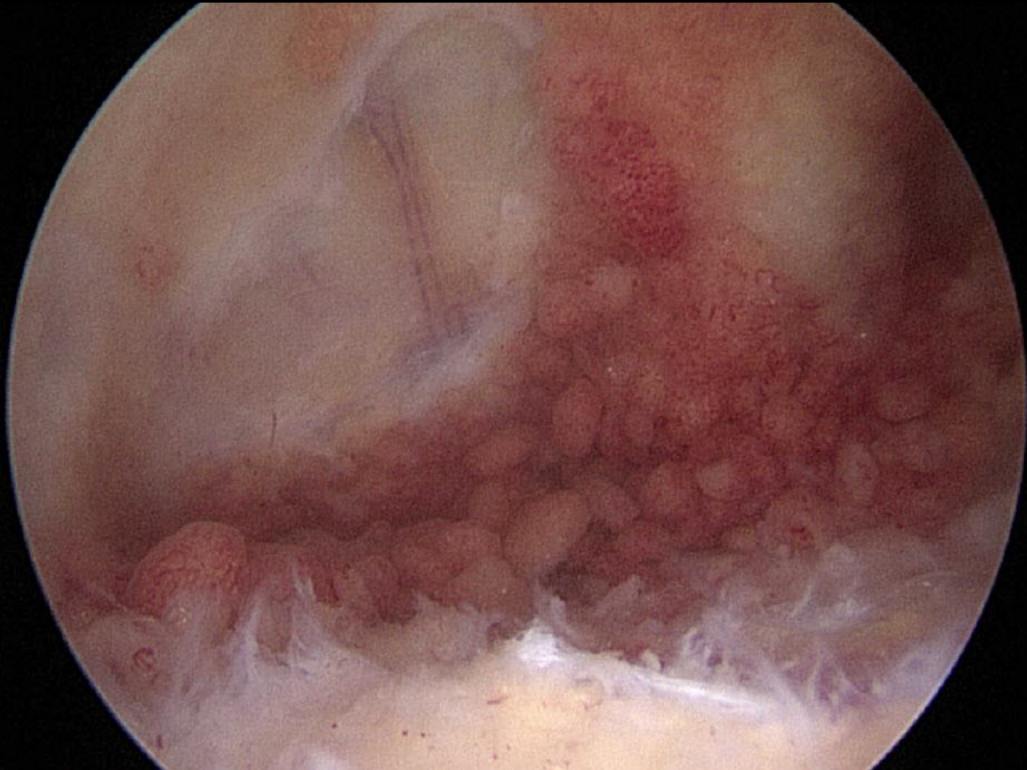


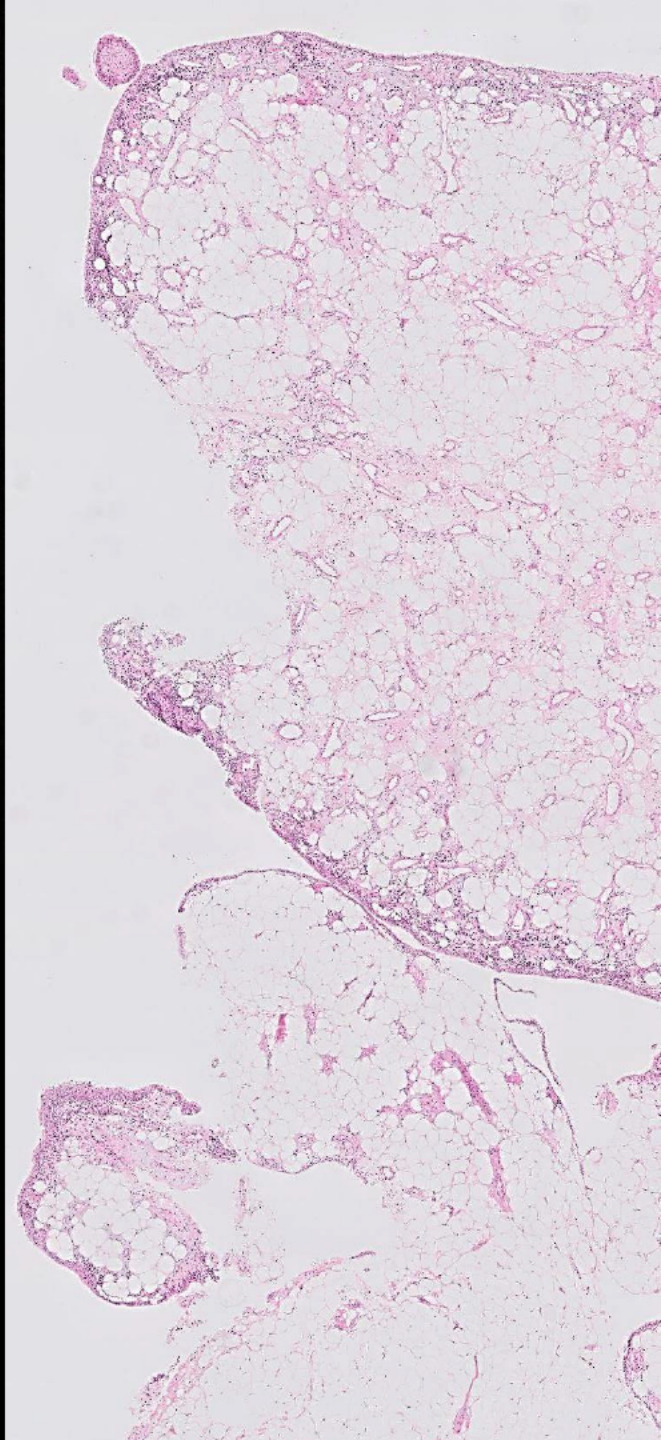
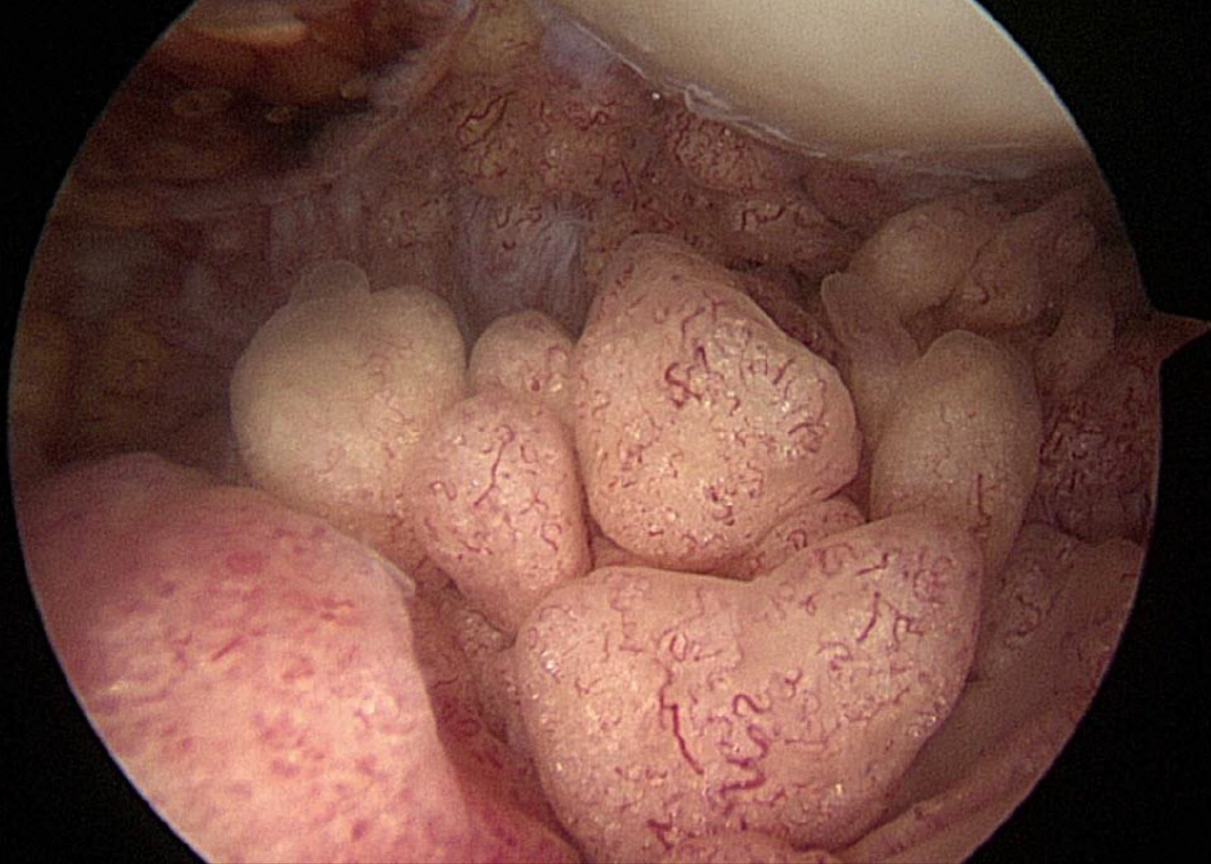


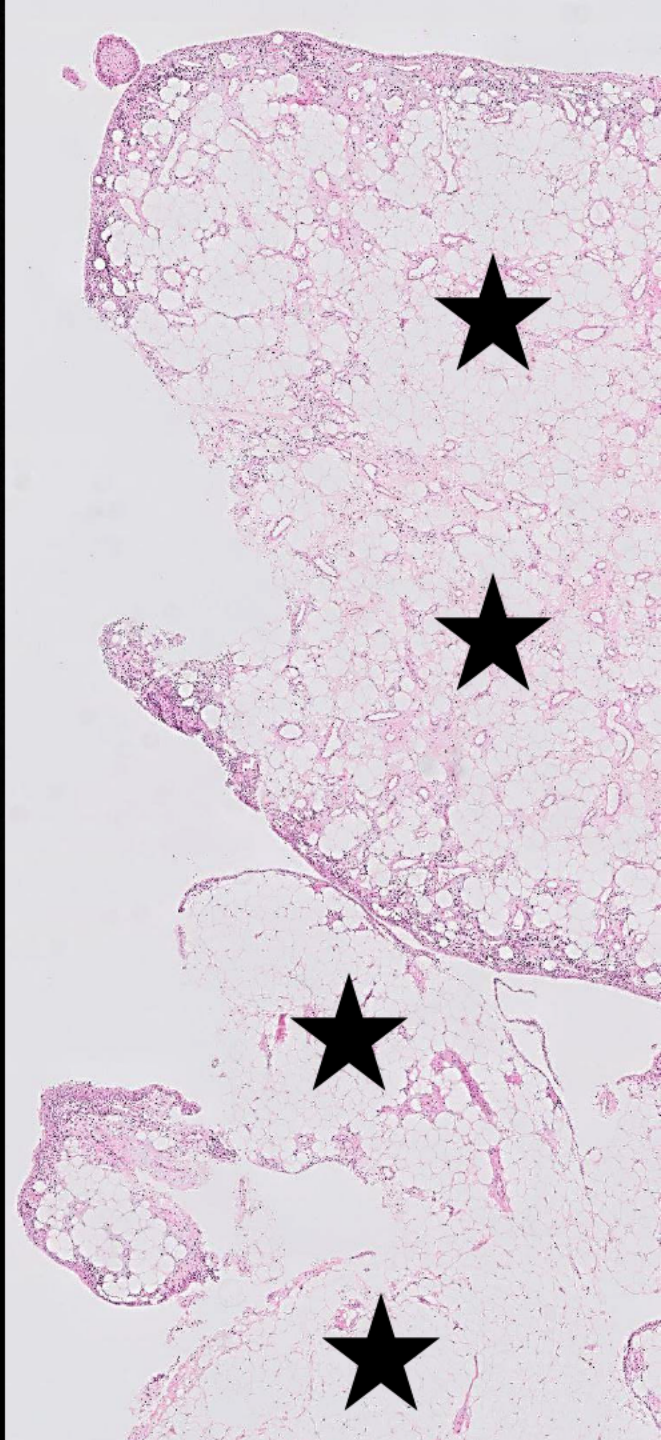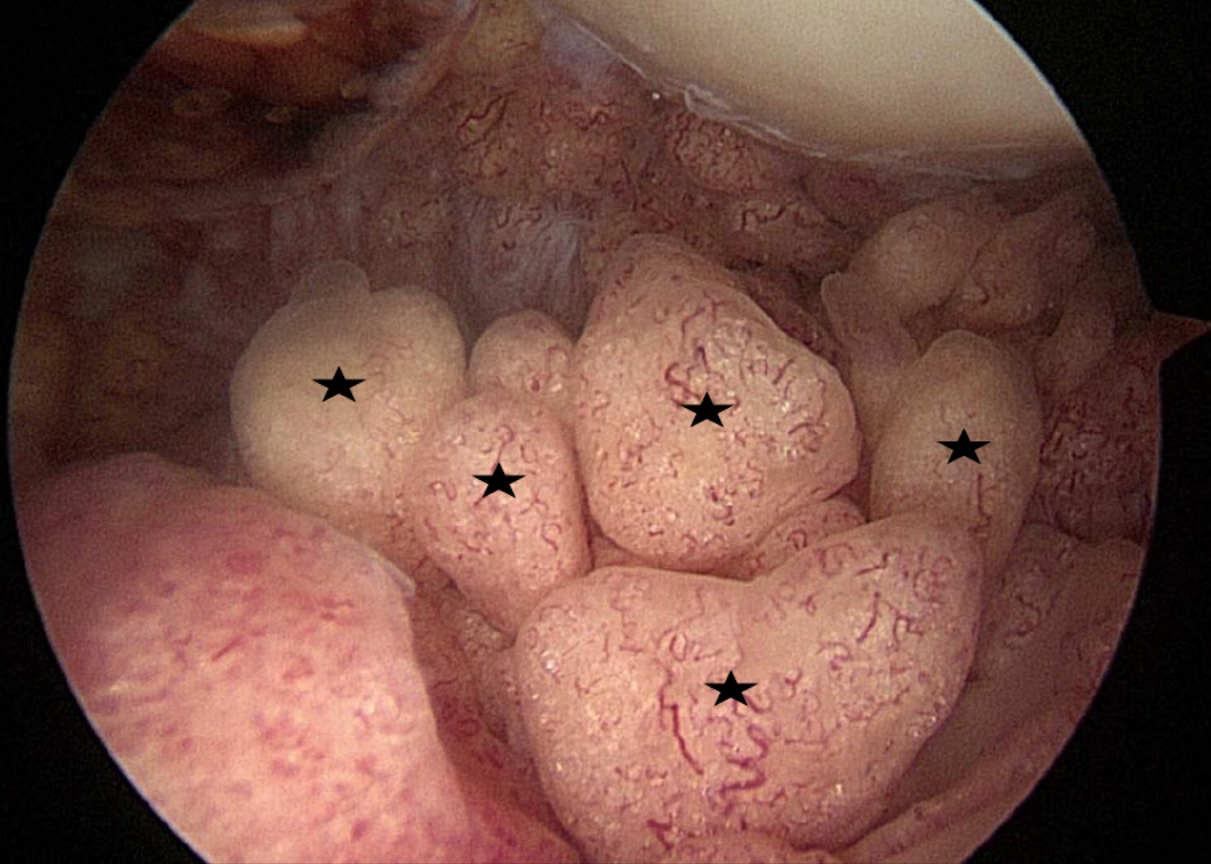


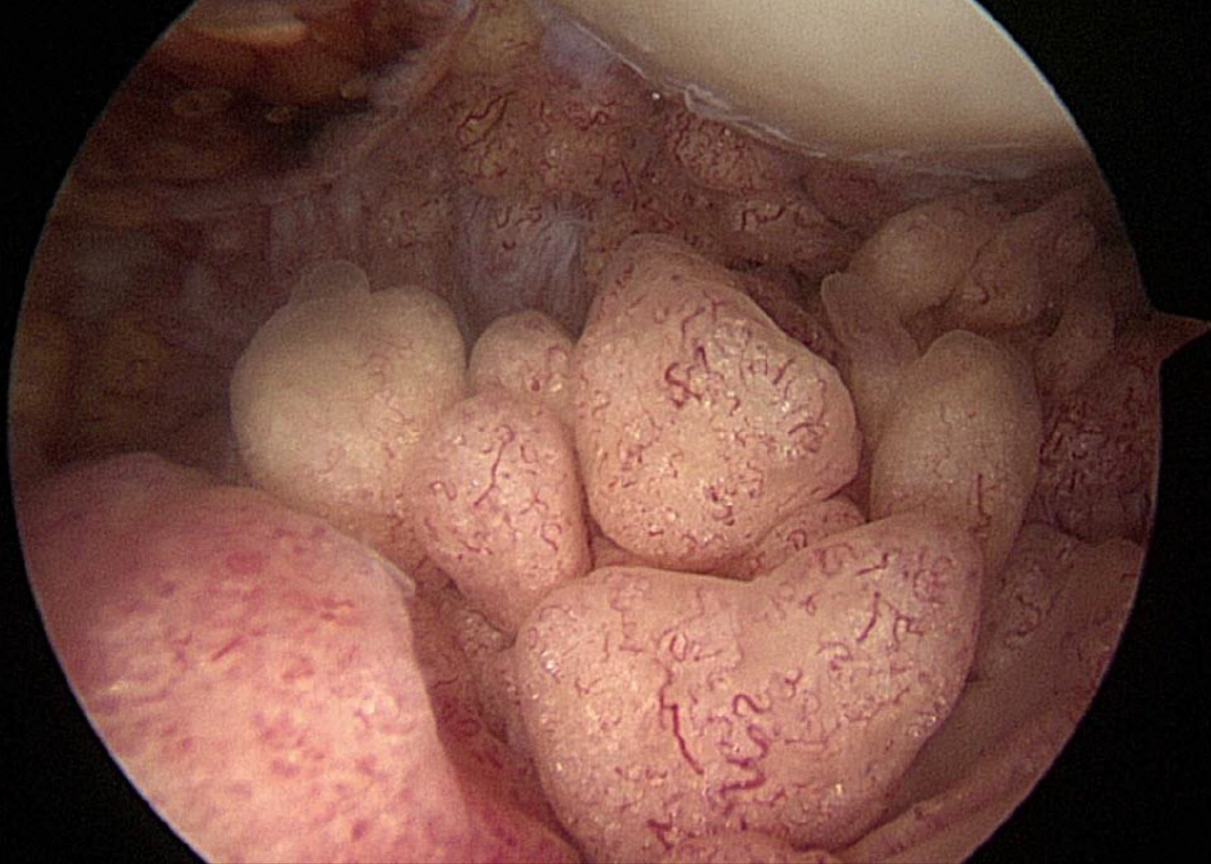


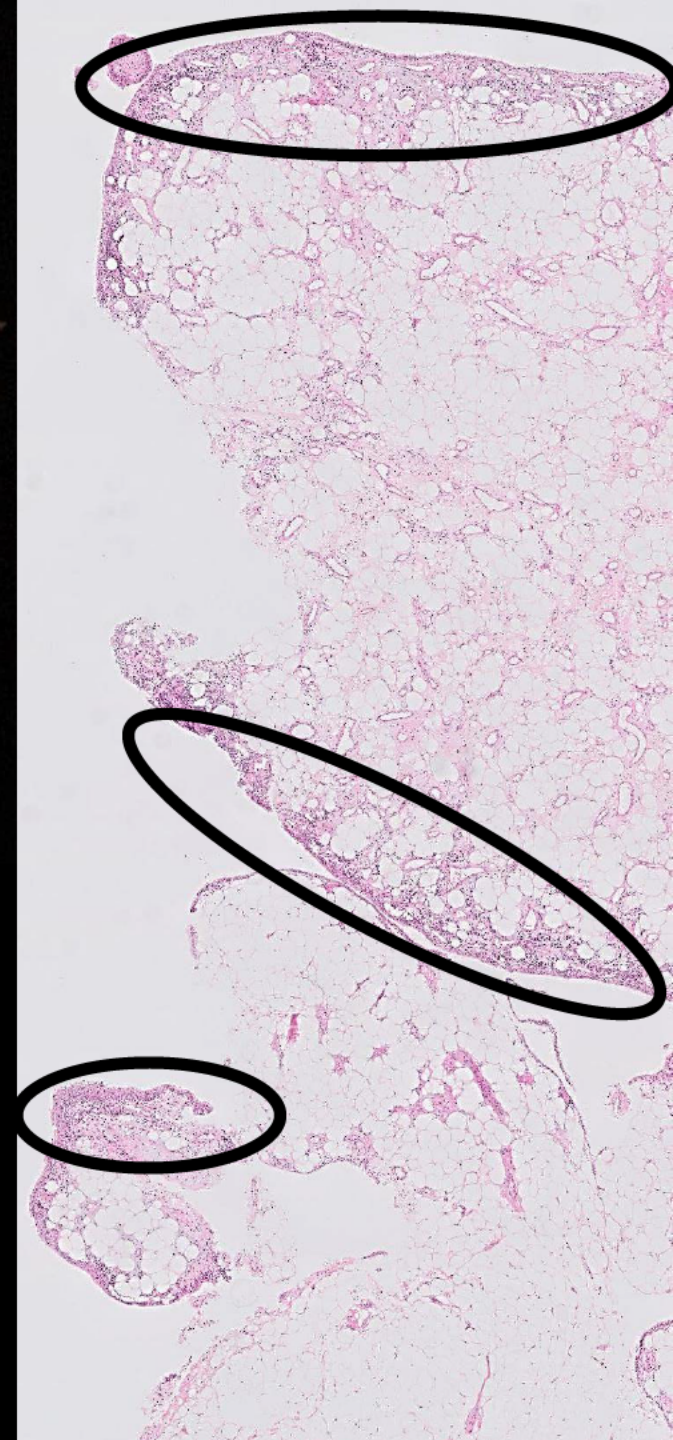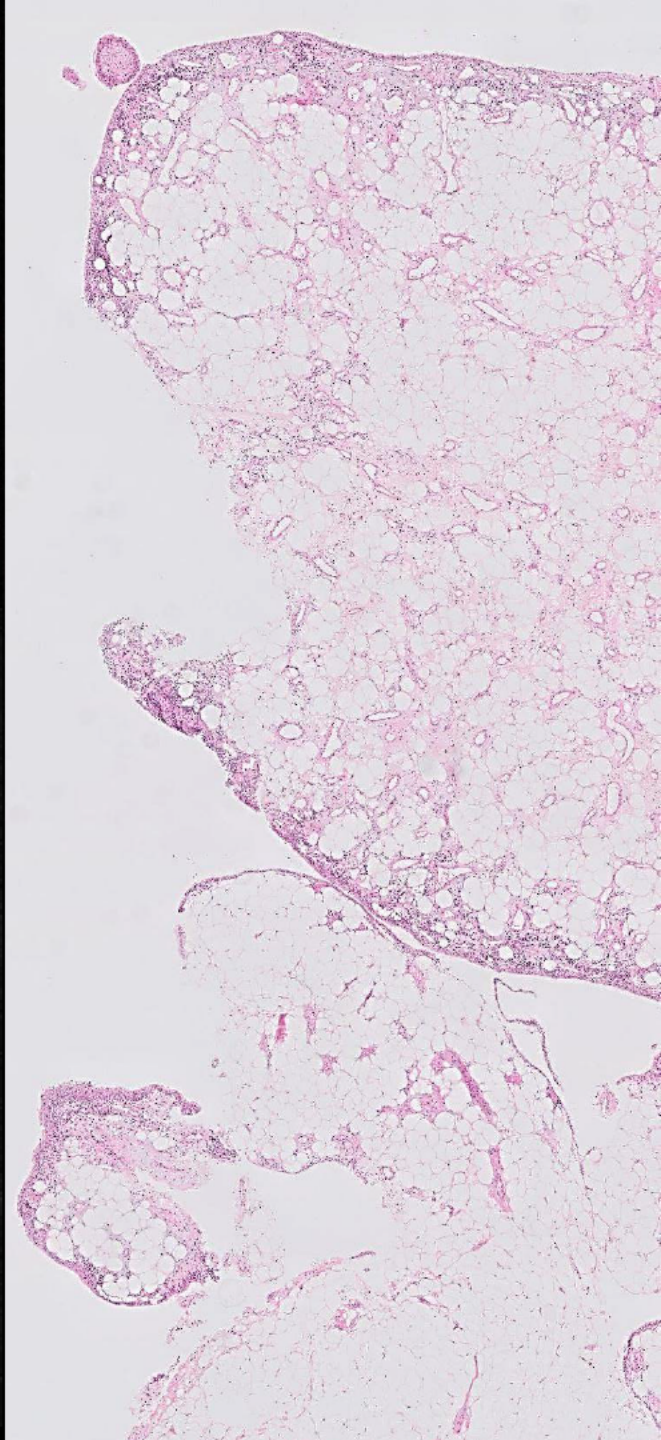
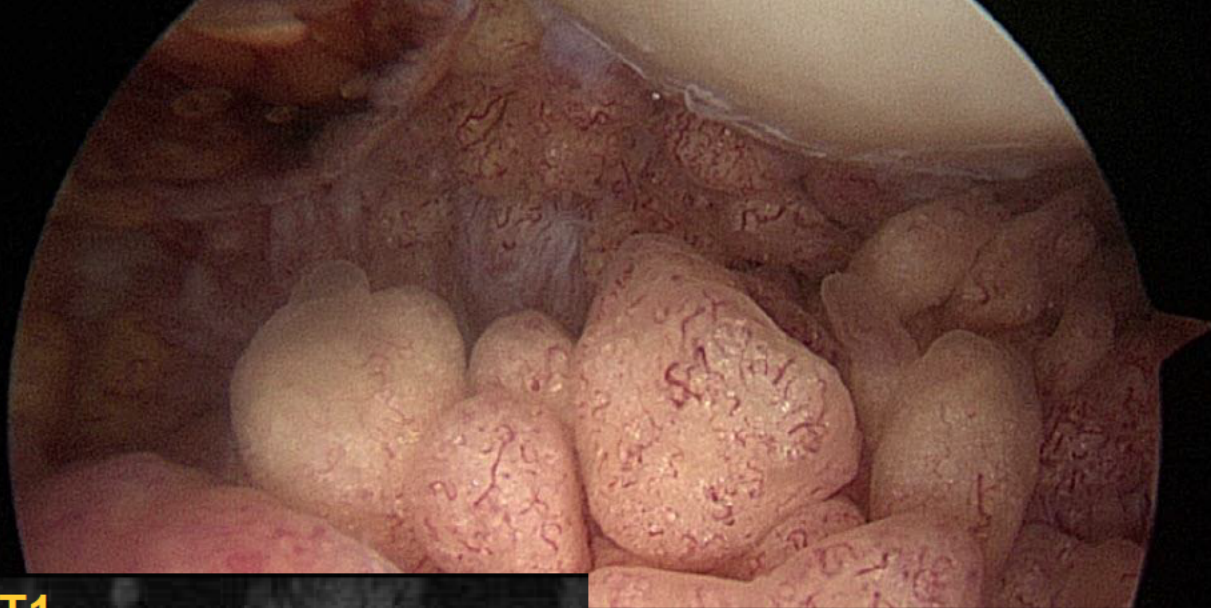




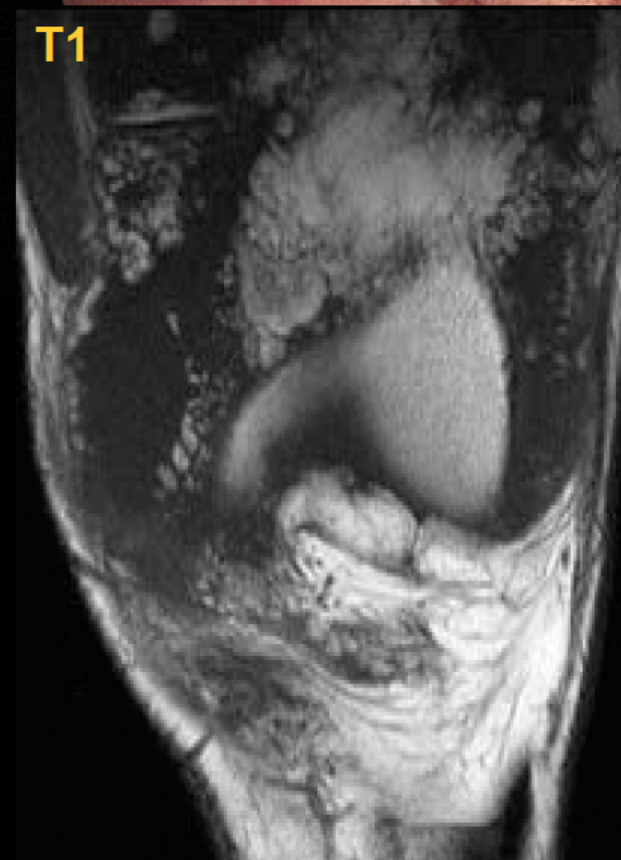




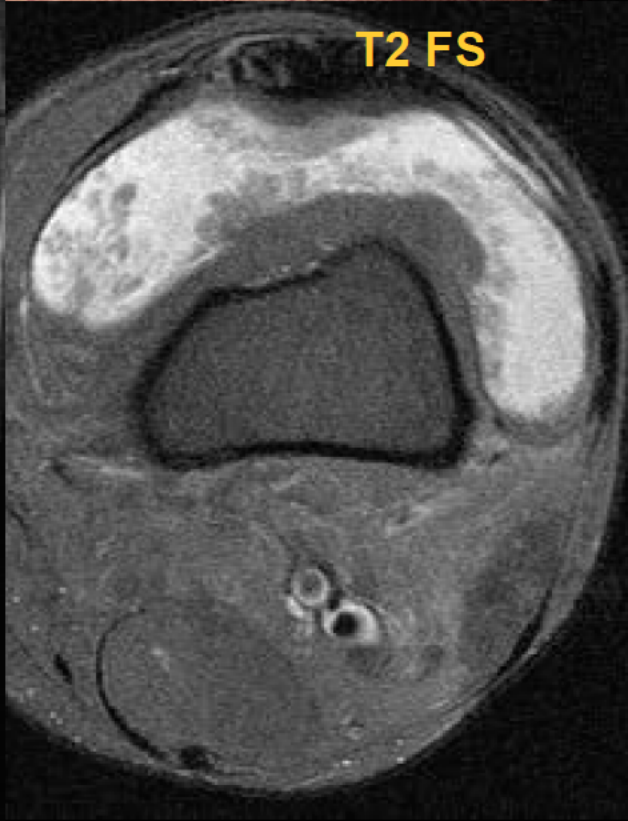




T1



T2 FS



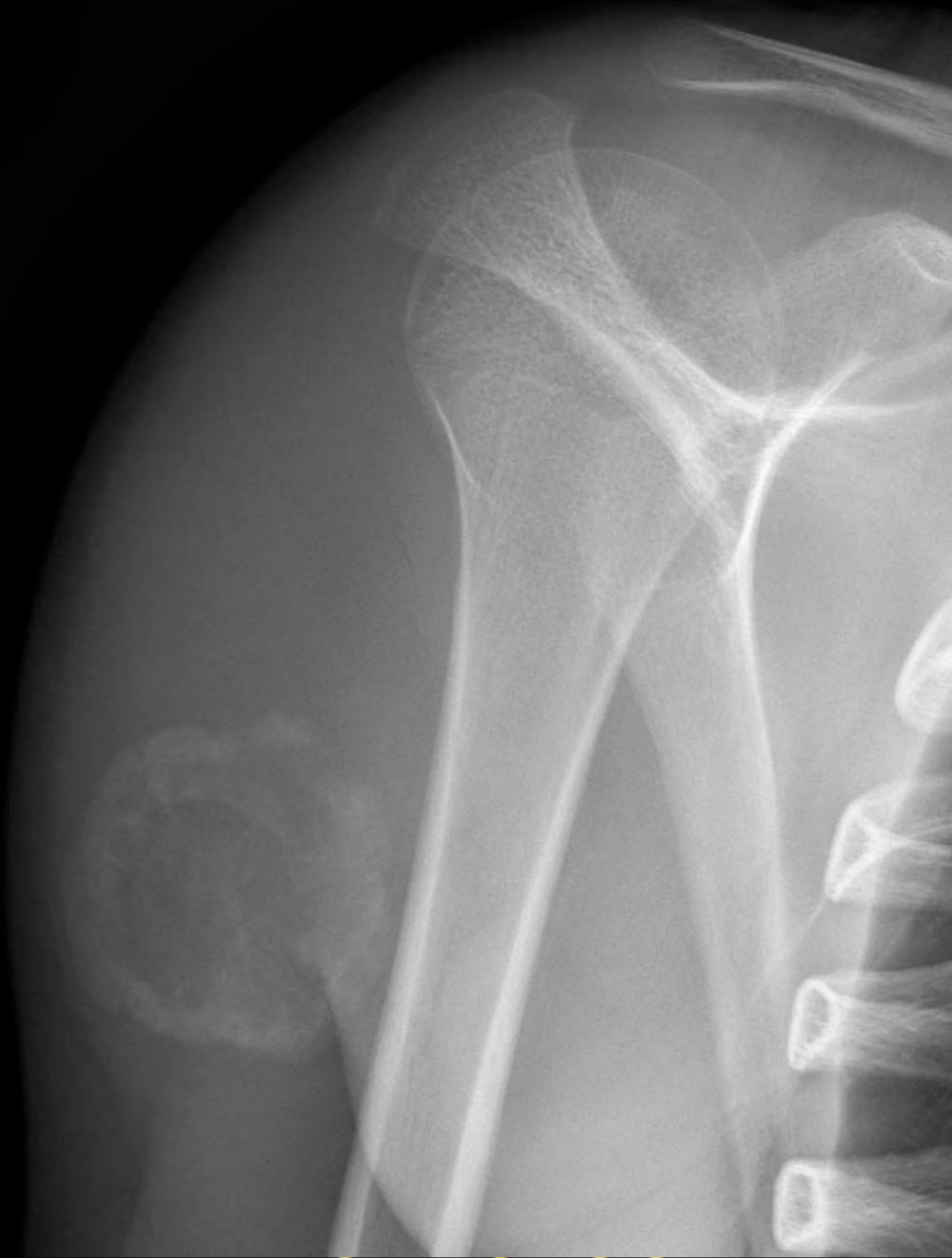
Lipoma Arborescens

Preston Eiswirth, MD

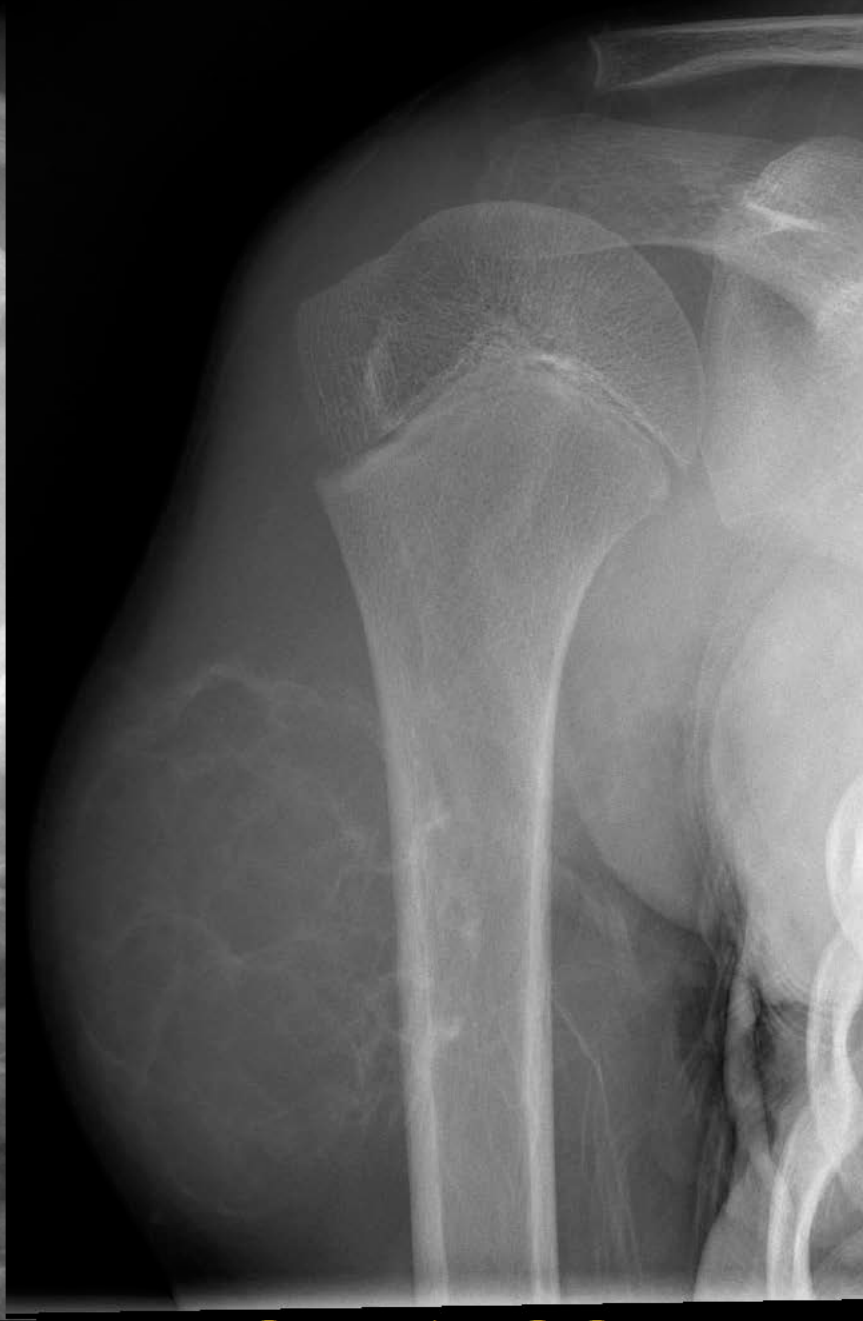Washington University School of Medicine
St. Louis, Missouri

Honorable mention

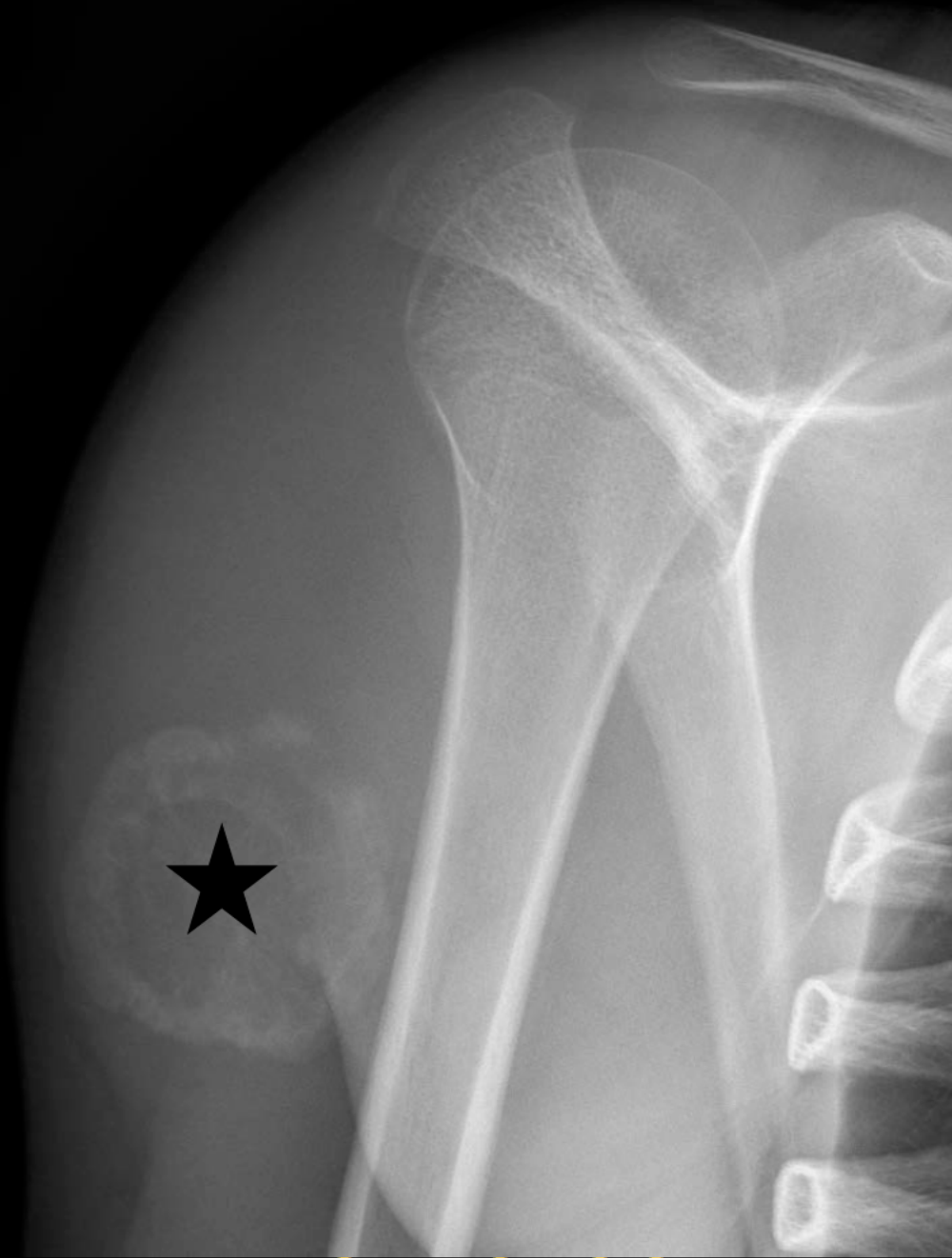
10-year-old female with 2 week history of gradually increasing right shoulder pain. She started developing an growing, tender lump.



9-18-2015



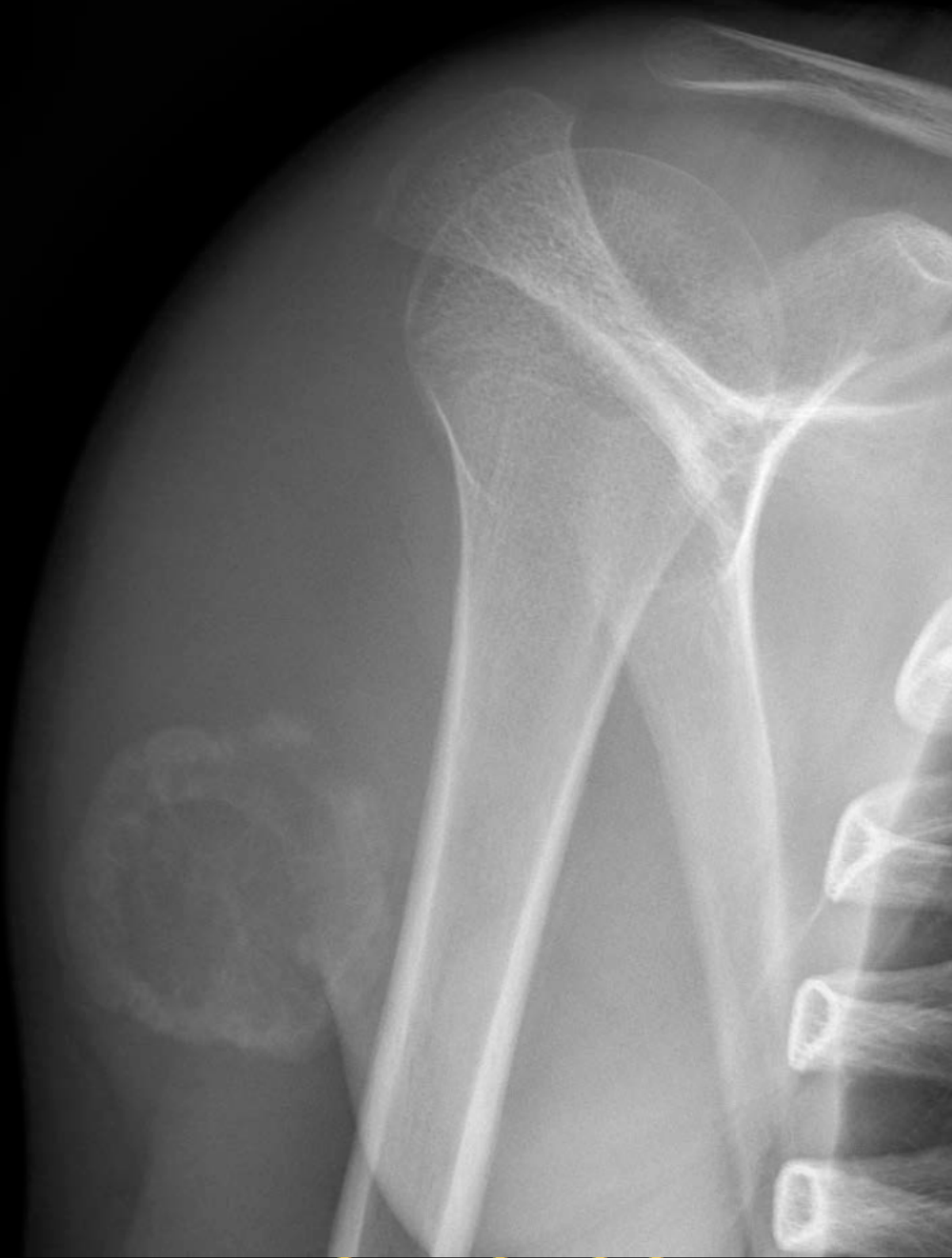
10-16-2015



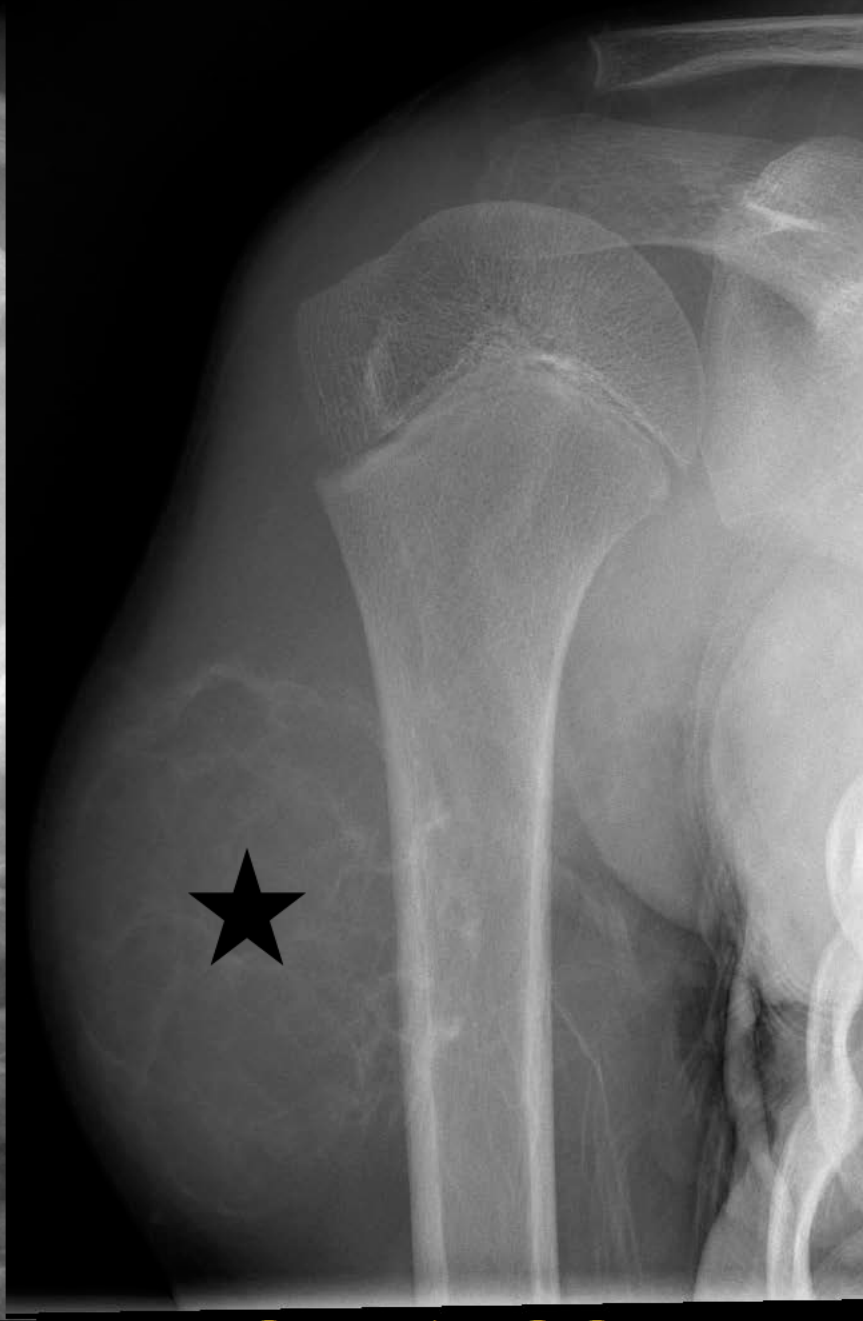
9-18-2015



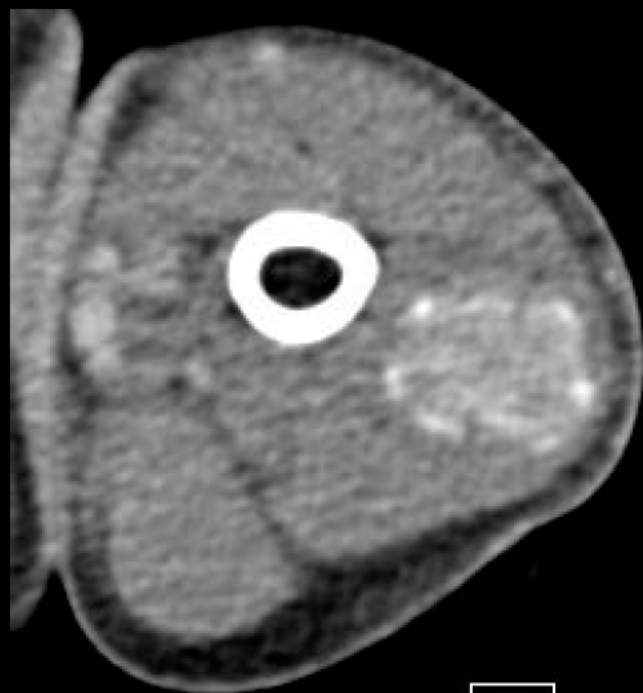
10-16-2015



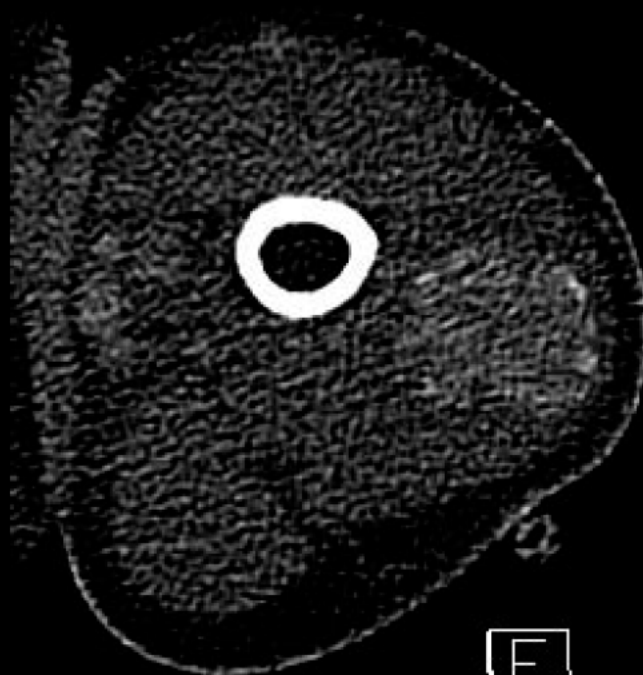
9-18-2015



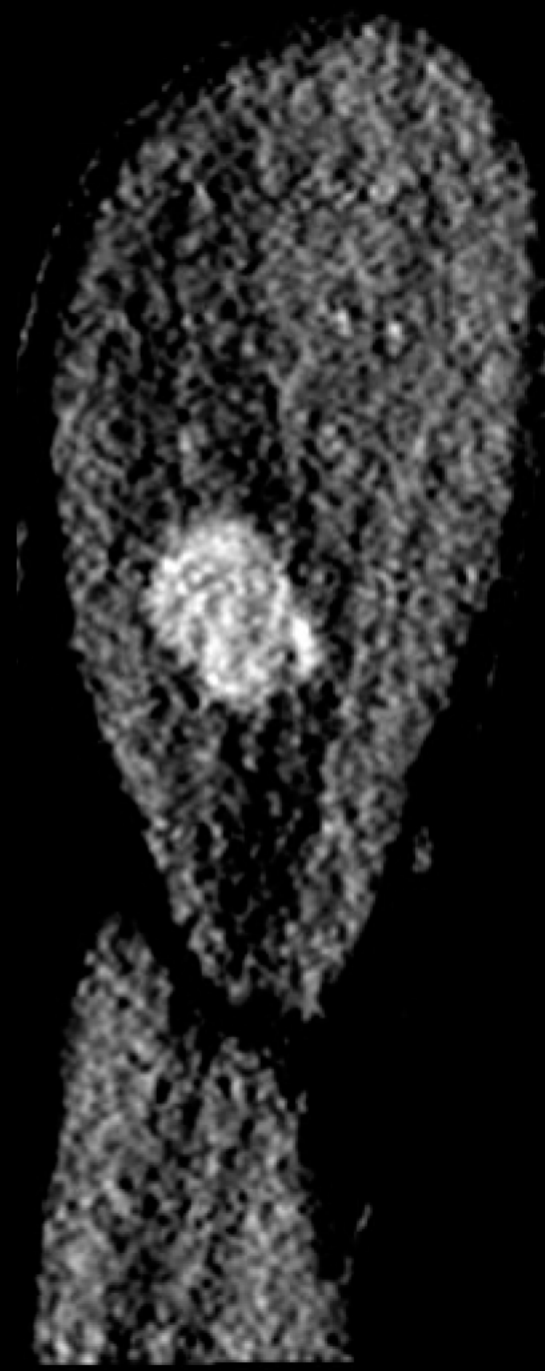
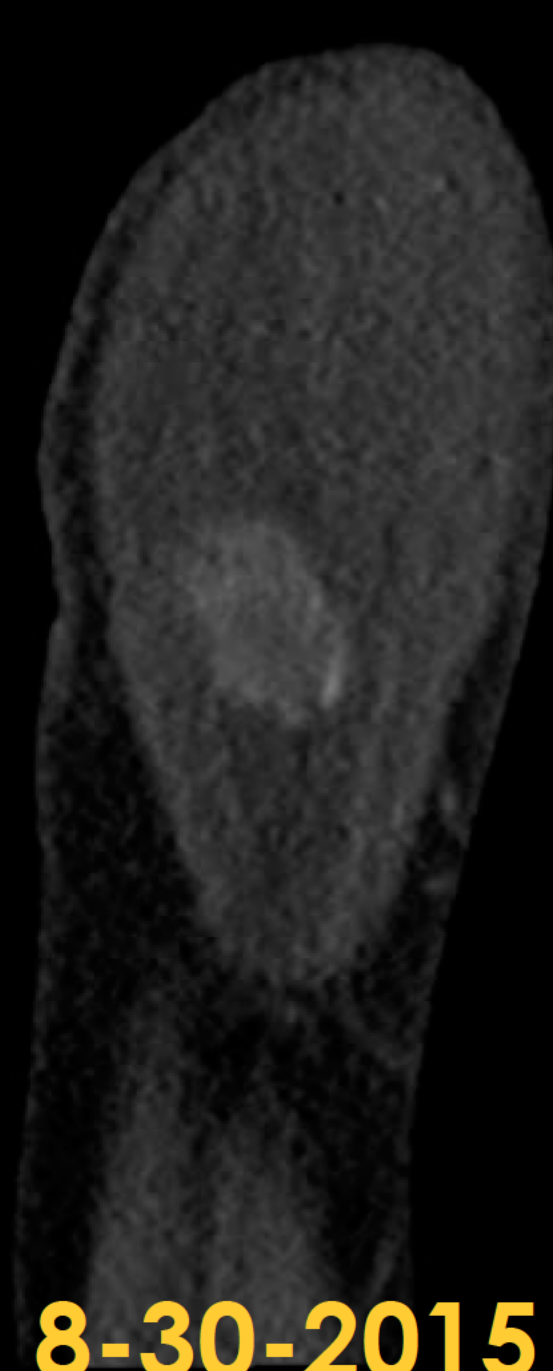
10-16-2015



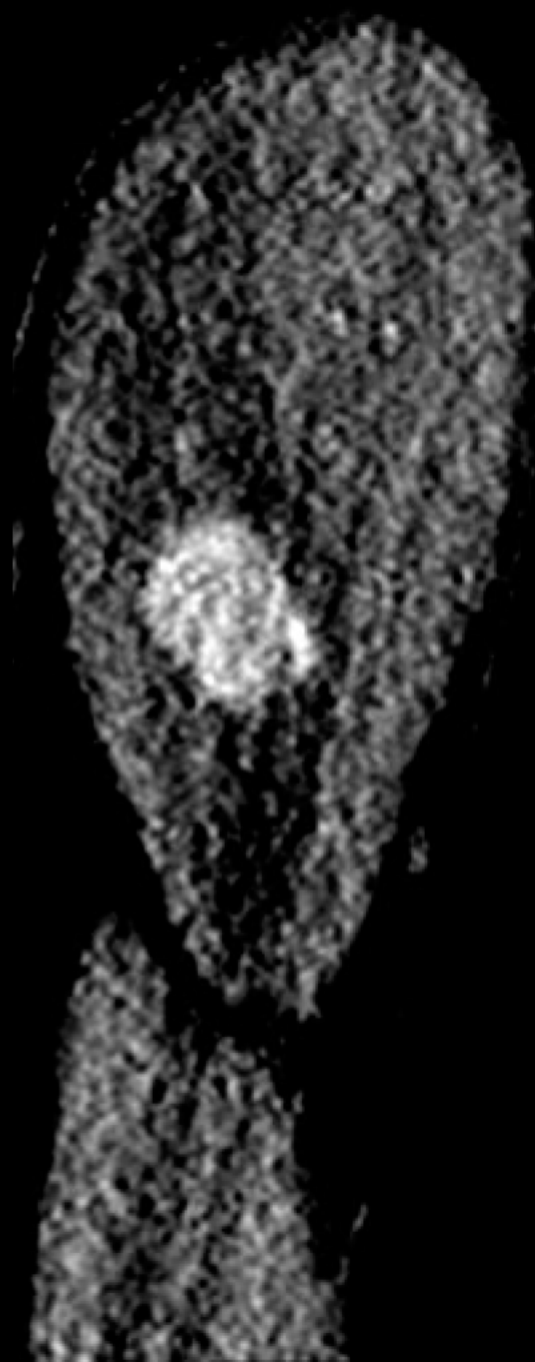
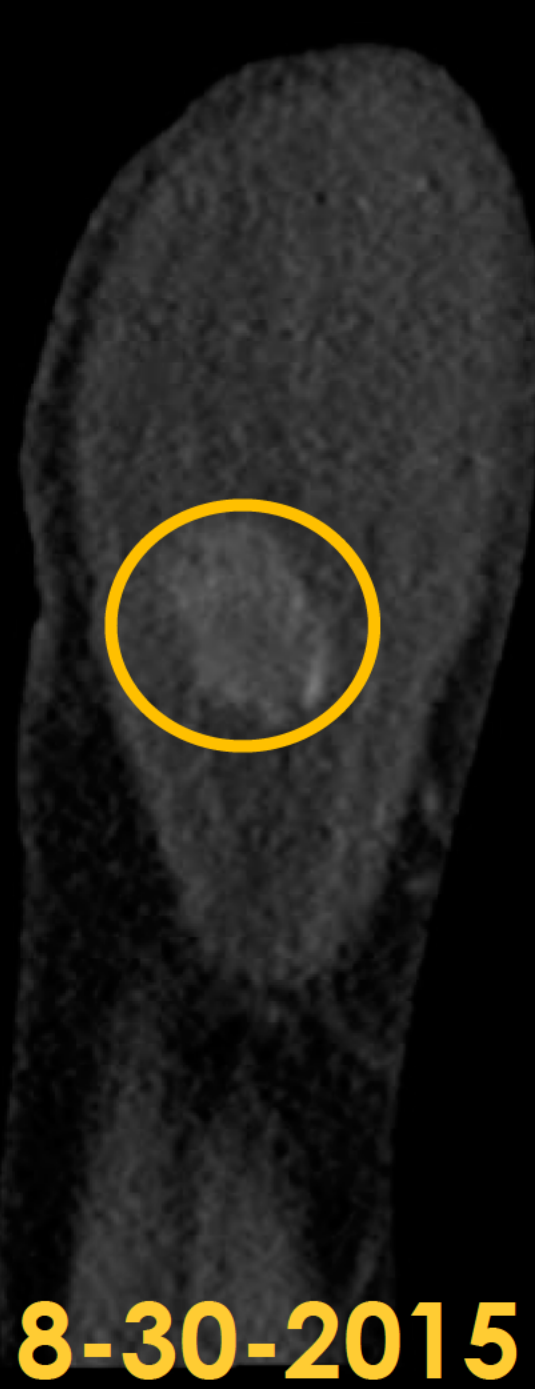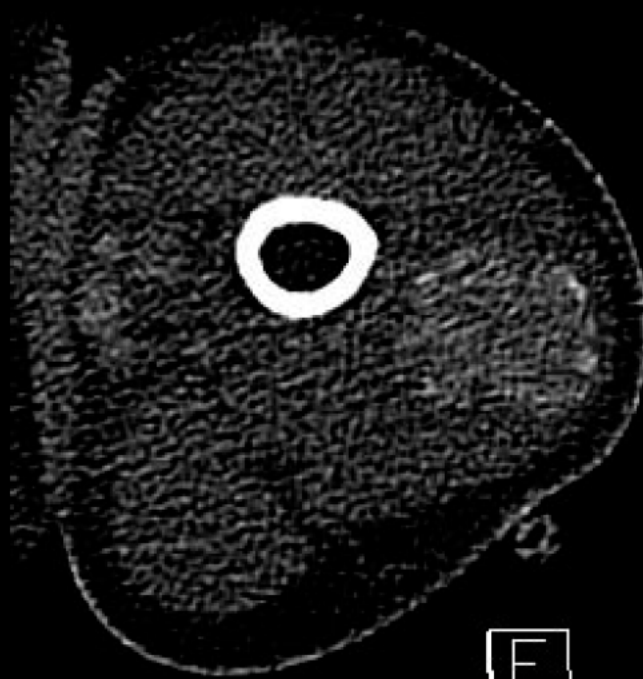
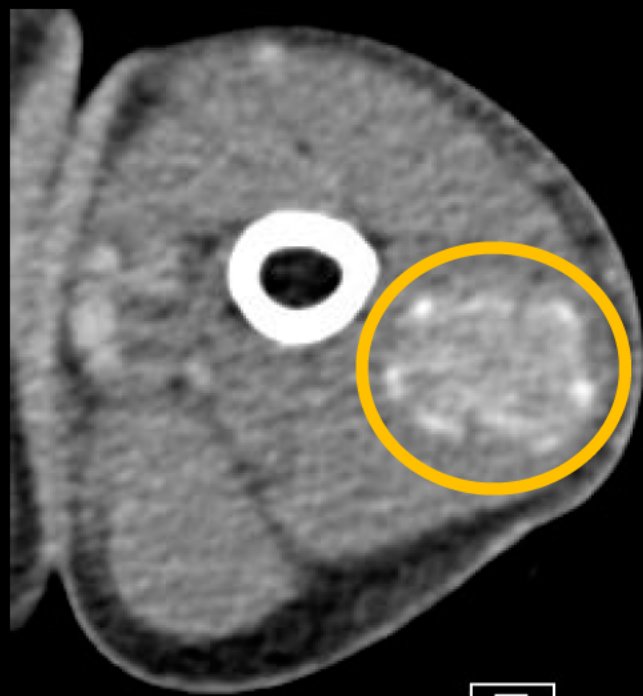[F]

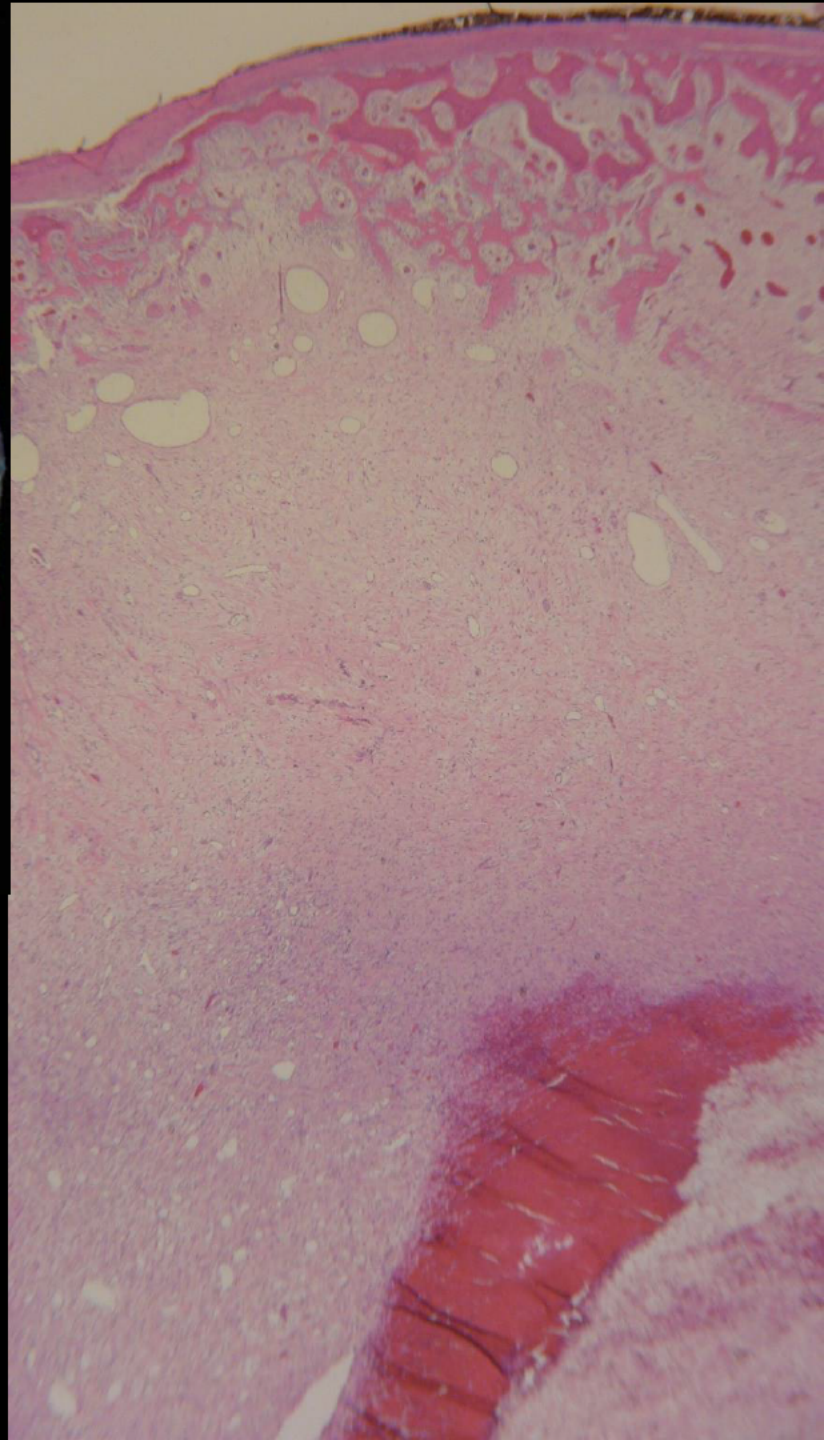
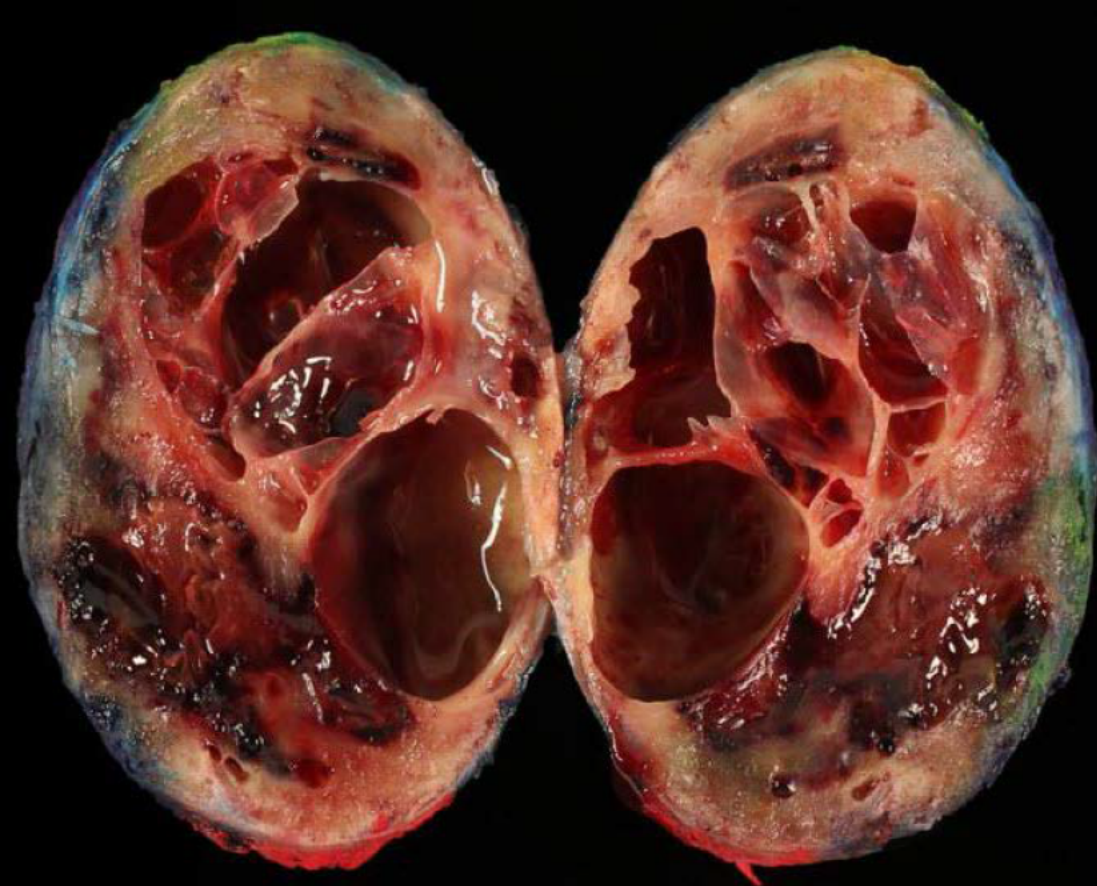


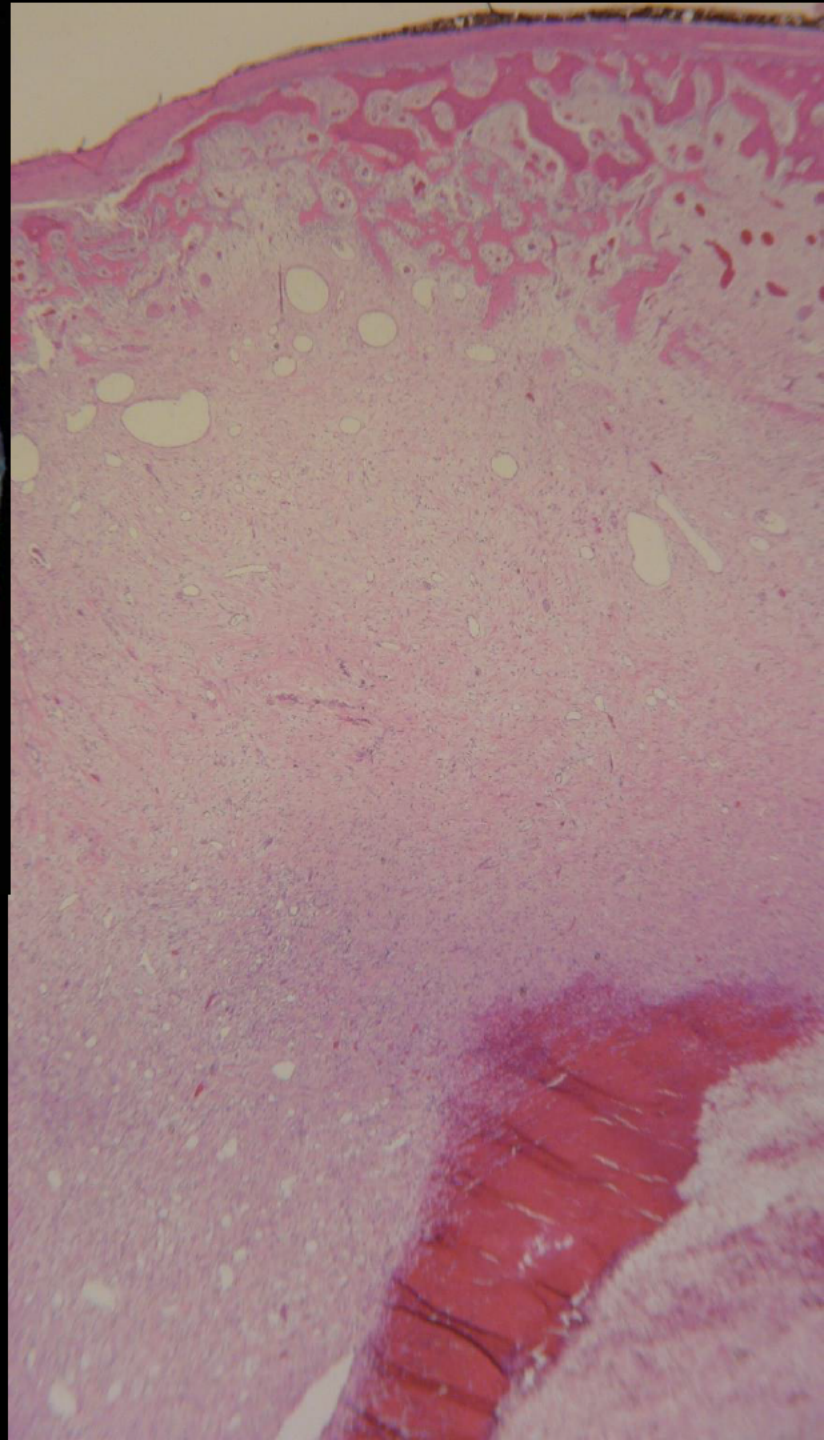
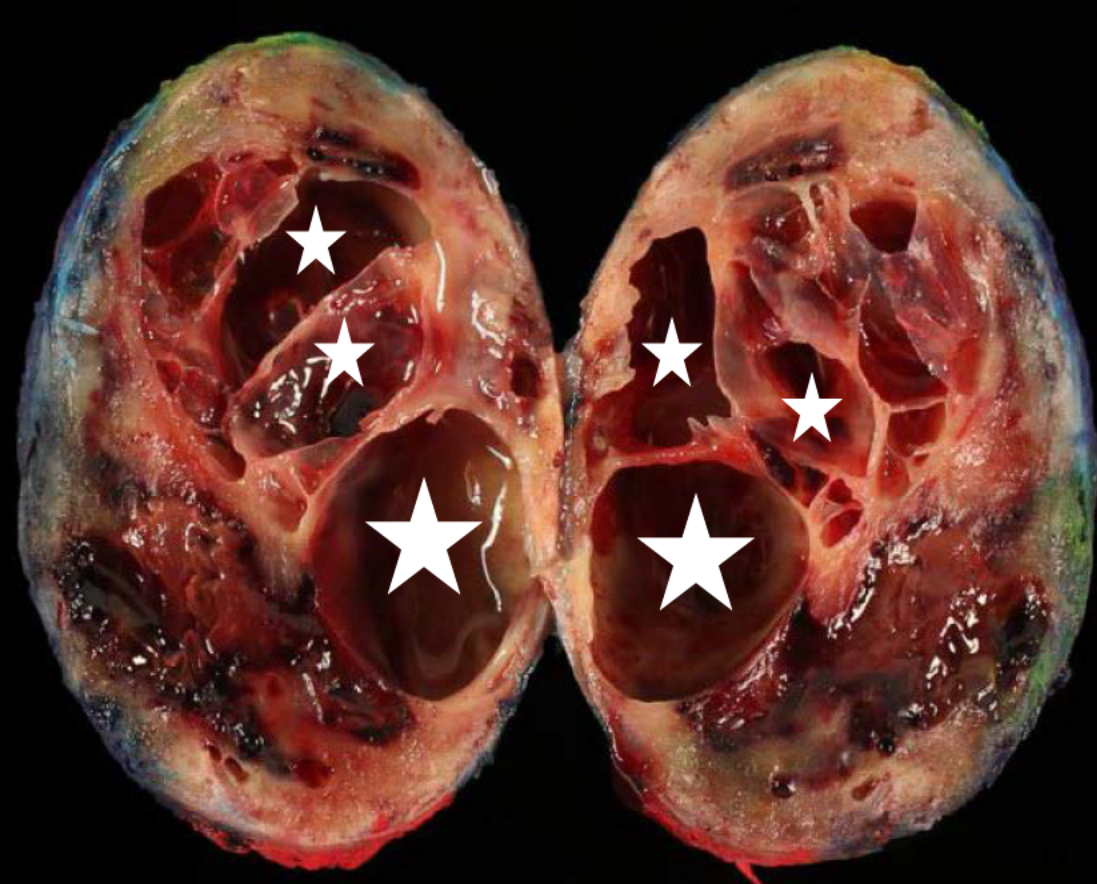
[F]

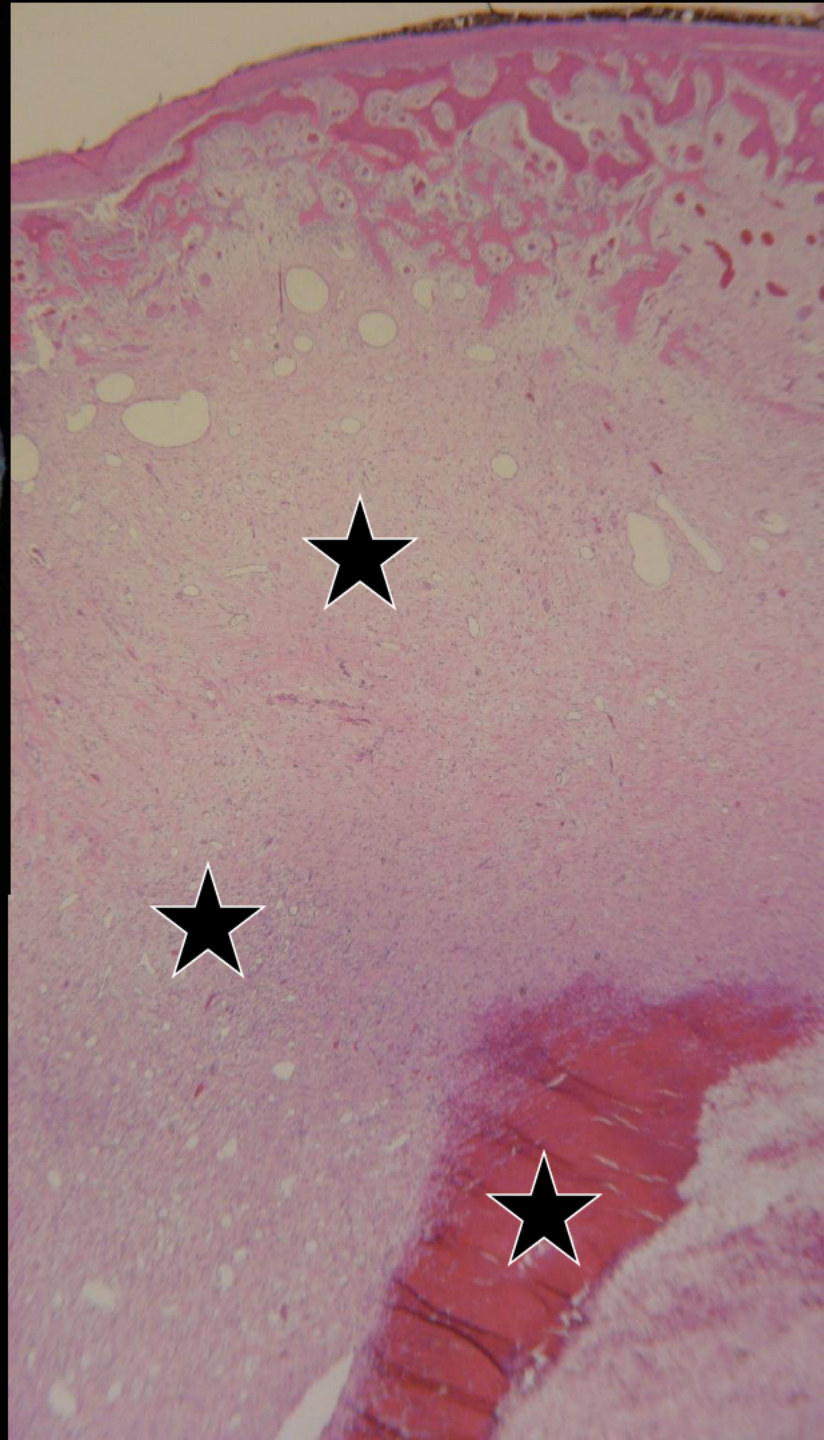
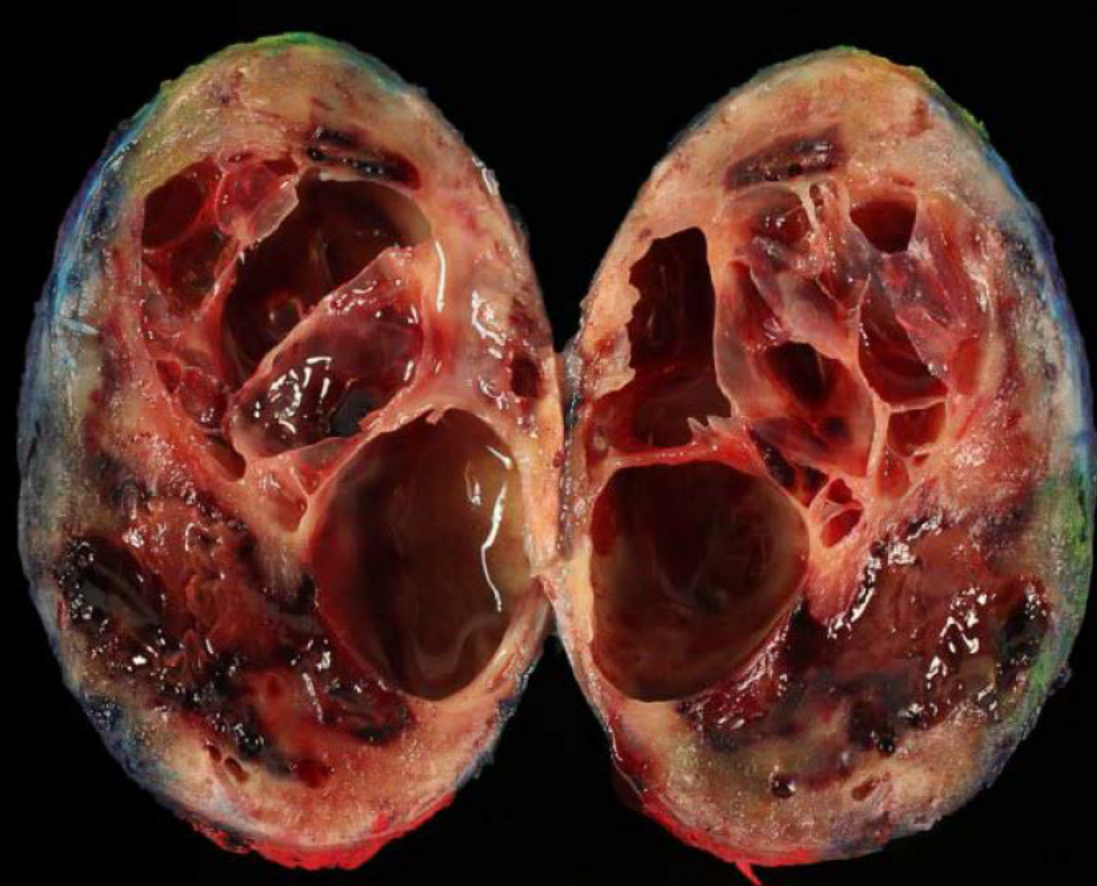


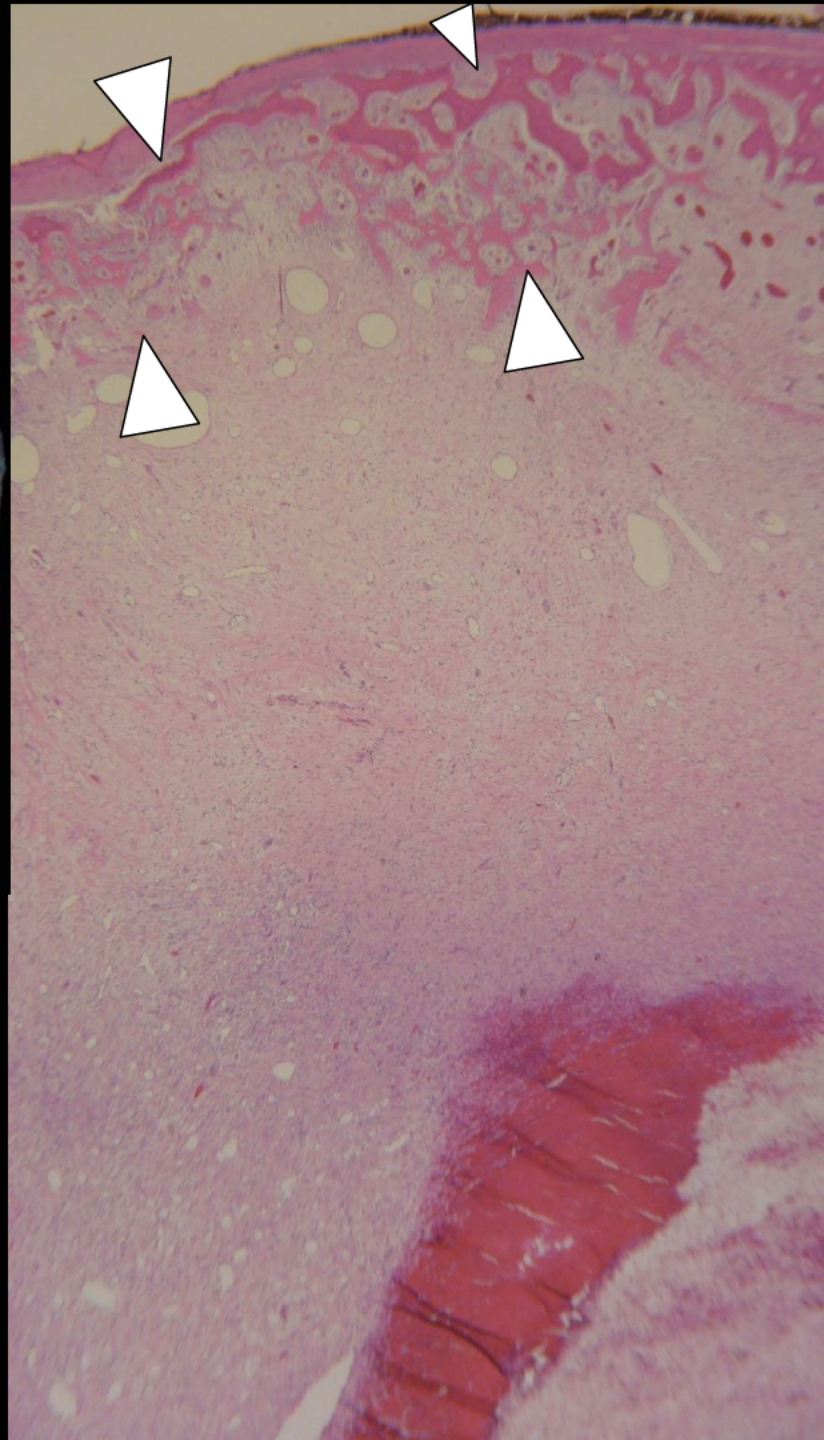
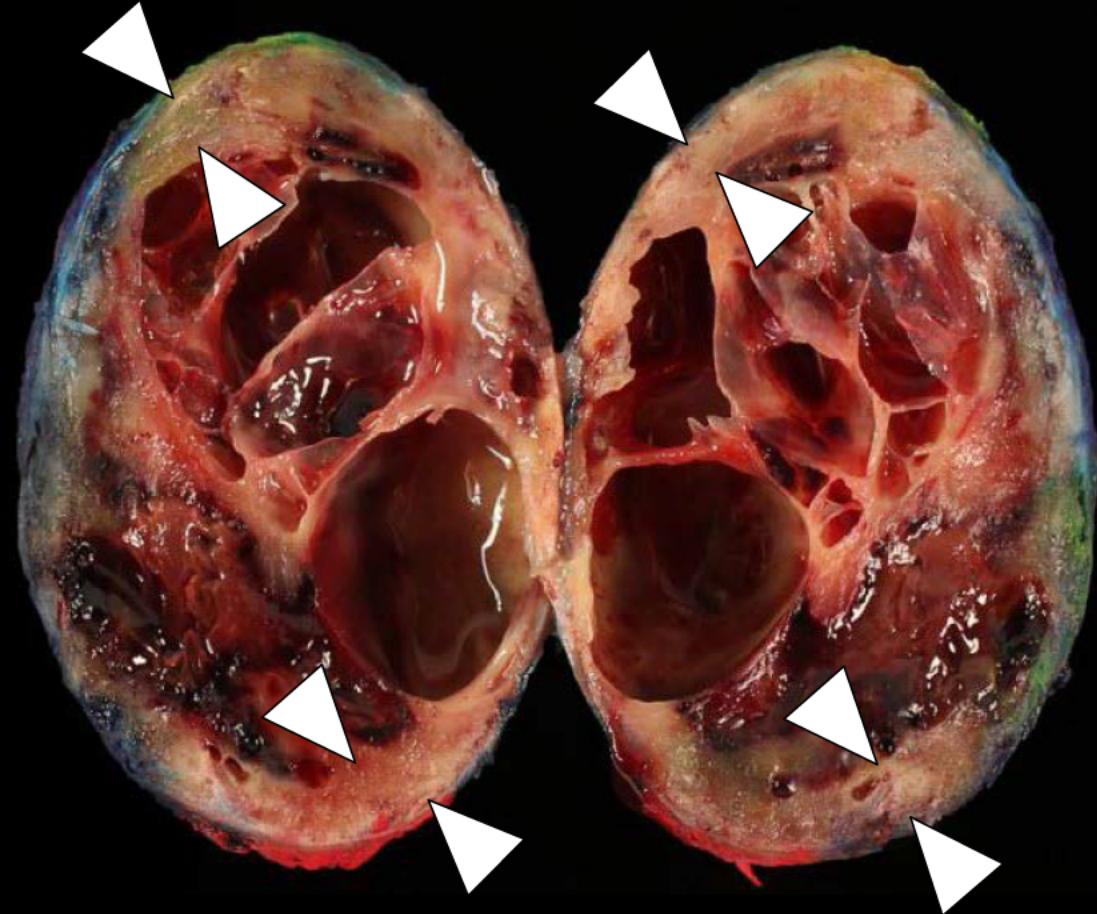
8-30-2015

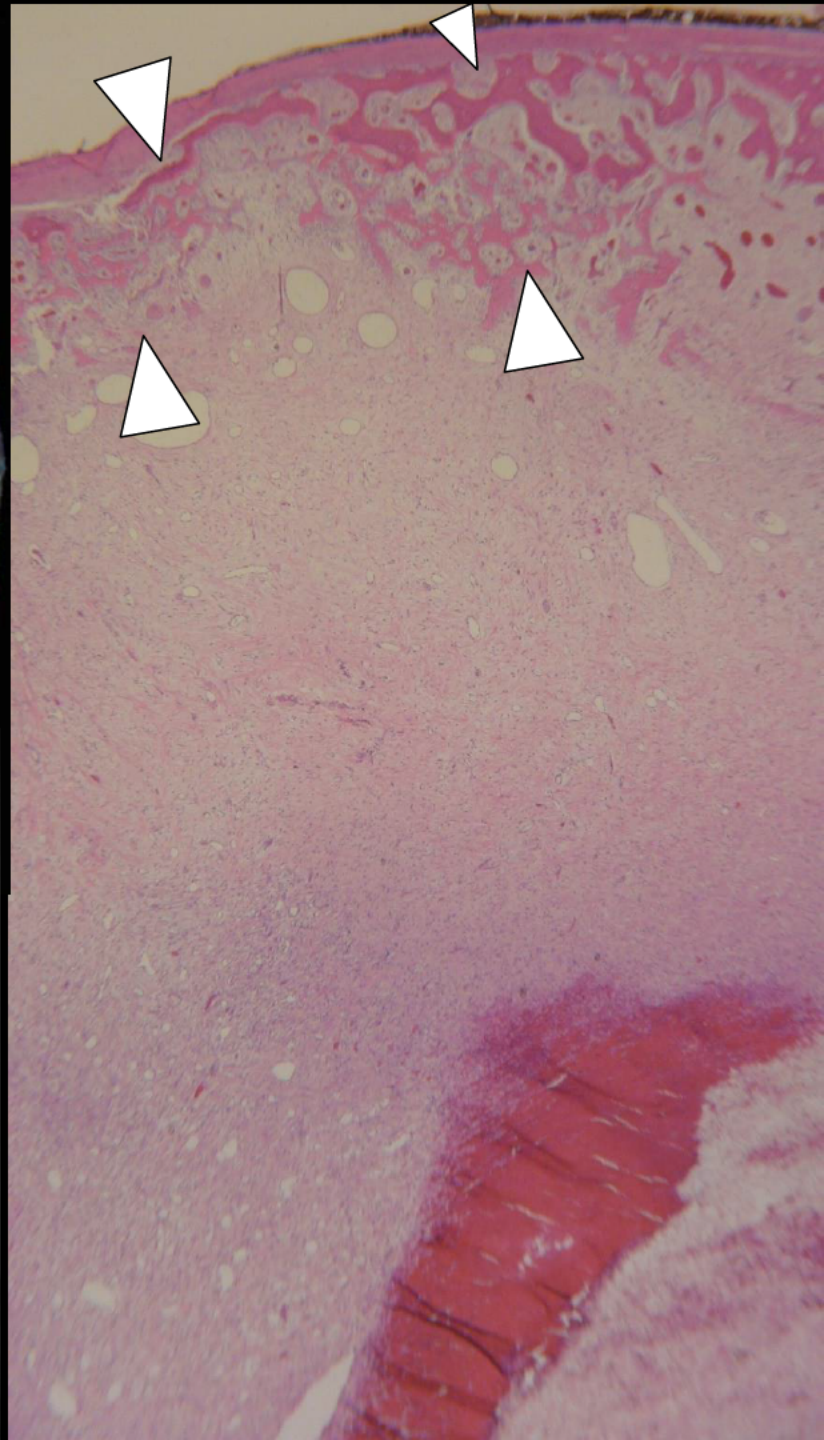
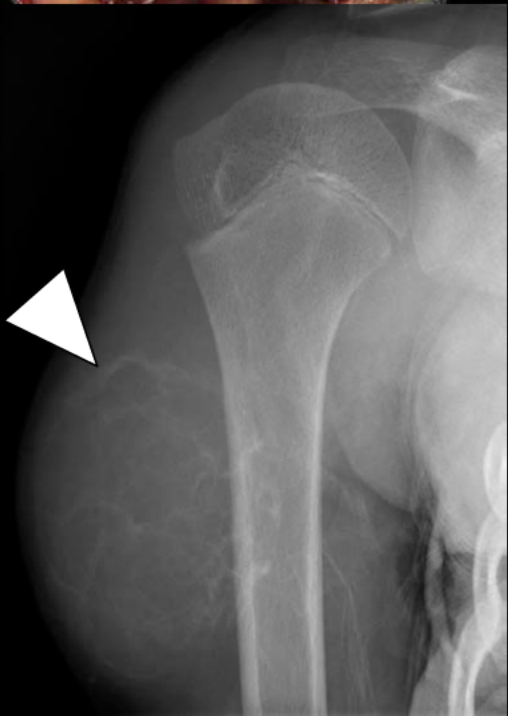
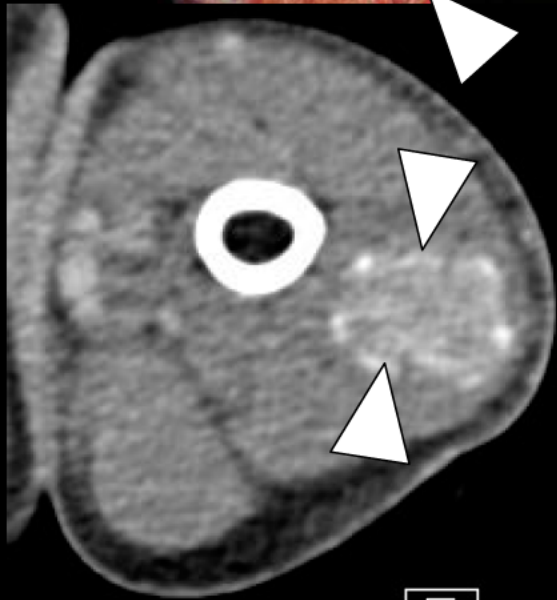
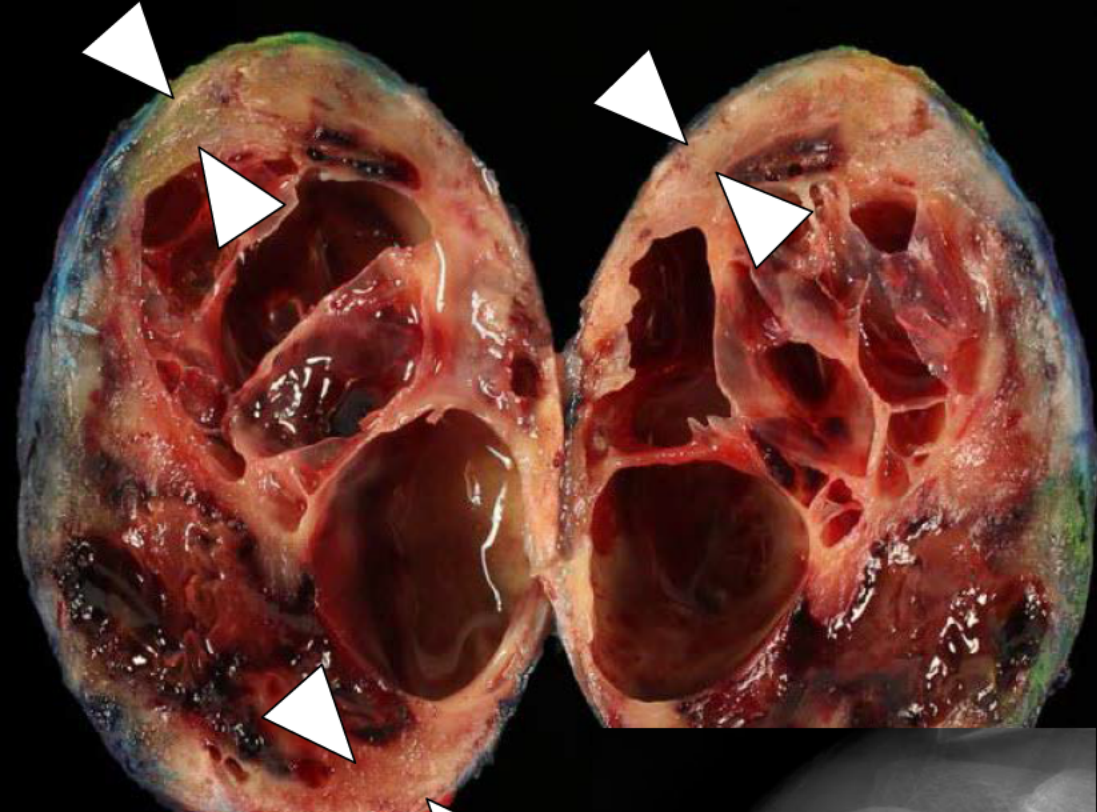








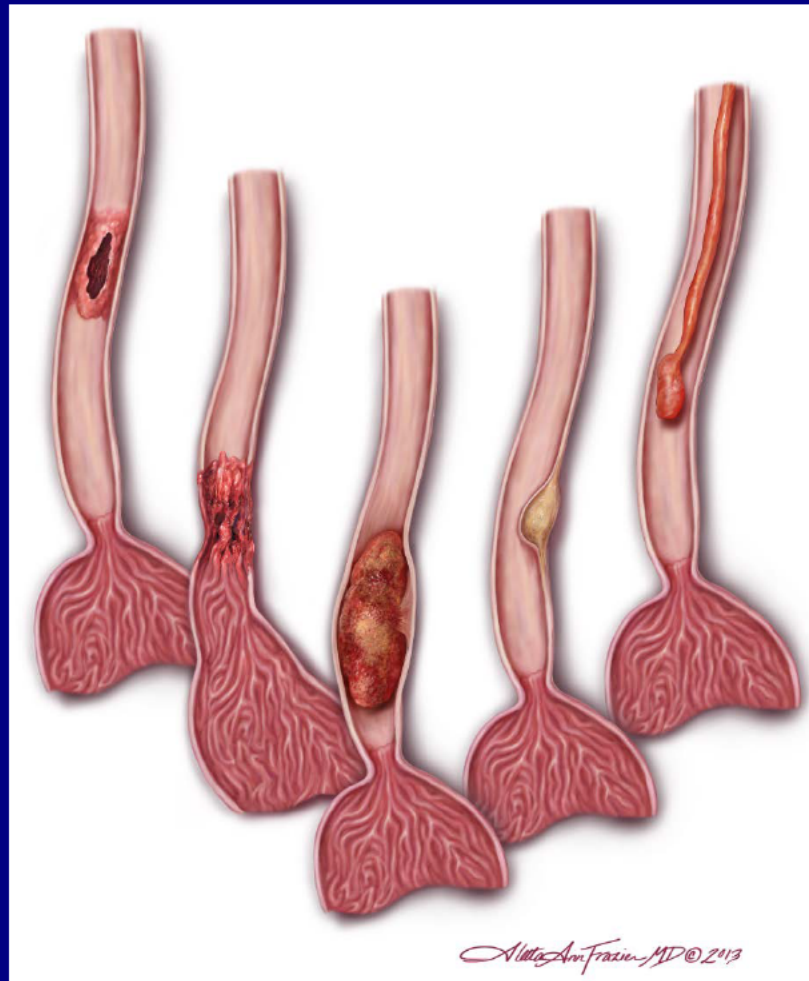



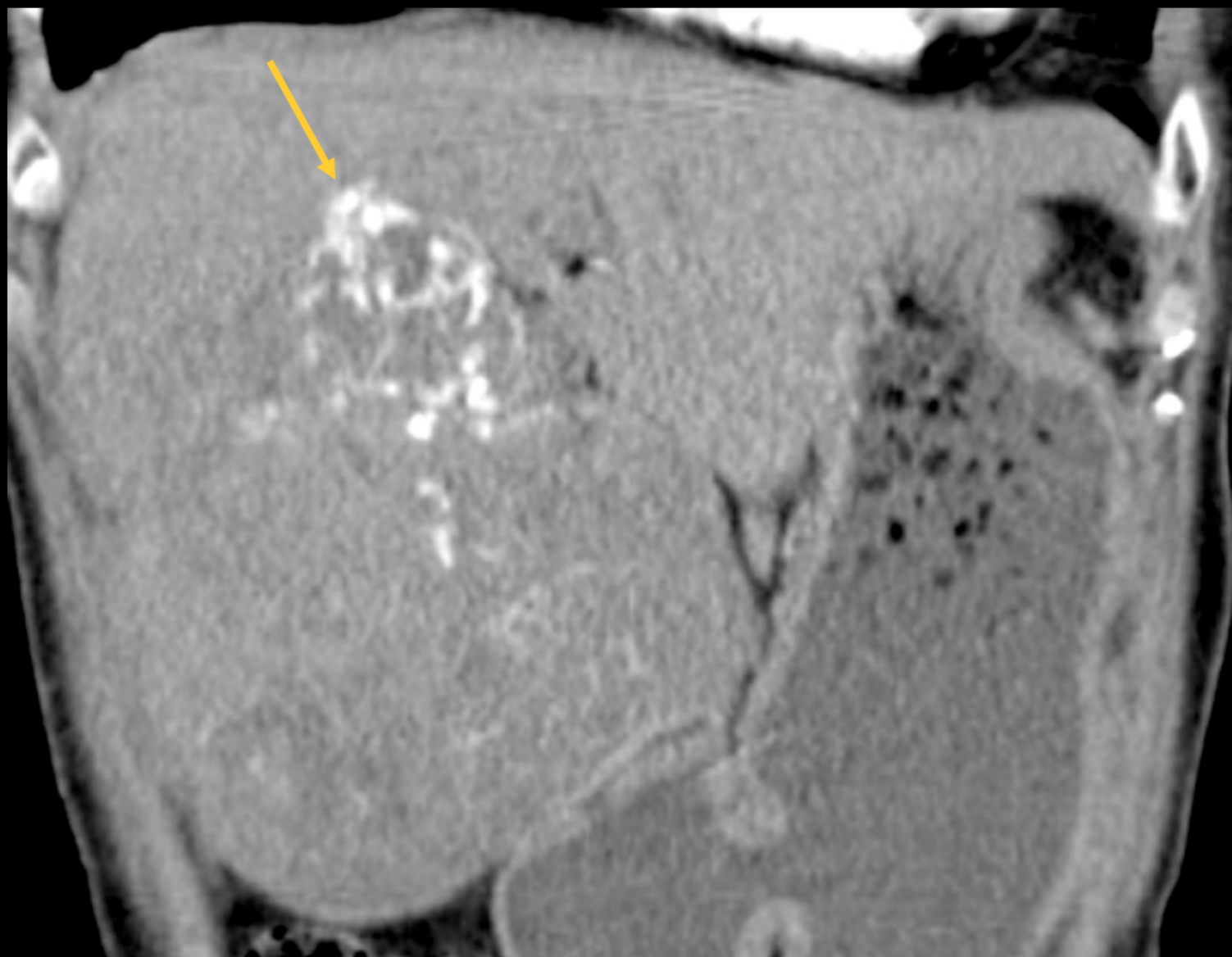
Myositis Ossificans

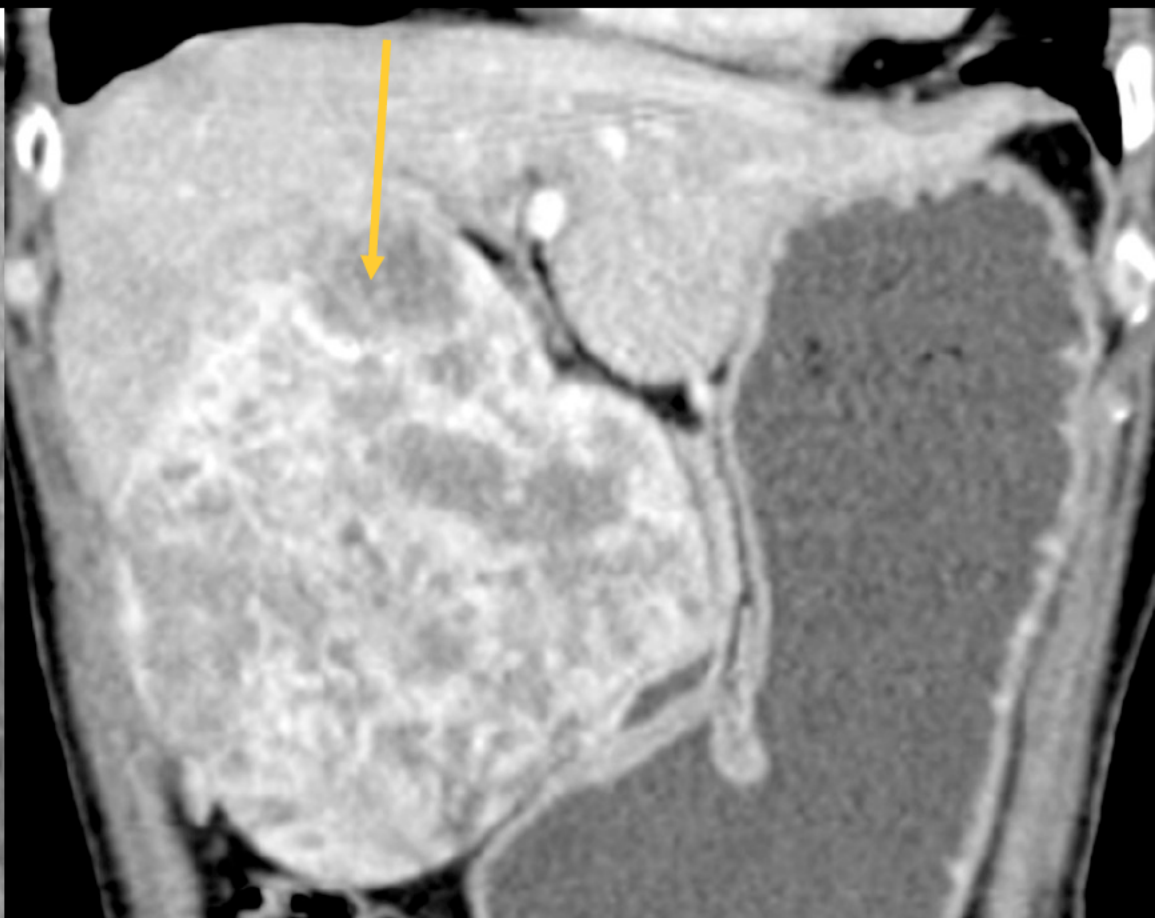
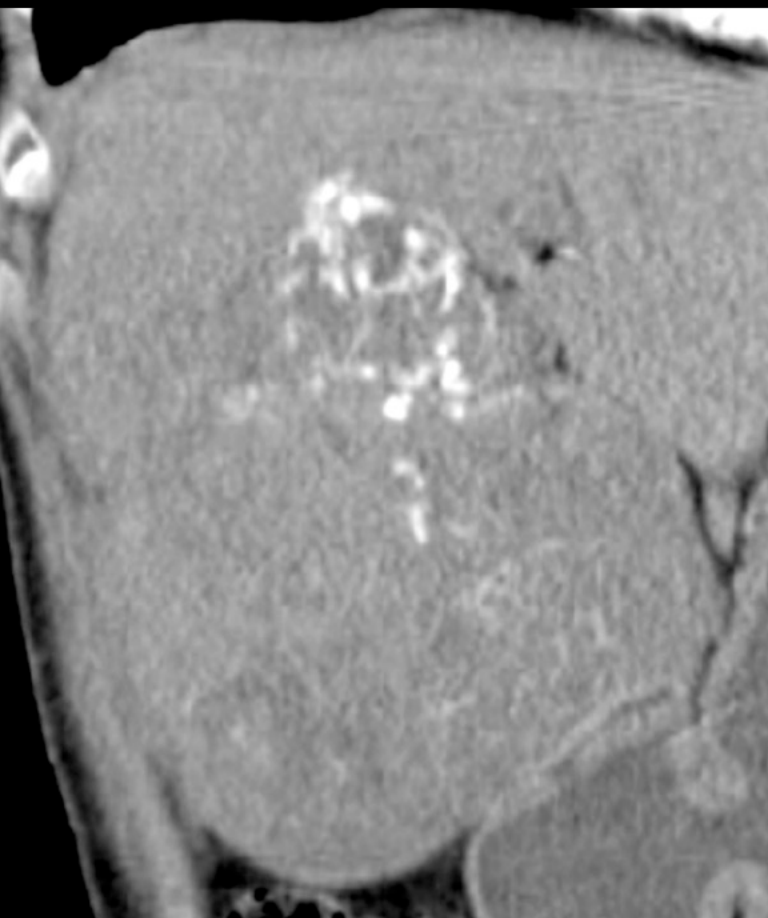
Luke Chambless, MD
Baylor Scott and White
Temple, Texas

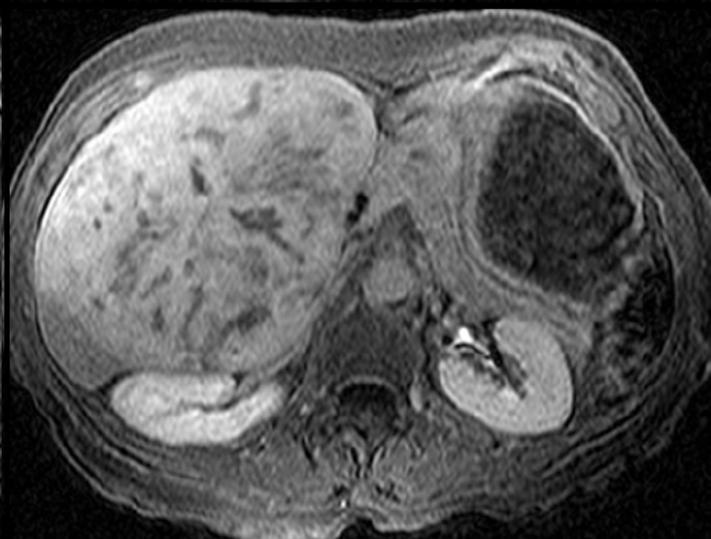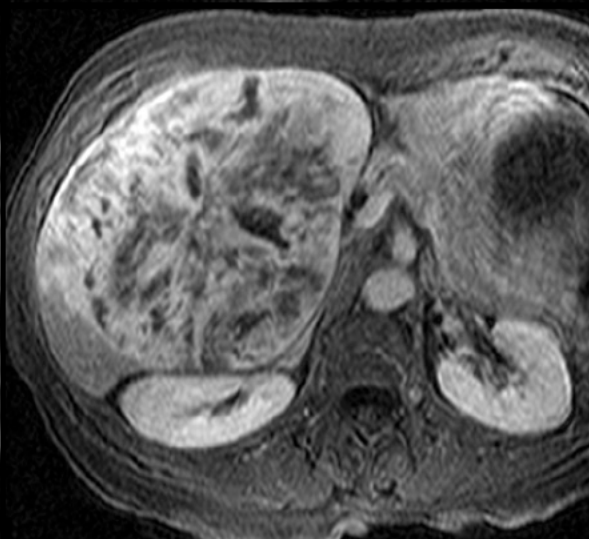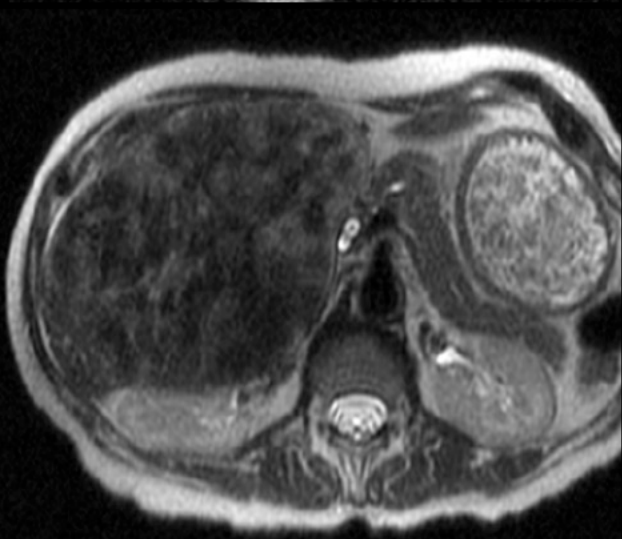
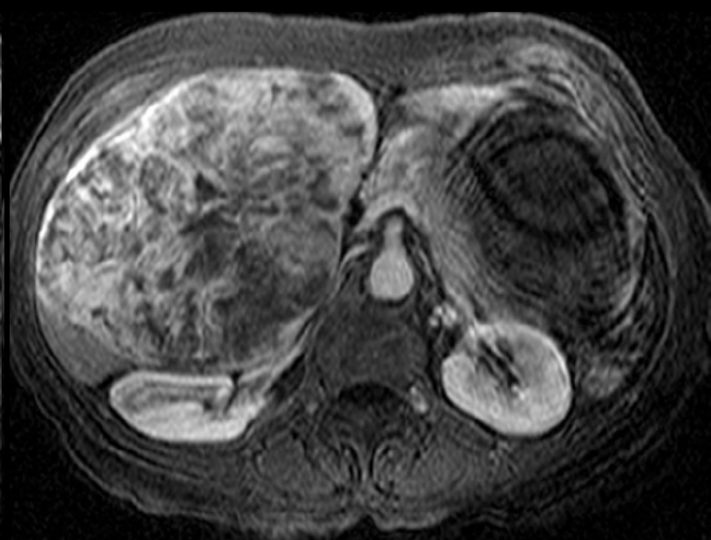
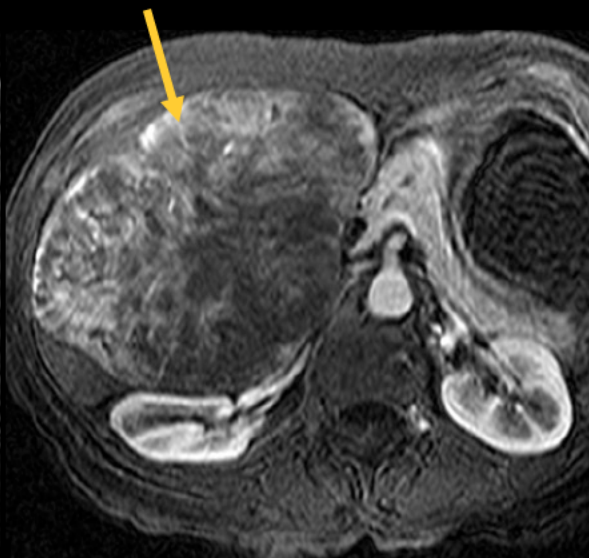
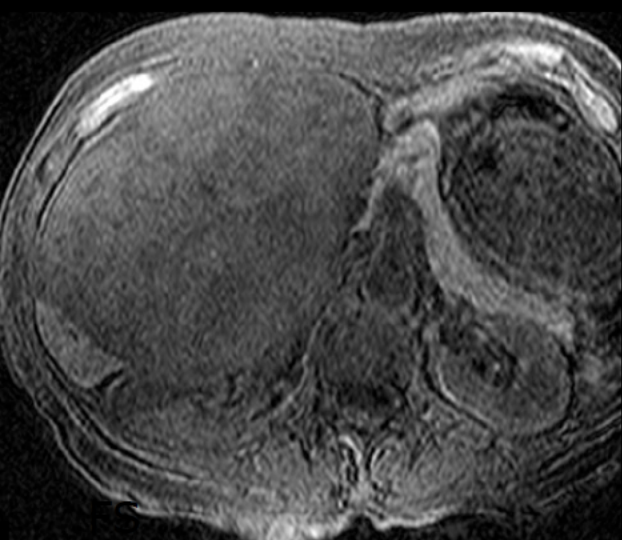
Gastrointestinal Best Case

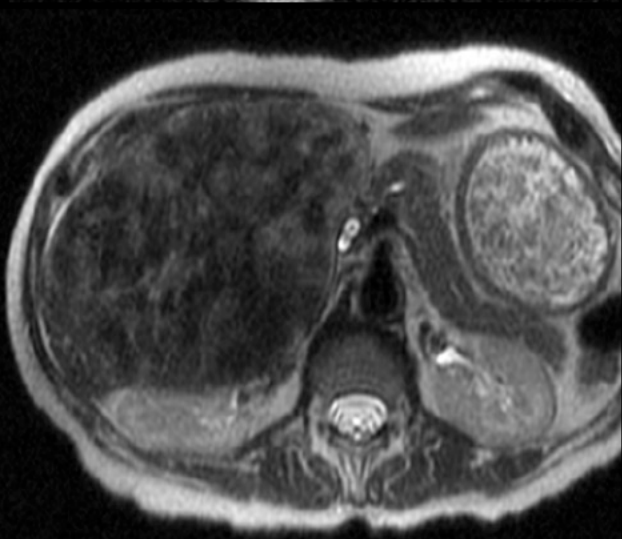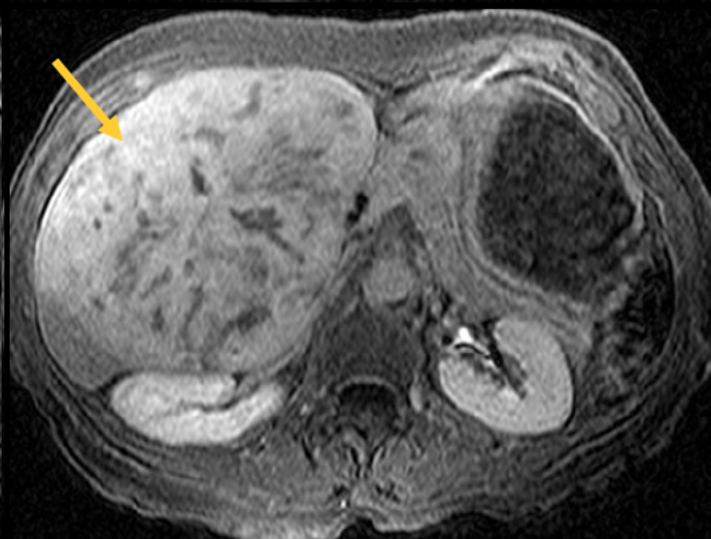
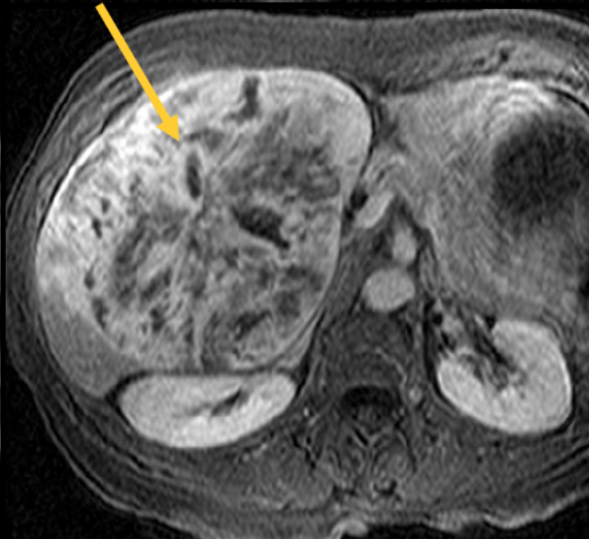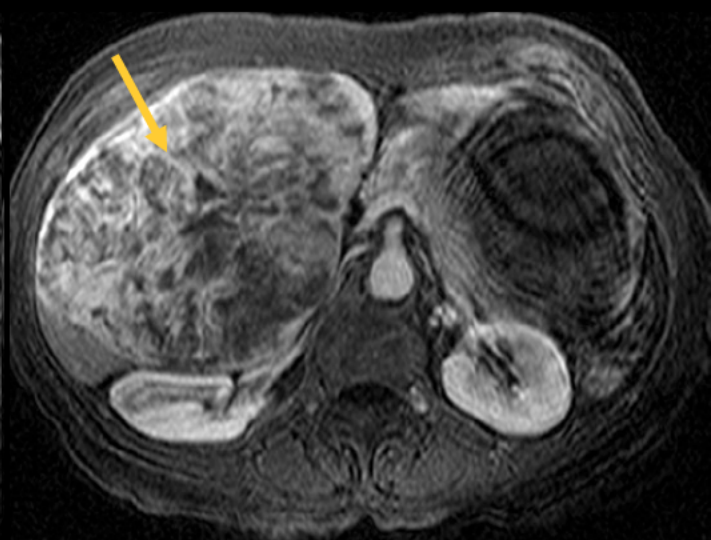
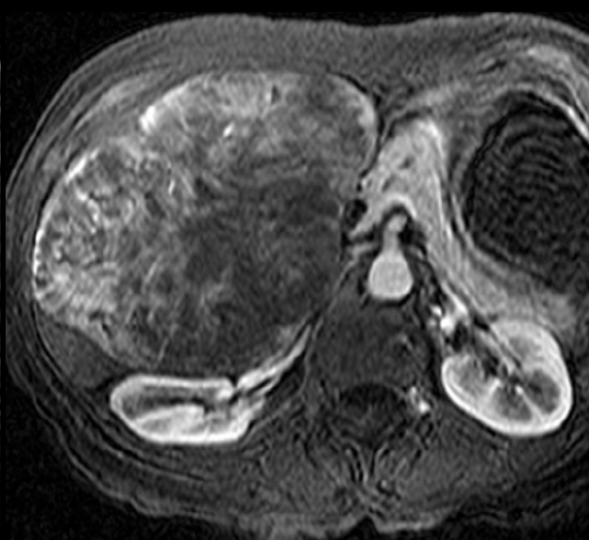
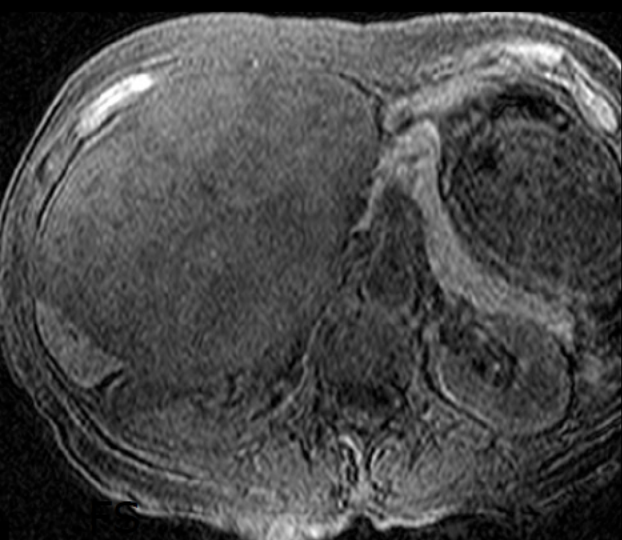


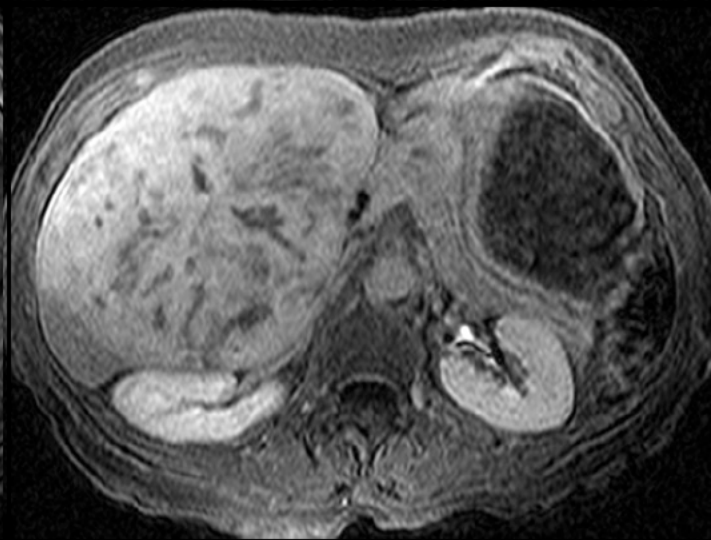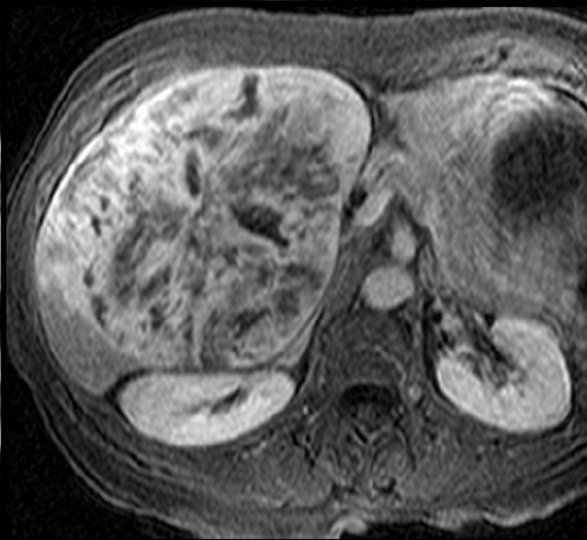
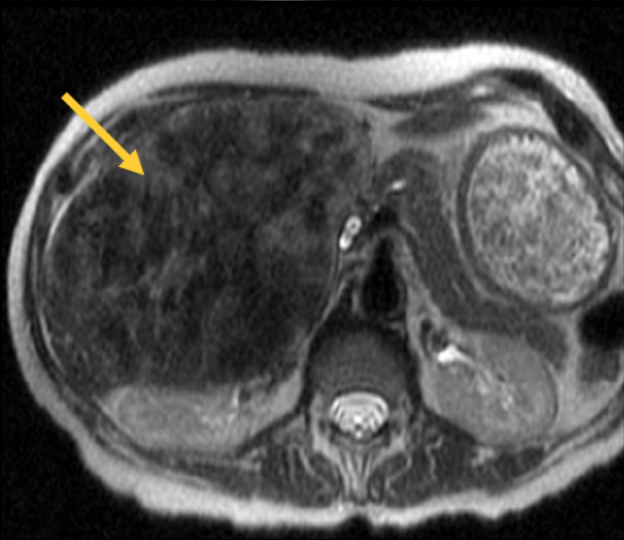
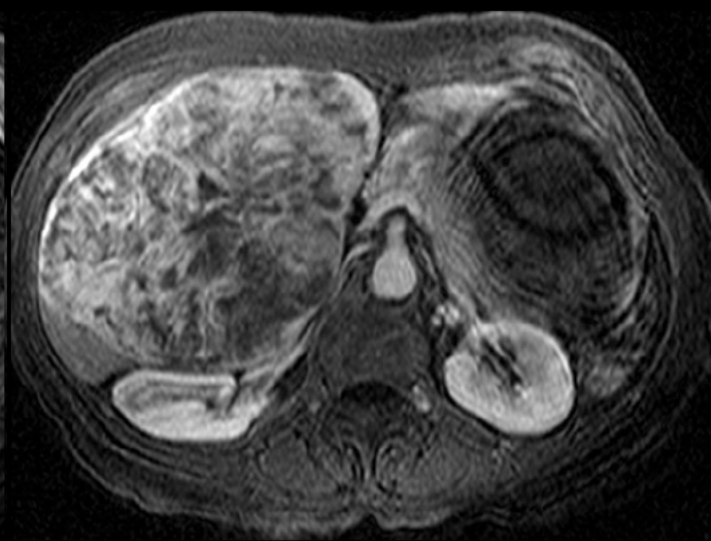
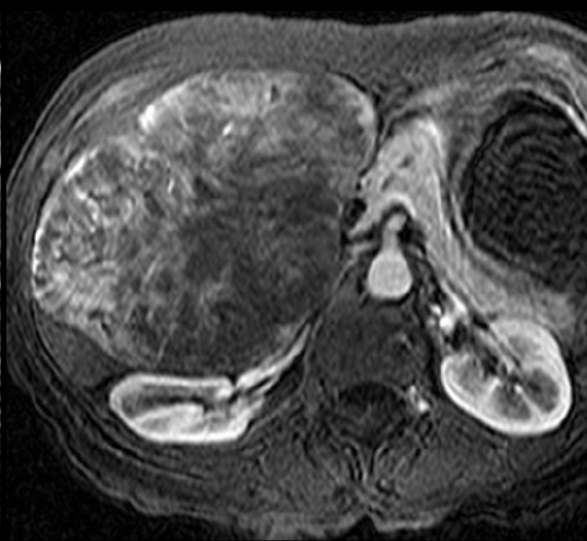
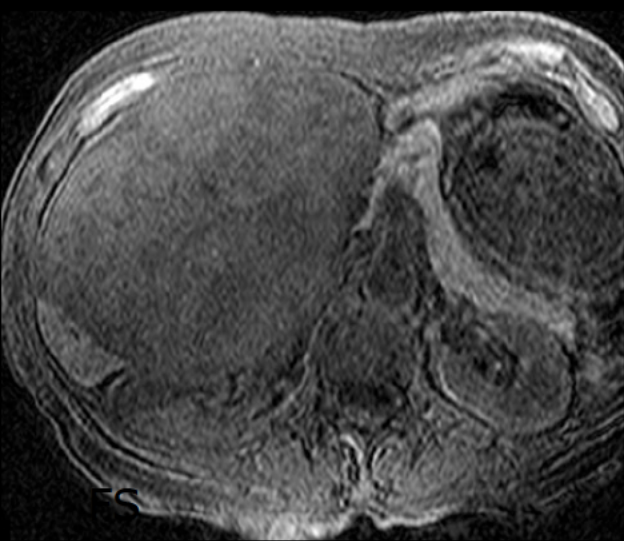
68 year old woman with incidentally found hepatic tumor

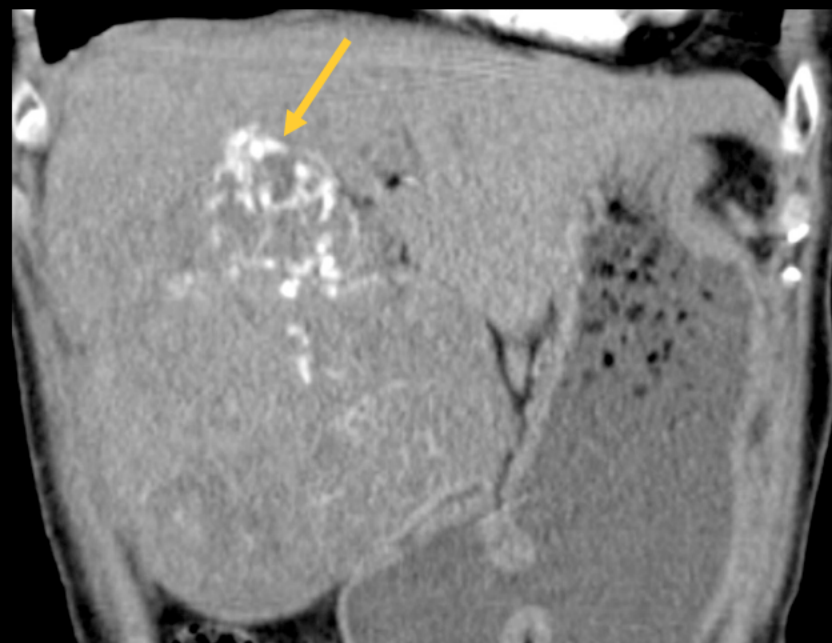
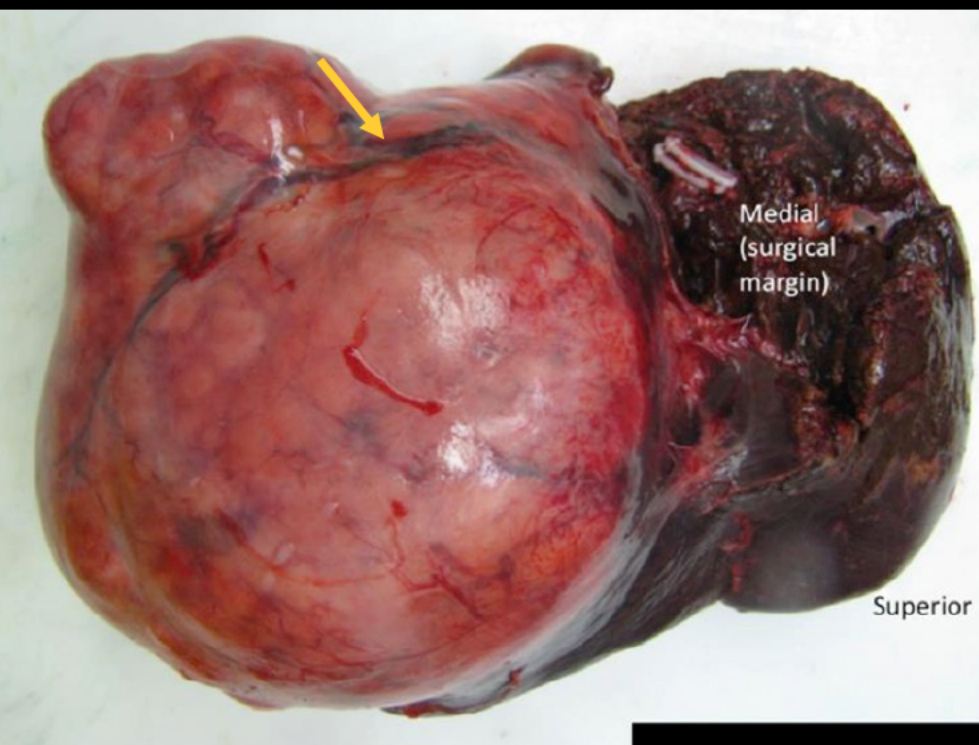


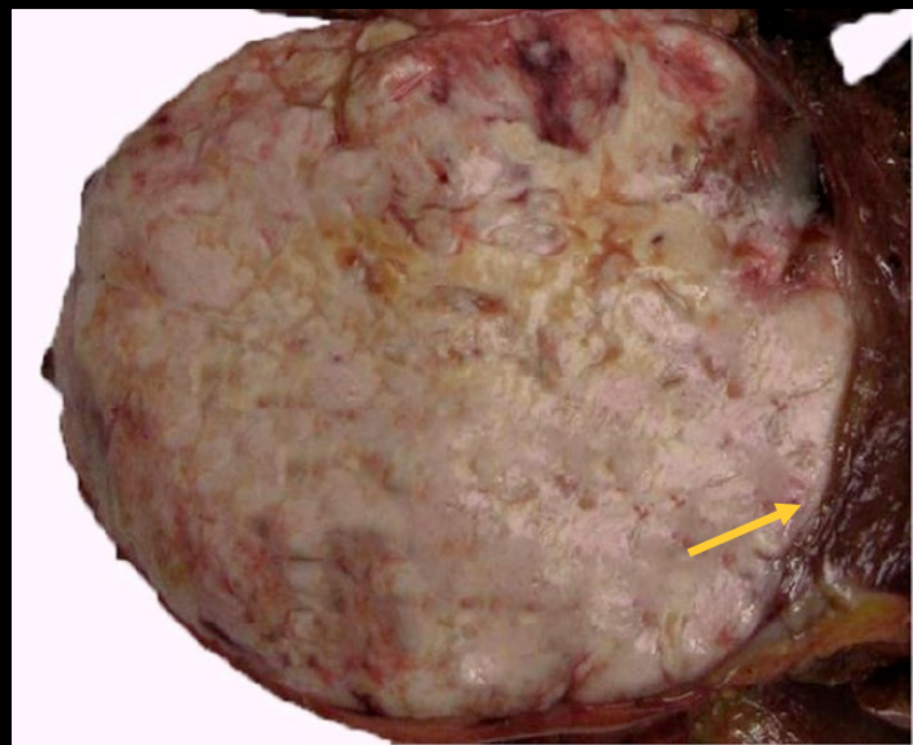
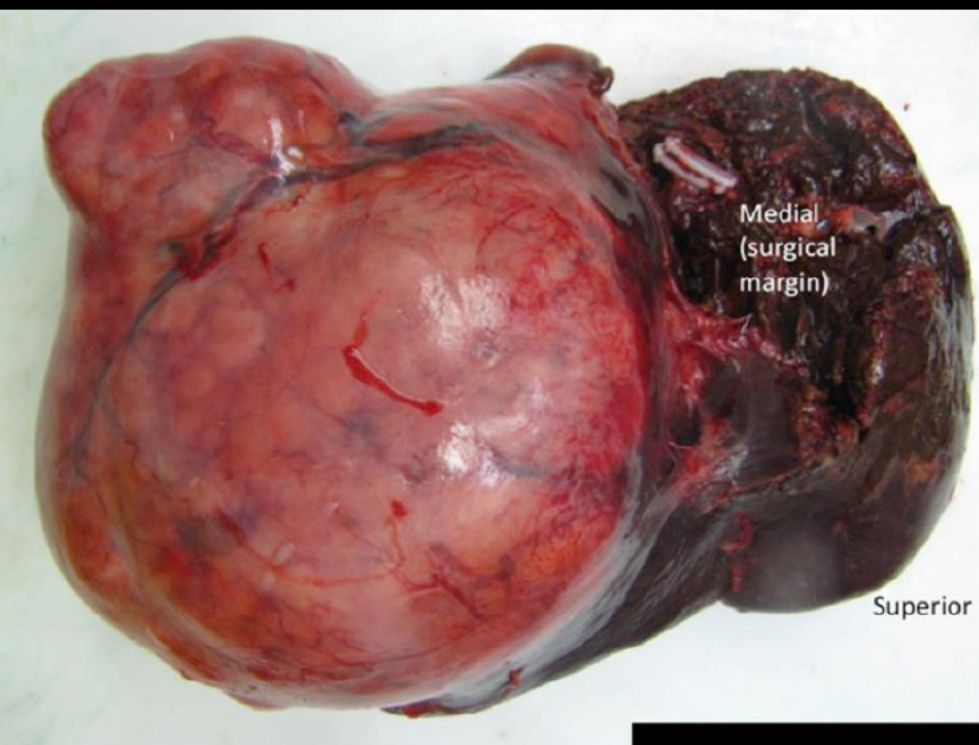


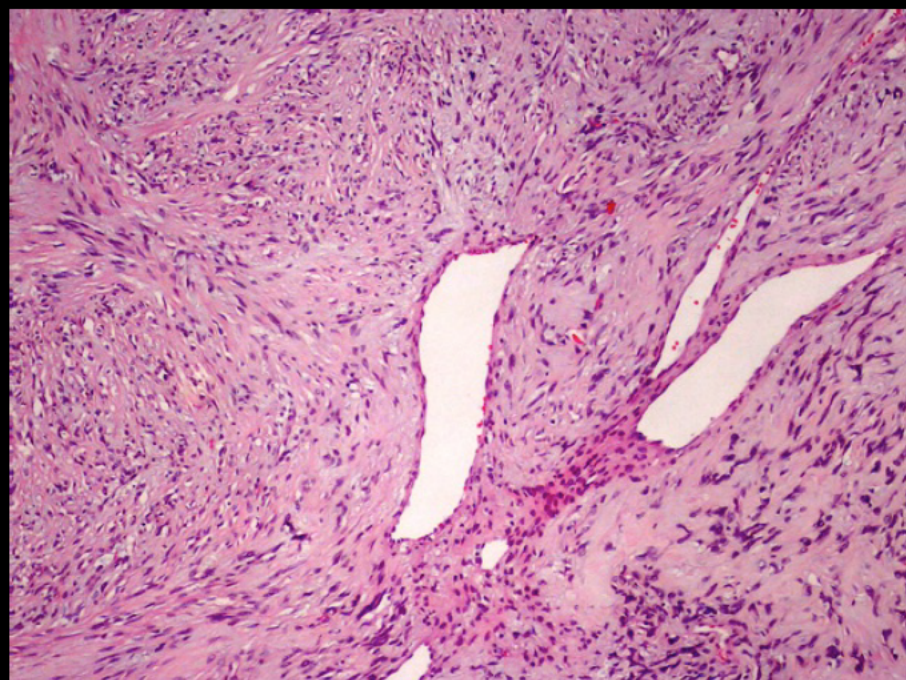
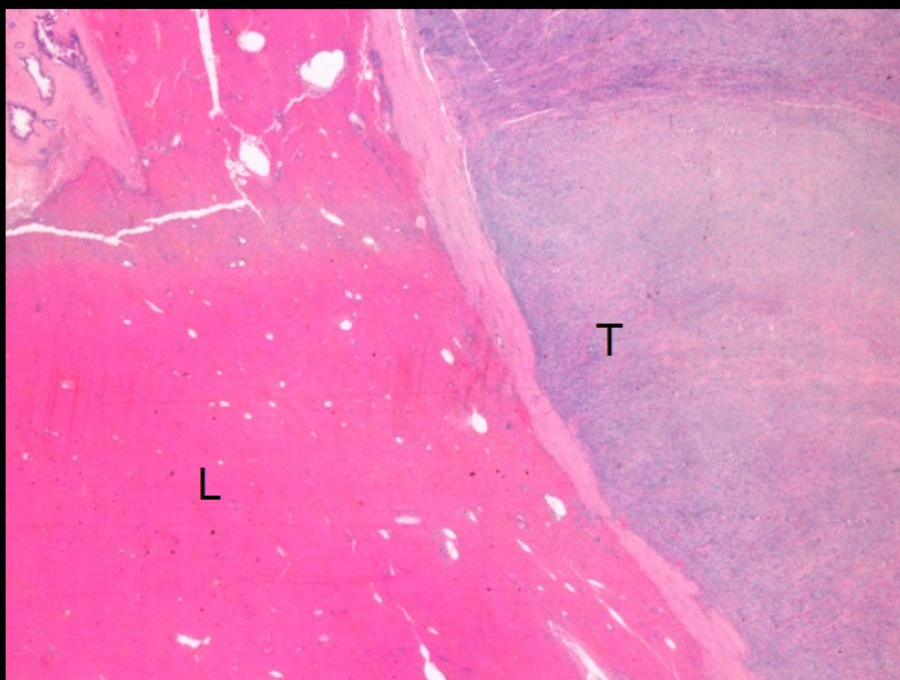


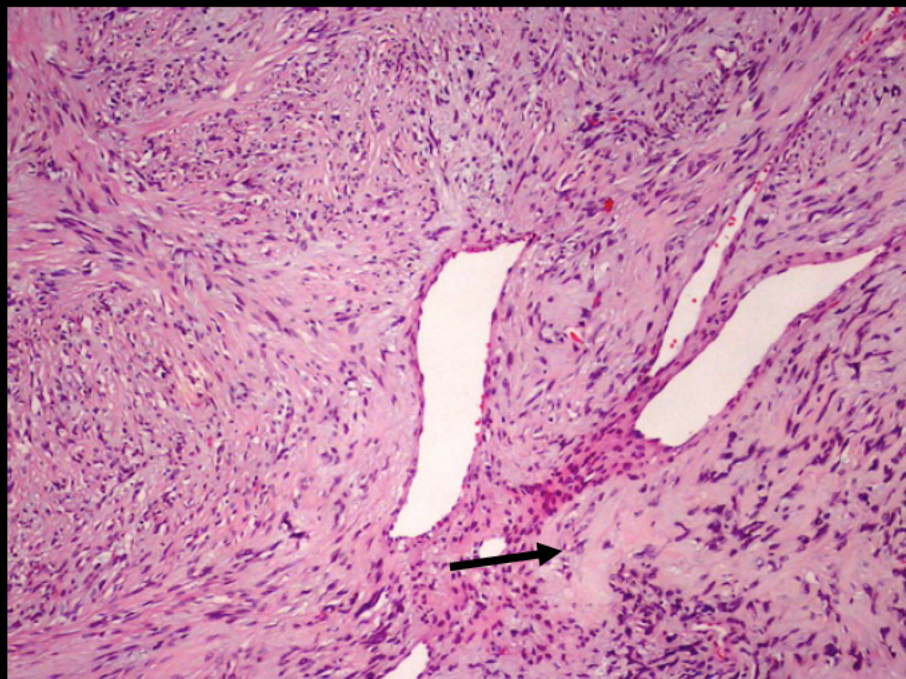
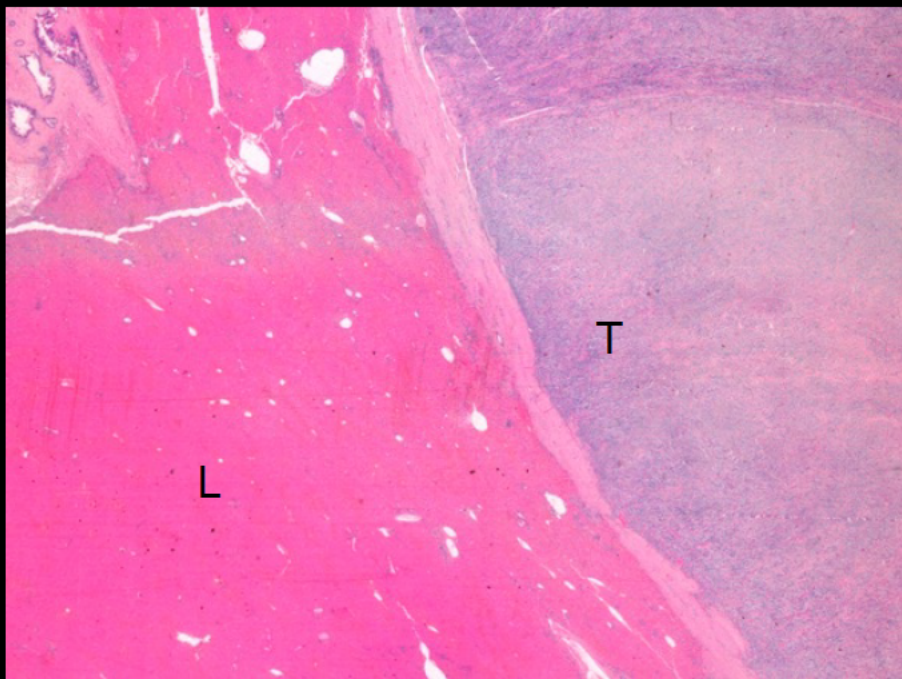


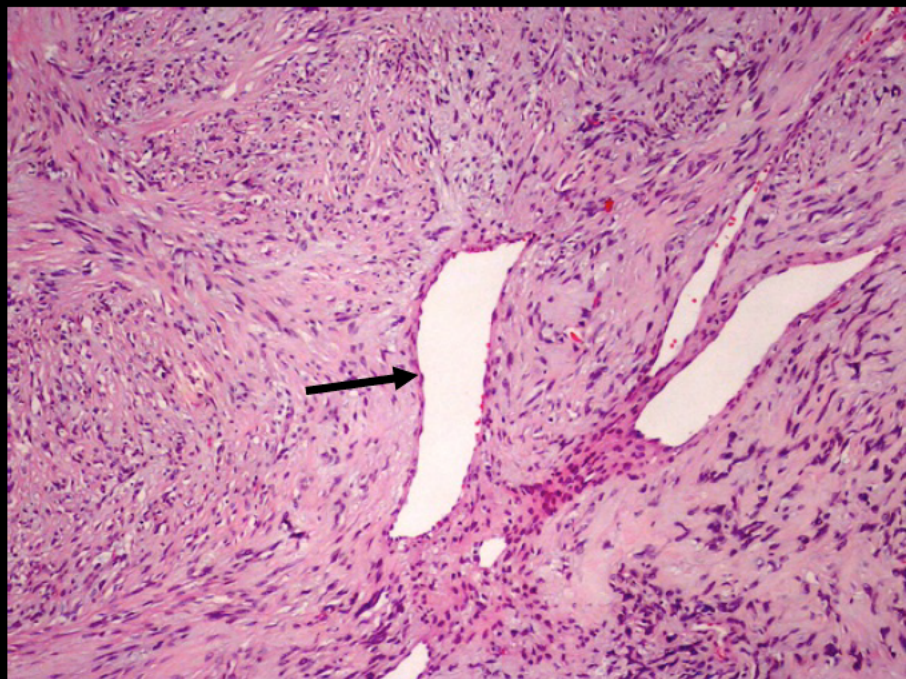
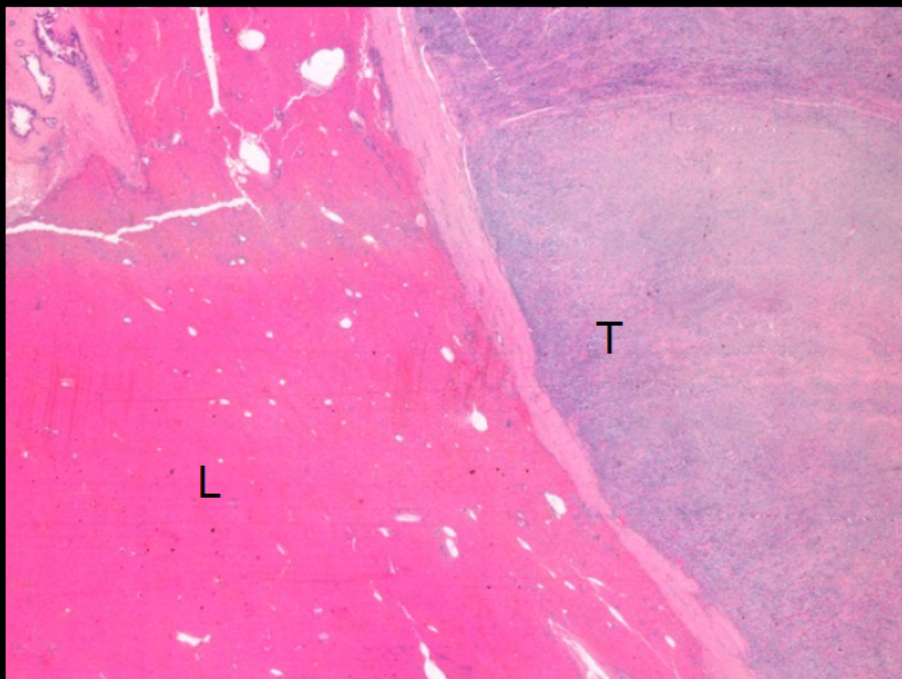


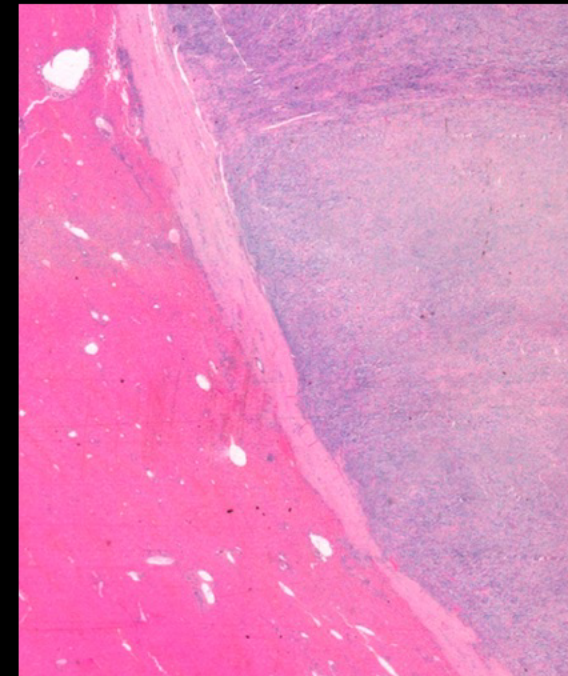
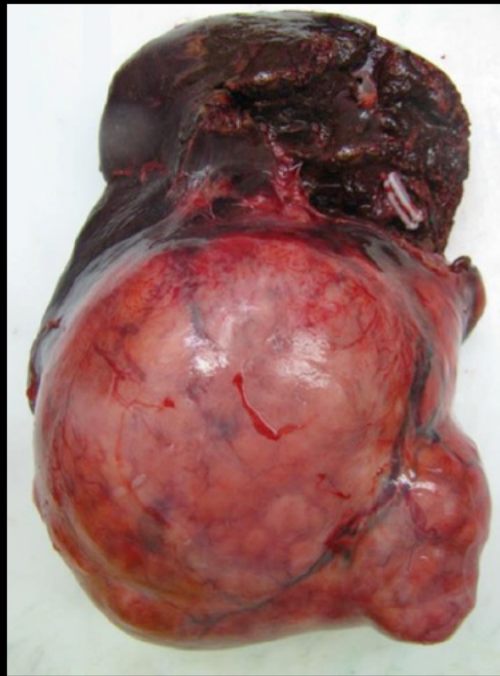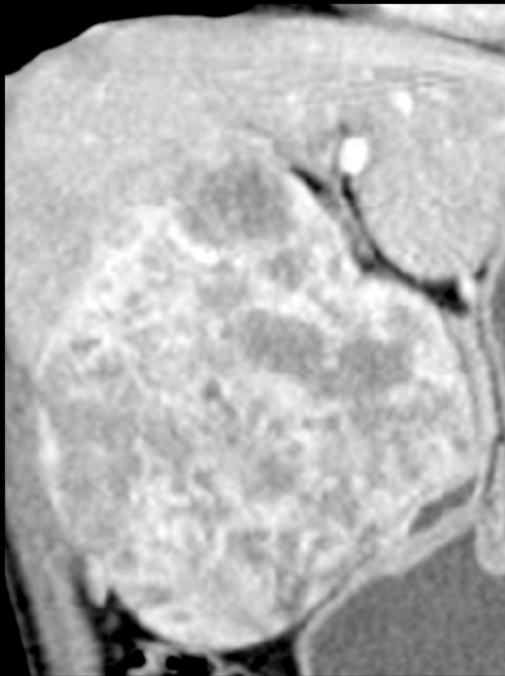






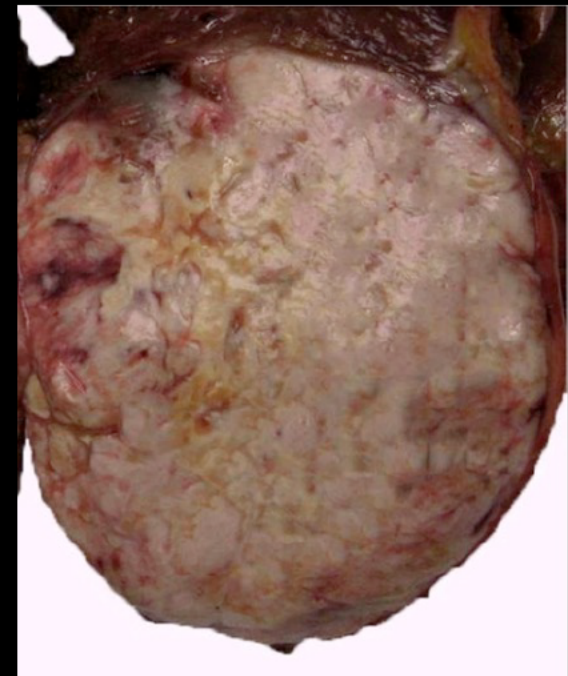
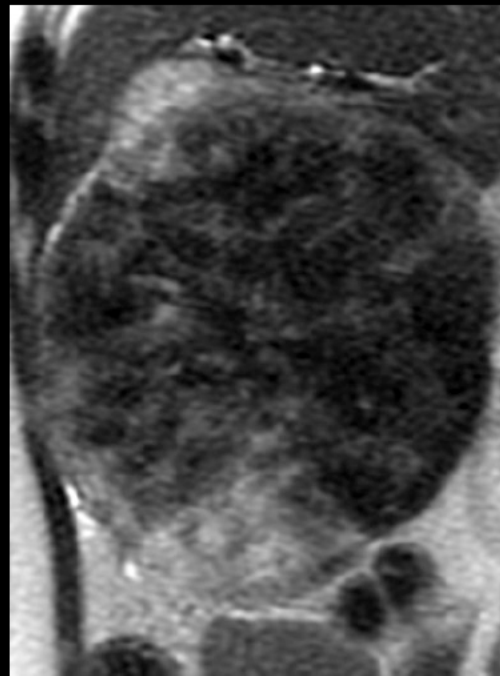






Solitary
Lobulated mass
Well-defined margins
Fibrous components

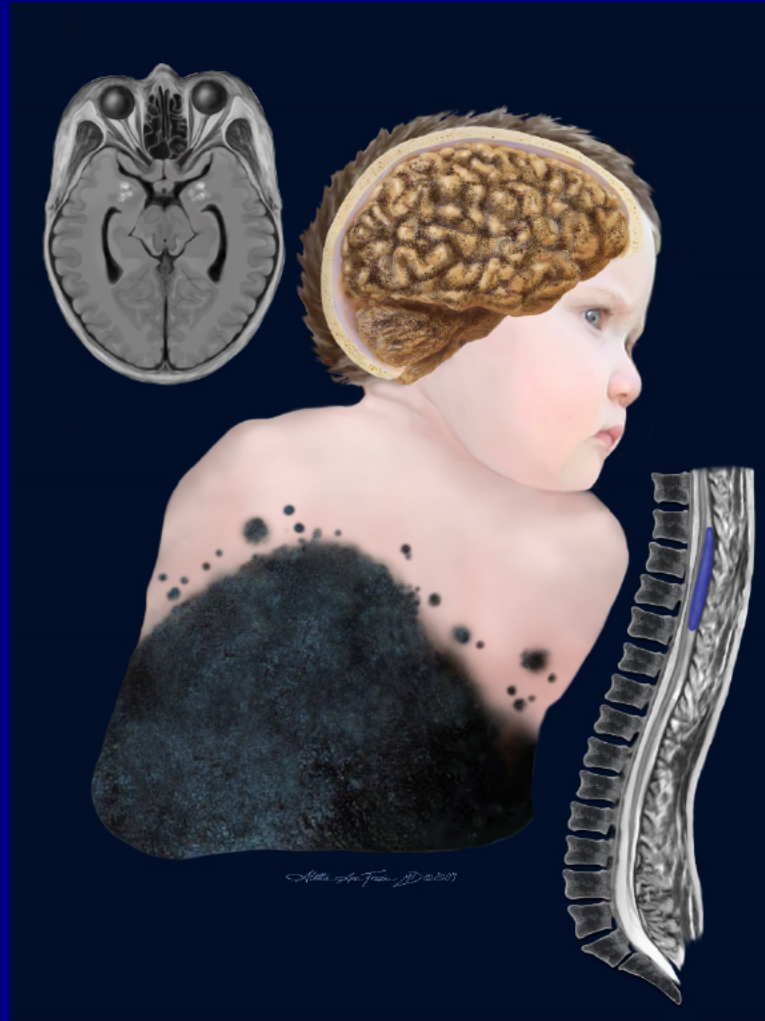
- T2 low signal
- Progressive enhancement



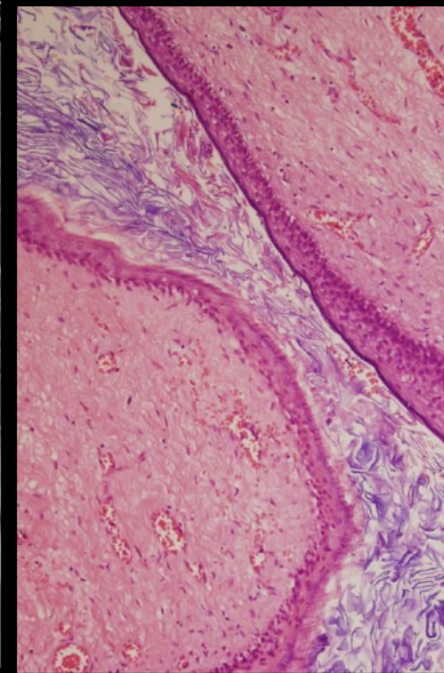
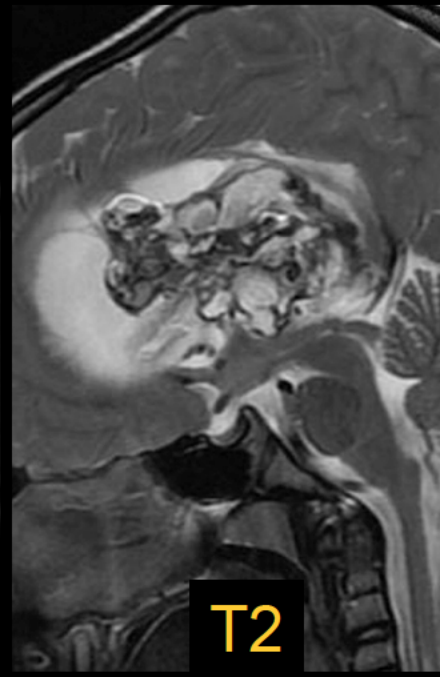
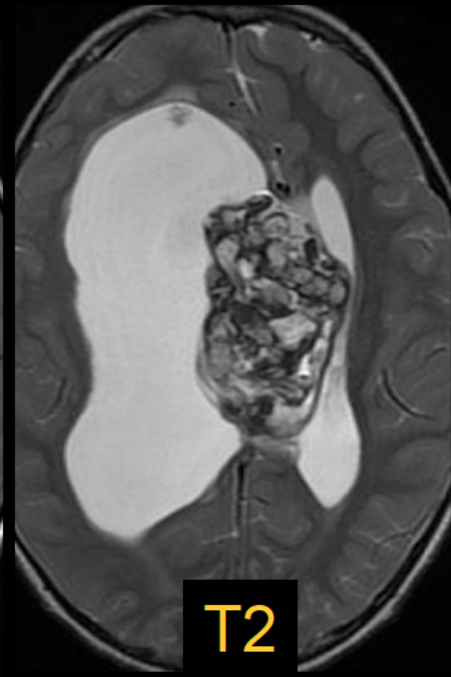
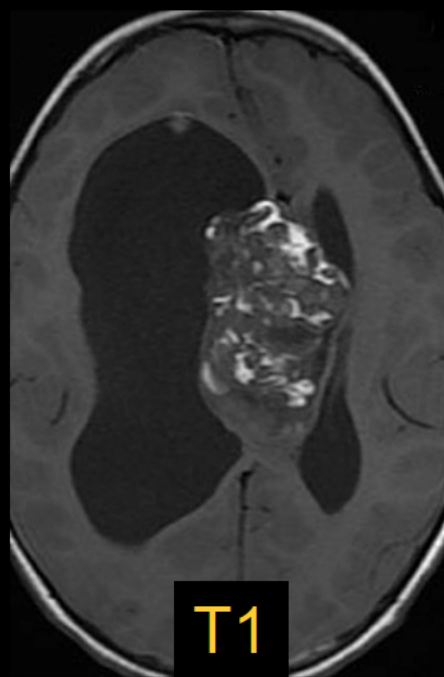
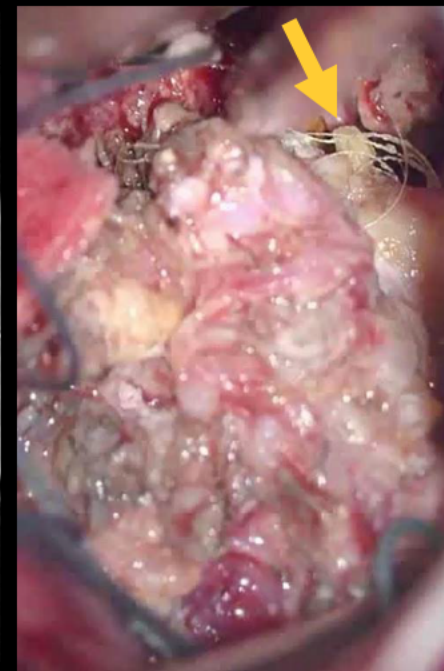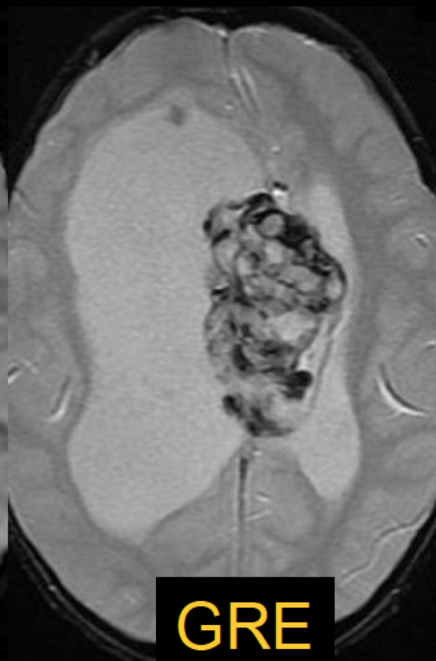
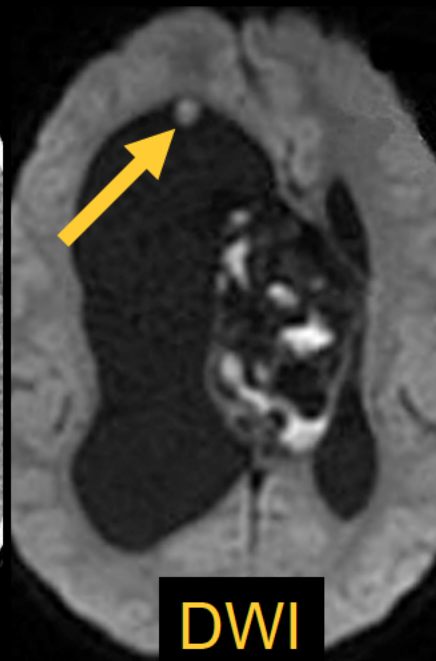
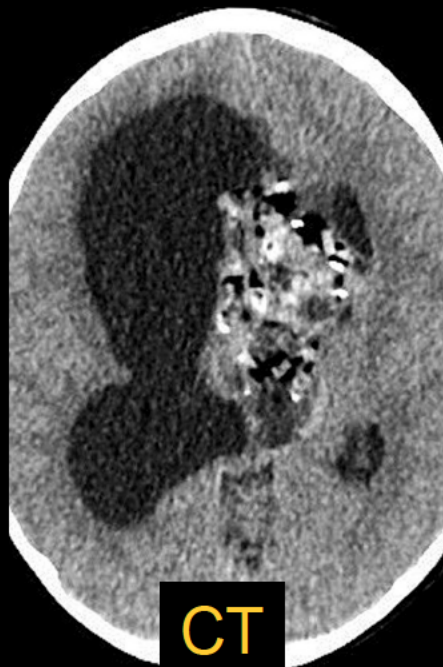
Solitary Fibrous Tumor

Cátia Esteves, M.D.
Centro Hospitalar de São João
Porto, Portugal

Neuroradiology Best Case



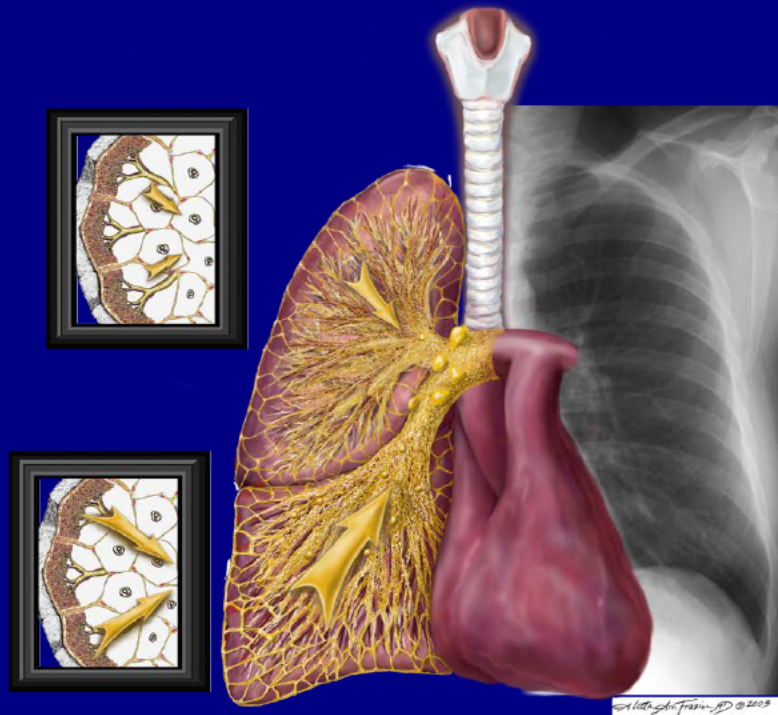
8-year-old male with 2 days history of
headaches and vomiting



Intraventricular Teratoma

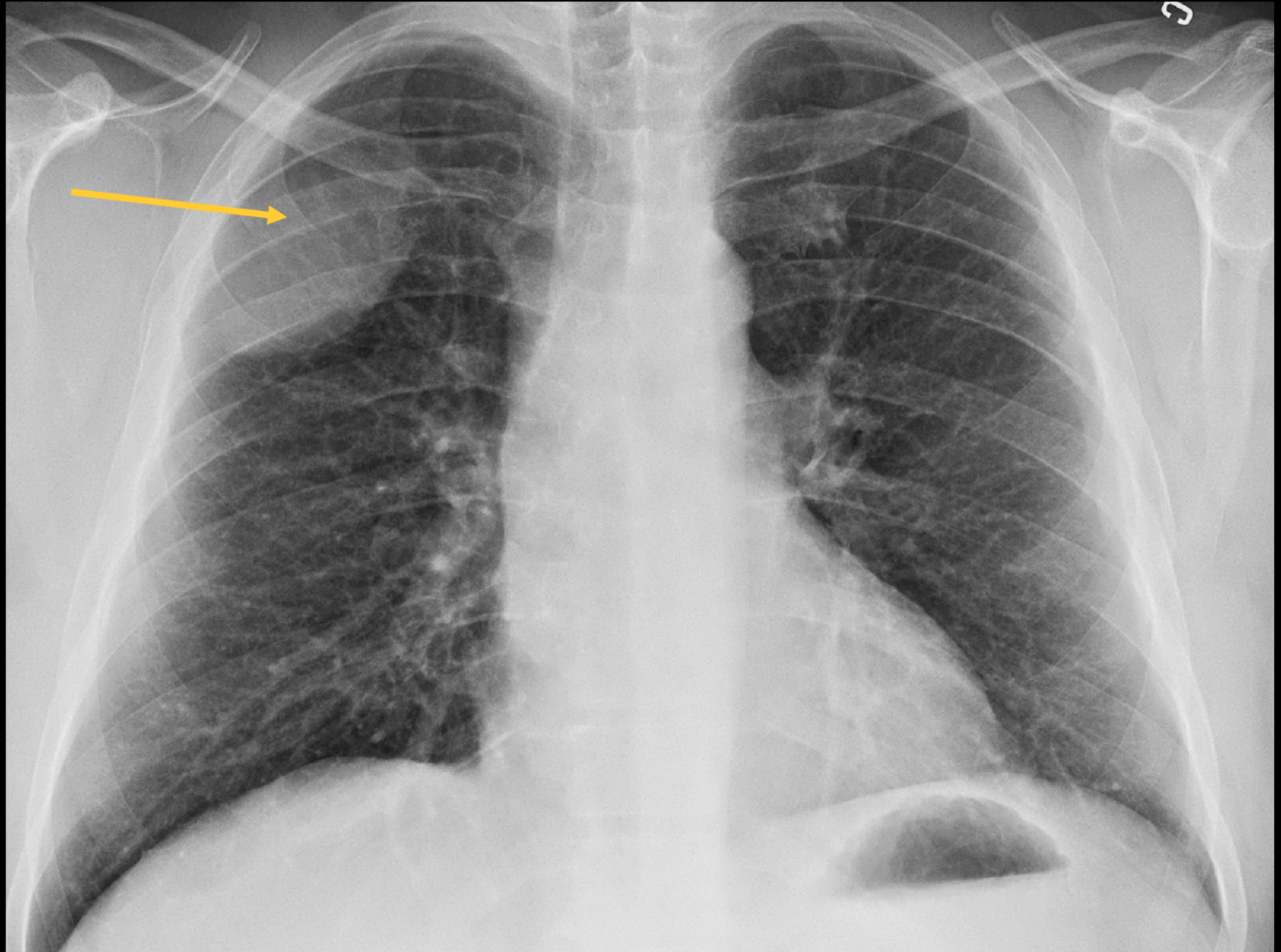
Ahmad Abdelmuhdi, M.D.
Rashid Hospital
Dubai, United Arab Emirates

Pulmonary and Mediastinal Best Case

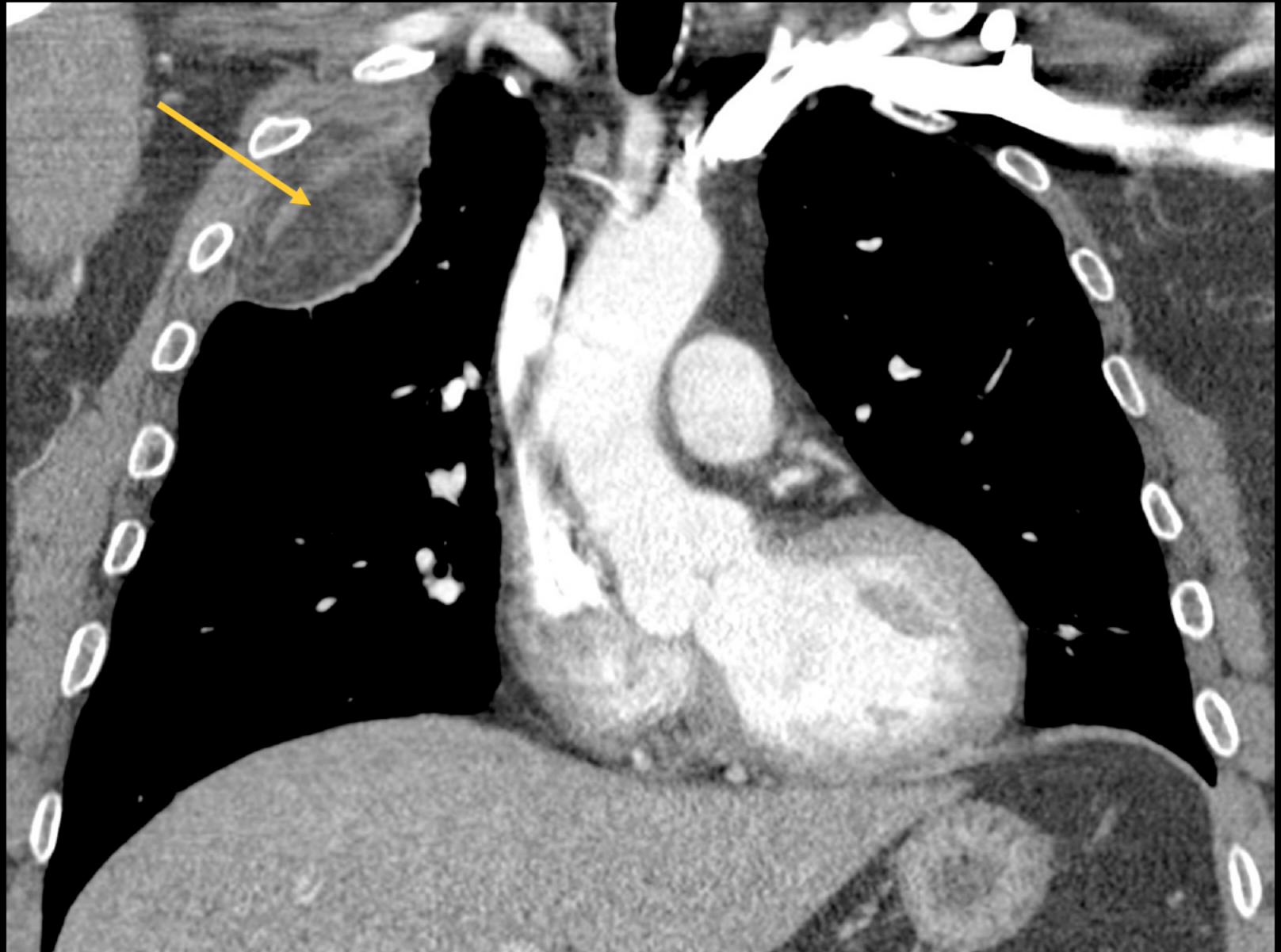


52 year old male with severe right upper
chest wall pain.

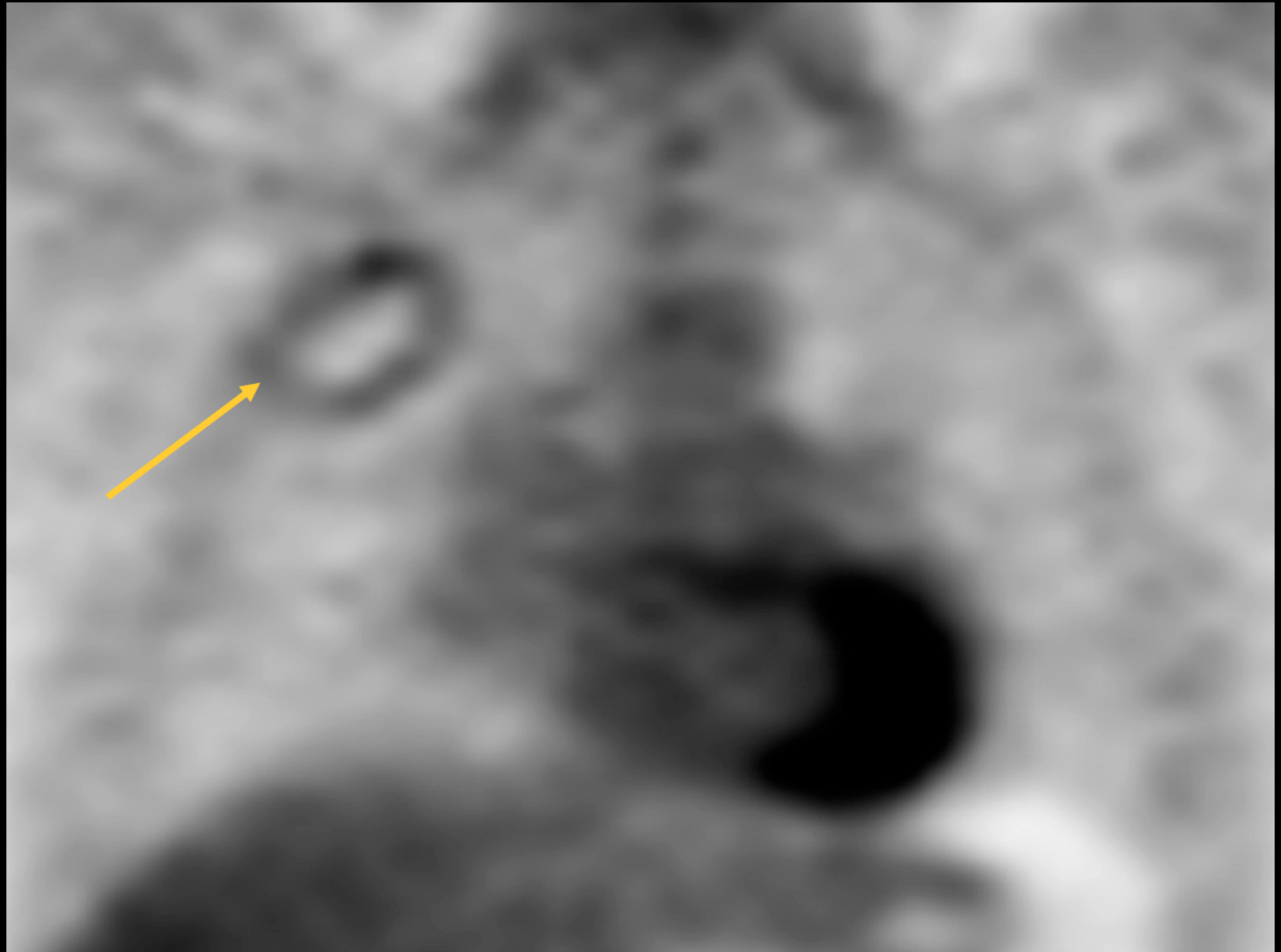
Incomplete border sign



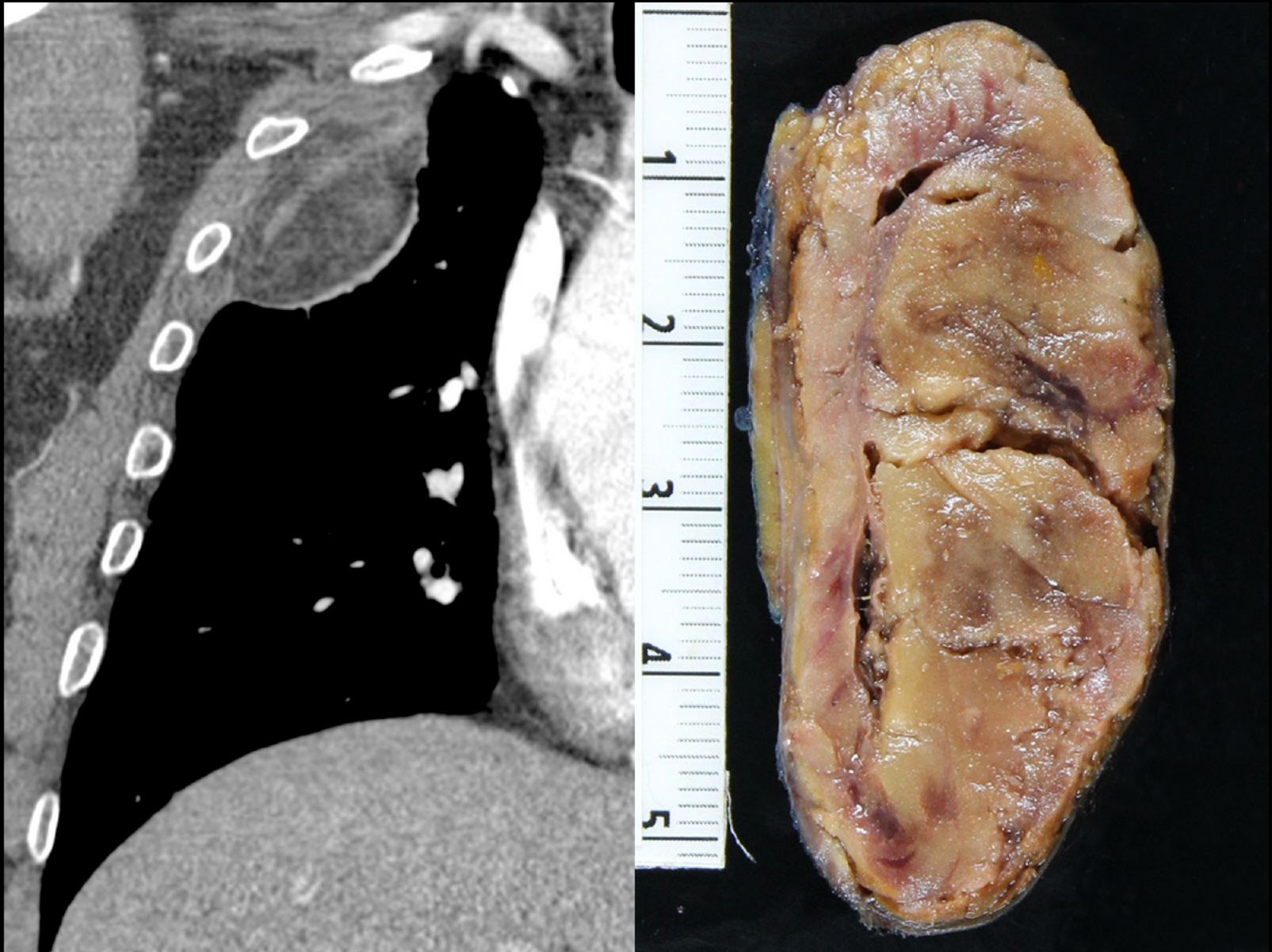
Extrapulmonary mass



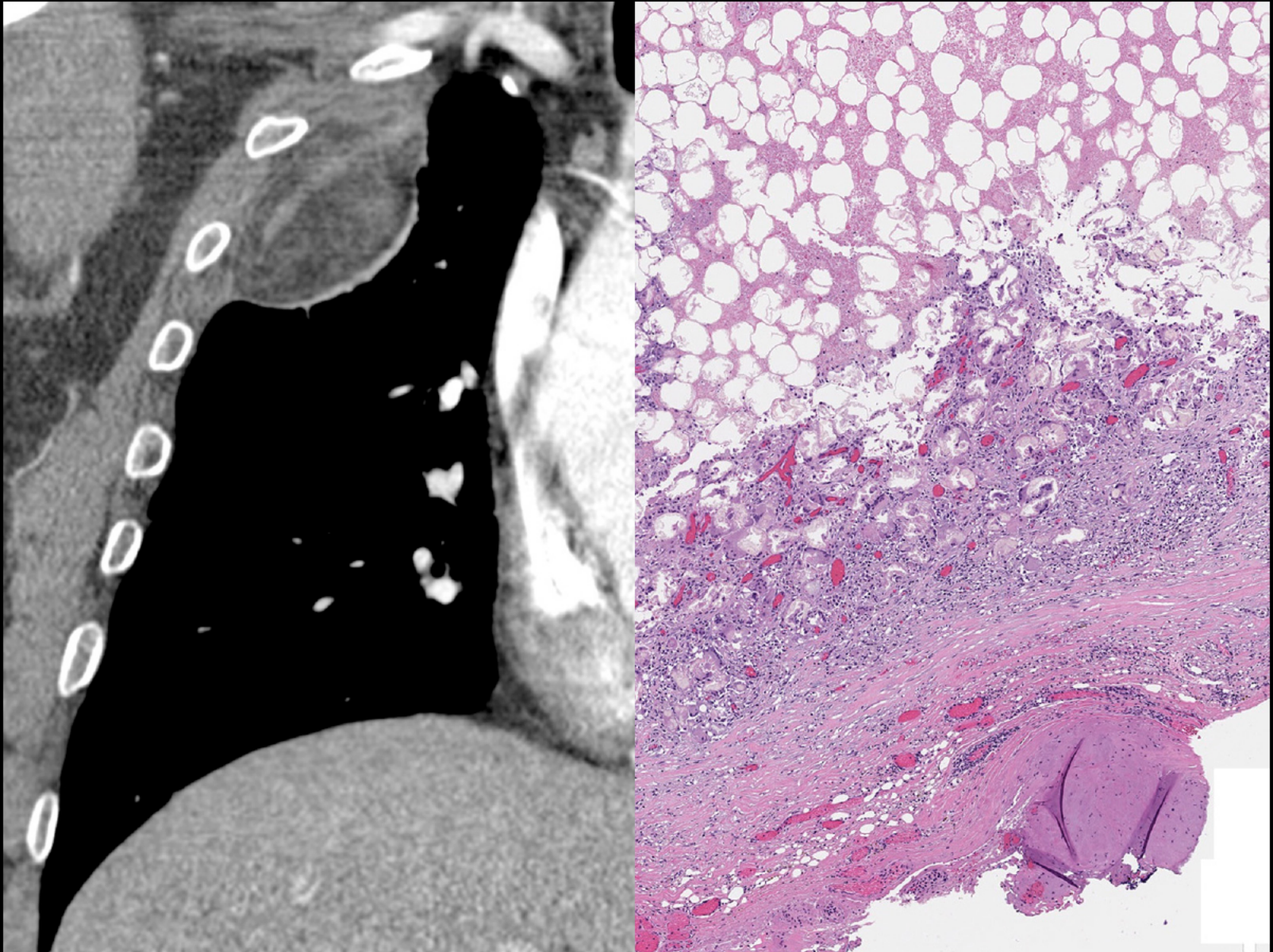
Peripheral activity on PET



Fat/soft tissue attenuation



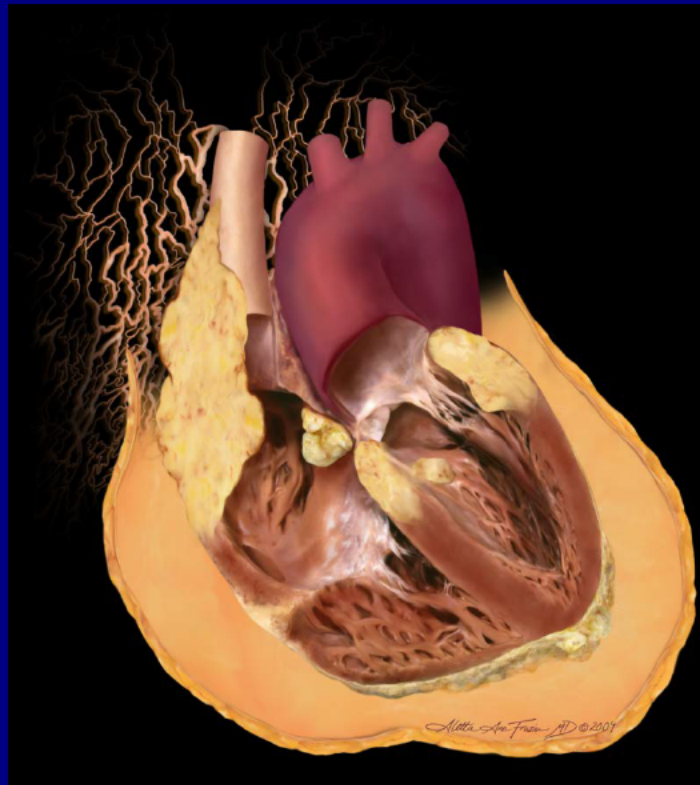
Lipoma with inflamed capsule



Lipoma

Jace Hilton, DO
Dartmouth Hitchcock
Lebanon, NH

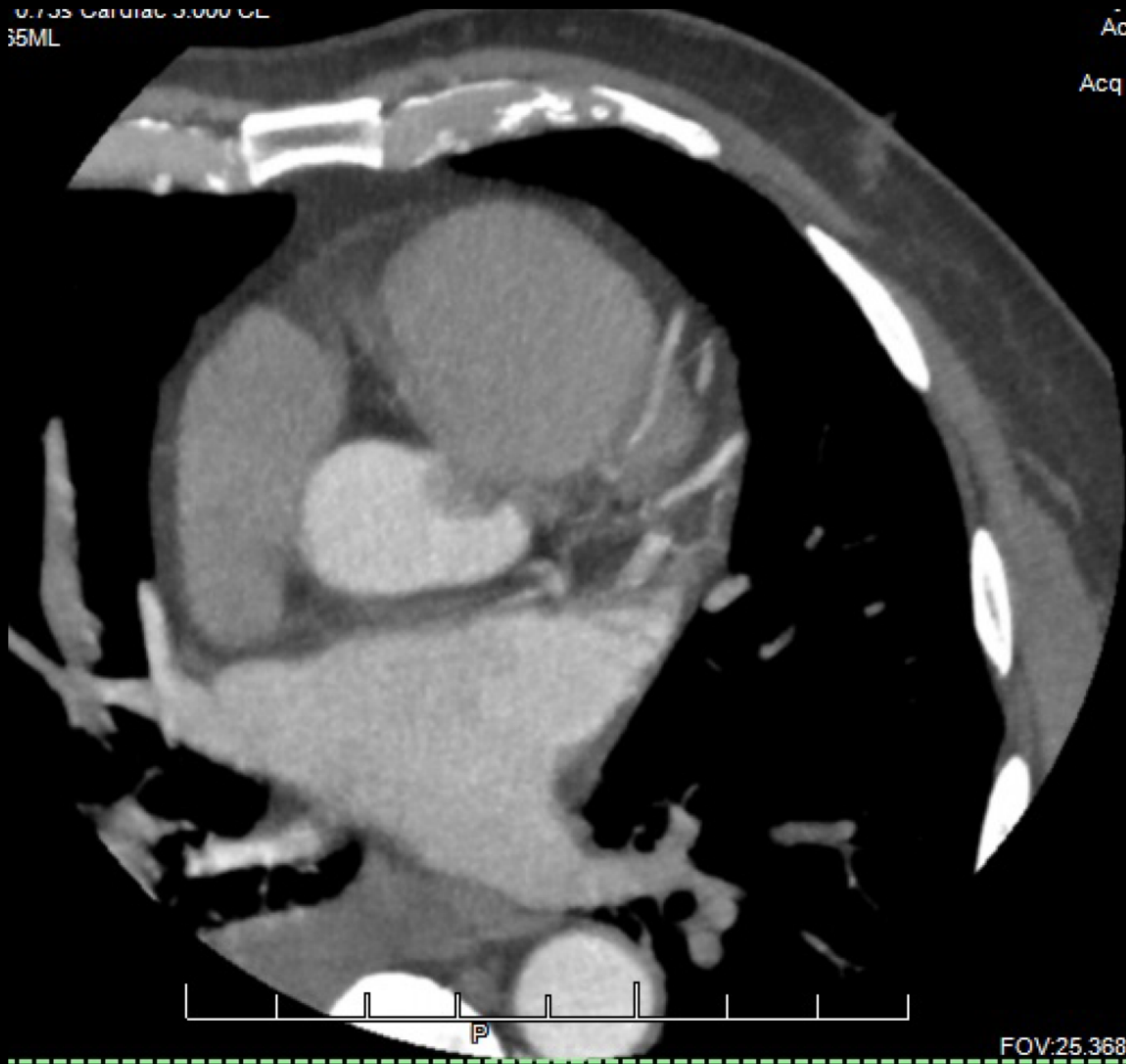
Cardiovascular Best Case



67 year old male with history of atrial fibrillation. A transesophageal echocardiogram (TEE) shows an unsuspected small mobile aortic lesion.

0.735 Cardiac 3.000 CL
35ML

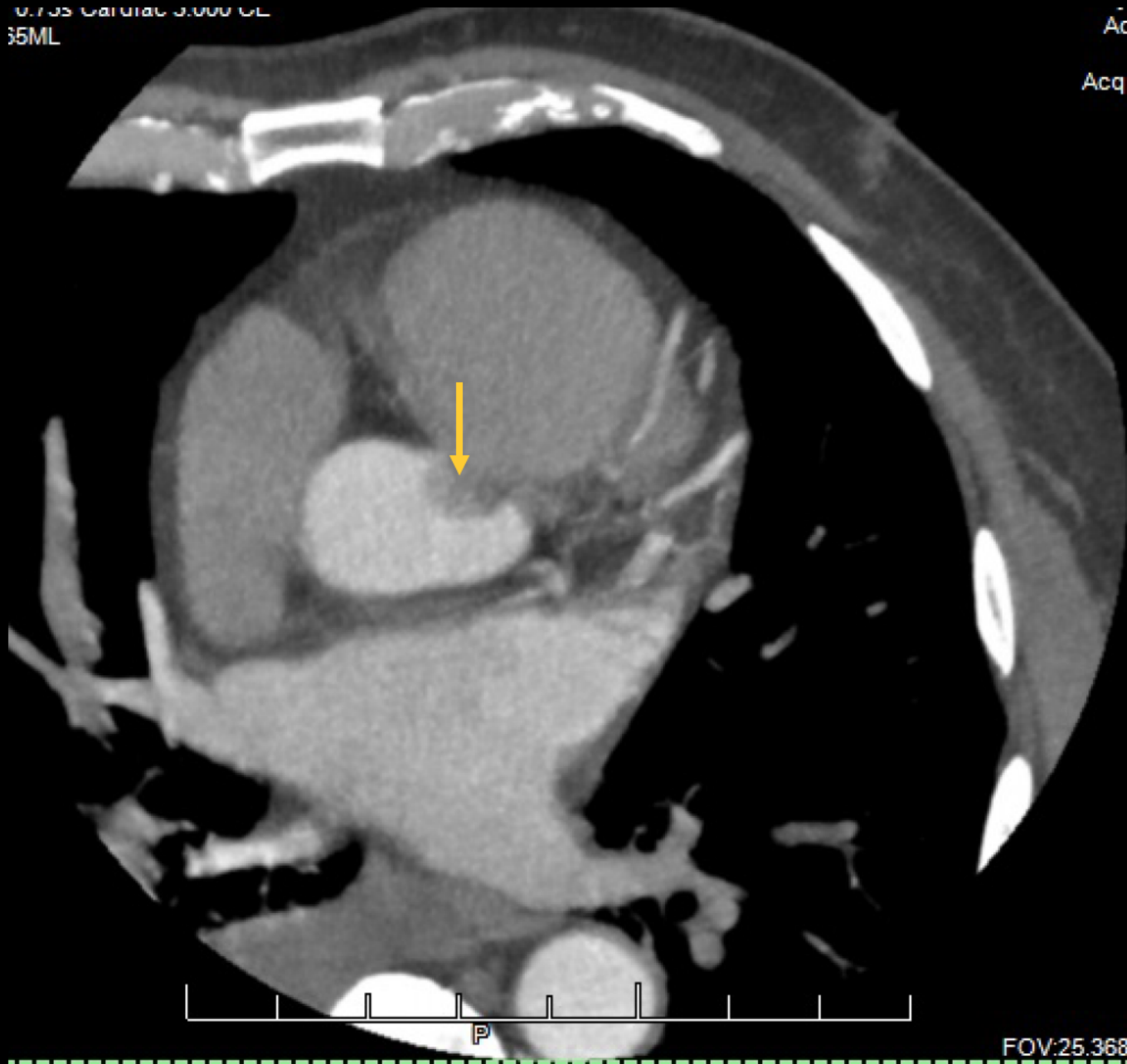
Act
Acq



FOV:25.3687

0.735 Cardiac 3.000 CL
35ML

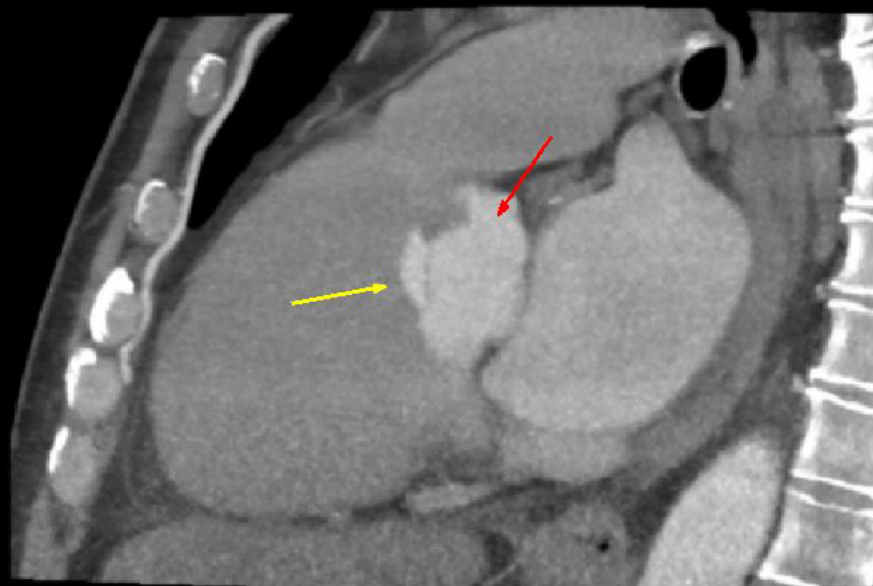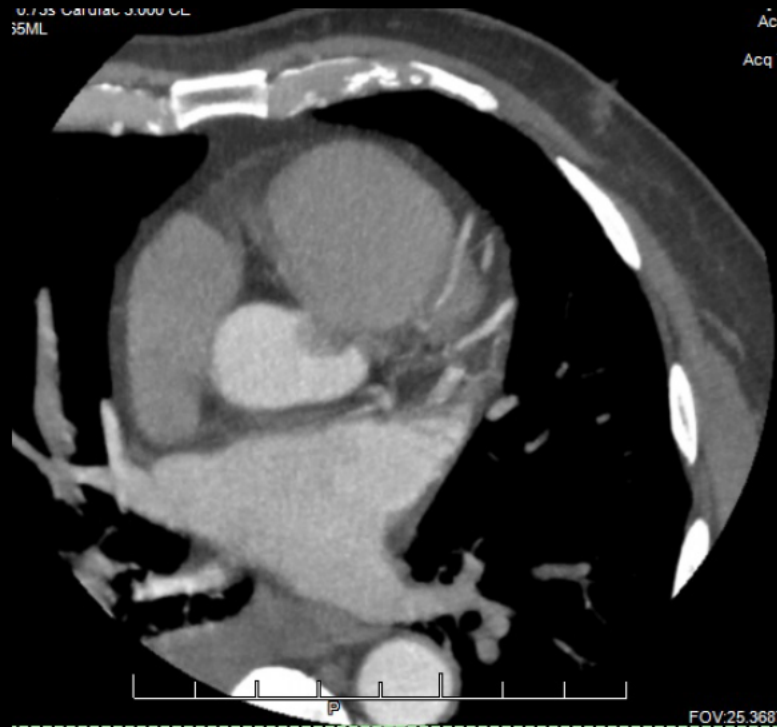
Act
Acq

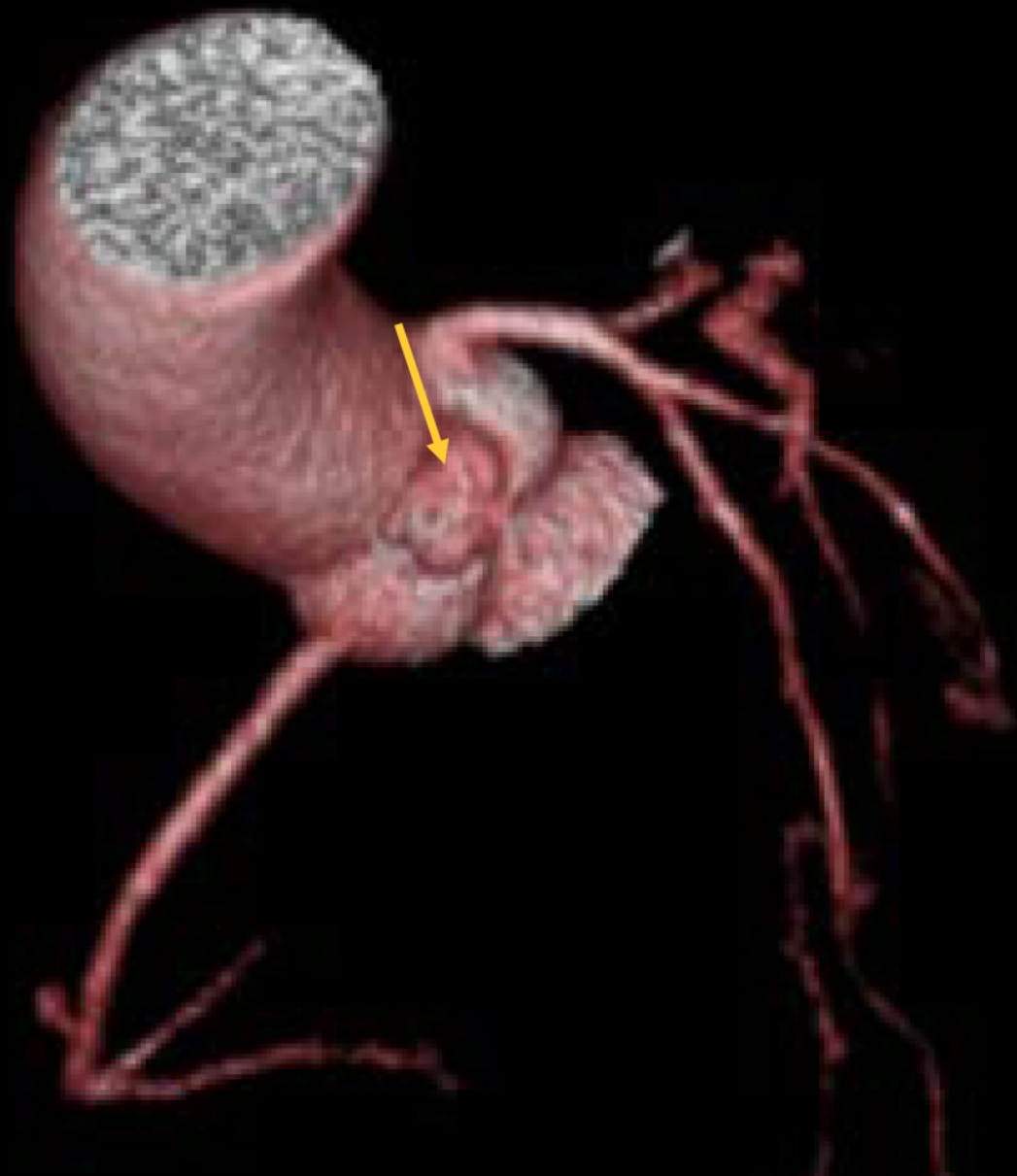


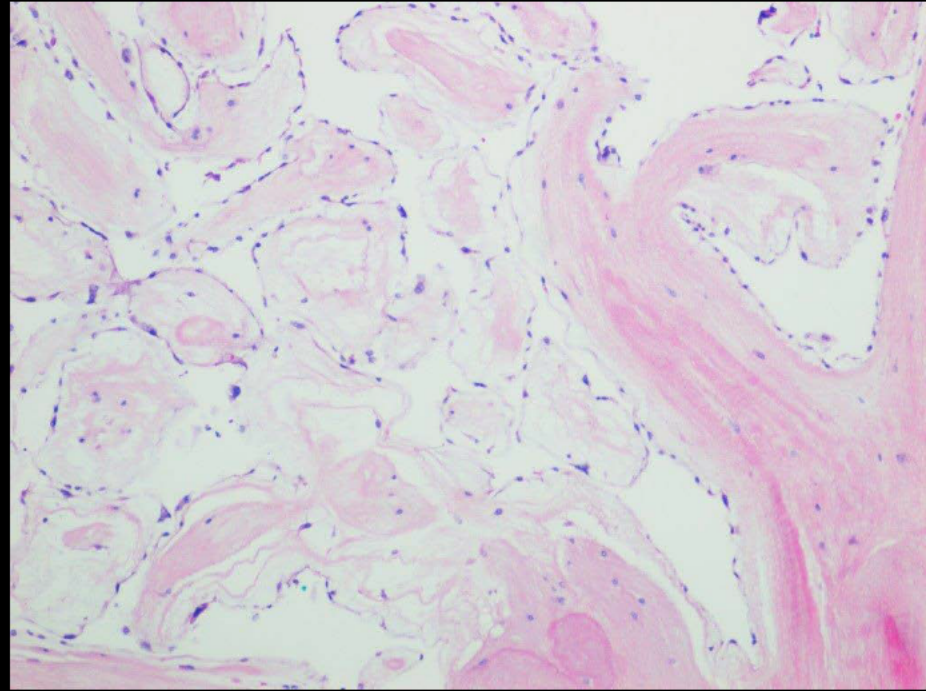
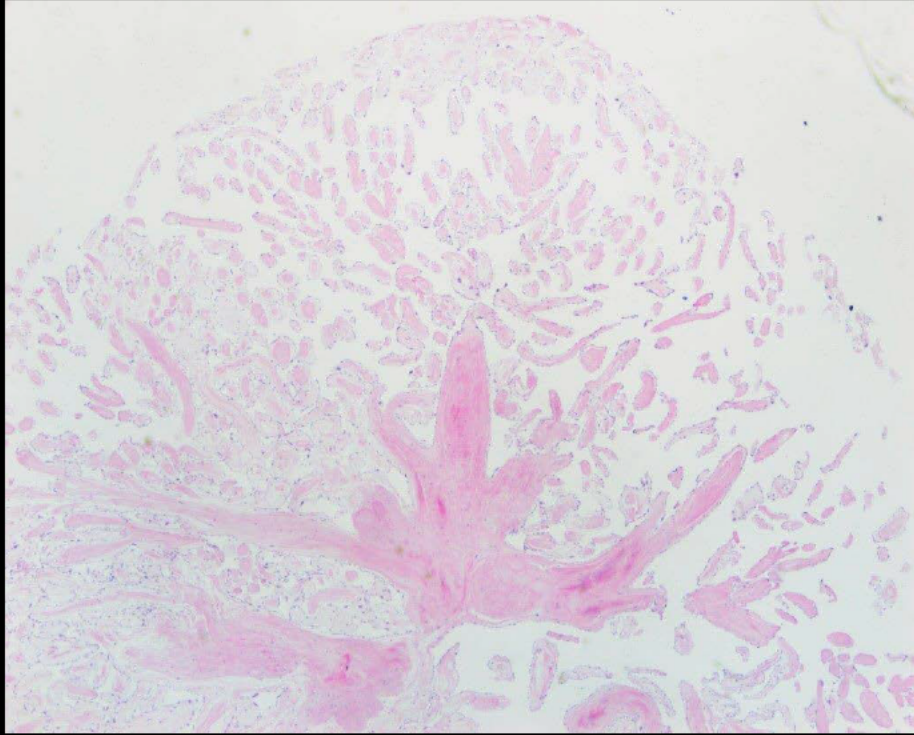
FOV:25.3687

0.735 Cardiac 3.000 CL
35ML

Acq
Acq



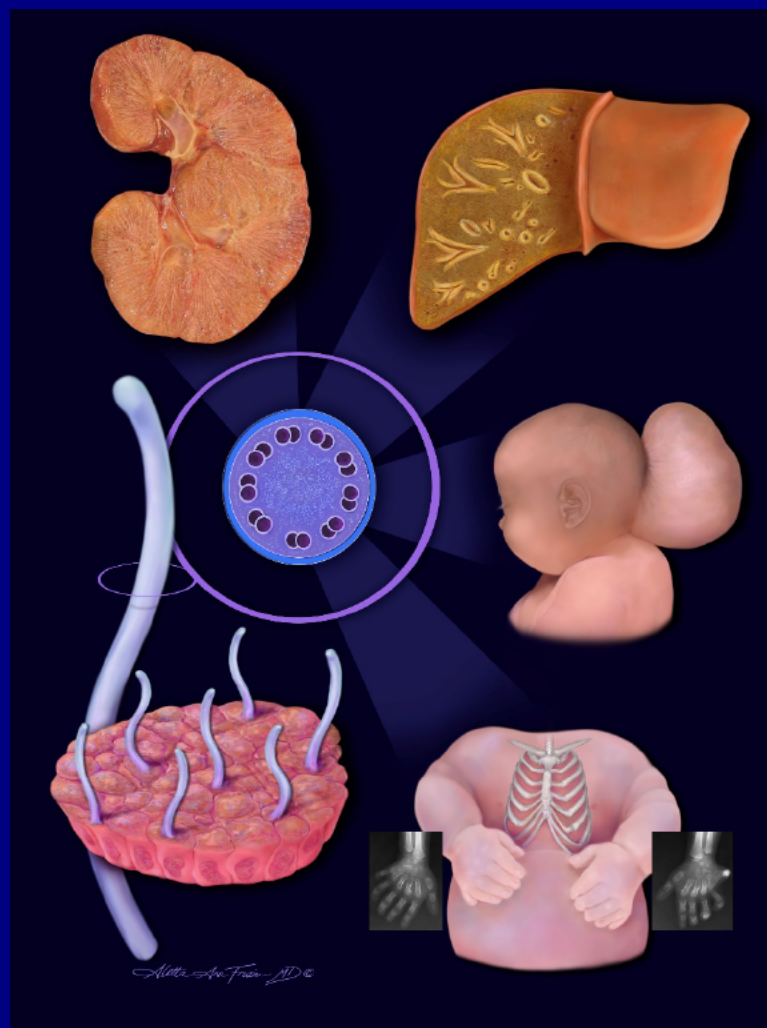




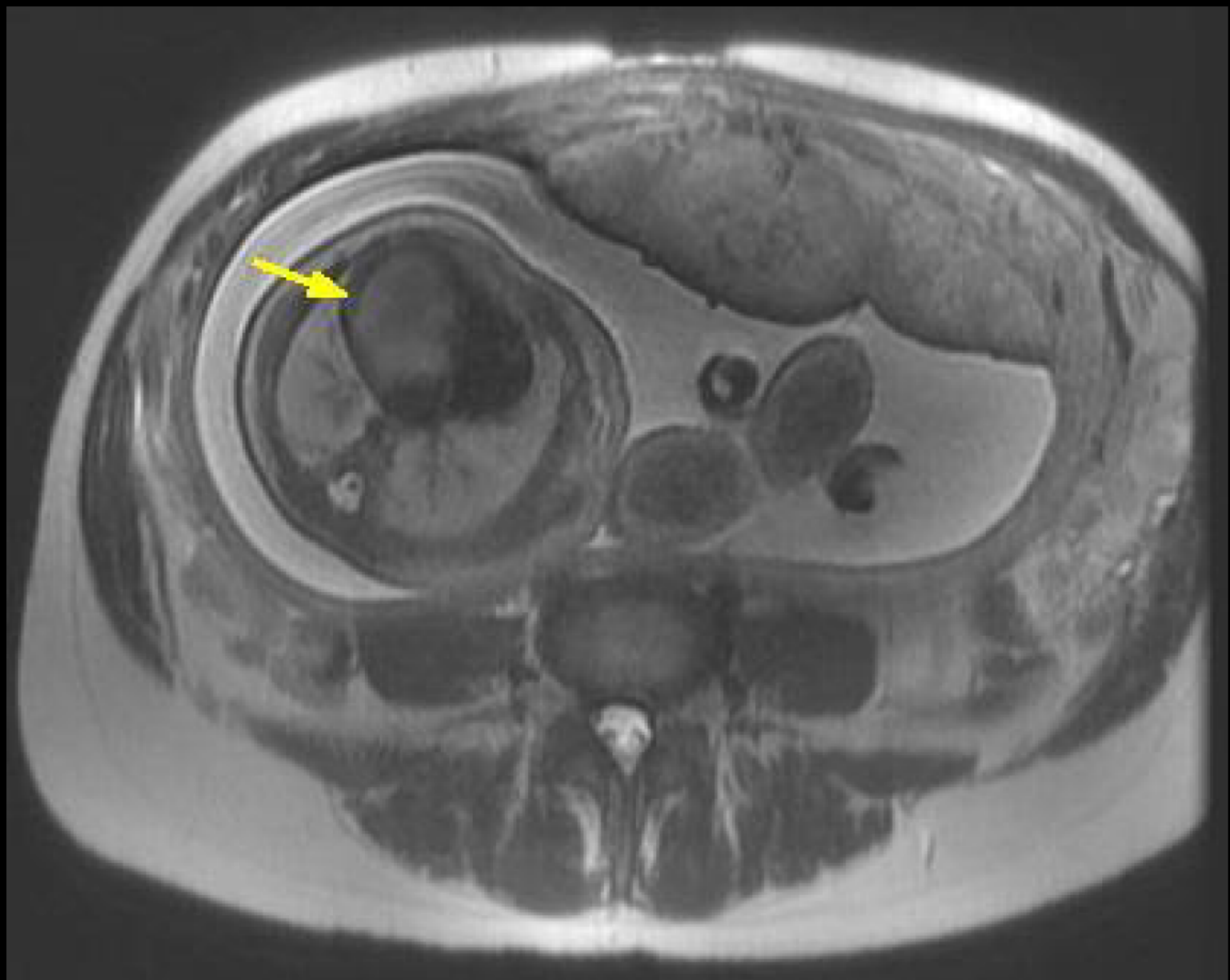
Papillary Fibroelastoma

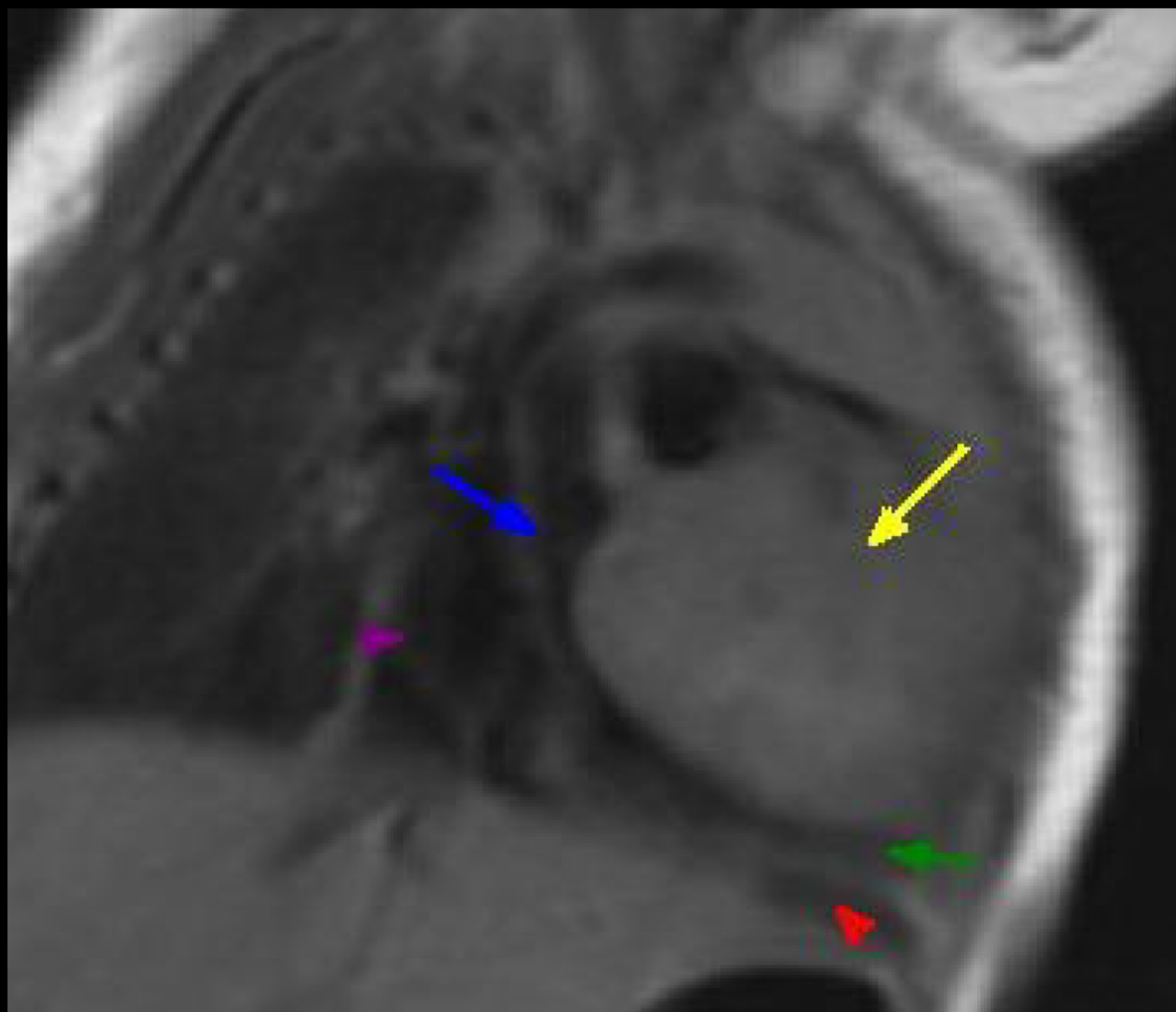
Nikhil Bhargava, MD
Virginia Commonwealth University
Richmond, VA

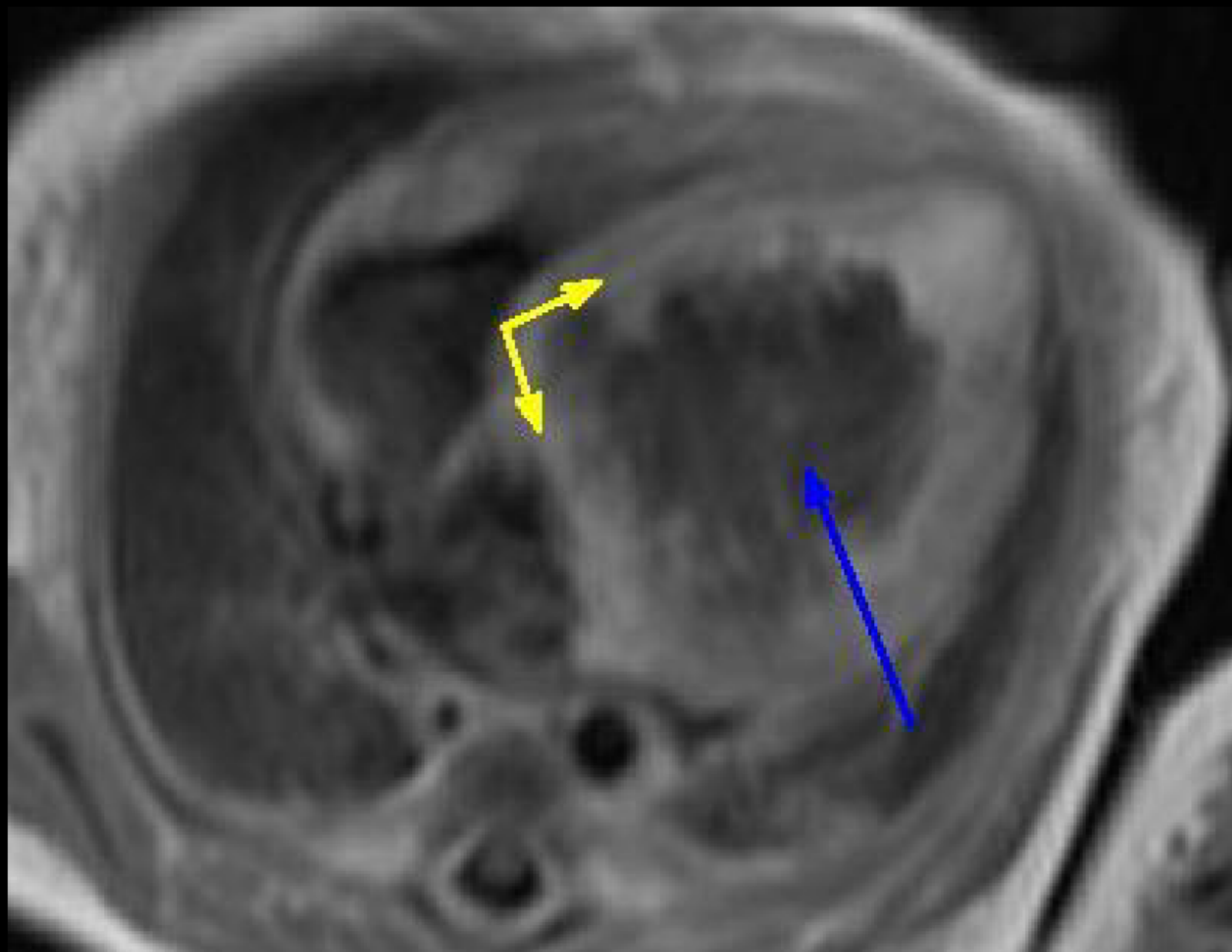
Pediatric Best Case

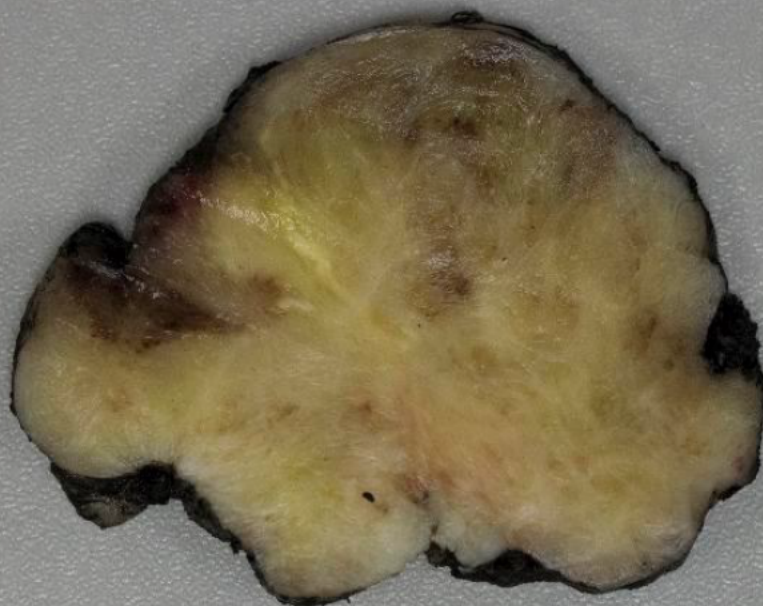

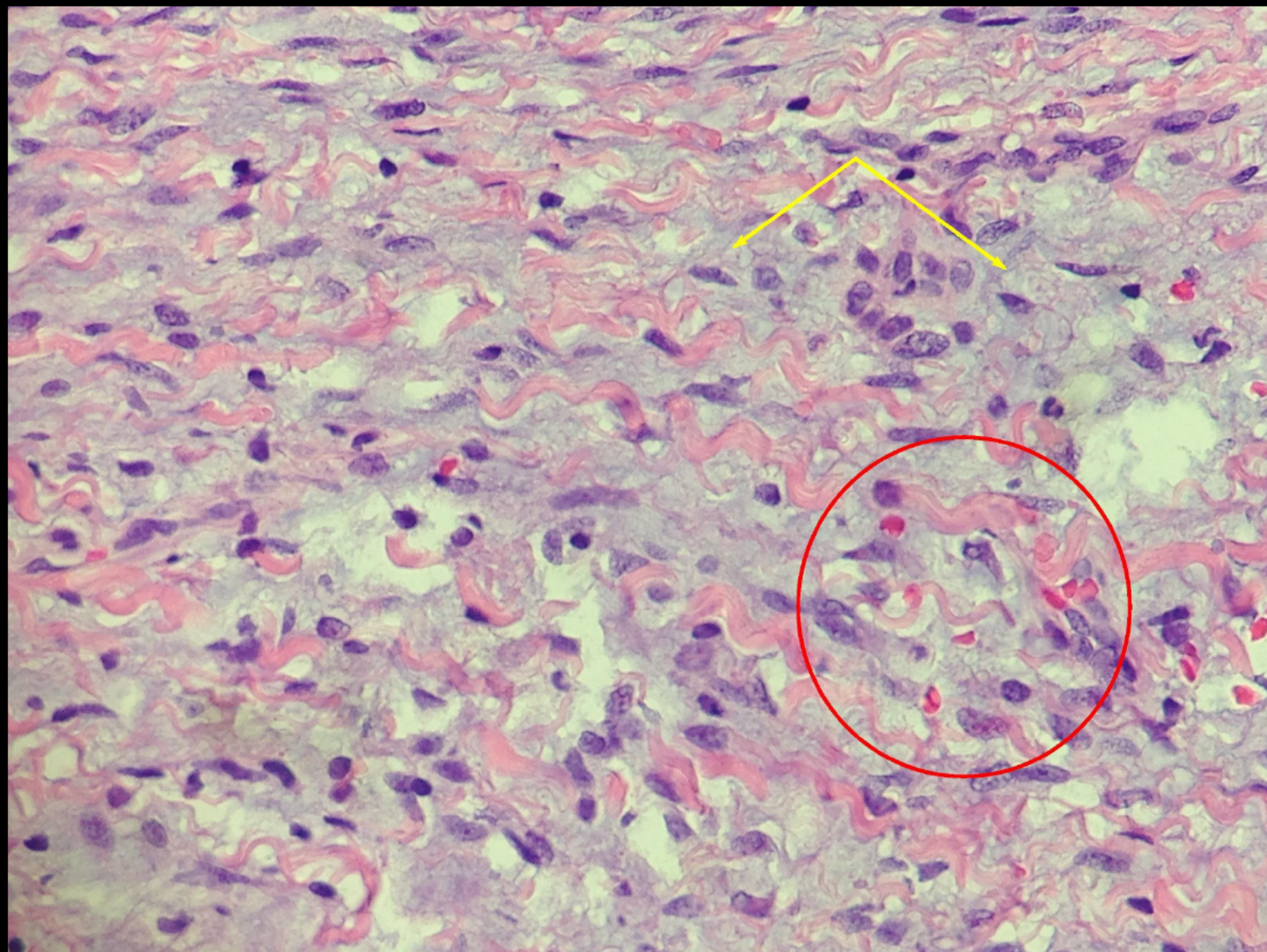
- 2-month-old female with prenatally diagnosed large intracardiac left ventricular mass who was born via induced vaginal delivery at 38+1 weeks estimated gestational age to a healthy 37-year-old G4P3 mother.











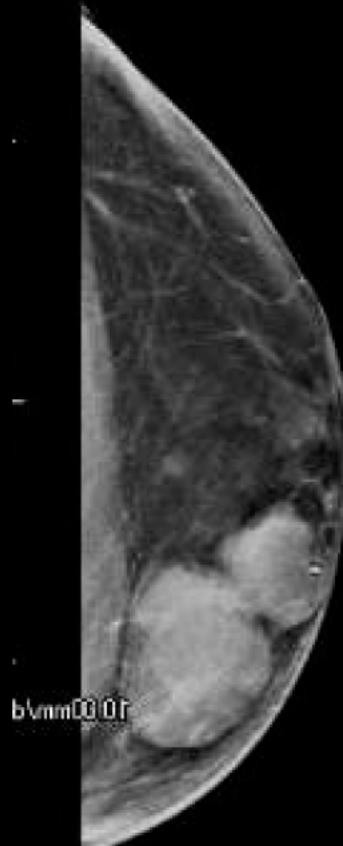Cardiac Fibroma

Jordan McDonald, MD
Indiana University School of Medicine
Indianapolis, IN

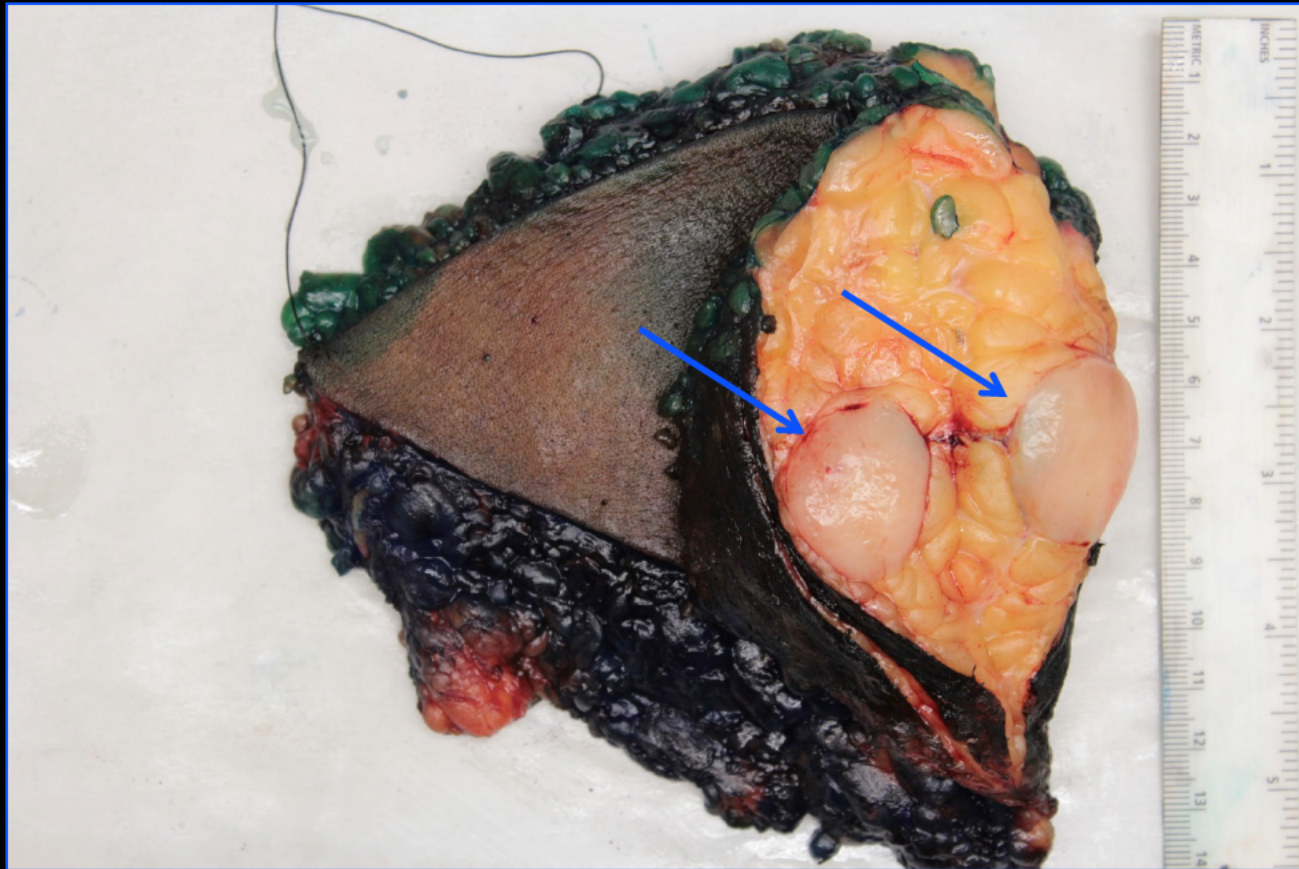


49 y.o. male with a slowly growing nodule and hardness in his upper inner left breast. He developed sharp shooting pains in left breast, and initially went to ER to r/o cardiac chest pain, which was negative.

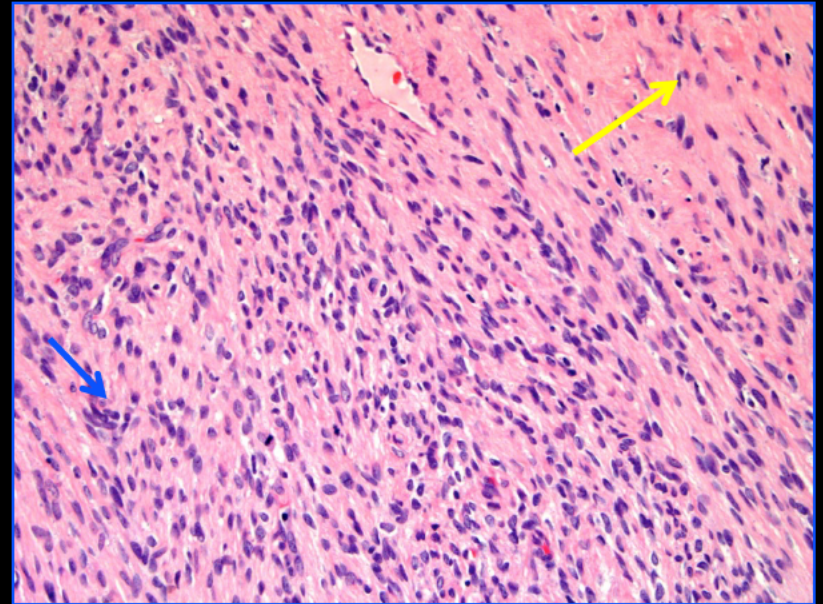
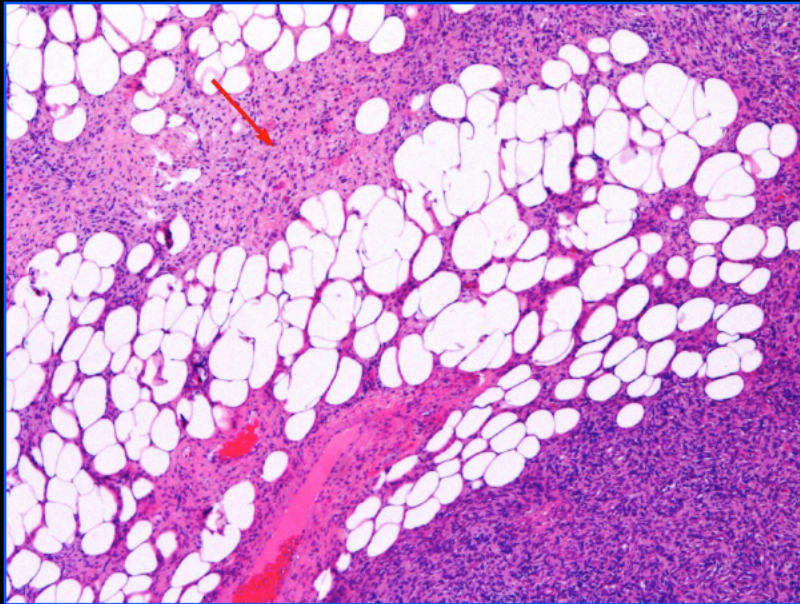
Diagnostic Mammogram



Gross



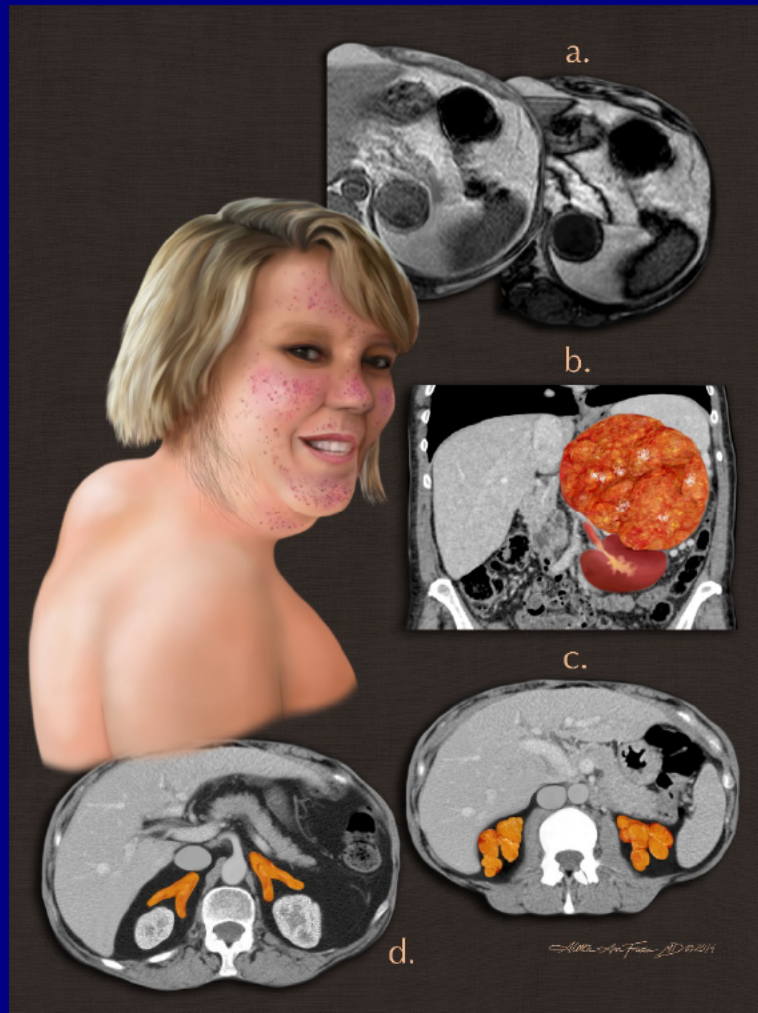
Histology



Dermatofibrosarcoma protuberans

Peiman Habibollahi
University of Pennsylvania
Philadelphia, Pennsylvania

Genitourinary Best Case



68 yo female with a retrograde
ureterogram after anormal cytology on UA

11/05/2015

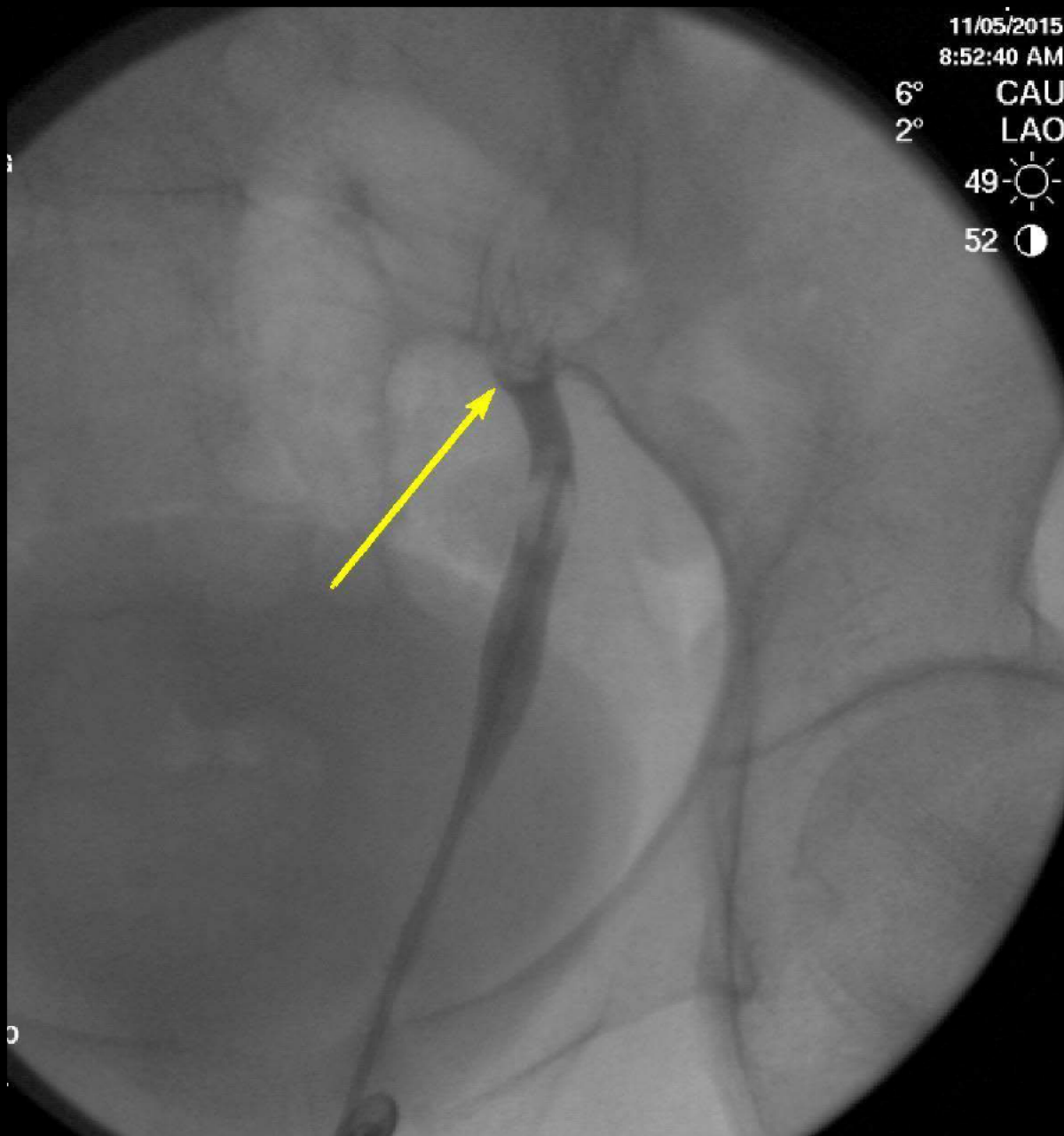
8:52:40 AM

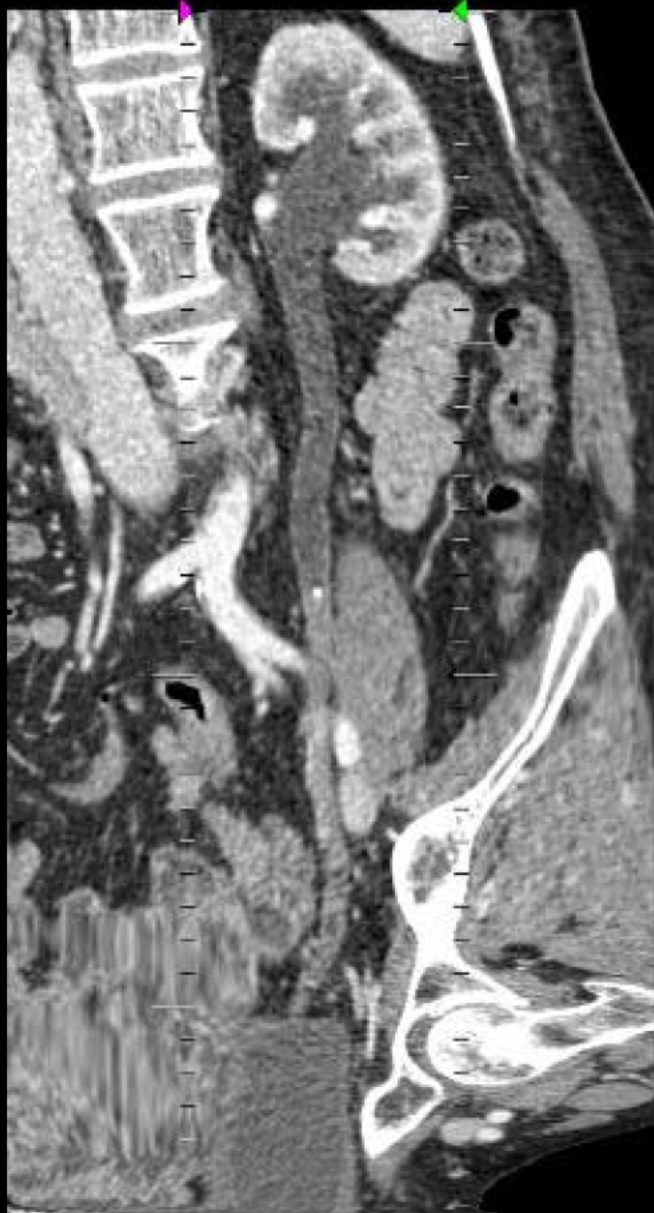
6° CAU

2° LAO

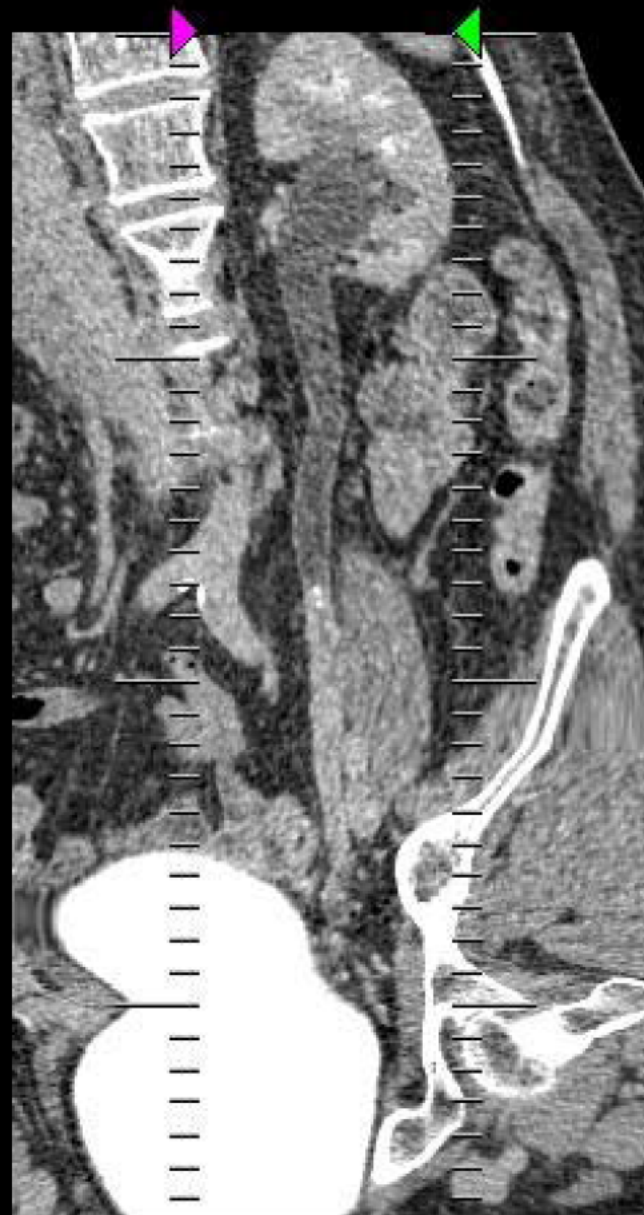49-

52 

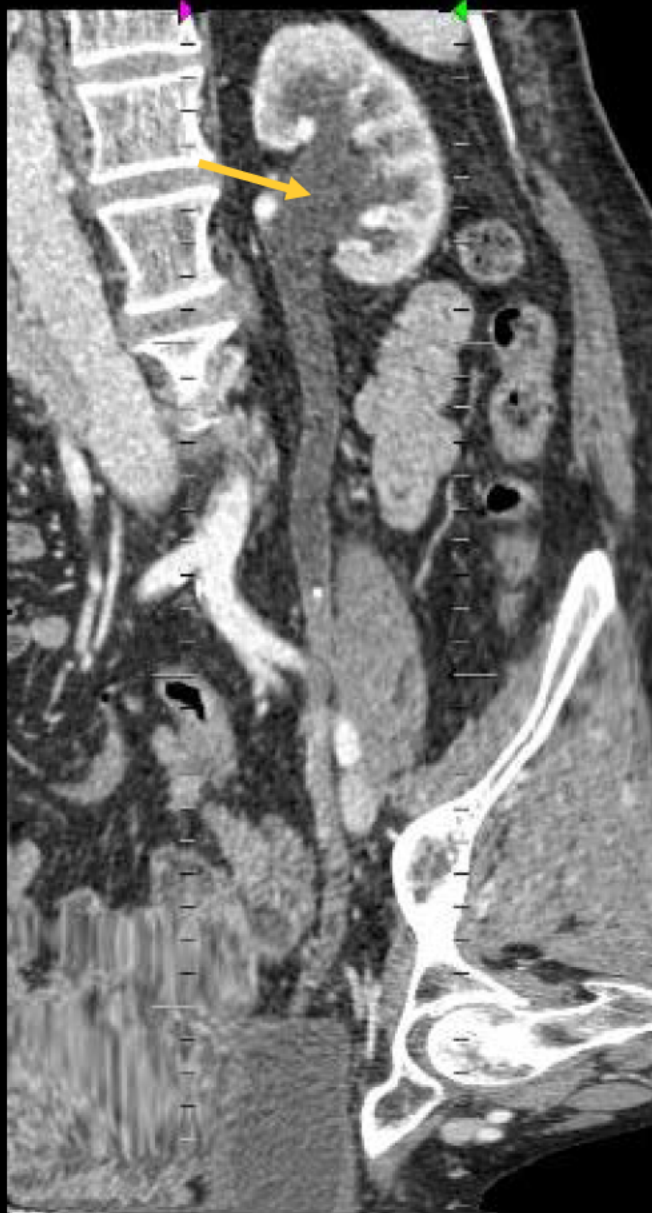




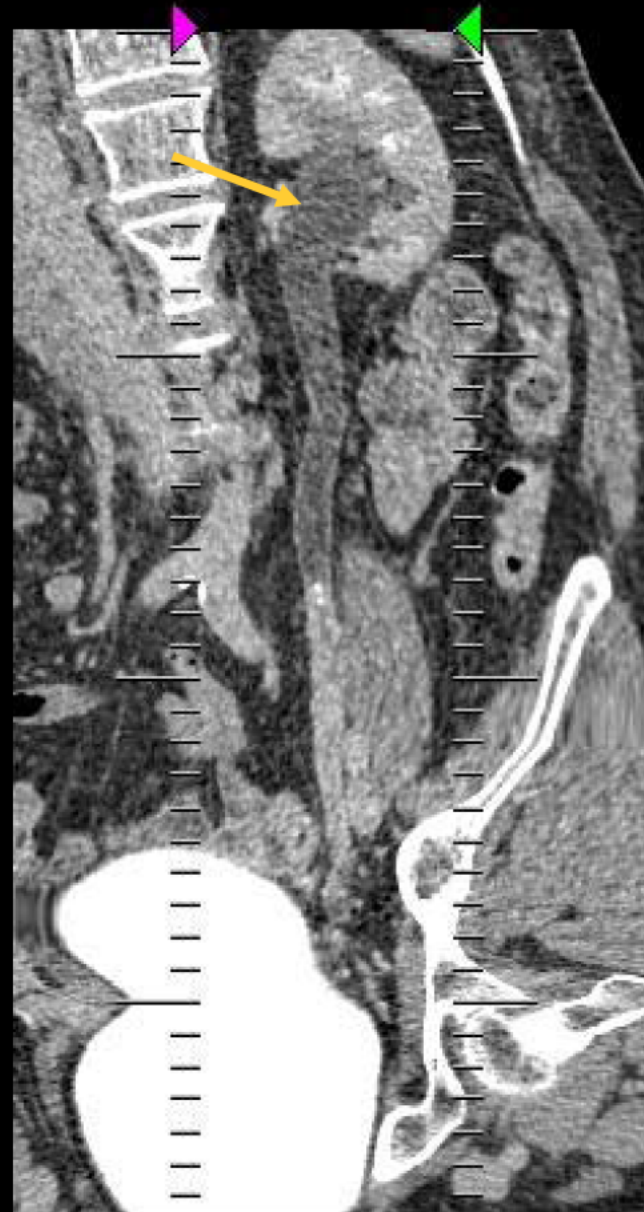
Thickness: 0 mm



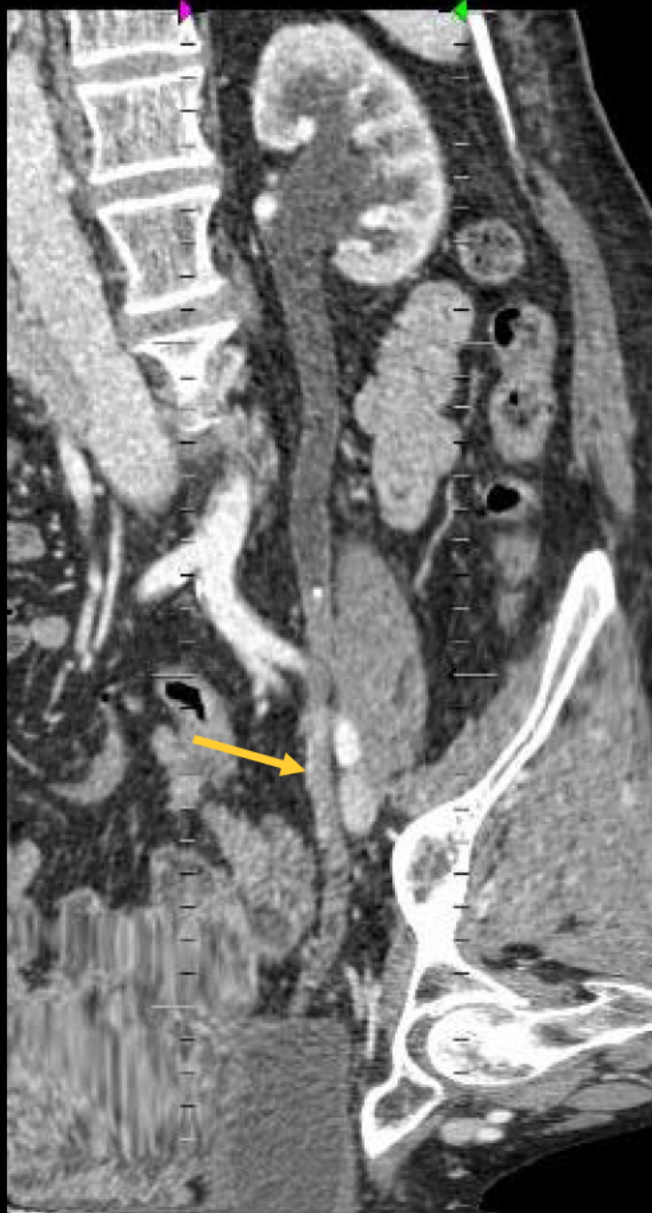Thickness: 0 mm



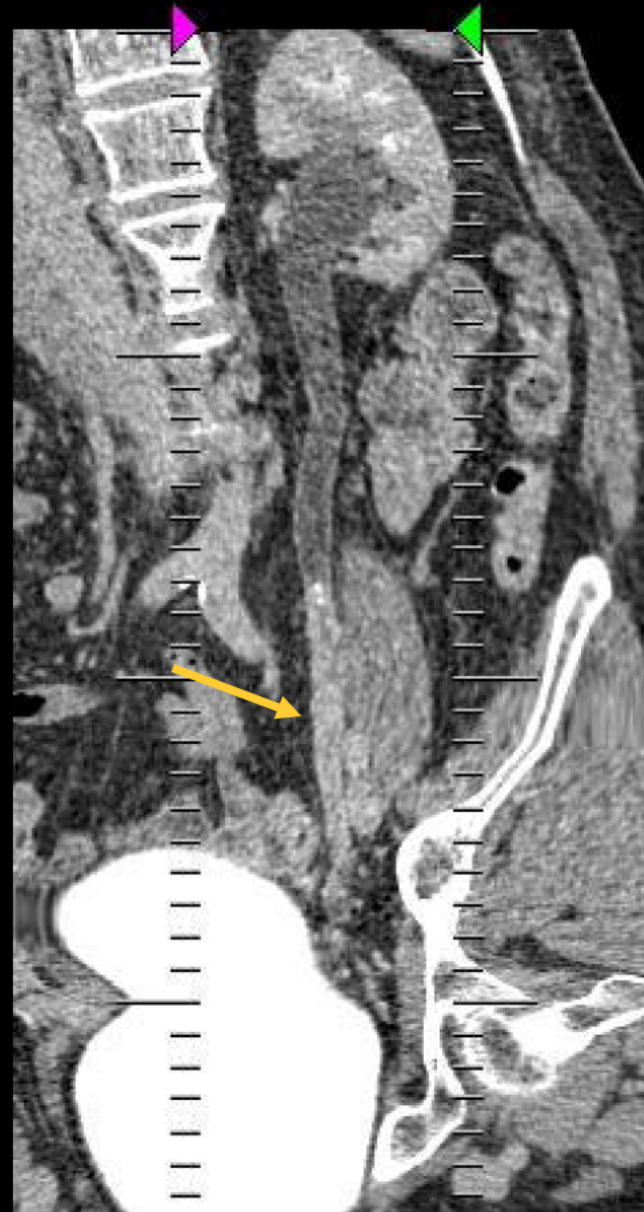Thickness: 0 mm



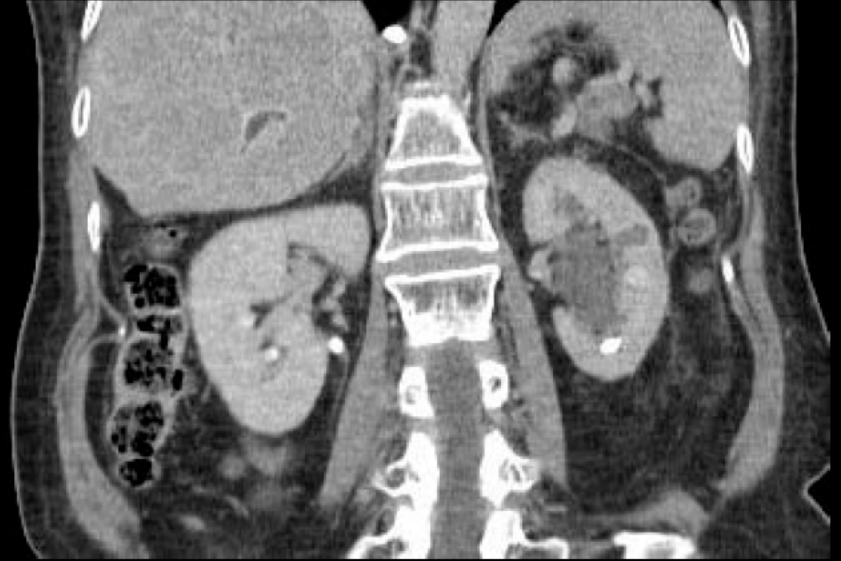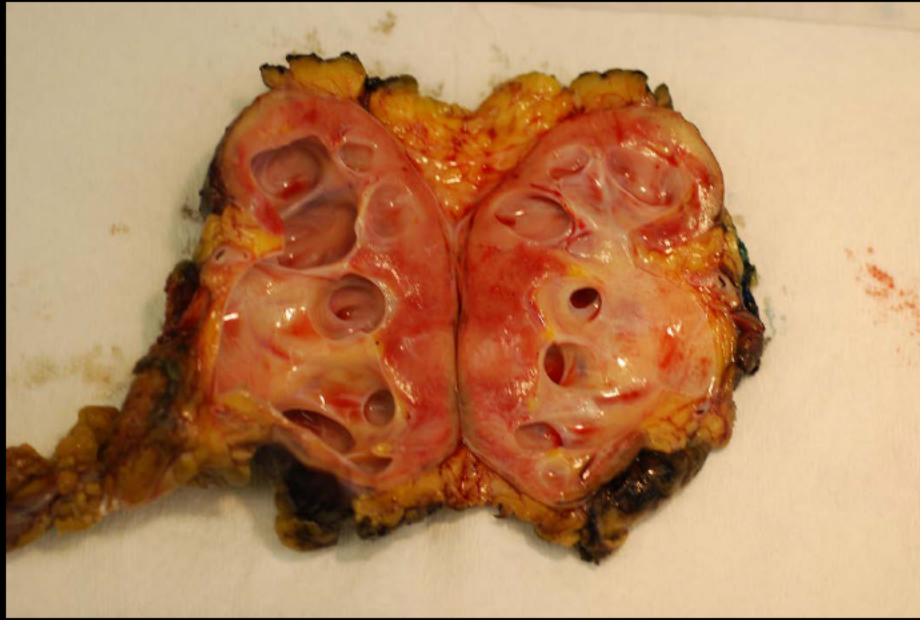Thickness: 0 mm

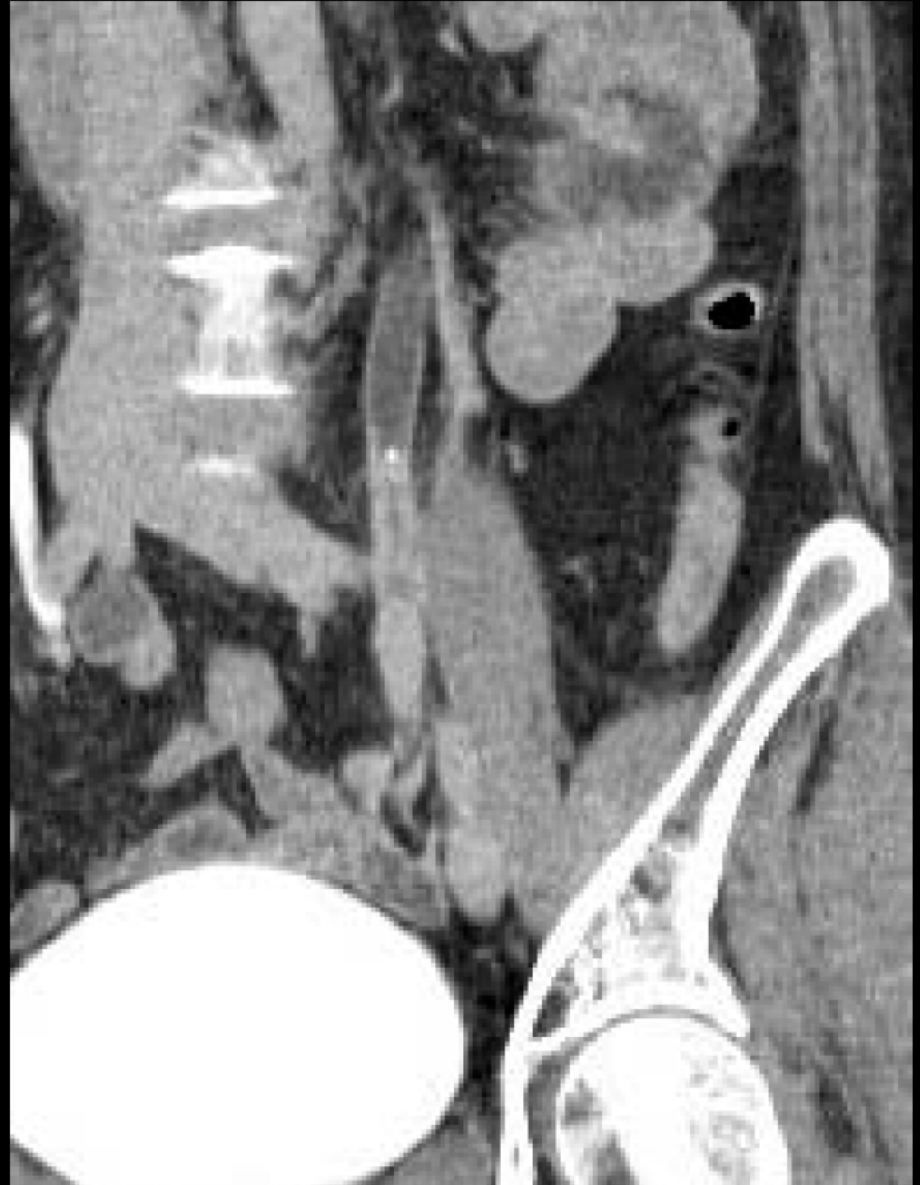
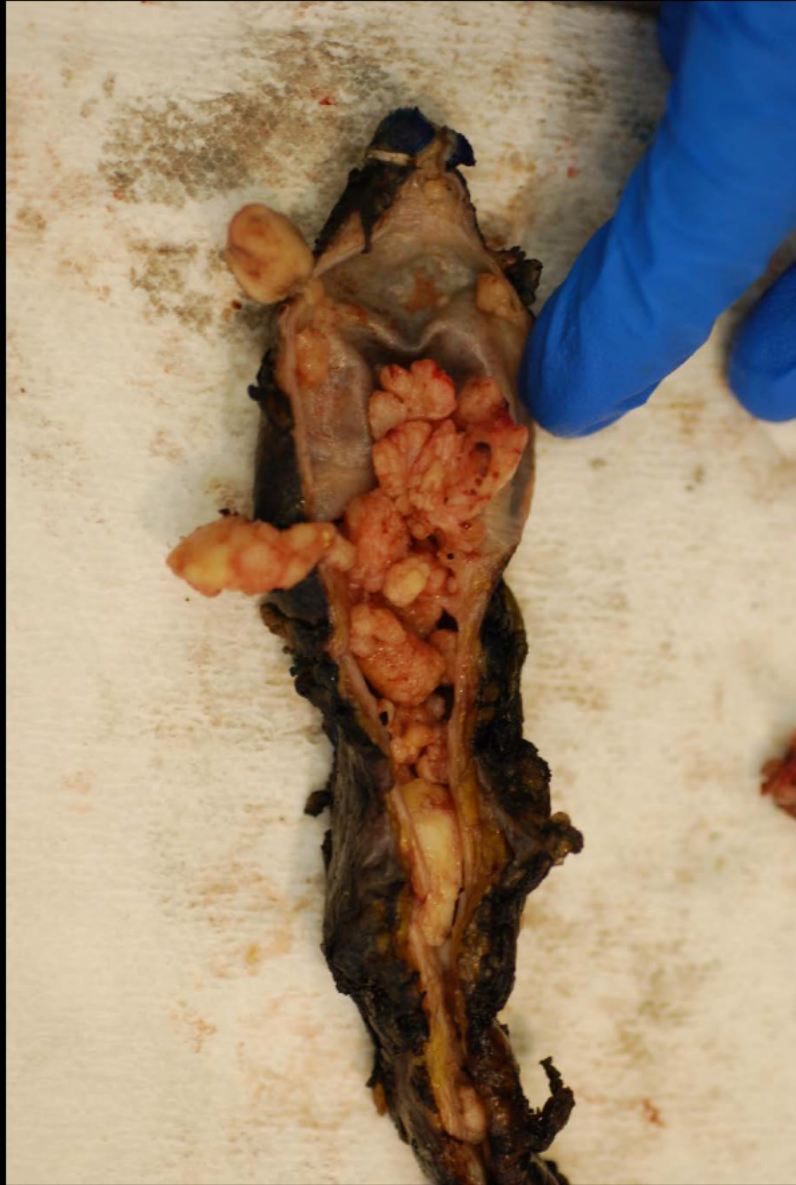
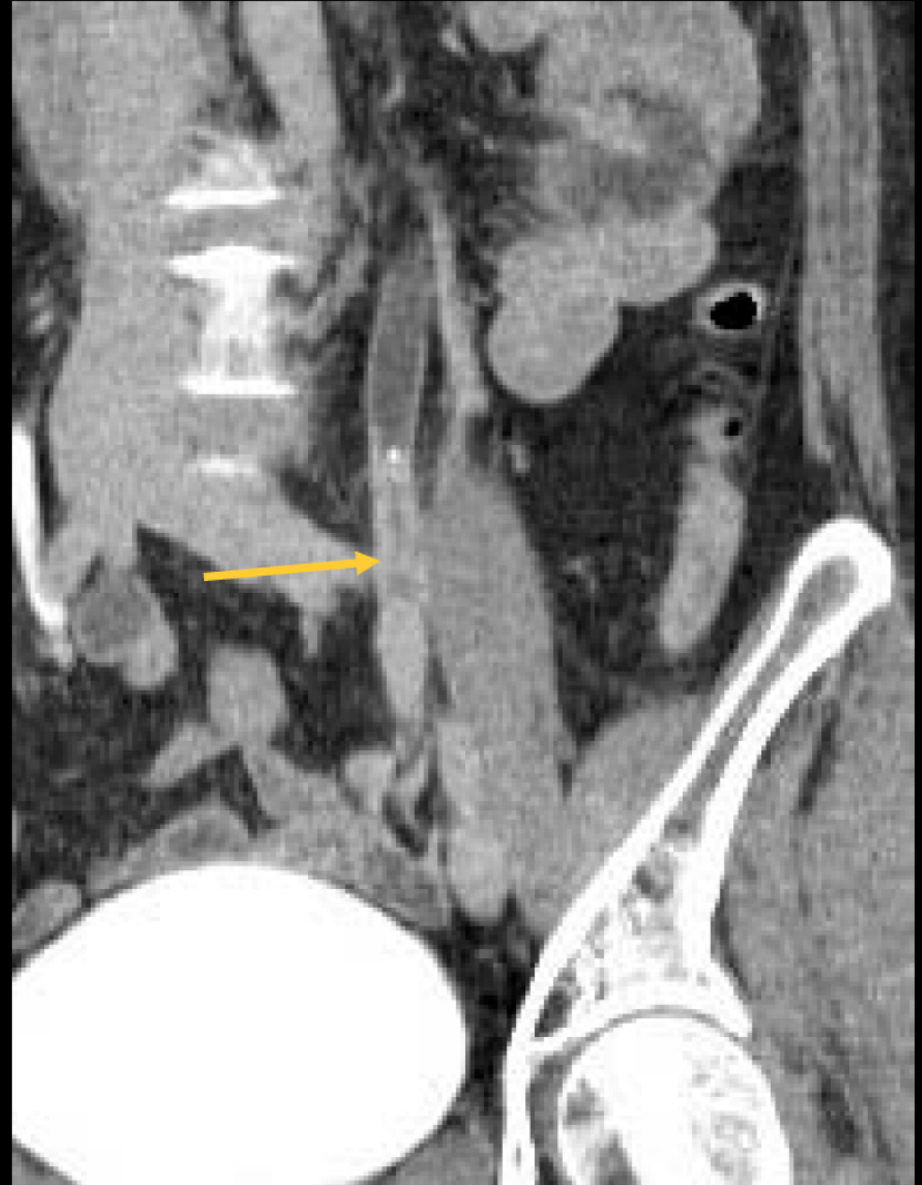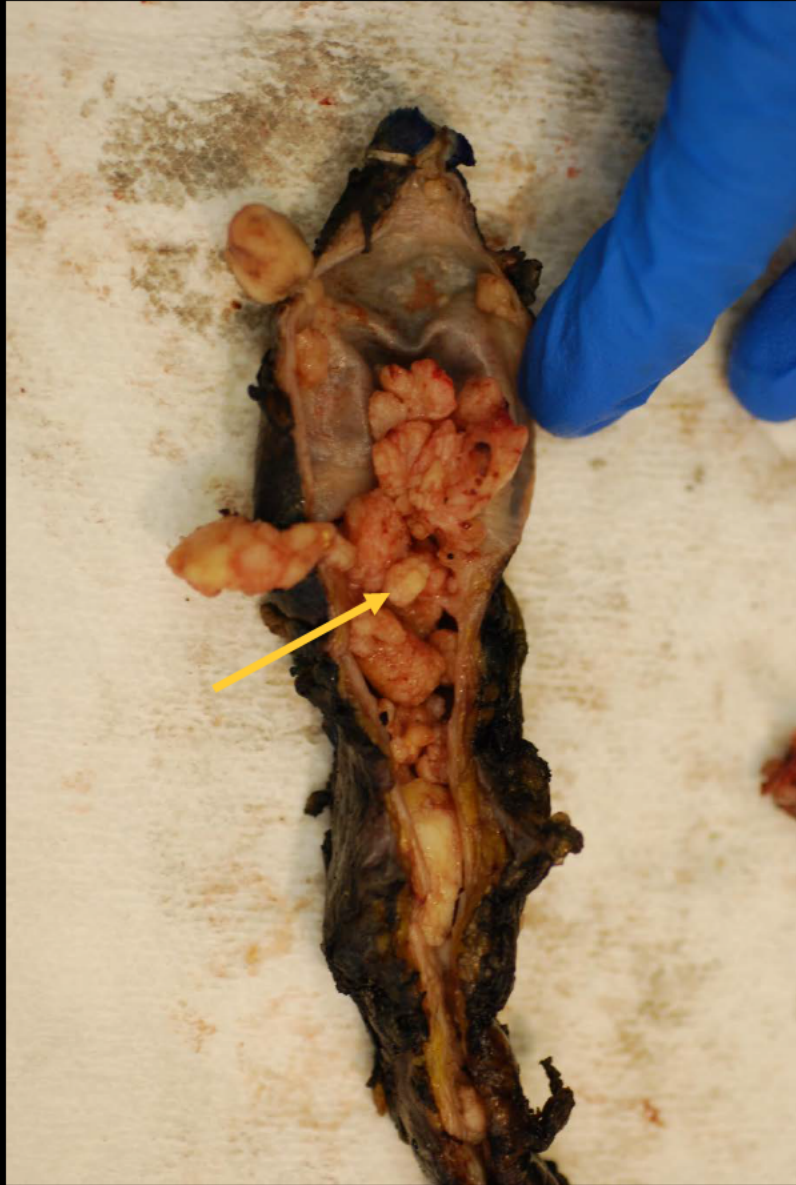Thickness: 0 mm

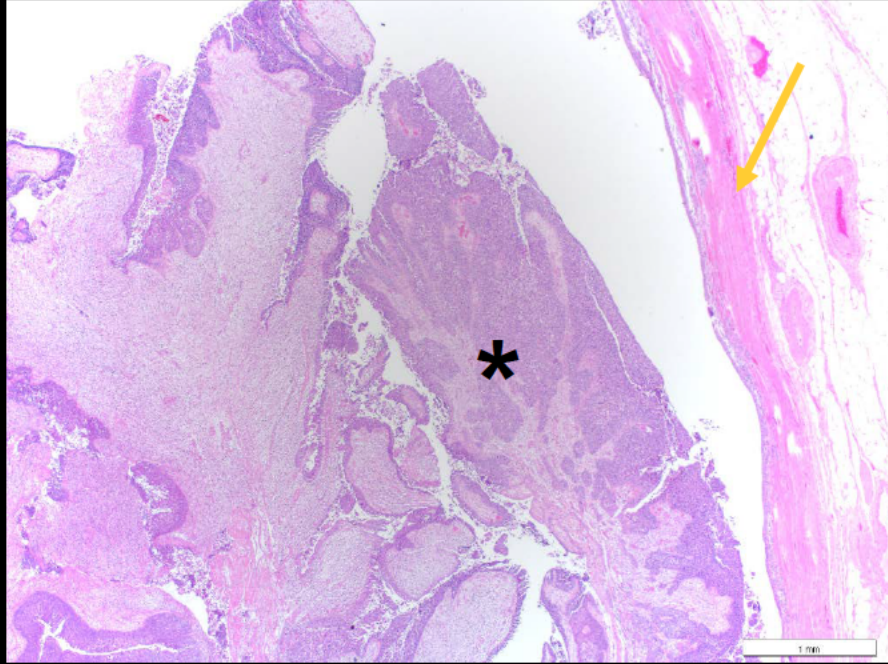


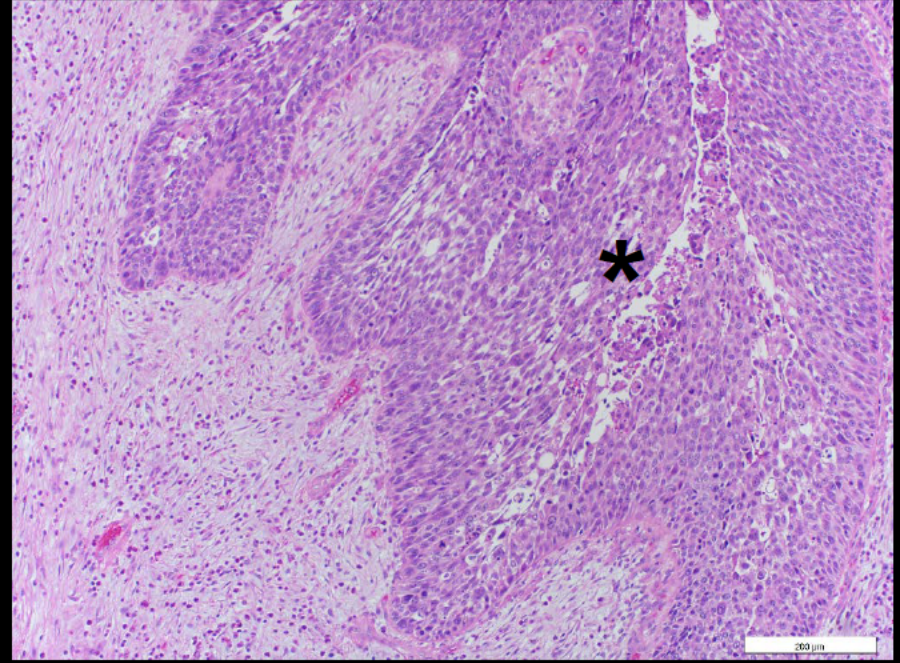
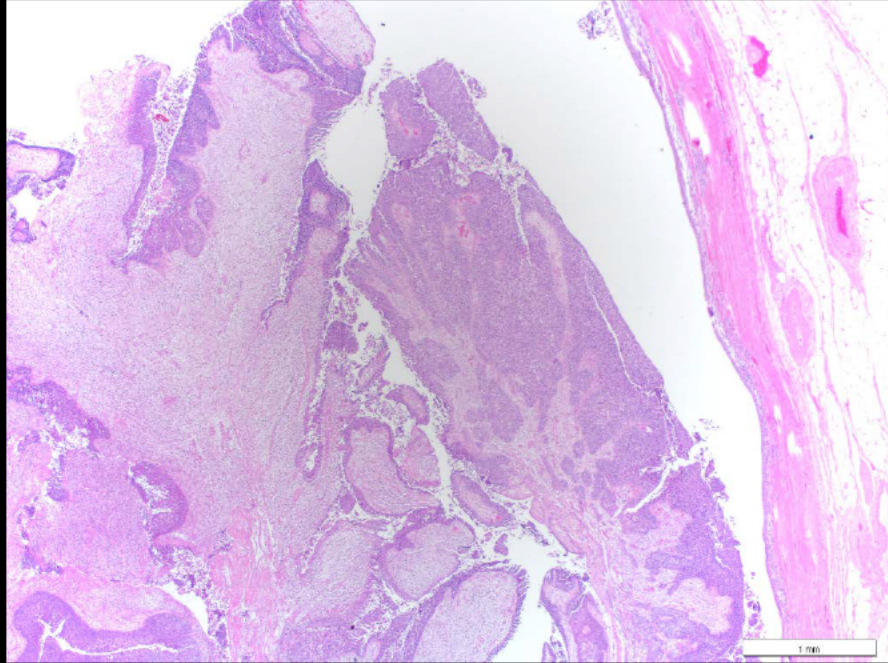
Thickness: 0 mm











Ureteral Urothelial Carcinoma

Russell Kelley
UCSF
San Francisco, CA