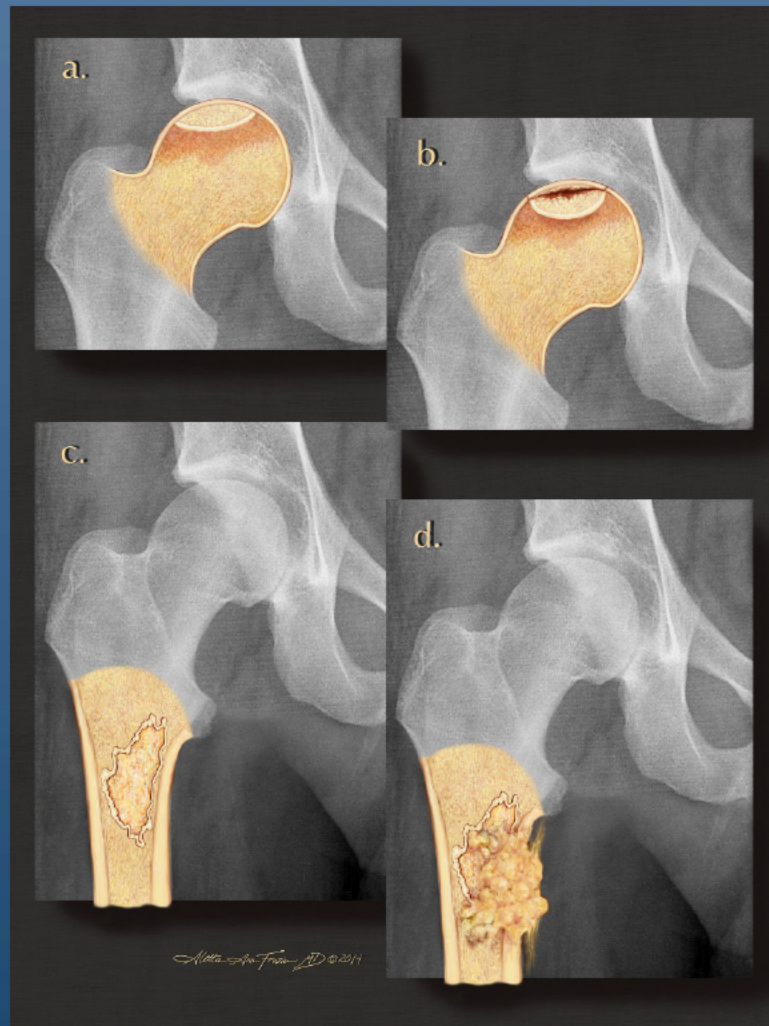


# **Best Cases of the AIRP**

**September-October, 2017**

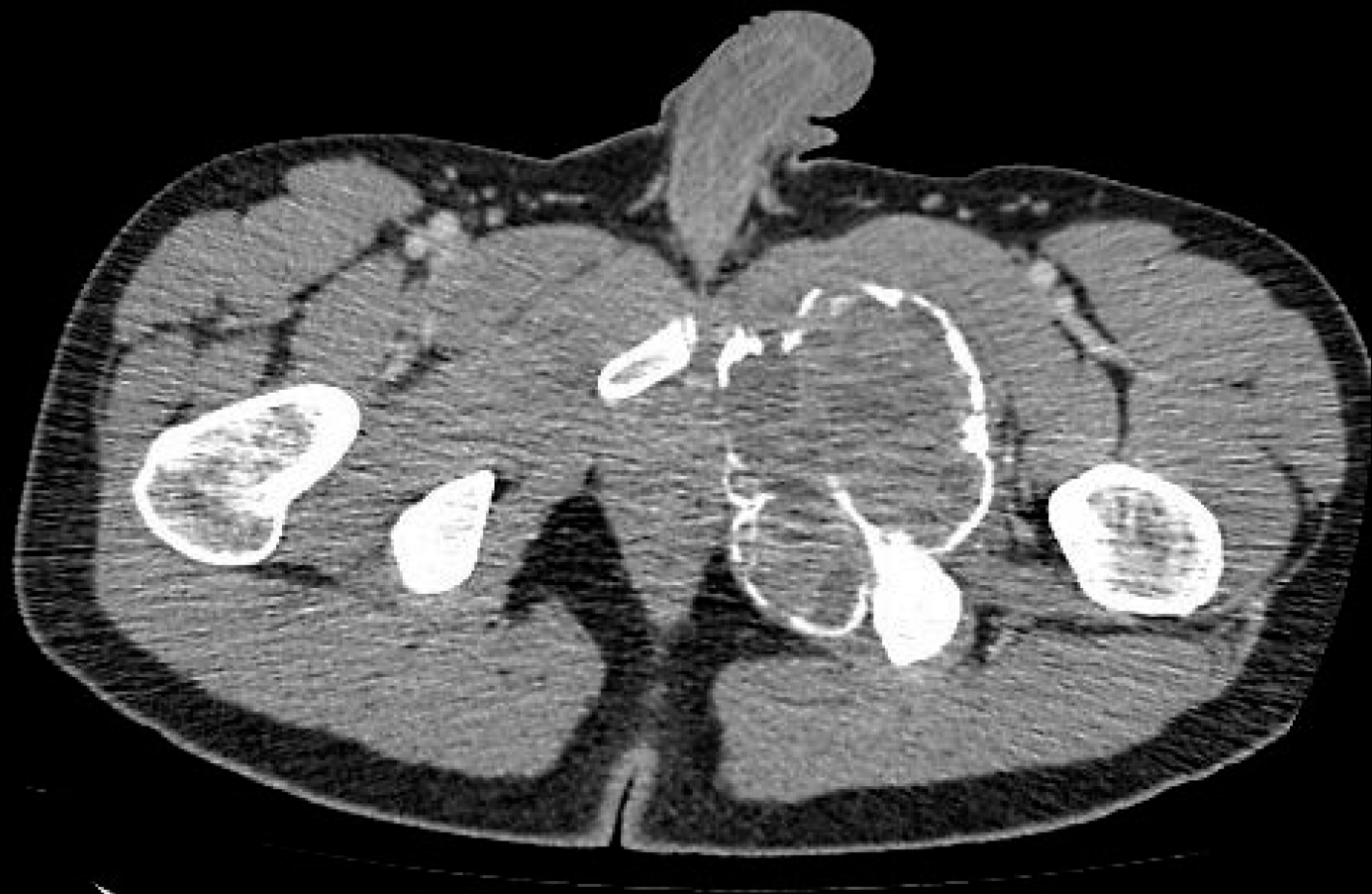# Musculoskeletal Best Case

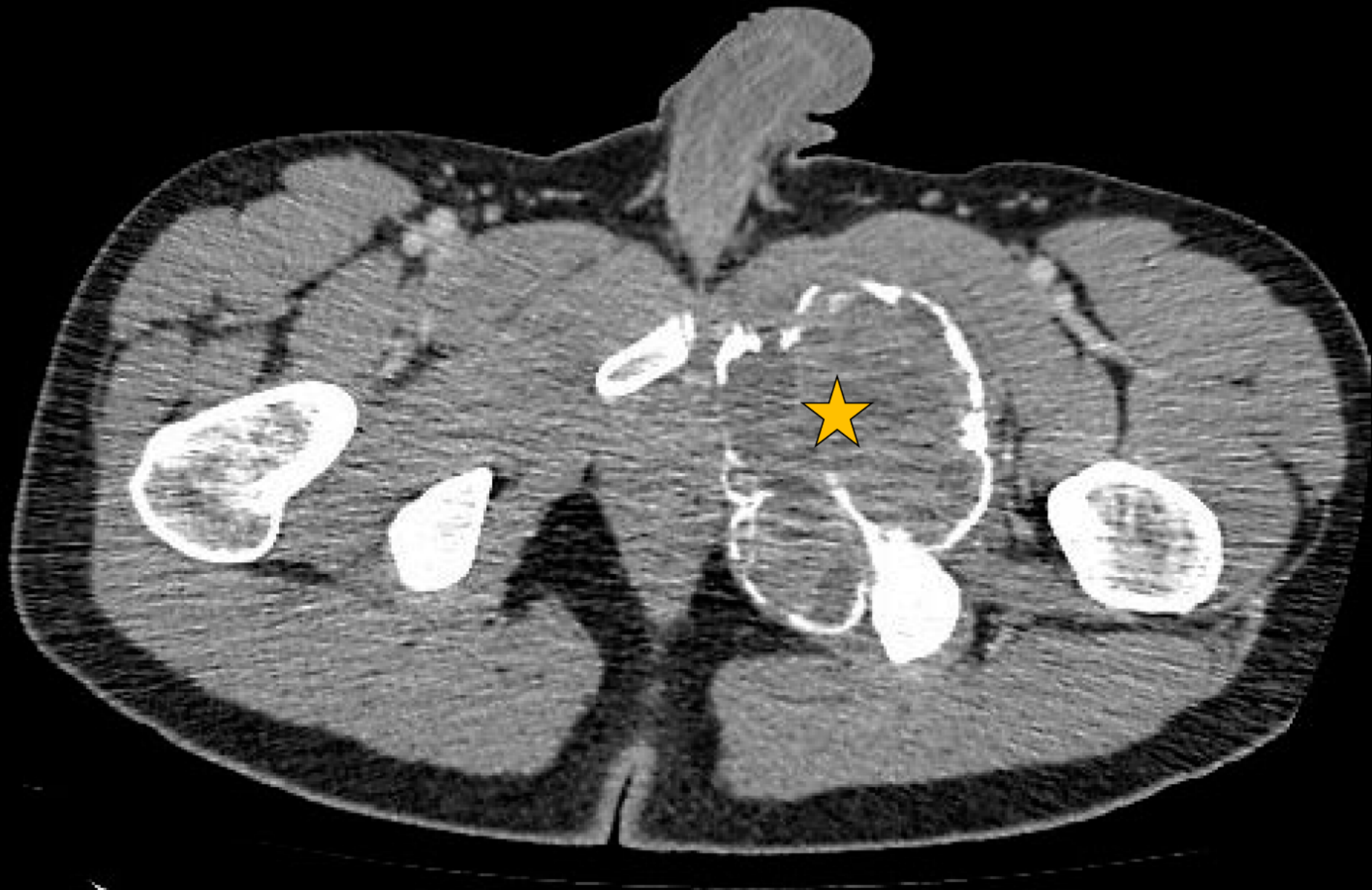

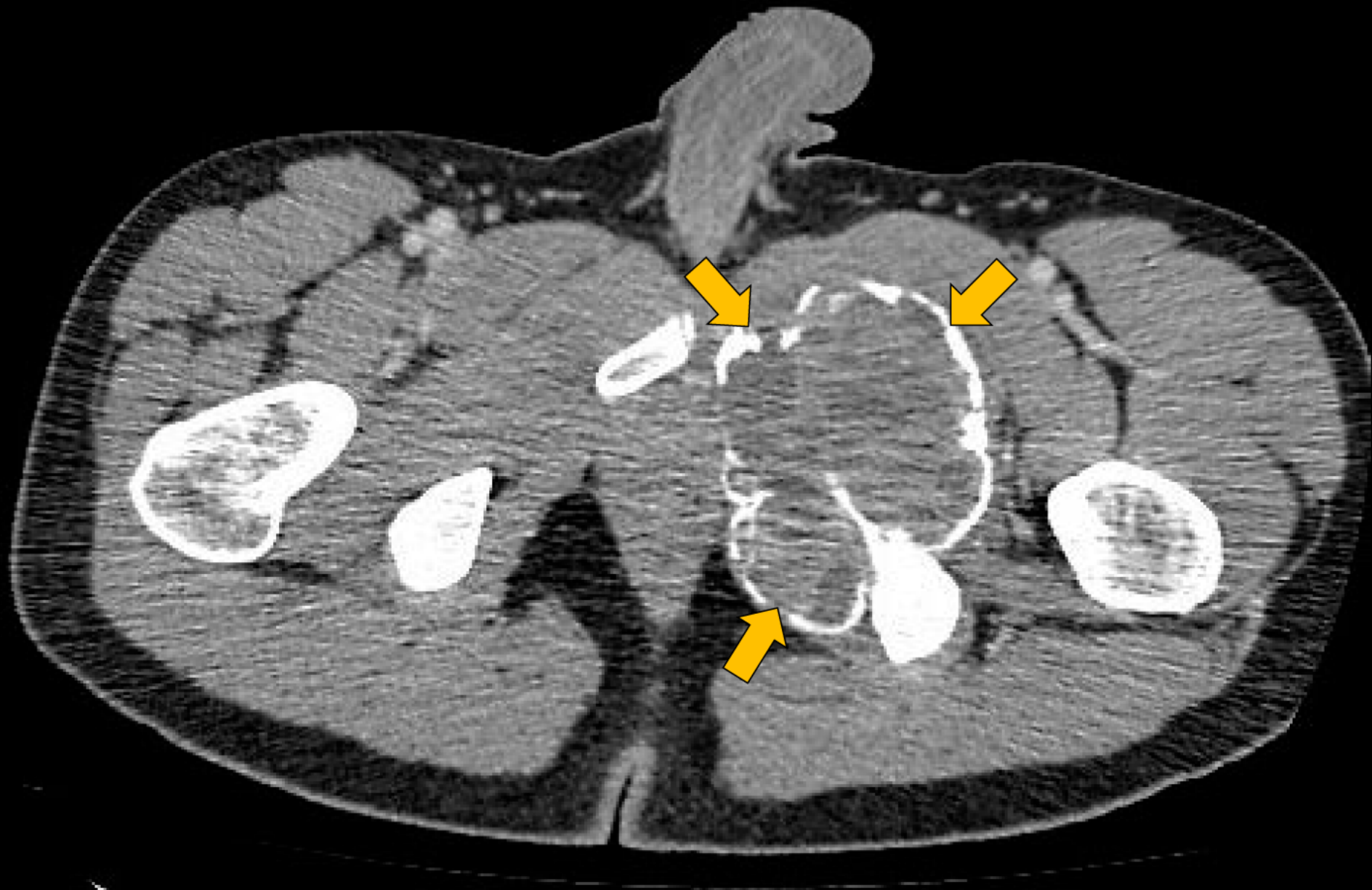


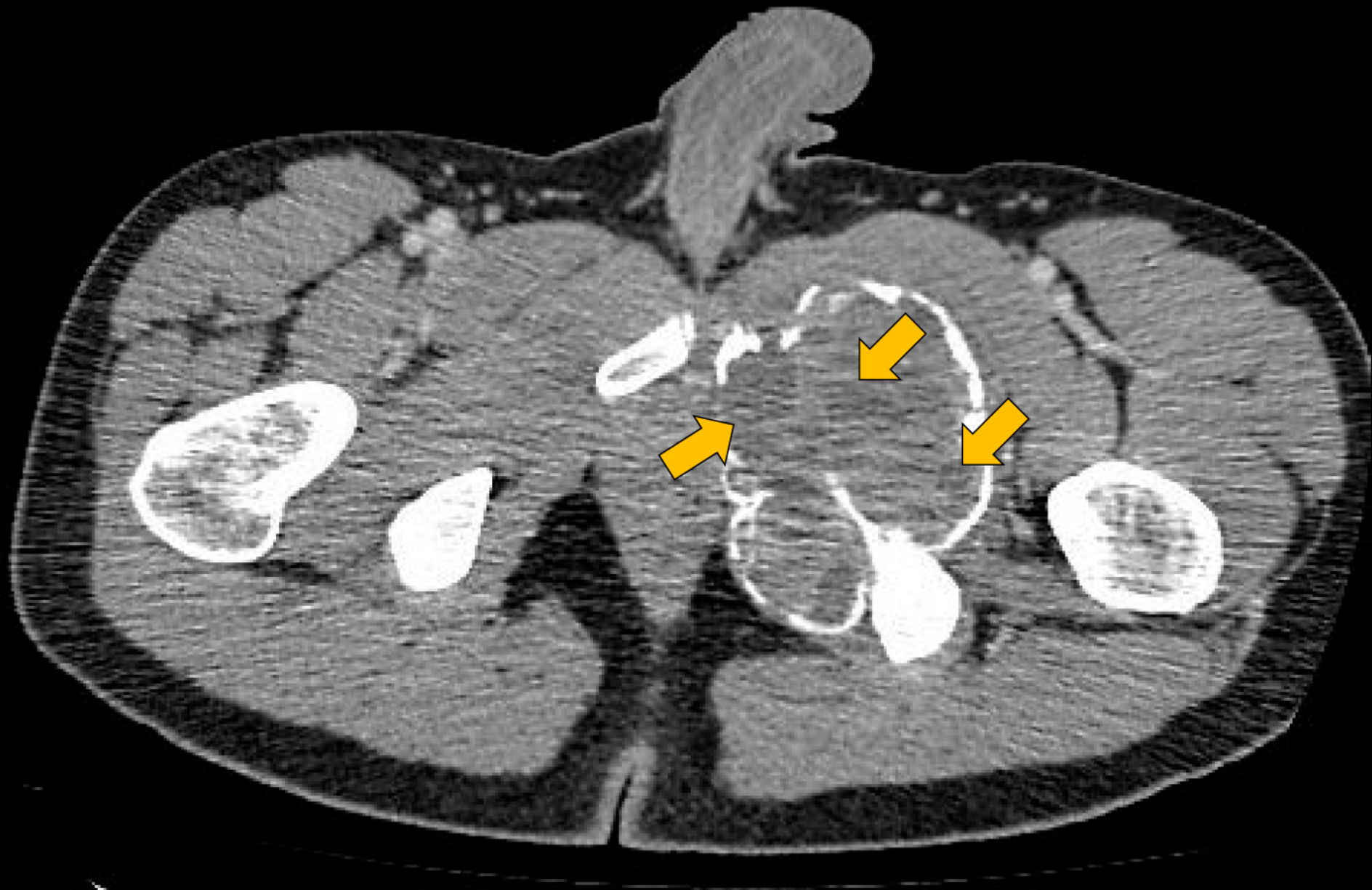## Clinical Information

**A 19-year-old patient, with no prior history, presents to ED for 3-hour epigastric and right lower quadrant pain. Incidental finding on CT.**

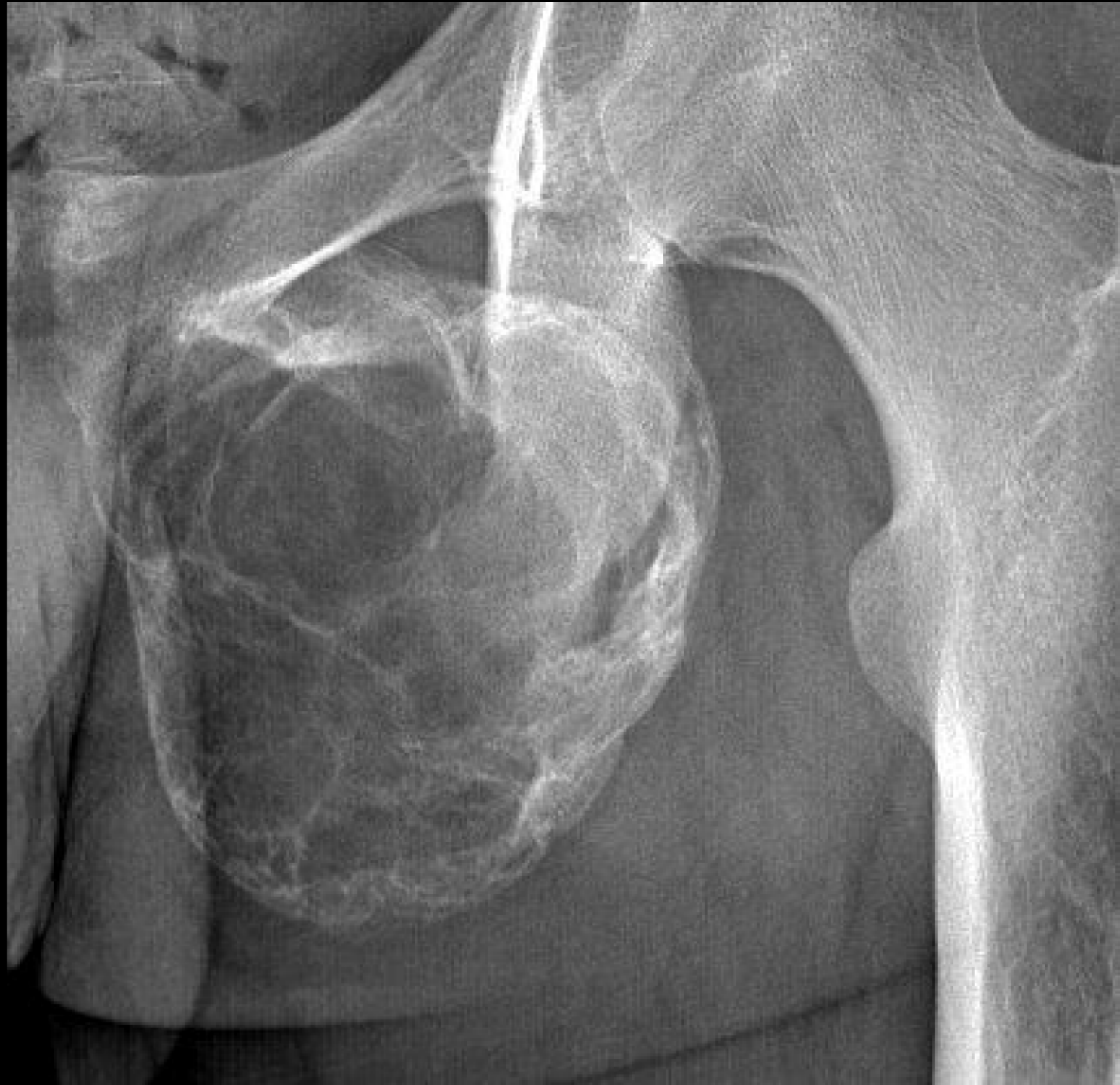




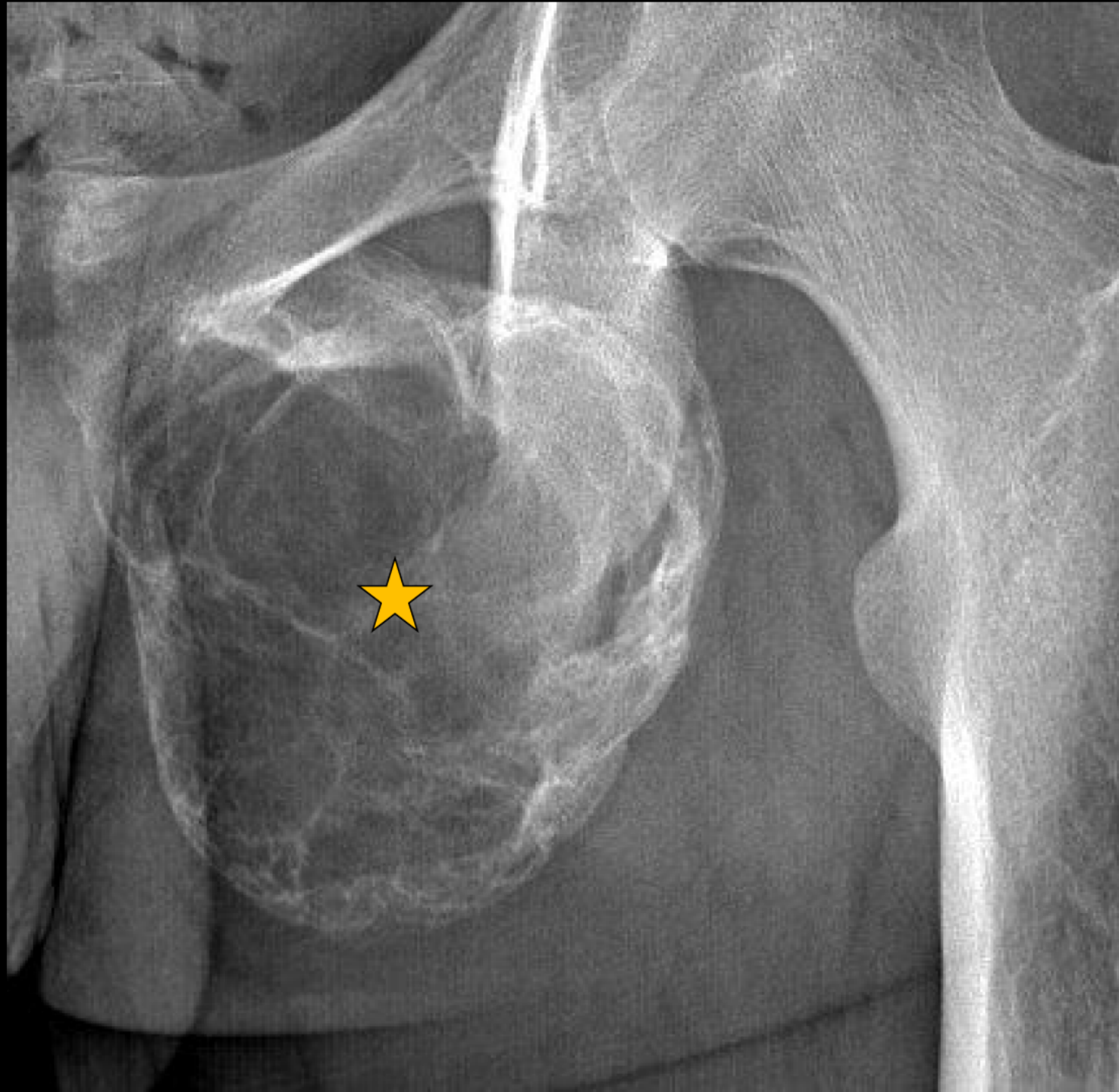


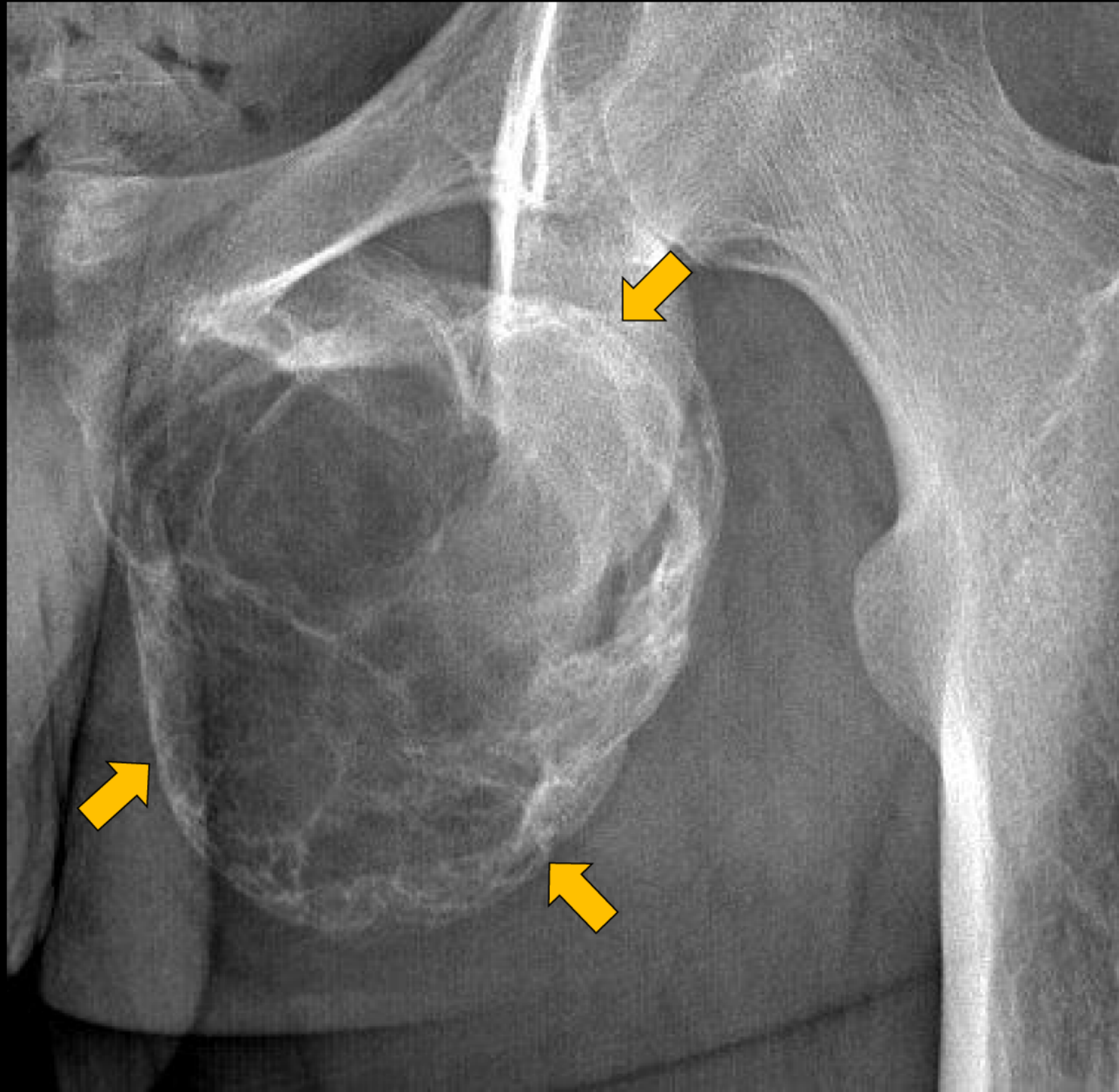


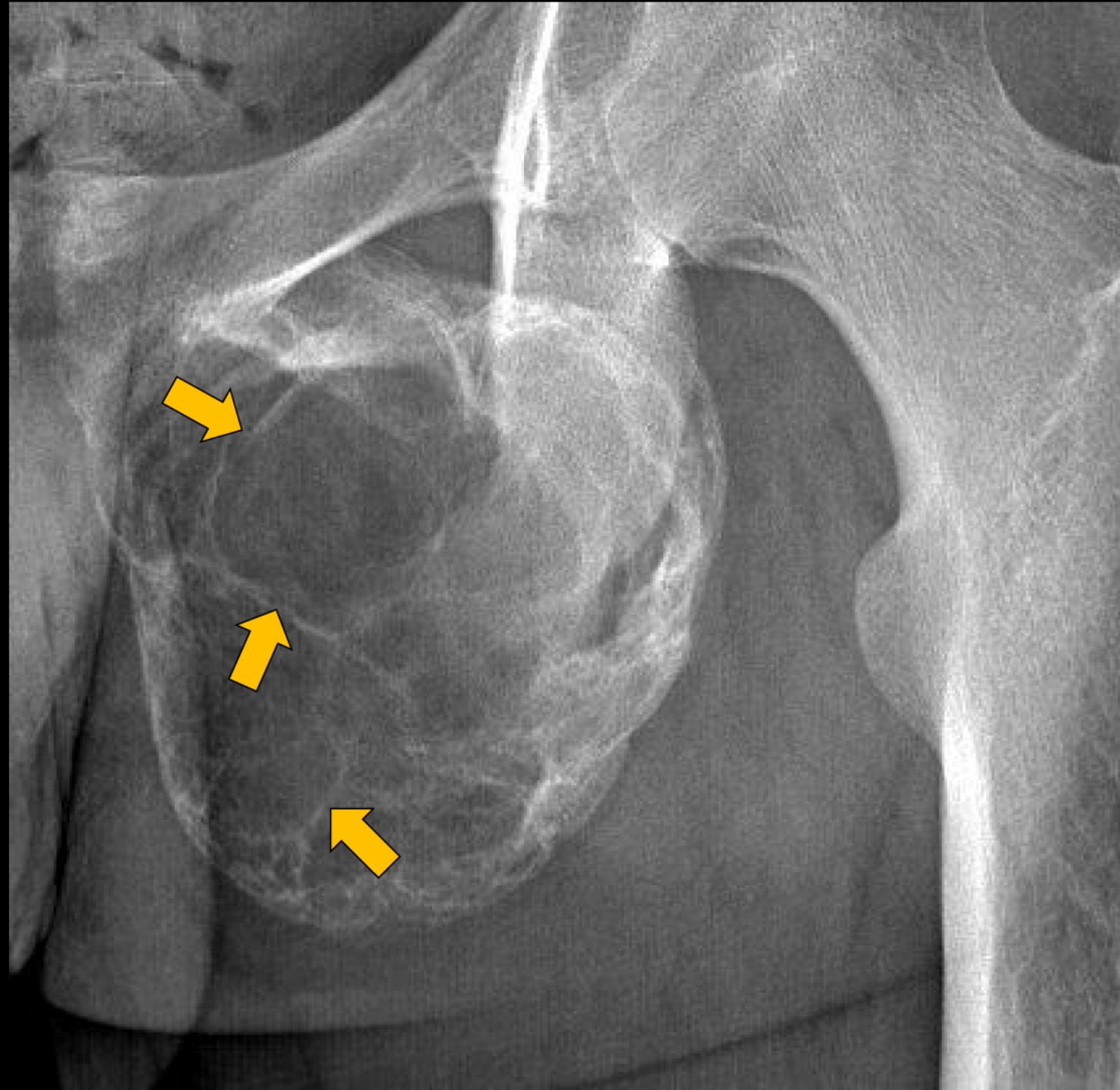




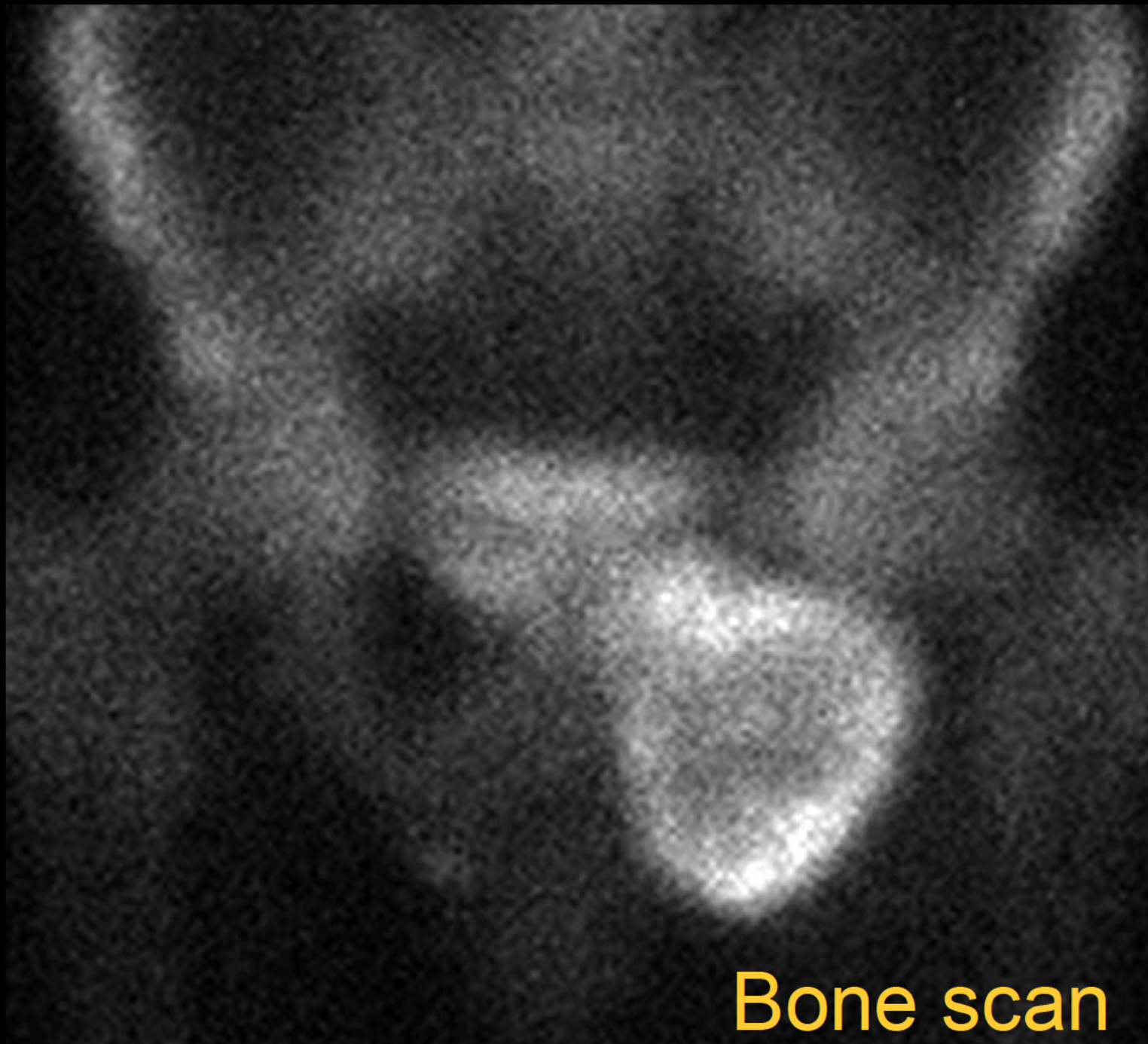




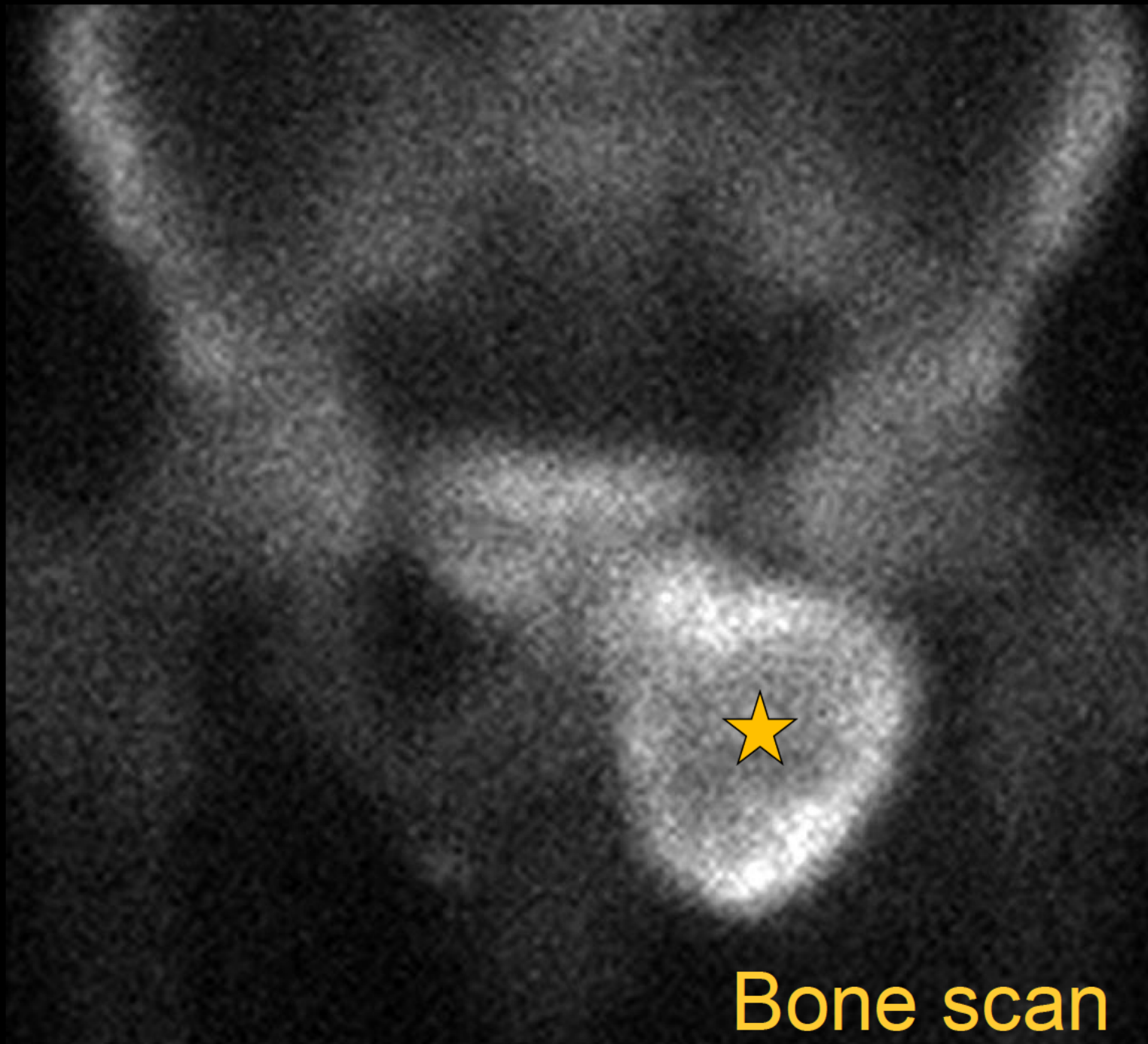


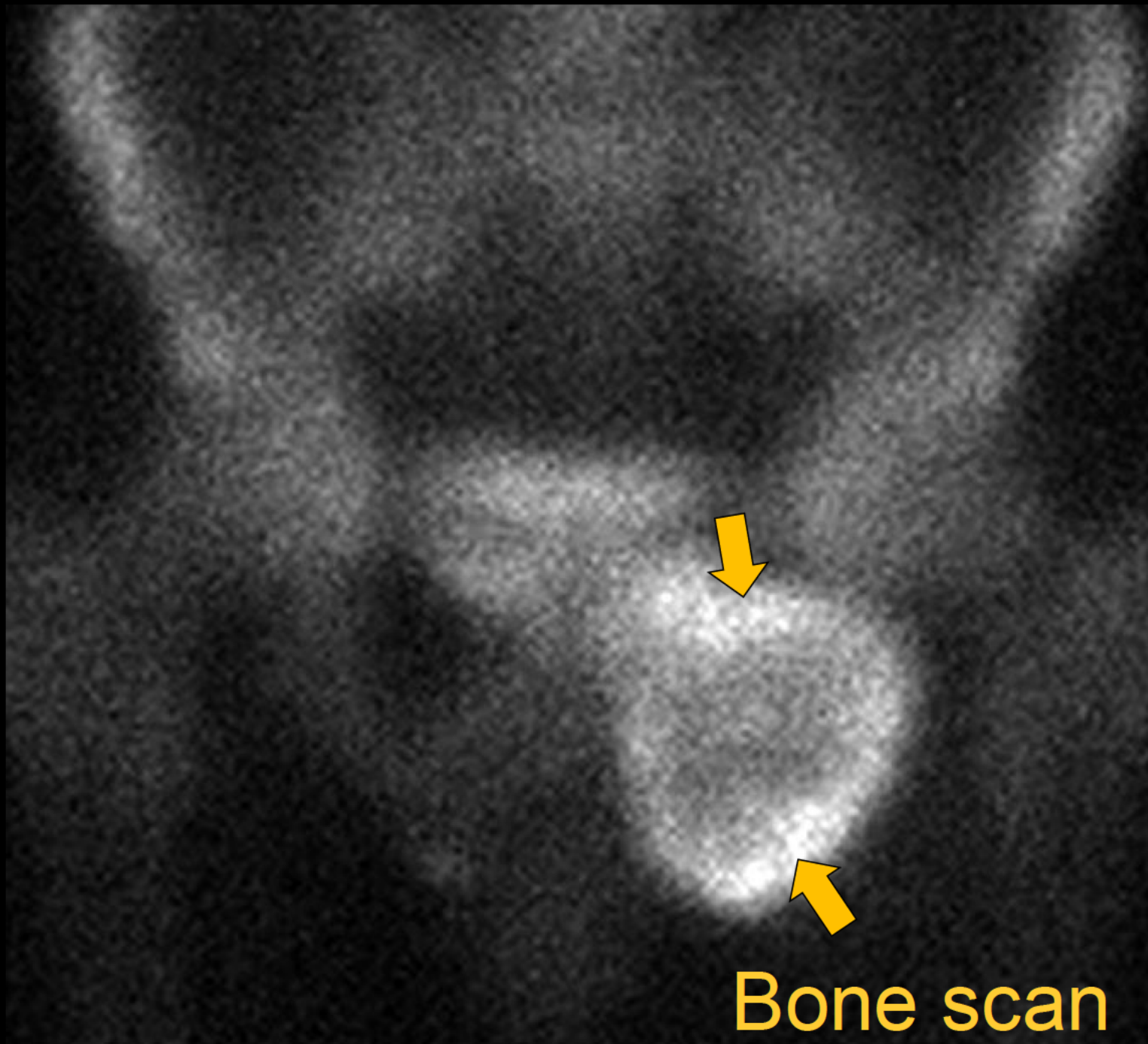






Bone scan

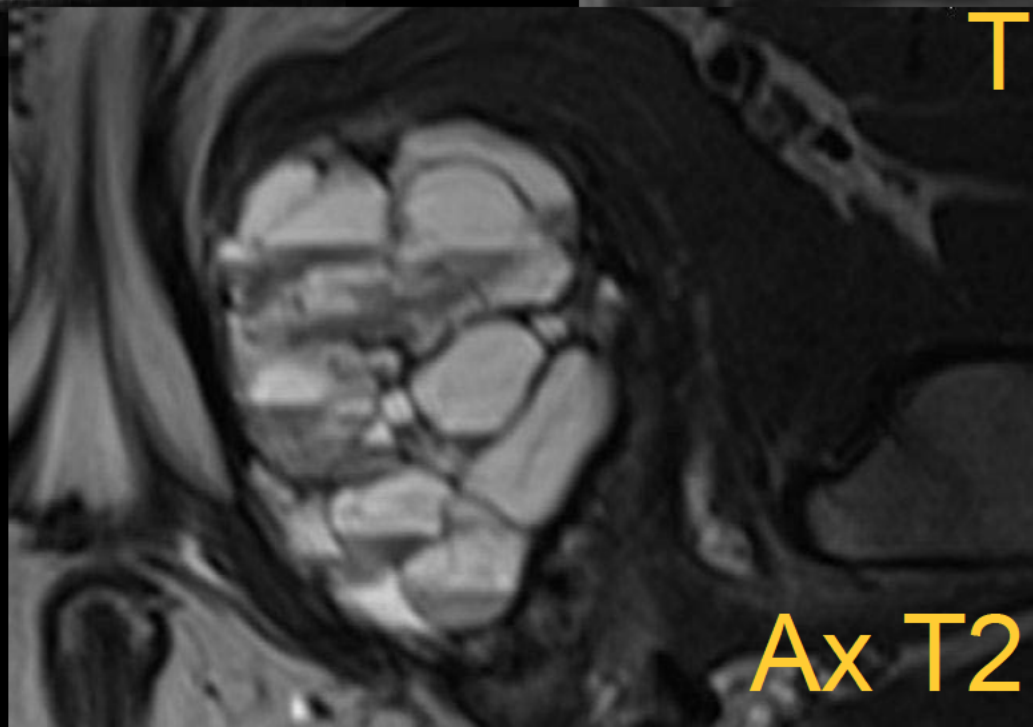
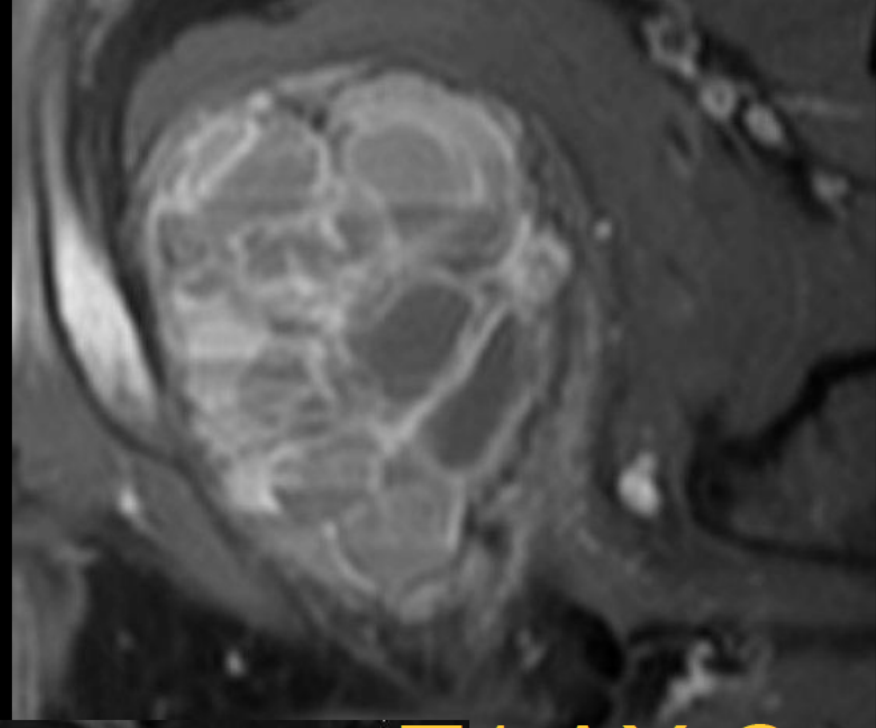
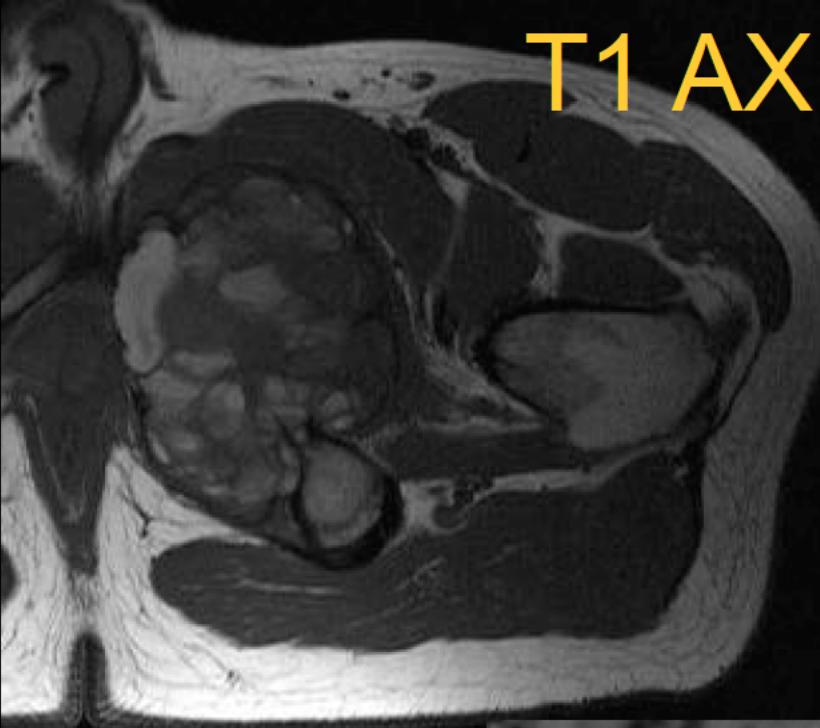


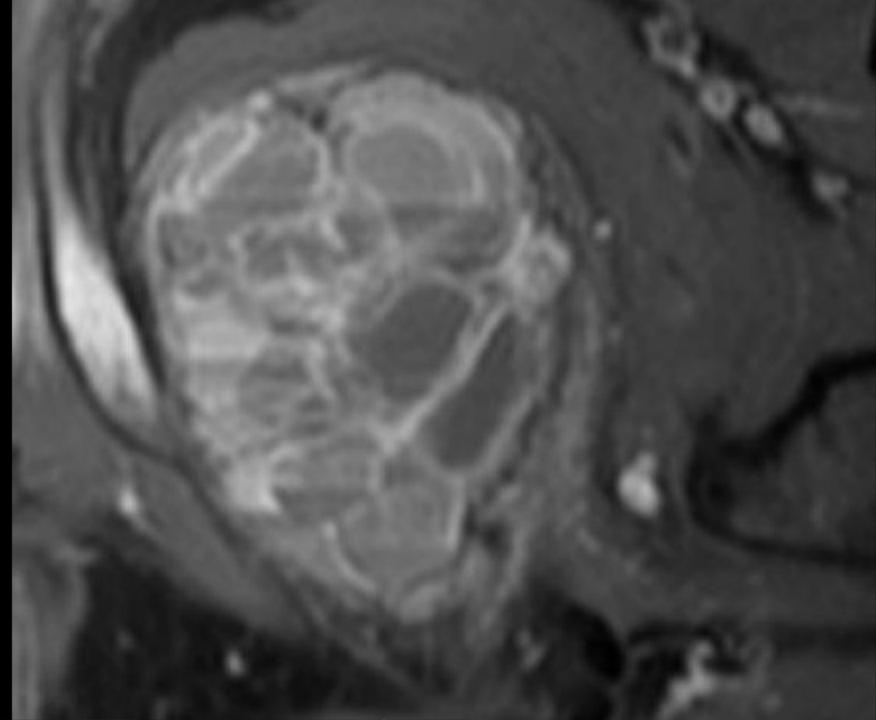
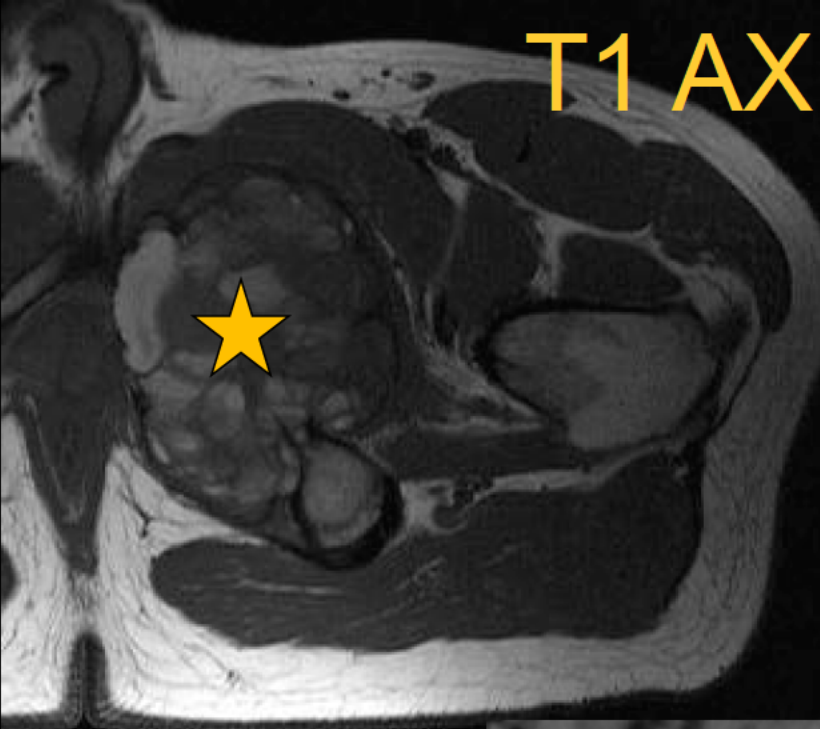




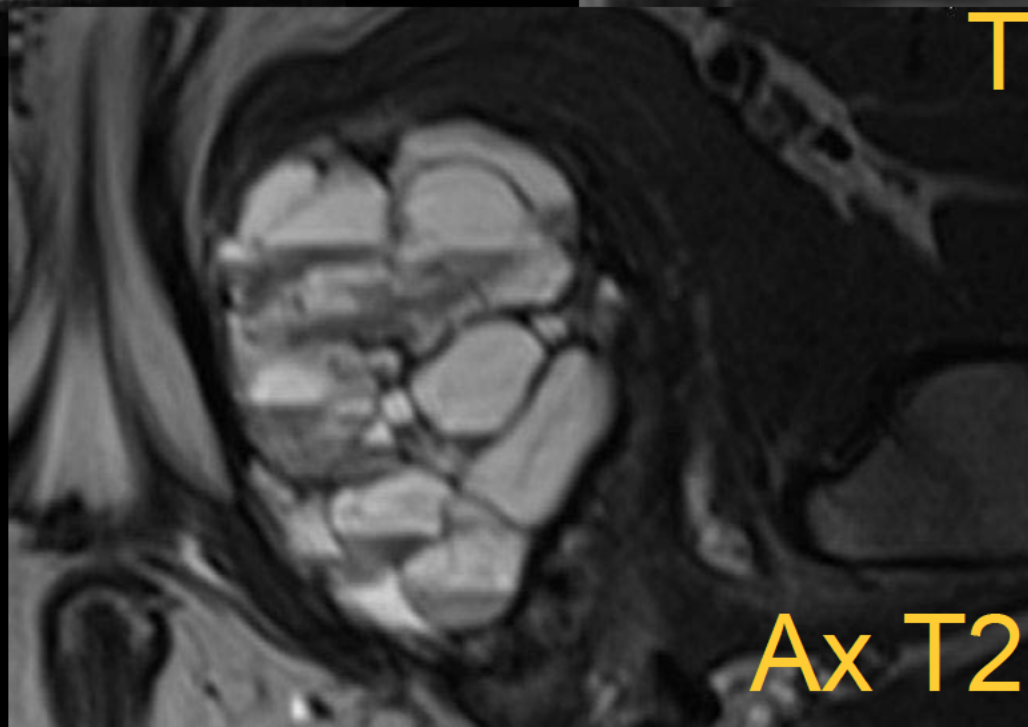






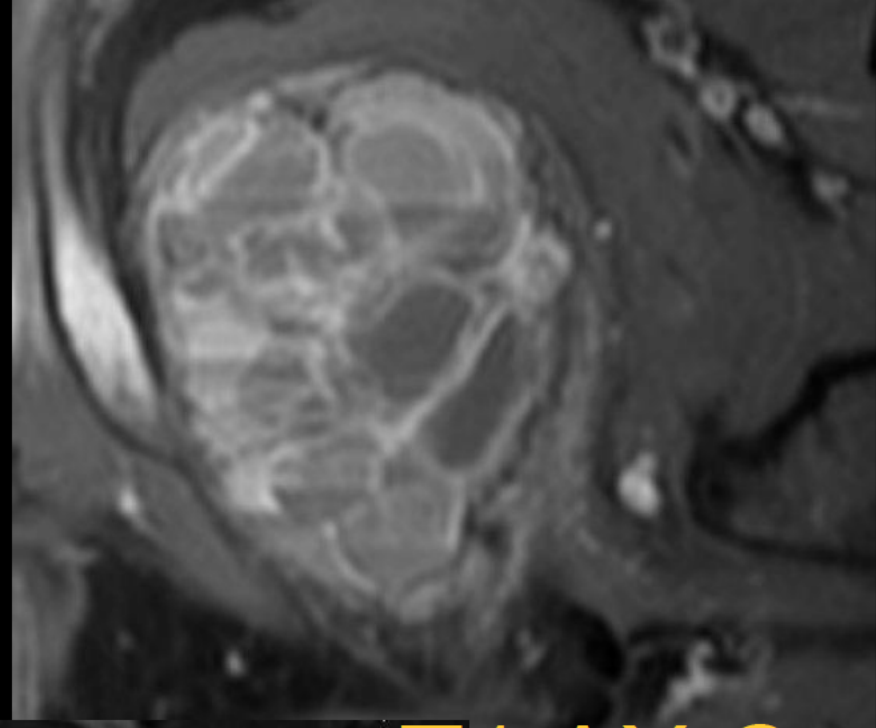
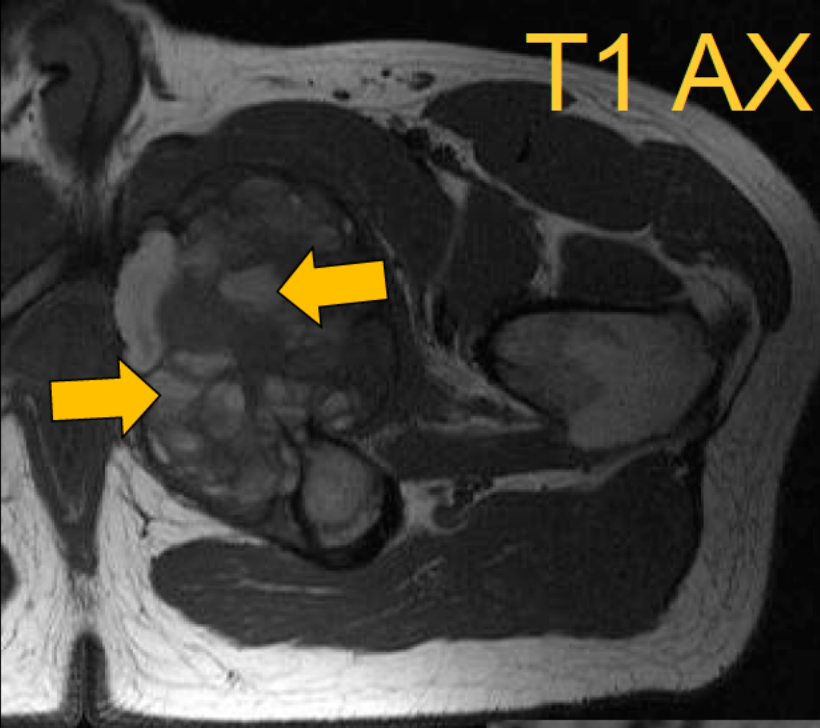


T1 AX C+

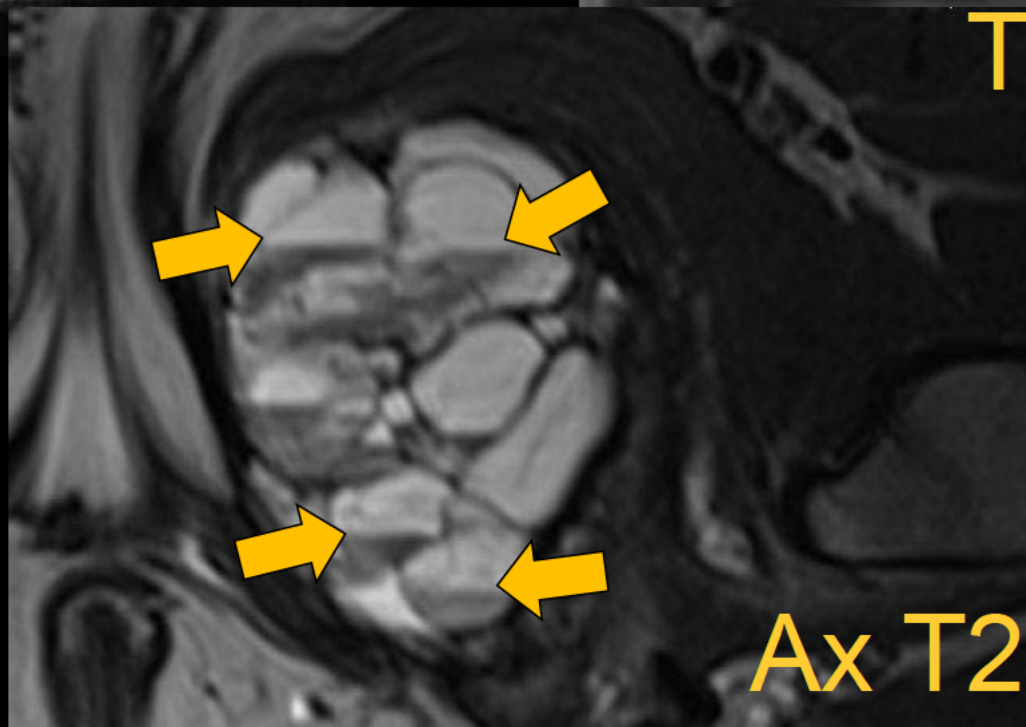


Ax T2

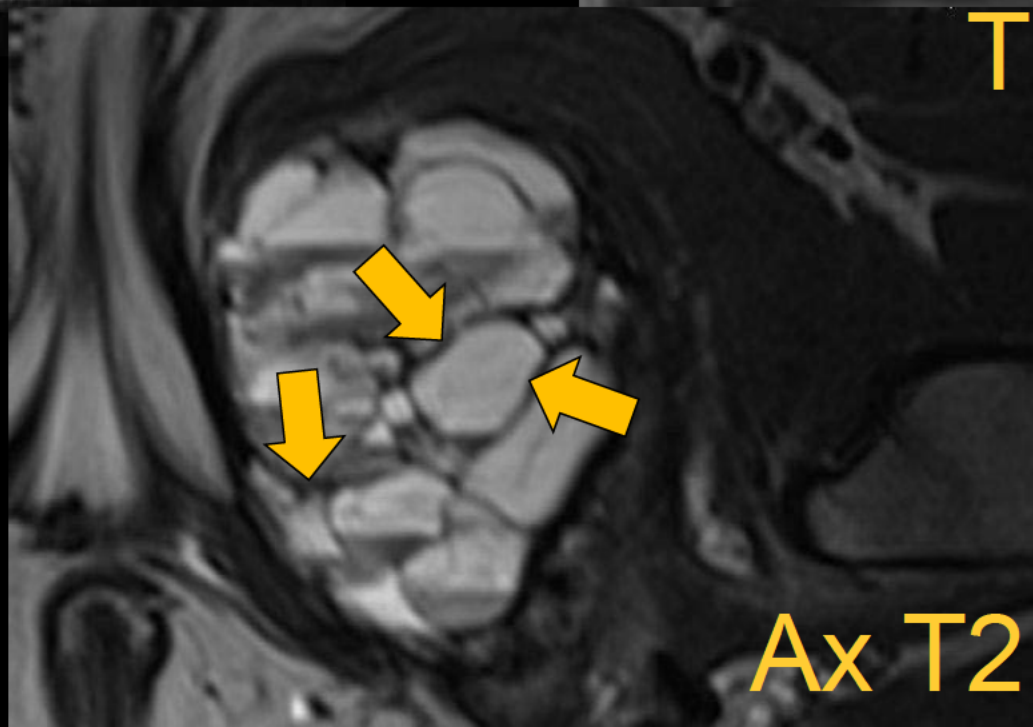
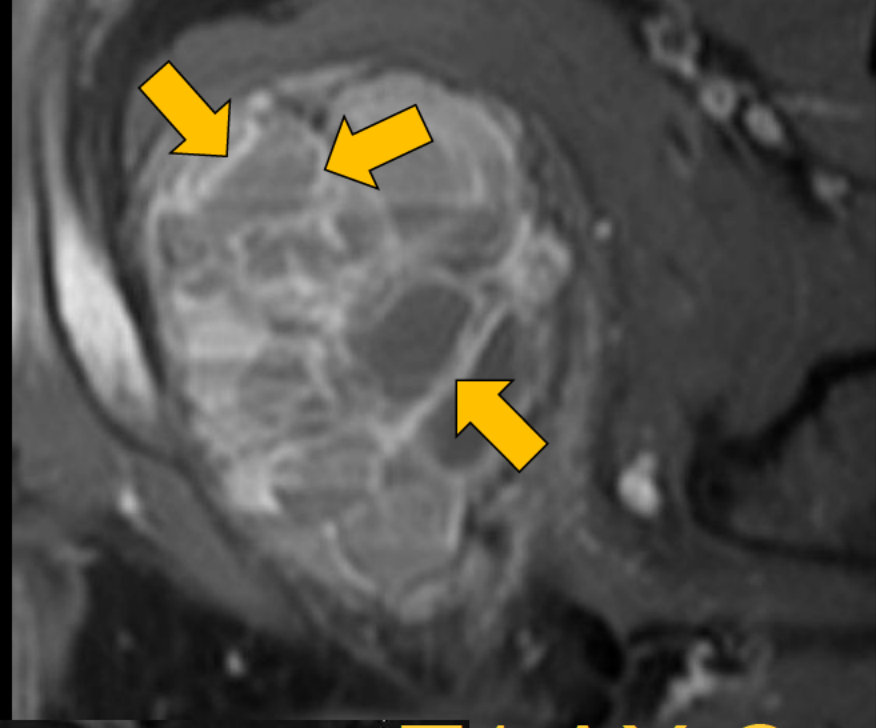
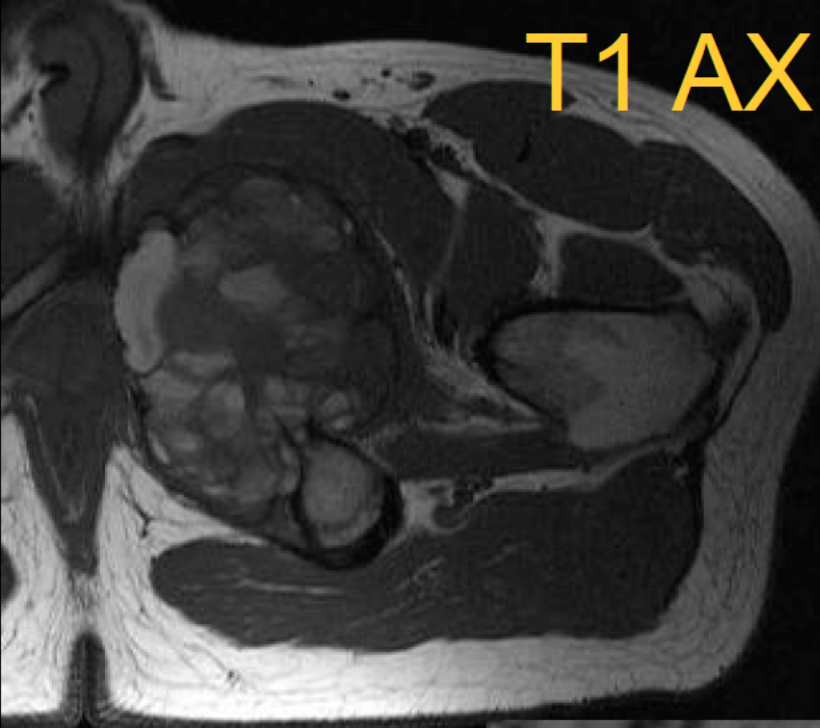




T1 AX C+



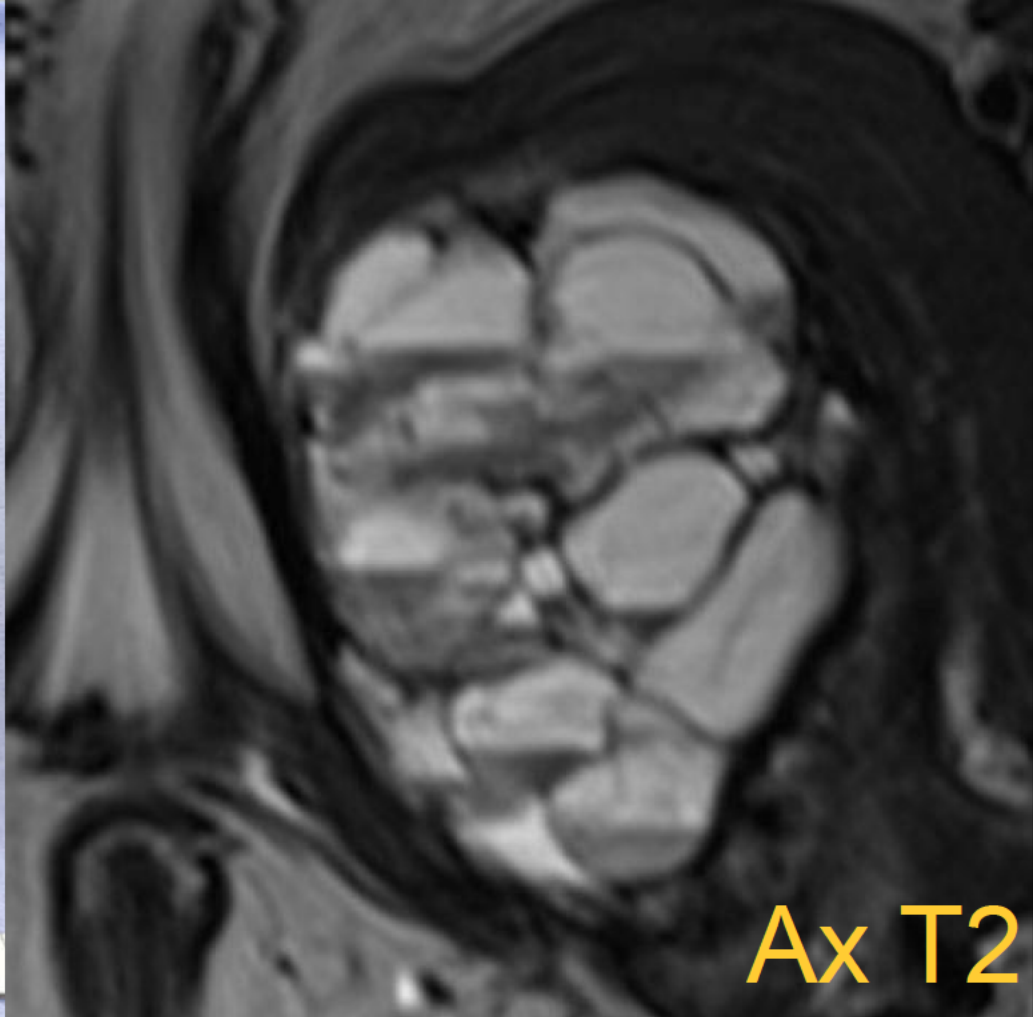
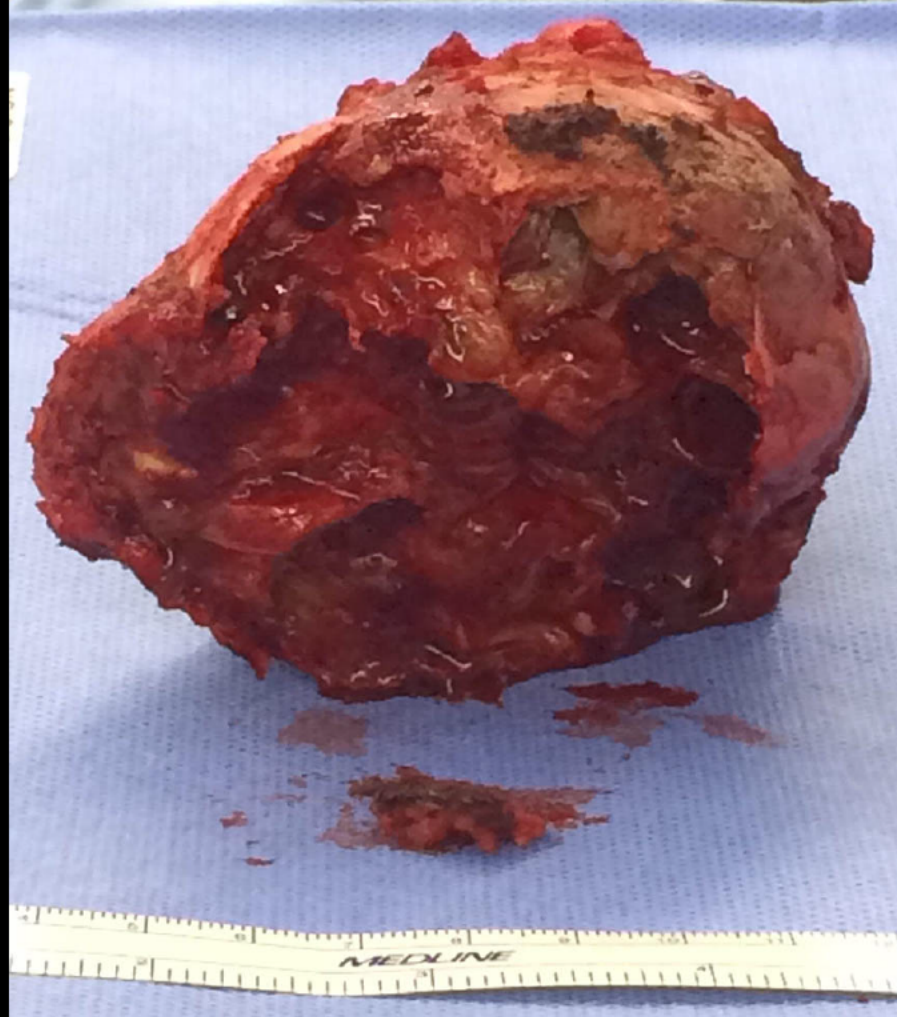
Ax T2

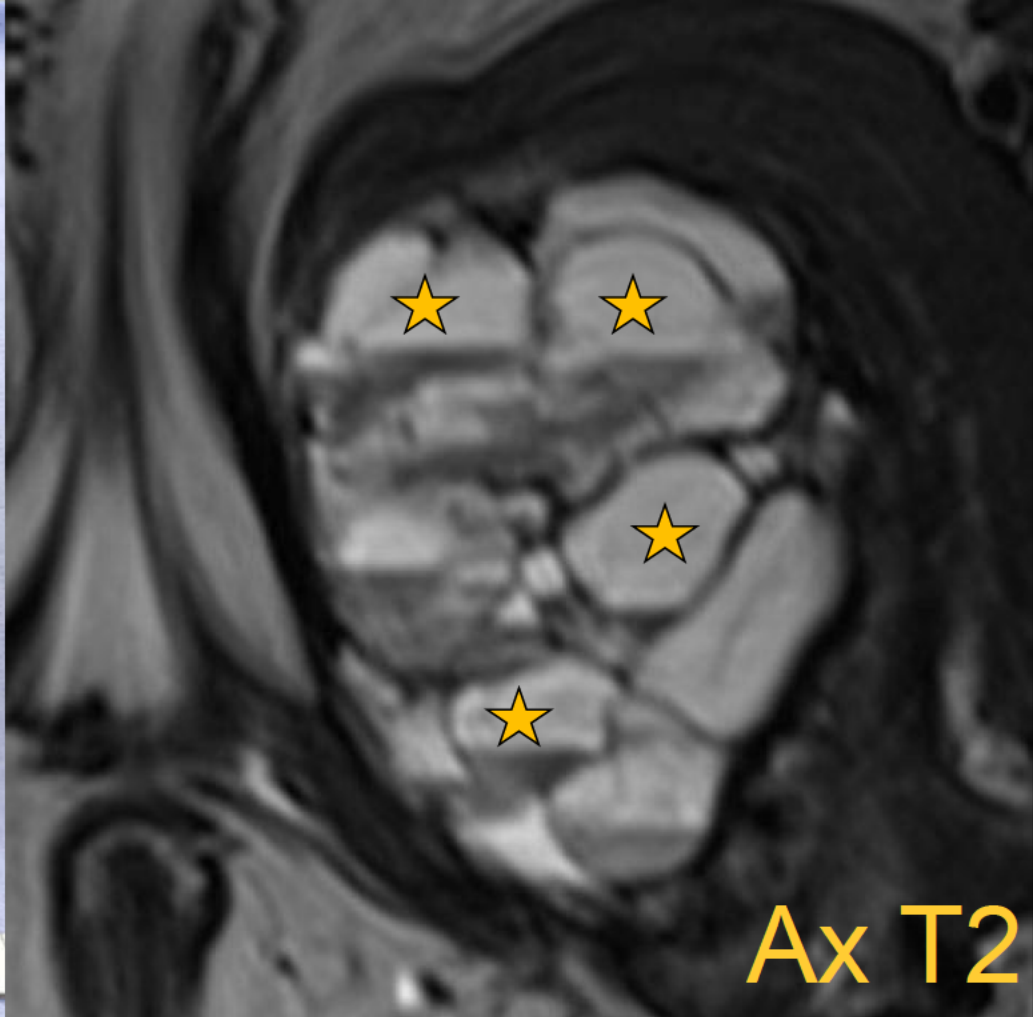
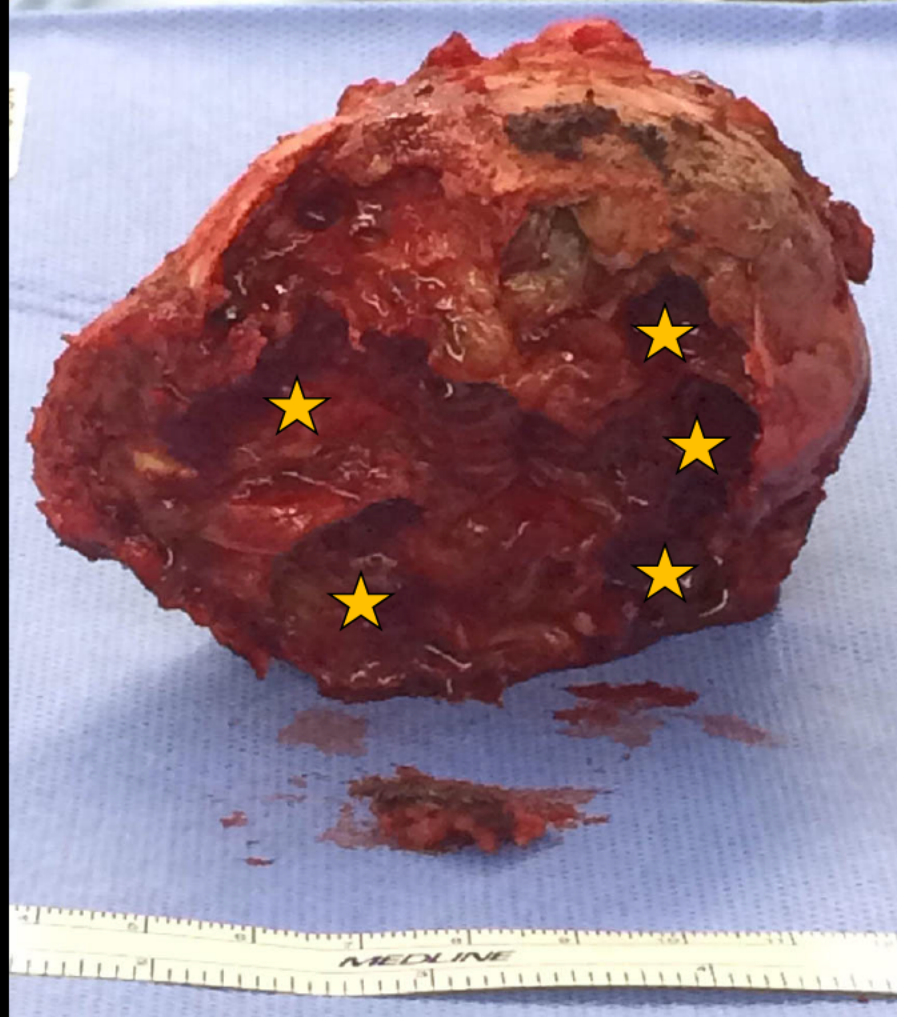

T1 AX C+

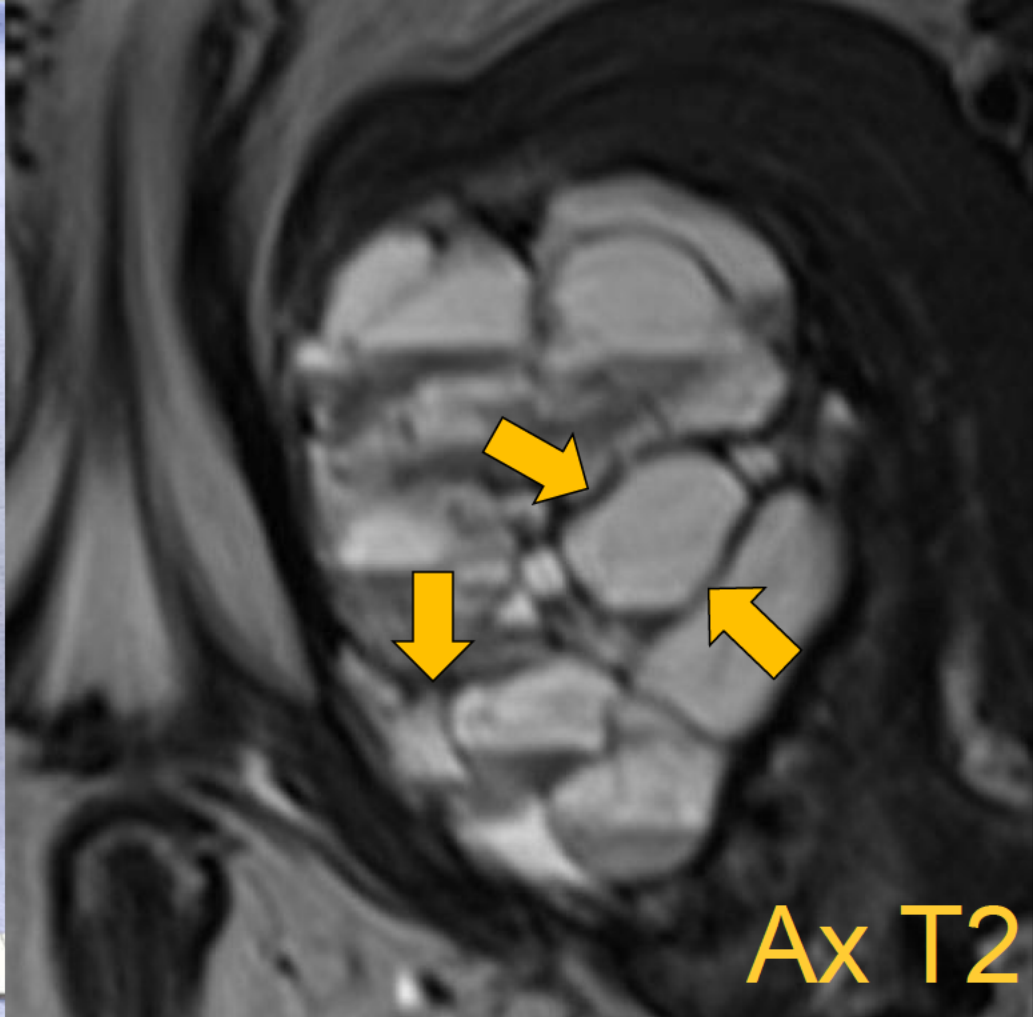
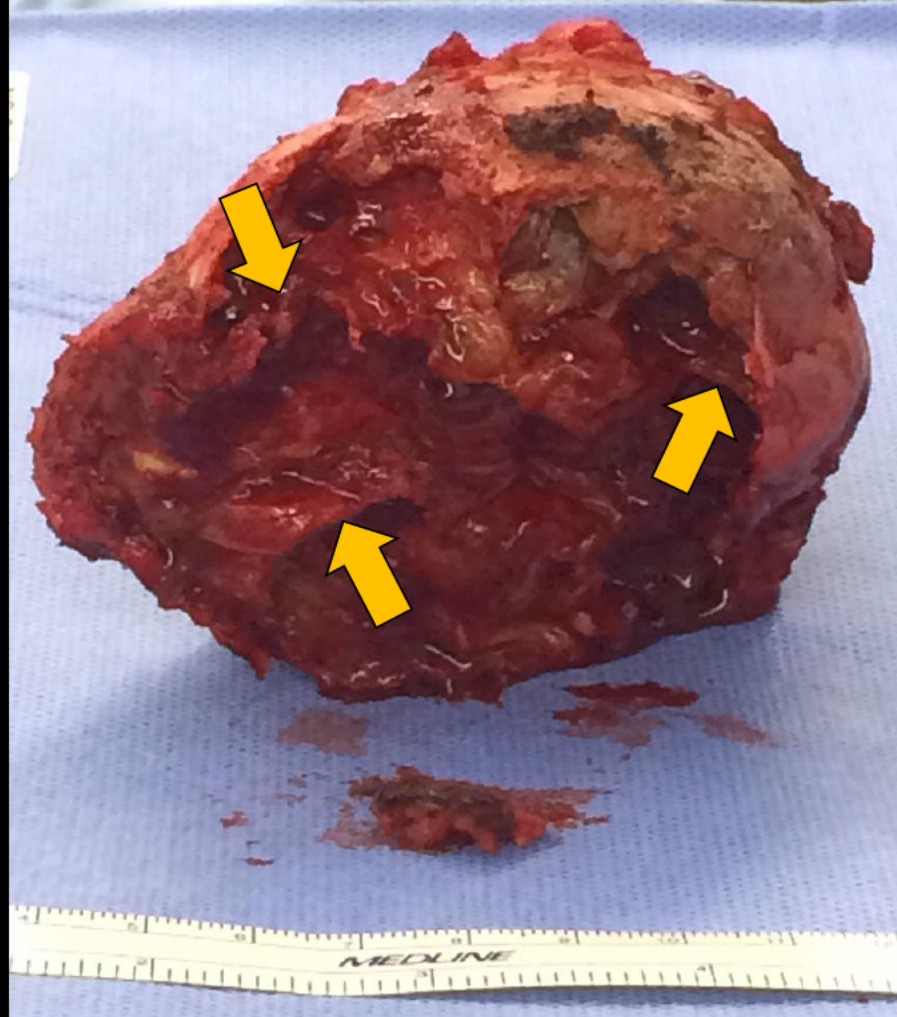
Ax T2

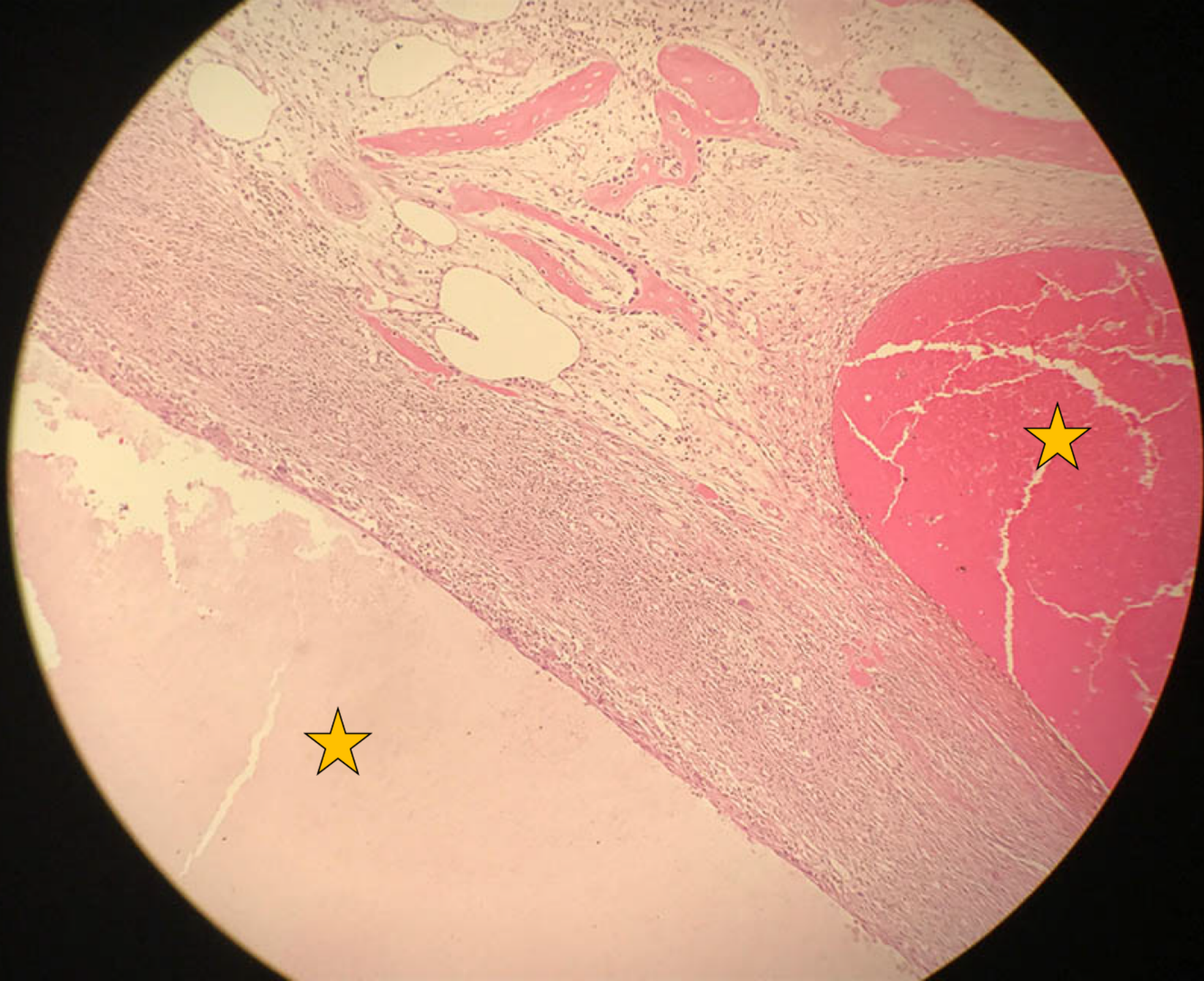




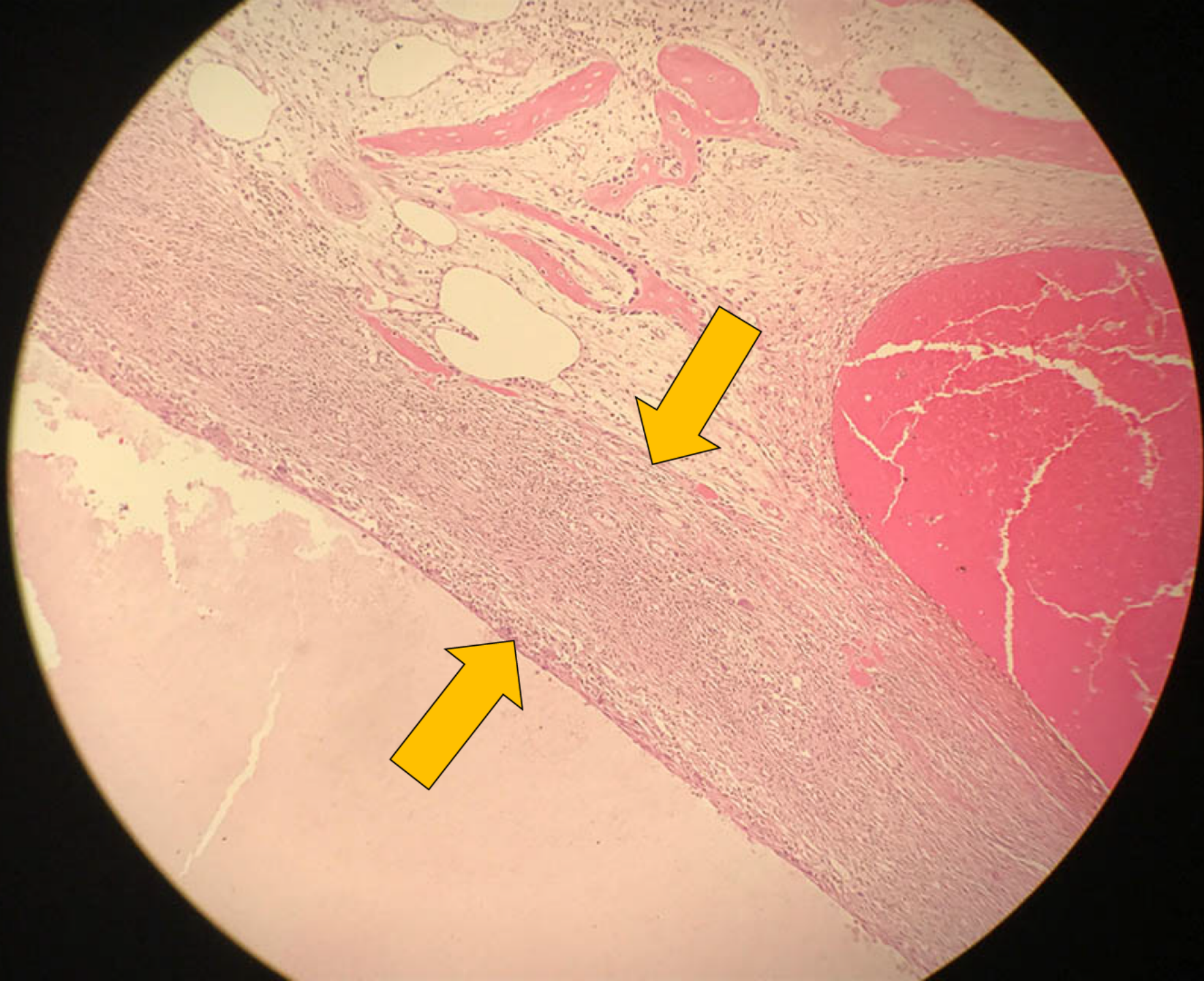












# ANEURYSMAL BONE CYST

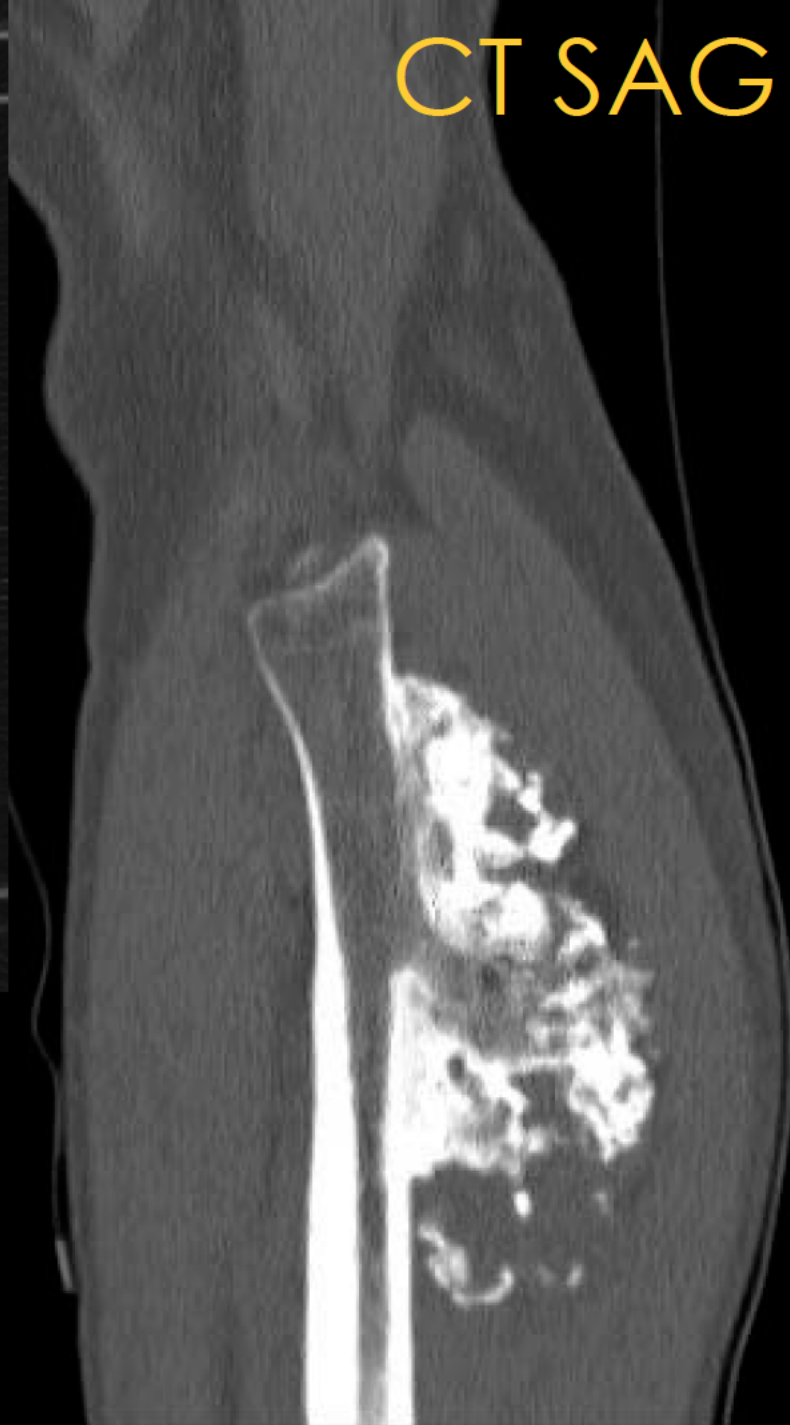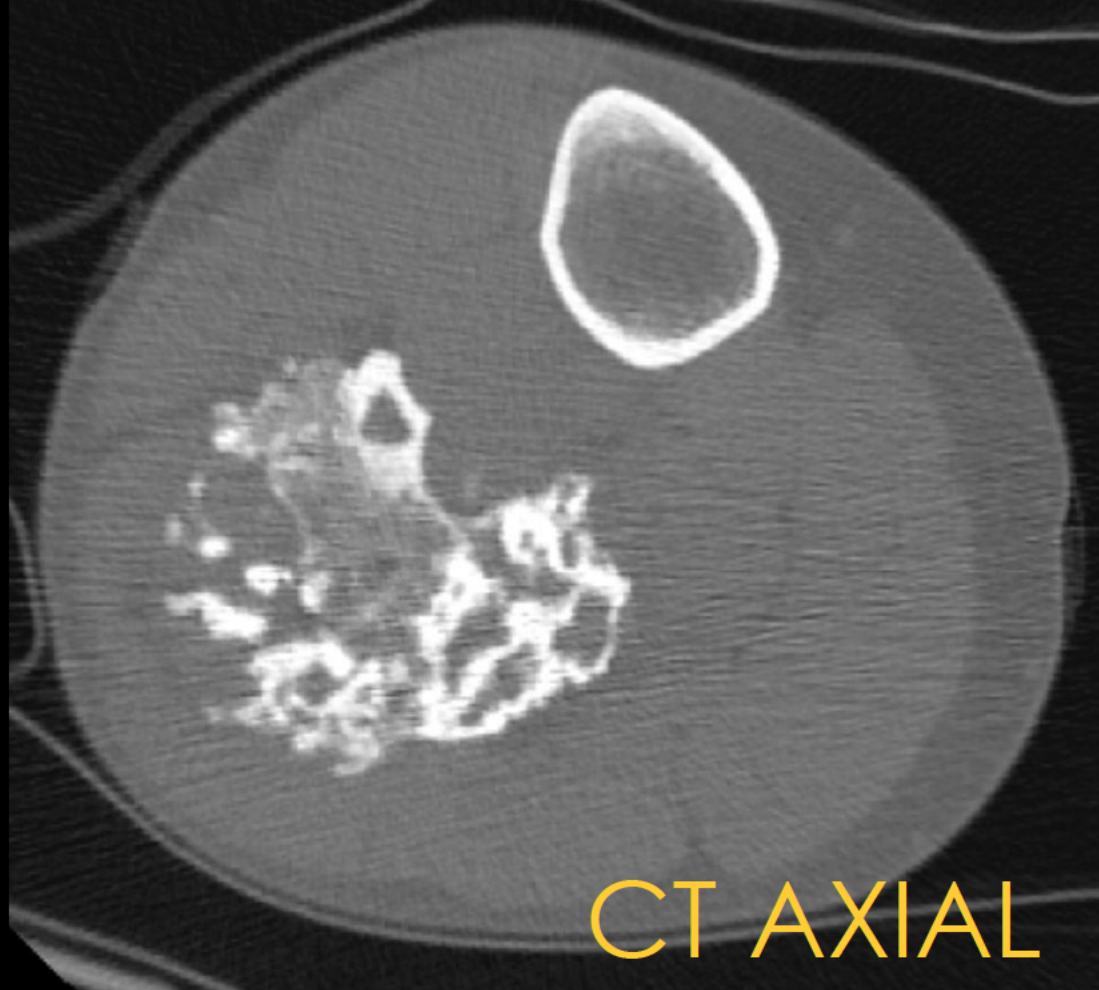Dr. Nicolas Garcia  
CLÍNICA DÁVILA  
RECOLETA, SANTIAGO, CHILE

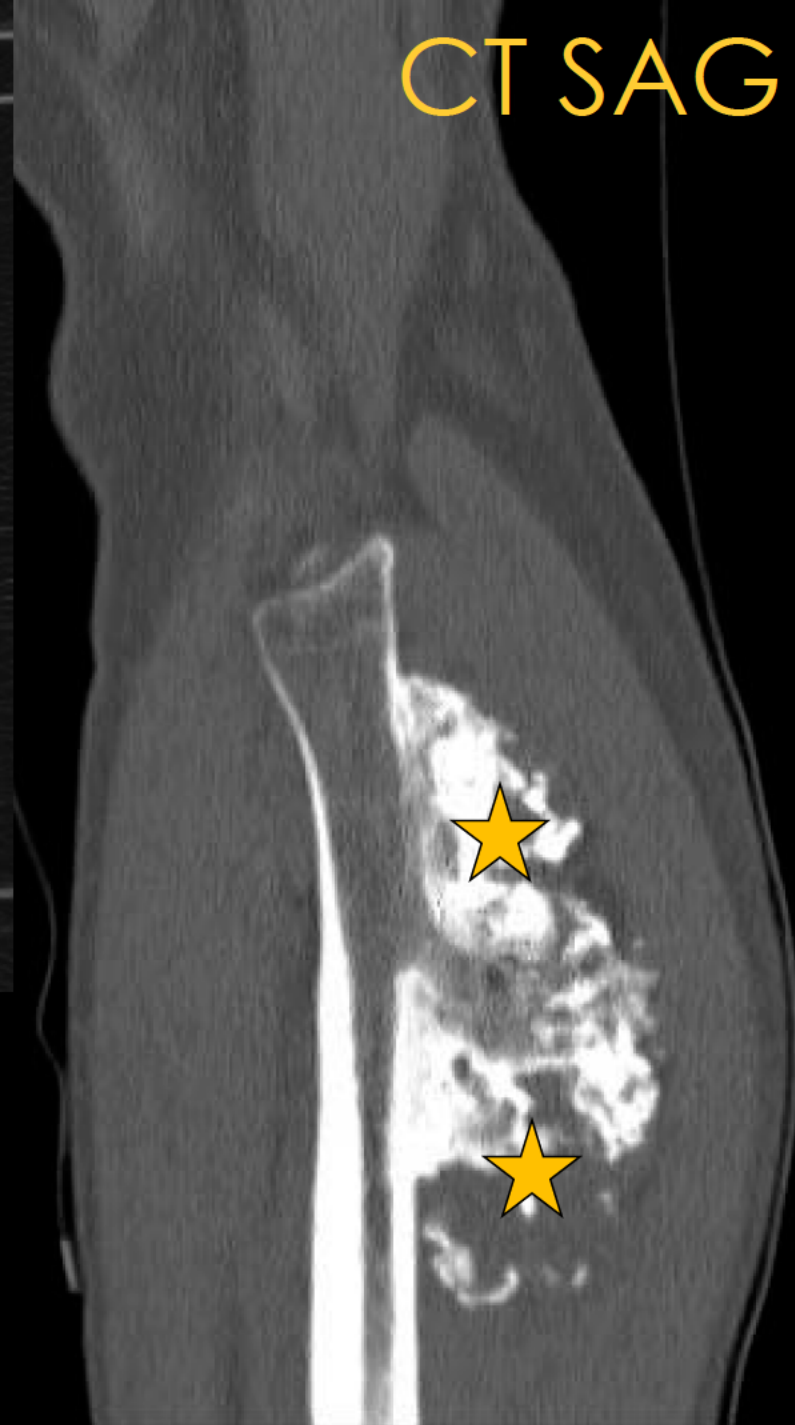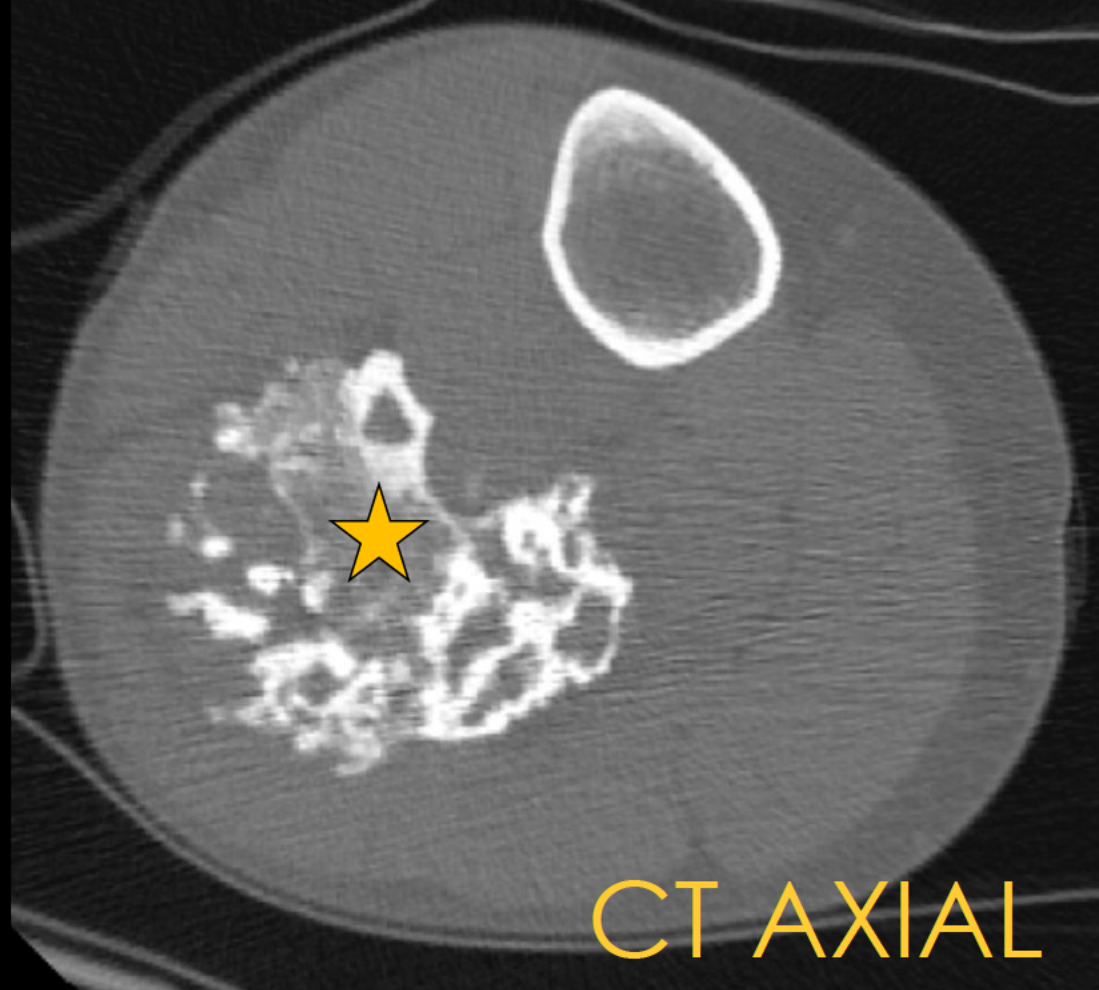


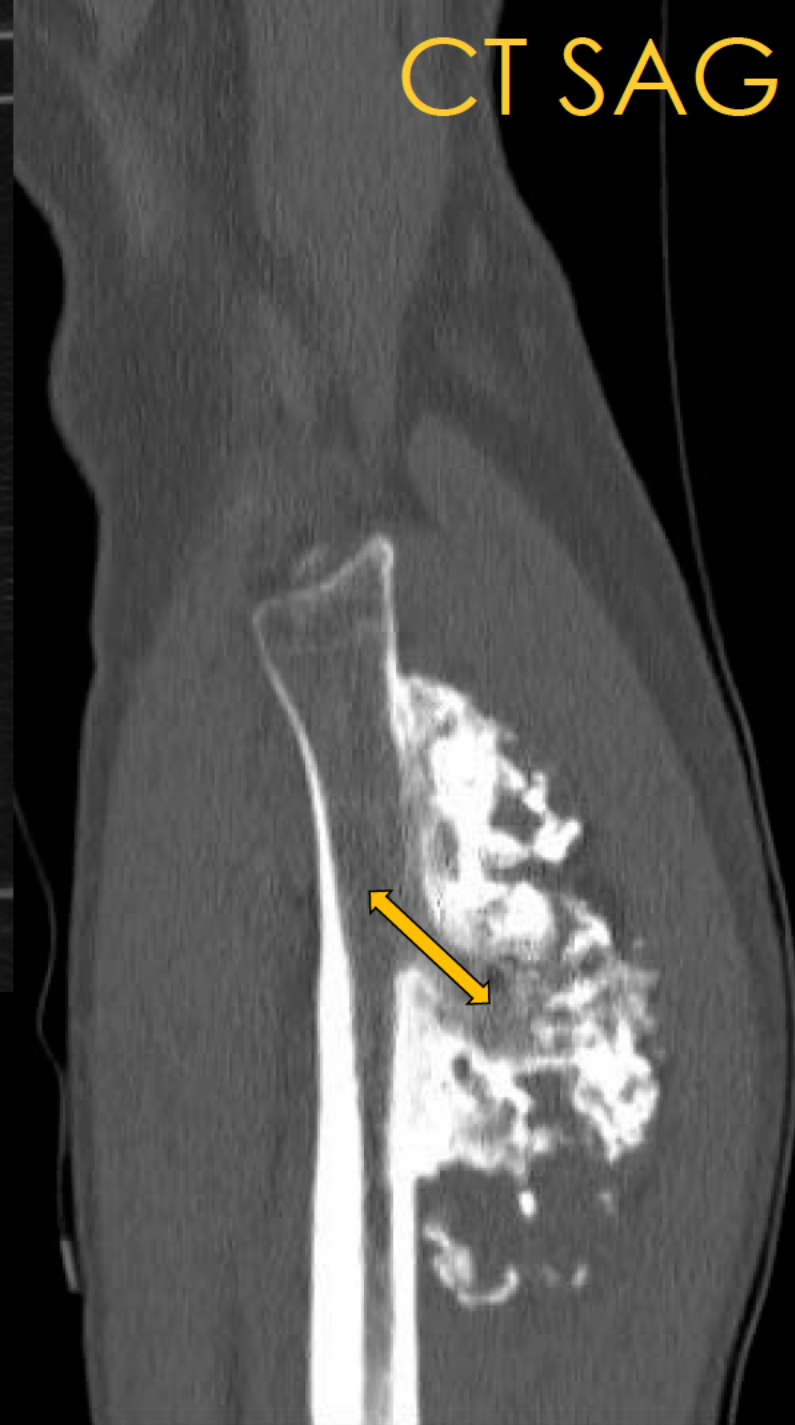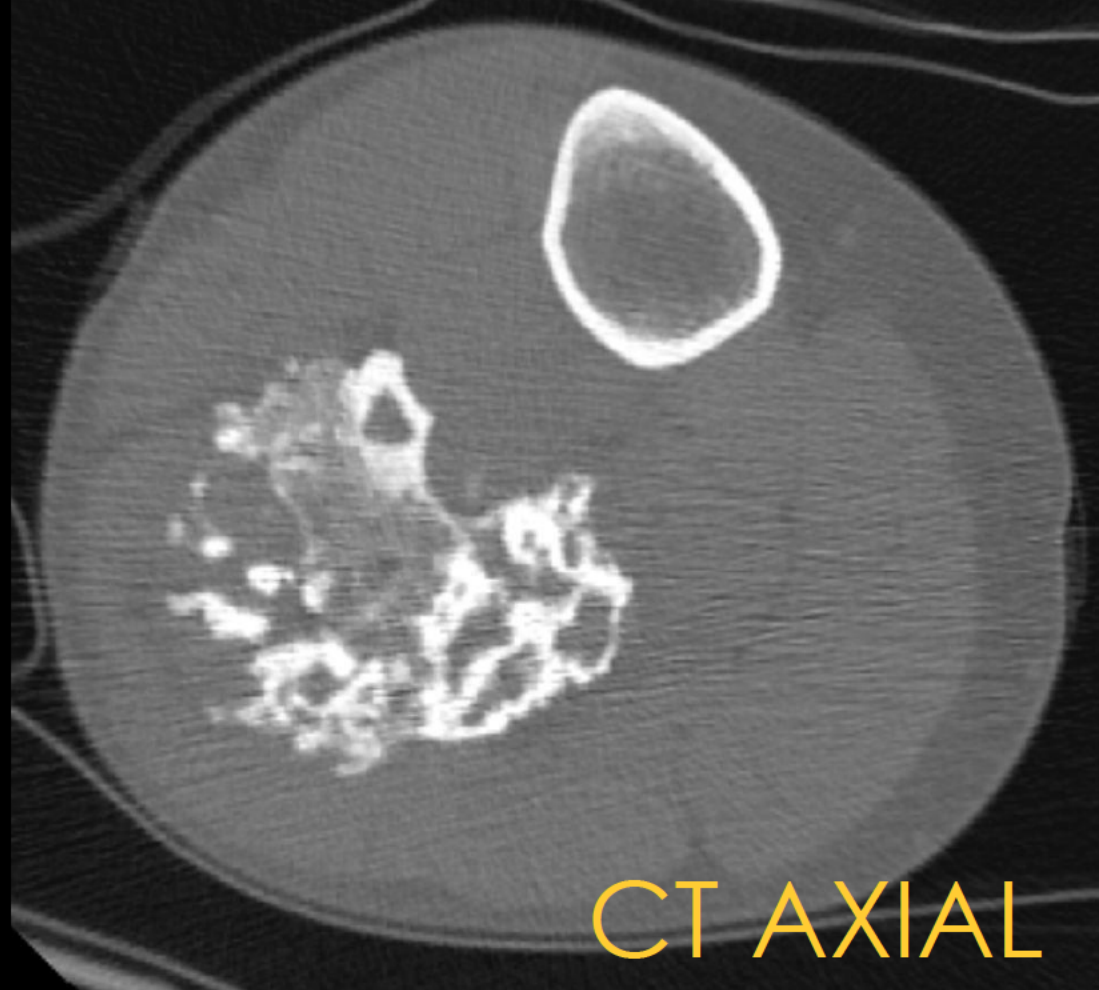# Honorable mention

# Clinical Information

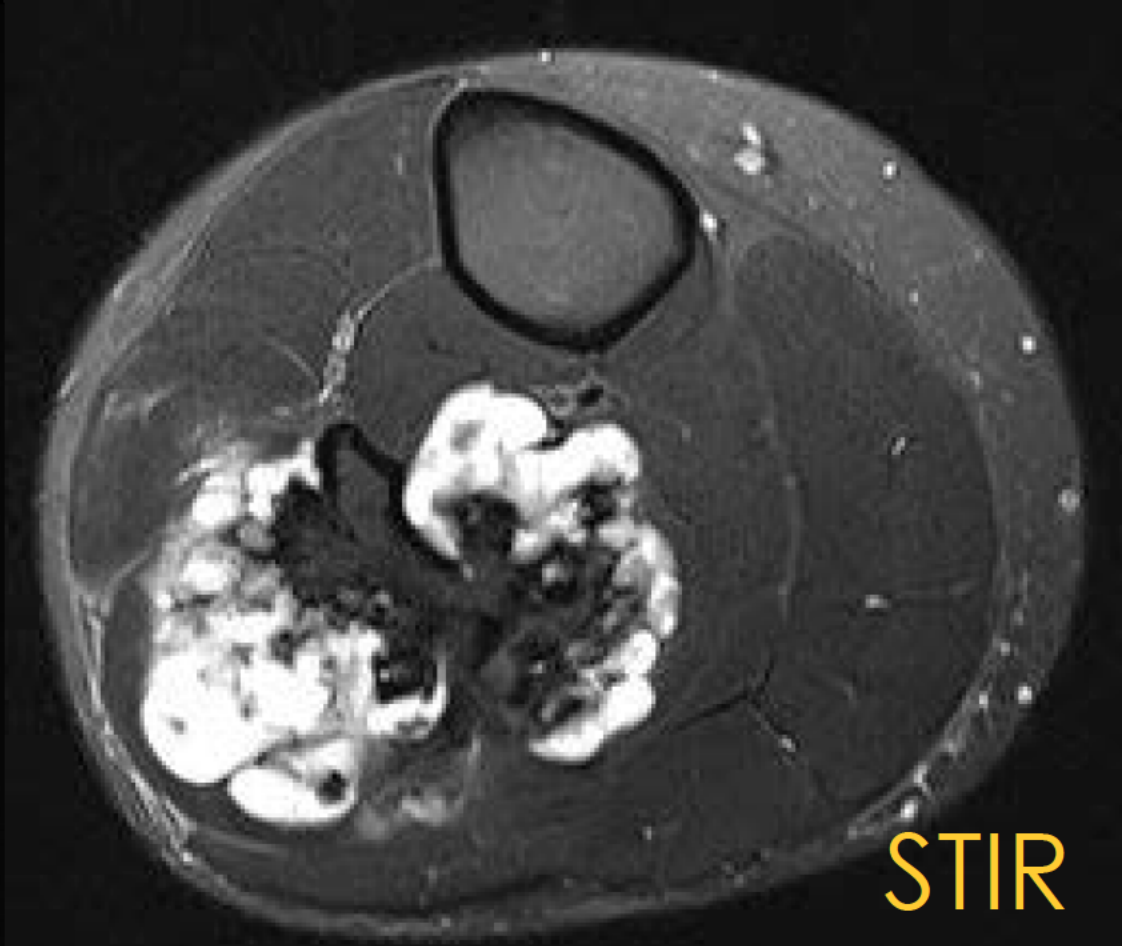
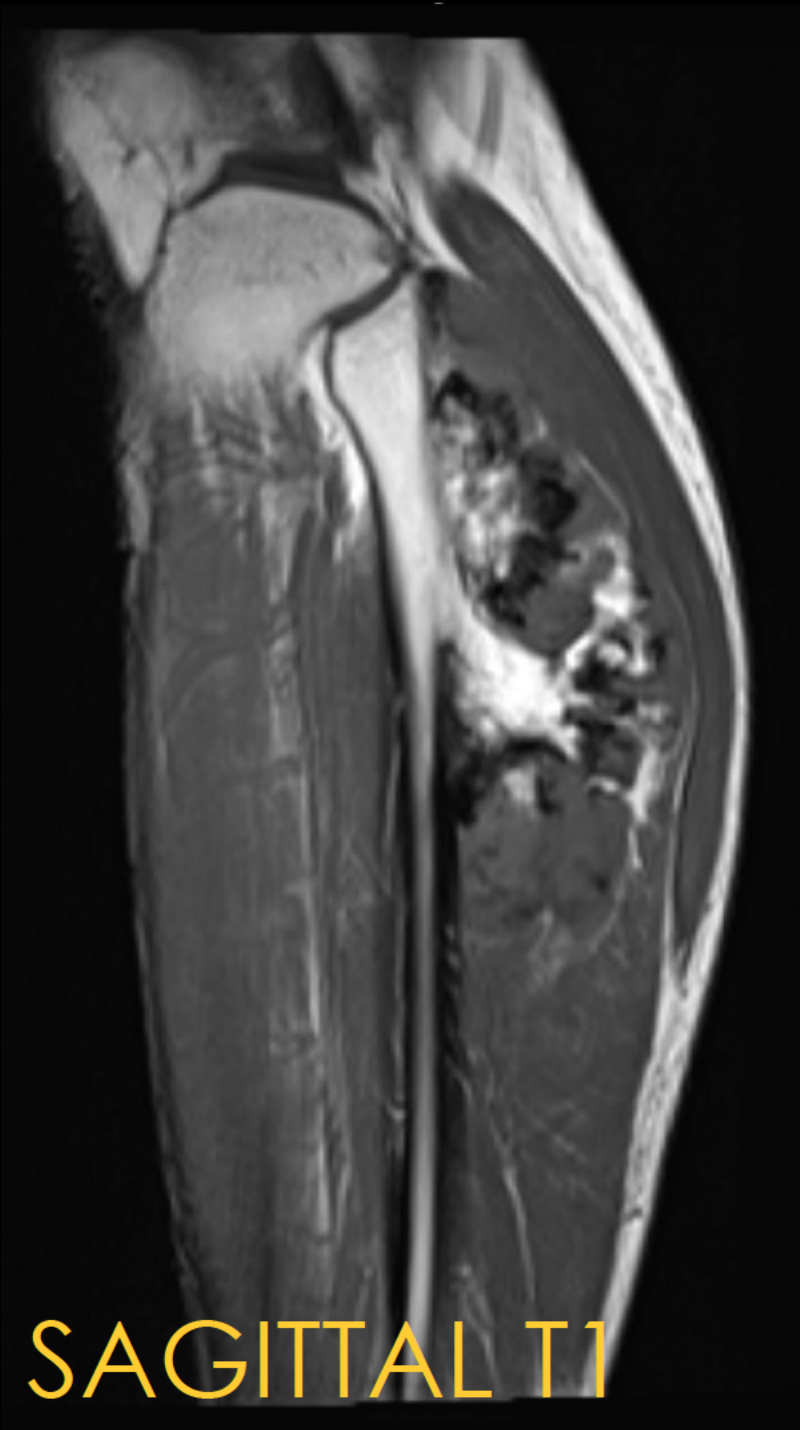
**34 year old African American female presents with painless right lower extremity swelling.**

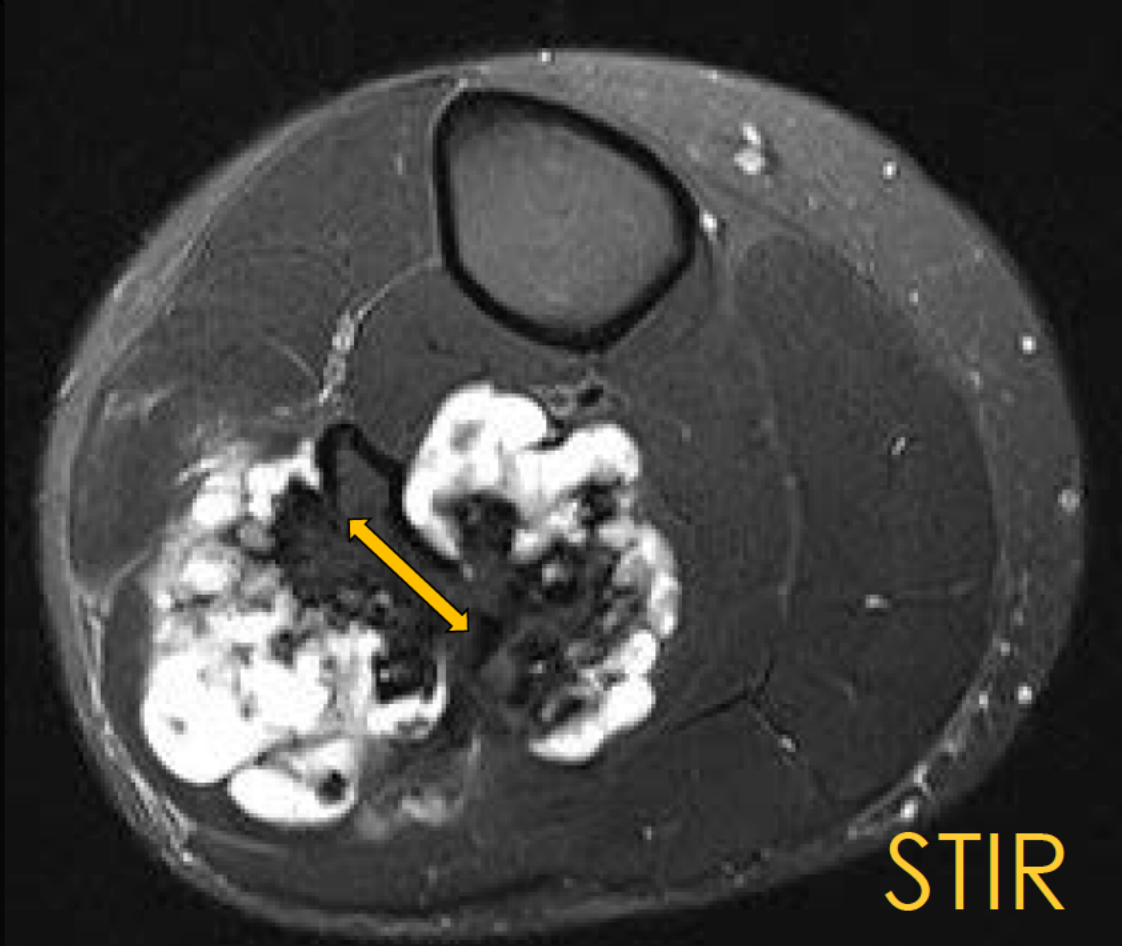
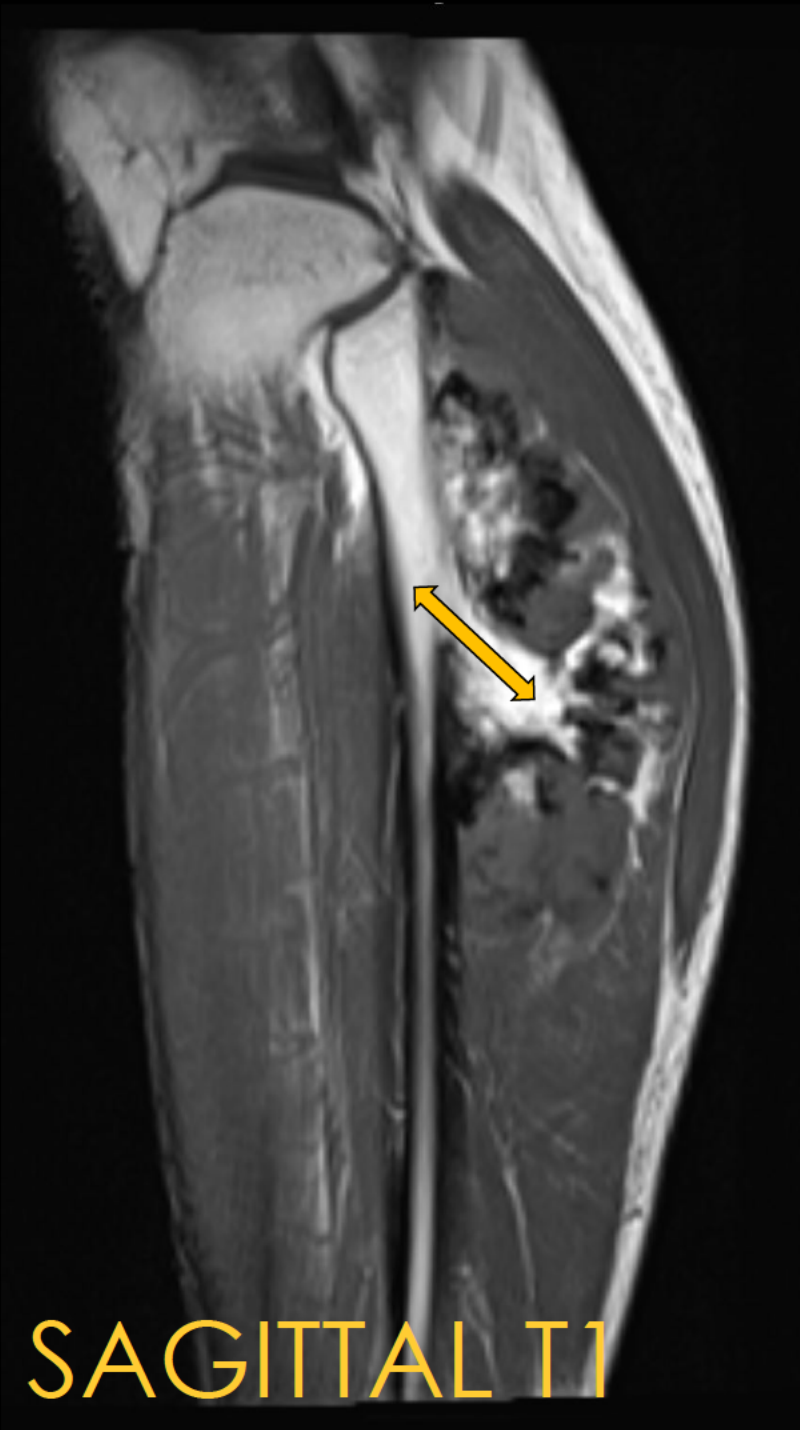




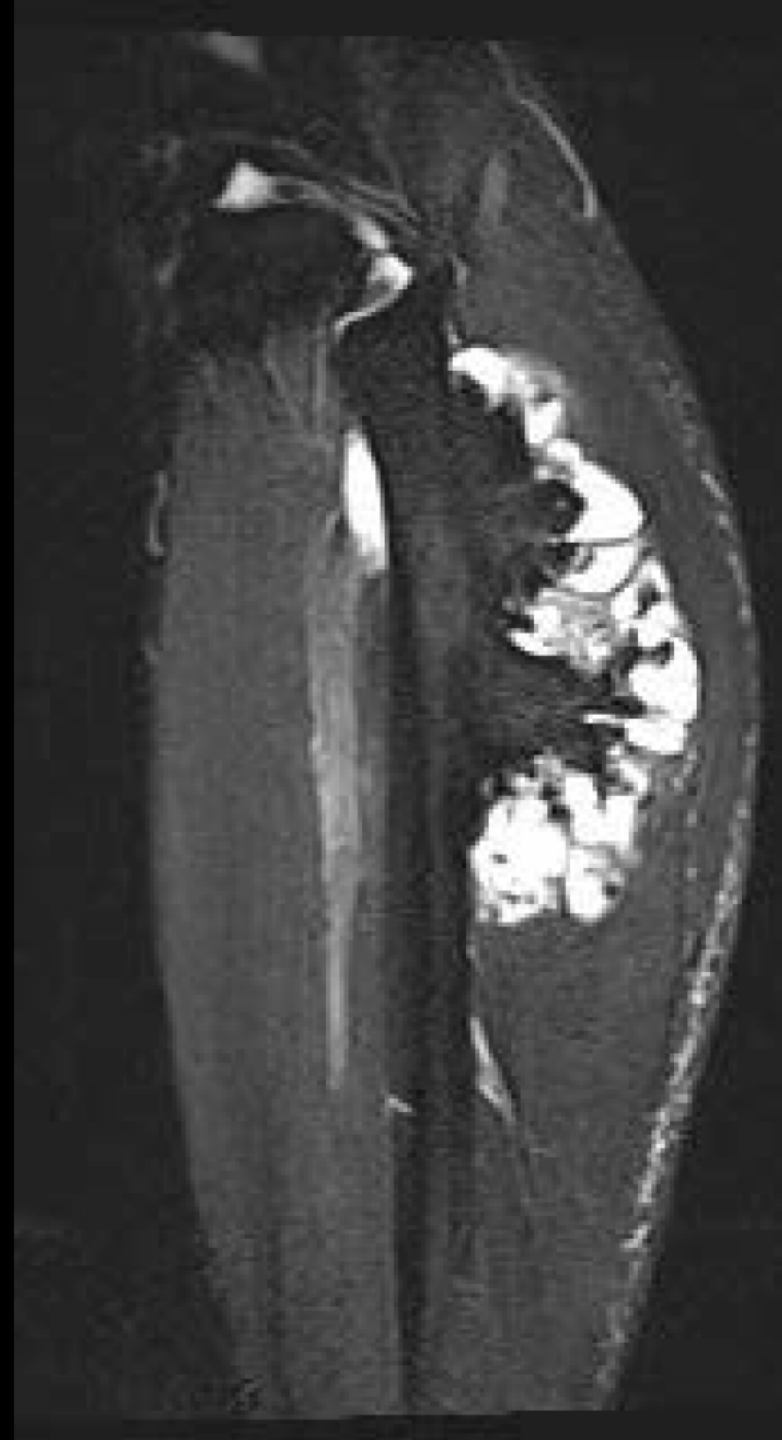
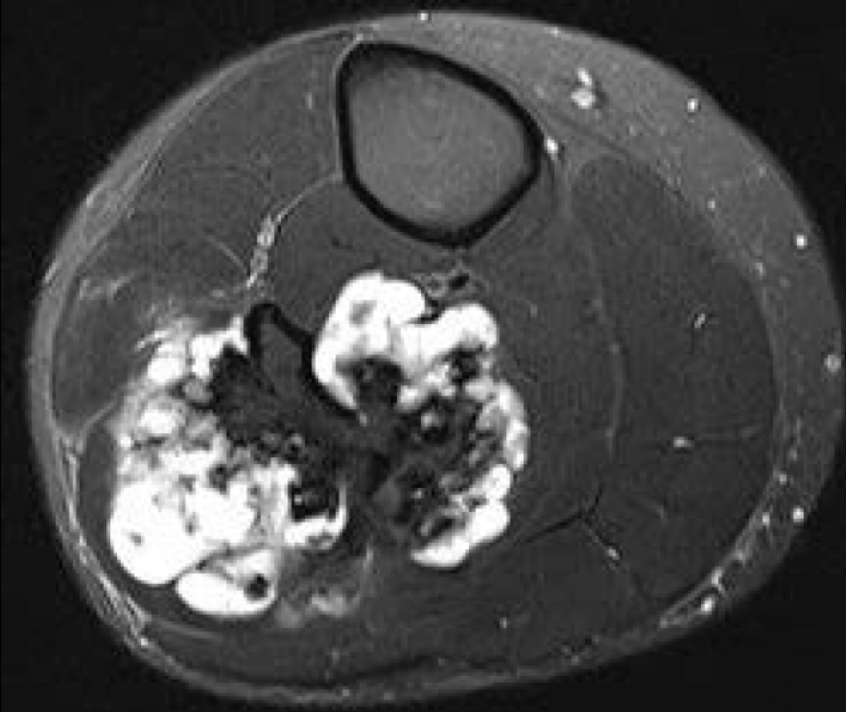
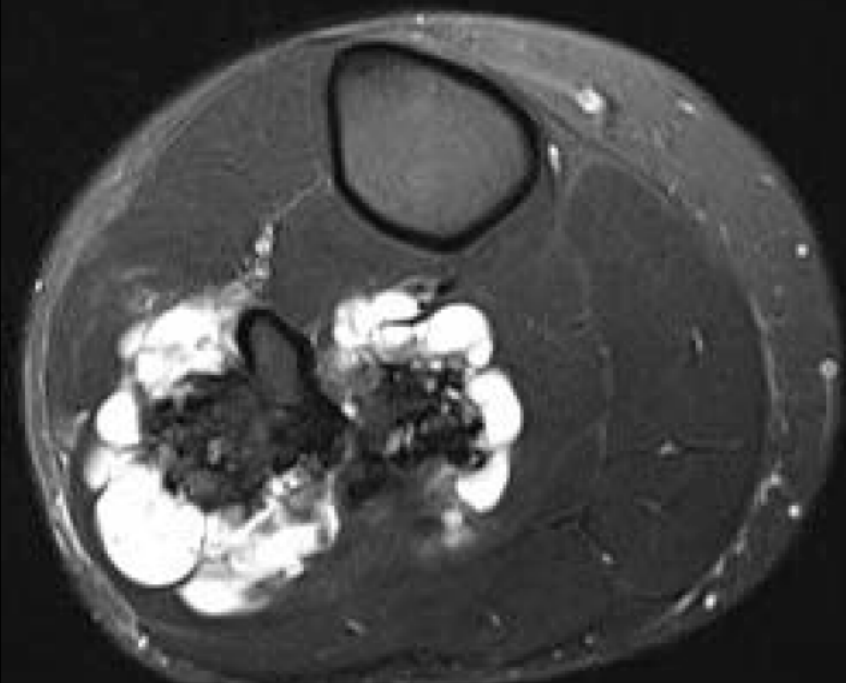




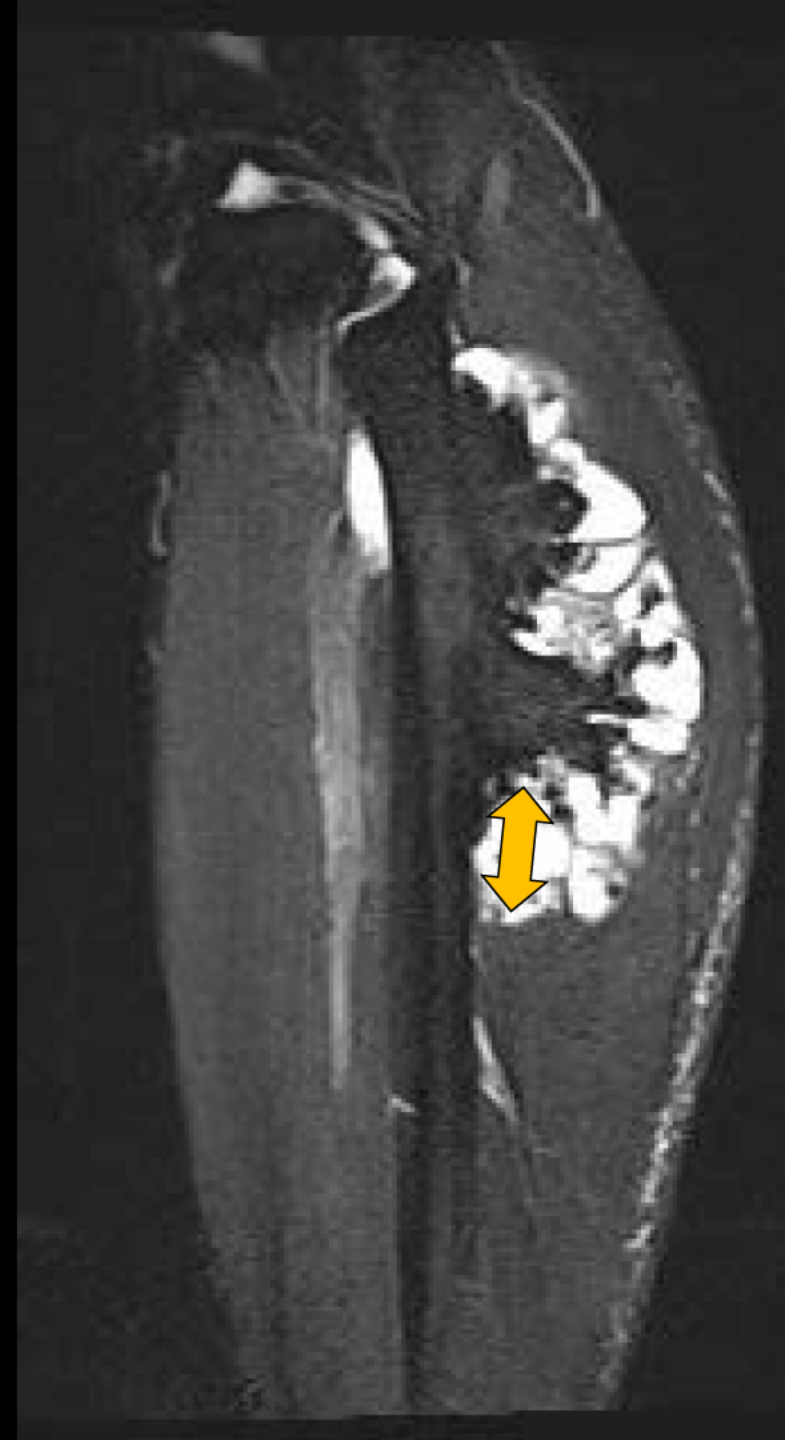
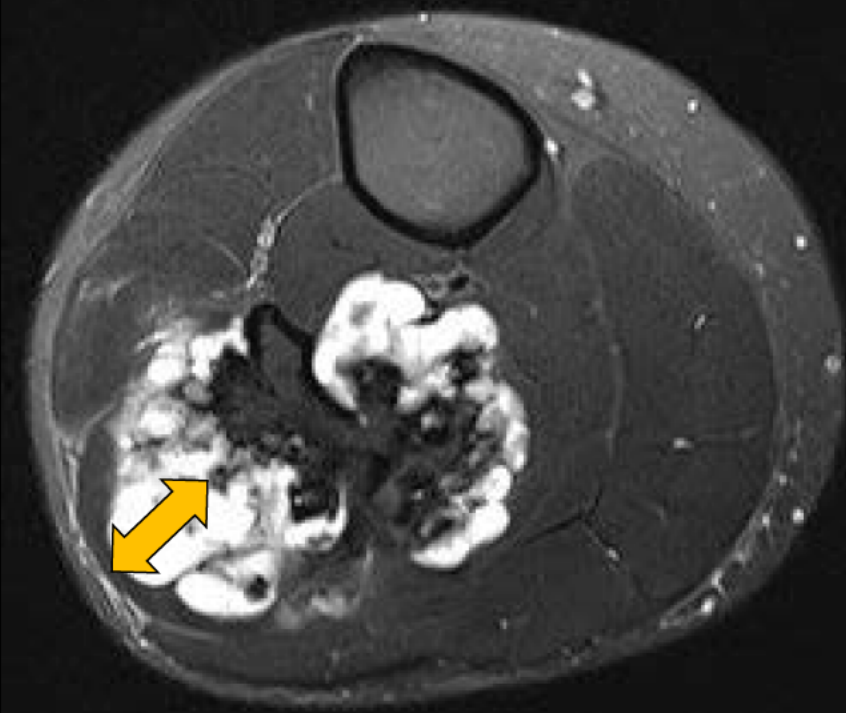
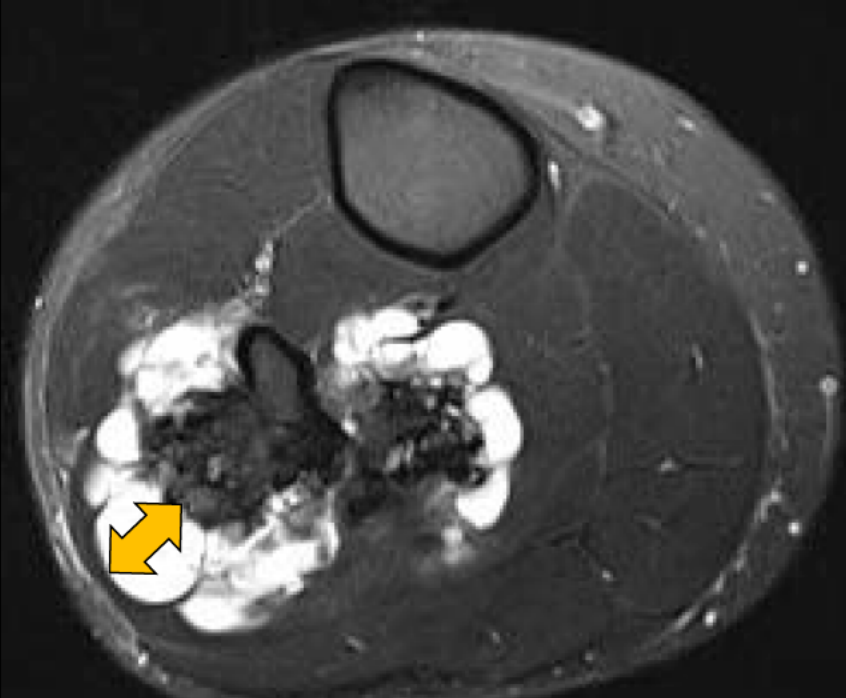




STIR

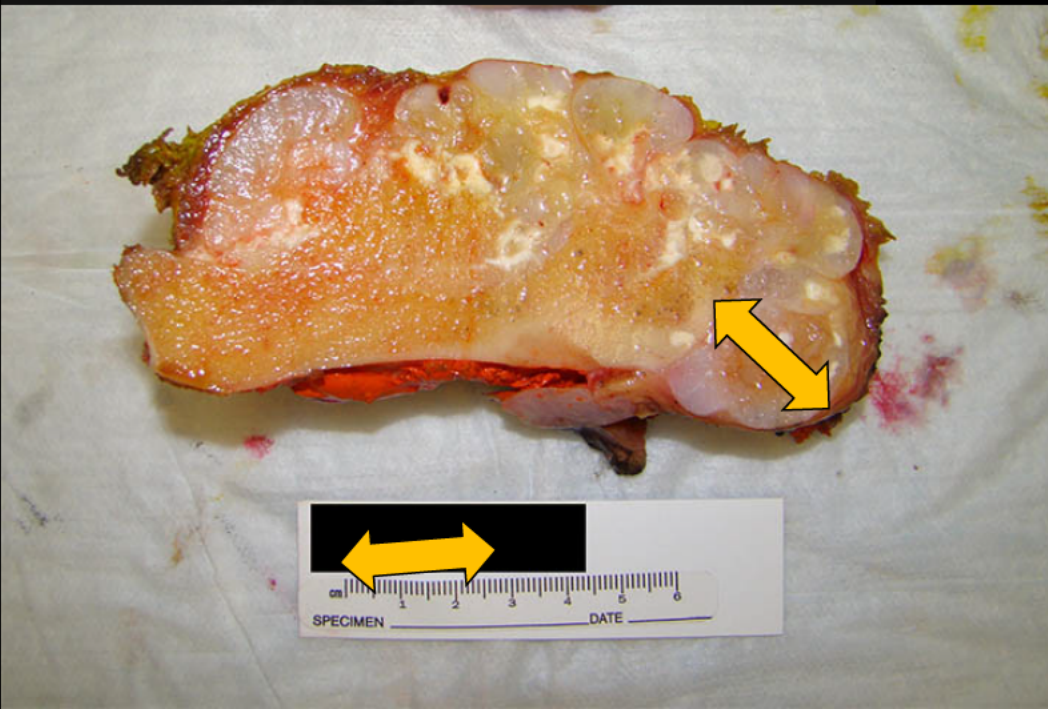
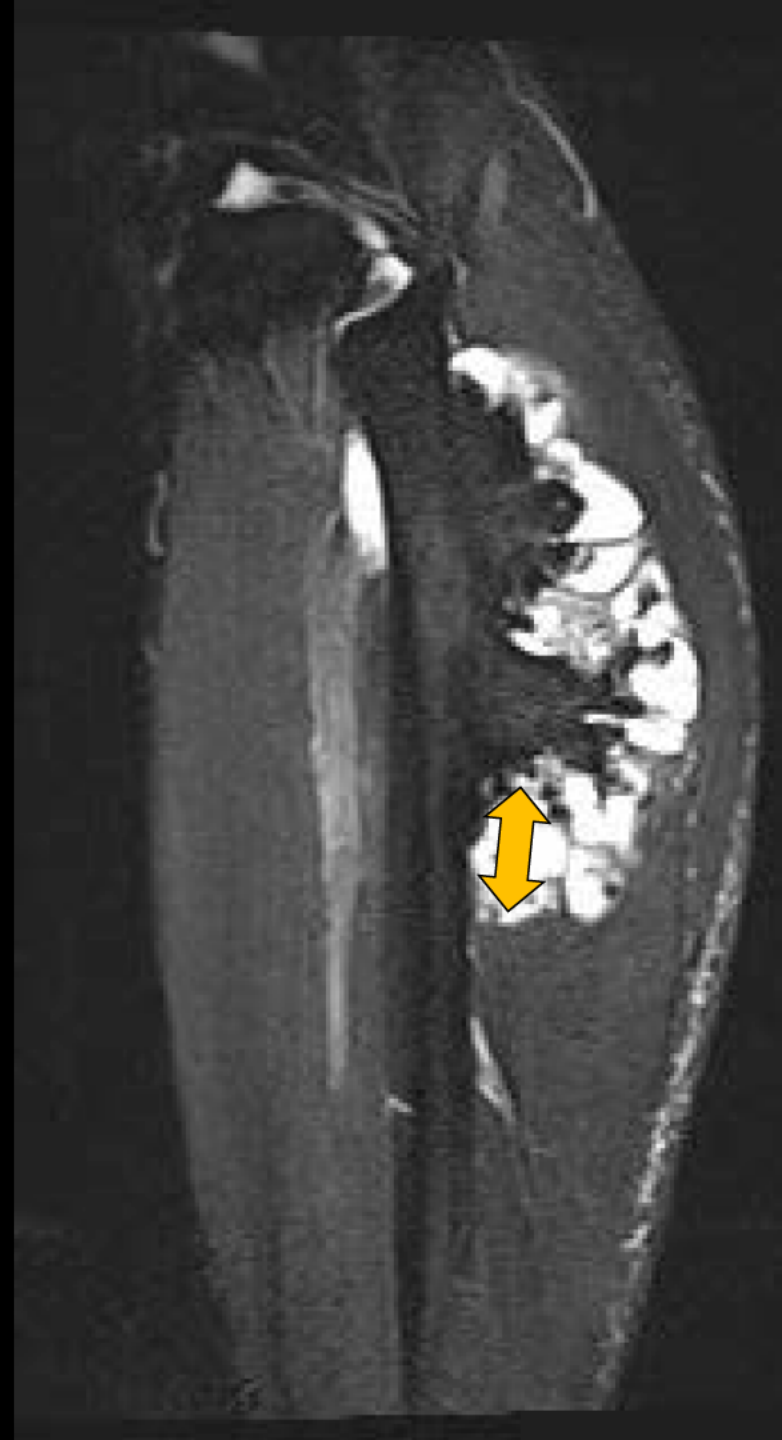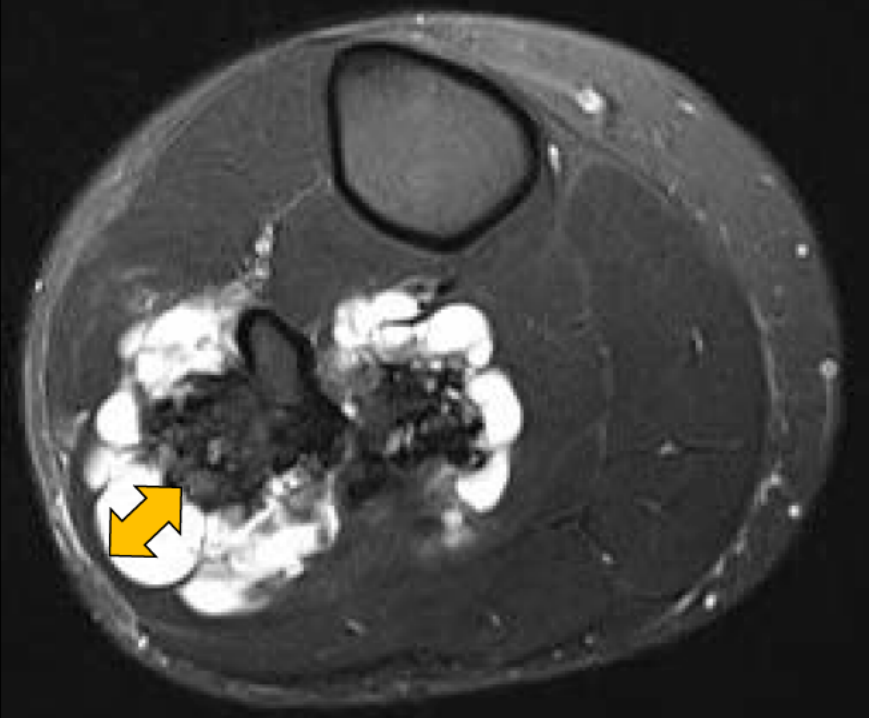


STIR

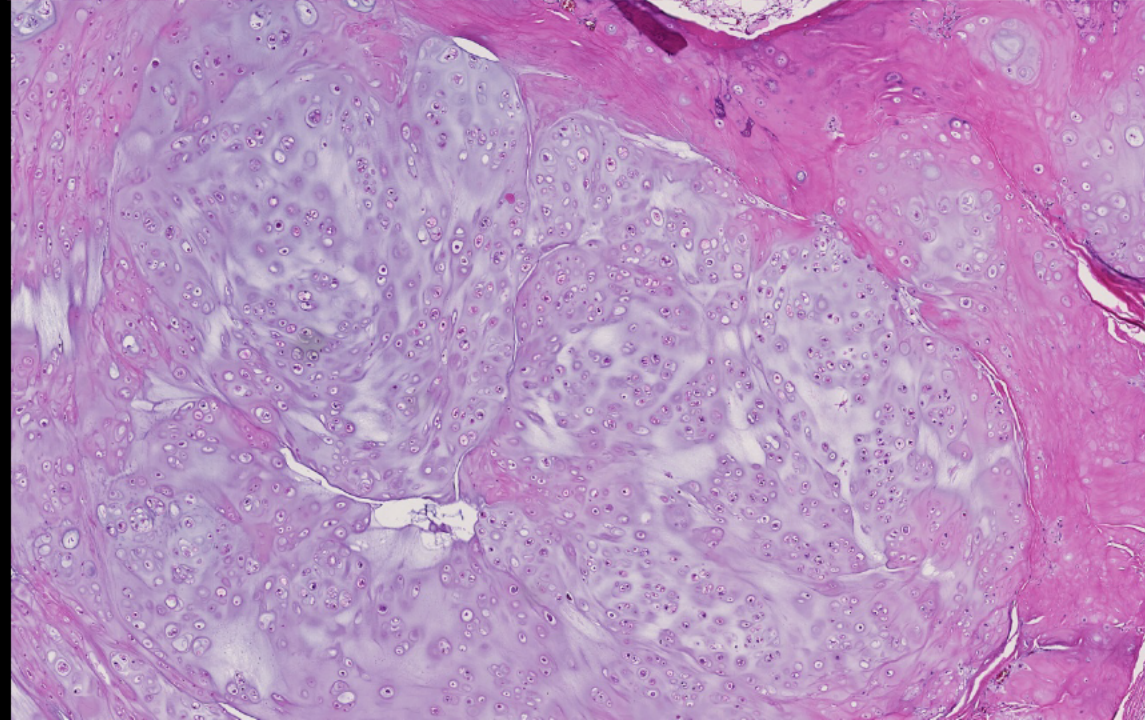
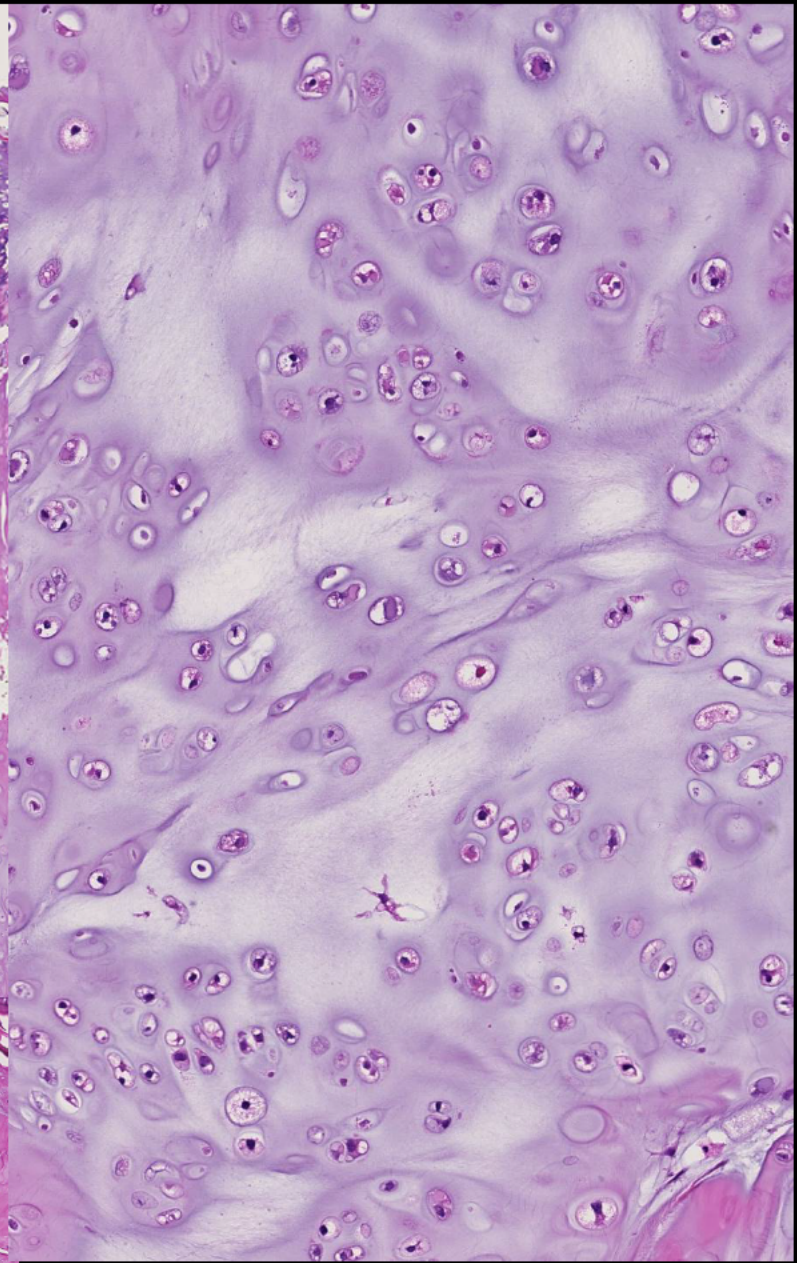
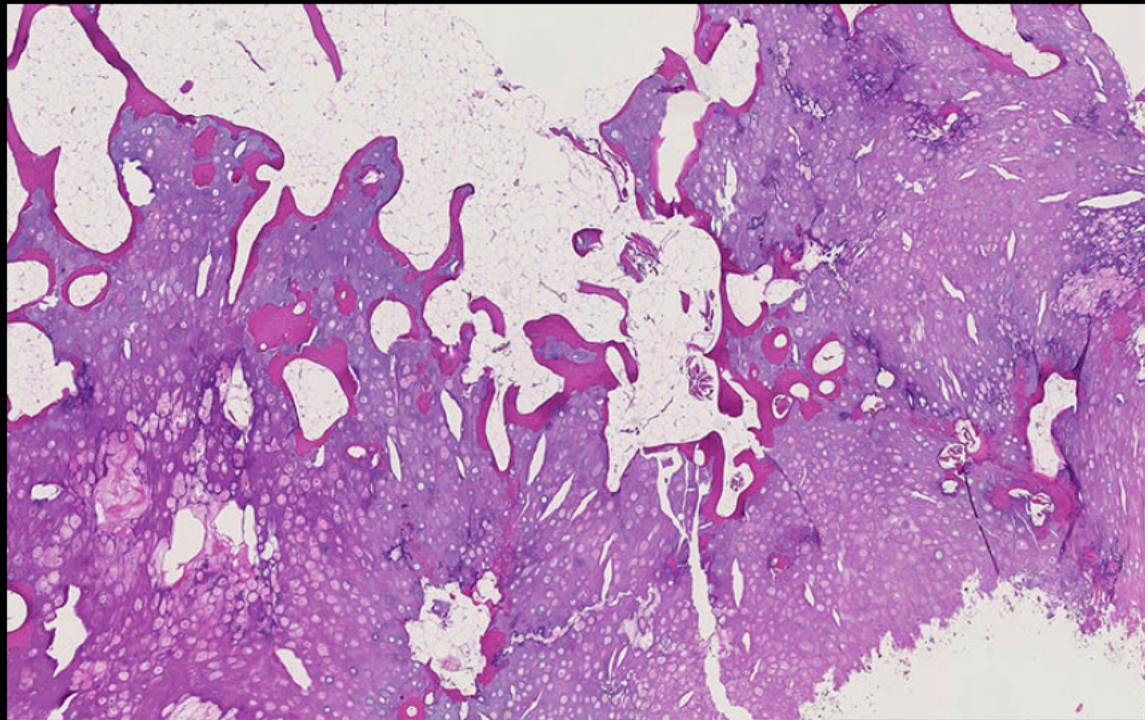




STIR

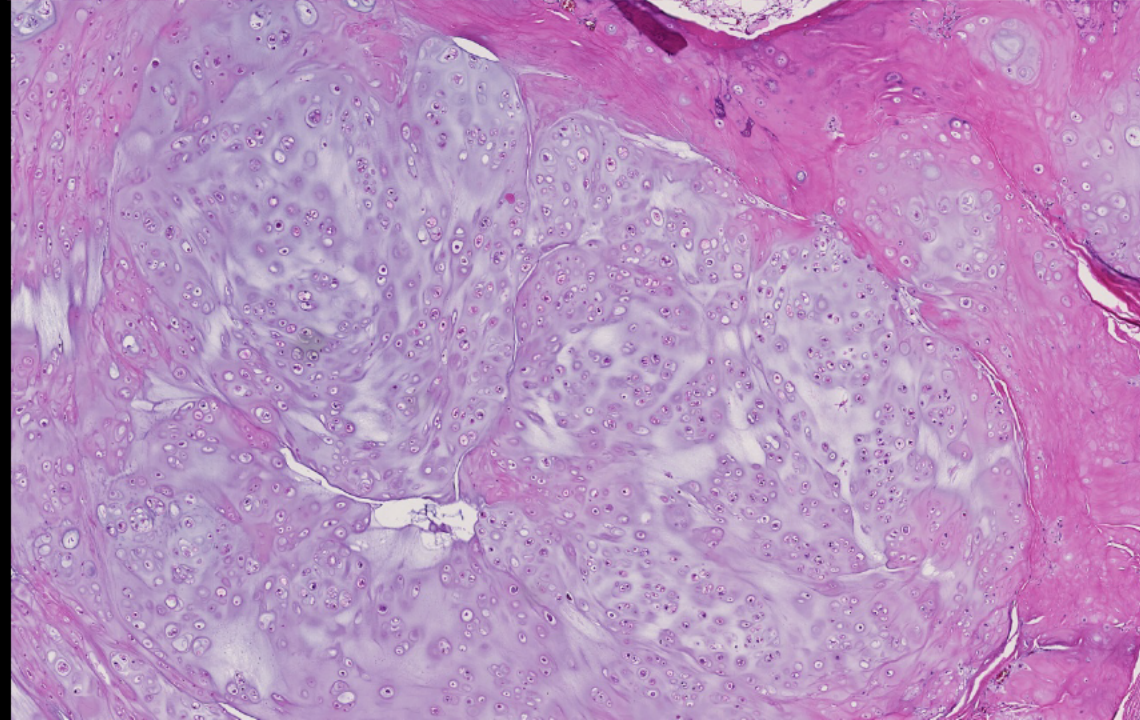
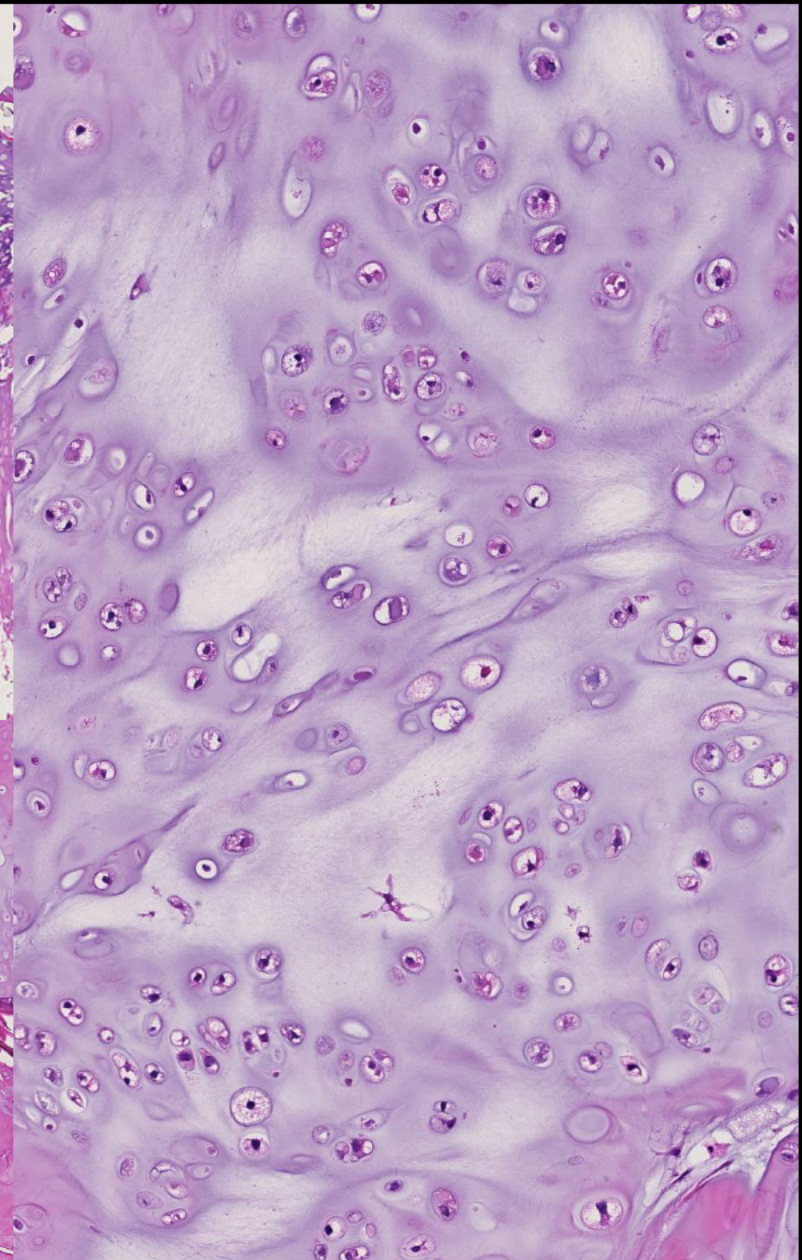
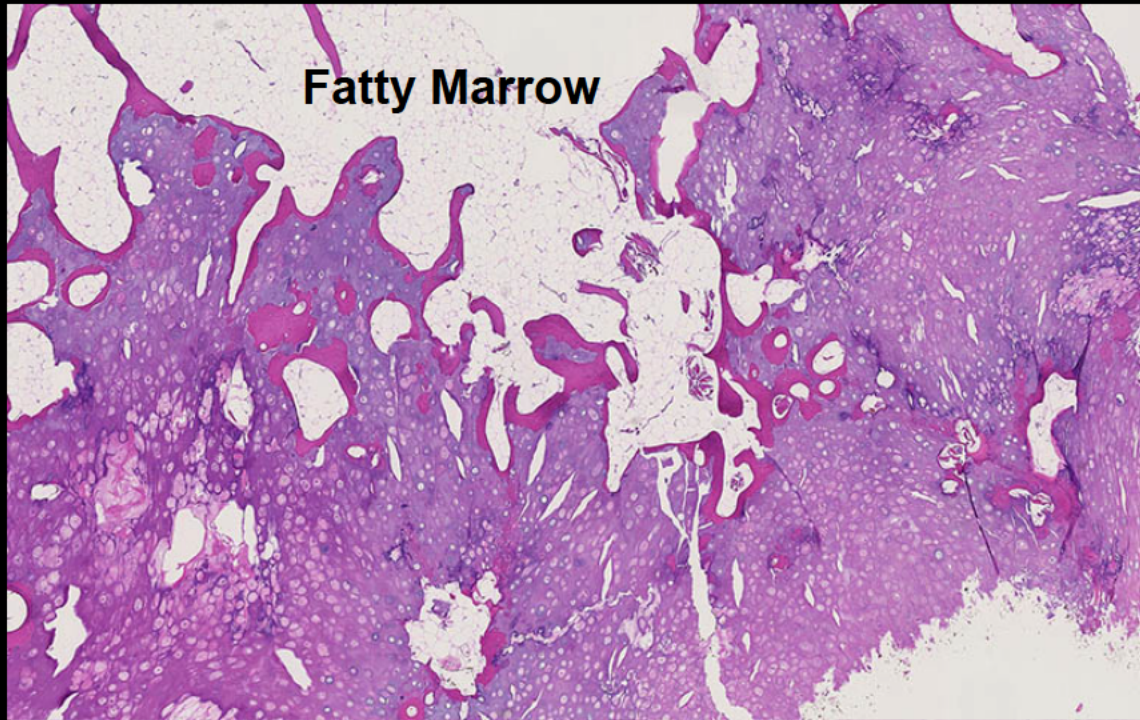




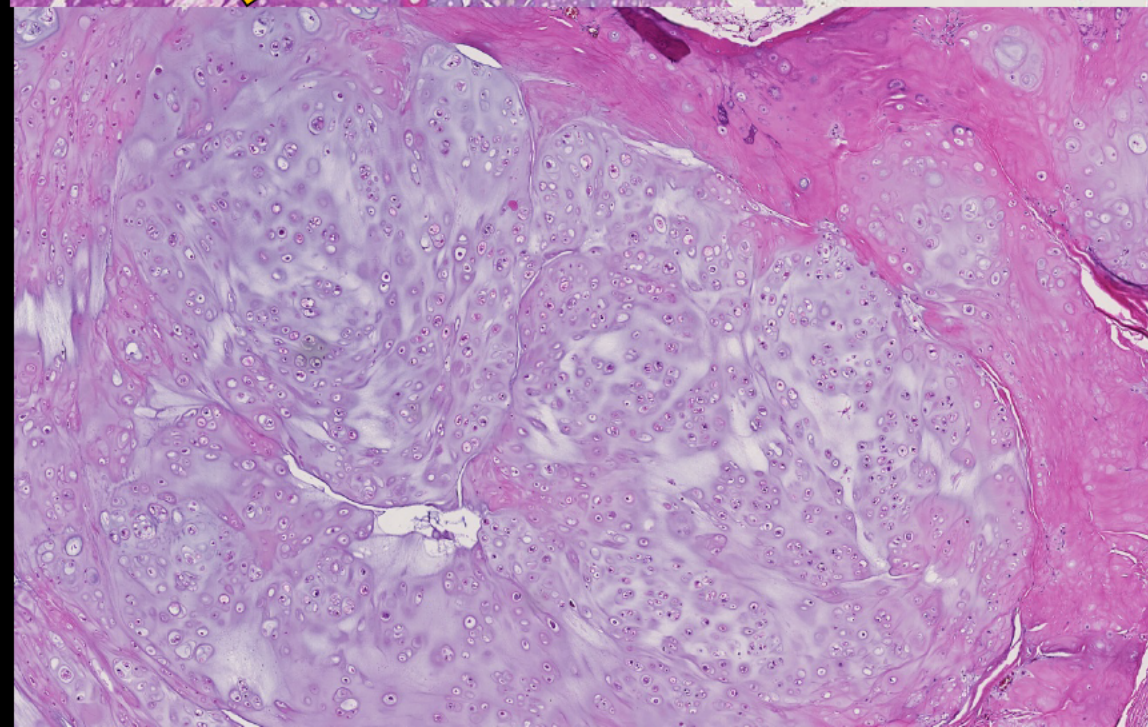
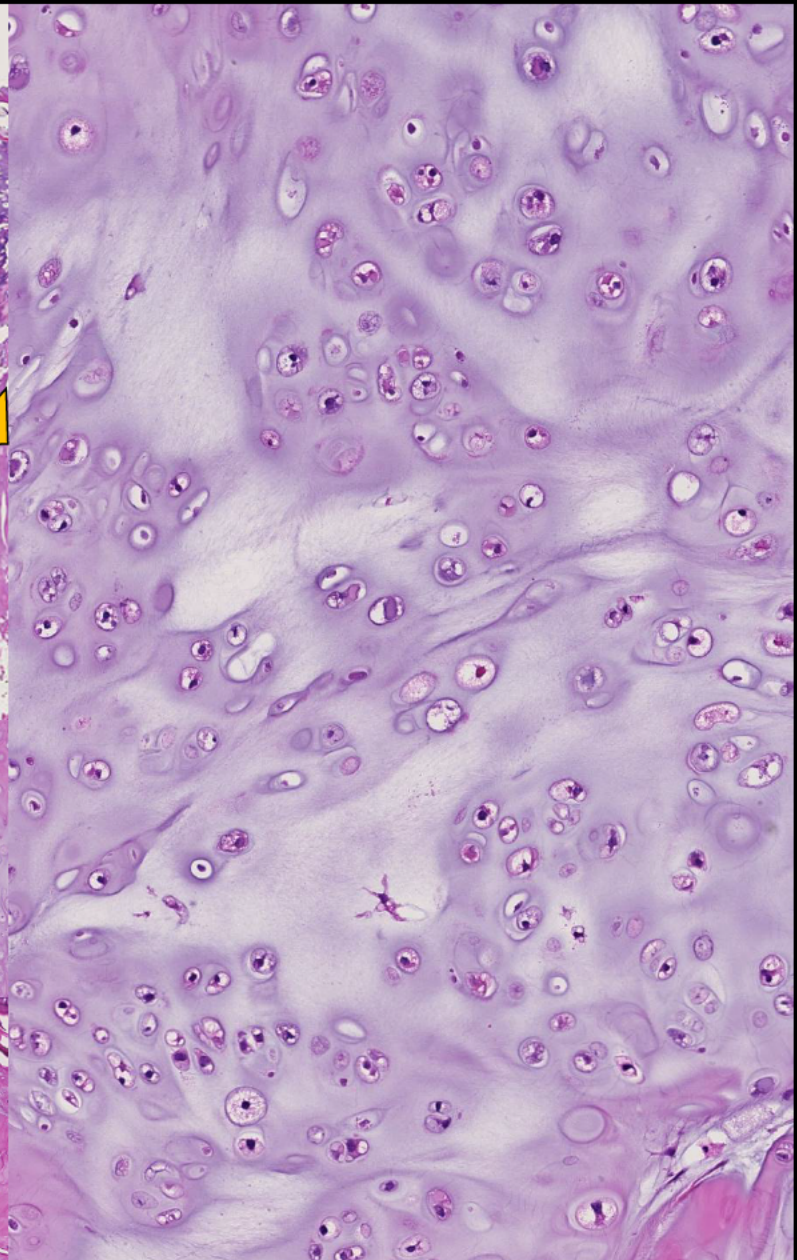
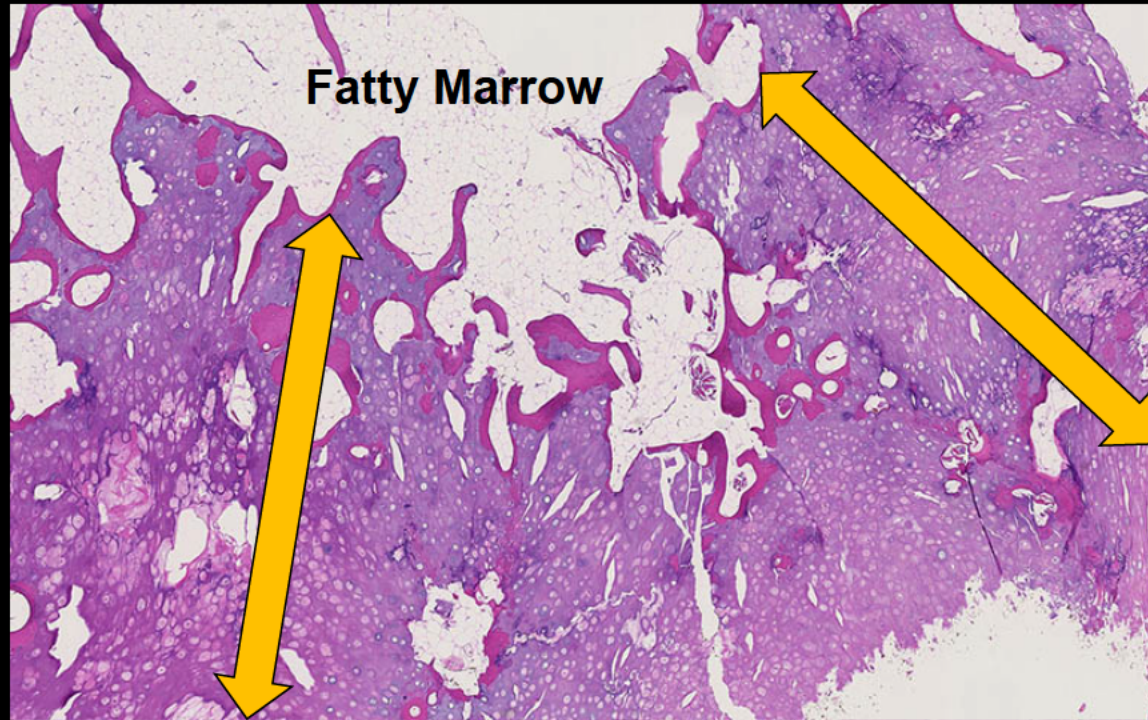



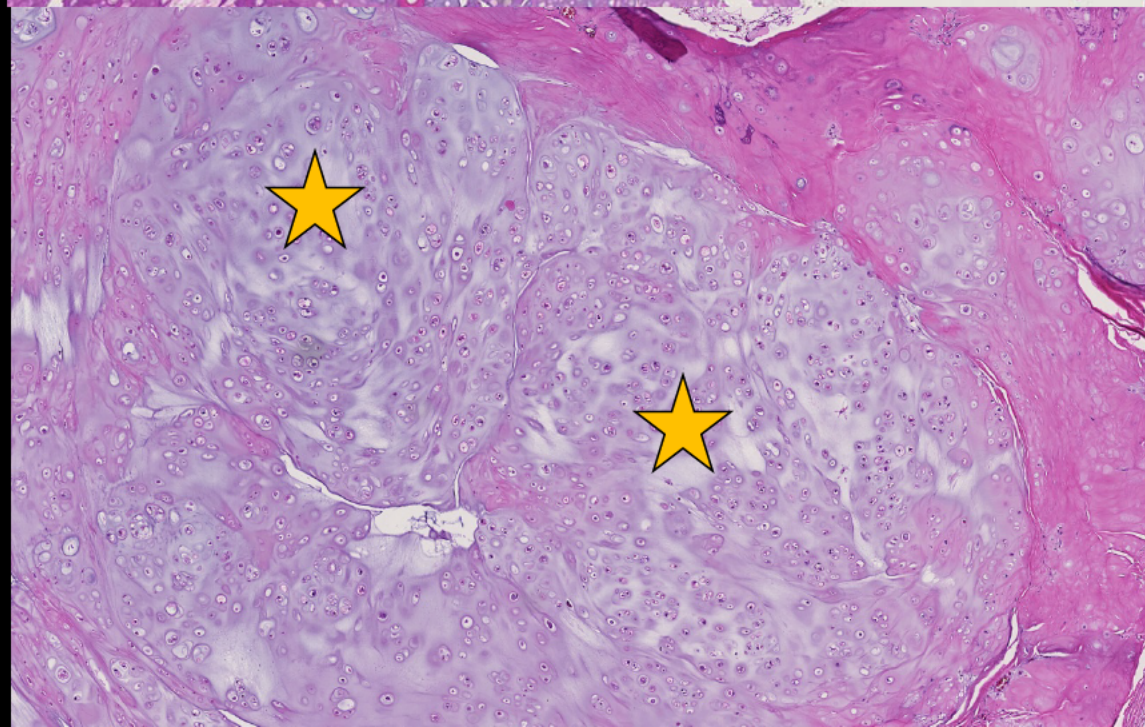
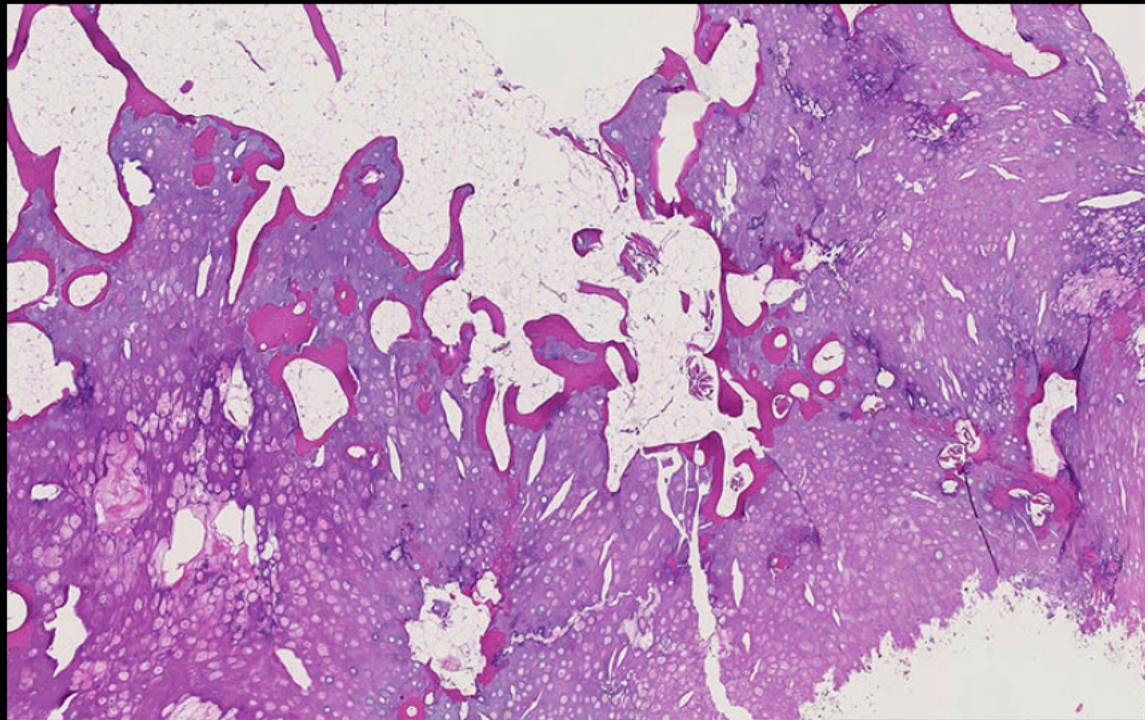
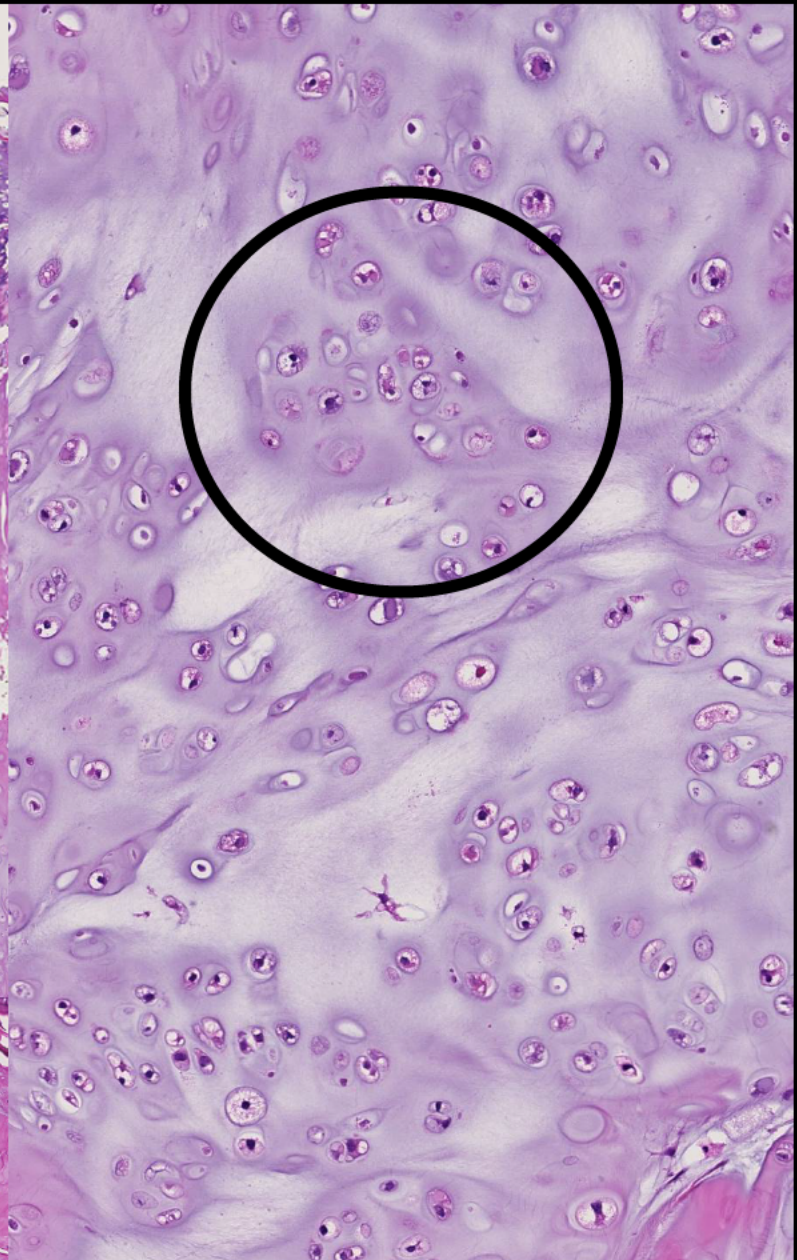**Fatty Marrow**











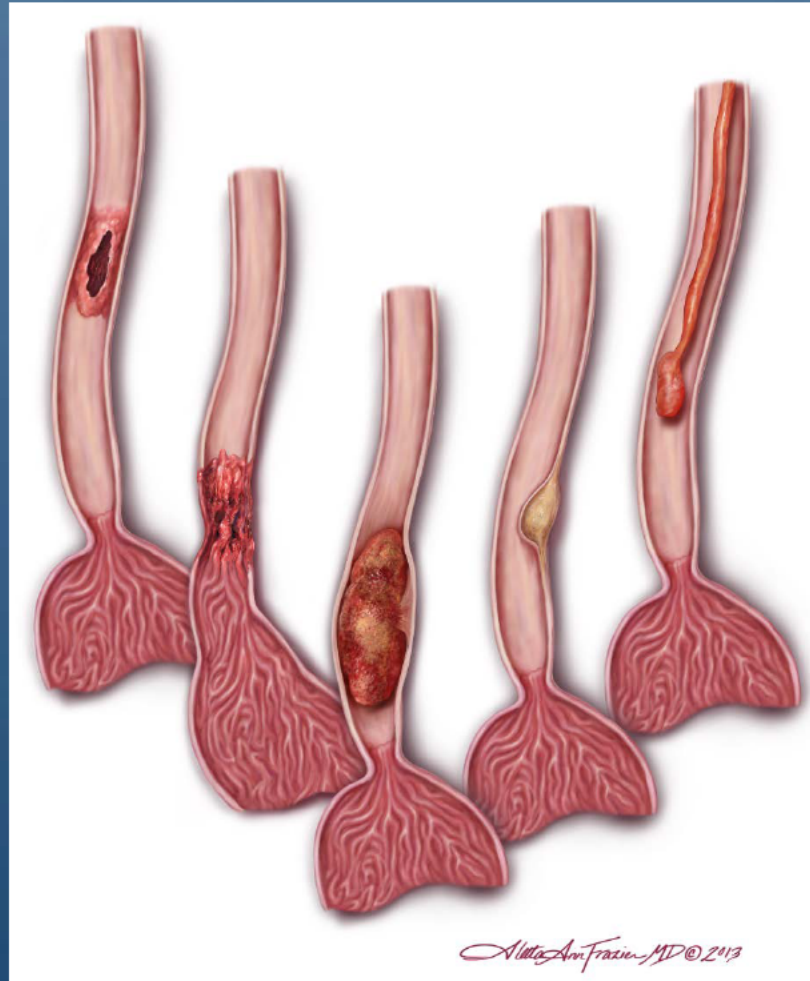

# **OSTEOCHONDROMA TO CHONDROSARCOMA**

**Dr. Marco Vitto  
Albany Medical Center  
Albany, NY**

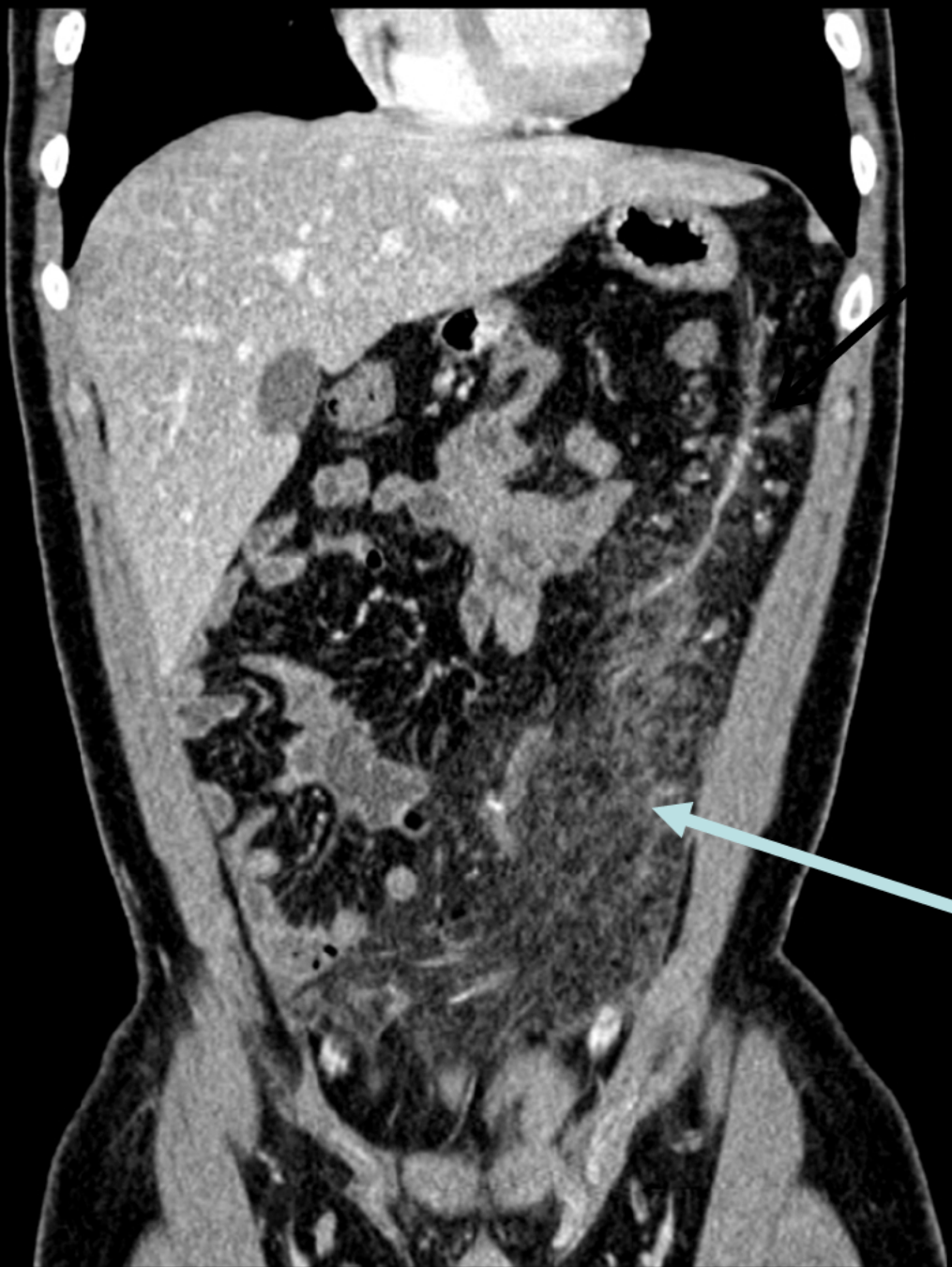
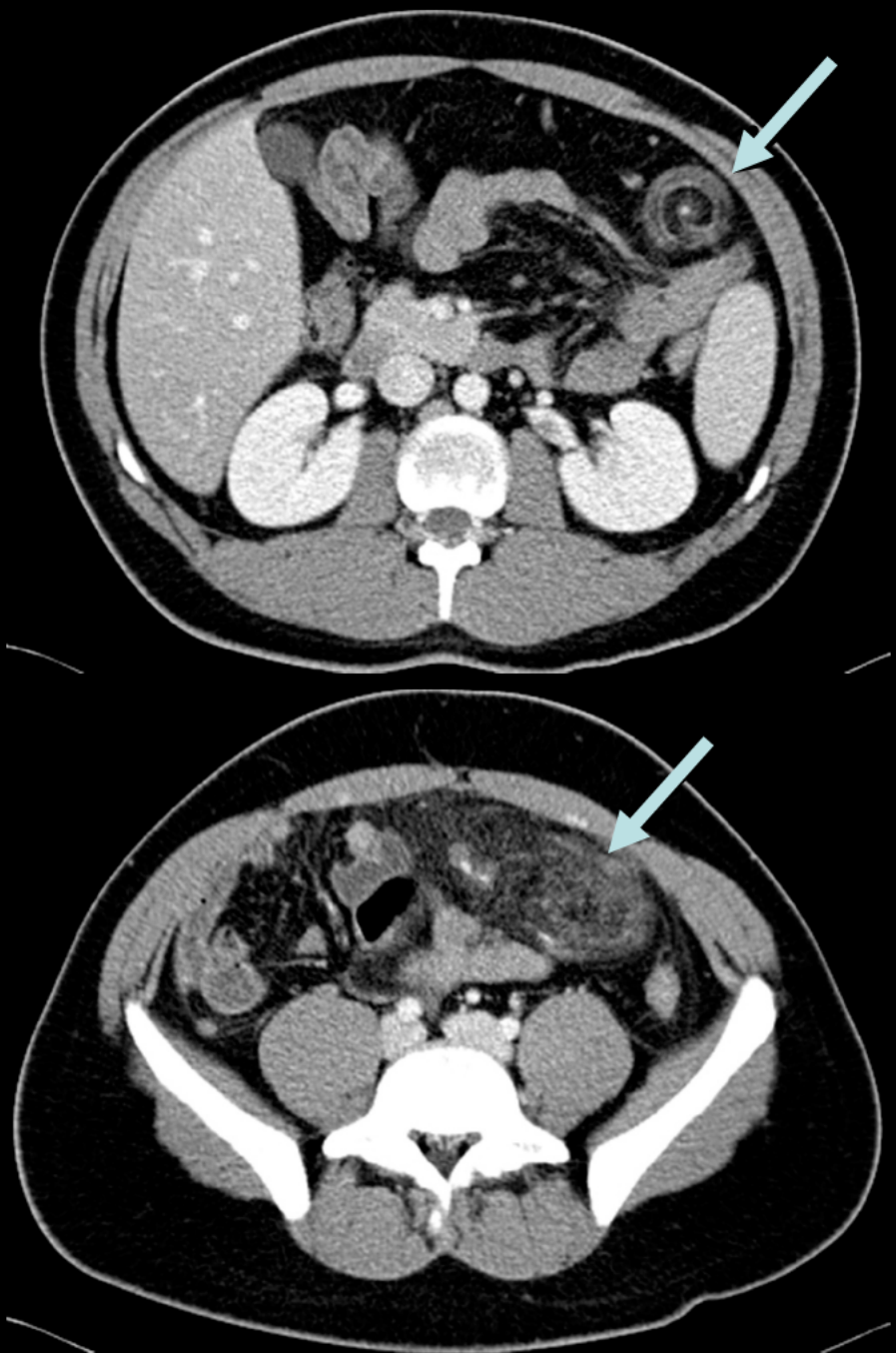


# Gastrointestinal Best Case

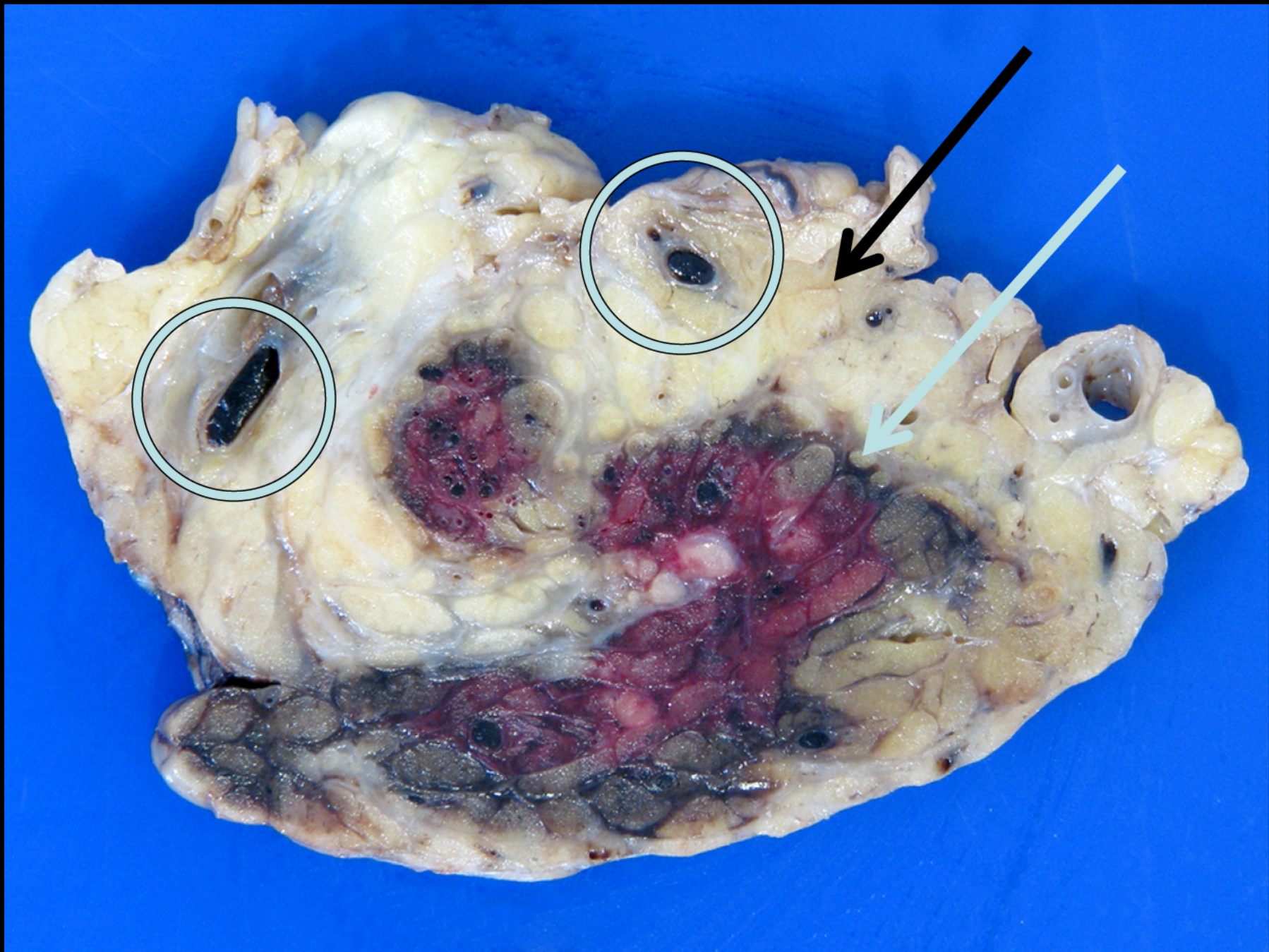


## Clinical information

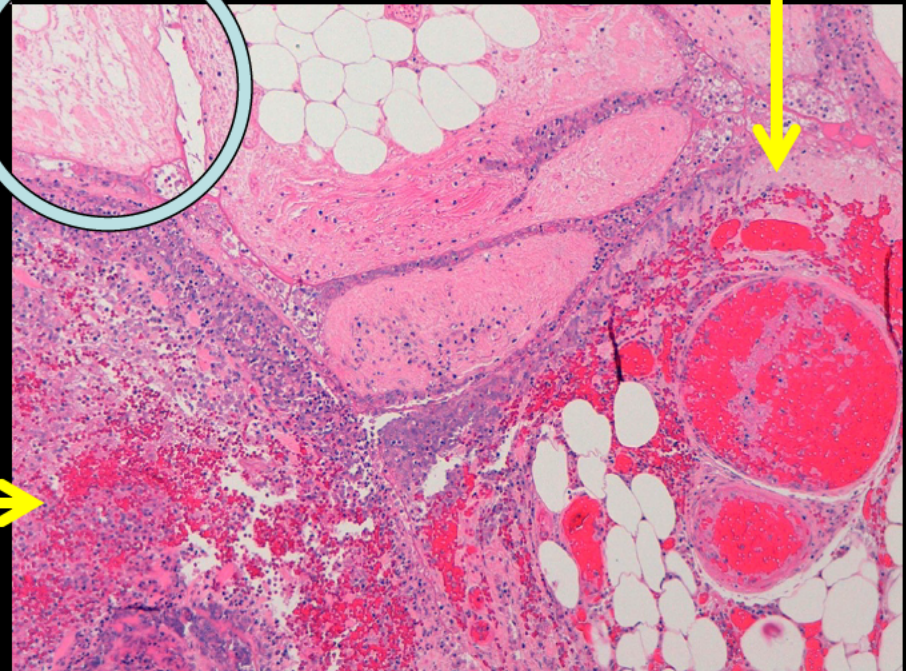
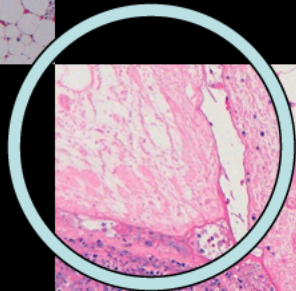
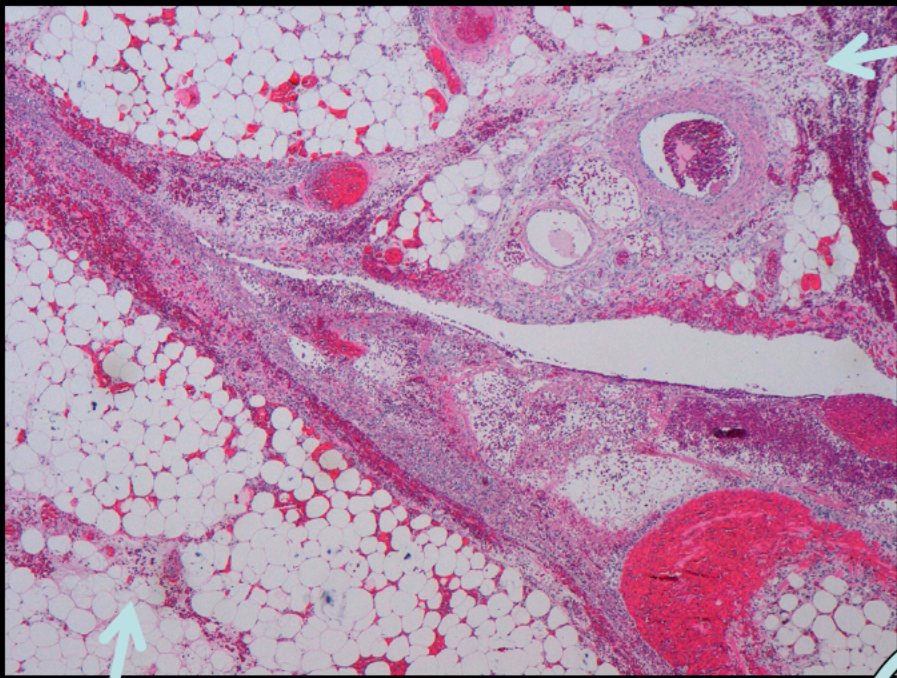
20 year old man with no significant medical history presents with acute onset left lower quadrant pain.











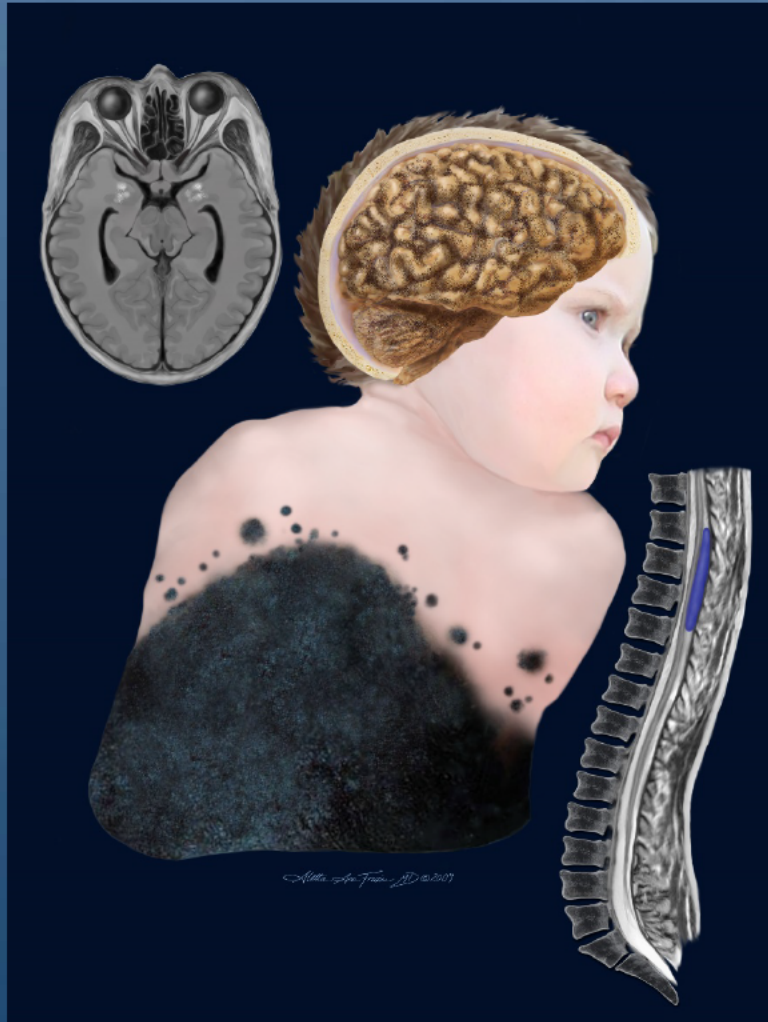# **Left-sided Omental Torsion**

**Paola Barón Ródiz, M.D.**

**Hospital Universitario Severo Ochoa**

**Madrid, Spain**

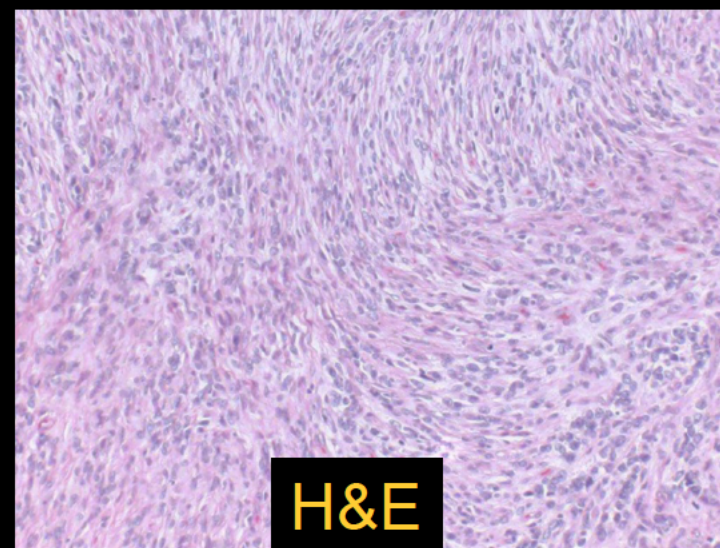
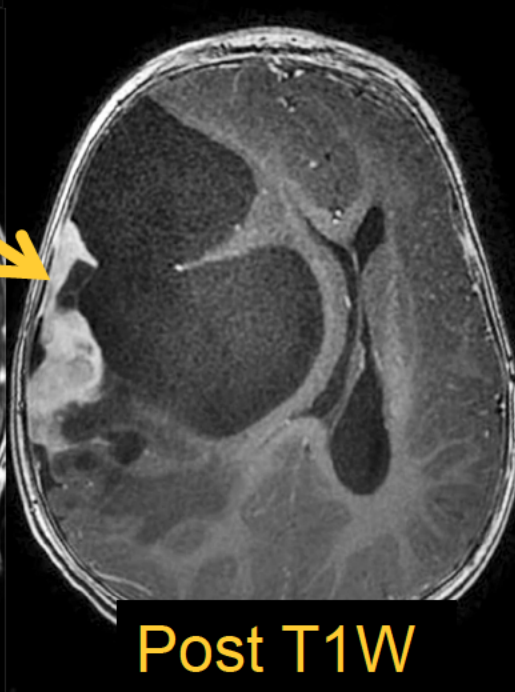
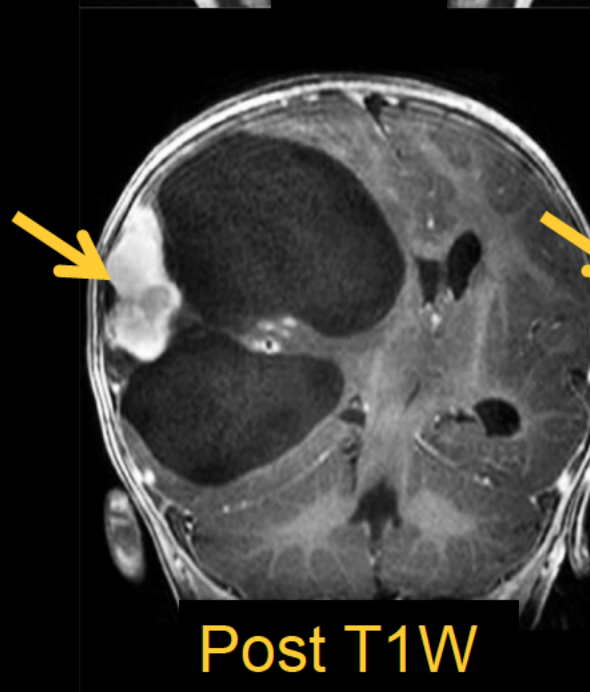
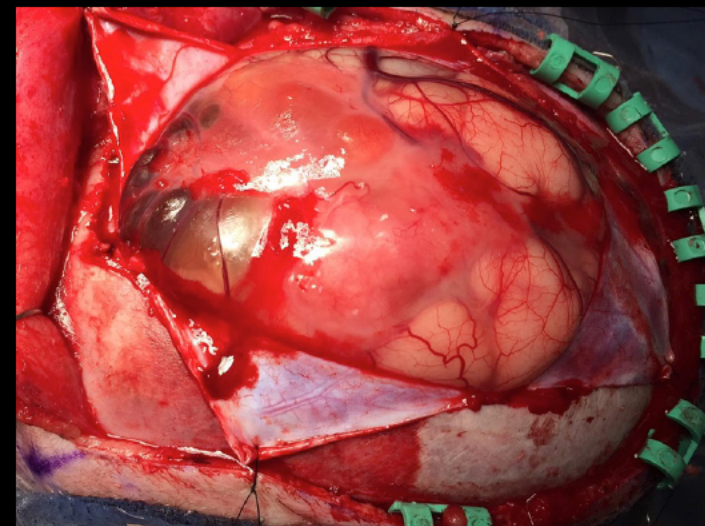
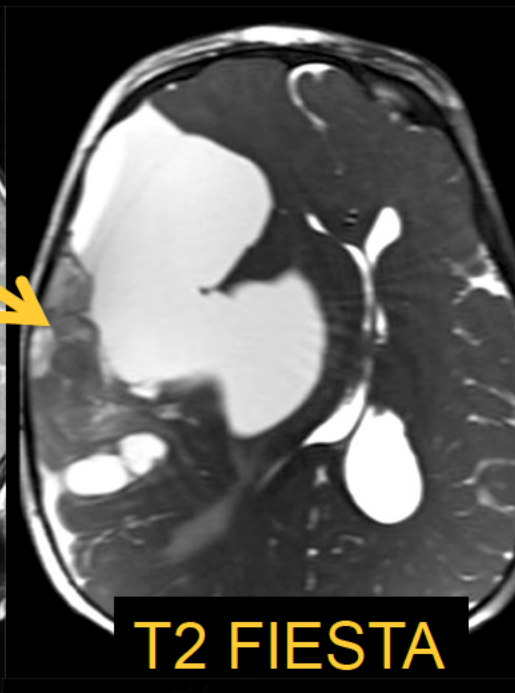
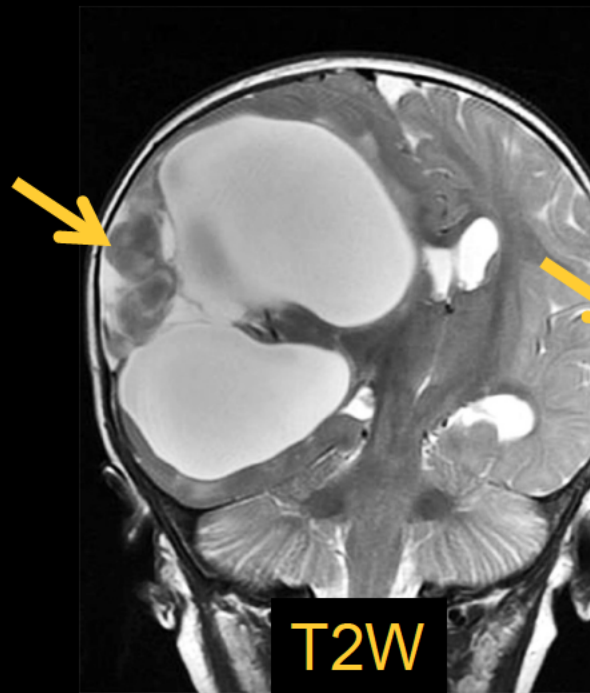
# Neuroradiology Best Case



# History

**8-month-old female with progressive  
left upper extremity weakness,  
lethargy, and macrocephaly**



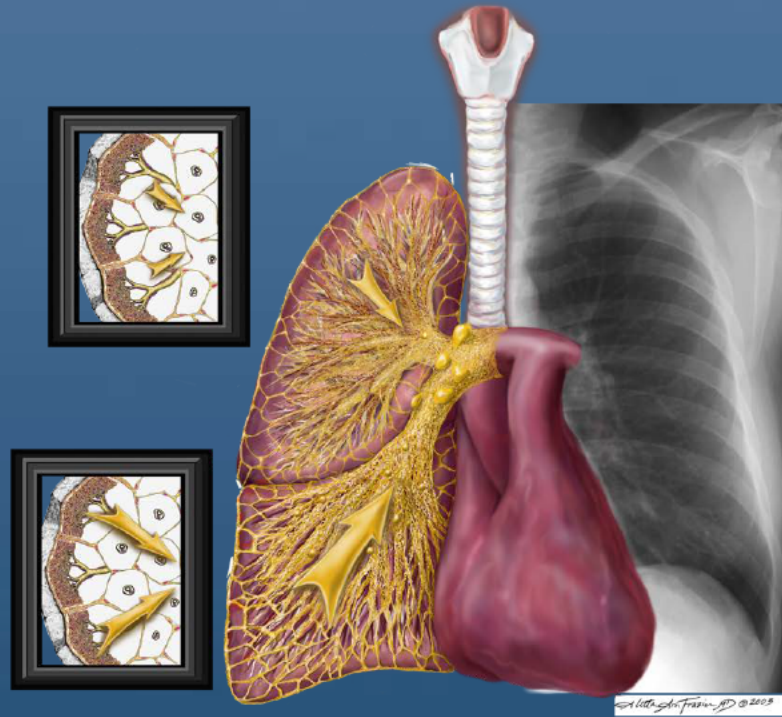


# **Desmoplastic Infantile Ganglioglioma**

**James Davis, M.D.**

**University of Pittsburgh  
Pittsburgh, Pennsylvania**

# Pulmonary and Mediastinal Best Case

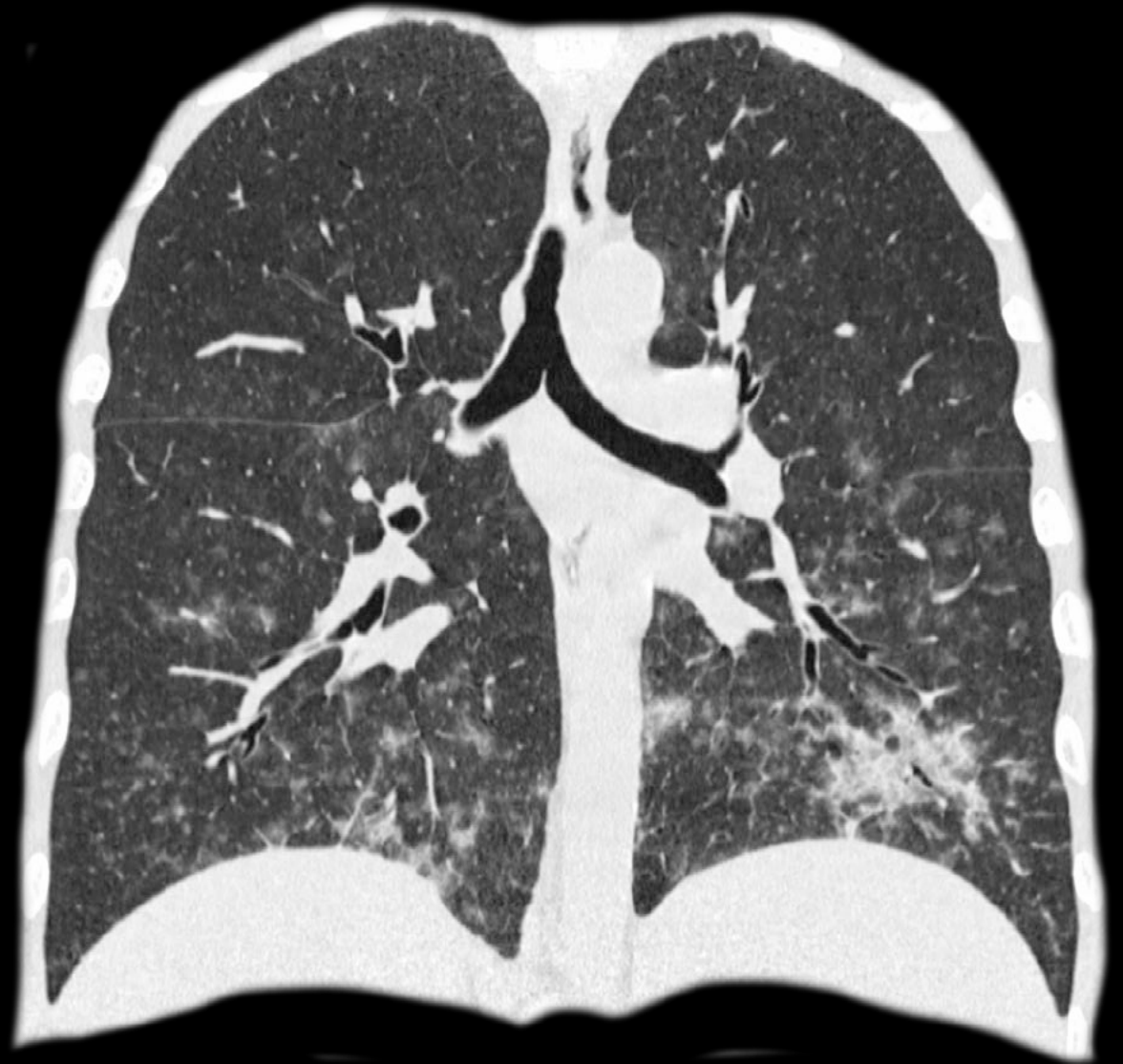
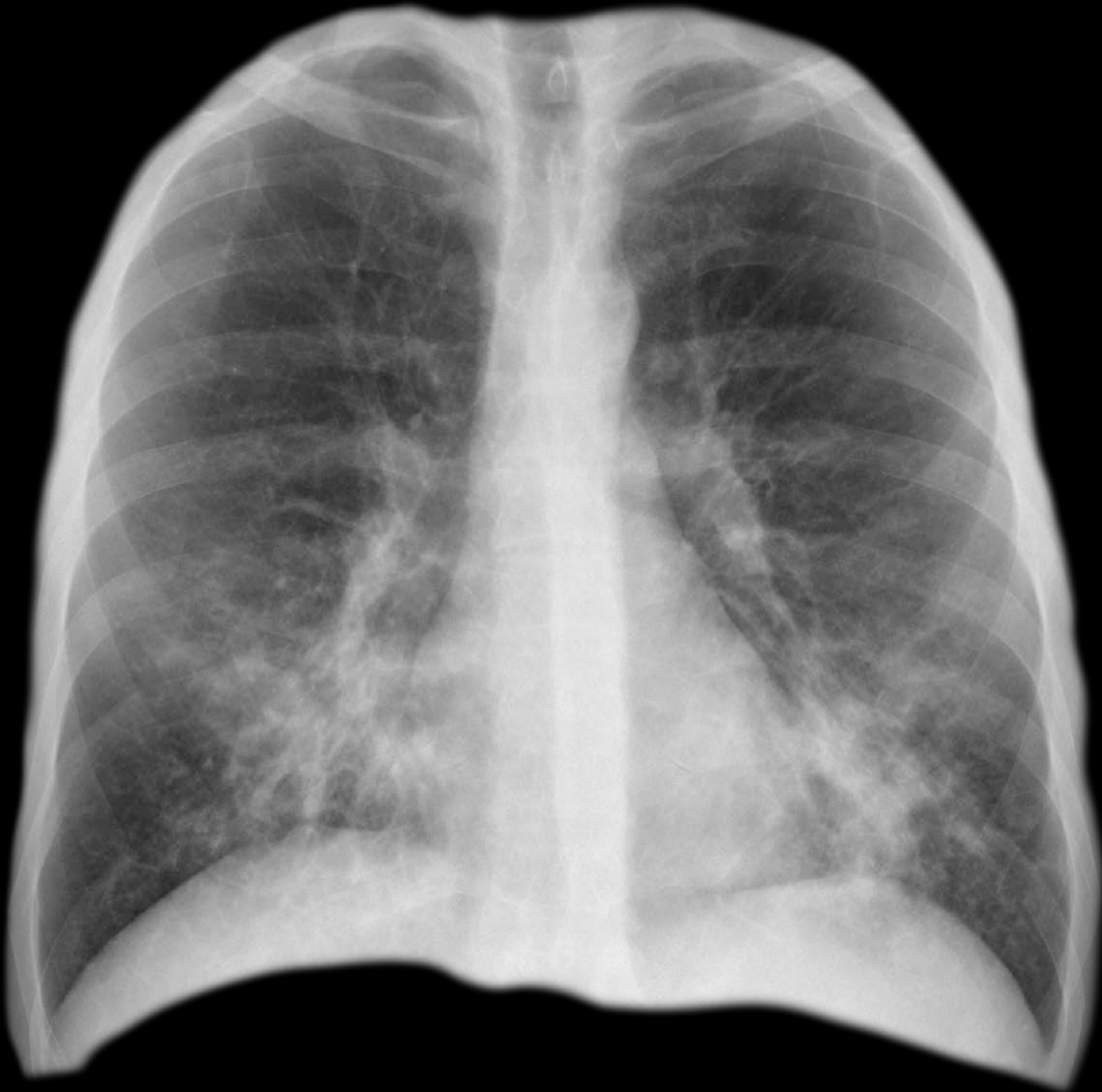


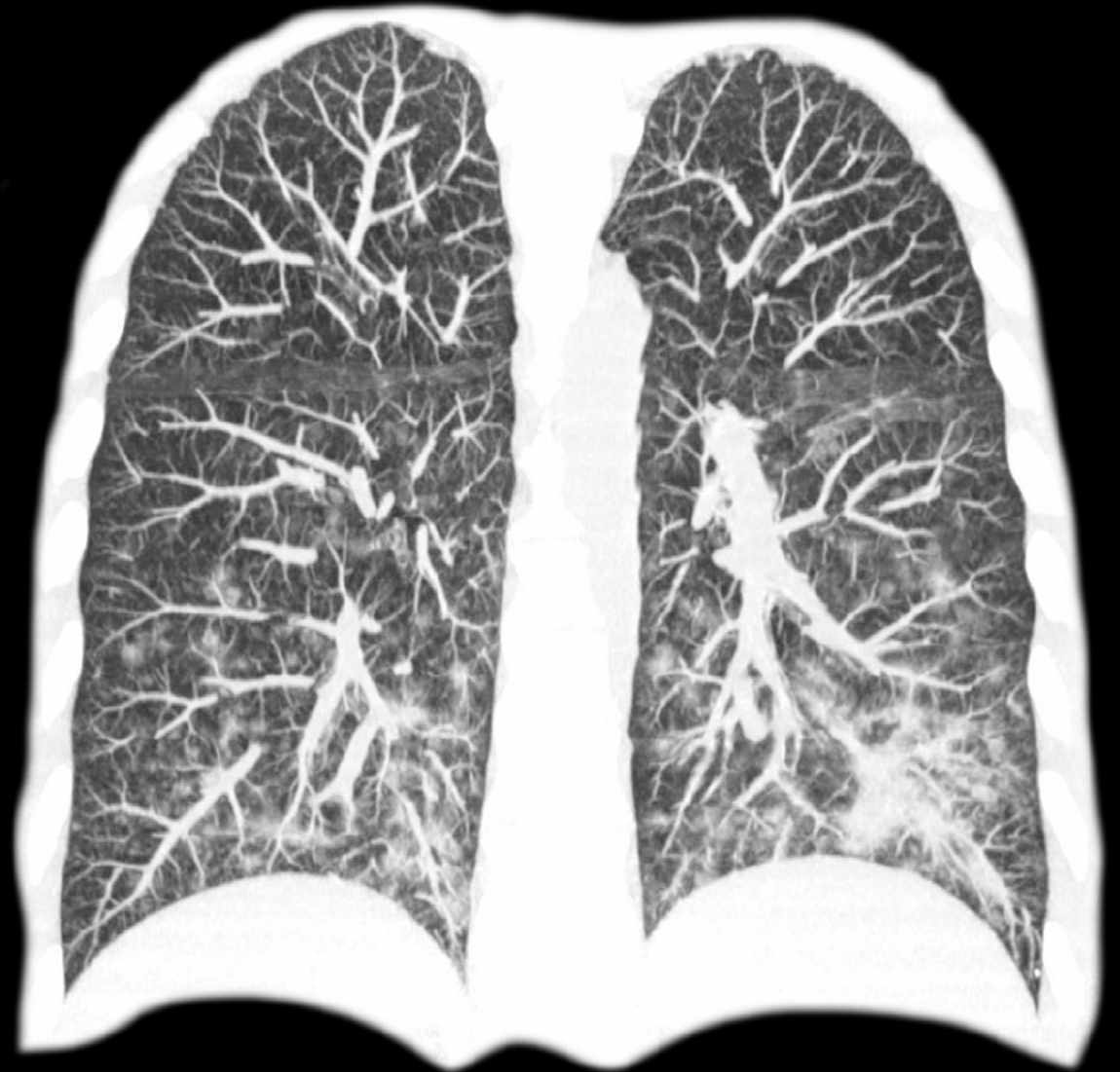
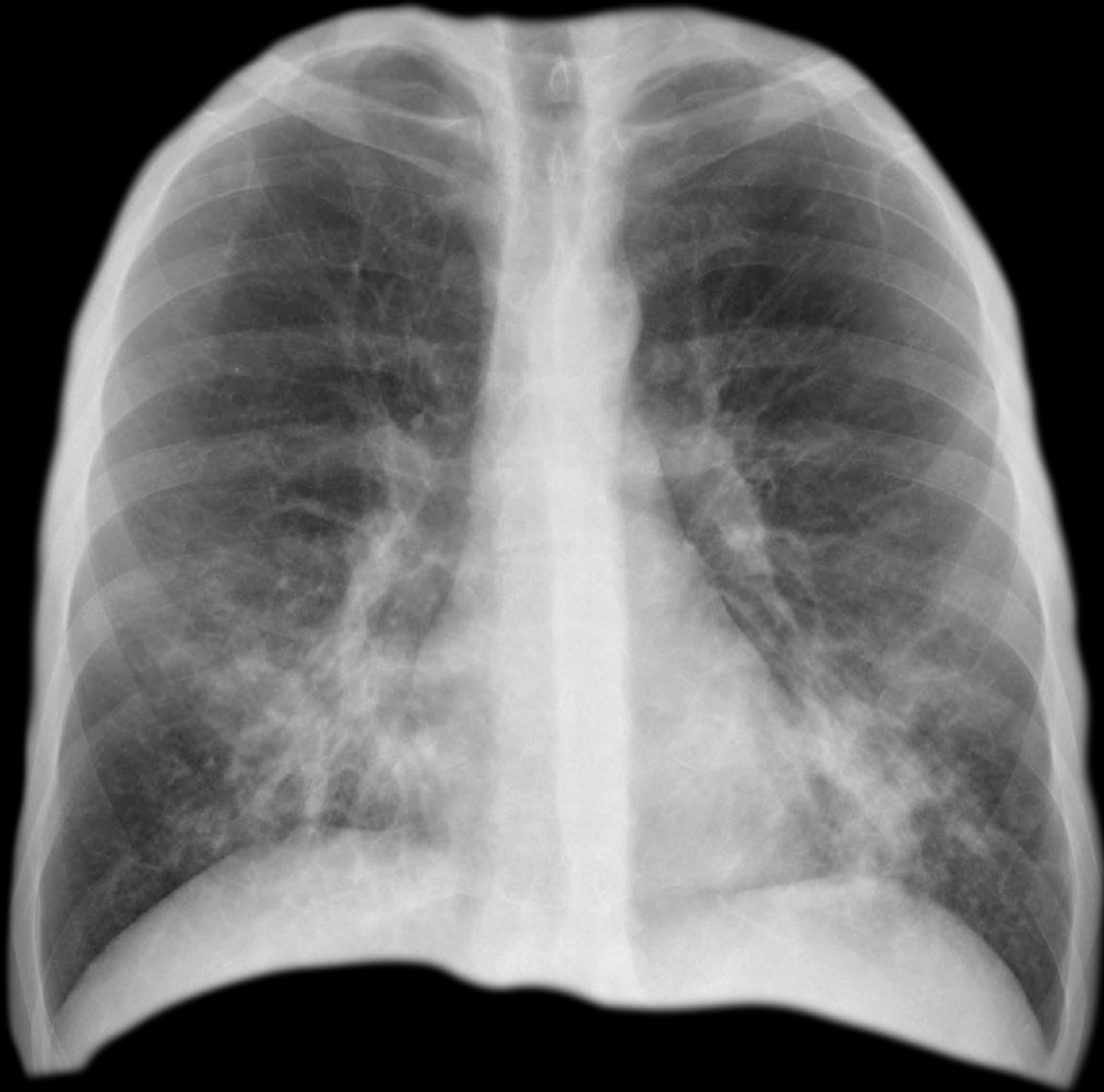# History

**54 year old male with a history of Rheumatoid Arthritis and Sjogren Syndrome. Currently treated with methotrexate. The patient presents with fever, cough, chills, sweats and malaise**

# Peribronchiolar consolidation

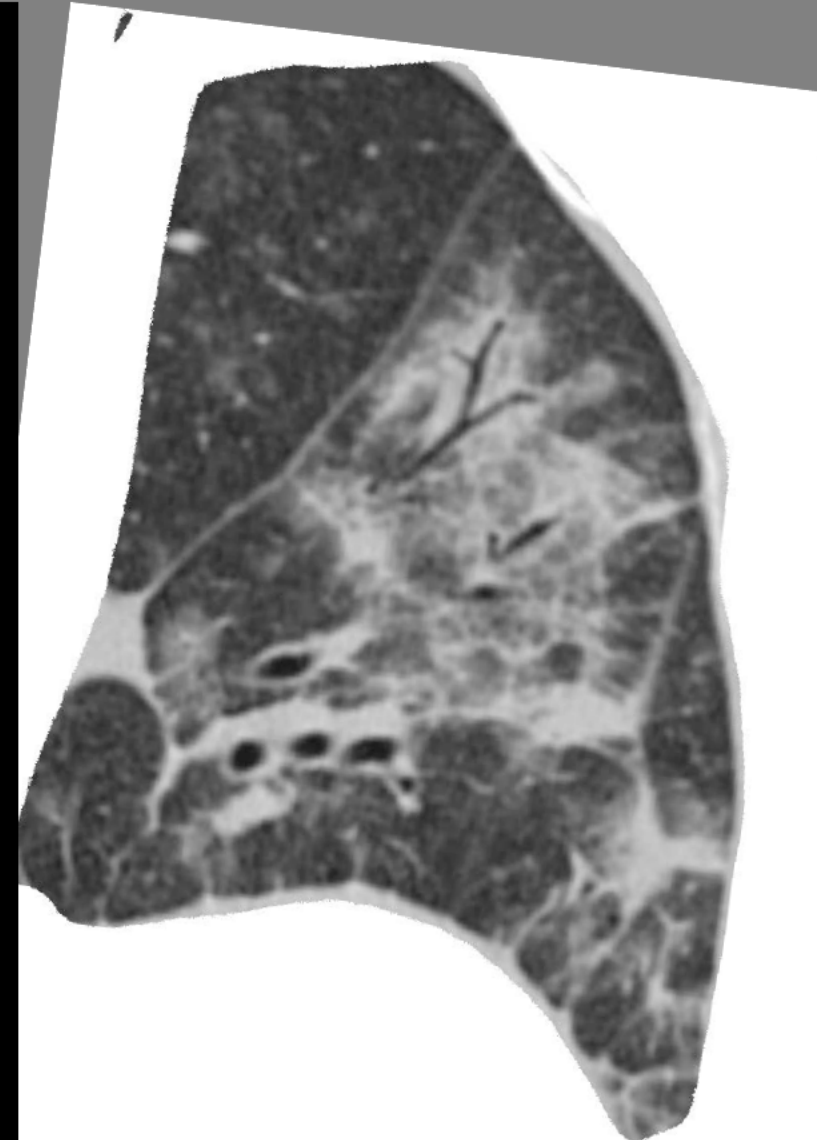



# Peribronchiolar consolidation





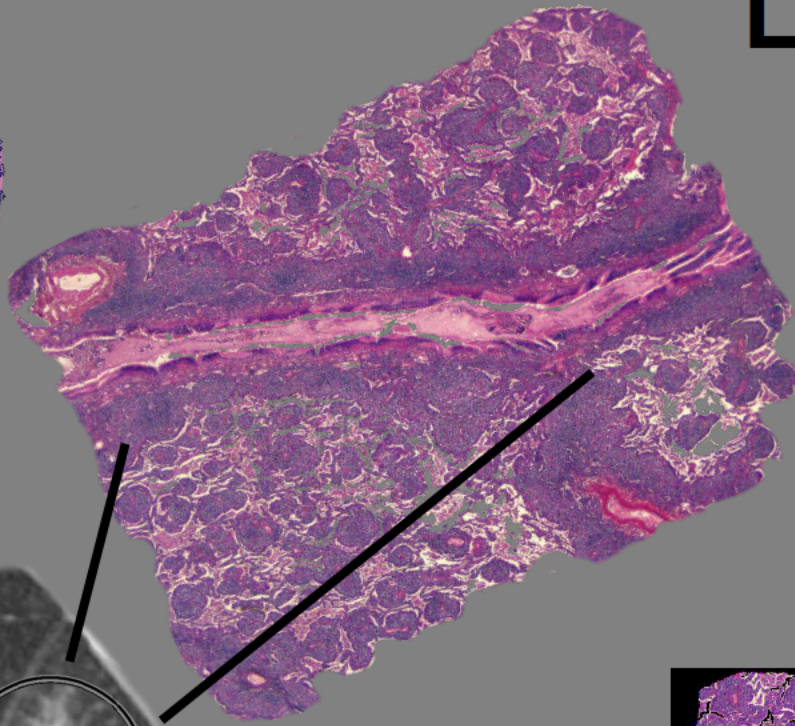
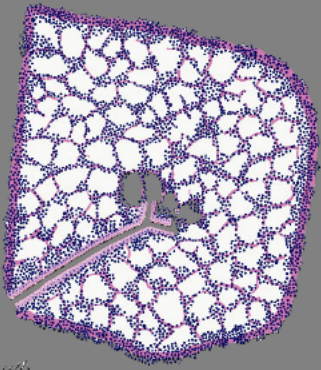
# Lymphocyte infiltration



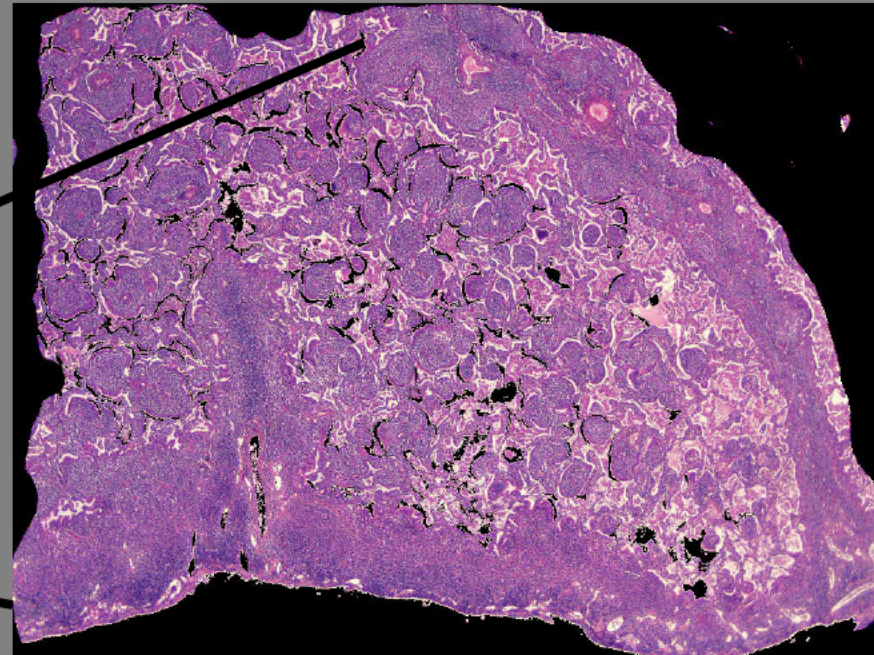
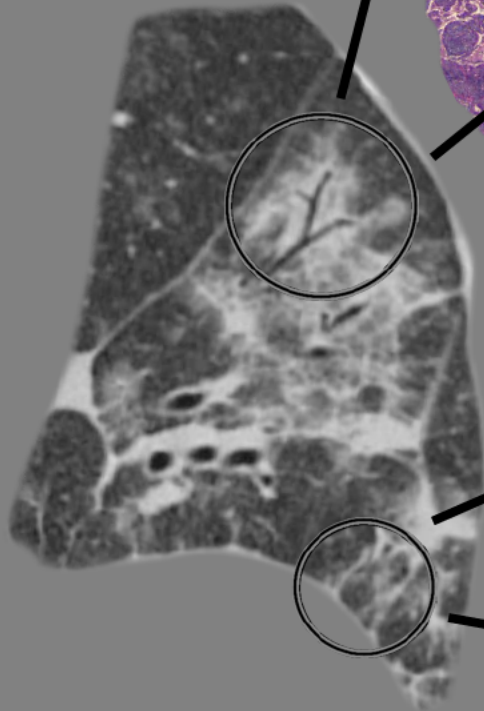


# Lymphocyte infiltration

Lymphocyte  
Lymphoid  
Follicle  
Nasopharyngeal lymphoid tissue  
spread from follicles  
Lymphoid infiltration down  
Infiltration of the  
respiratory epithelium  
by nasopharyngeal lymphoid cells



bronchovascular infiltration



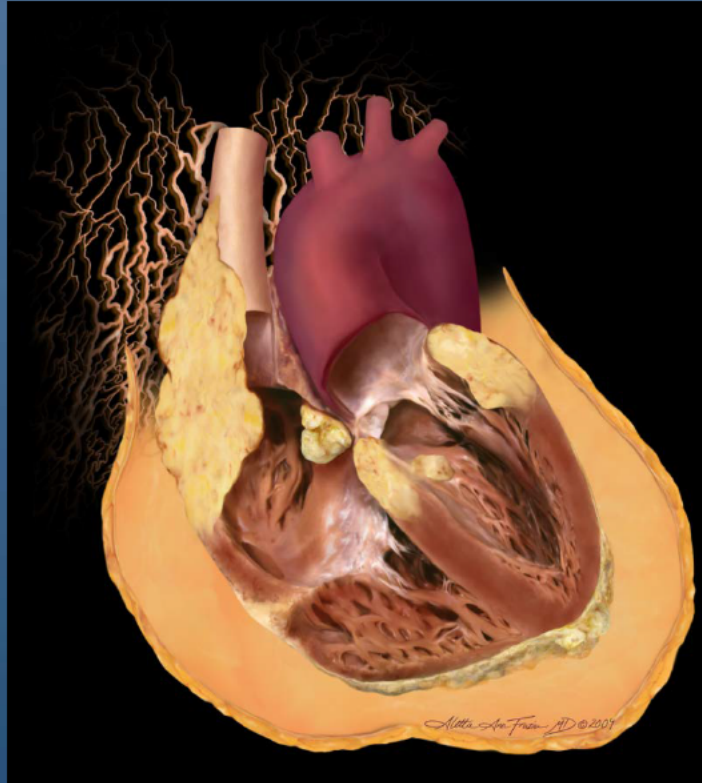total infiltration

# **BALT Lymphoma**

**Belén Del Rio Carrero**  
**Barcelona, Spain**



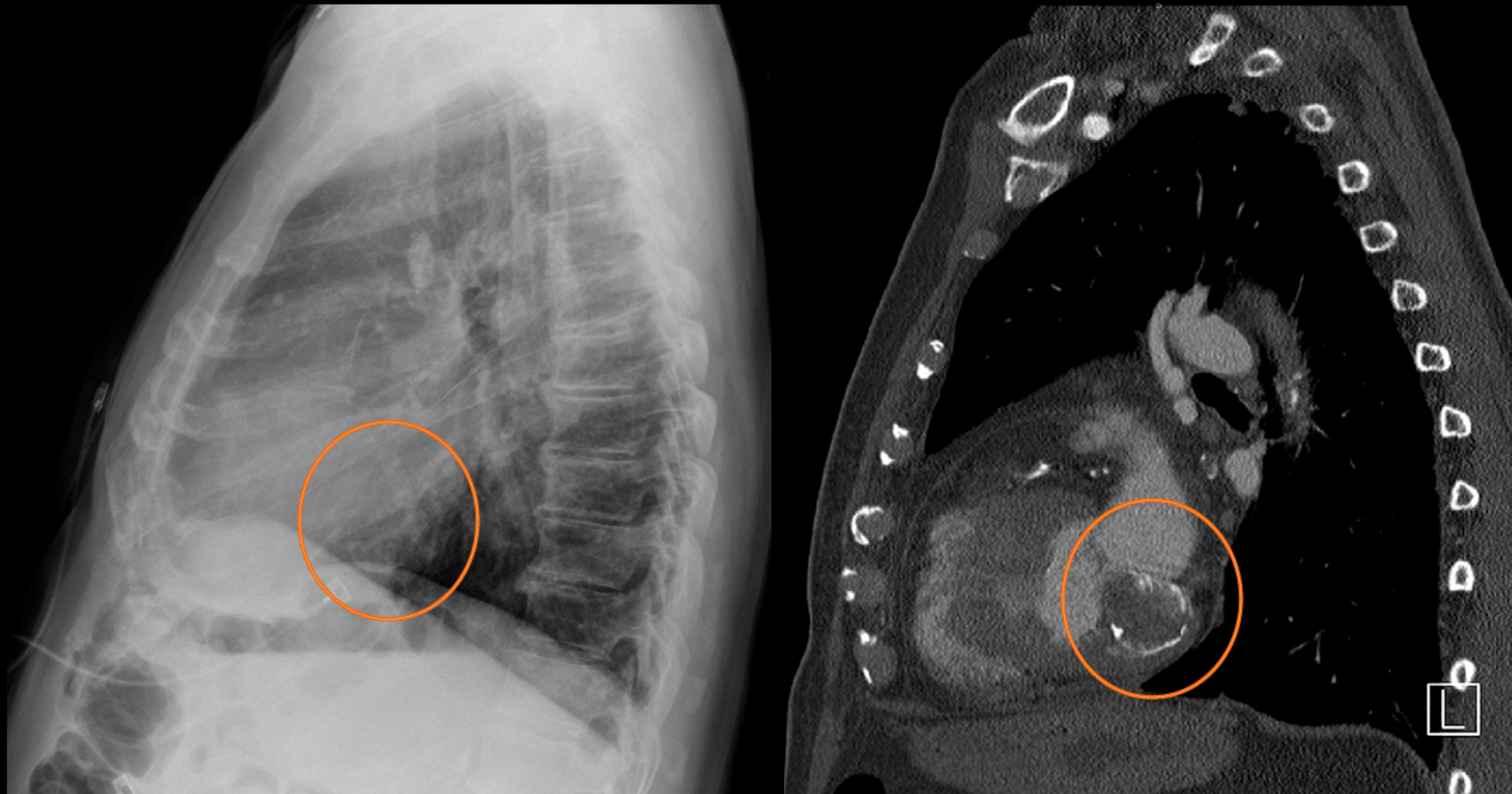
# Cardiovascular Best Case



# History

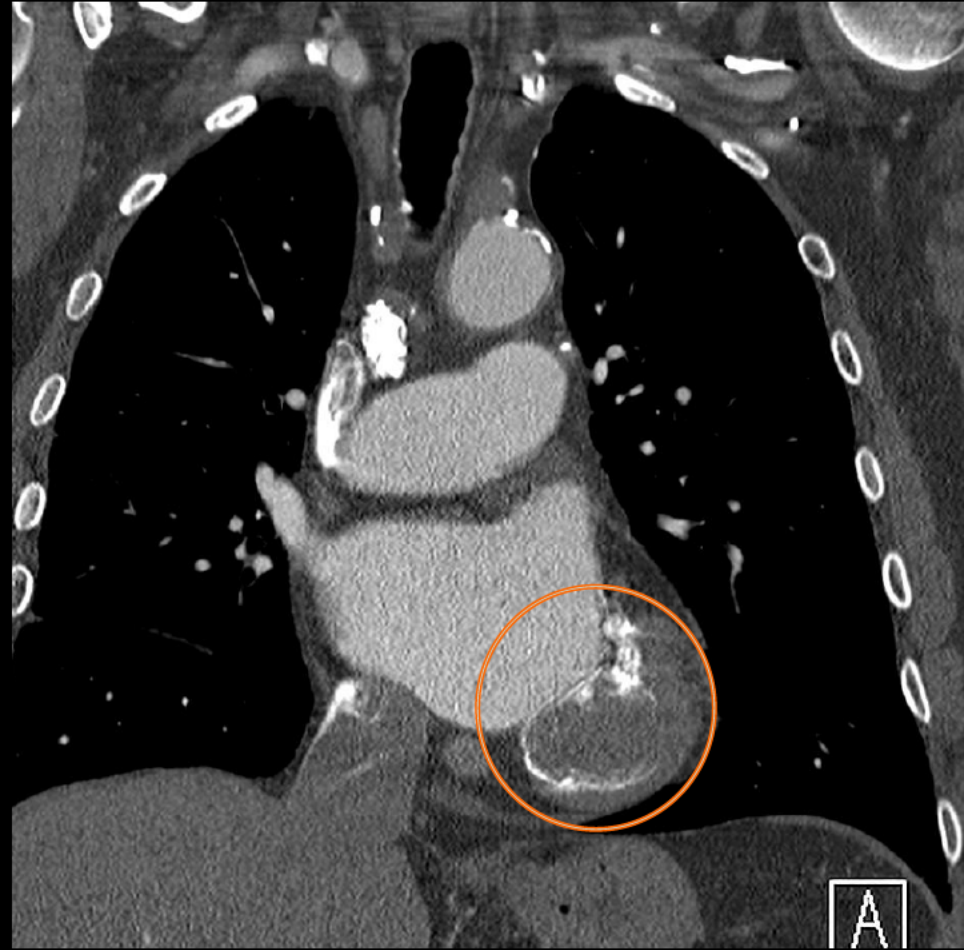
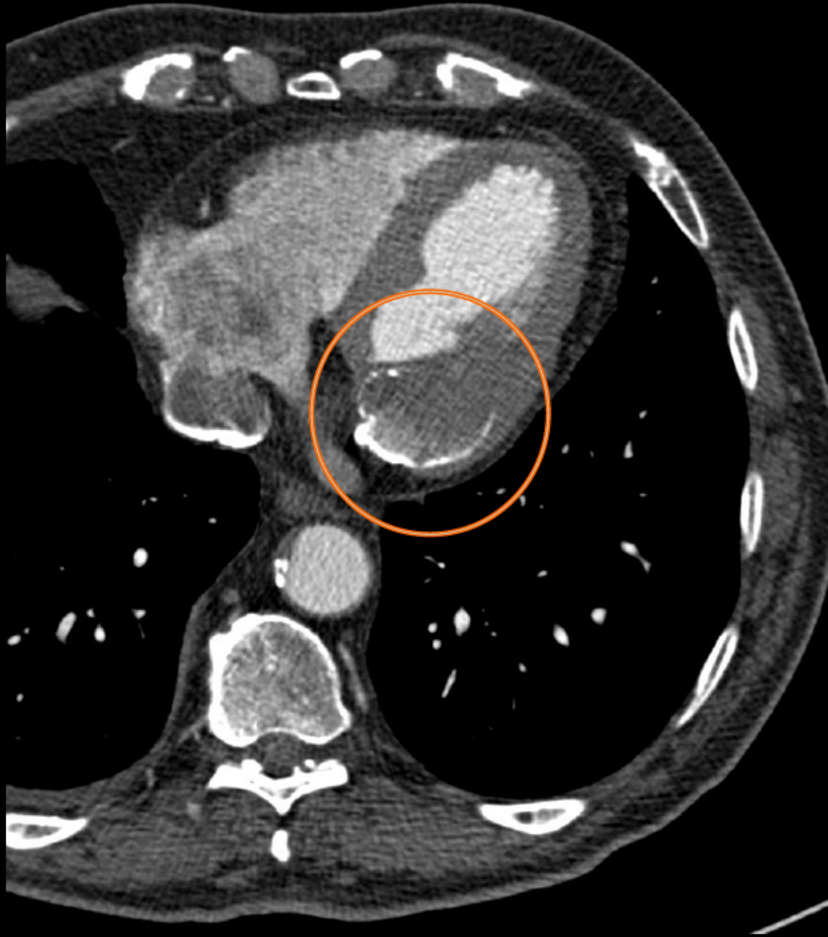
79 year old male with mild dyspnea and chest pain.

**Lateral CXR & Sagittal CT MPR:**  
**Hypodense rounded lesion margined with calcification,**  
**adjacent to the left atrio-ventricular groove on CT.**

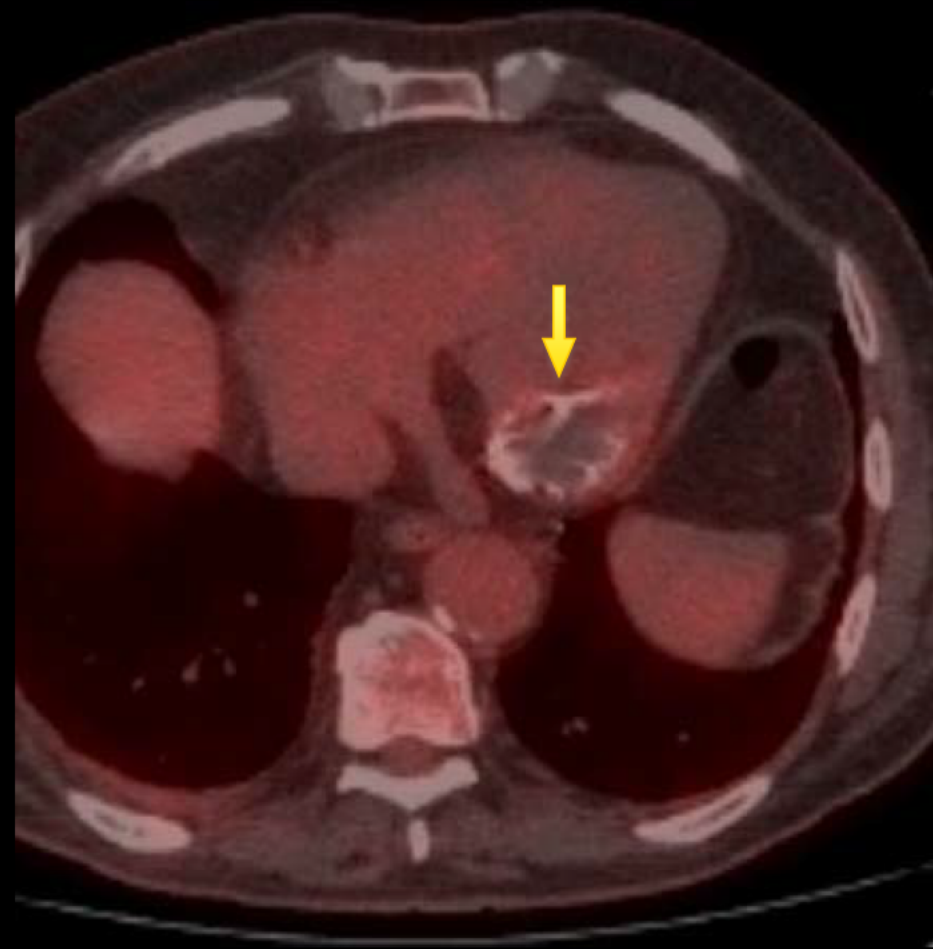
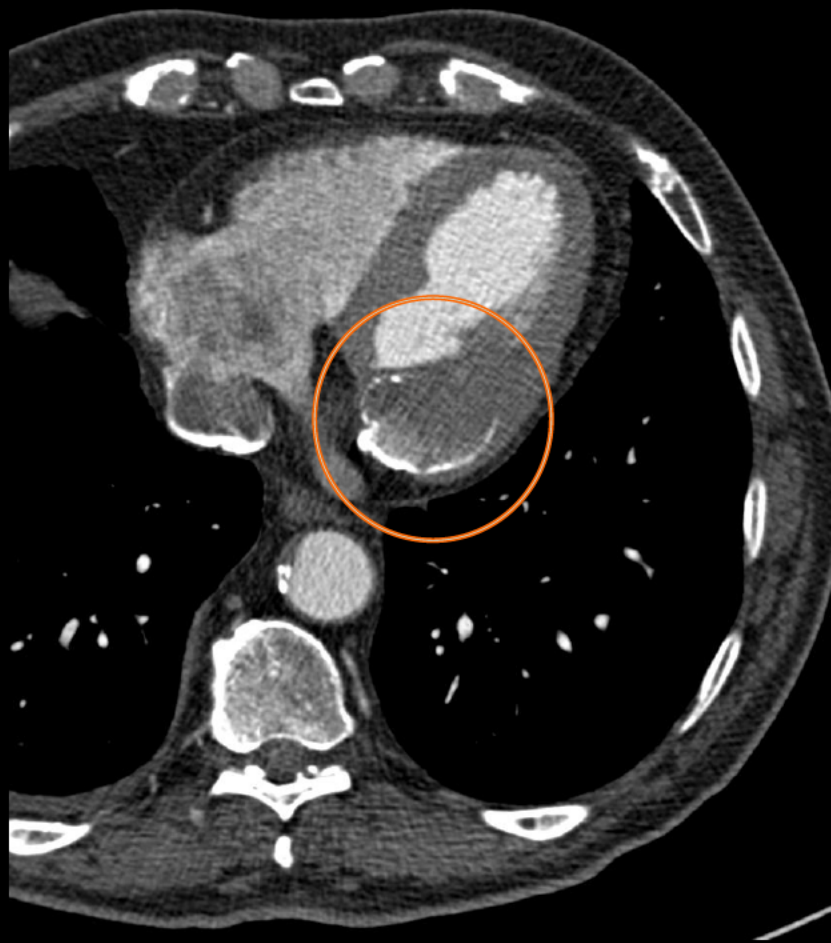


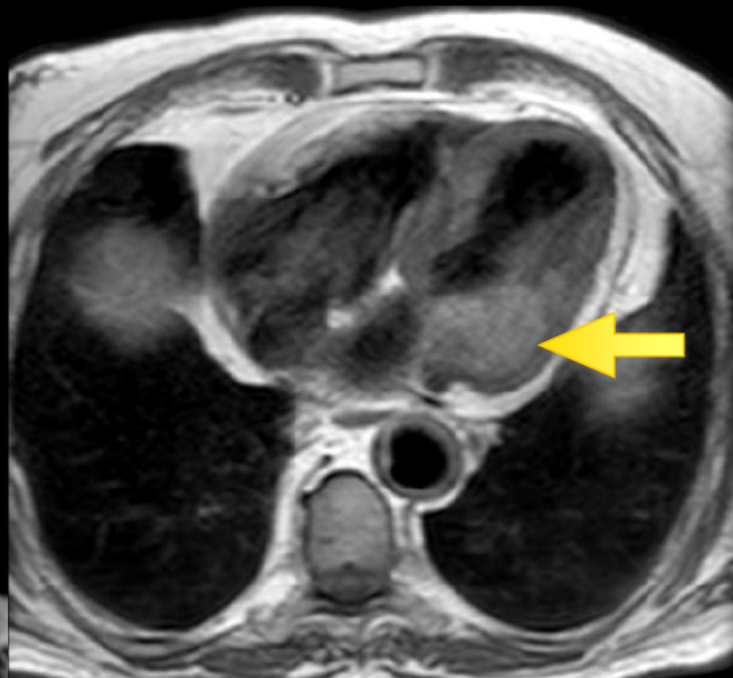


**Axial & Coronal CT MPR:**  
**Hypodense rounded lesion marginated with calcification,**  
**adjacent to the left atrio-ventricular groove on CT.**

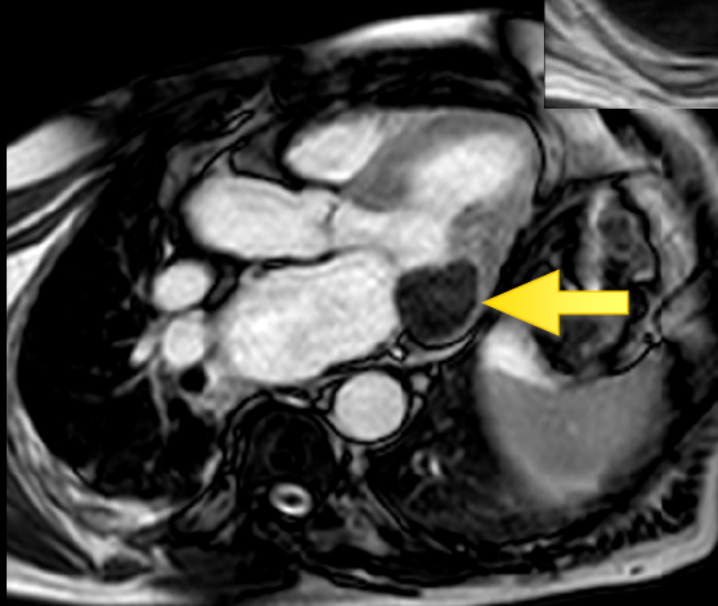


**PET-CT FDG IMAGING:**  
**No FDG uptake within the cardiac mass.**

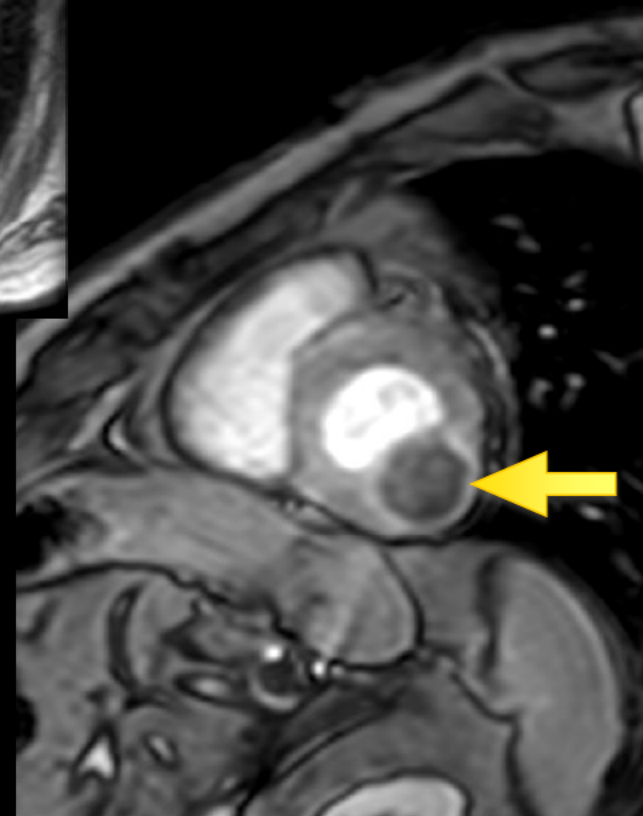




**T1-W MRI**



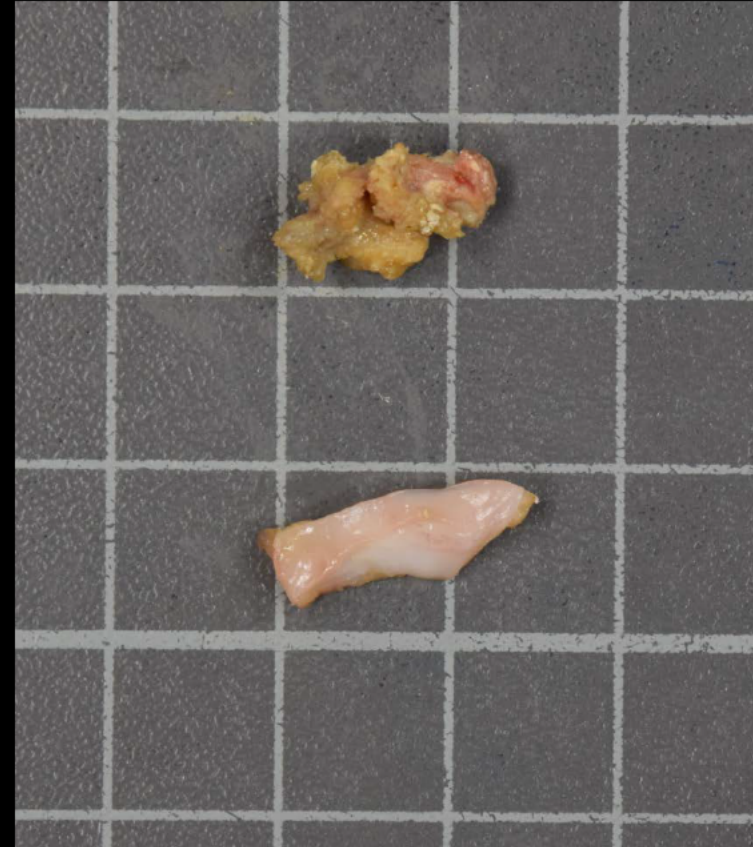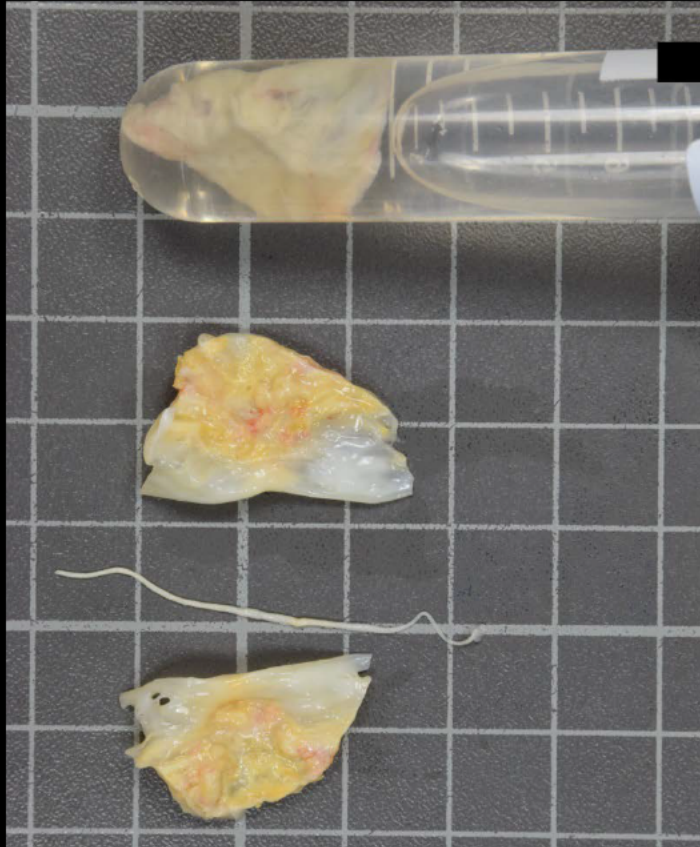**Cine MRI: 3-Chamber**



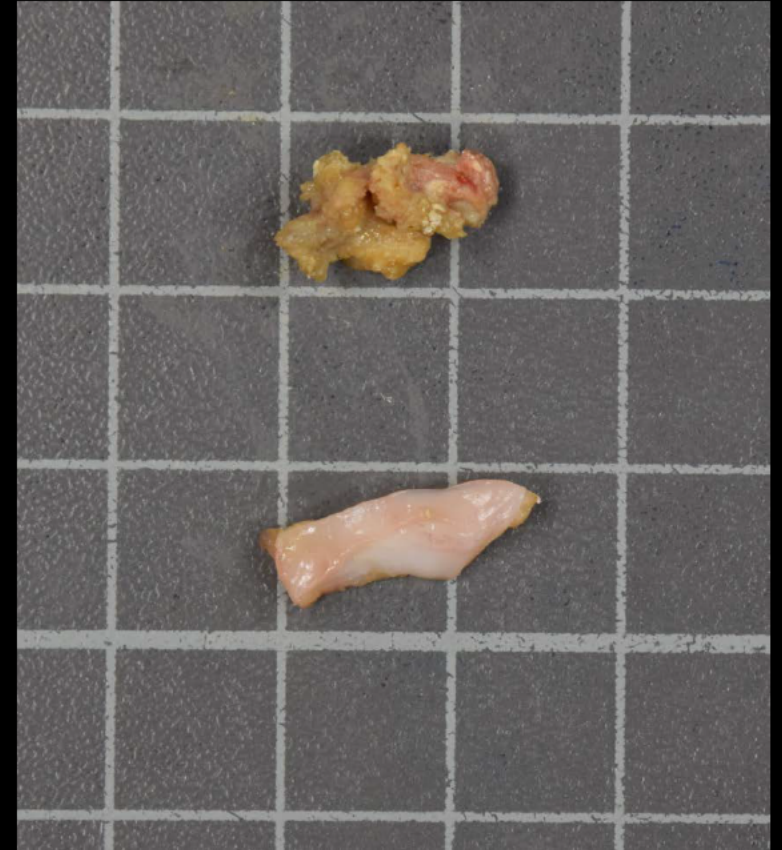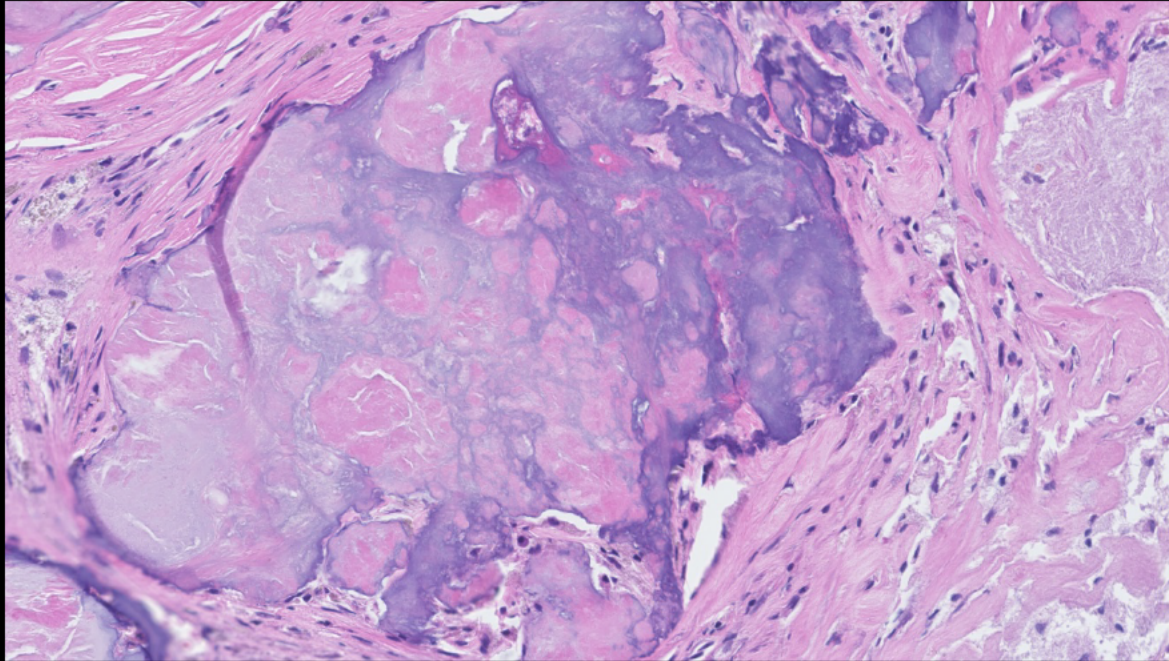
**Perfusion MRI**



**Gross resection specimen of mitral valve and adjacent encapsulated lesion with caseous internal contents.**



**Histologic examination shows necrotic tissue with elements of calcification compatible with caseous necrosis.**



# Caseous Necrosis of the Mitral Annulus

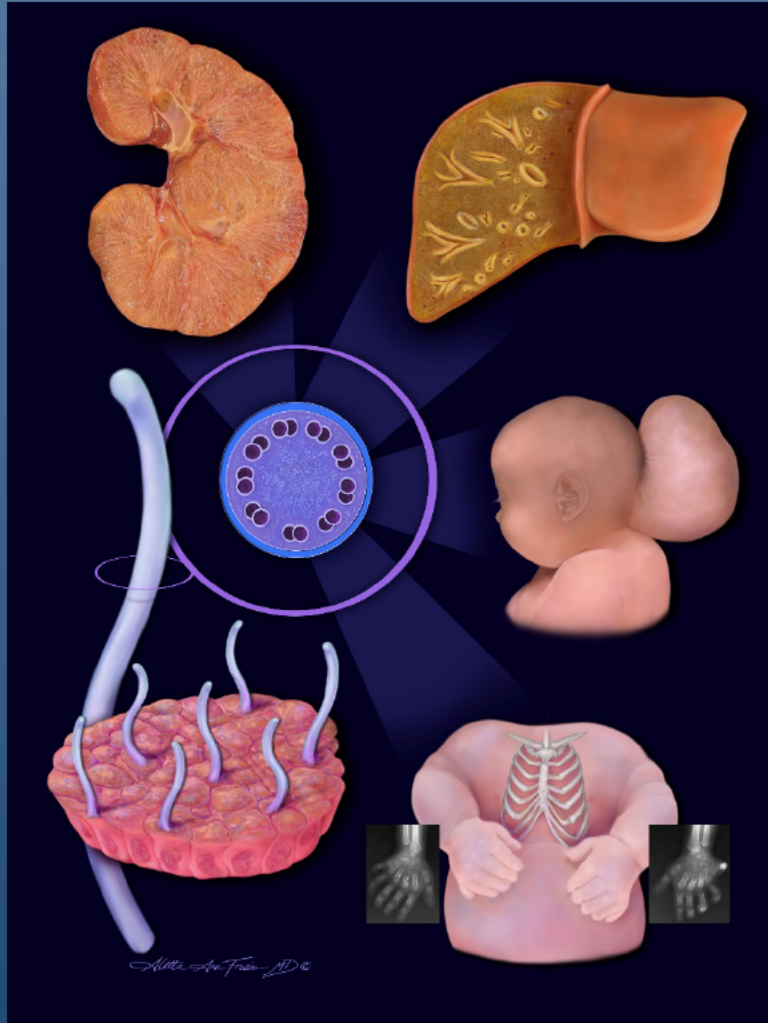
**Alexandre Asselin , MD**

Institut Universitaire de Cardiologie et Pneumologie de  
Quebec

Quebec, Canada

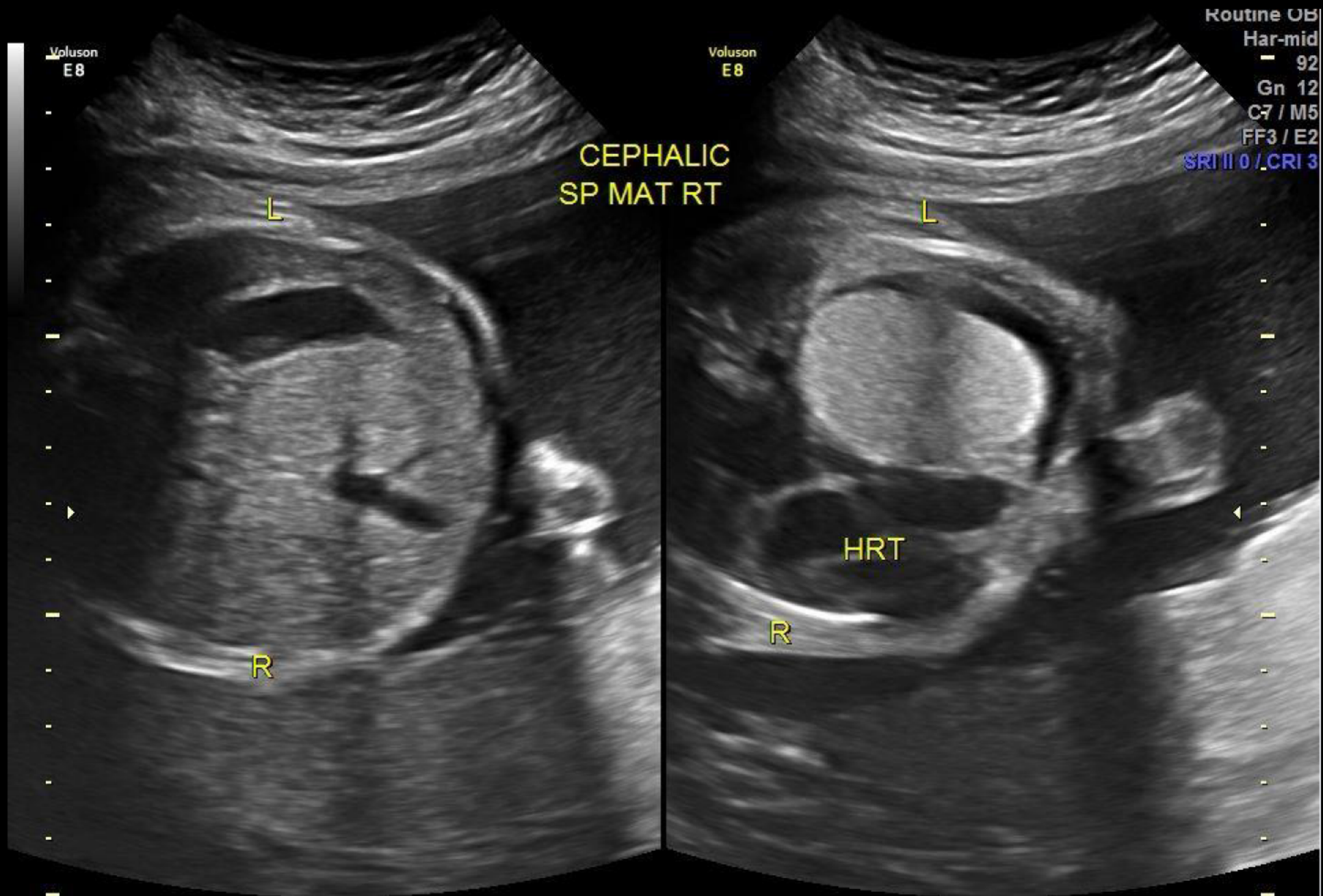


# Pediatric Best Case

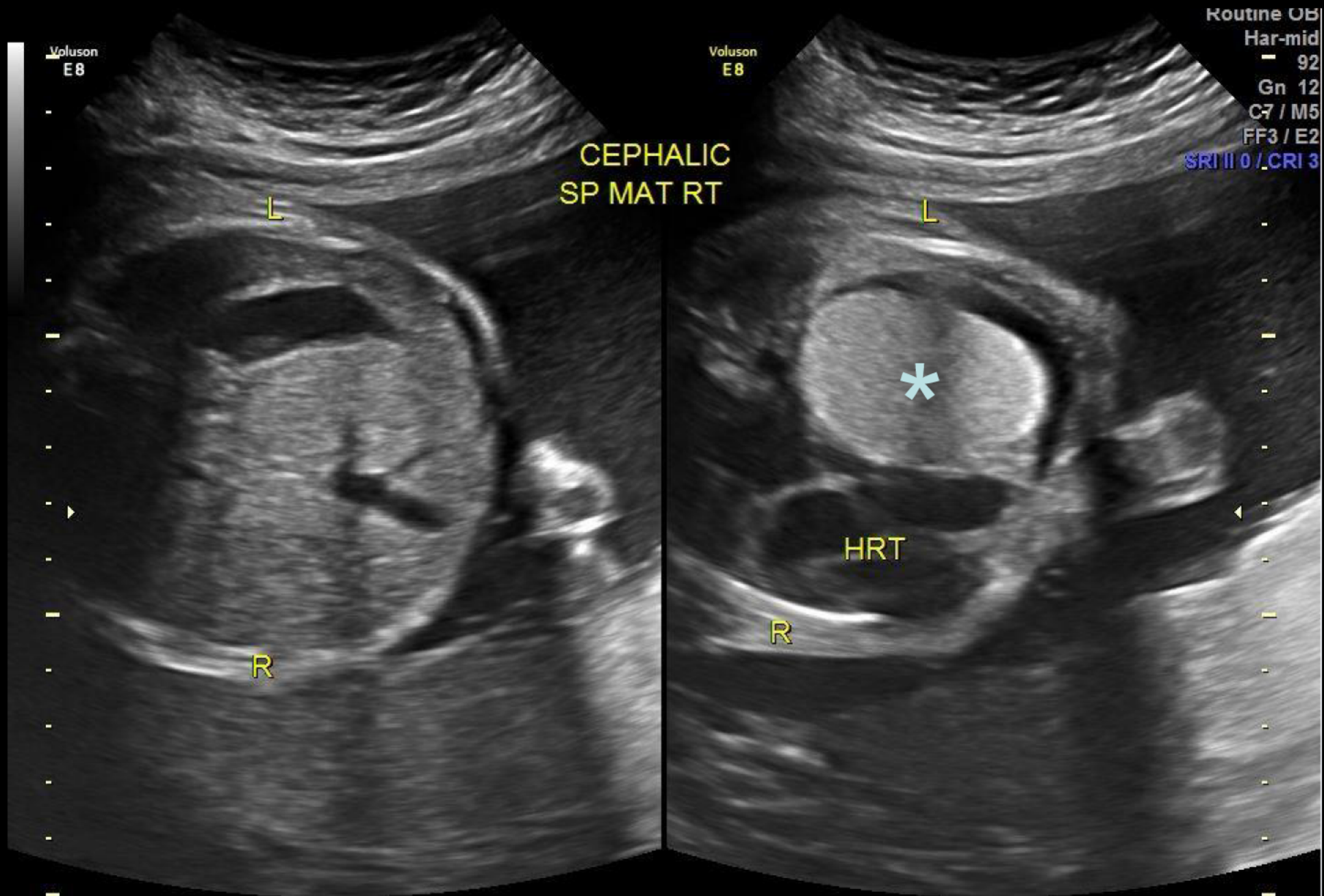


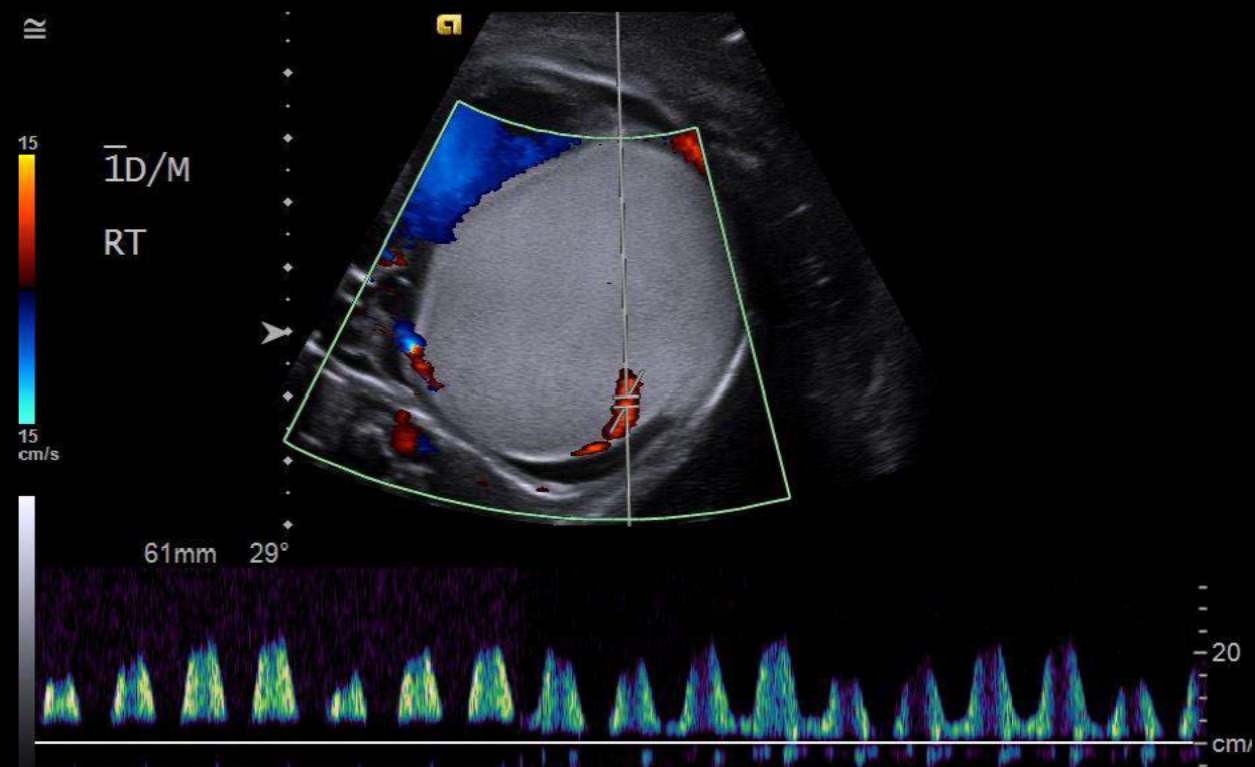
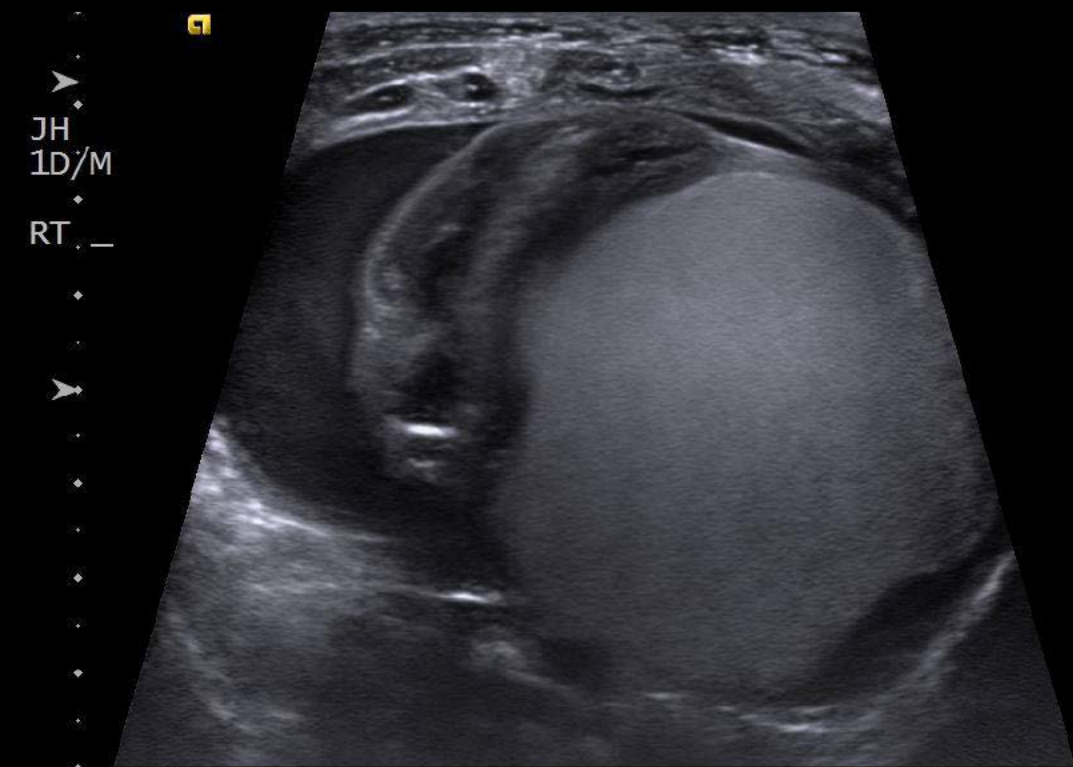
## Clinical Information

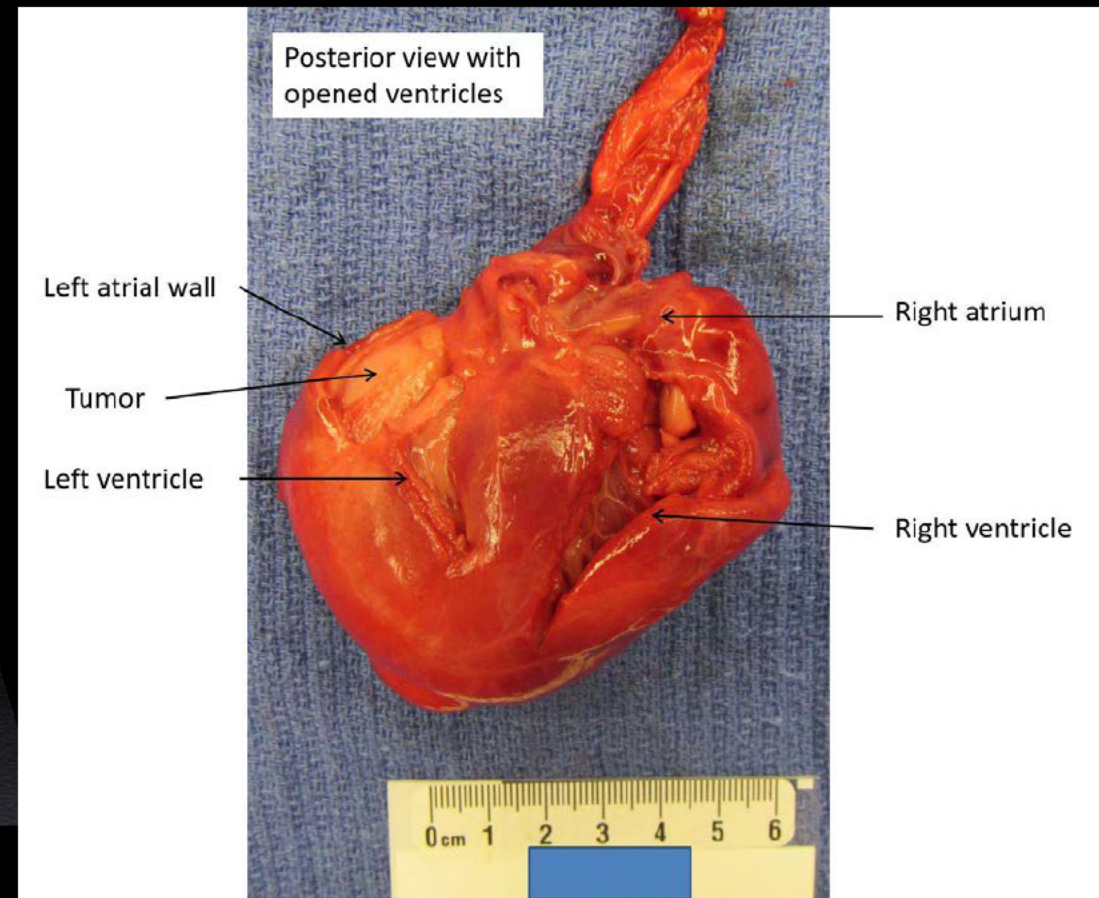
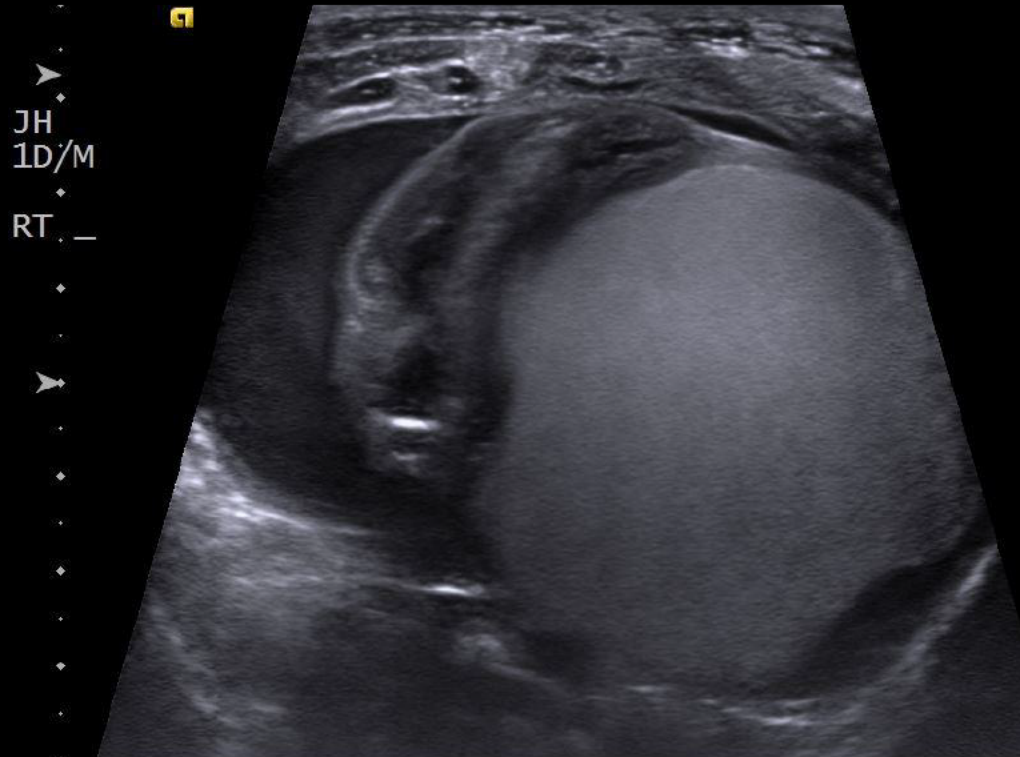
**35 3/7 week, 3000 gram infant born by c-section to a 28 y/o G4 T2 P2 A0 L4 mother. Pregnancy complicated by polyhydramnios, fetal ascites, hypothyroidism. Infant required intubation at delivery.**





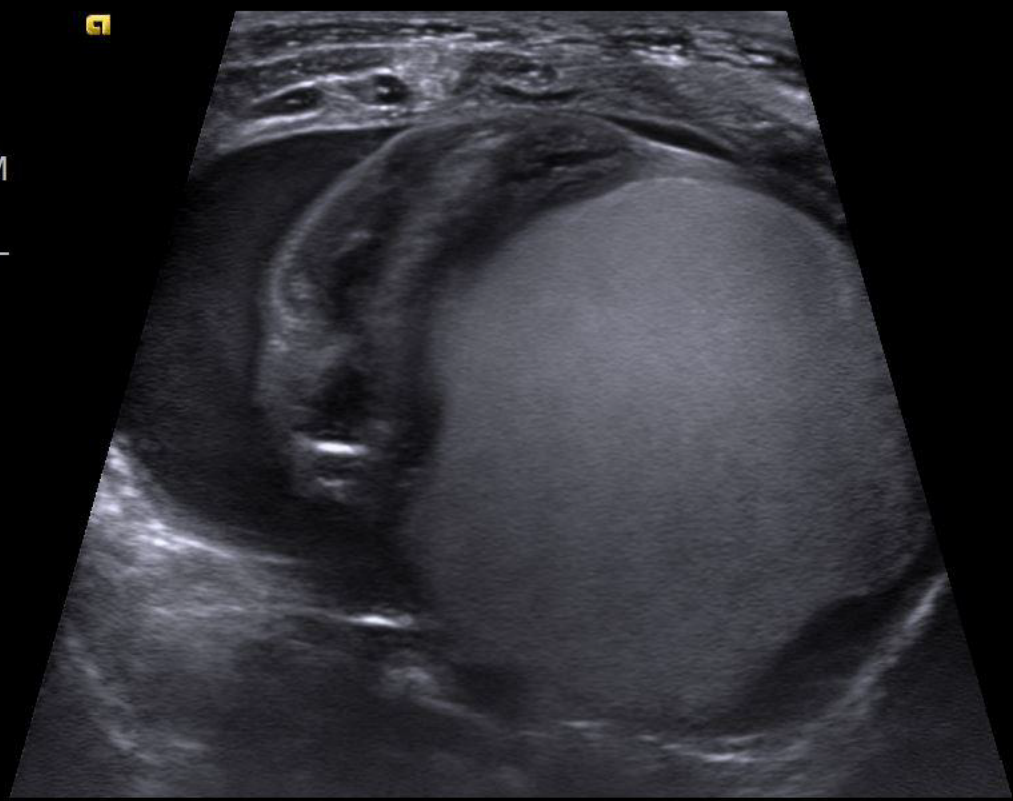




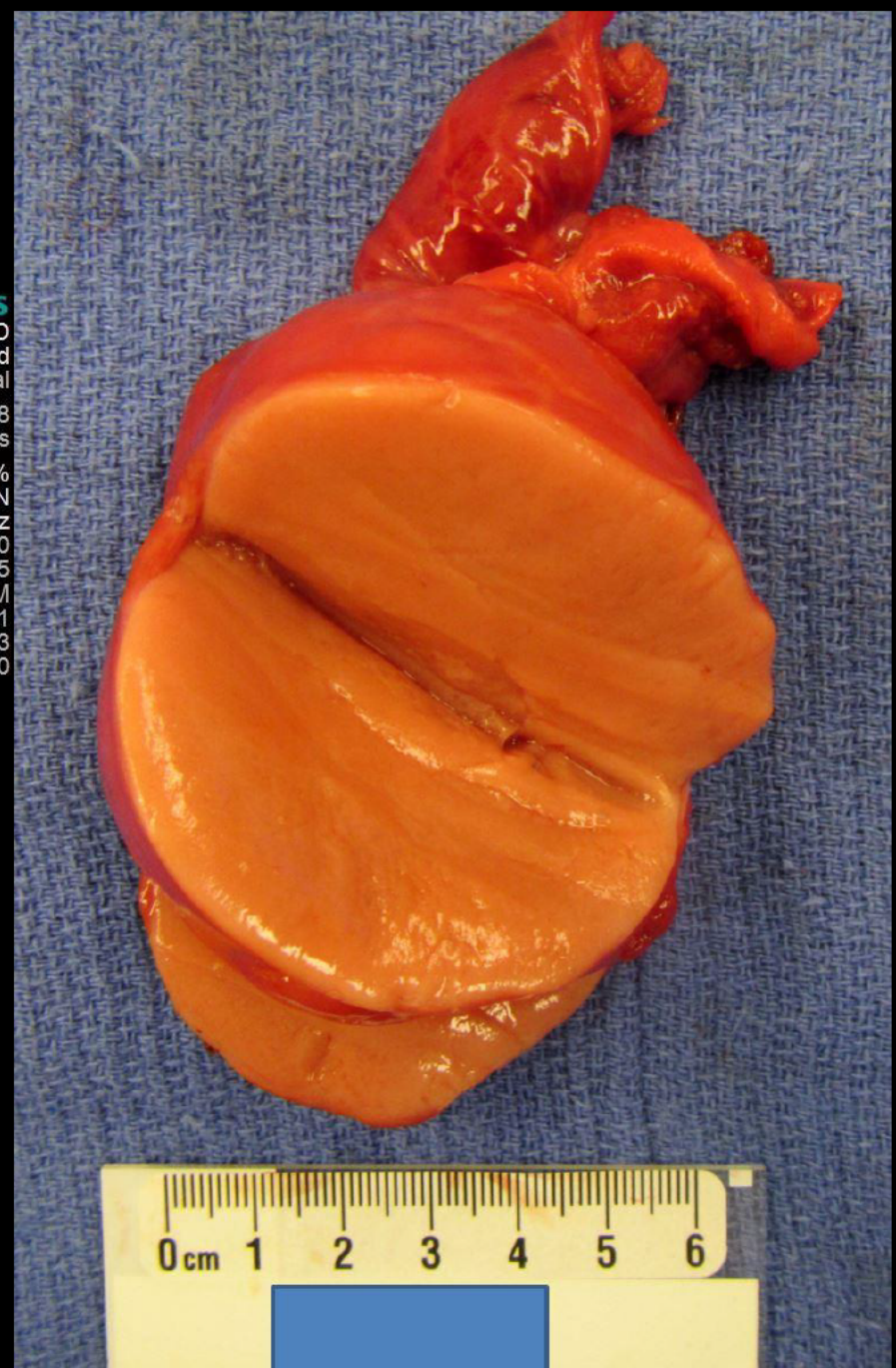




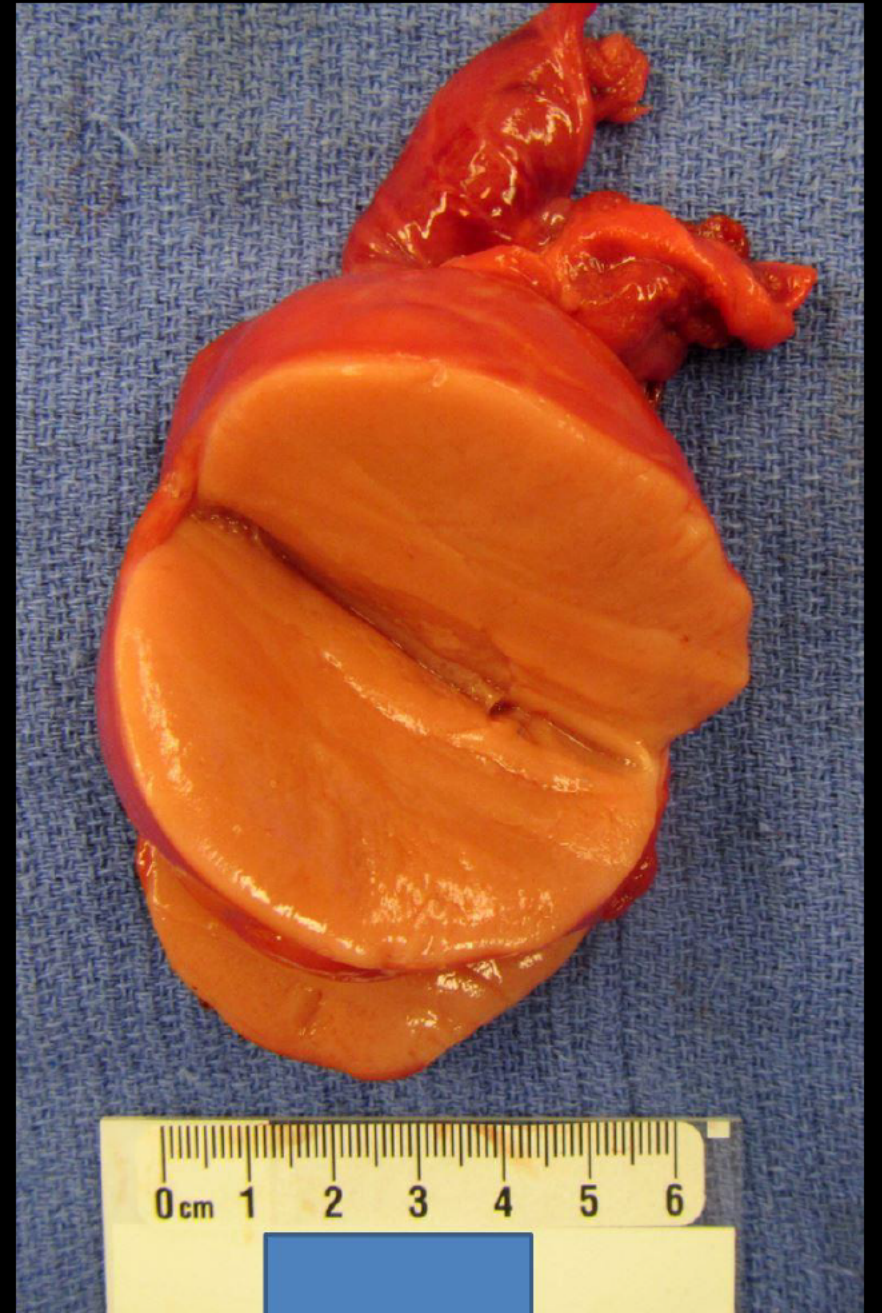
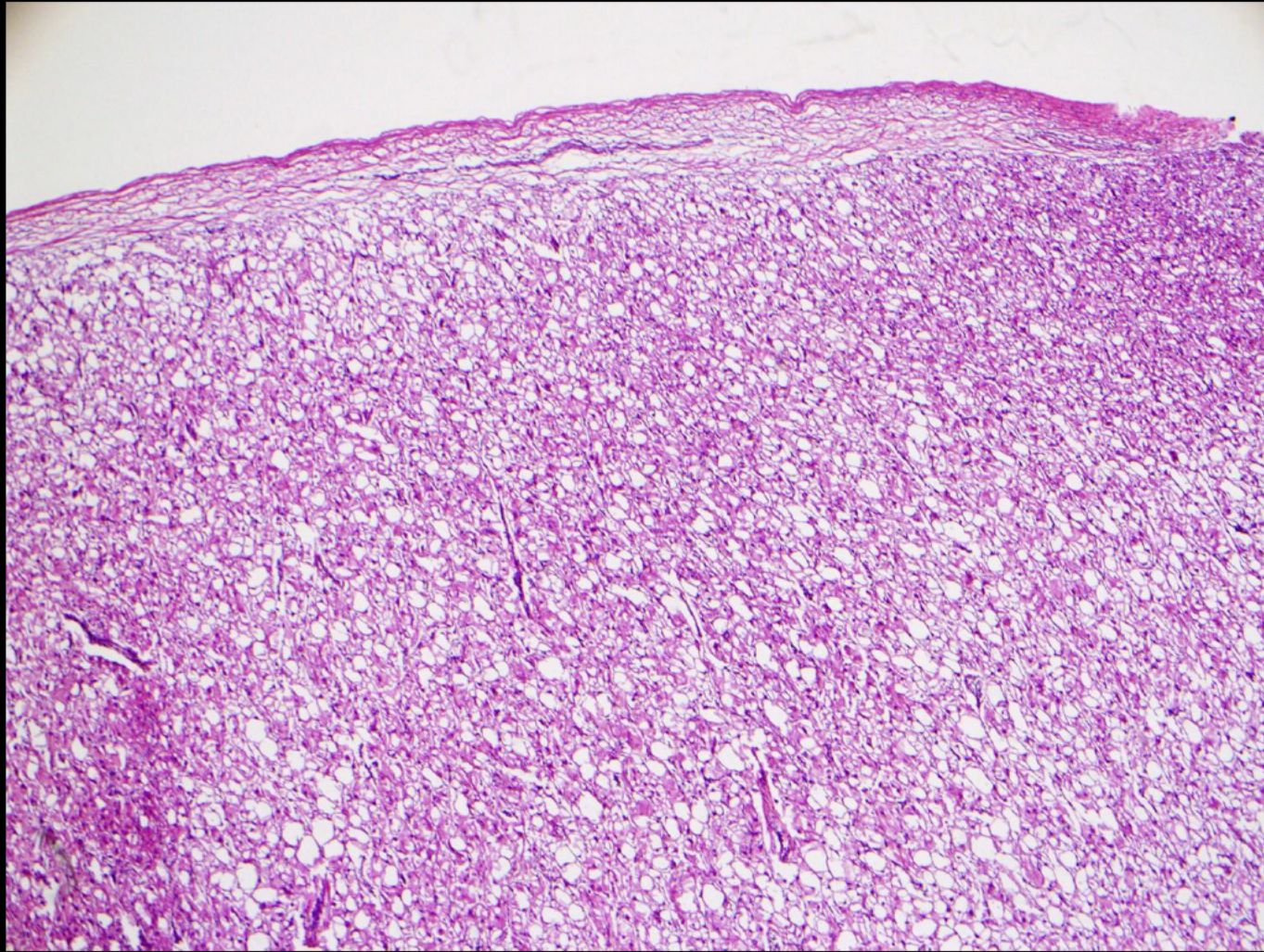
JH  
1D/M  
RT



SIEMENS  
18L6 HD  
\*Neo Abd  
General  
MI: 0.8  
44fps  
2D-- 100%  
GEN  
10.00 MHz  
6dB DR70  
ASC 5  
DTCE M  
MapC/ST1  
E2/P3  
T1/B0







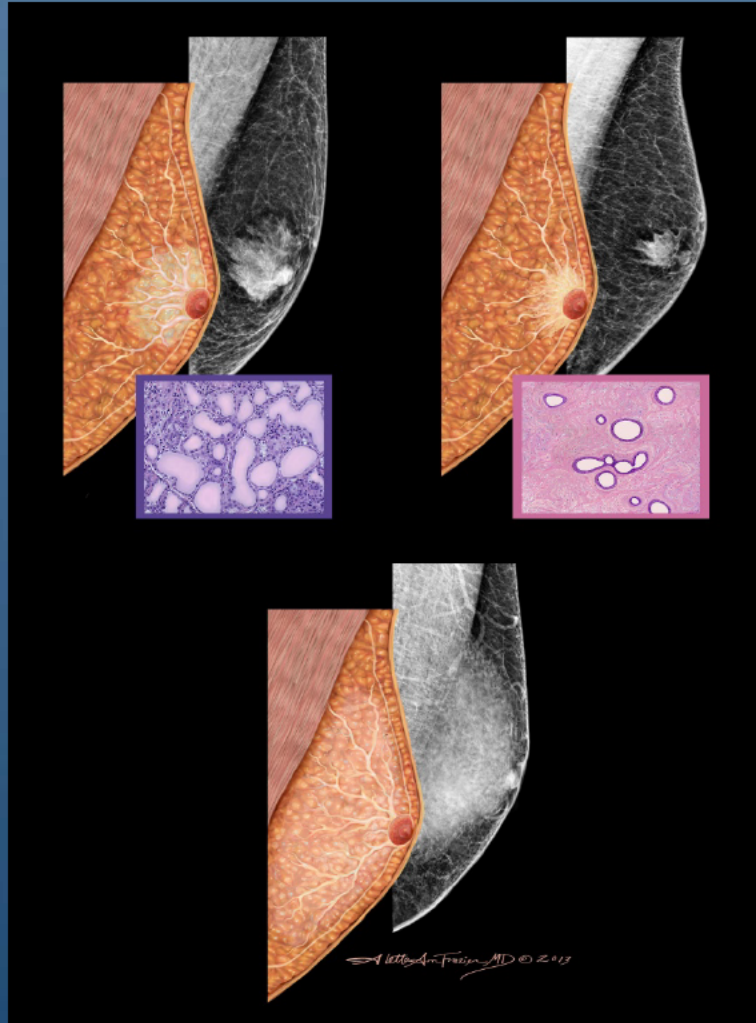


# Cardiac Rhabdomyoma

**Meaghan Magarik, M.D.**  
**Vanderbilt University**  
**Nashville, TN**



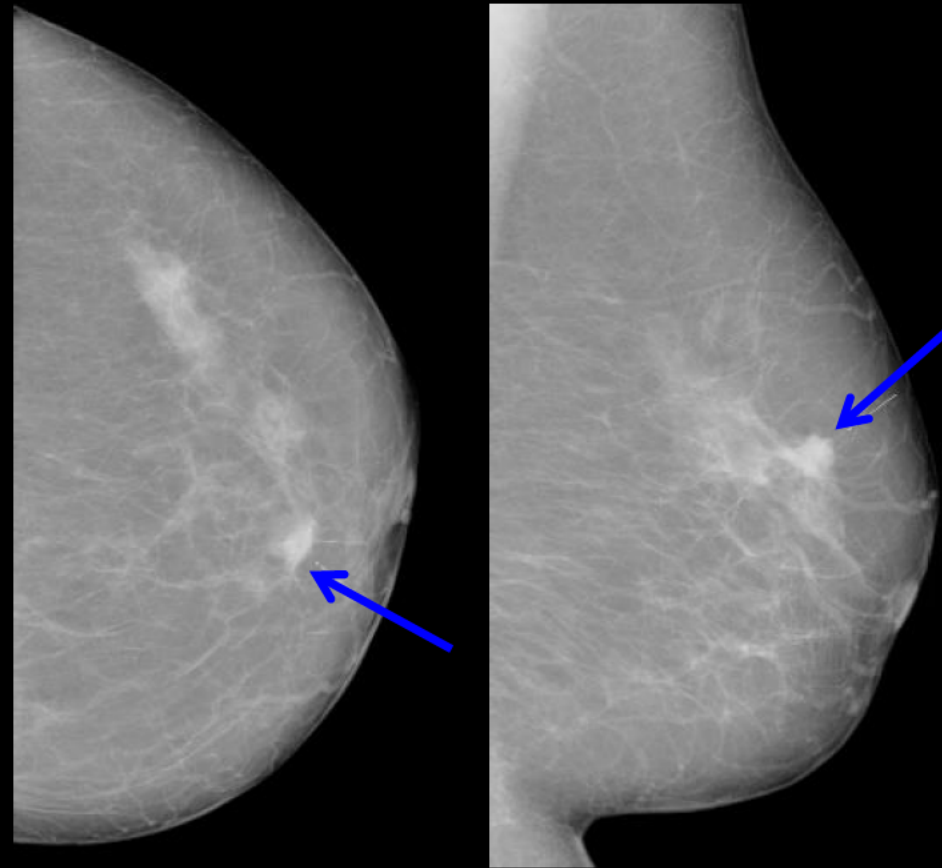
# Breast Best Case



## History

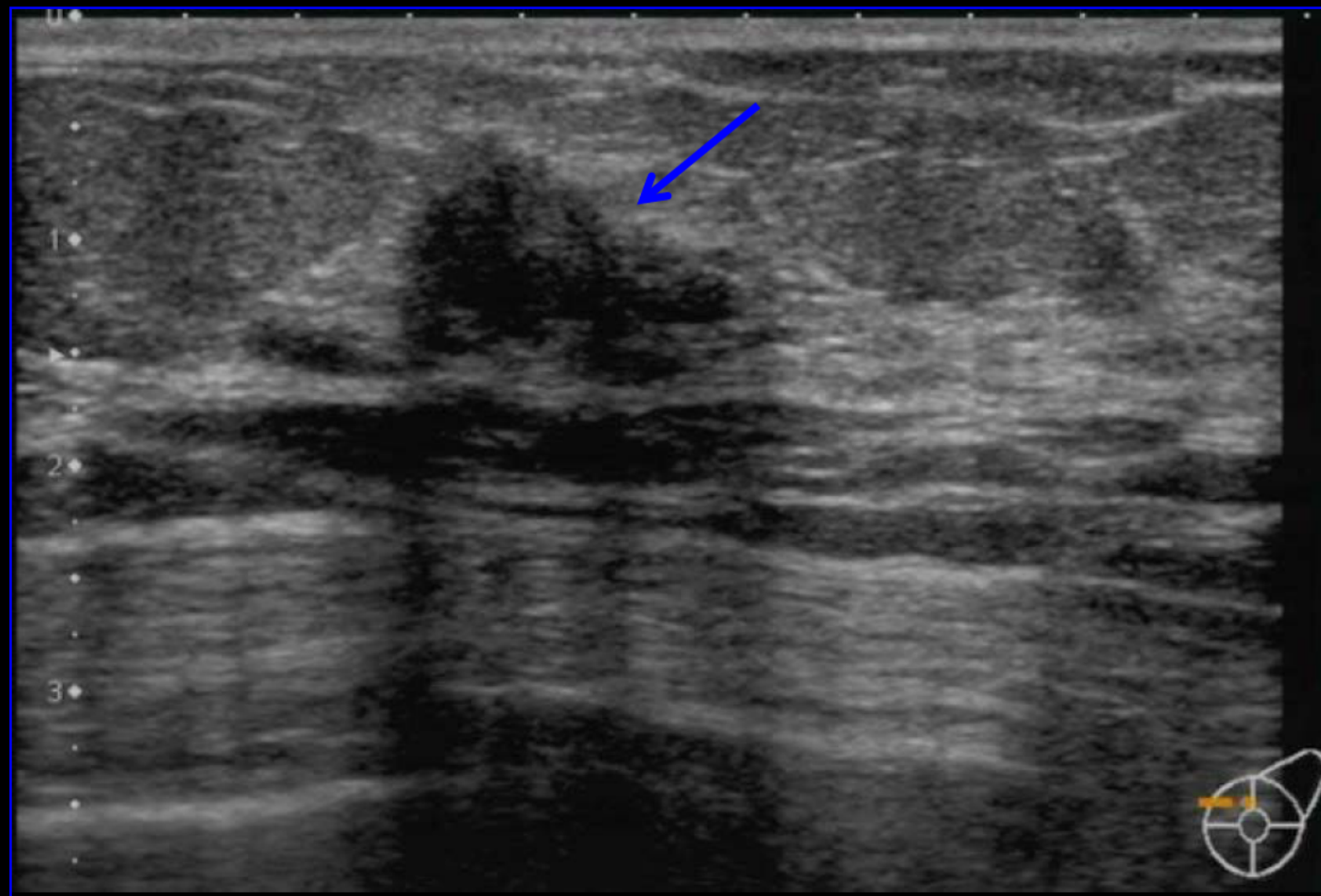
**An 83-year-old woman presented to the primary care center with a nonpainful palpable lump in the left breast and no other accompanying symptoms**

# Bilateral Mammogram

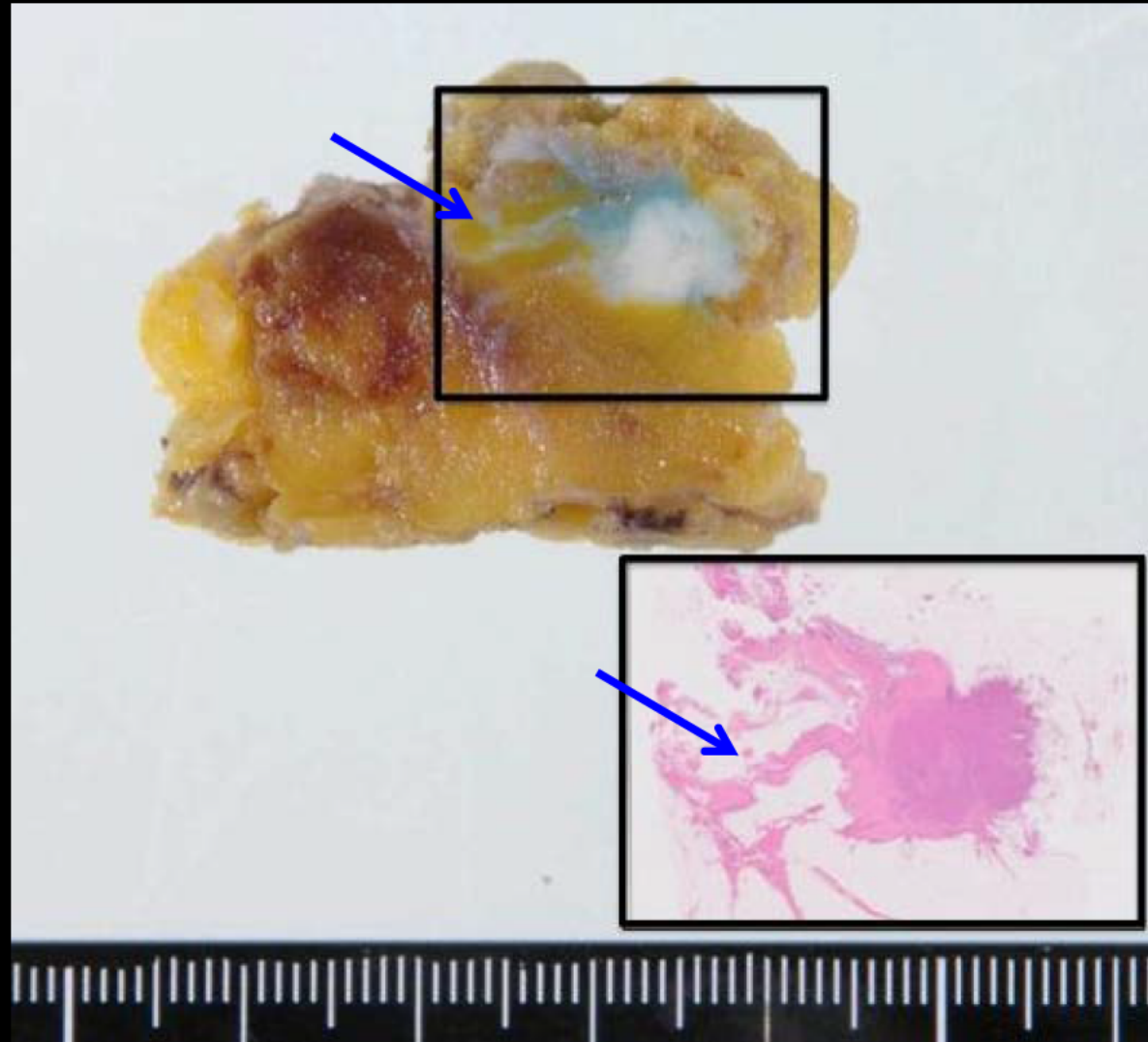




US

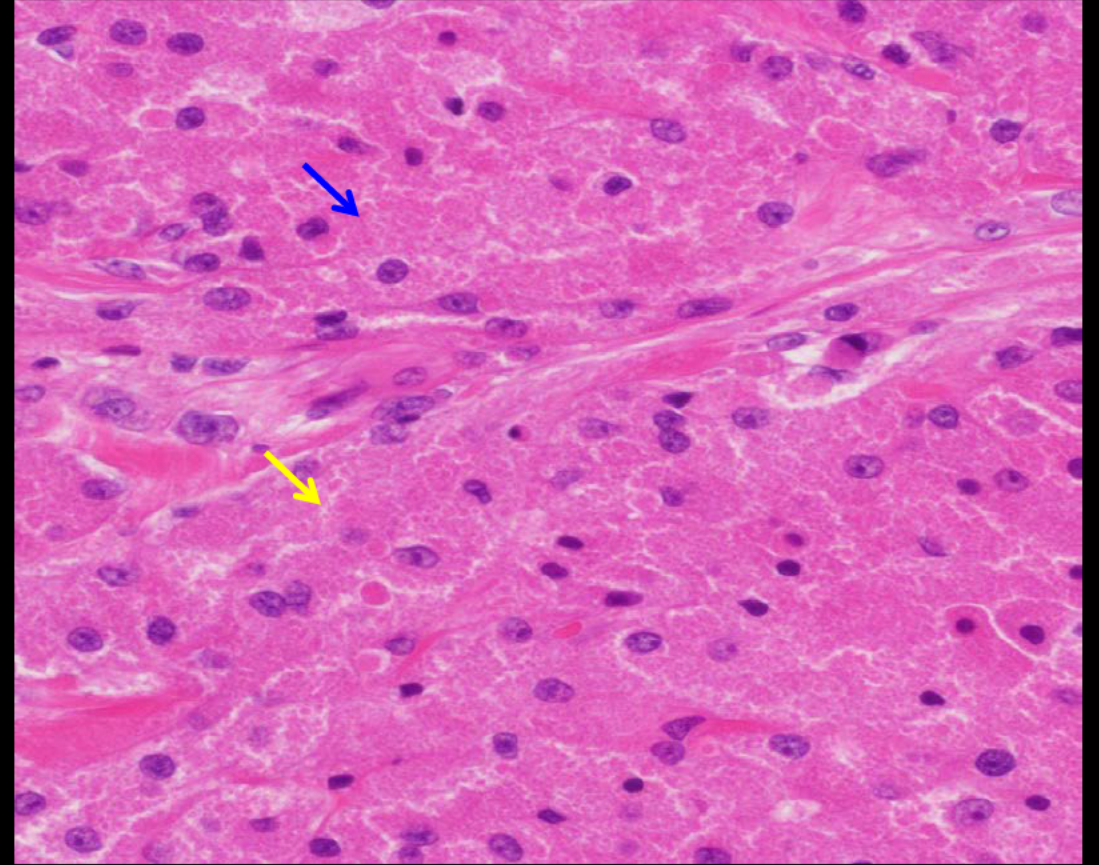
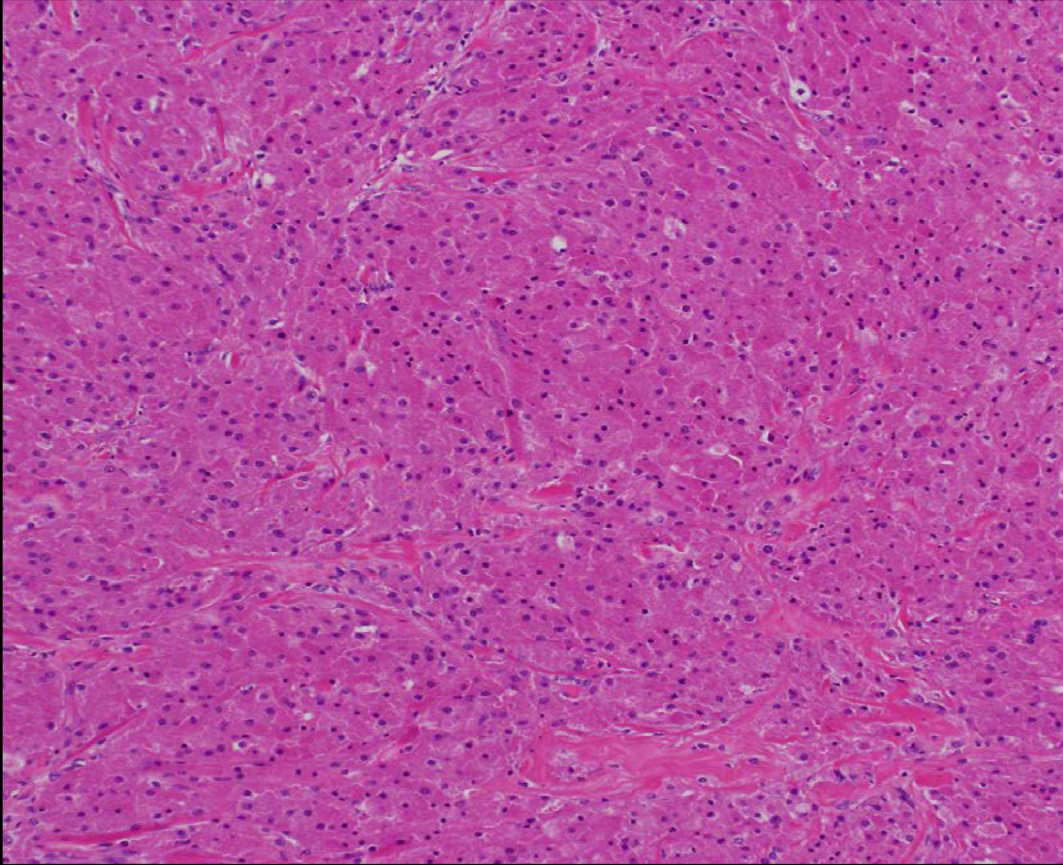


# Pathology





# Histology





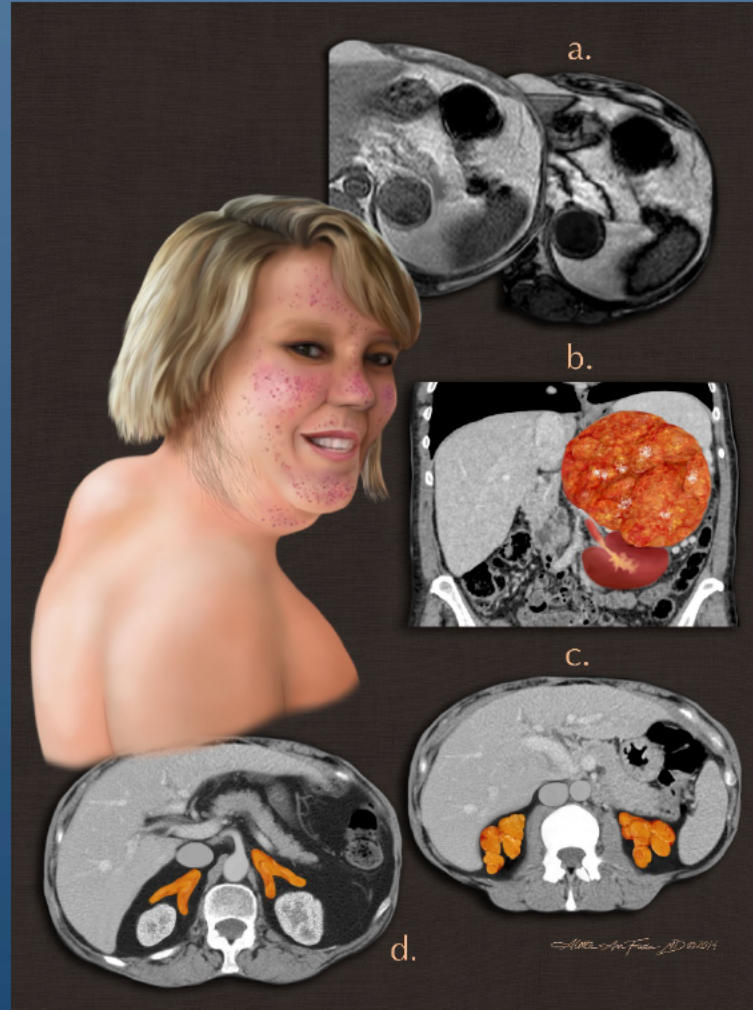# **Granular Cell Tumor**

**Keishi Fujiwara**

**St. Marianna University School of Medicine**

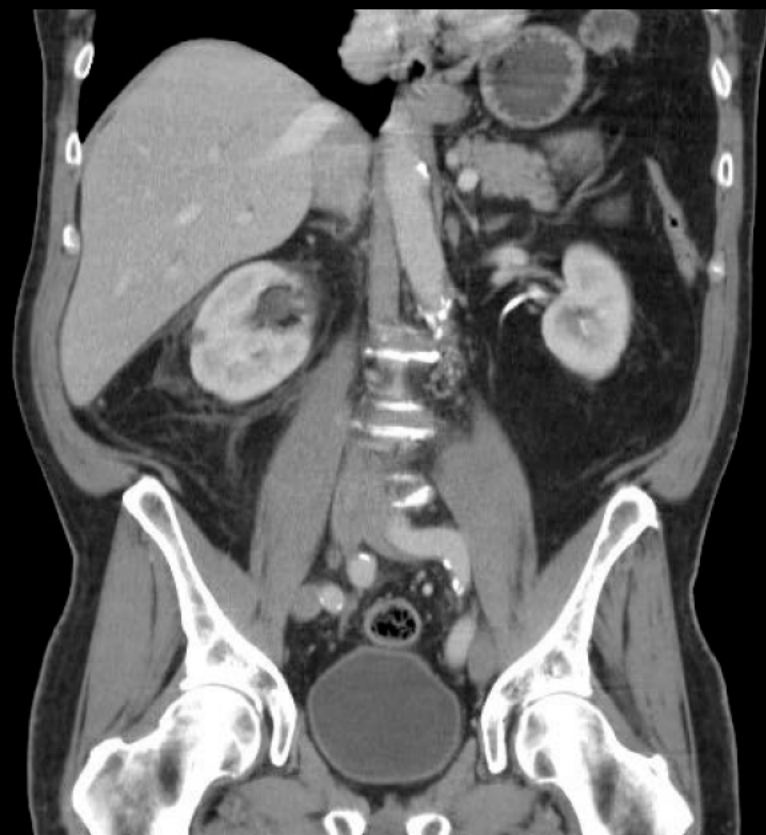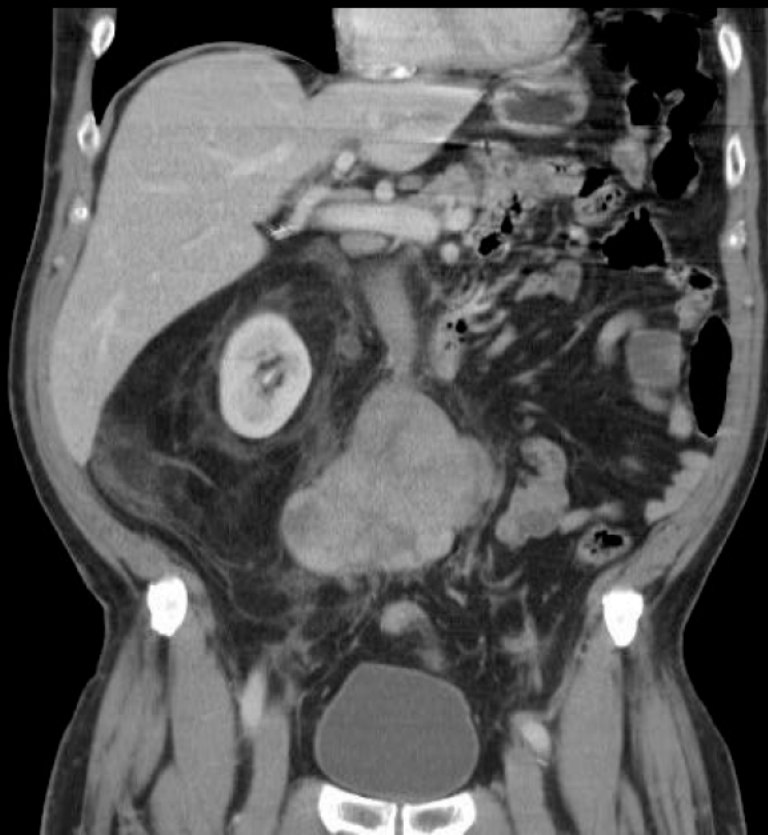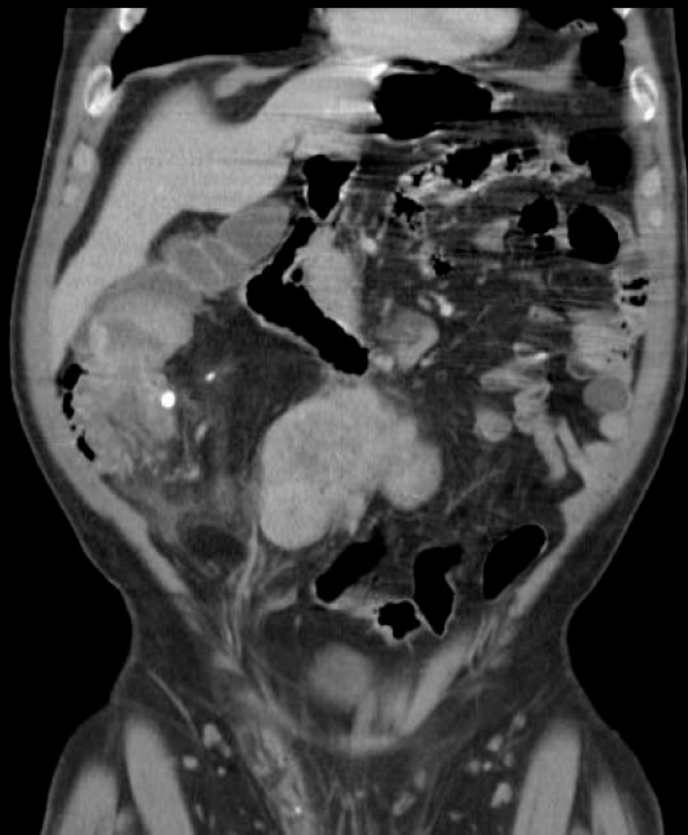
**Kawasaki, Japan**

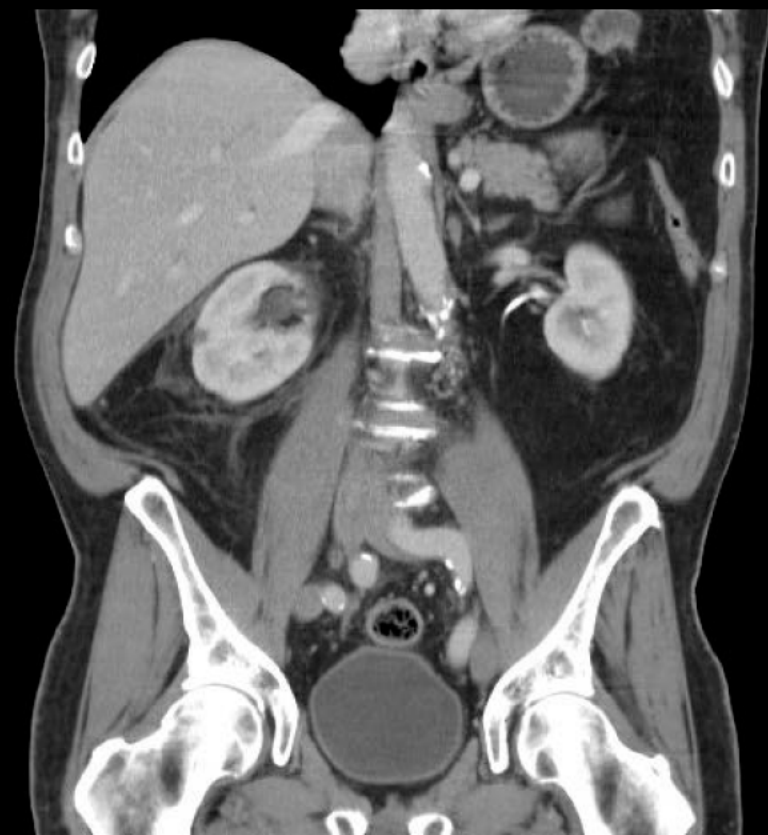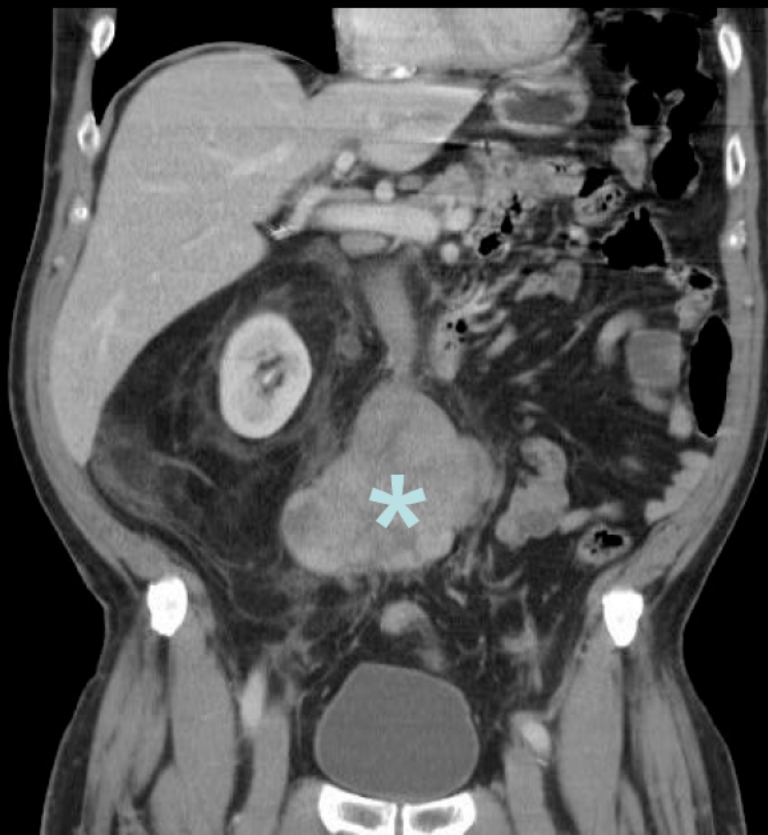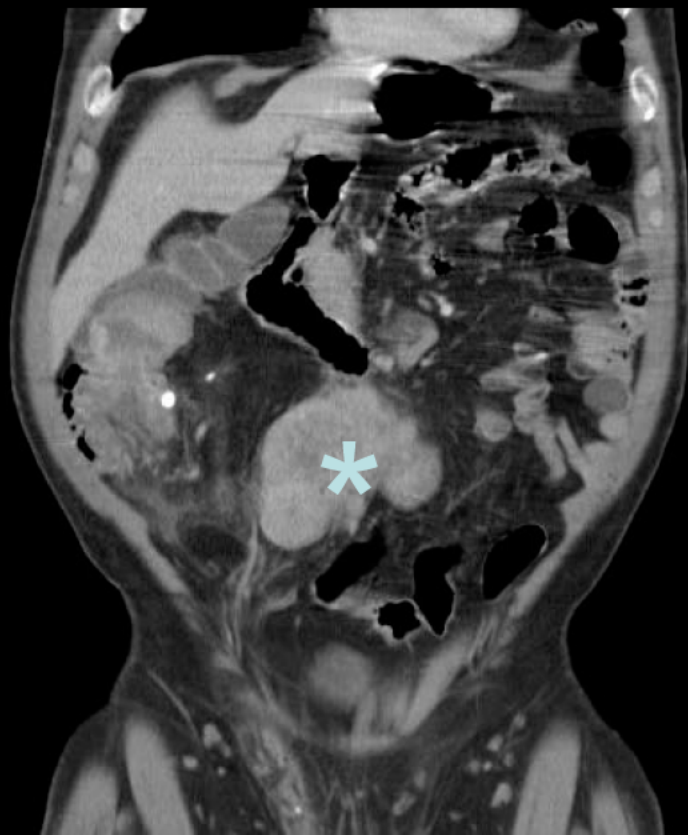
# Genitourinary Best Case

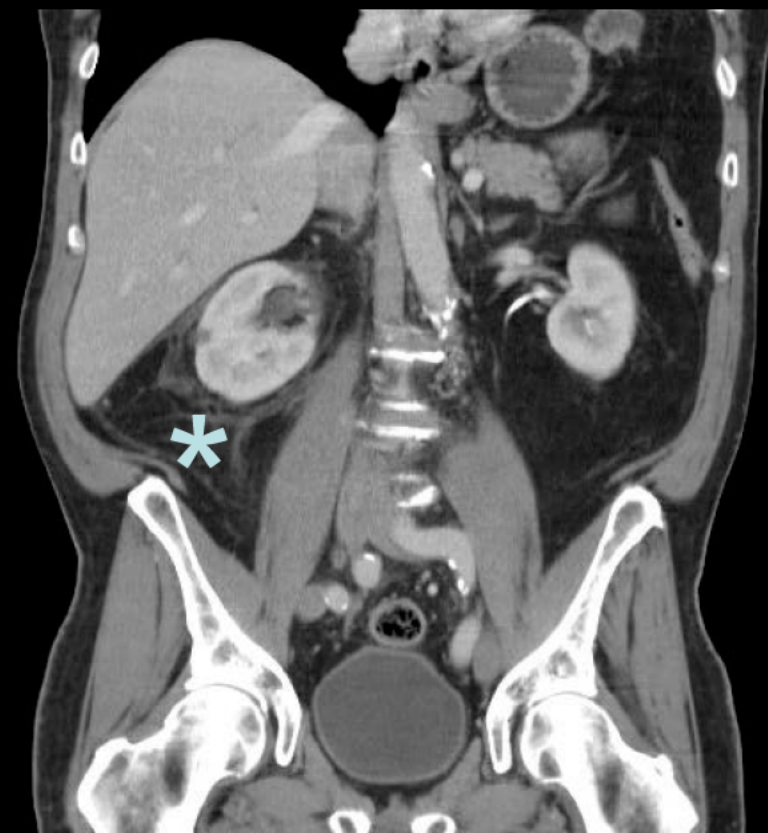
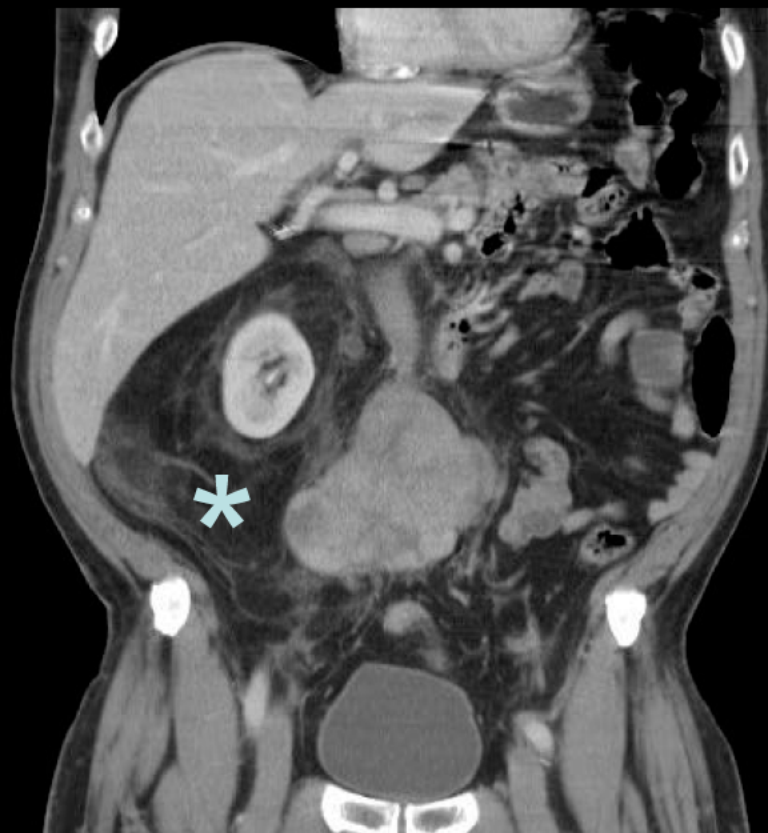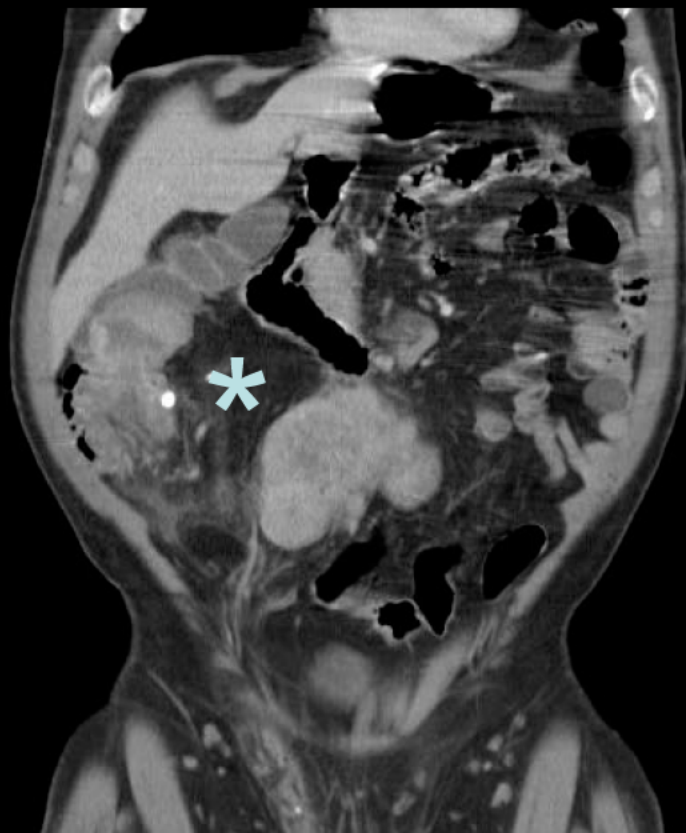


**69 yo male with PMH of CAD s/p cardiac stents, hyperlipidemia, and HTN who presented to his PCP with abdominal bloating.**

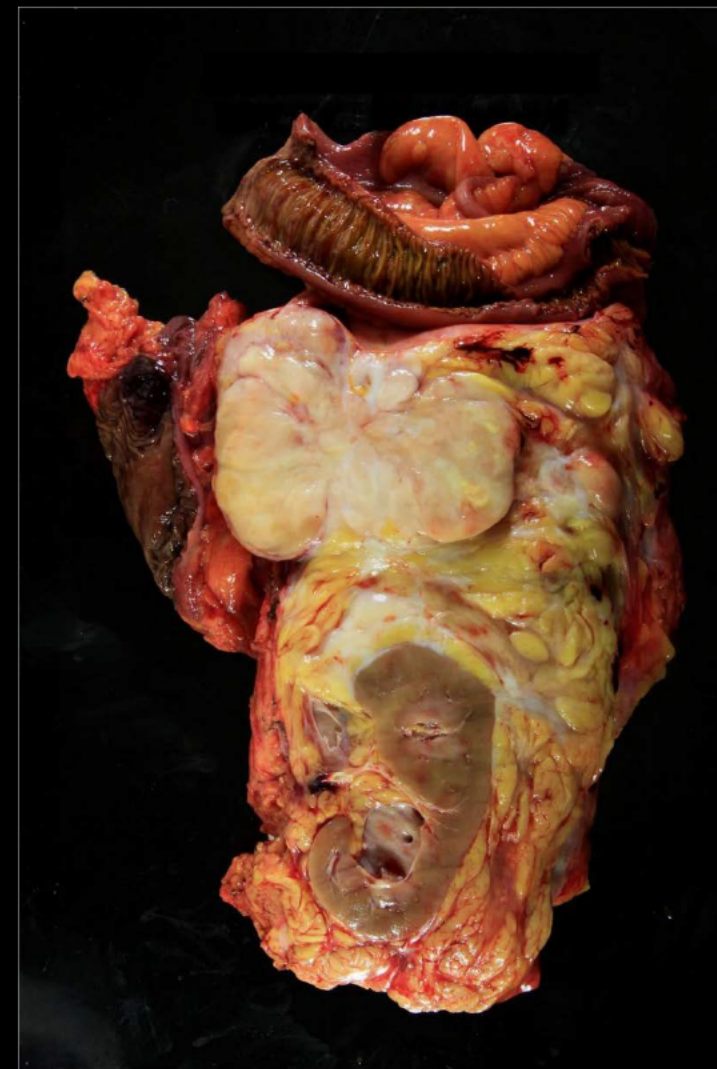
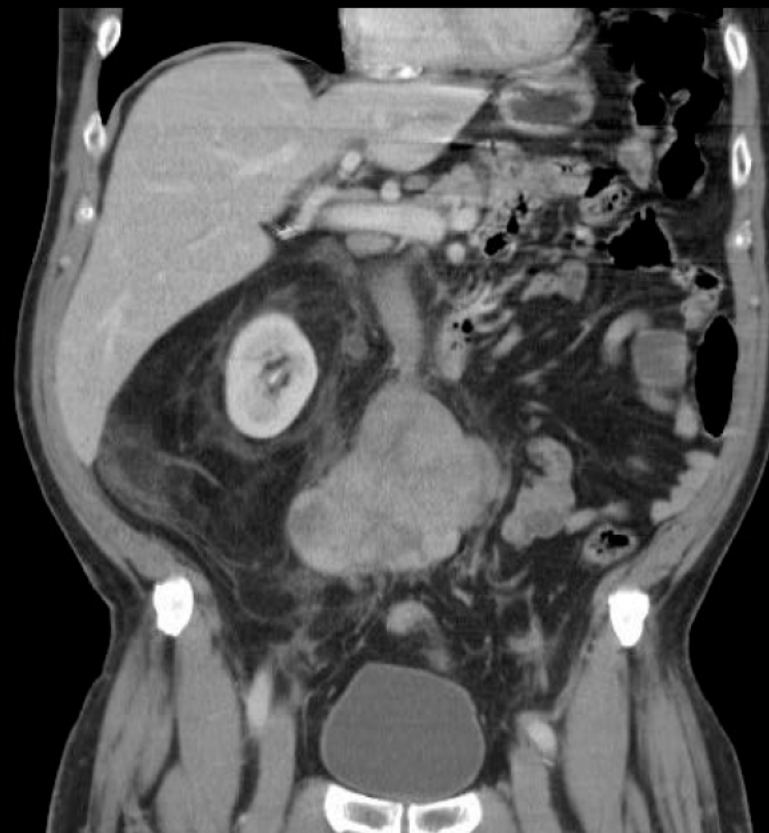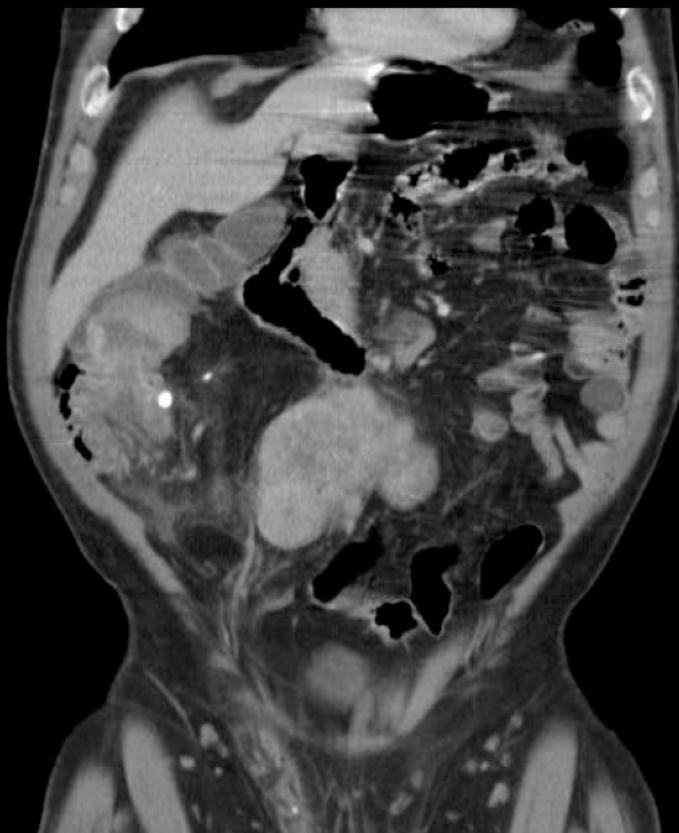


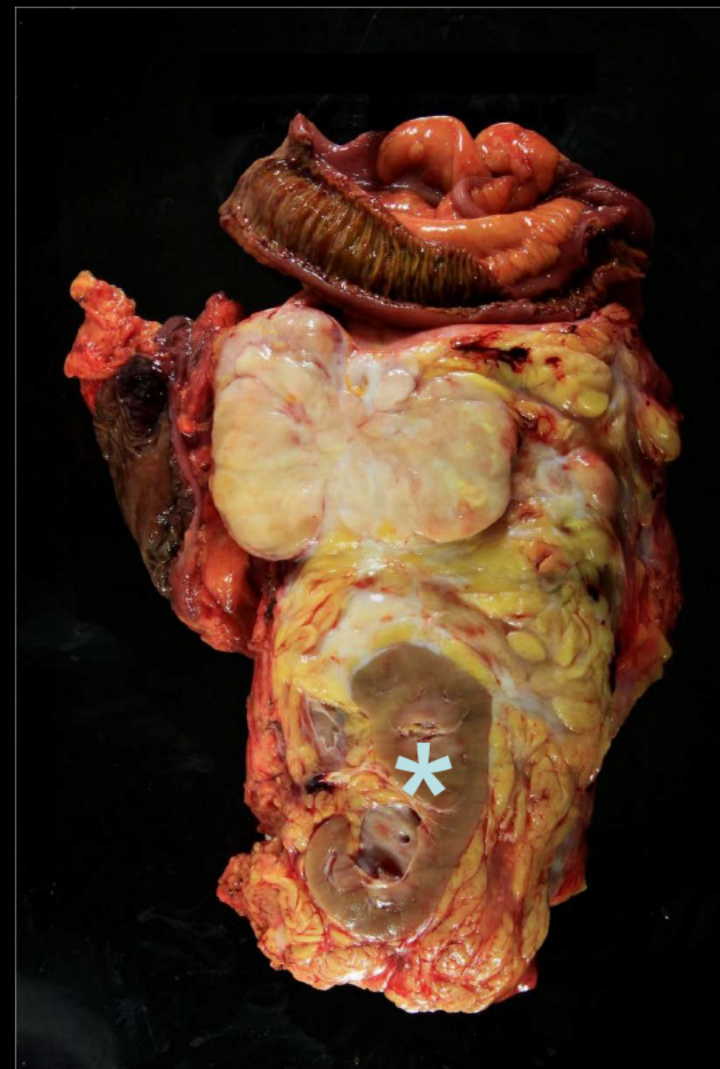
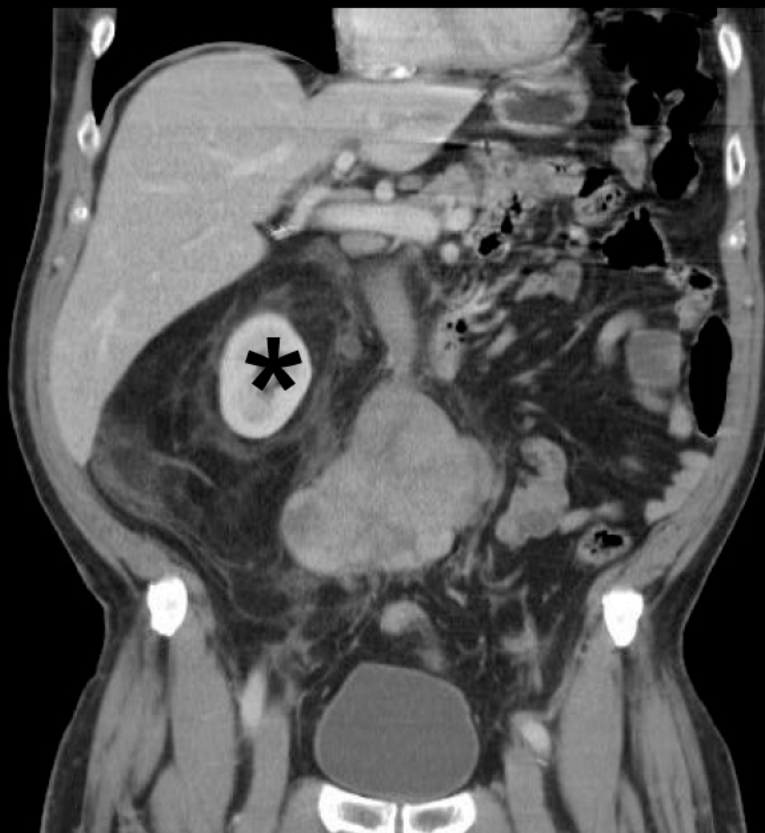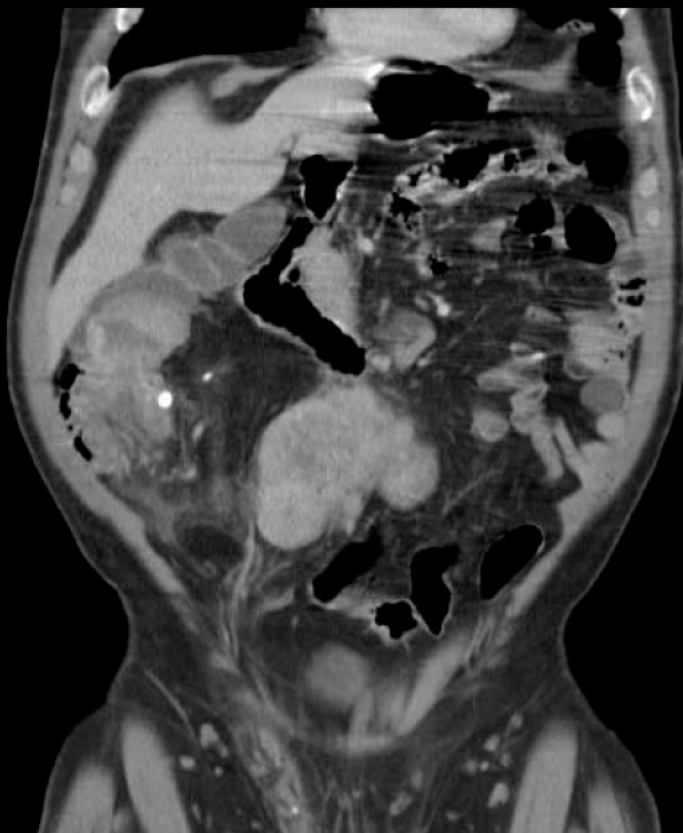




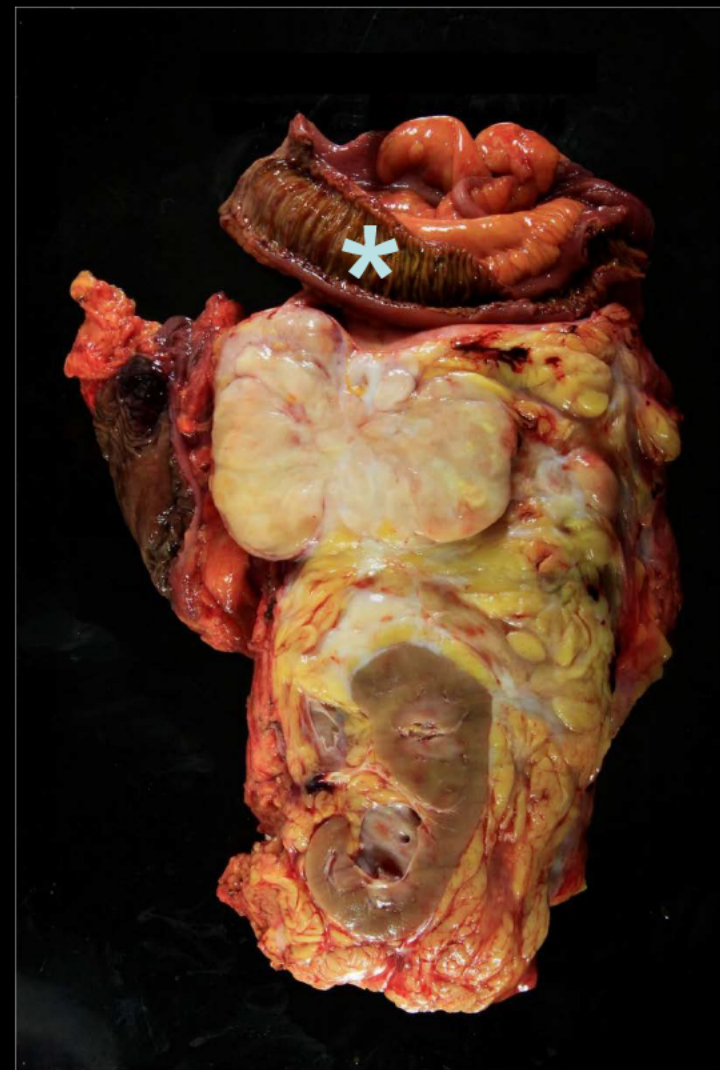
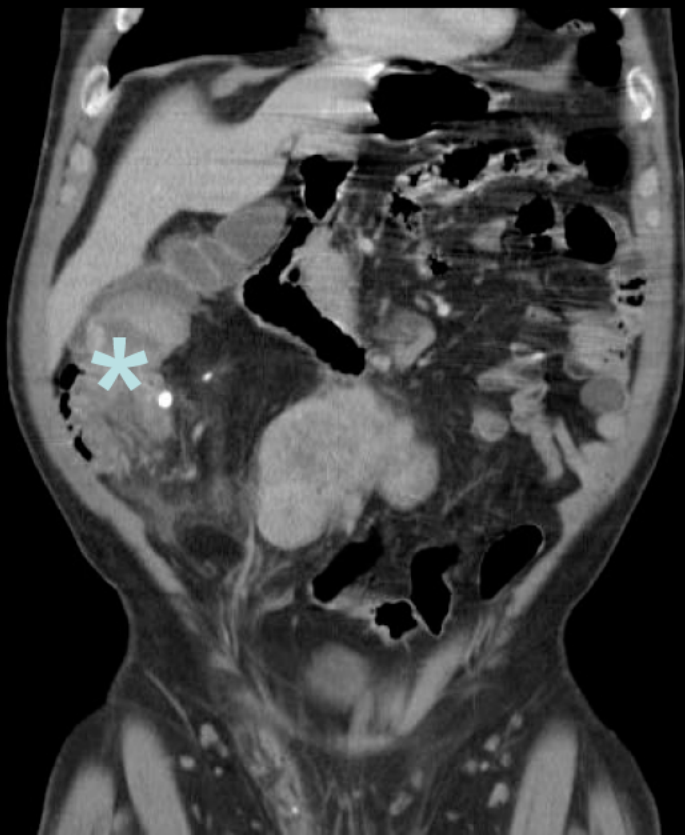




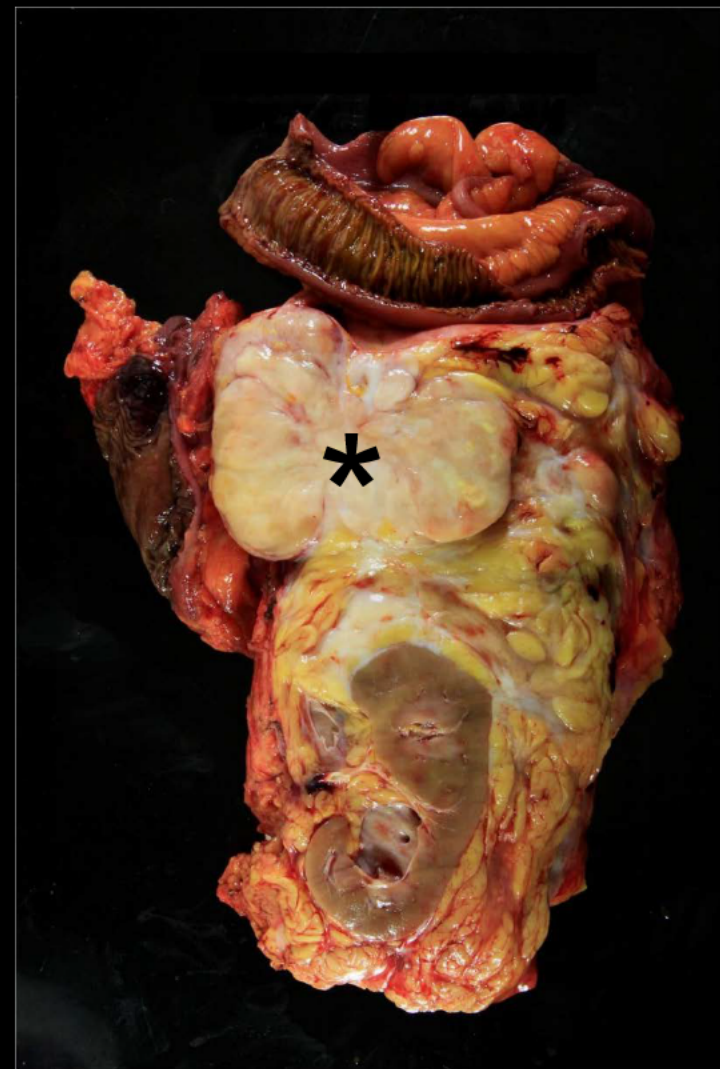
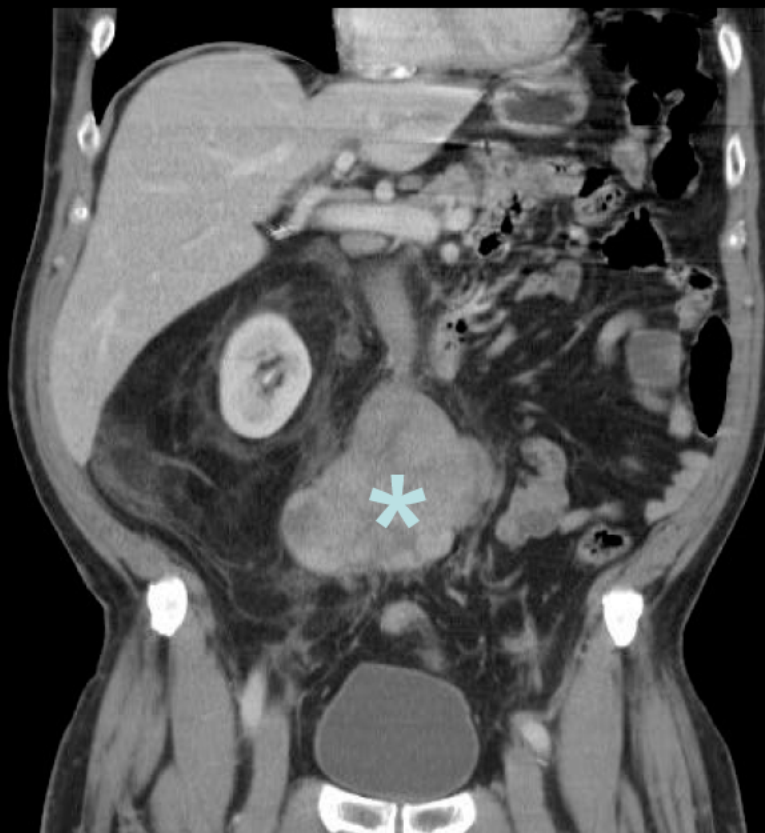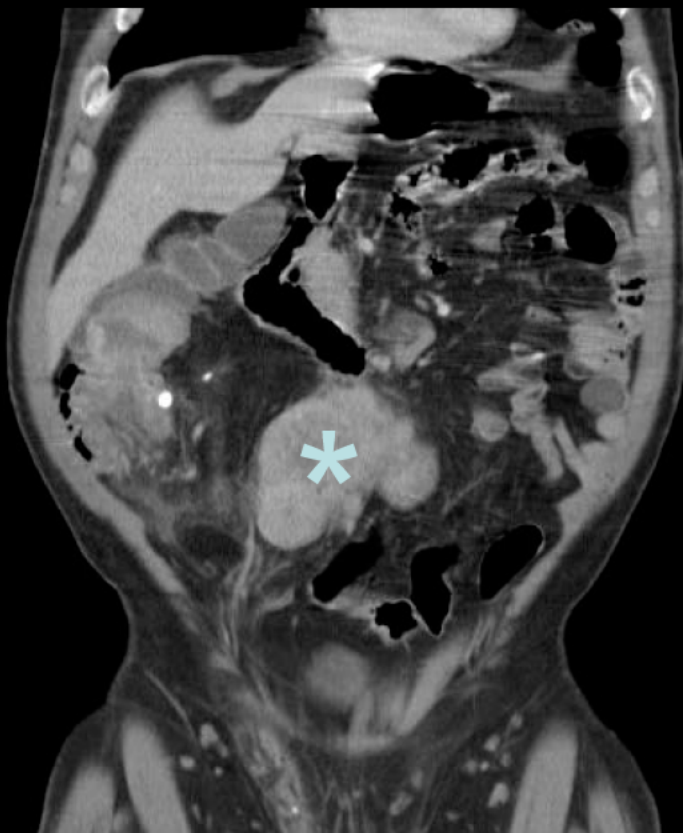


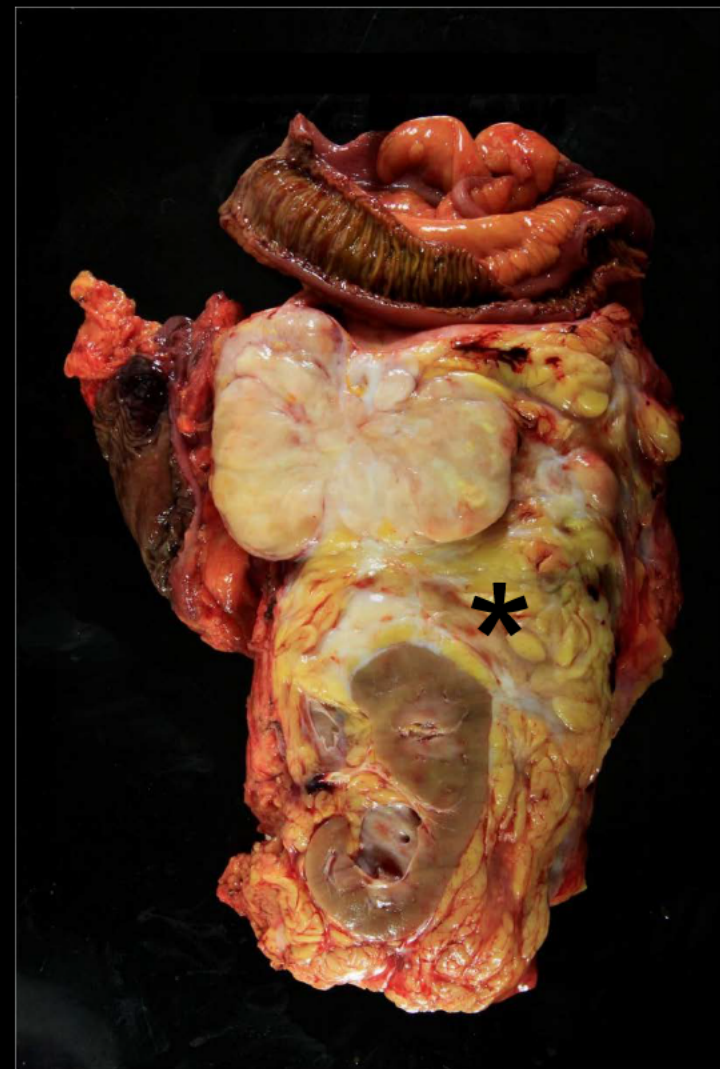
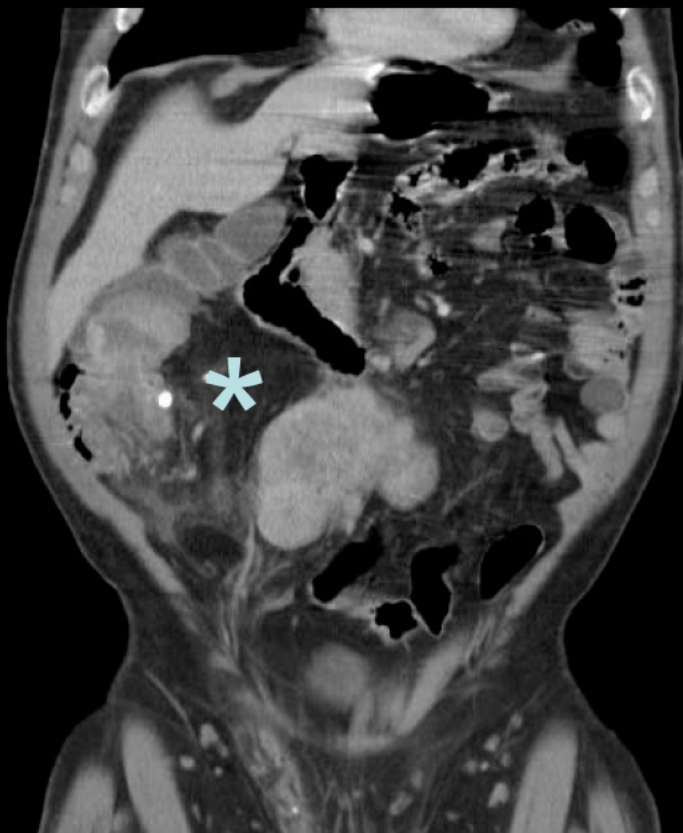




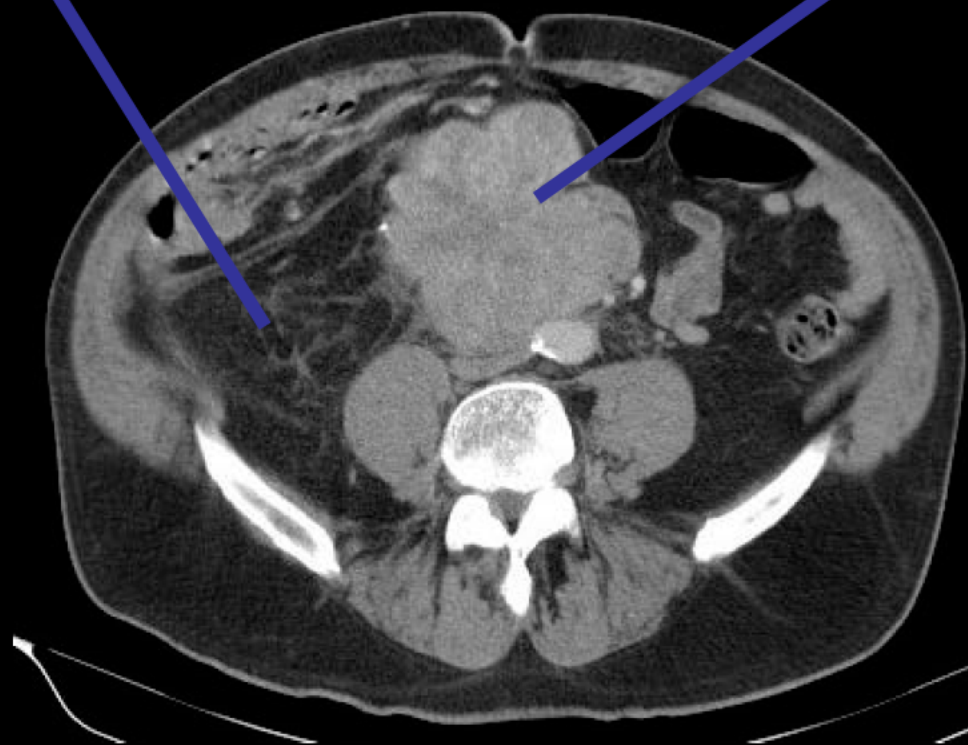
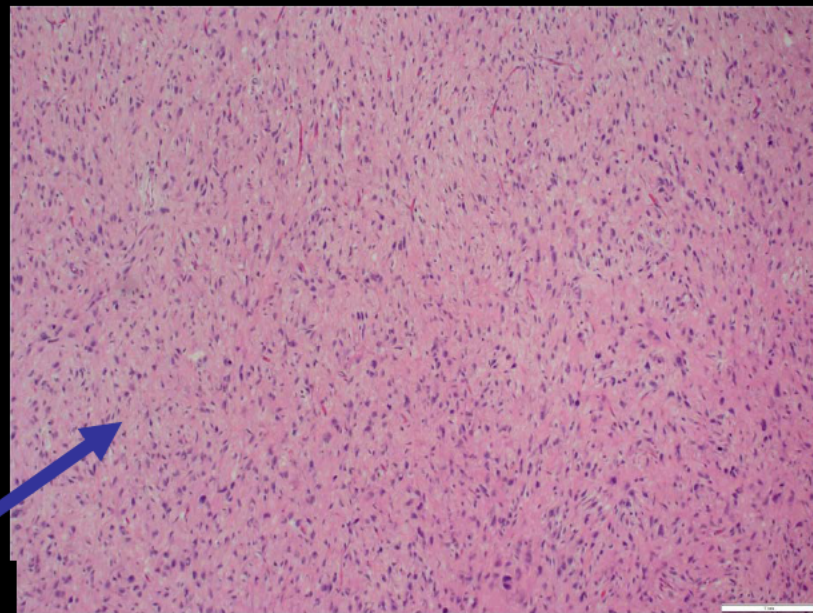
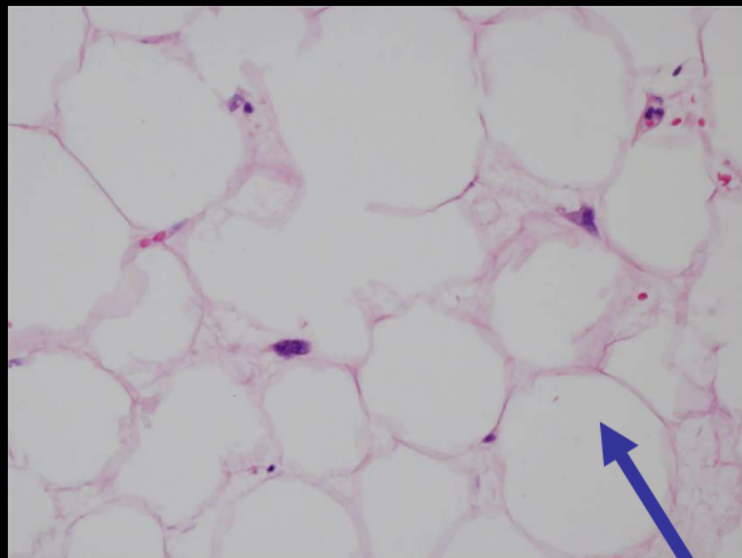














# **Retroperitoneal Liposarcoma**

**Weier Li, MD**

**Massachusetts General Hospital**

**Boston, MA**