

Best Cases of the AIRP

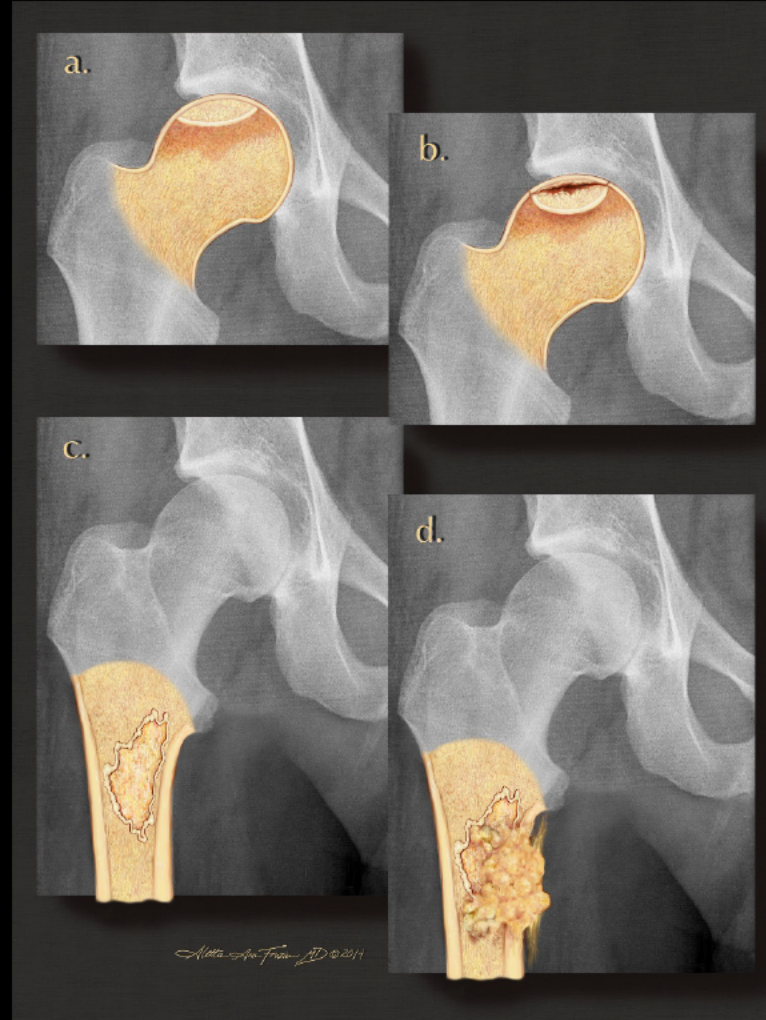
September-October, 2020

AIRPTM

AMERICAN INSTITUTE FOR
RADIOLOGIC PATHOLOGY

A PROGRAM OF THE
AMERICAN COLLEGE OF RADIOLOGY

Musculoskeletal Best Case



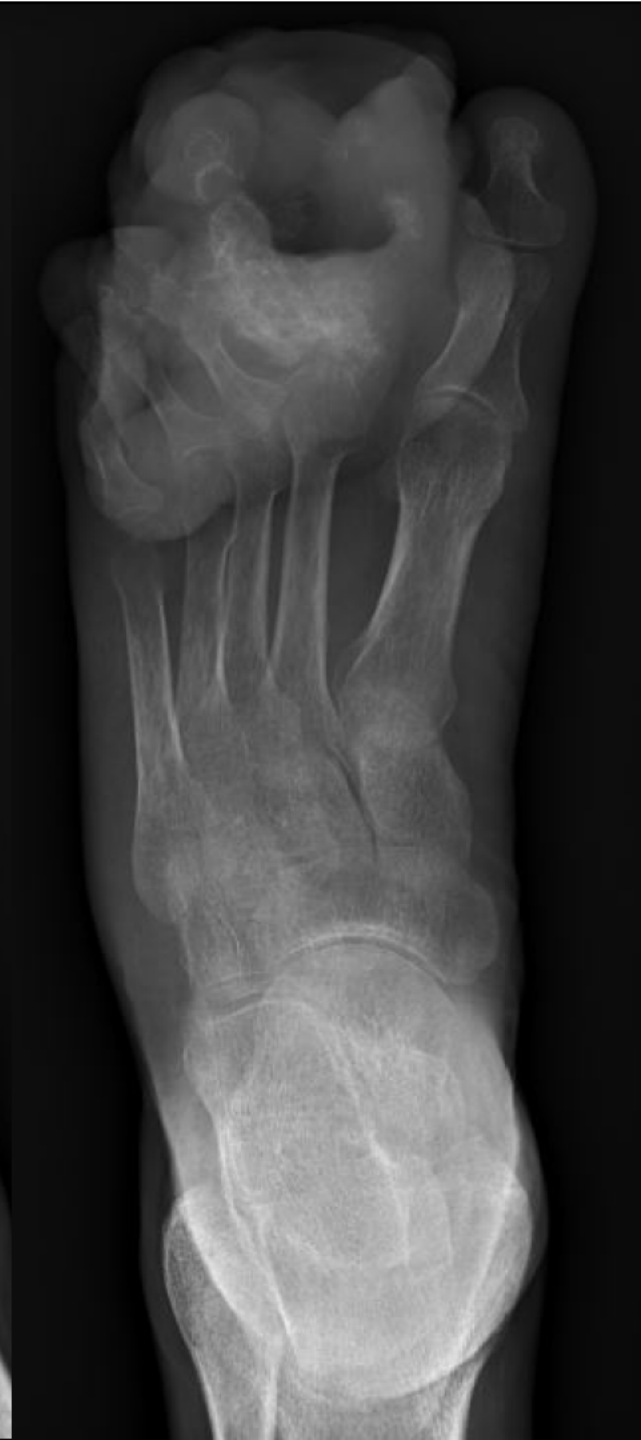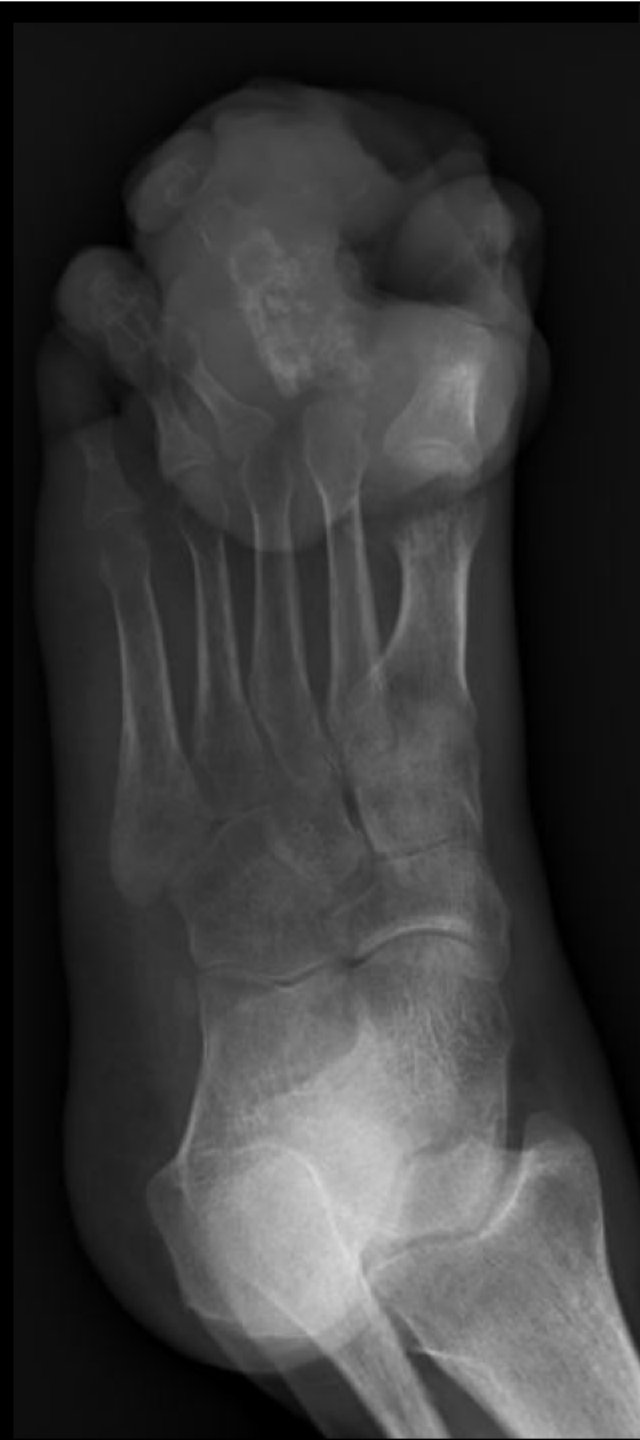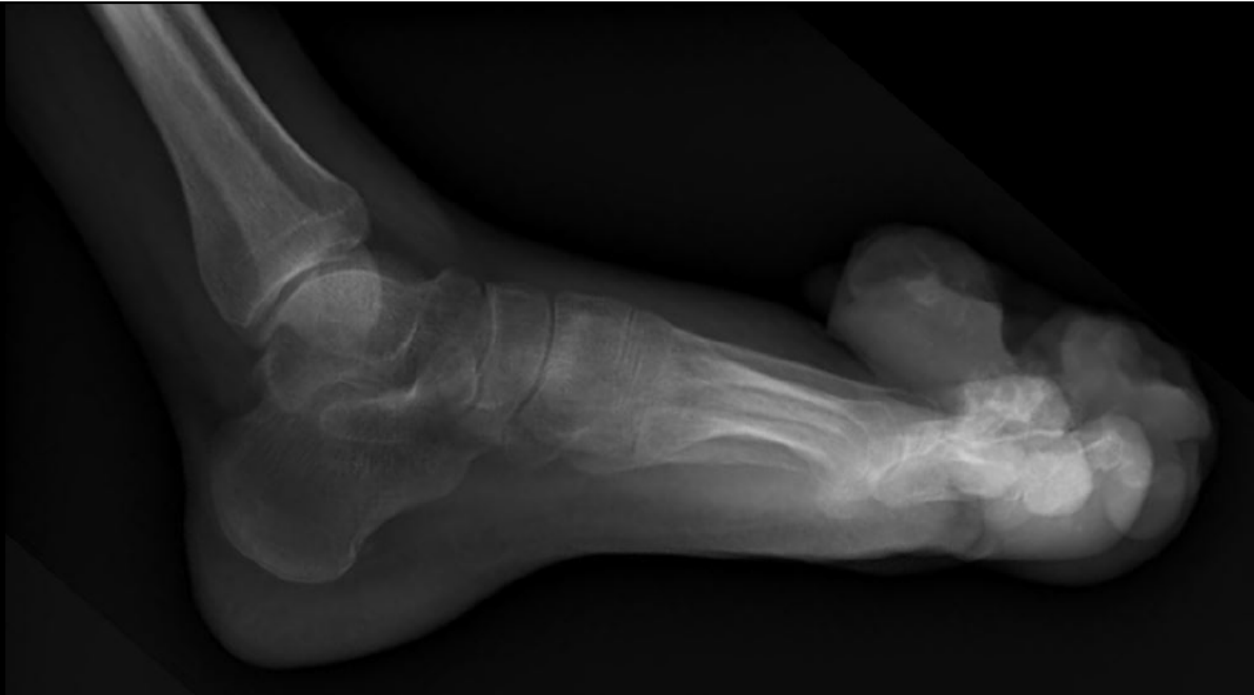AIRPTM

AMERICAN INSTITUTE FOR
RADIOLOGIC PATHOLOGY

A PROGRAM OF THE
AMERICAN COLLEGE OF RADIOLOGY

CLINICAL INFORMATION

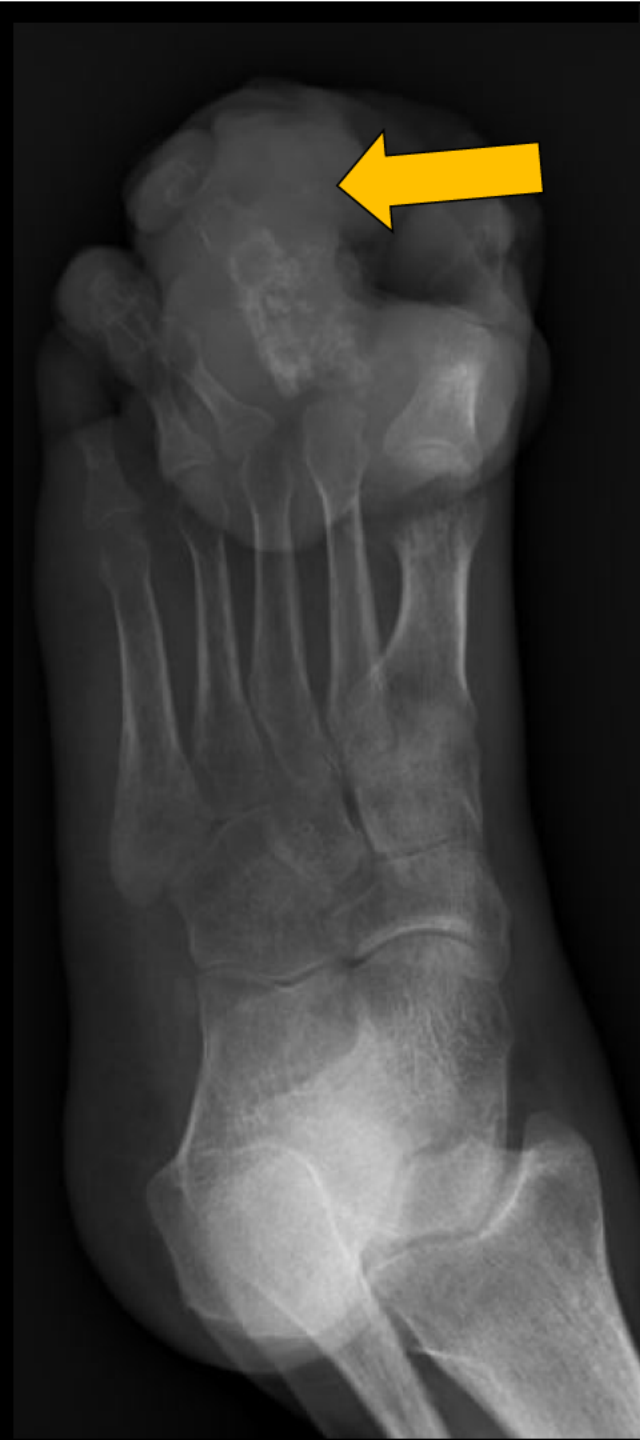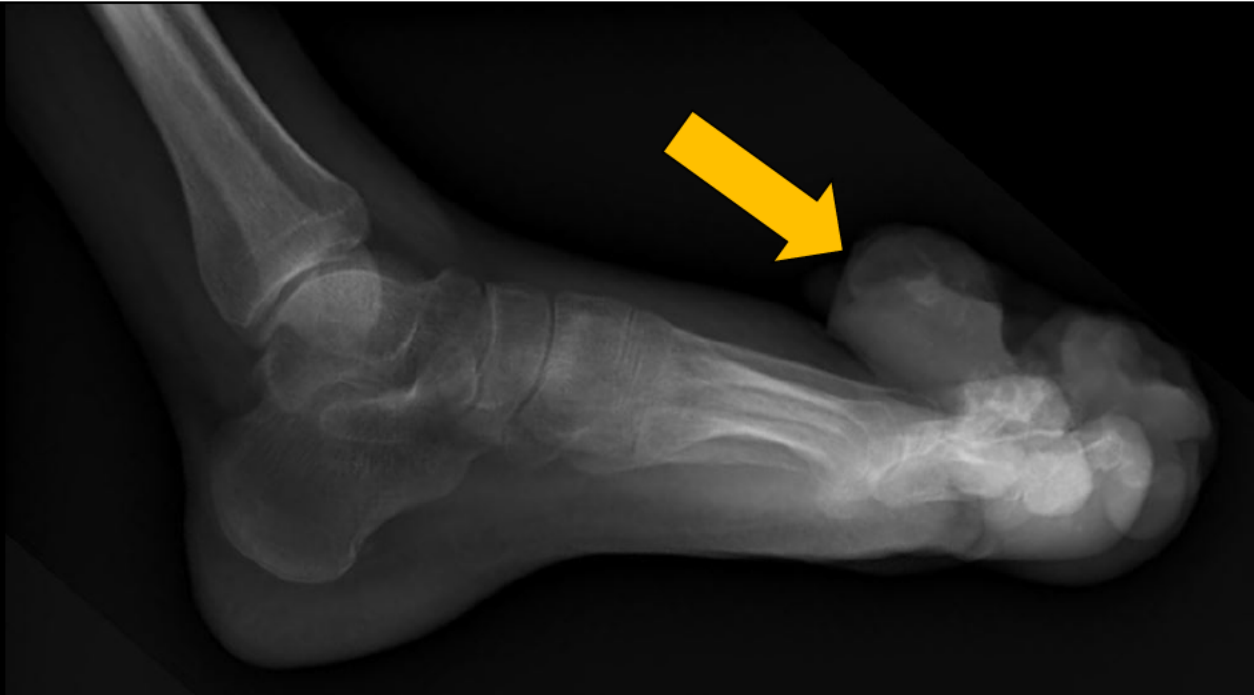52-year-old male with a fungating left foot soft tissue mass with purulent drainage



AIRPTM

AMERICAN INSTITUTE FOR
RADIOLOGIC PATHOLOGY

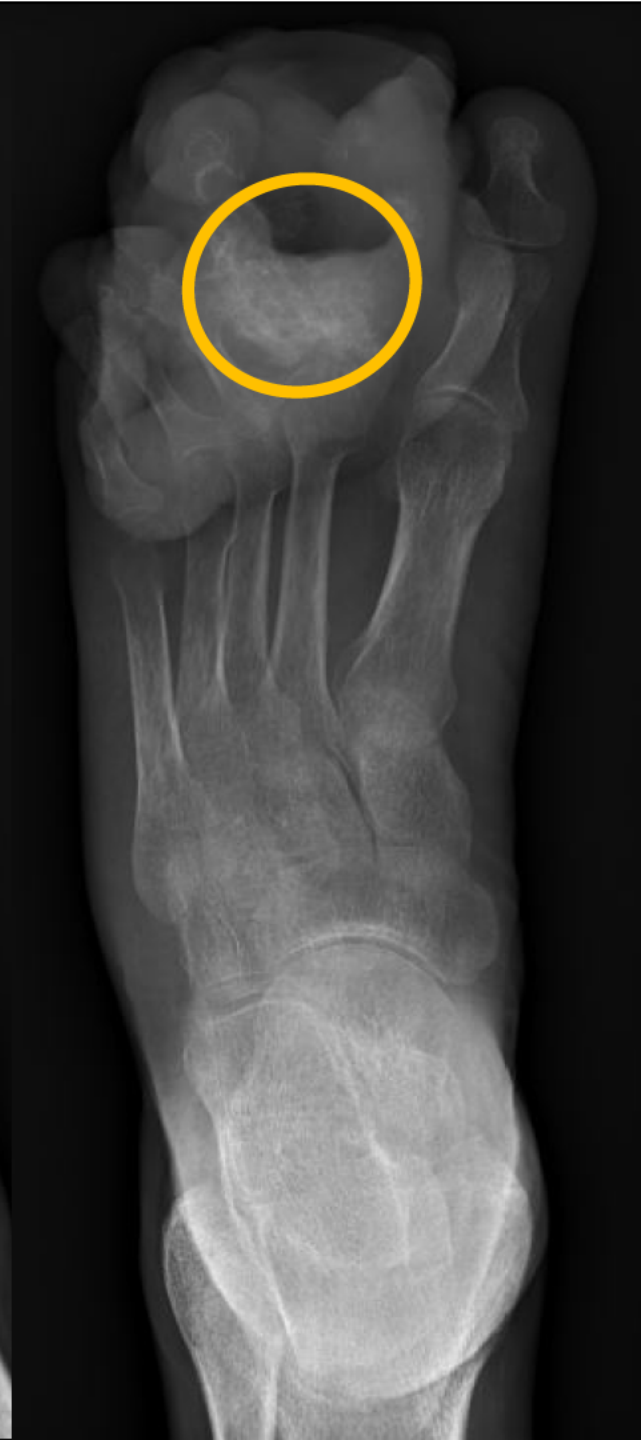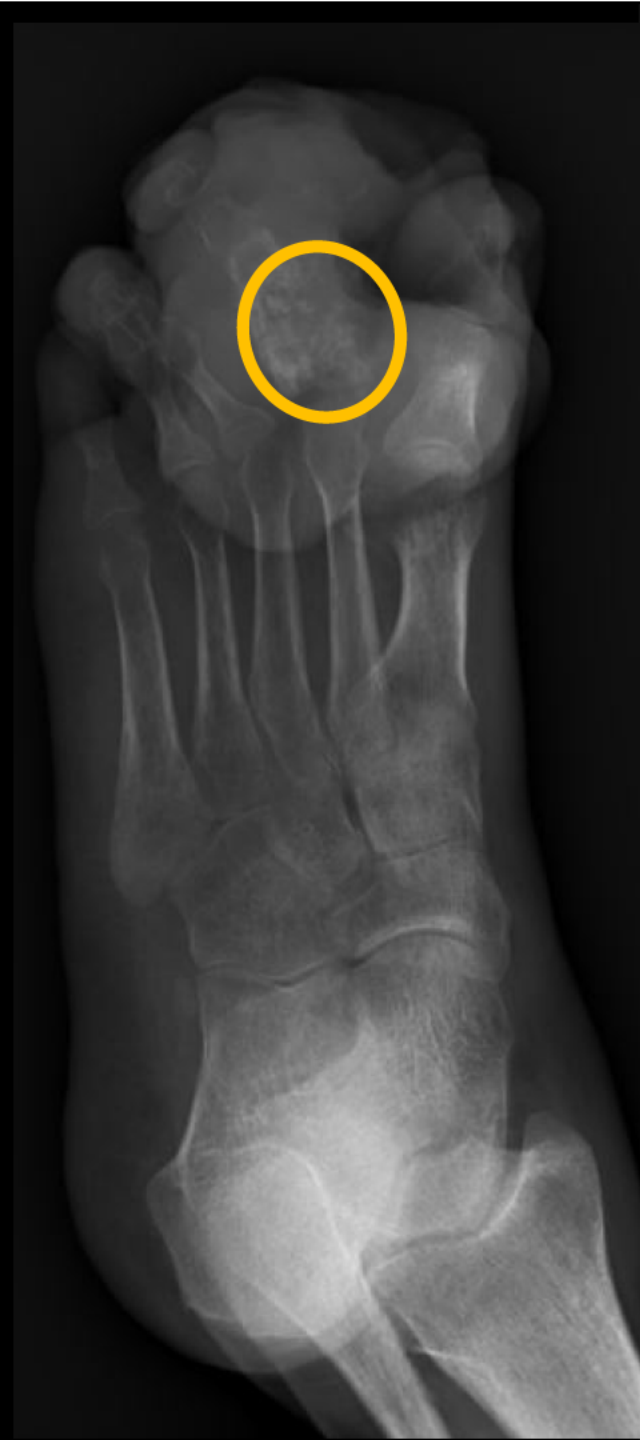A PROGRAM OF THE
AMERICAN COLLEGE OF RADIOLOGY



AIRPTM

AMERICAN INSTITUTE FOR
RADIOLOGIC PATHOLOGY

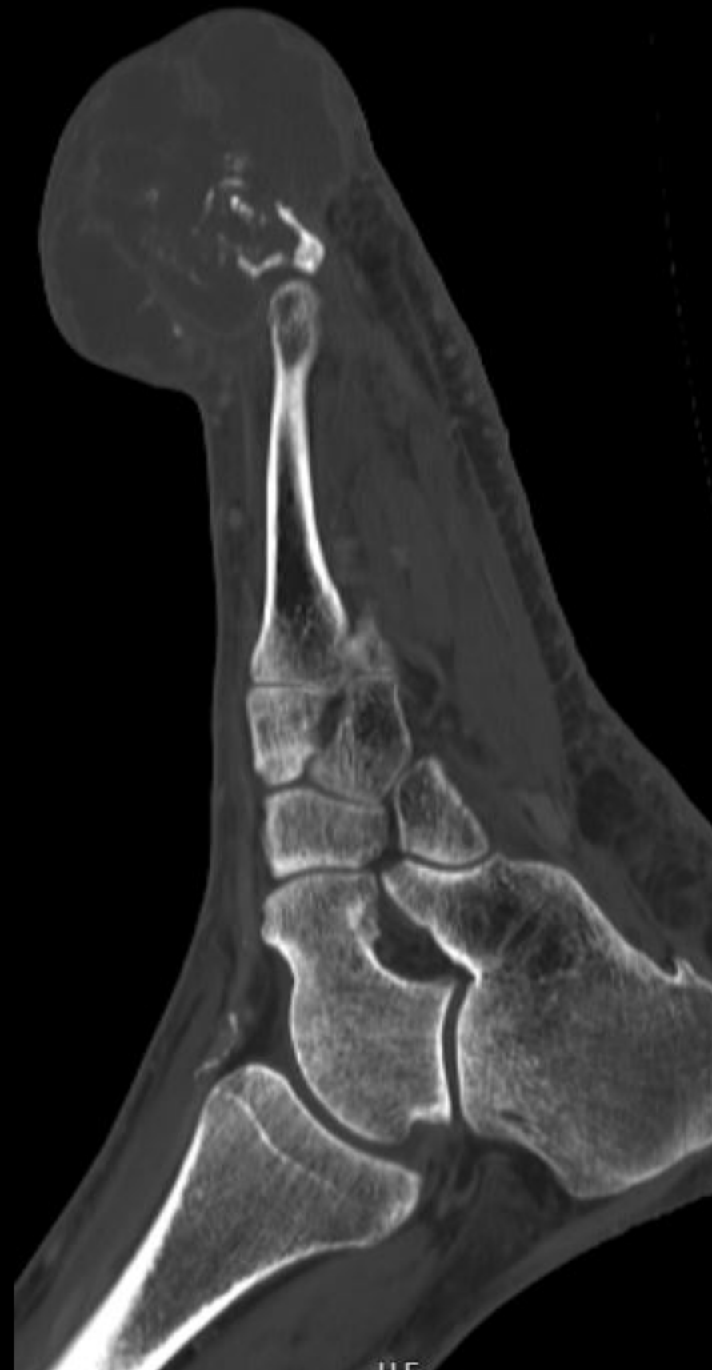
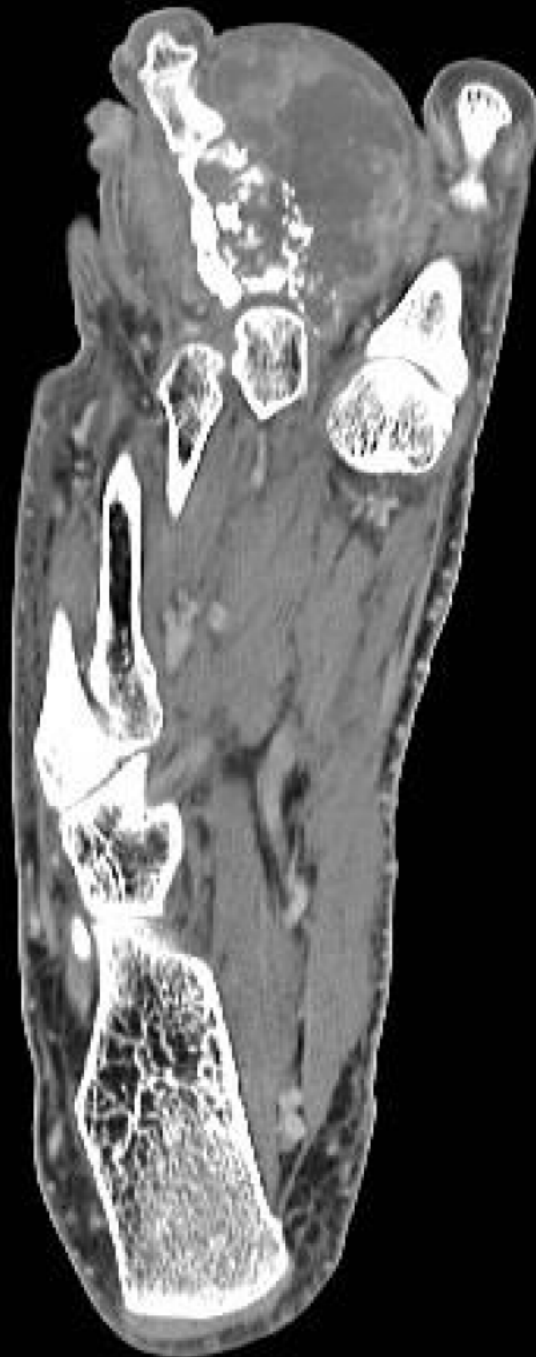
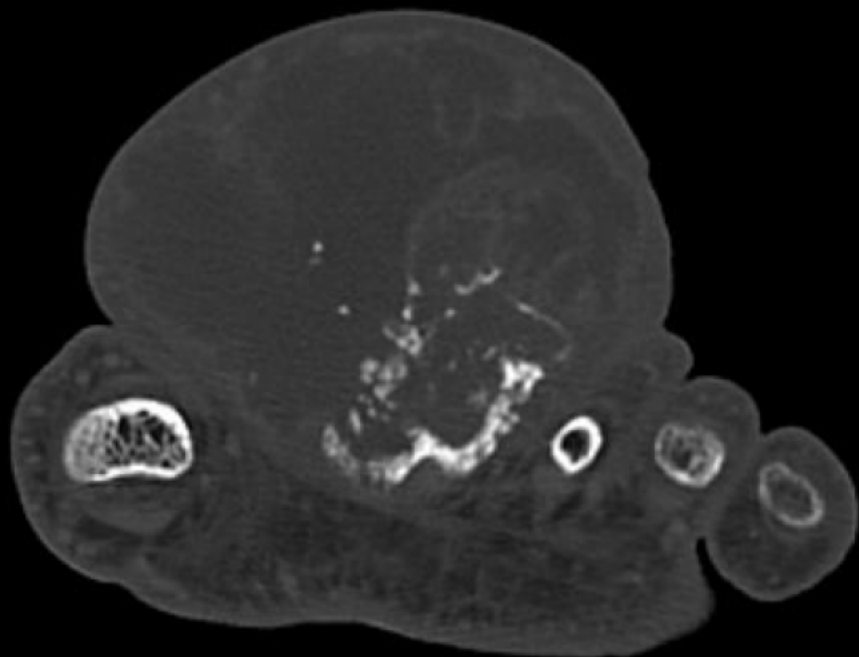
A PROGRAM OF THE
AMERICAN COLLEGE OF RADIOLOGY



AIRPTM

AMERICAN INSTITUTE FOR
RADIOLOGIC PATHOLOGY

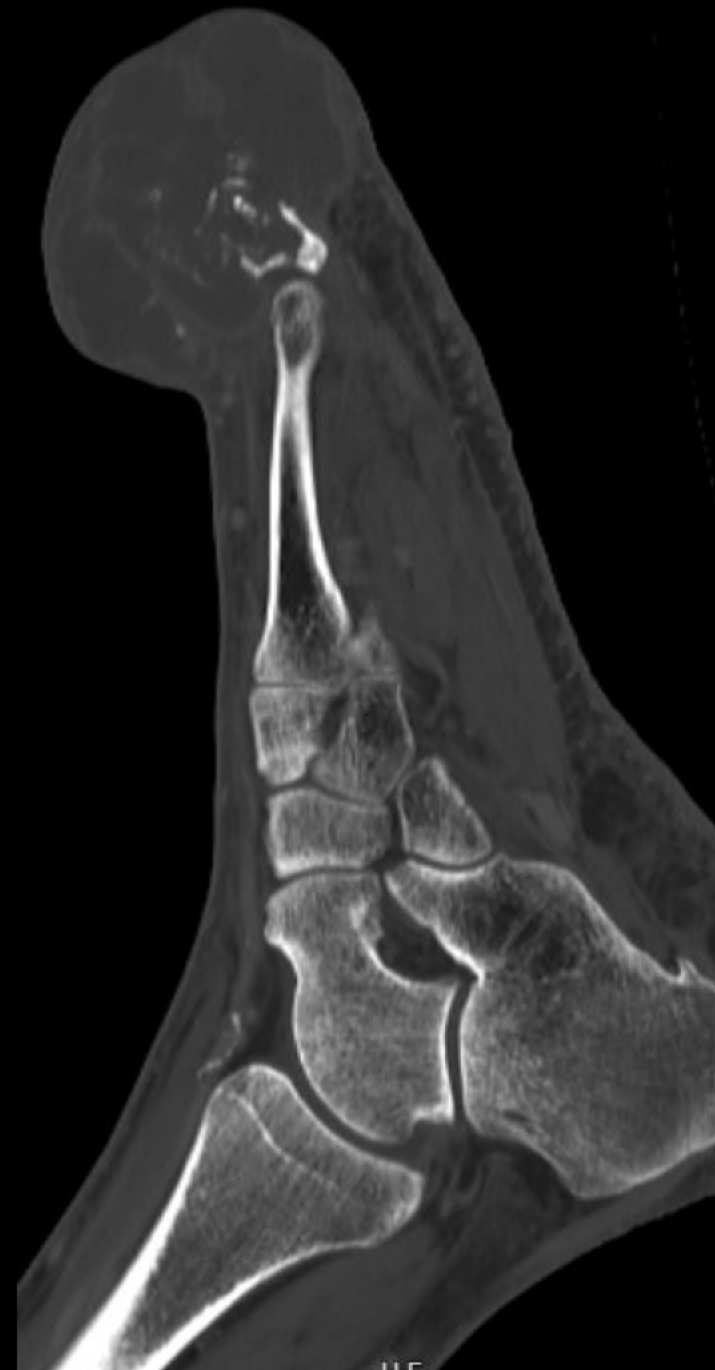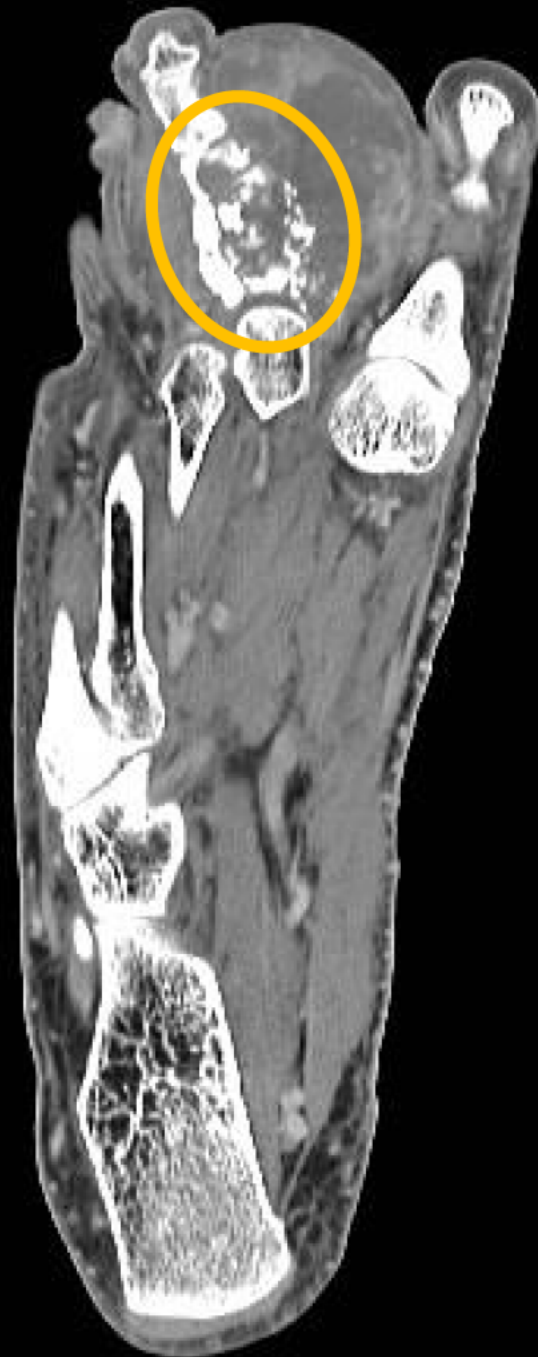
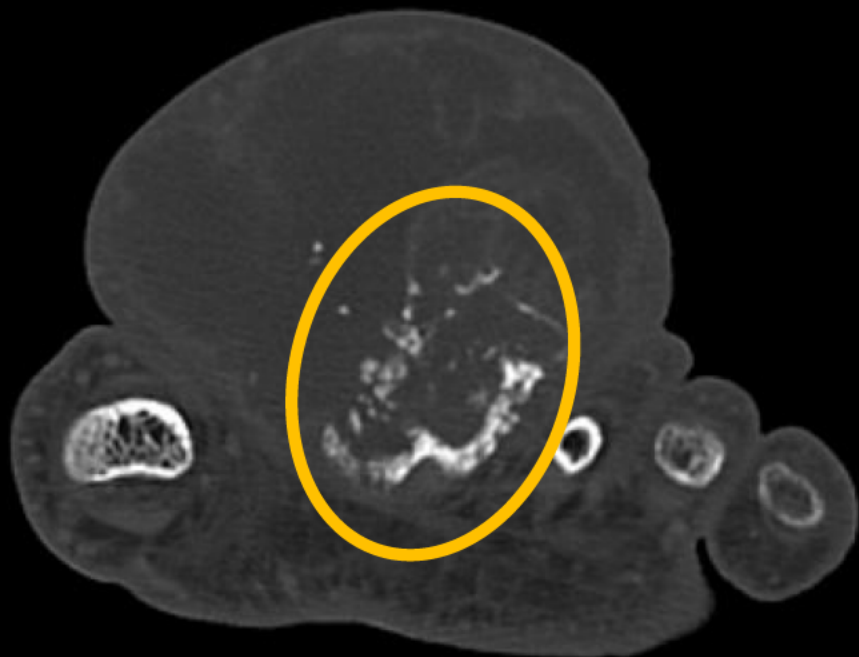
A PROGRAM OF THE
AMERICAN COLLEGE OF RADIOLOGY



AIRPTM

AMERICAN INSTITUTE FOR
RADIOLOGIC PATHOLOGY

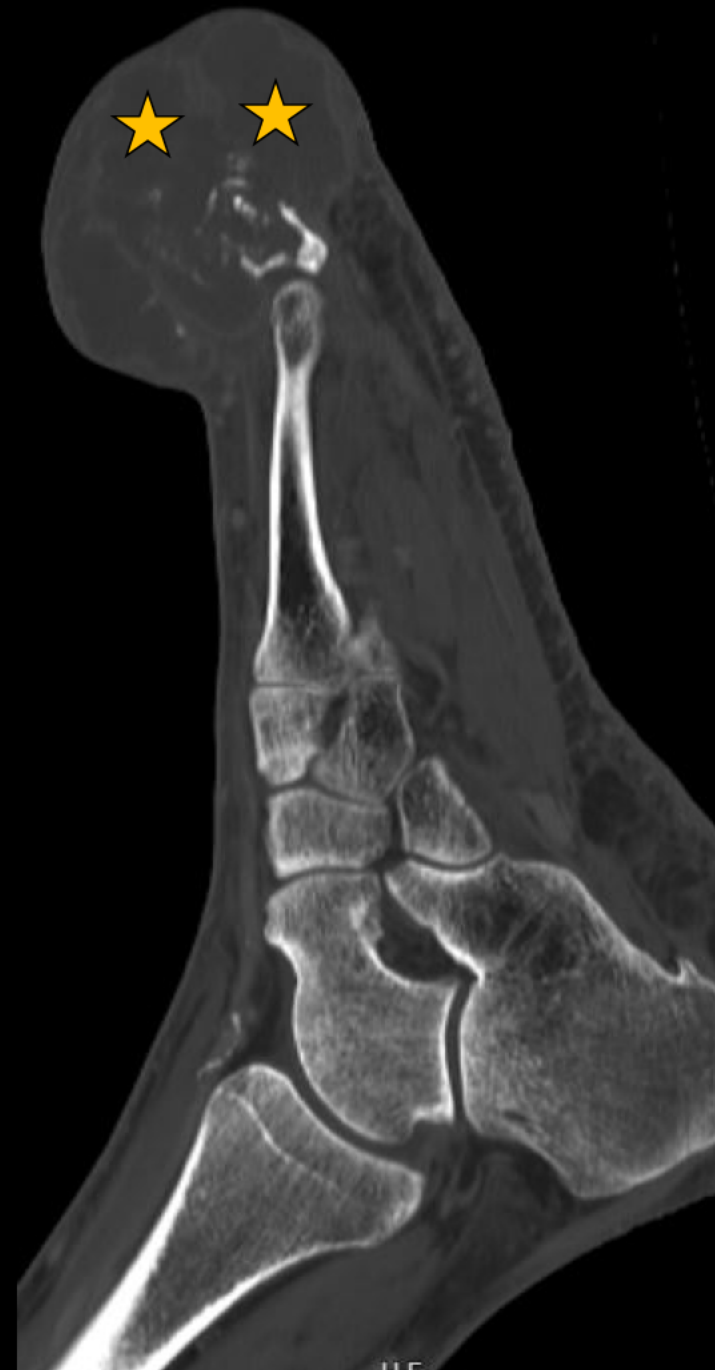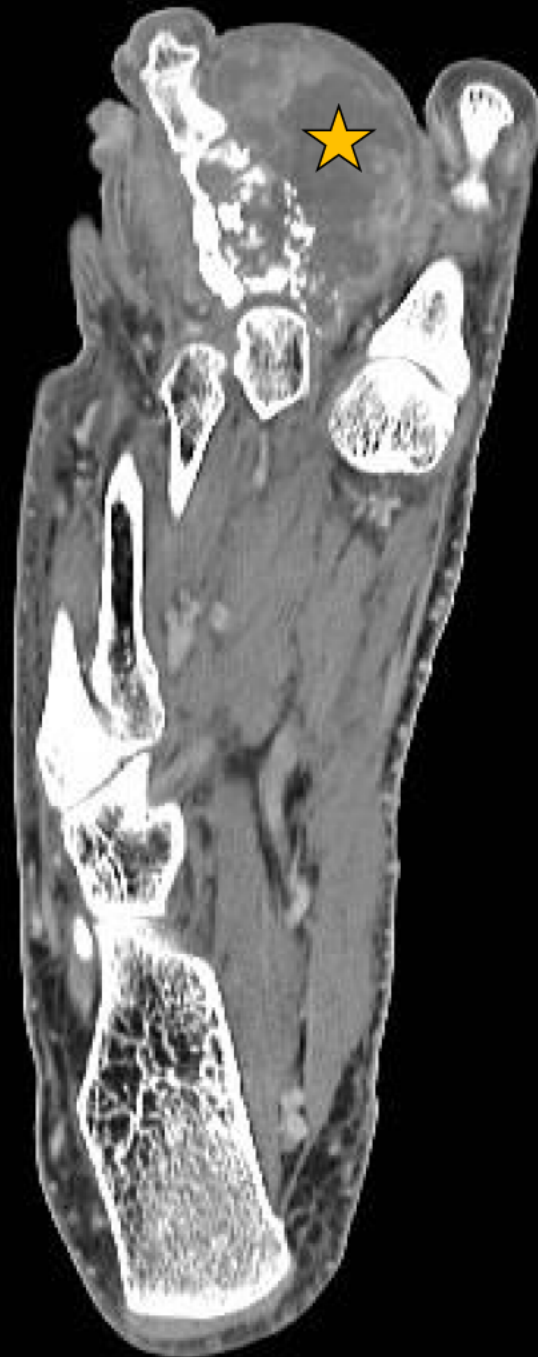
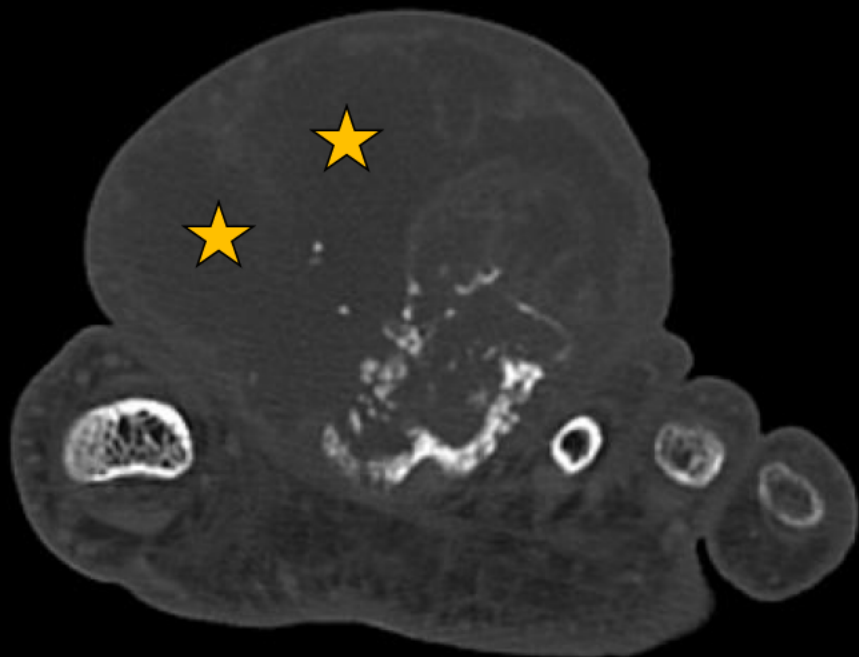
A PROGRAM OF THE
AMERICAN COLLEGE OF RADIOLOGY



AIRPTM

AMERICAN INSTITUTE FOR
RADIOLOGIC PATHOLOGY

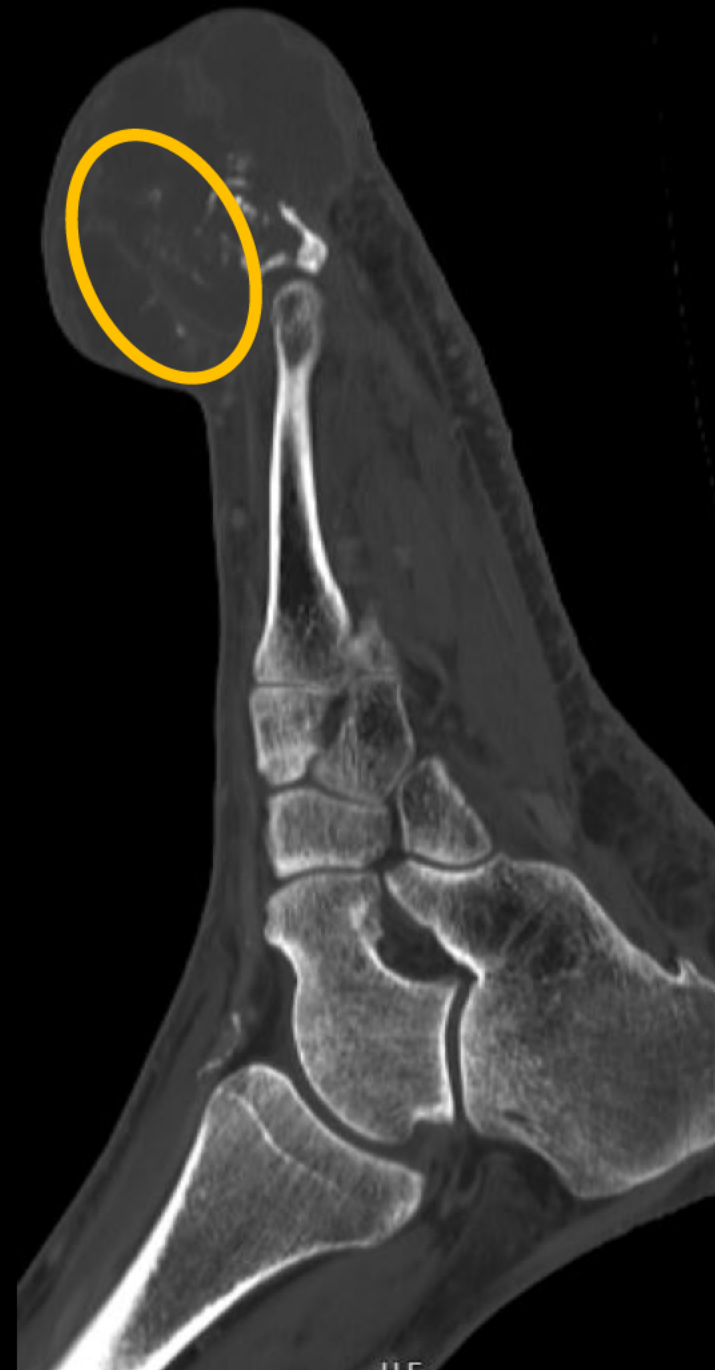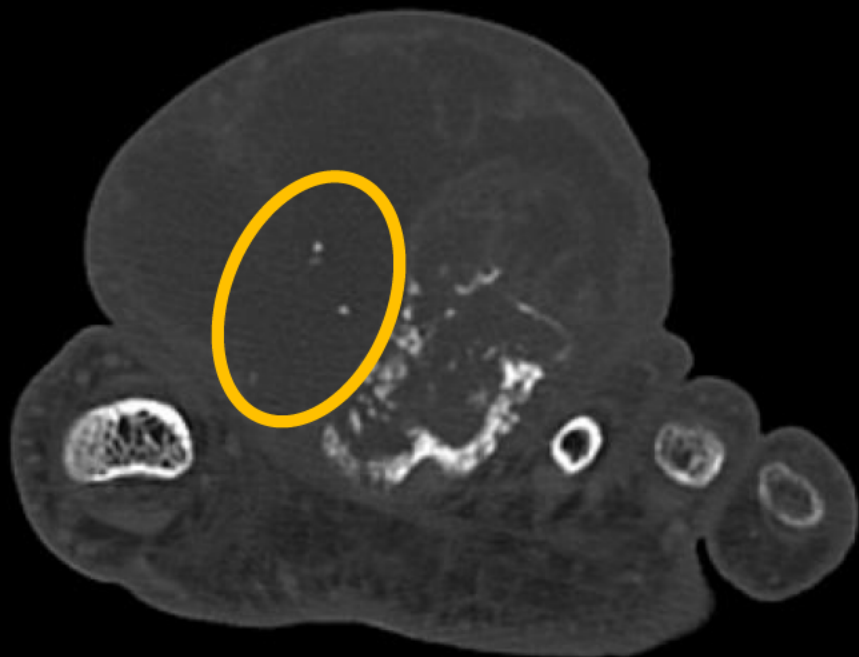
A PROGRAM OF THE
AMERICAN COLLEGE OF RADIOLOGY



AIRPTM

AMERICAN INSTITUTE FOR
RADIOLOGIC PATHOLOGY

A PROGRAM OF THE
AMERICAN COLLEGE OF RADIOLOGY

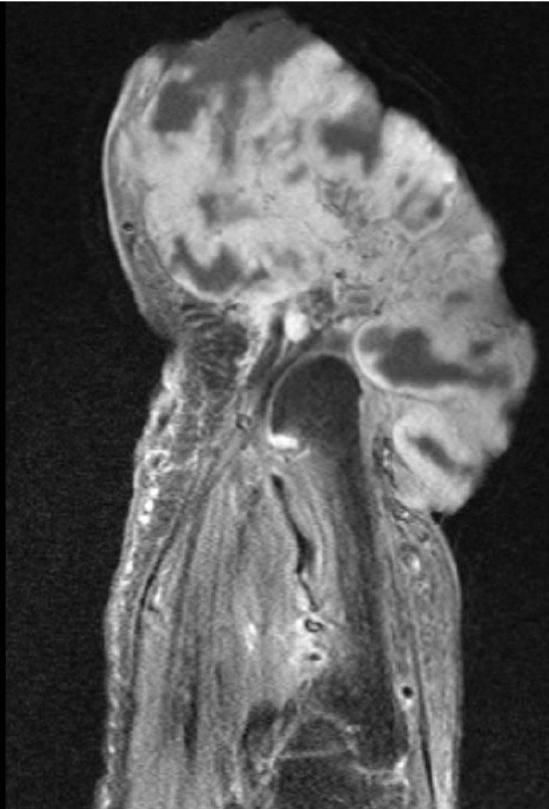
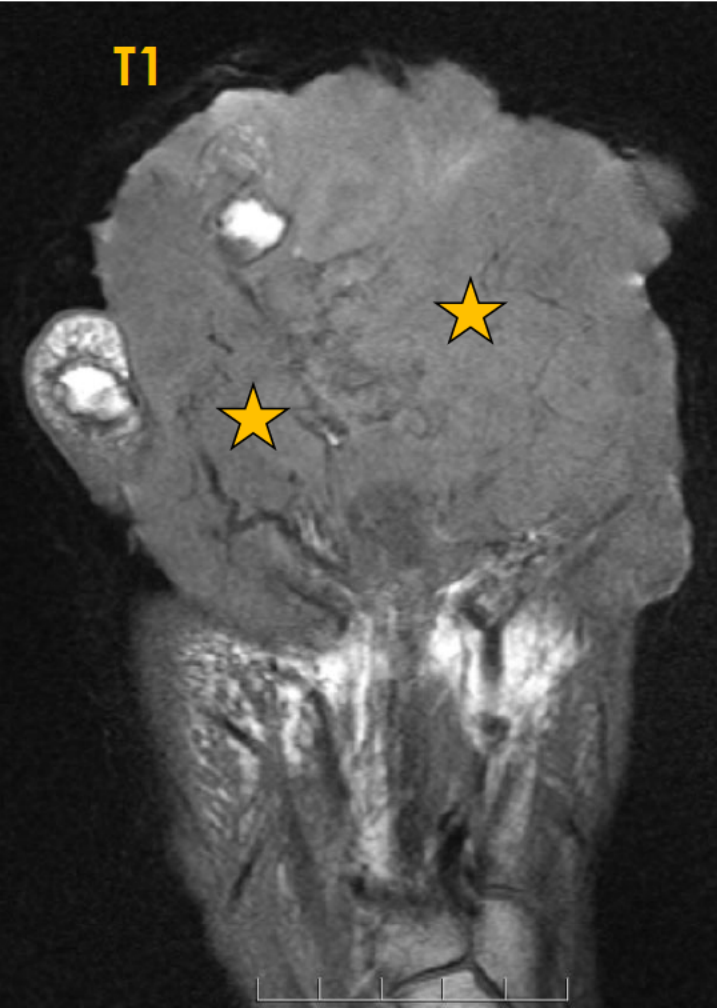


AIRPTM

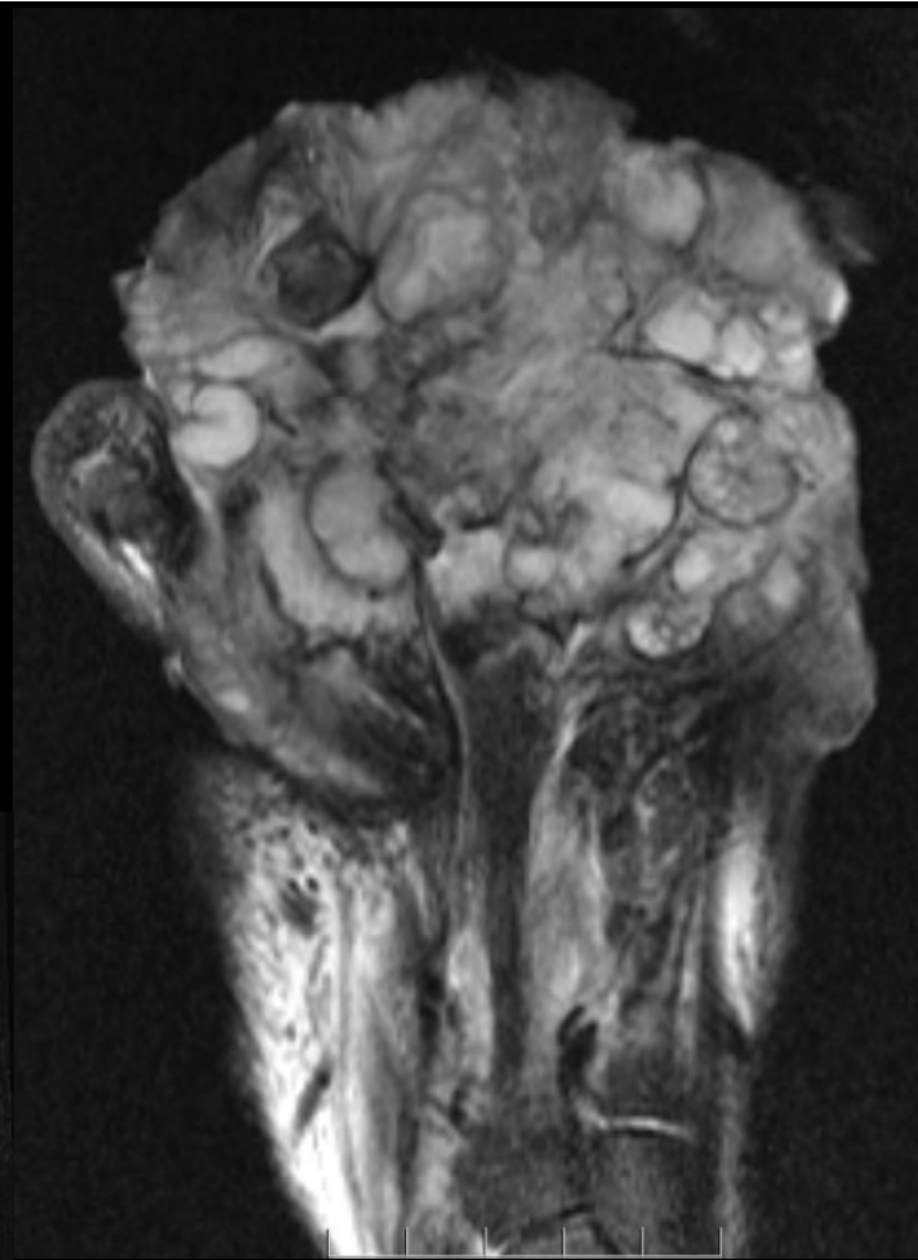
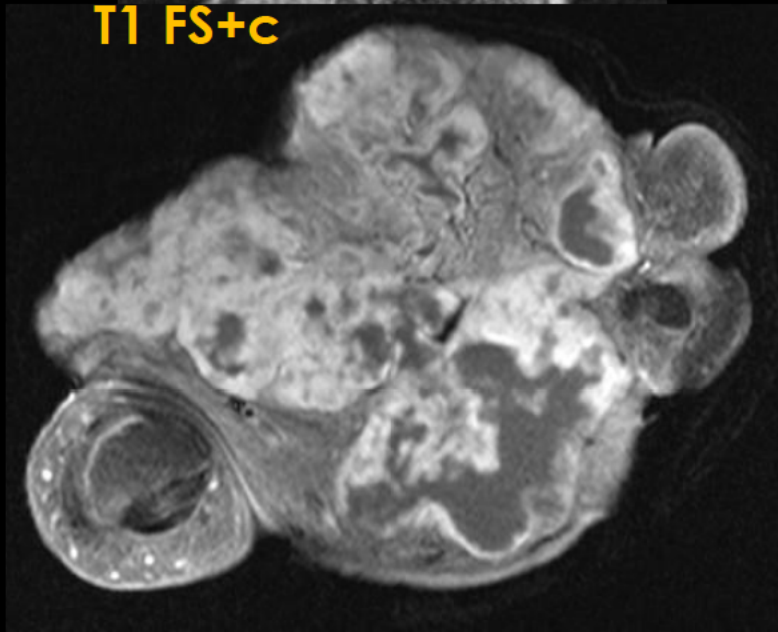
AMERICAN INSTITUTE FOR
RADIOLOGIC PATHOLOGY

A PROGRAM OF THE
AMERICAN COLLEGE OF RADIOLOGY

T1



T1 FS+c



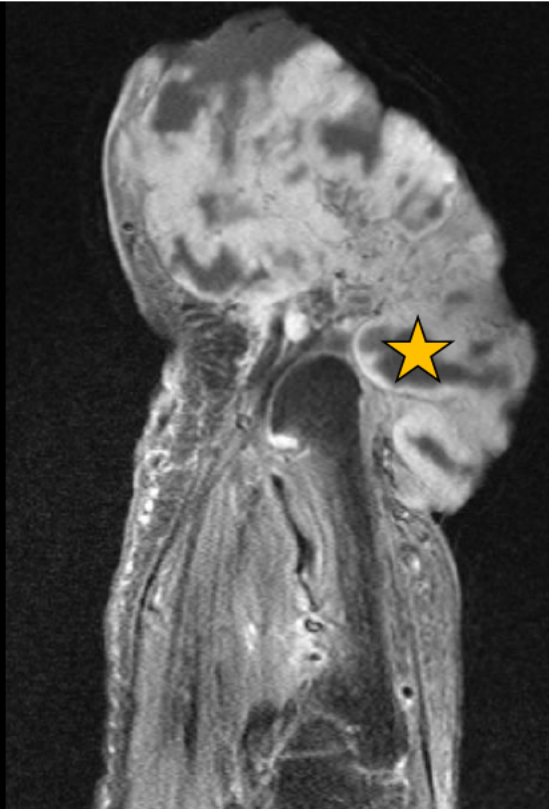
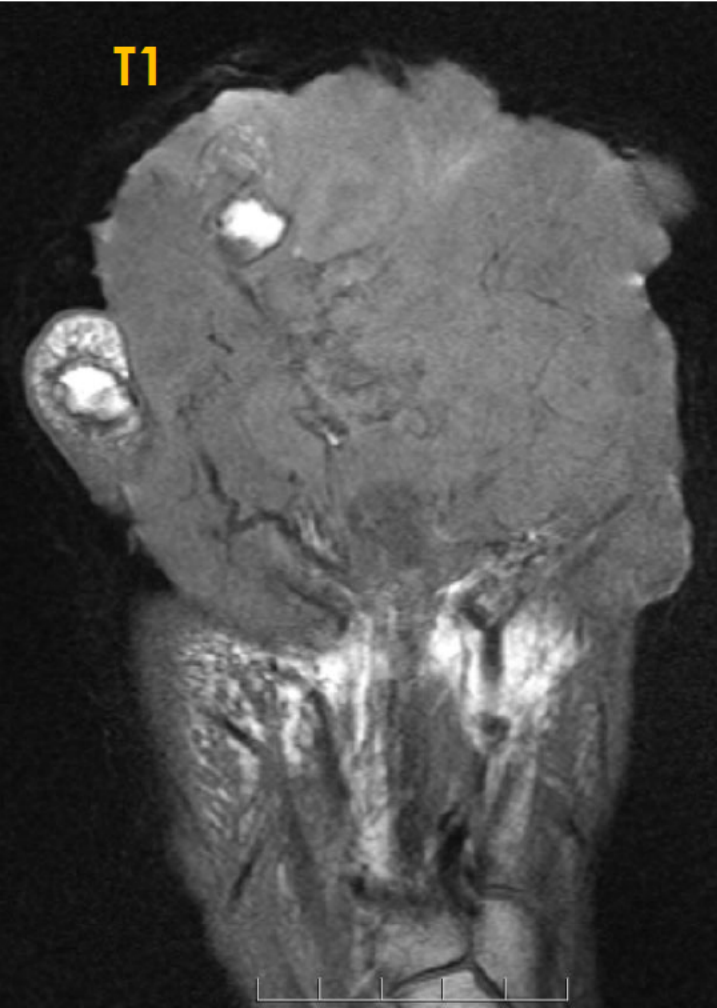
STIR

AIRPTM

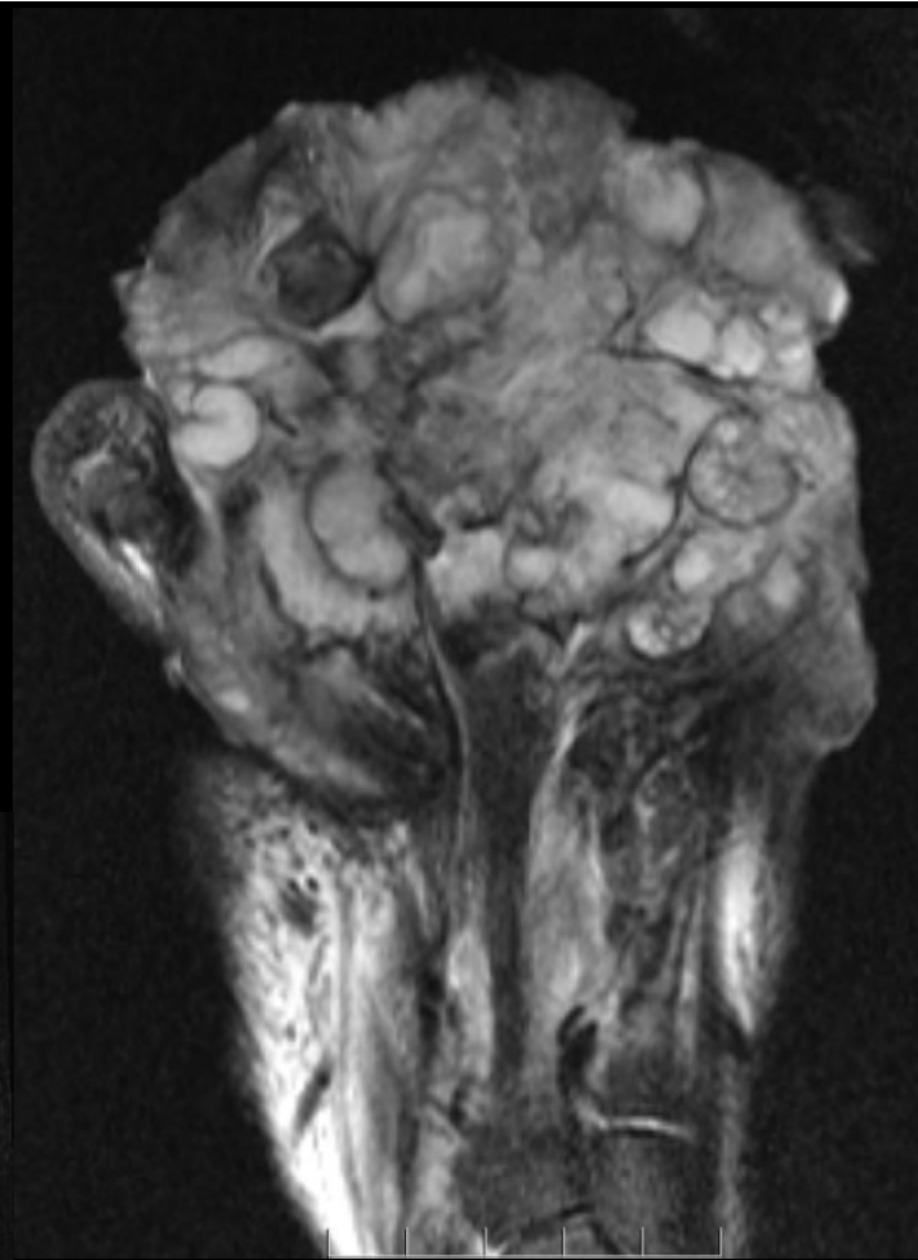
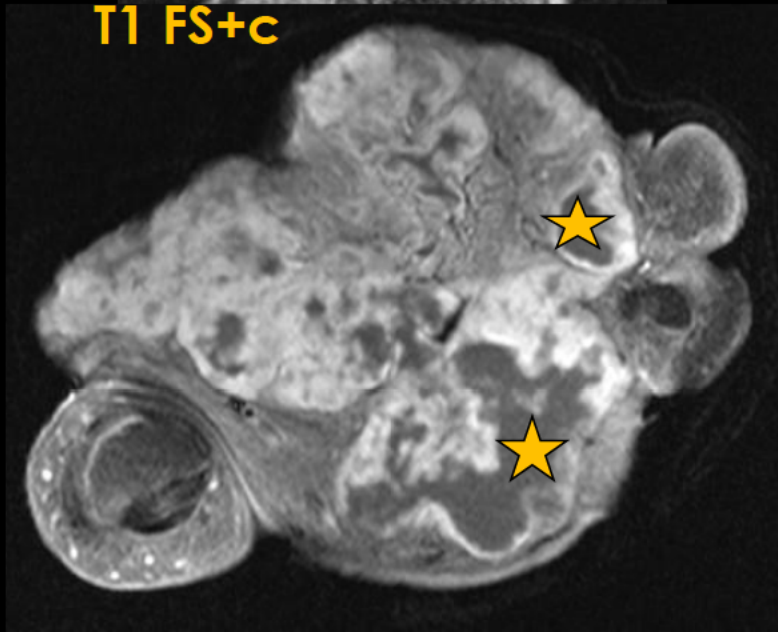
AMERICAN INSTITUTE FOR
RADIOLOGIC PATHOLOGY

A PROGRAM OF THE
AMERICAN COLLEGE OF RADIOLOGY

T1



T1 FS+c



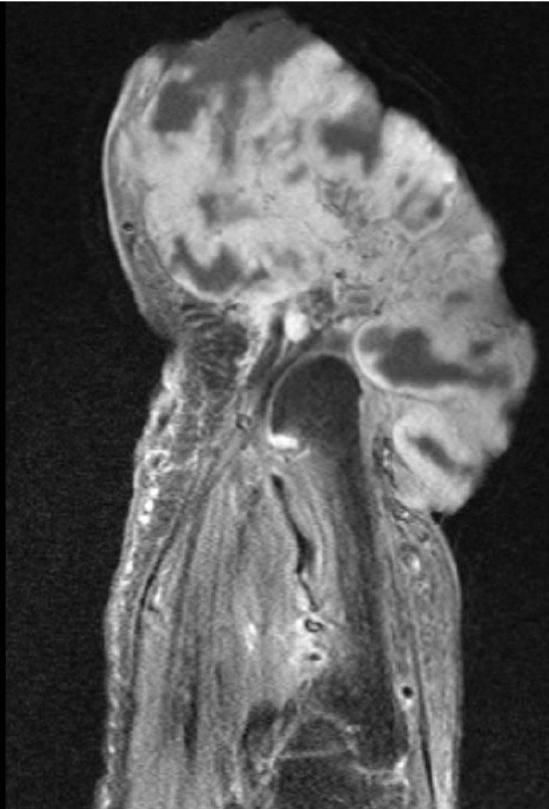
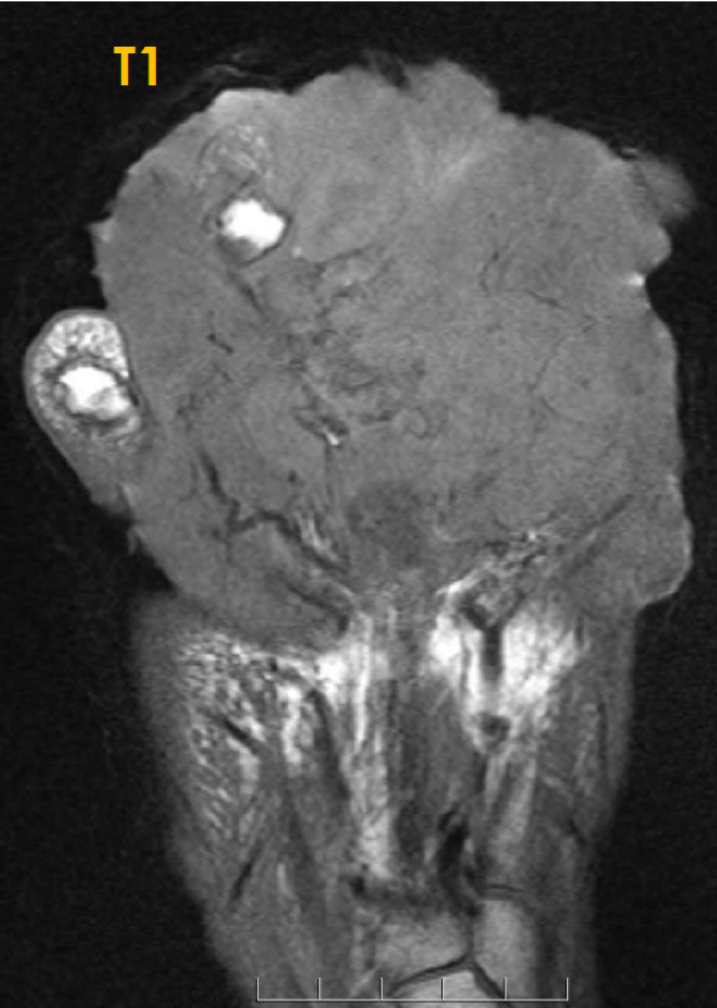
STIR

AIRPTM

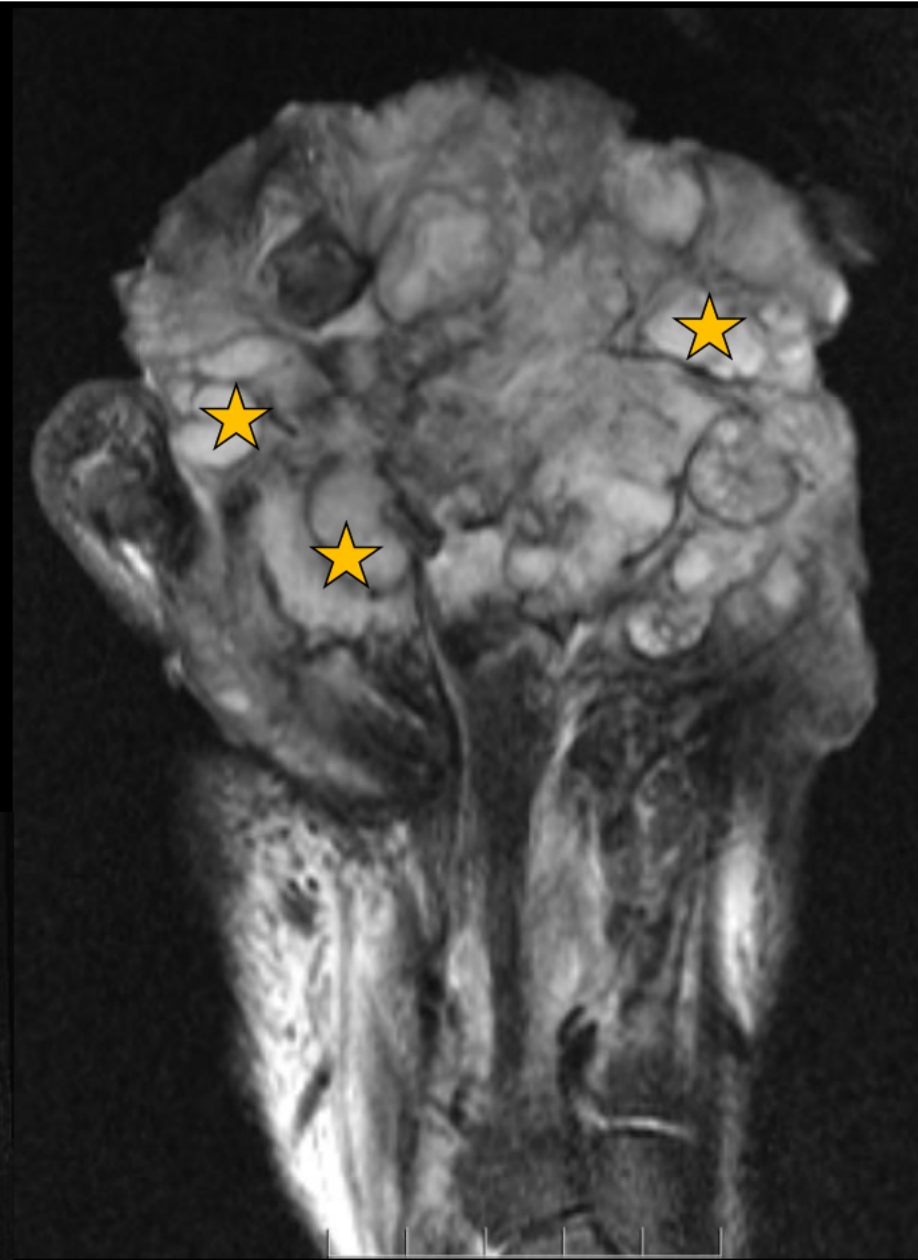
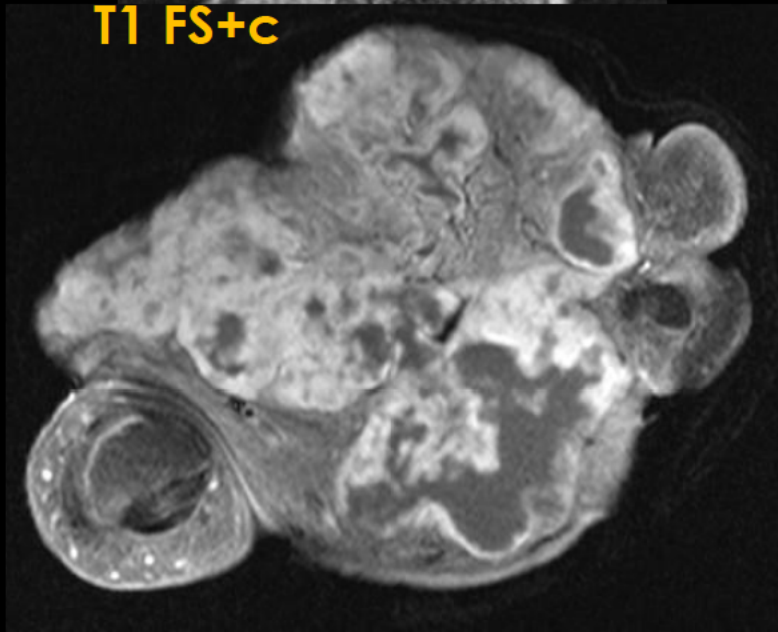
AMERICAN INSTITUTE FOR
RADIOLOGIC PATHOLOGY

A PROGRAM OF THE
AMERICAN COLLEGE OF RADIOLOGY

T1



T1 FS+c



STIR

AIRPTM

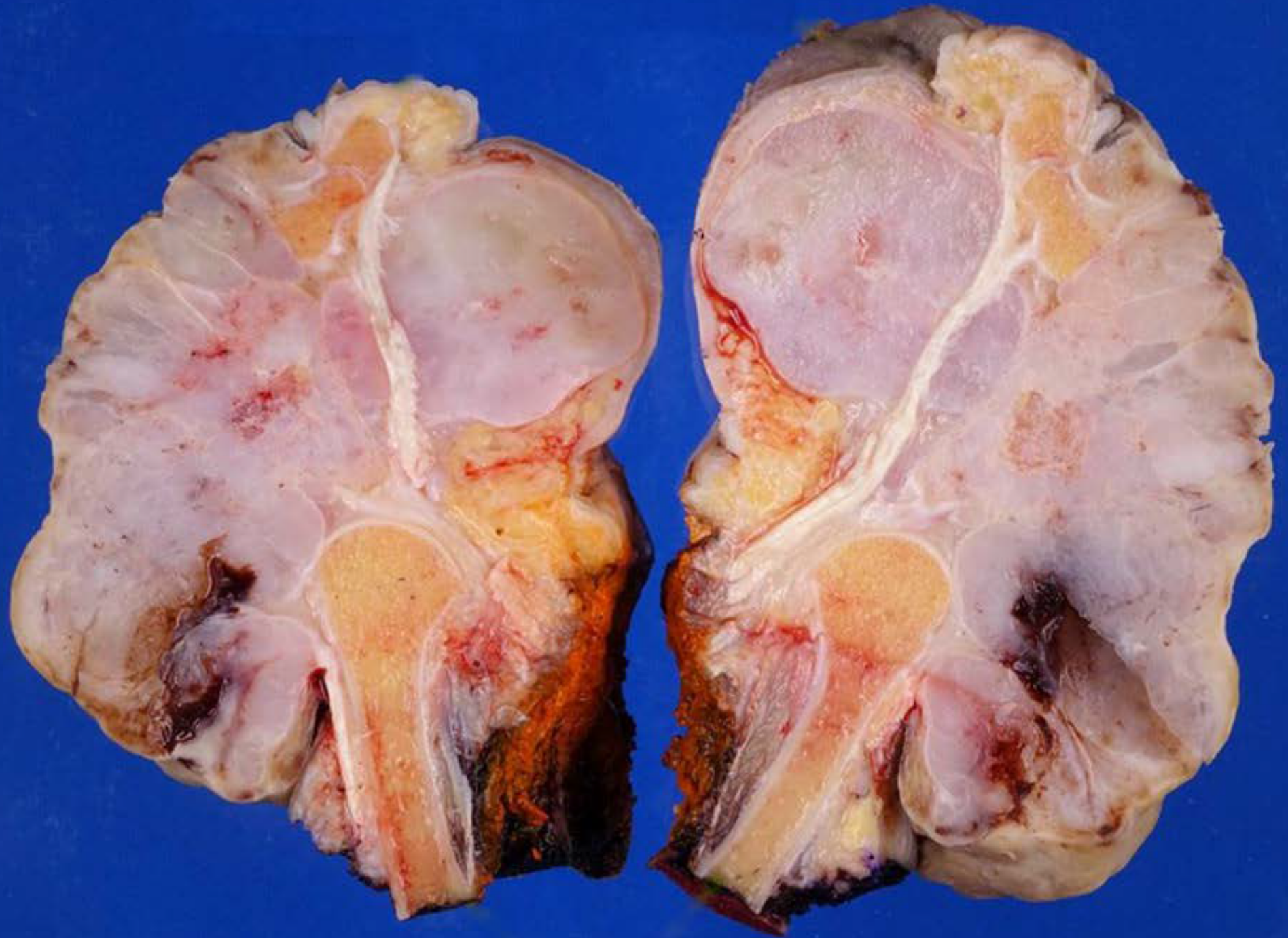
AMERICAN INSTITUTE FOR
RADIOLOGIC PATHOLOGY

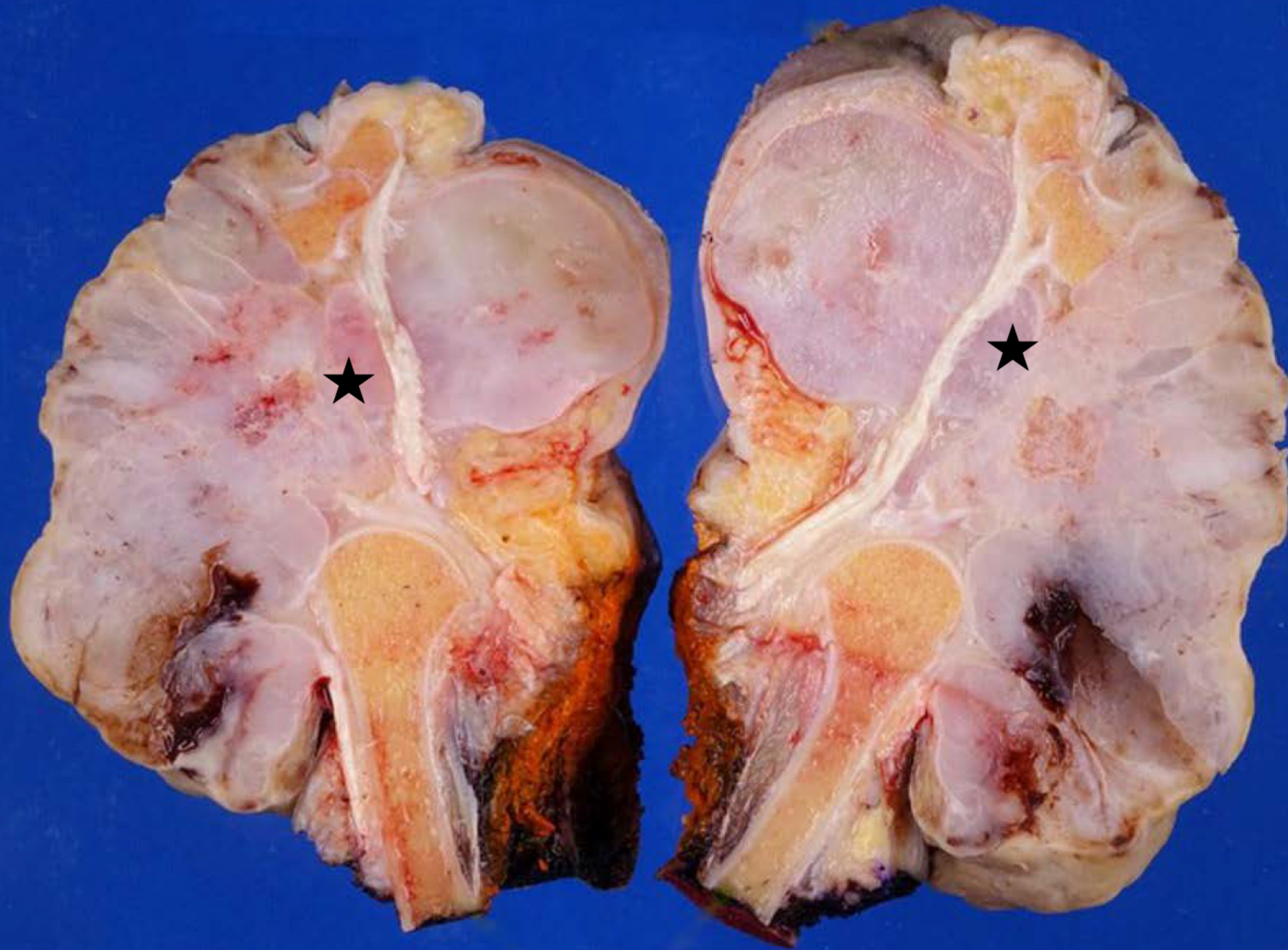
A PROGRAM OF THE
AMERICAN COLLEGE OF RADIOLOGY

AIRP™

AMERICAN INSTITUTE FOR
RADIOLOGIC PATHOLOGY

A PROGRAM OF THE
AMERICAN COLLEGE OF RADIOLOGY

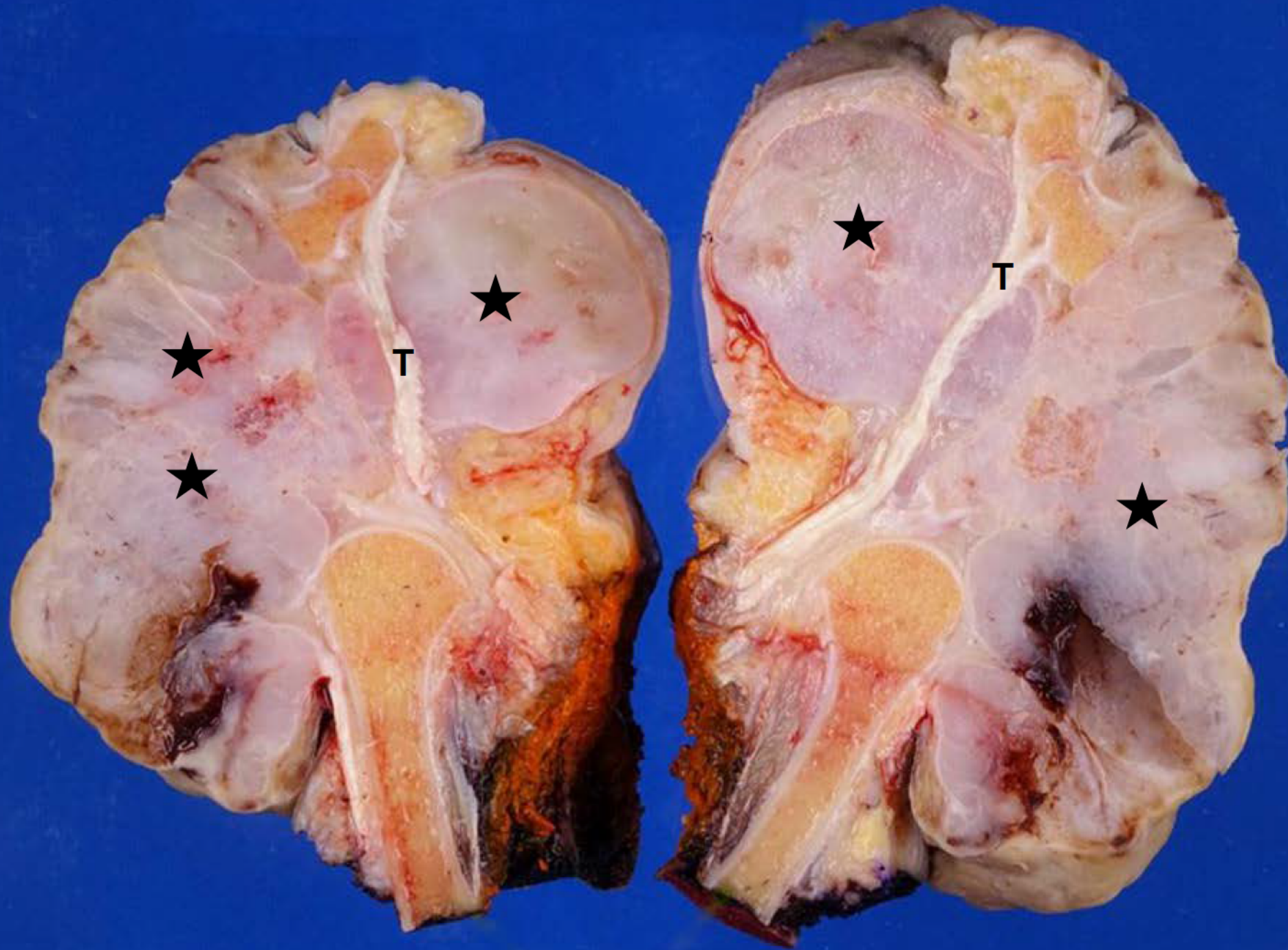




AIRP™

AMERICAN INSTITUTE FOR
RADIOLOGIC PATHOLOGY

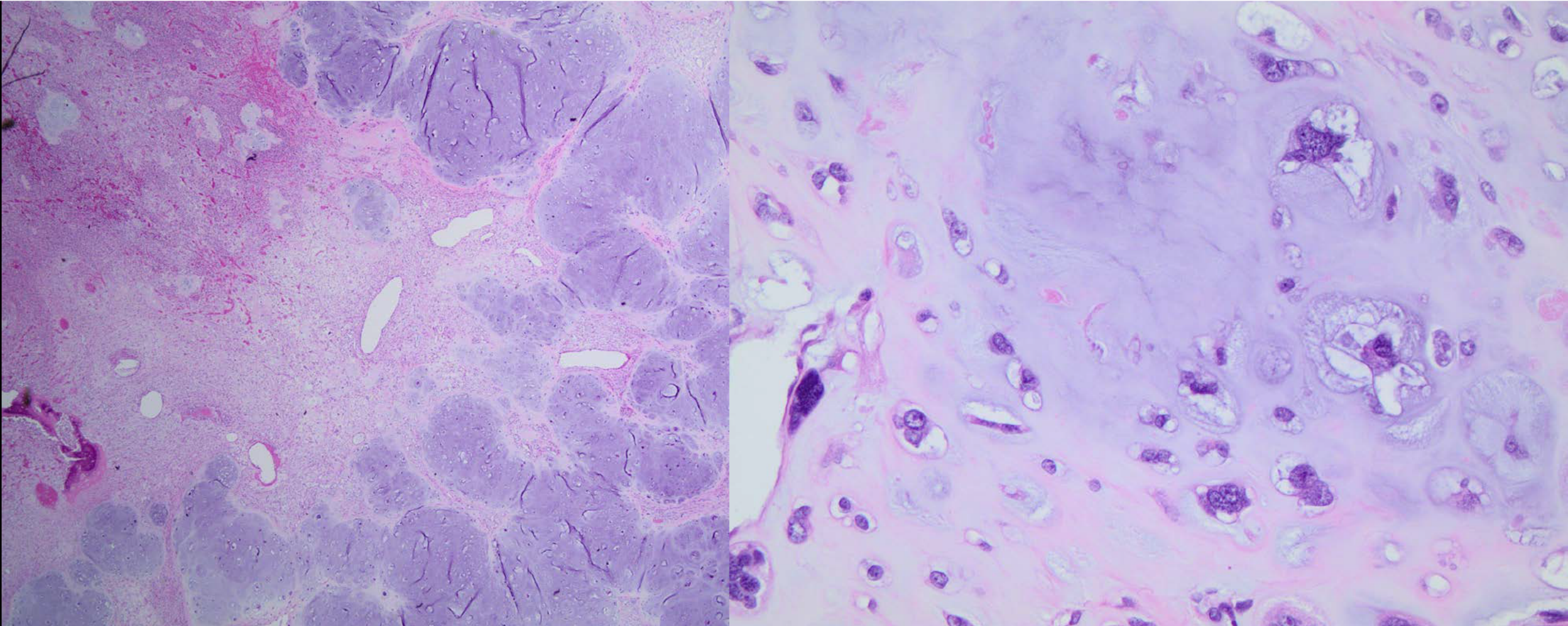
A PROGRAM OF THE
AMERICAN COLLEGE OF RADIOLOGY



AIRP™

AMERICAN INSTITUTE FOR
RADIOLOGIC PATHOLOGY

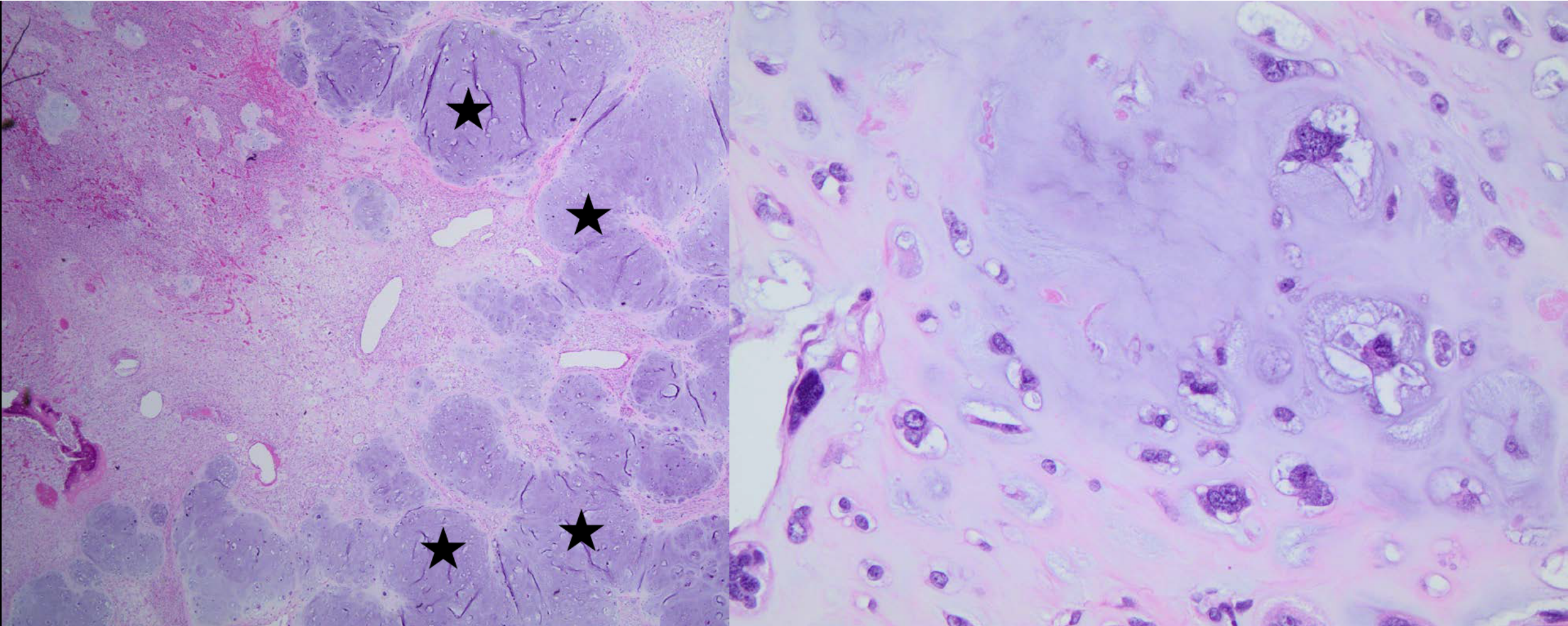
A PROGRAM OF THE
AMERICAN COLLEGE OF RADIOLOGY



AIRPTM

AMERICAN INSTITUTE FOR
RADIOLOGIC PATHOLOGY

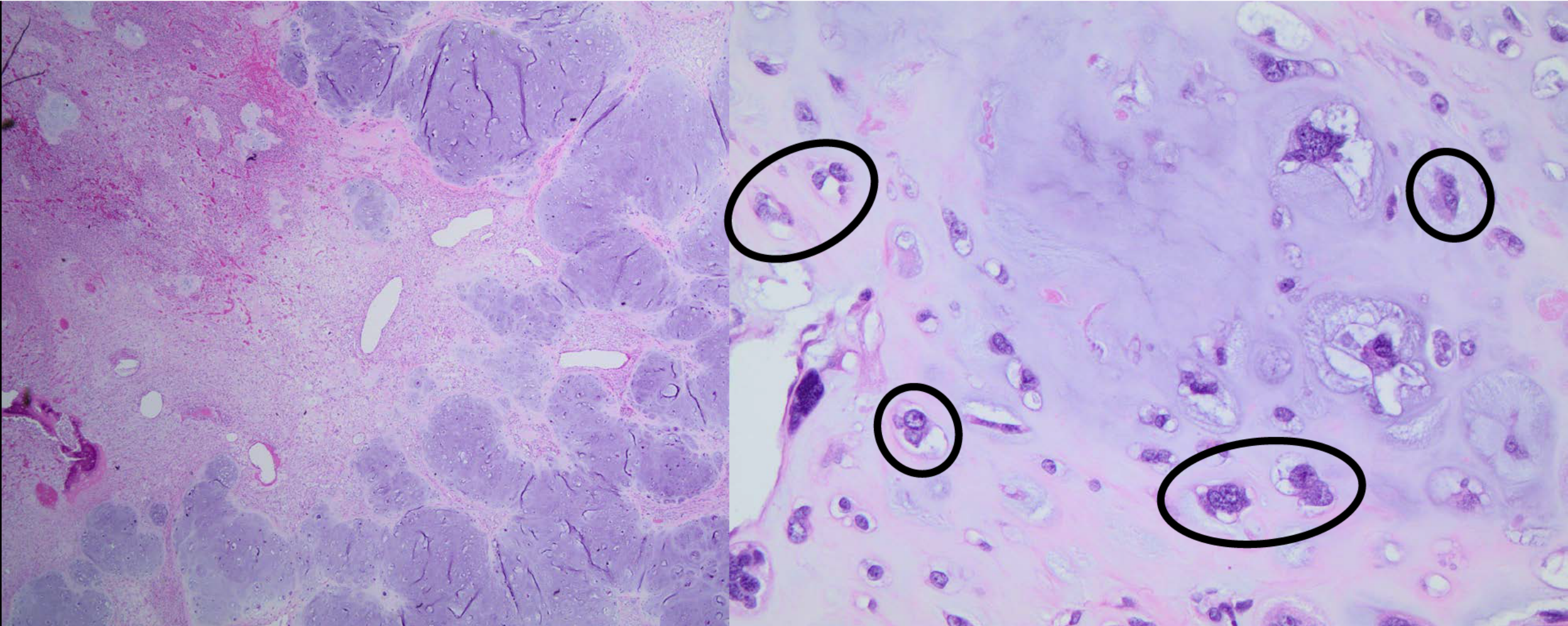
A PROGRAM OF THE
AMERICAN COLLEGE OF RADIOLOGY



AIRPTM

AMERICAN INSTITUTE FOR
RADIOLOGIC PATHOLOGY

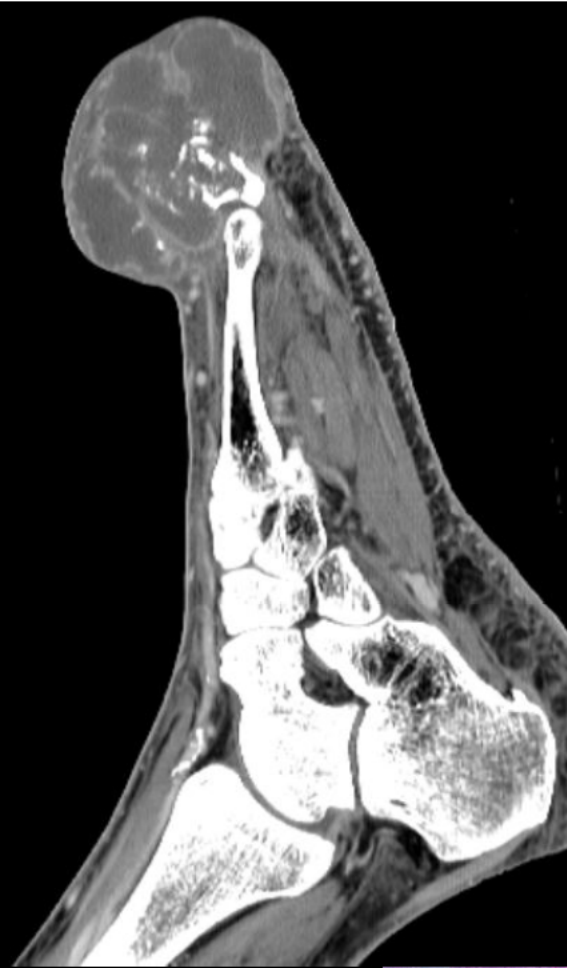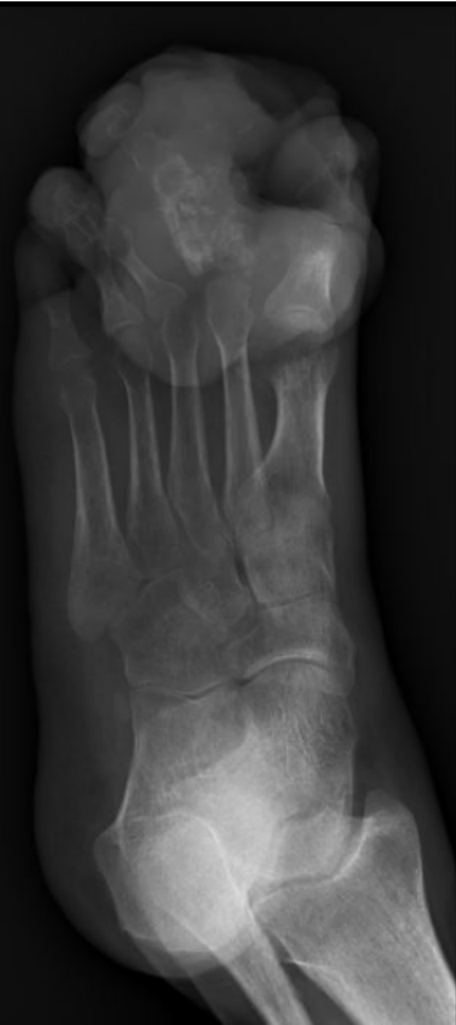A PROGRAM OF THE
AMERICAN COLLEGE OF RADIOLOGY



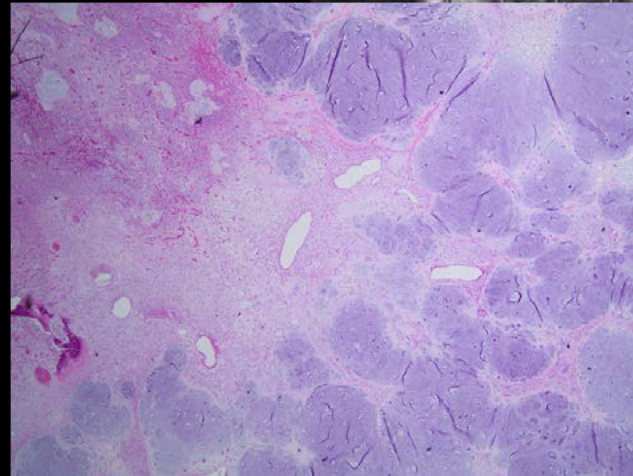
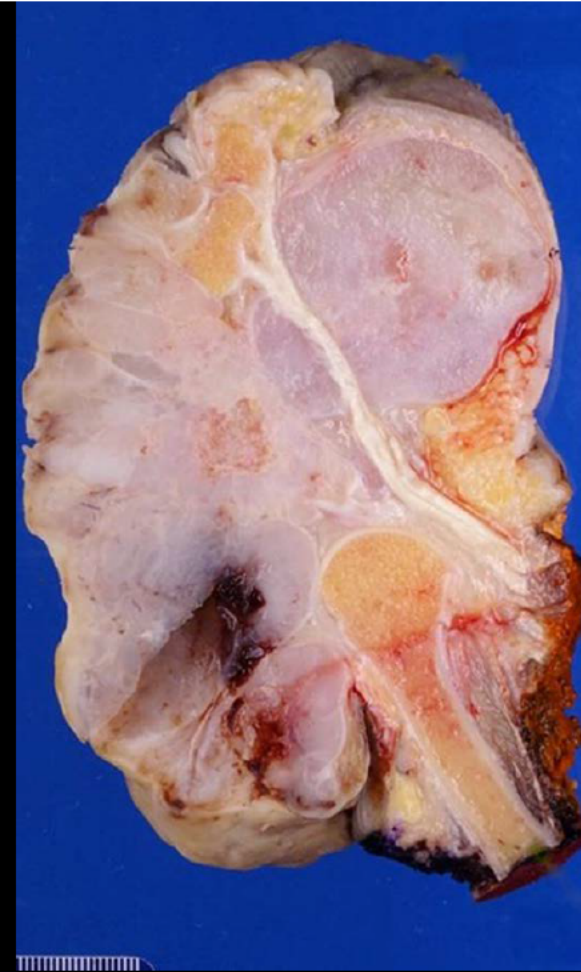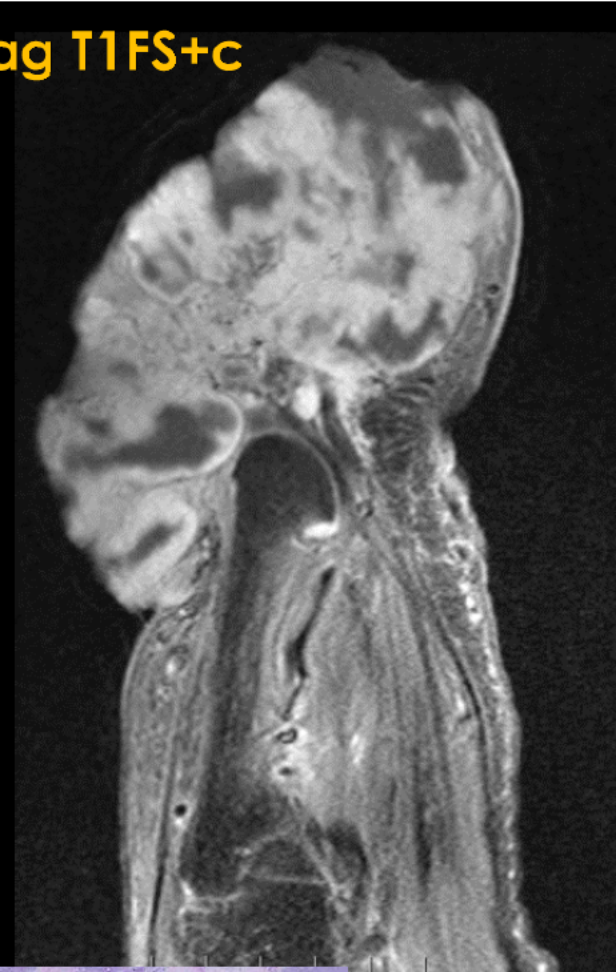
AIRPTM

AMERICAN INSTITUTE FOR
RADIOLOGIC PATHOLOGY

A PROGRAM OF THE
AMERICAN COLLEGE OF RADIOLOGY



Sag T1FS+c



AIRPTM

AMERICAN INSTITUTE FOR
RADIOLOGIC PATHOLOGY

A PROGRAM OF THE
AMERICAN COLLEGE OF RADIOLOGY

INTRAMEDULLARY CHONDROSARCOMA

Dr. Jesse Spinner

The Ohio State University

Wexner Medical Center

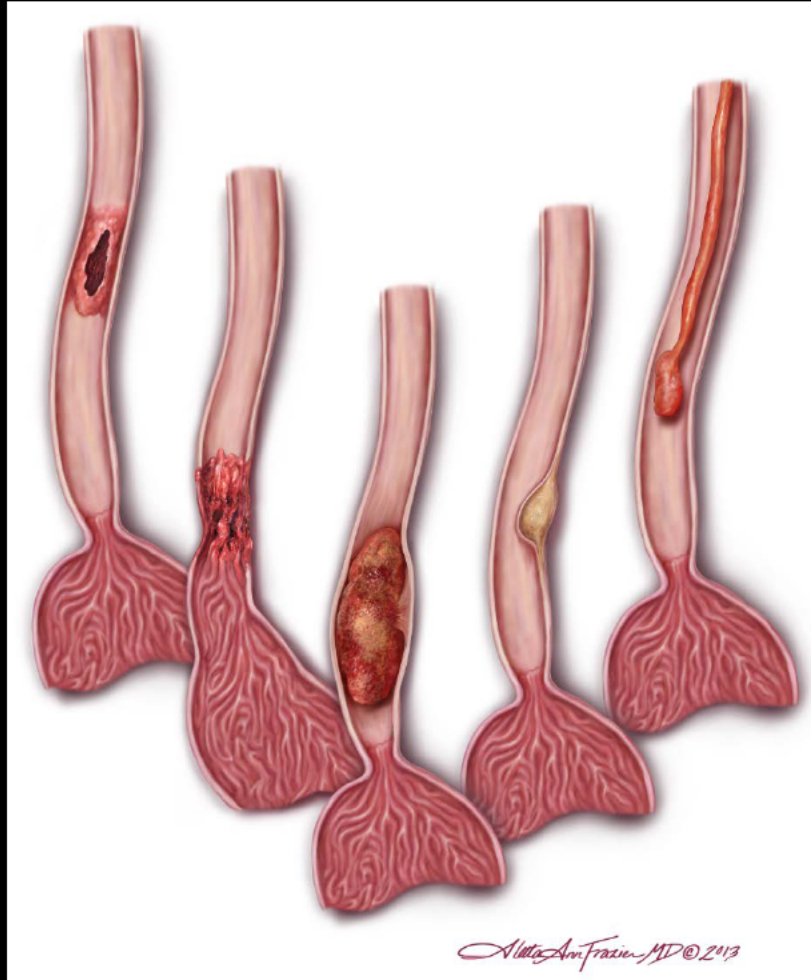
Columbus, OH

AIRPTM

**AMERICAN INSTITUTE FOR
RADIOLOGIC PATHOLOGY**

**A PROGRAM OF THE
AMERICAN COLLEGE OF RADIOLOGY**

Gastrointestinal Best Case



AIRPTM

AMERICAN INSTITUTE FOR
RADIOLOGIC PATHOLOGY

A PROGRAM OF THE
AMERICAN COLLEGE OF RADIOLOGY

Natasha Anfrizion MD © 2013

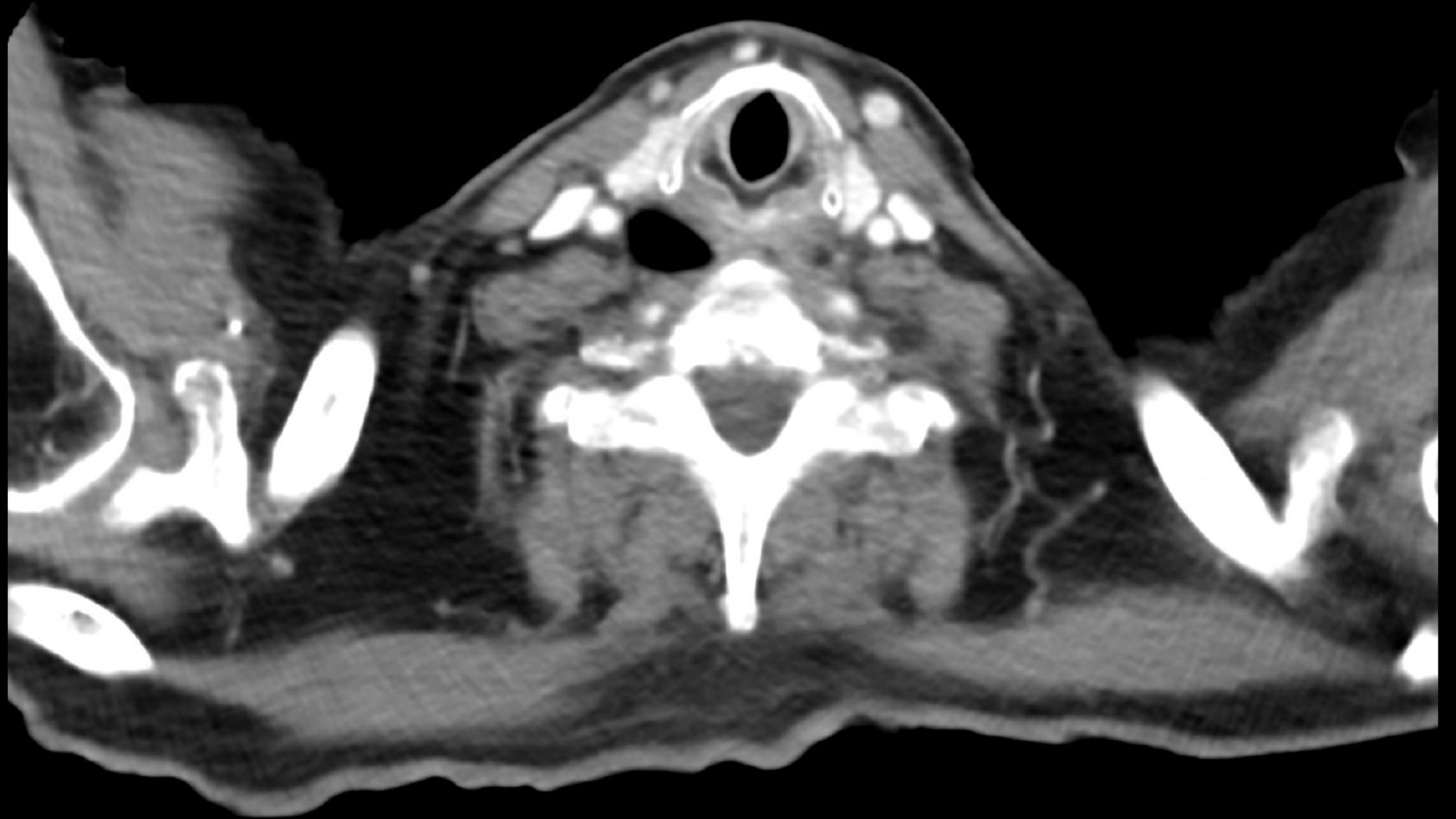
Clinical information

72-year-old Hispanic man with 2 month history of unintentional weight loss, voice change, and dysphagia.



AMERICAN INSTITUTE FOR
RADIOLOGIC PATHOLOGY

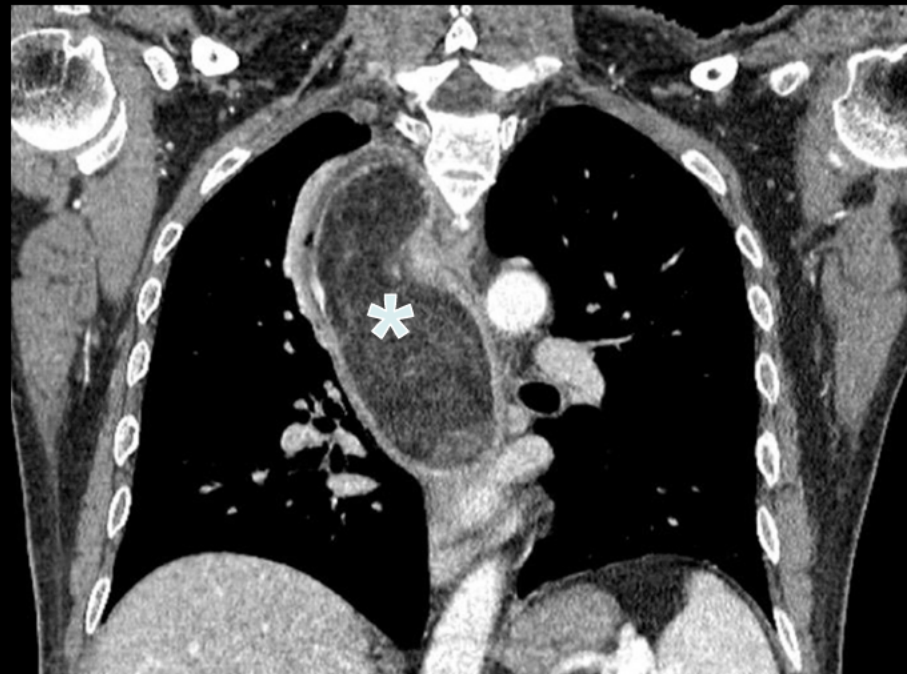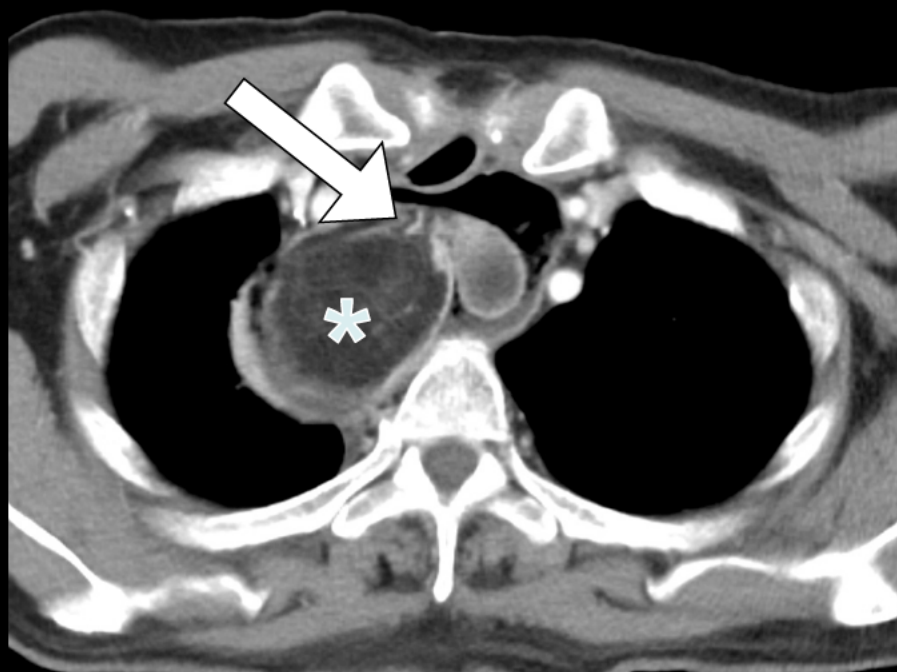
A PROGRAM OF THE
AMERICAN COLLEGE OF RADIOLOGY



AIRPTM

AMERICAN INSTITUTE FOR
RADIOLOGIC PATHOLOGY

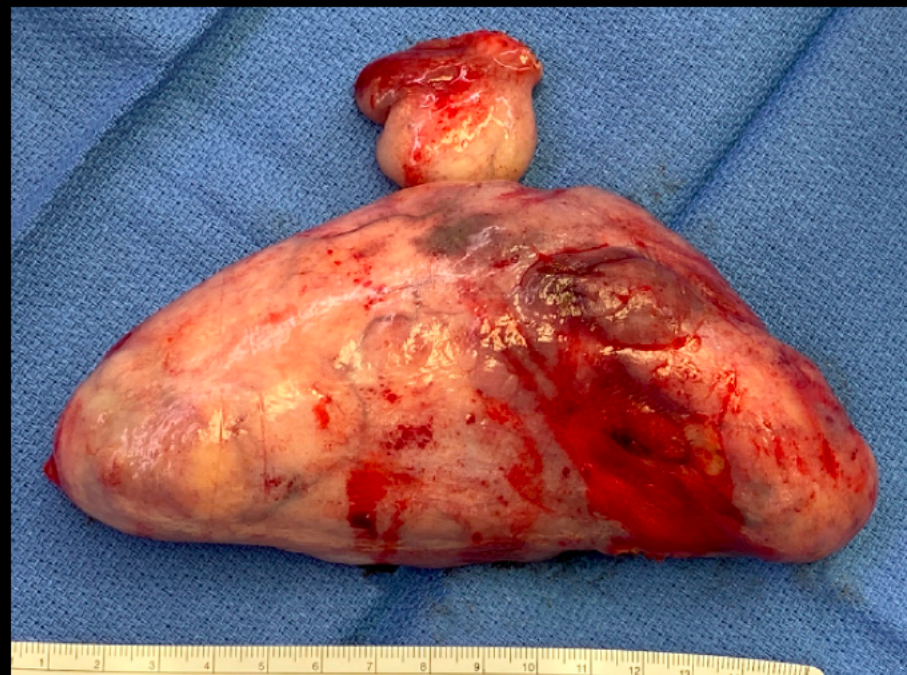
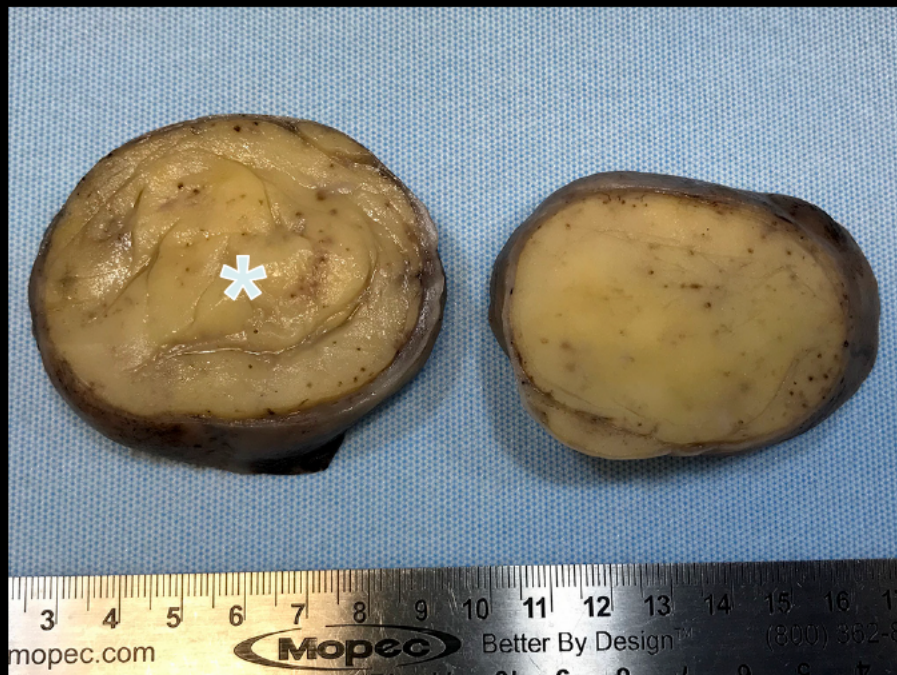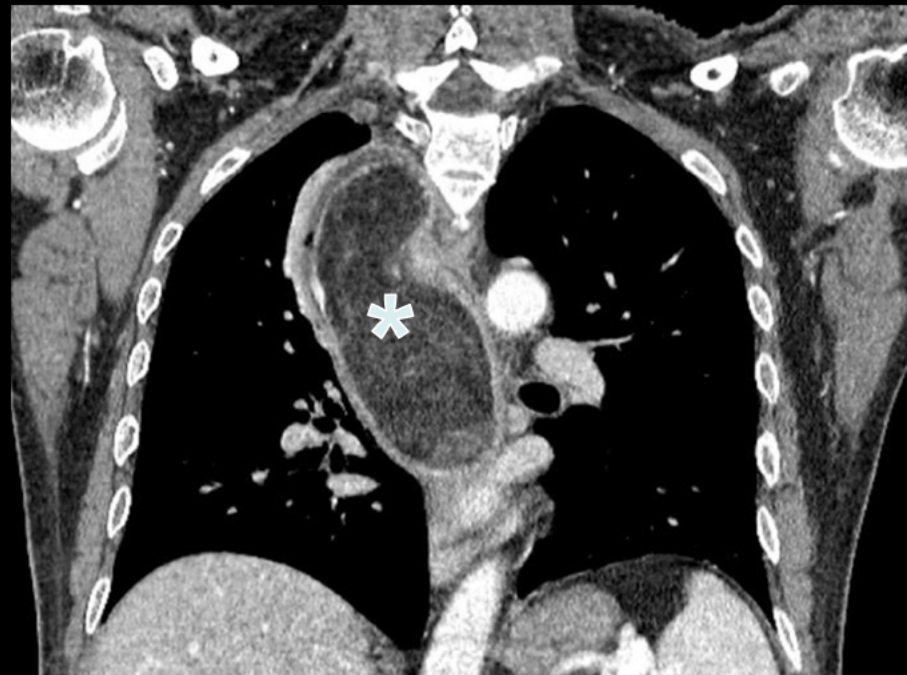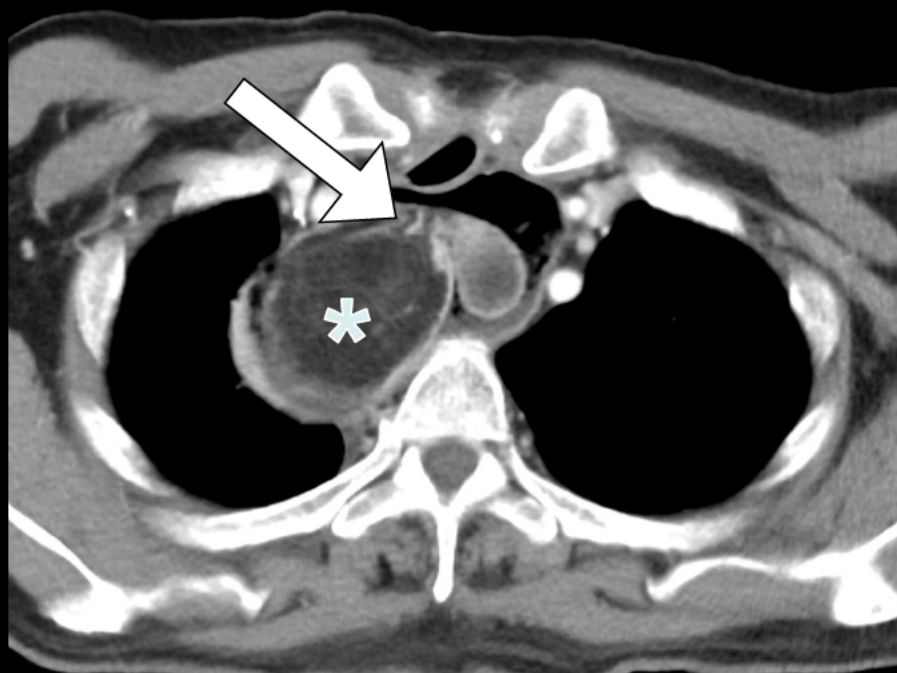
A PROGRAM OF THE
AMERICAN COLLEGE OF RADIOLOGY



AIRPTM

AMERICAN INSTITUTE FOR
RADIOLOGIC PATHOLOGY

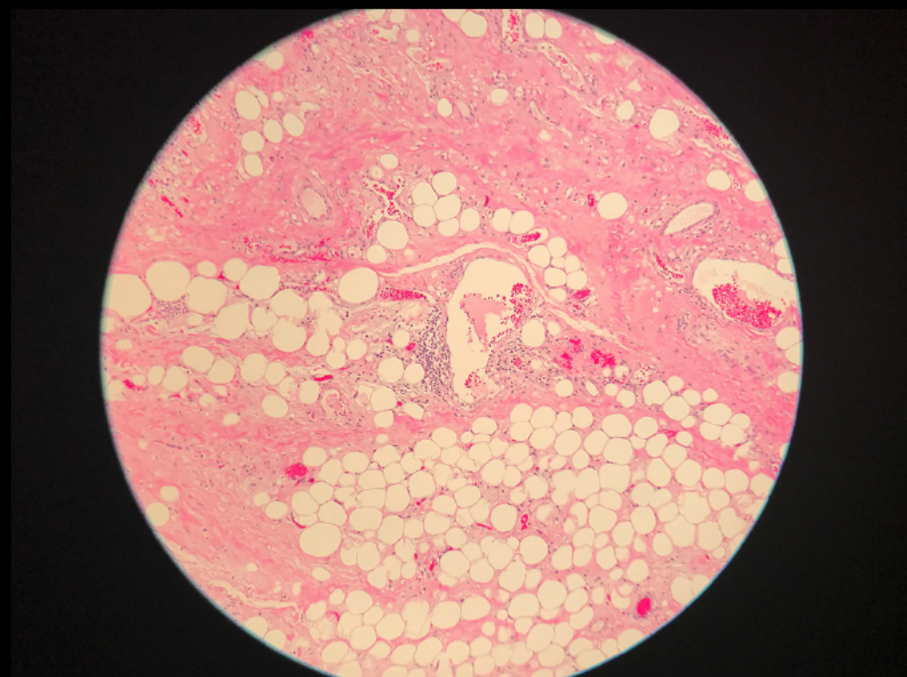
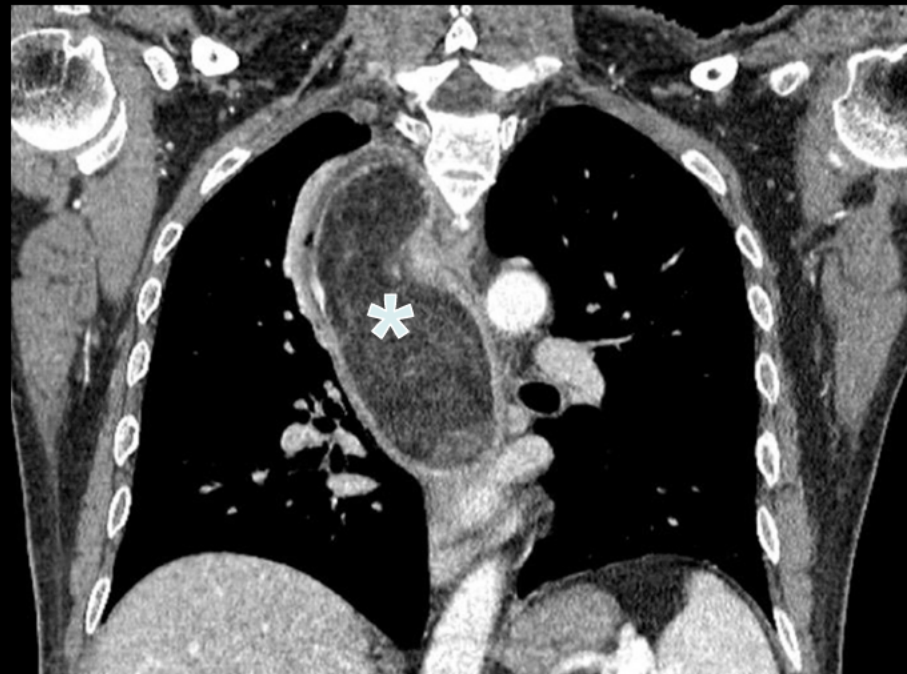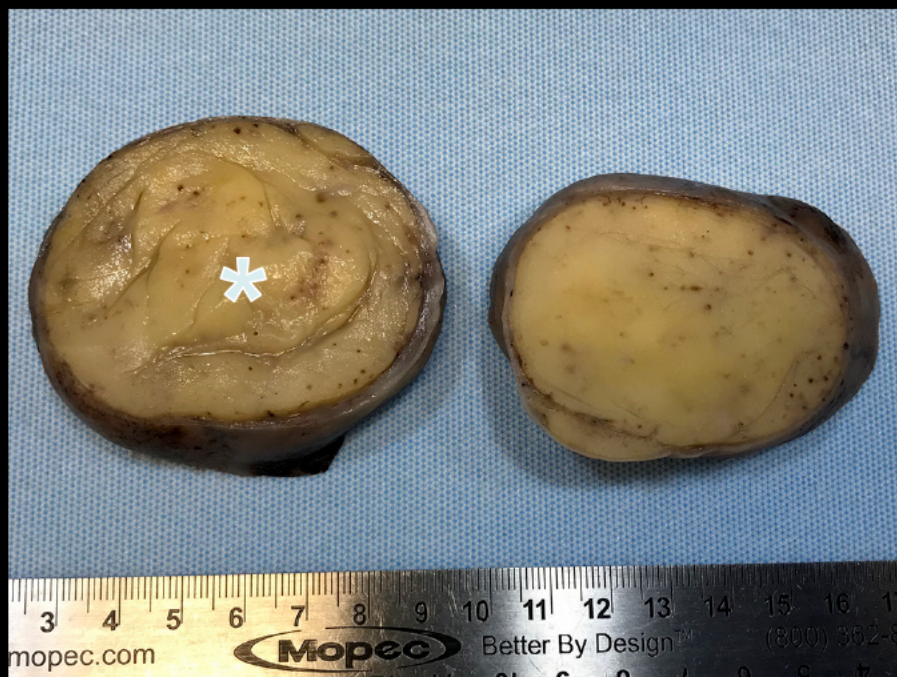
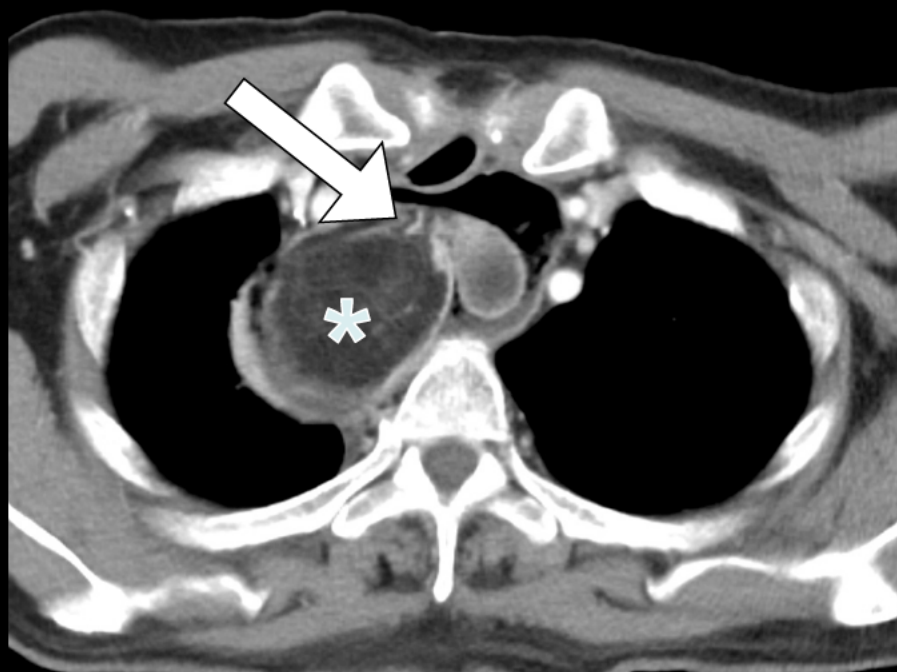
A PROGRAM OF THE
AMERICAN COLLEGE OF RADIOLOGY



AIRP™

AMERICAN INSTITUTE FOR
RADIOLOGIC PATHOLOGY

A PROGRAM OF THE
AMERICAN COLLEGE OF RADIOLOGY



Esophageal Liposarcoma

Sarah Cheng, MD

Stanford Hospital and Clinics

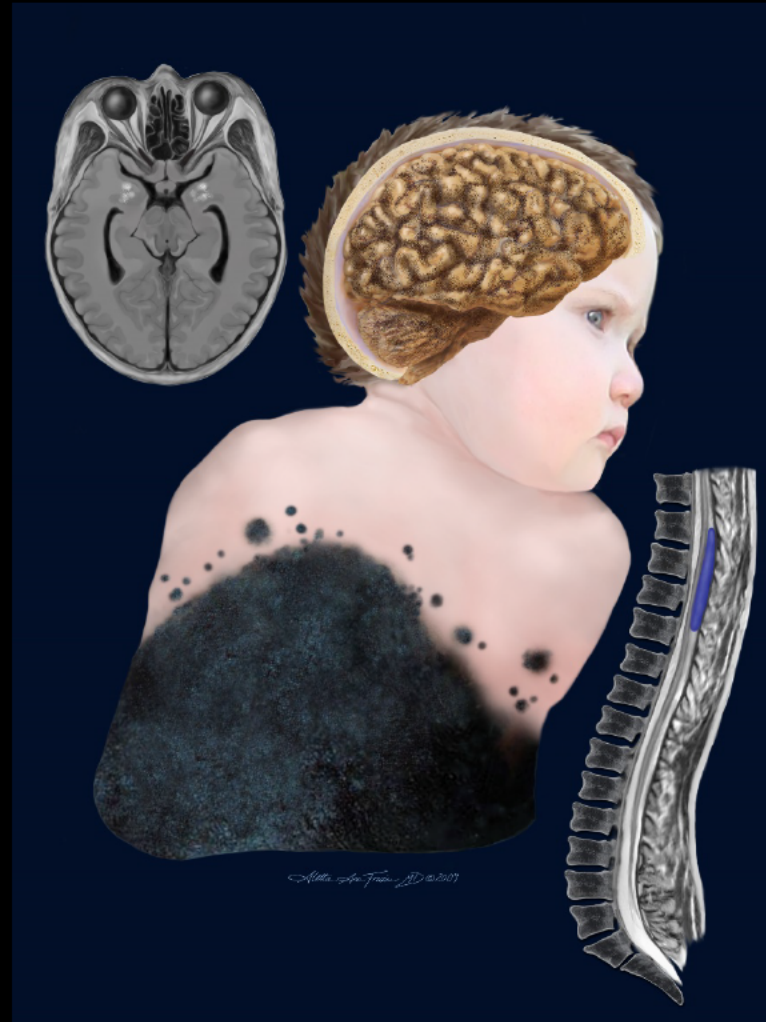
Stanford, CA



**AMERICAN INSTITUTE FOR
RADIOLOGIC PATHOLOGY**

**A PROGRAM OF THE
AMERICAN COLLEGE OF RADIOLOGY**

Neuroradiology Best Case



AIRPTM

AMERICAN INSTITUTE FOR
RADIOLOGIC PATHOLOGY

A PROGRAM OF THE
AMERICAN COLLEGE OF RADIOLOGY

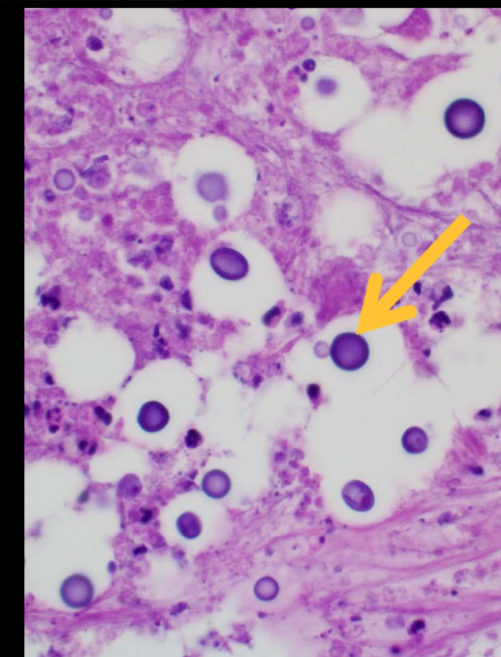
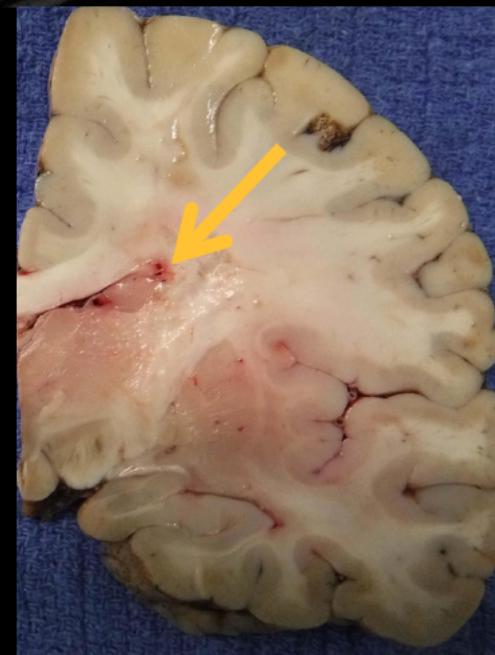
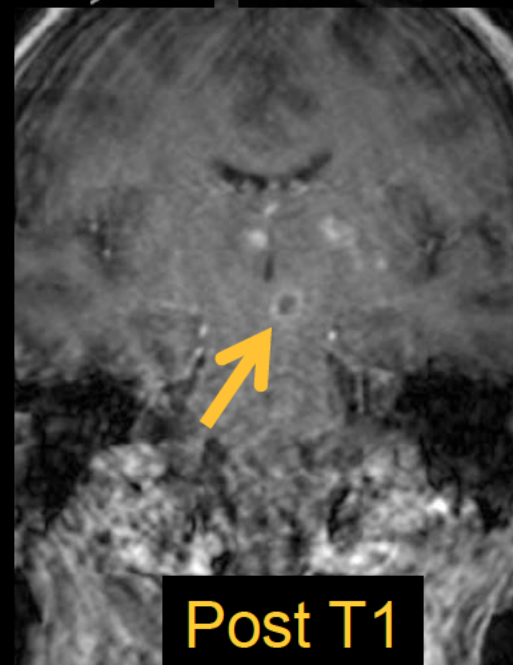
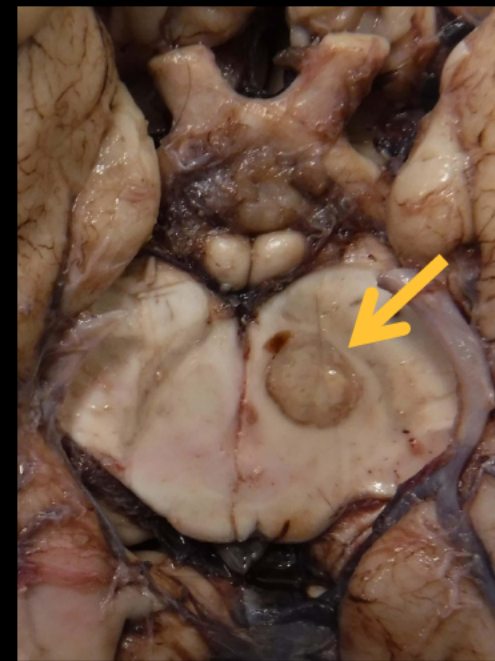
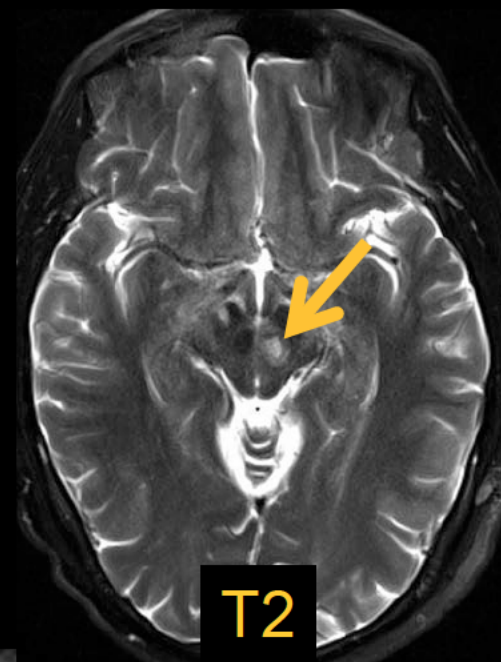
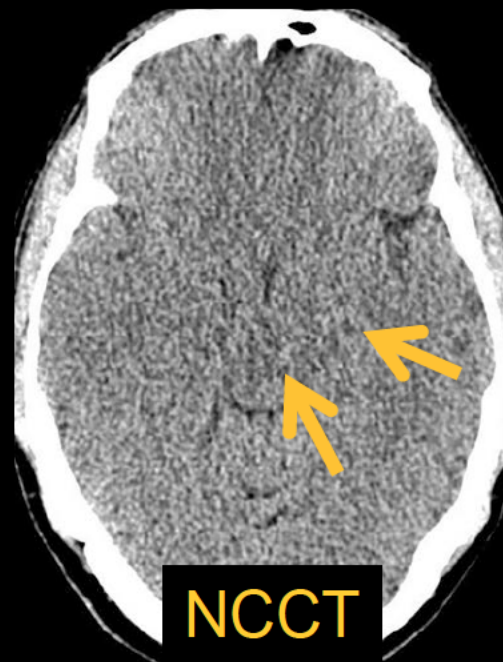
Clinical Information

39-year-old male with history of substance abuse, chronic hepatitis B and C with decompensated cirrhosis. Altered mental status upon presentation to ER.



AMERICAN INSTITUTE FOR
RADIOLOGIC PATHOLOGY

A PROGRAM OF THE
AMERICAN COLLEGE OF RADIOLOGY



Cryptococcosis

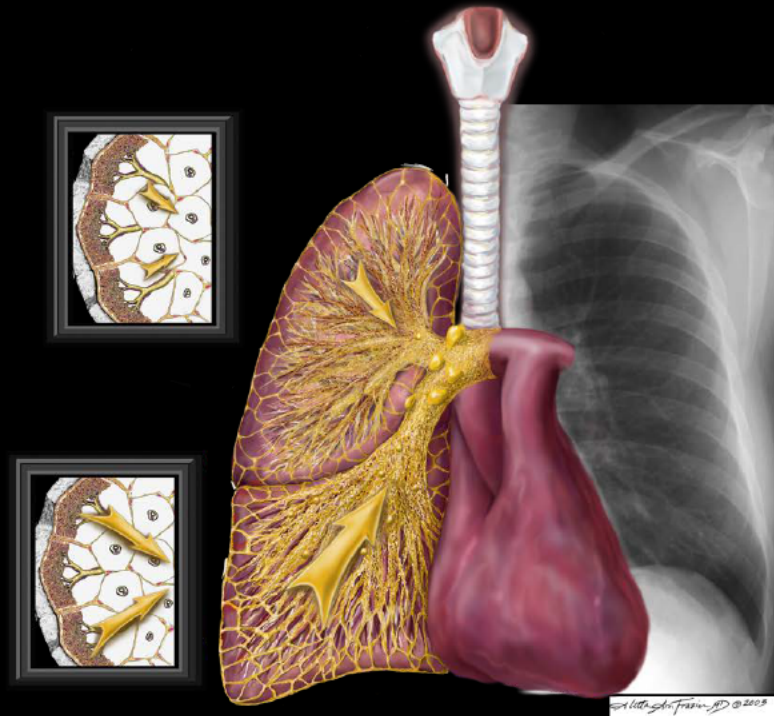
Mauro Hanaoka, M.D.
University of Kentucky
Lexington, Kentucky



AMERICAN INSTITUTE FOR
RADIOLOGIC PATHOLOGY

A PROGRAM OF THE
AMERICAN COLLEGE OF RADIOLOGY

Pulmonary and Mediastinal Best Case



AIRP™

AMERICAN INSTITUTE FOR
RADIOLOGIC PATHOLOGY

A PROGRAM OF THE
AMERICAN COLLEGE OF RADIOLOGY

Clinical information

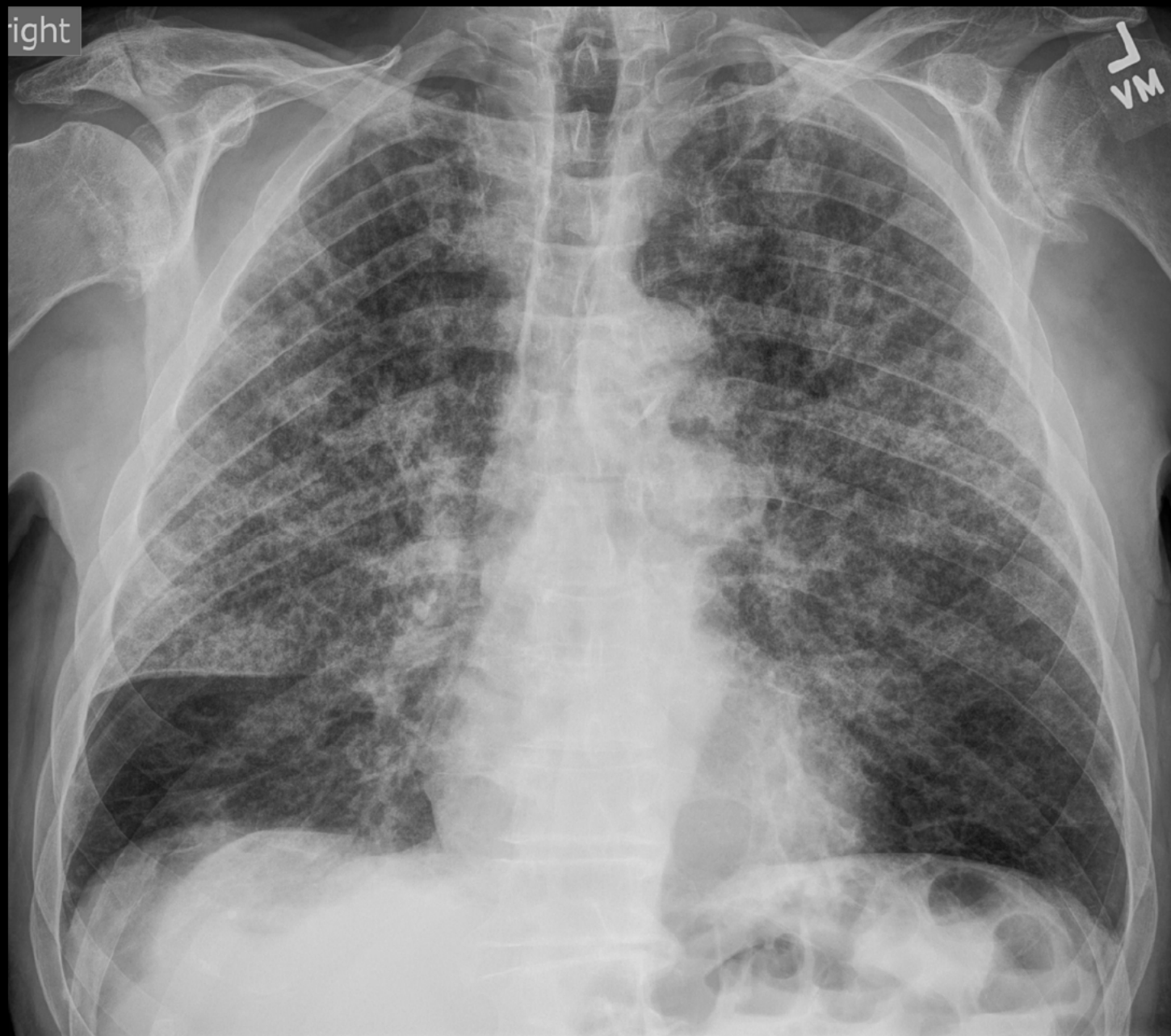
71-year-old male with progressive shortness of breath and new hemoptysis, despite recent treatment for presumed pneumonia at outside medical practice.

Additional history of 100-pack year smoking with prior exposure history to asbestos and agent orange.



**AMERICAN INSTITUTE FOR
RADIOLOGIC PATHOLOGY**

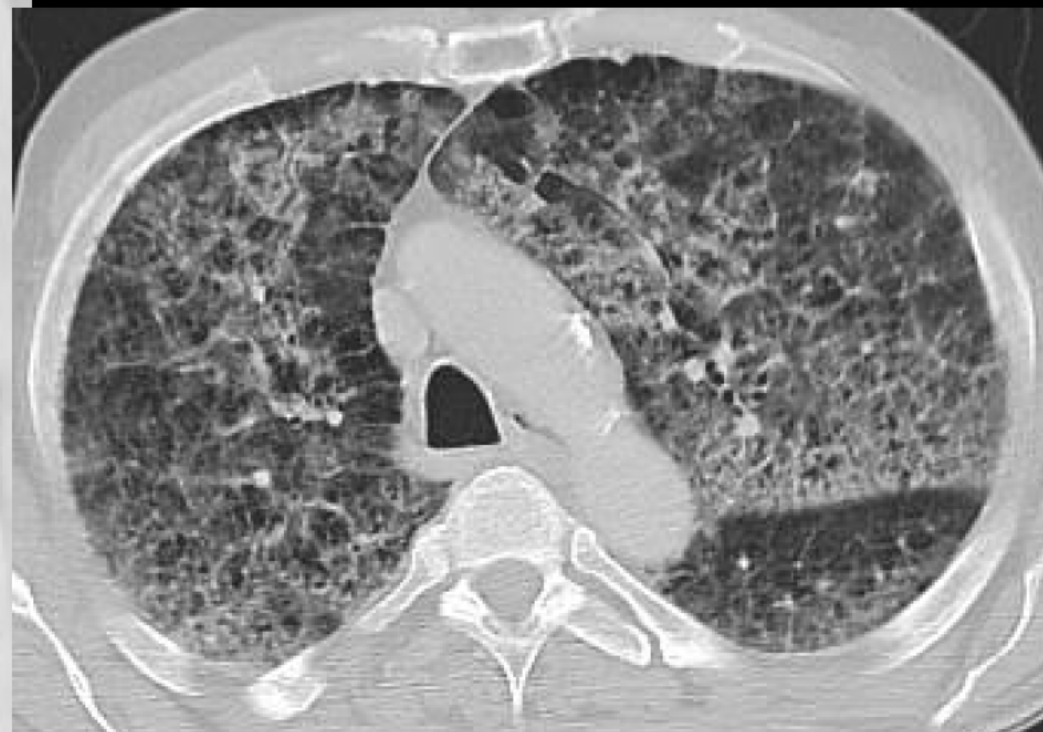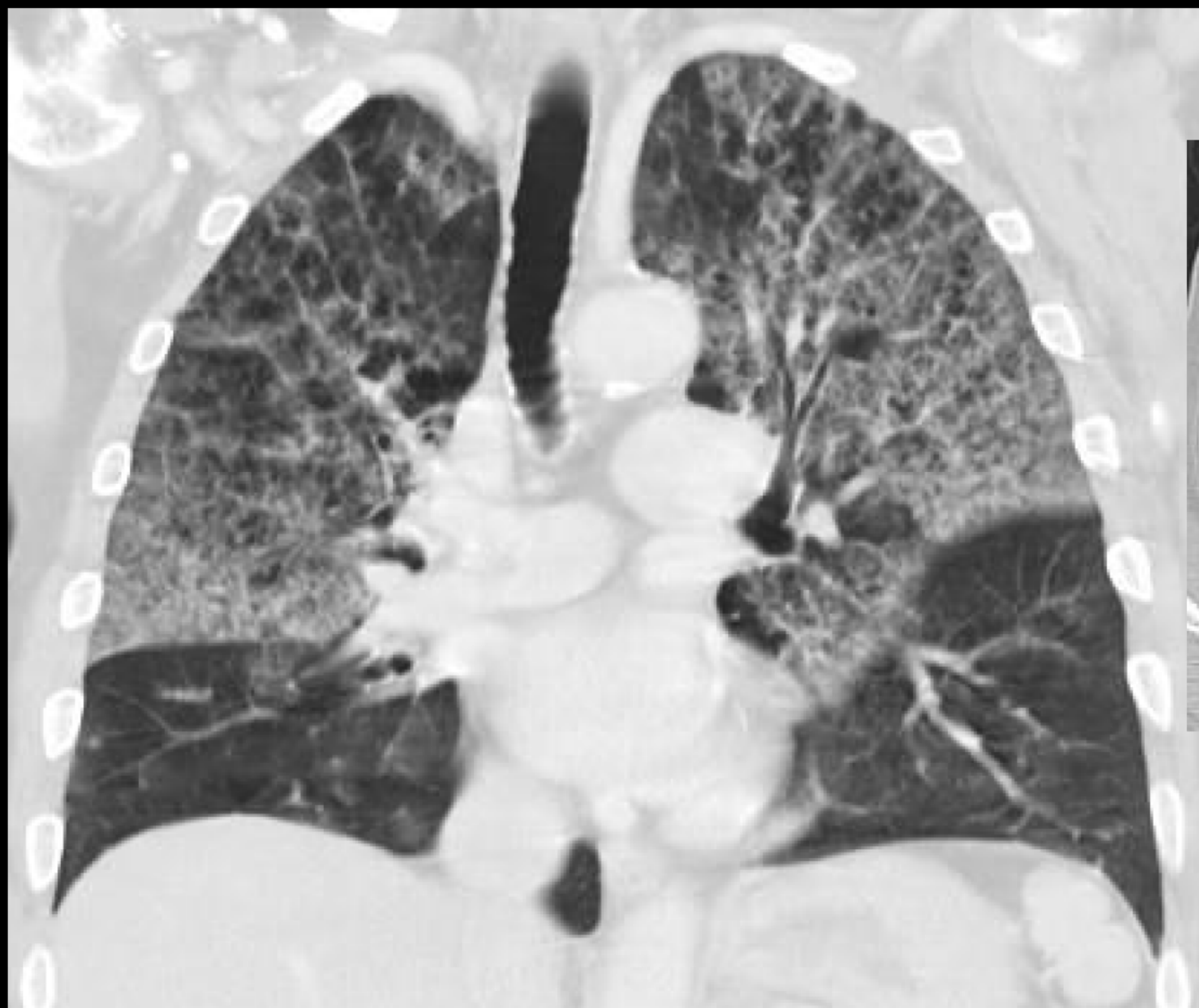**A PROGRAM OF THE
AMERICAN COLLEGE OF RADIOLOGY**

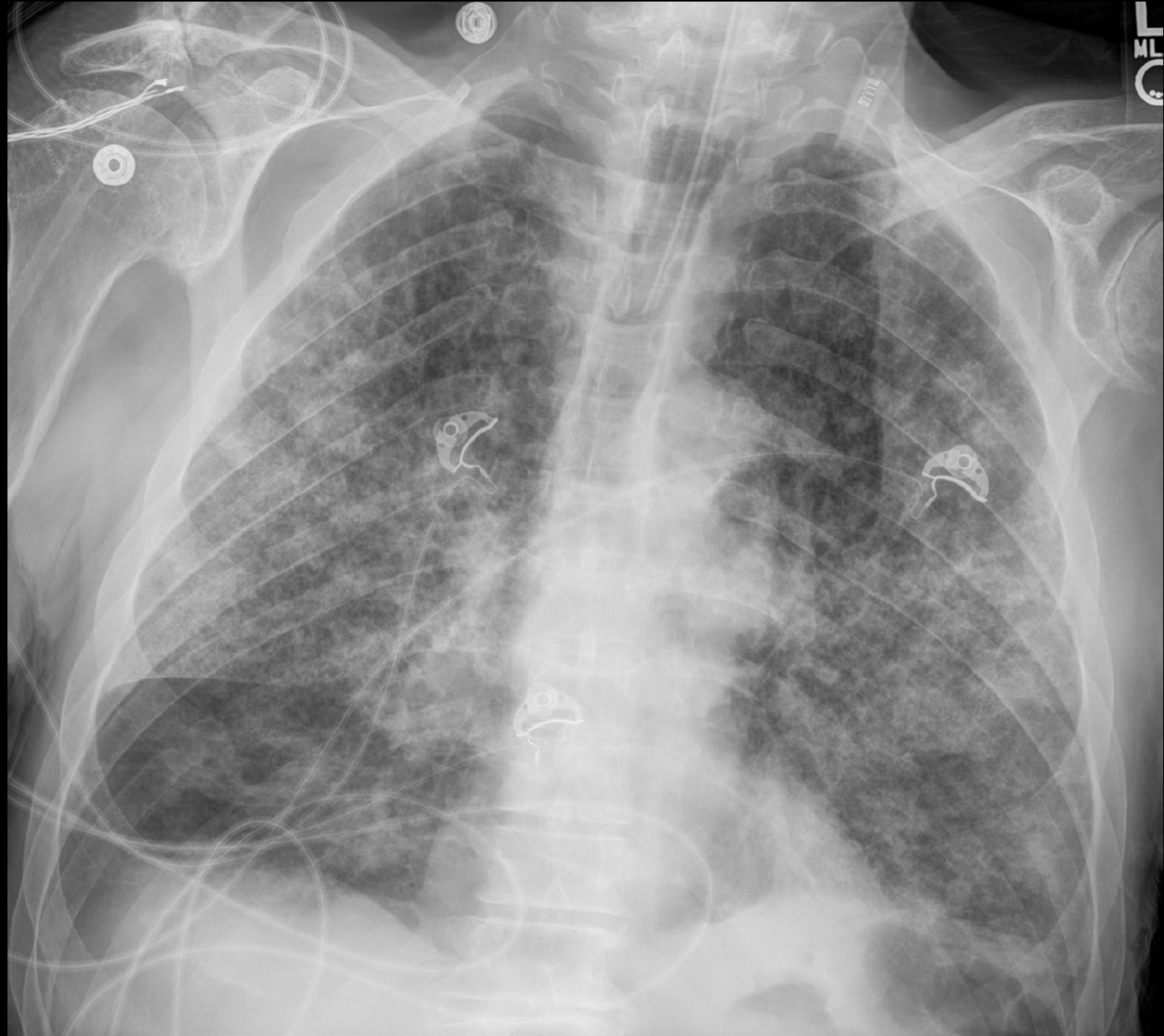
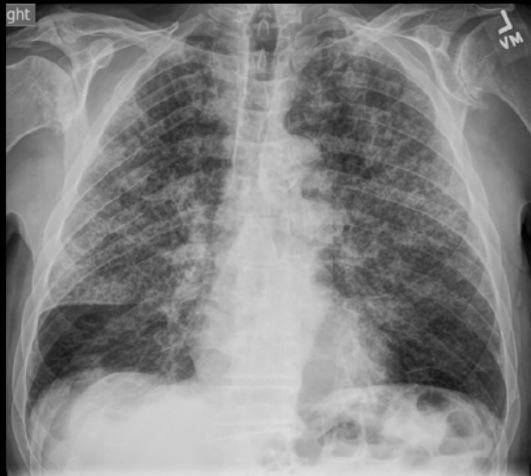
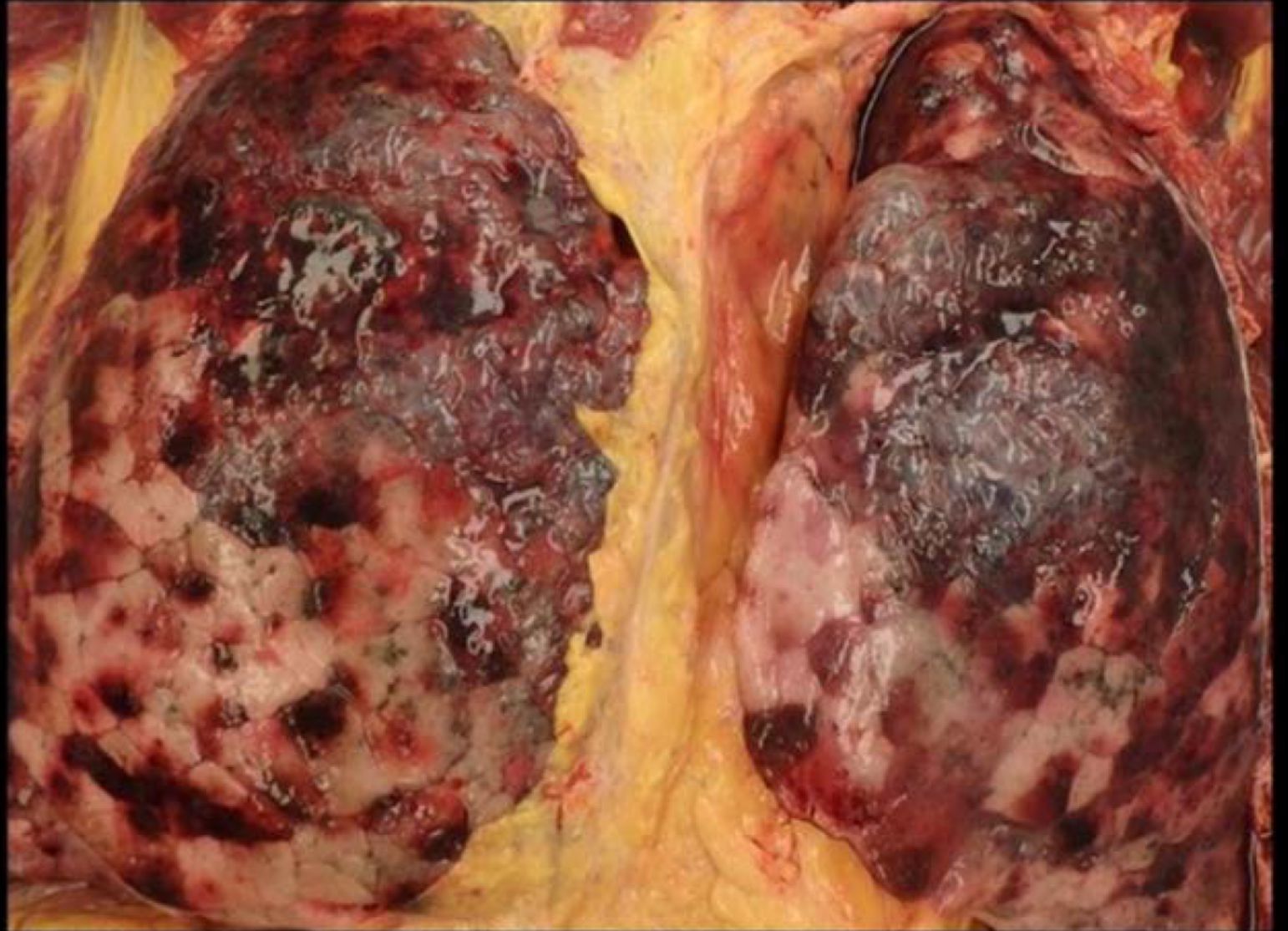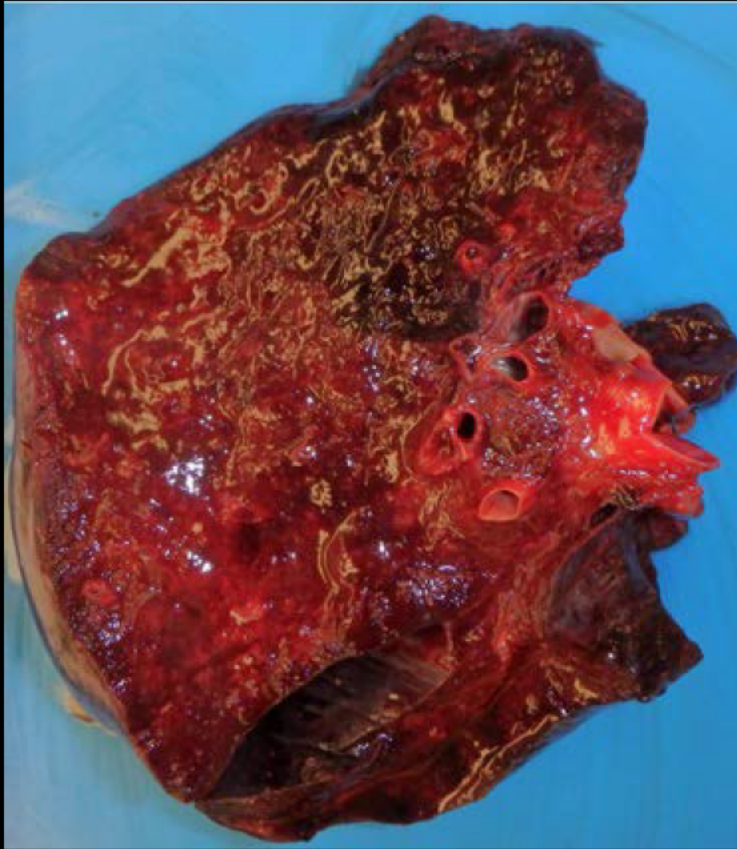
AIRPTM

AMERICAN INSTITUTE FOR
RADIOLOGIC PATHOLOGY

A PROGRAM OF THE
AMERICAN COLLEGE OF RADIOLOGY



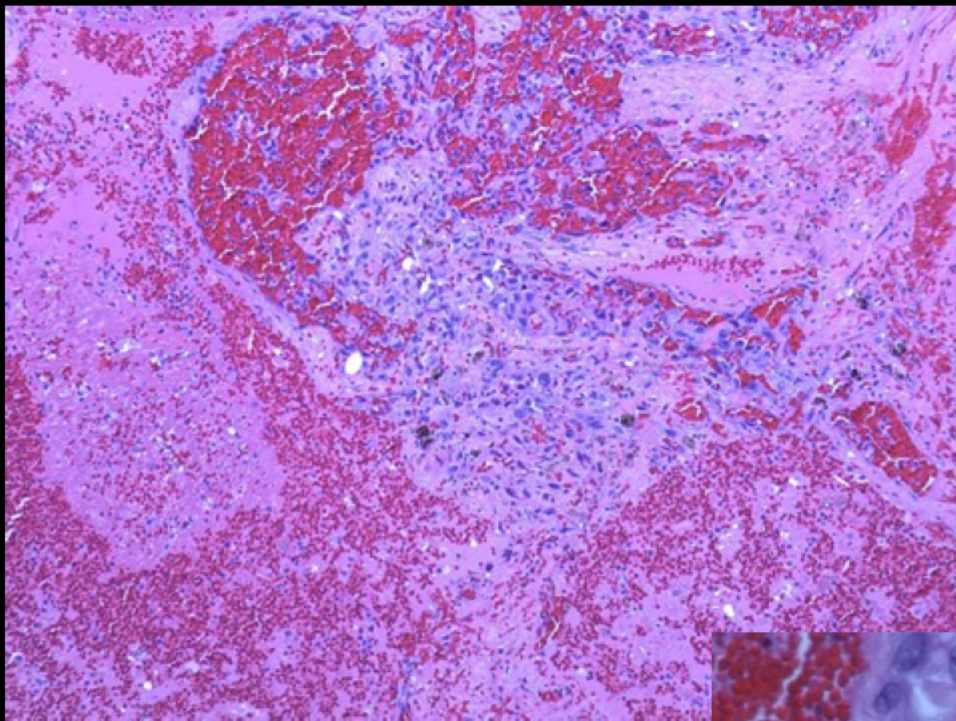




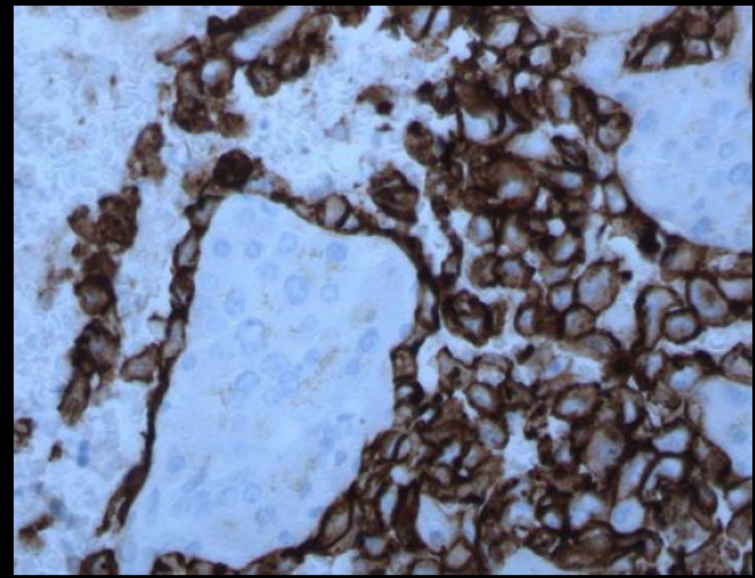
AIRPTM

AMERICAN INSTITUTE FOR
RADIOLOGIC PATHOLOGY

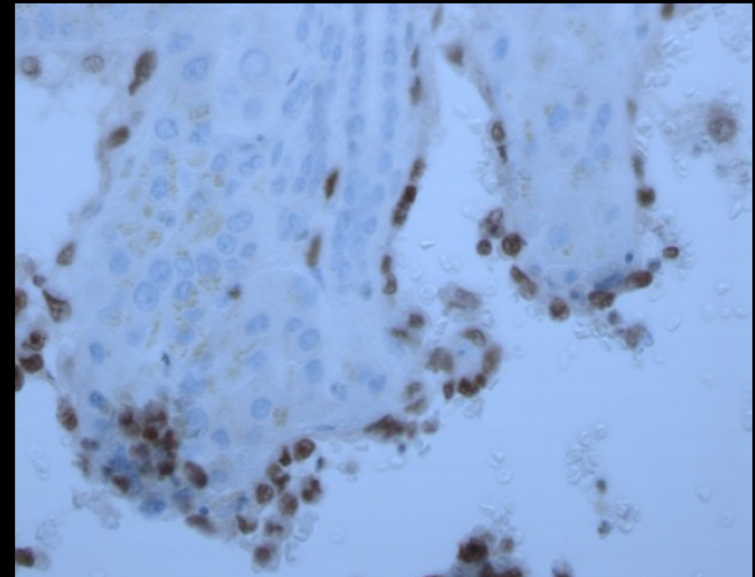
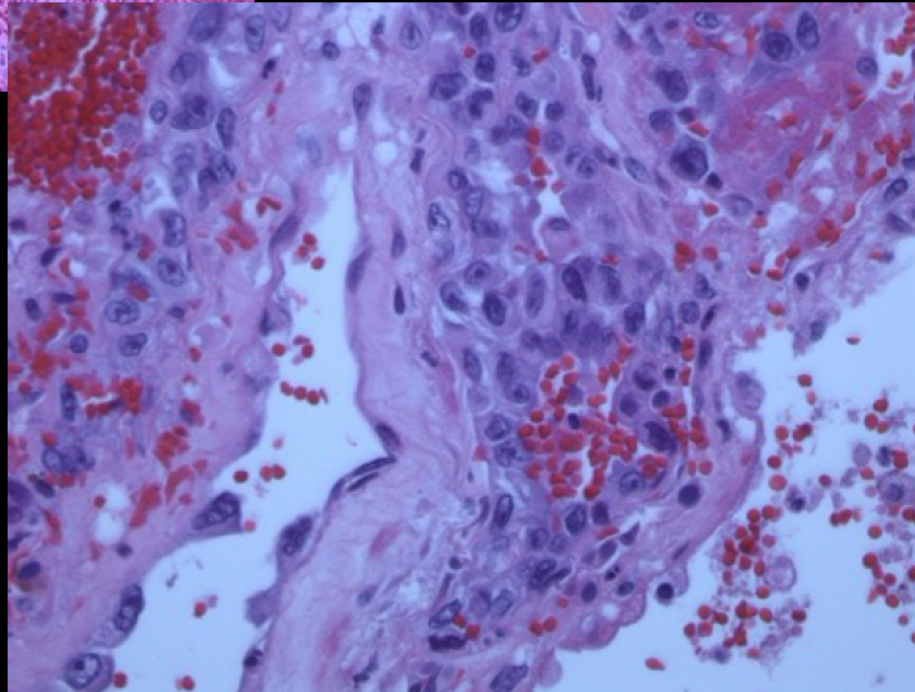
A PROGRAM OF THE
AMERICAN COLLEGE OF RADIOLOGY



H&E
Hemorrhage
With
atypical endothelial cells
w/abundant cytoplasm



CD 31 positivity

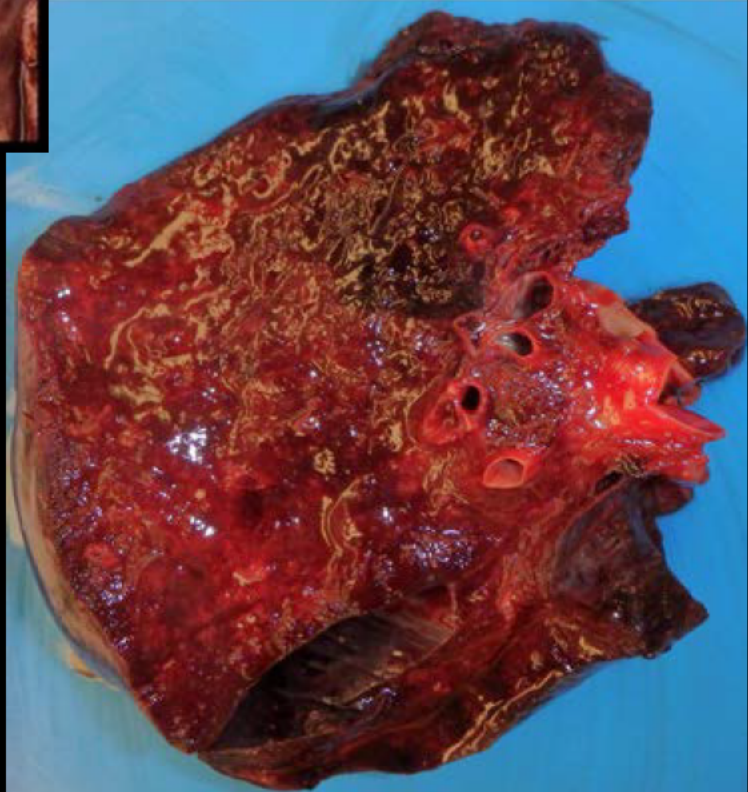
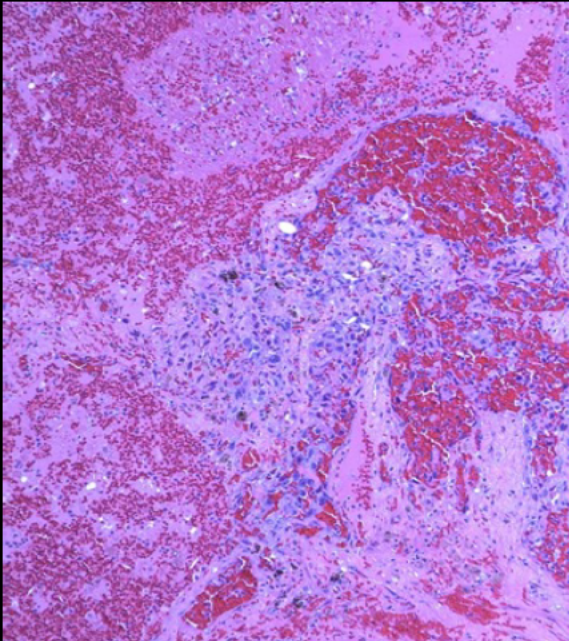
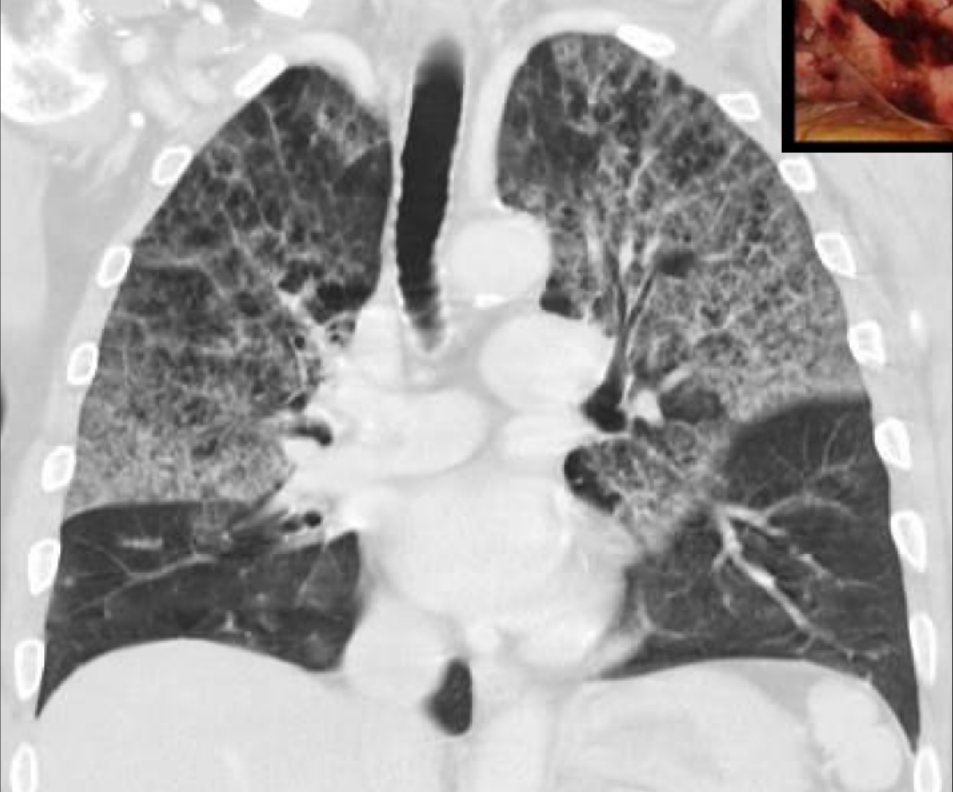
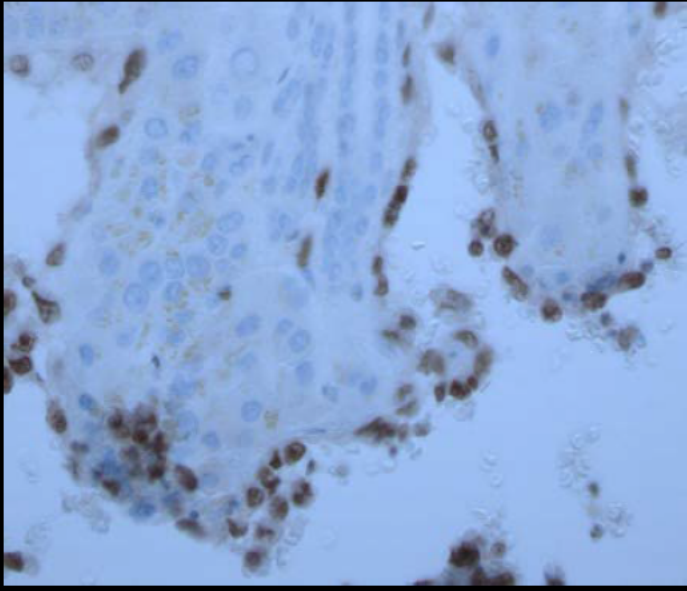
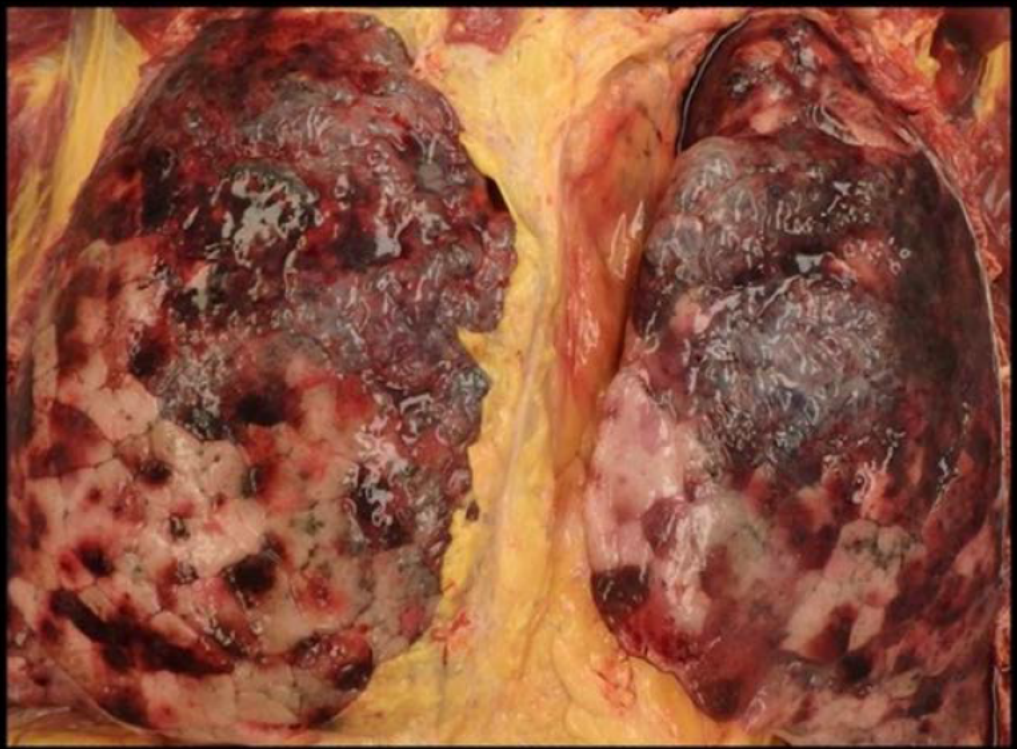
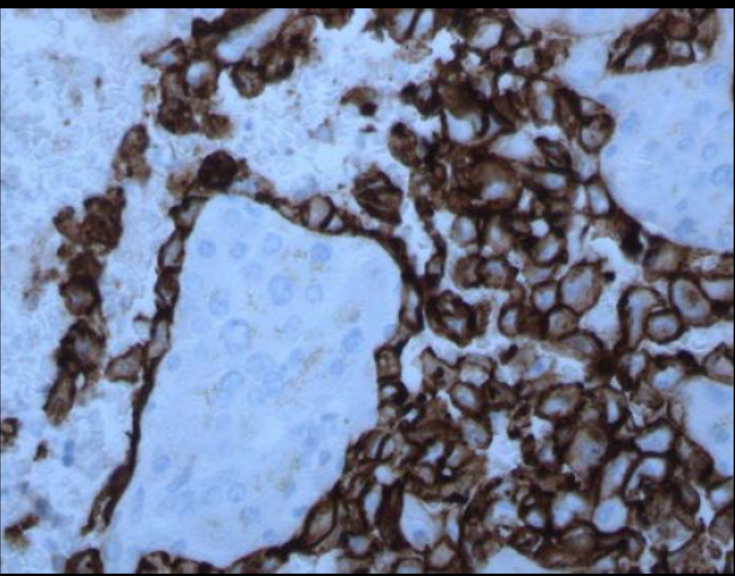


ERG Nuclear Stain

AIRPTM

AMERICAN INSTITUTE FOR
RADIOLOGIC PATHOLOGY

A PROGRAM OF THE
AMERICAN COLLEGE OF RADIOLOGY



Primary Pulmonary Angiosarcoma

Molly Downey, MD

Oregon Health & Science University

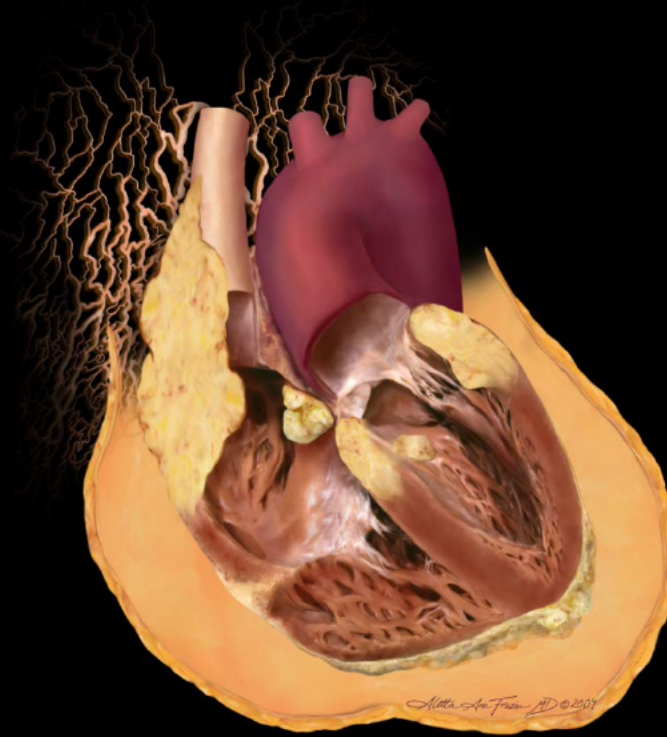
Portland, Oregon

AIRPTM

AMERICAN INSTITUTE FOR
RADIOLOGIC PATHOLOGY

A PROGRAM OF THE
AMERICAN COLLEGE OF RADIOLOGY

Cardiovascular Best Case



AIRP™

AMERICAN INSTITUTE FOR
RADIOLOGIC PATHOLOGY

A PROGRAM OF THE
AMERICAN COLLEGE OF RADIOLOGY

Clinical information

69-year-old woman with shortness of breath and tearing back pain.



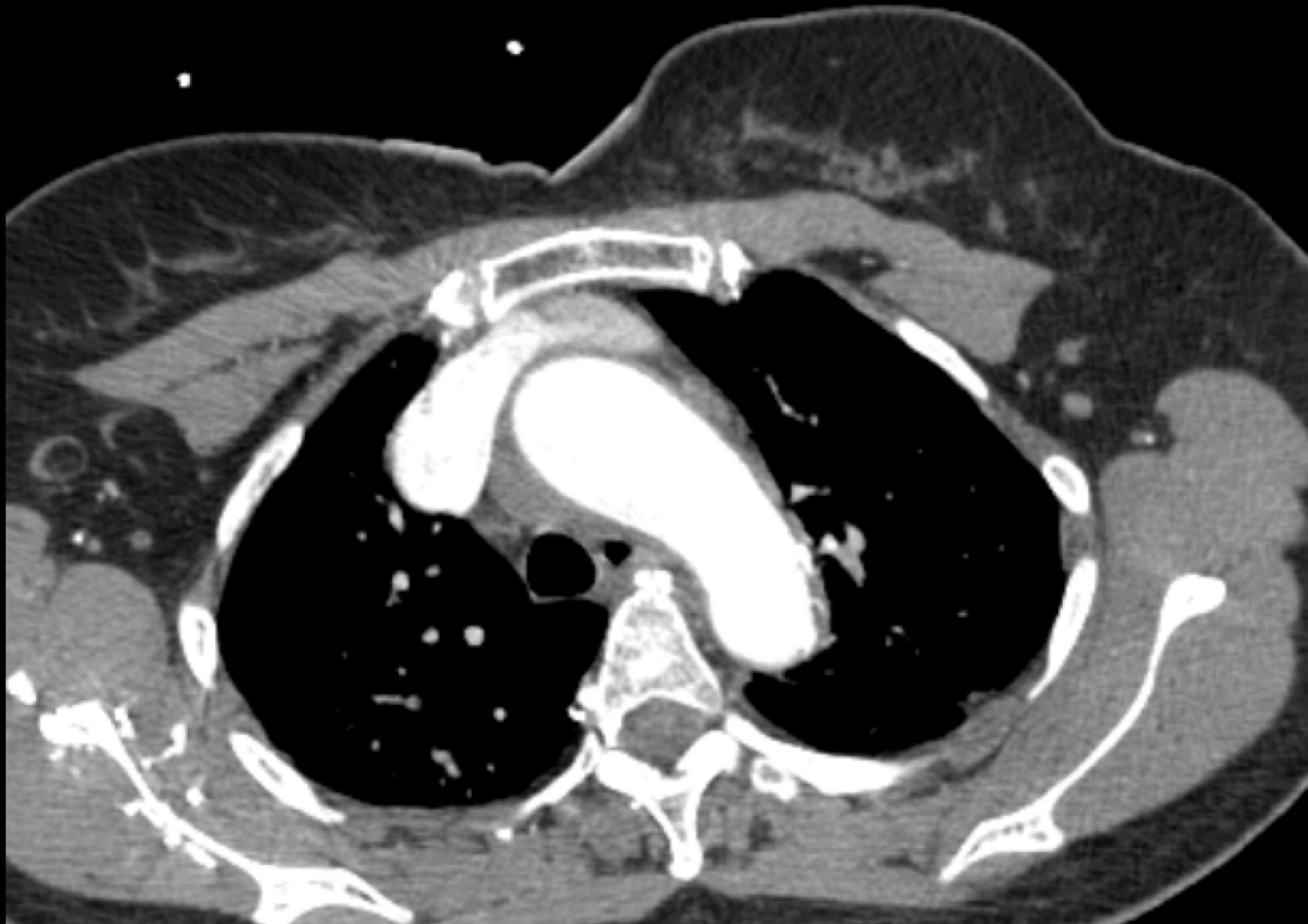AMERICAN INSTITUTE FOR
RADIOLOGIC PATHOLOGY

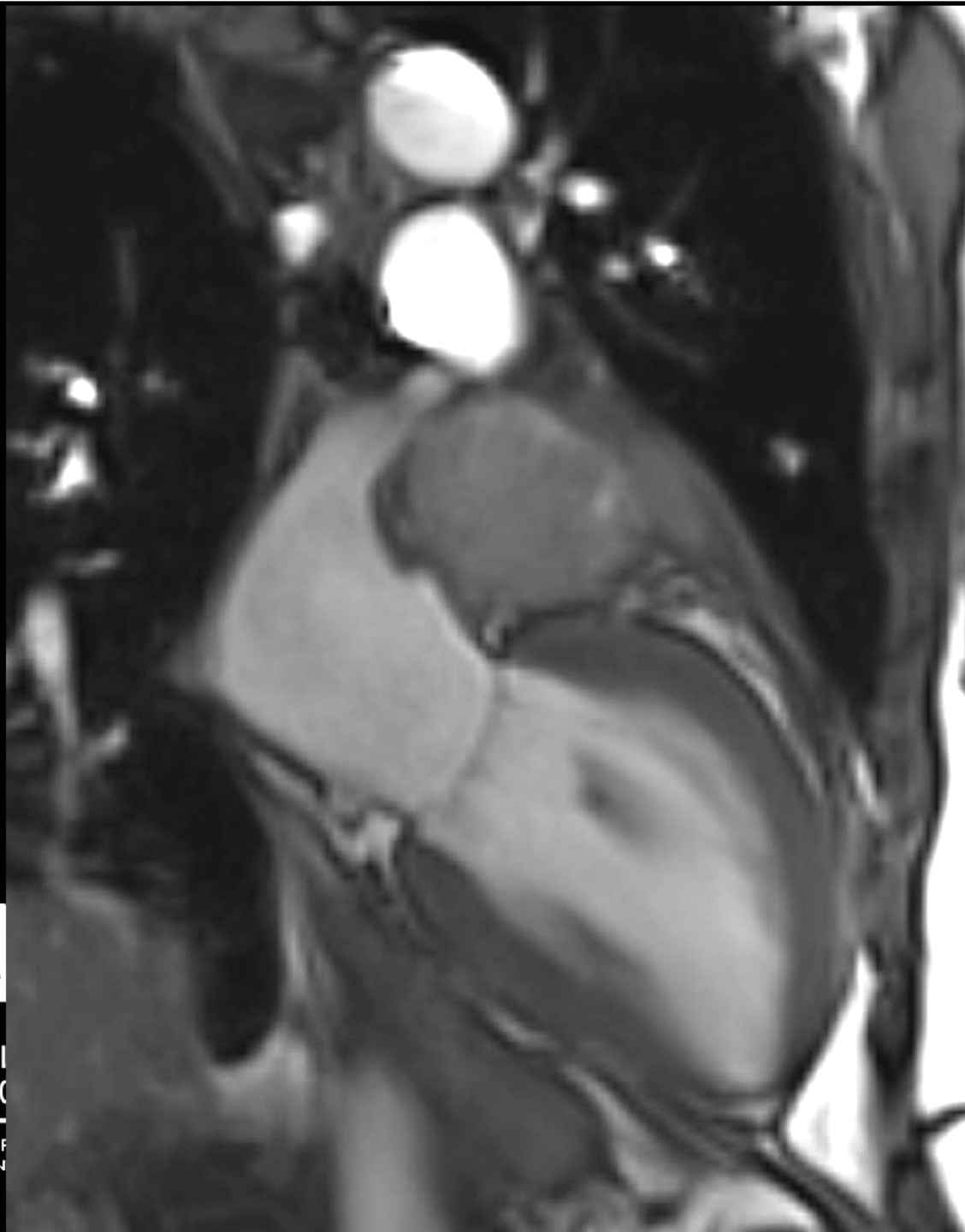
A PROGRAM OF THE
AMERICAN COLLEGE OF RADIOLOGY

AIRPTM

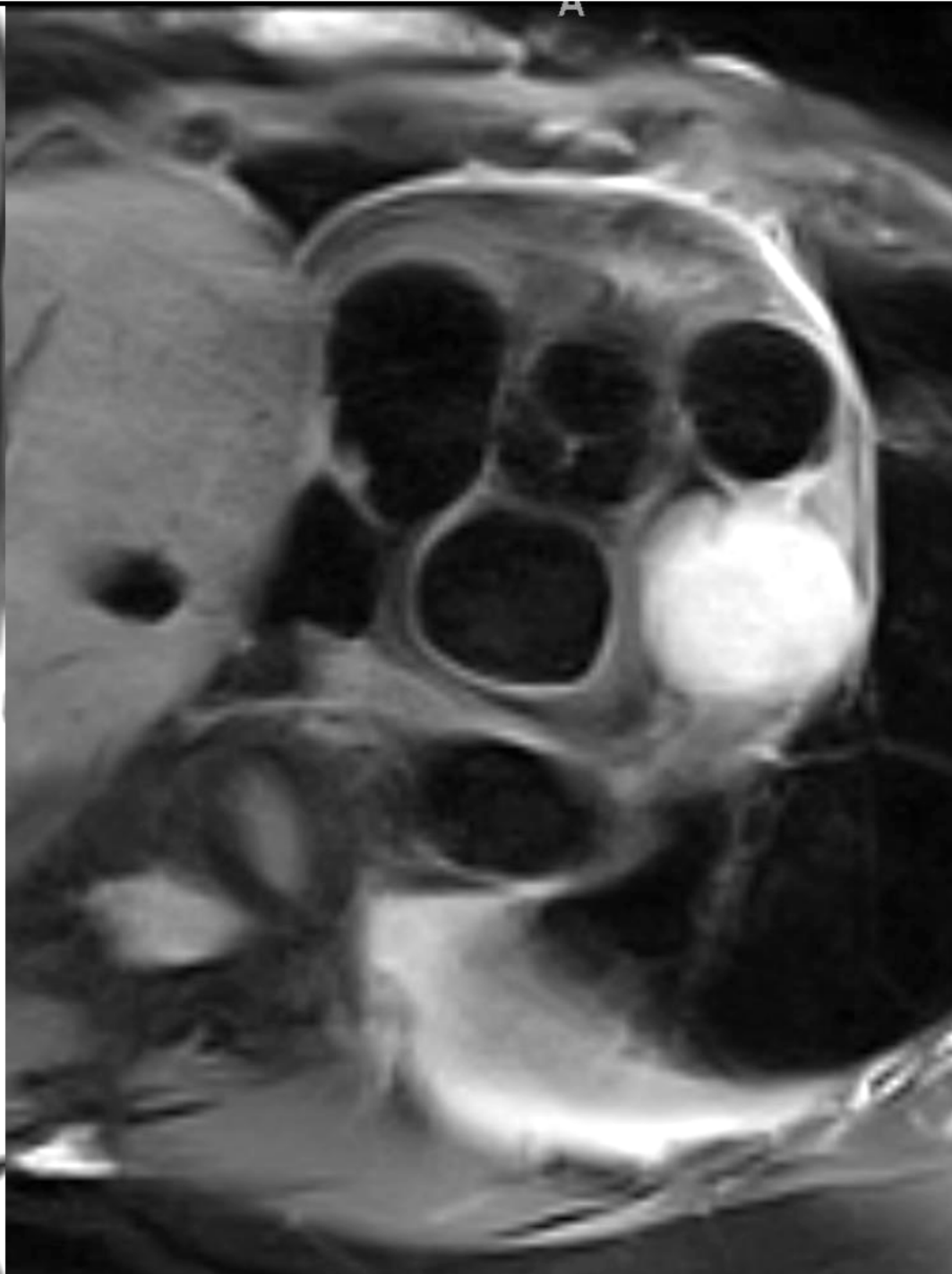
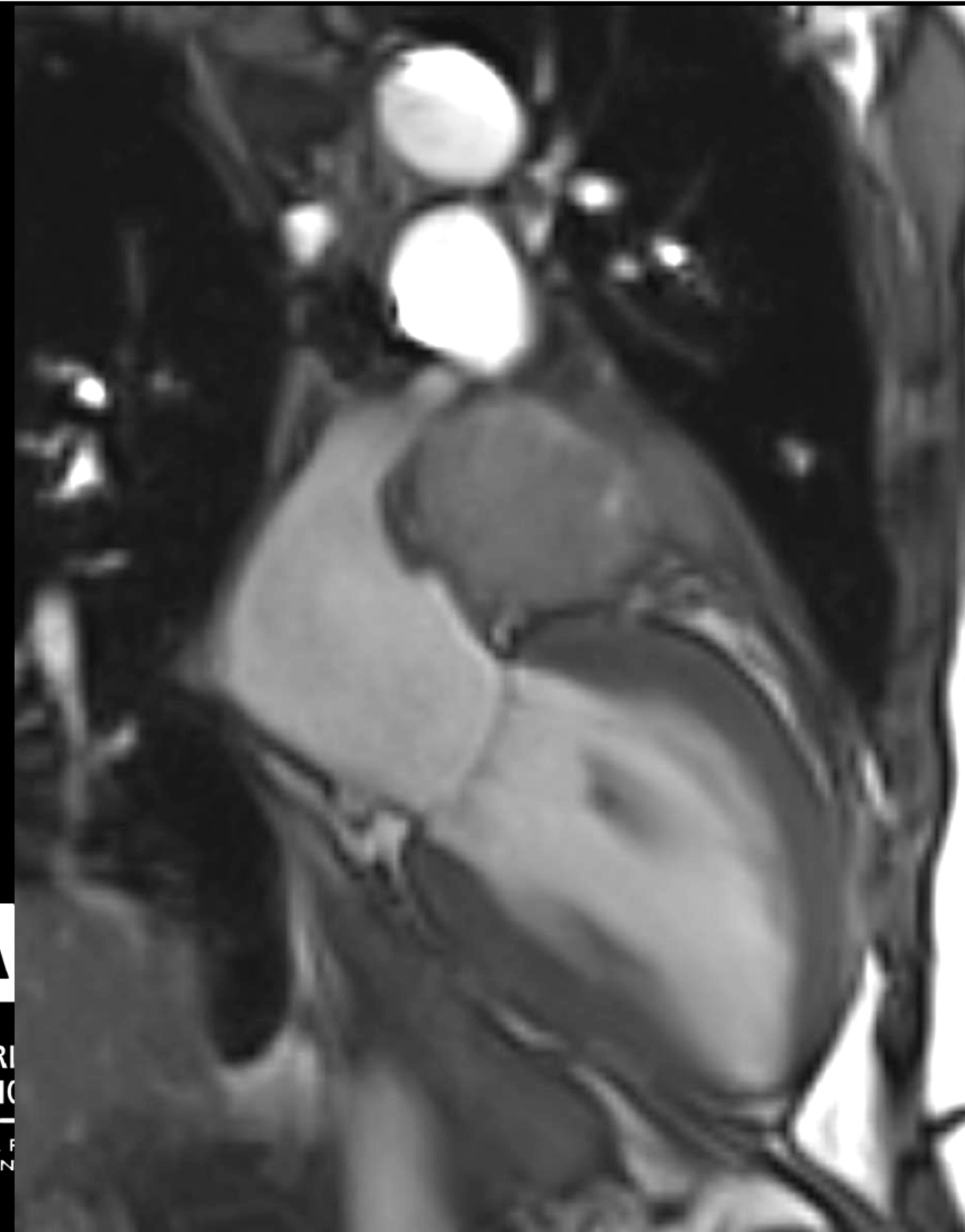
AMERICAN INSTITUTE FOR
RADIOLOGIC PATHOLOGY

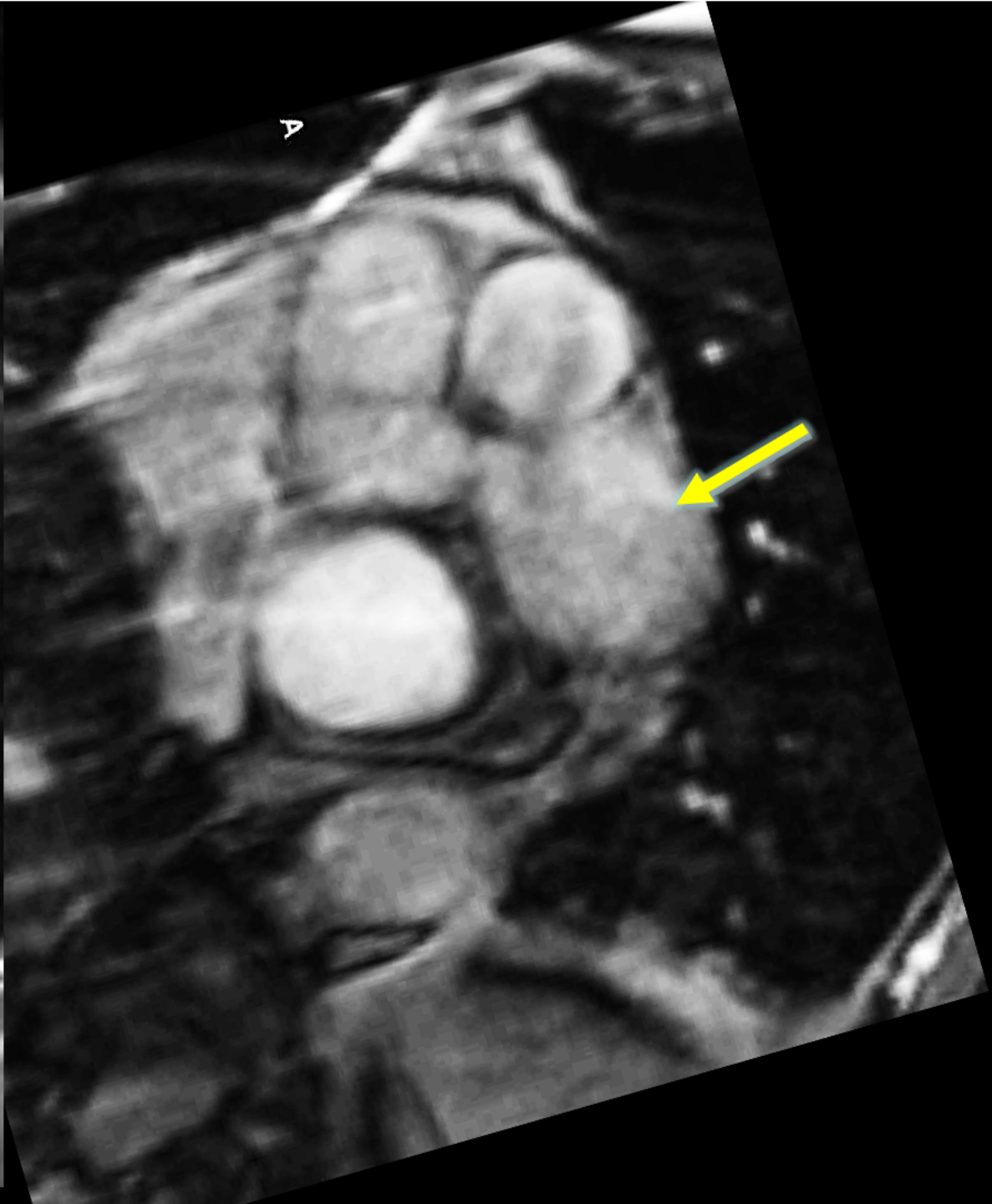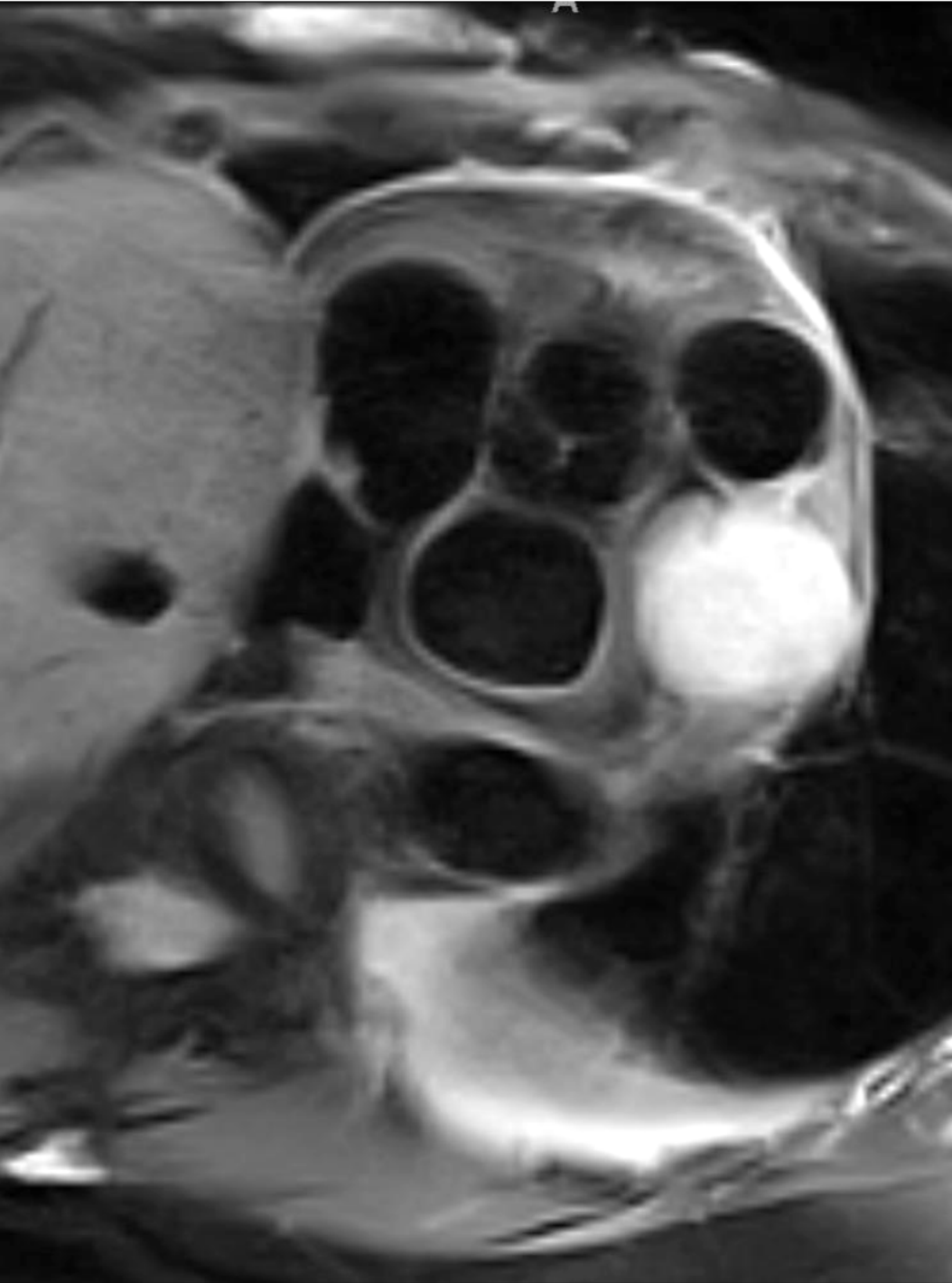
A PROGRAM OF THE
AMERICAN COLLEGE OF RADIOLOGY

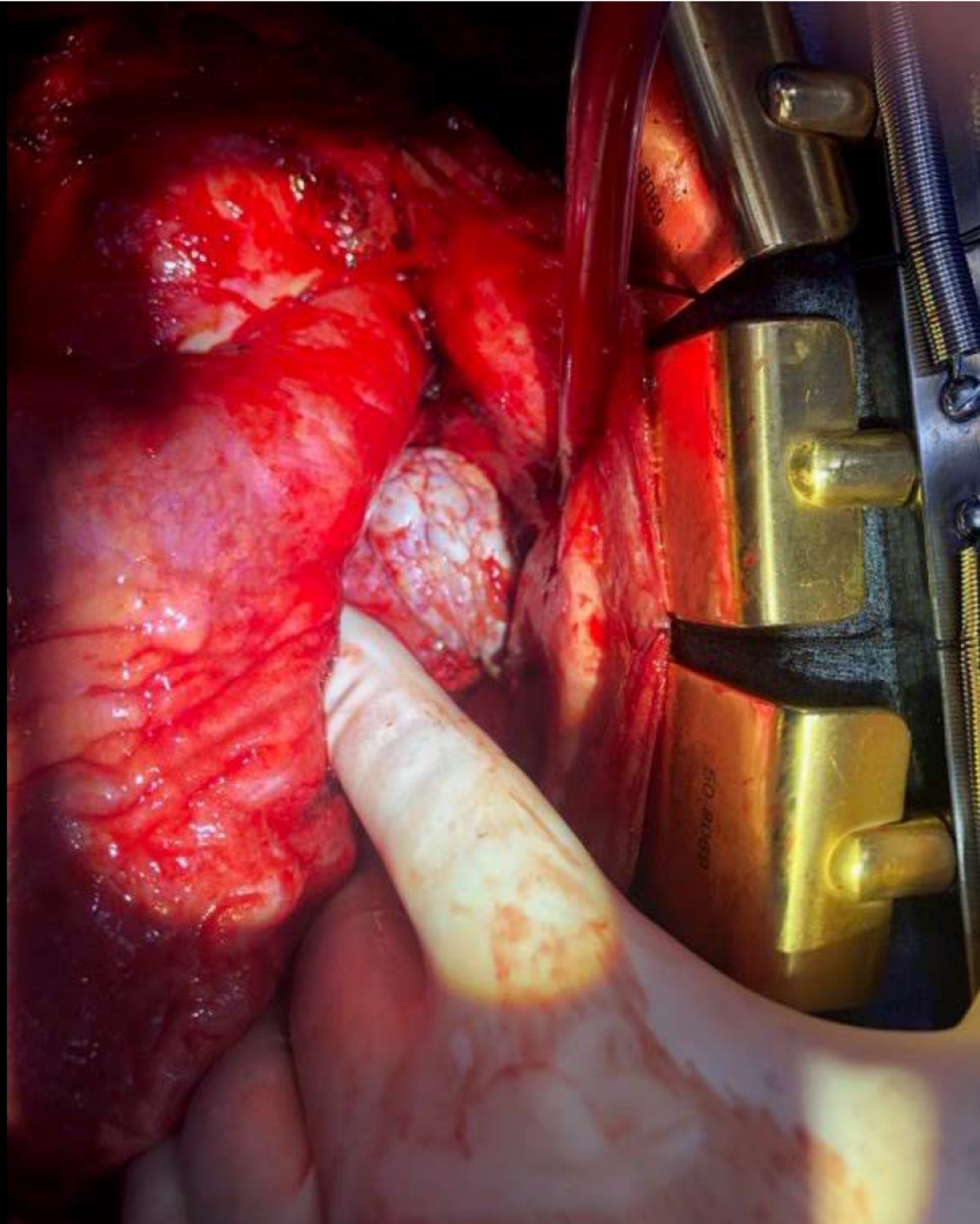


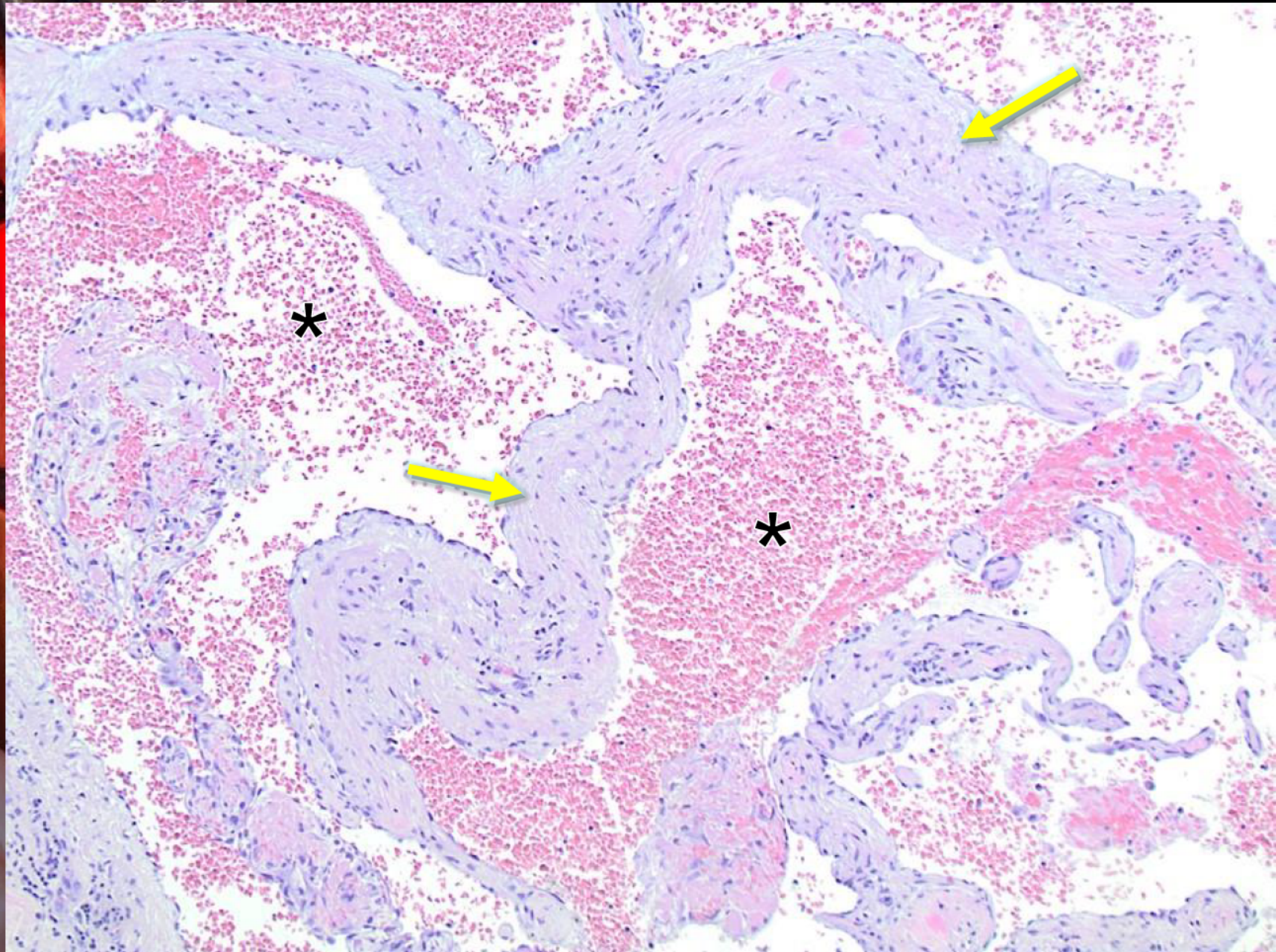
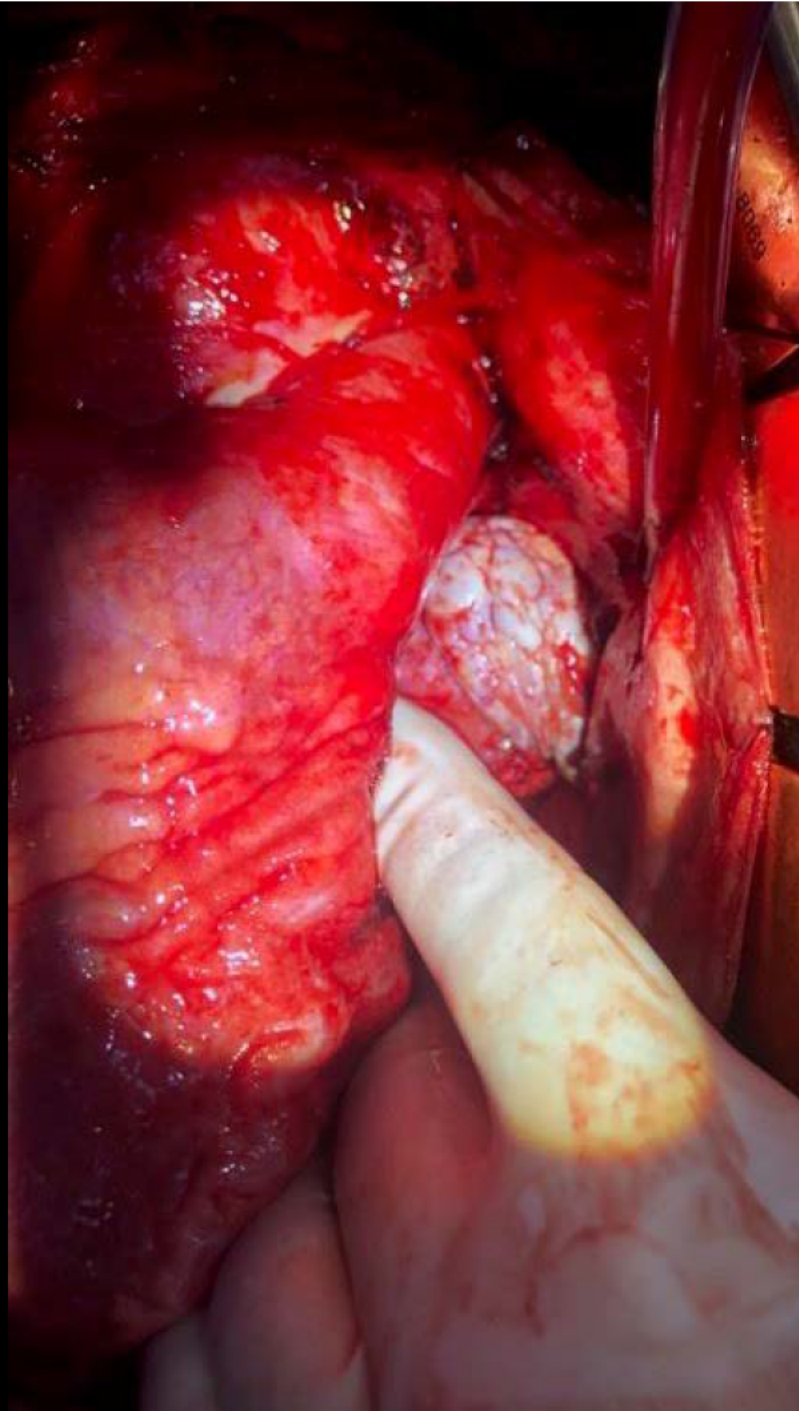


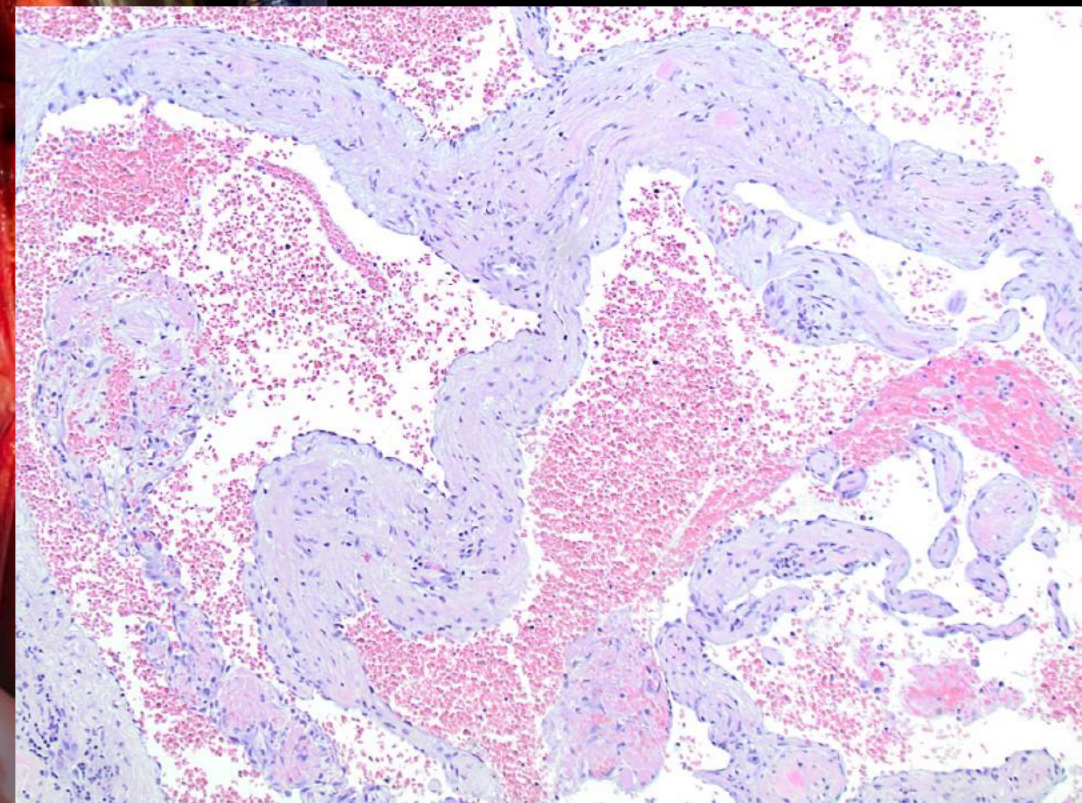
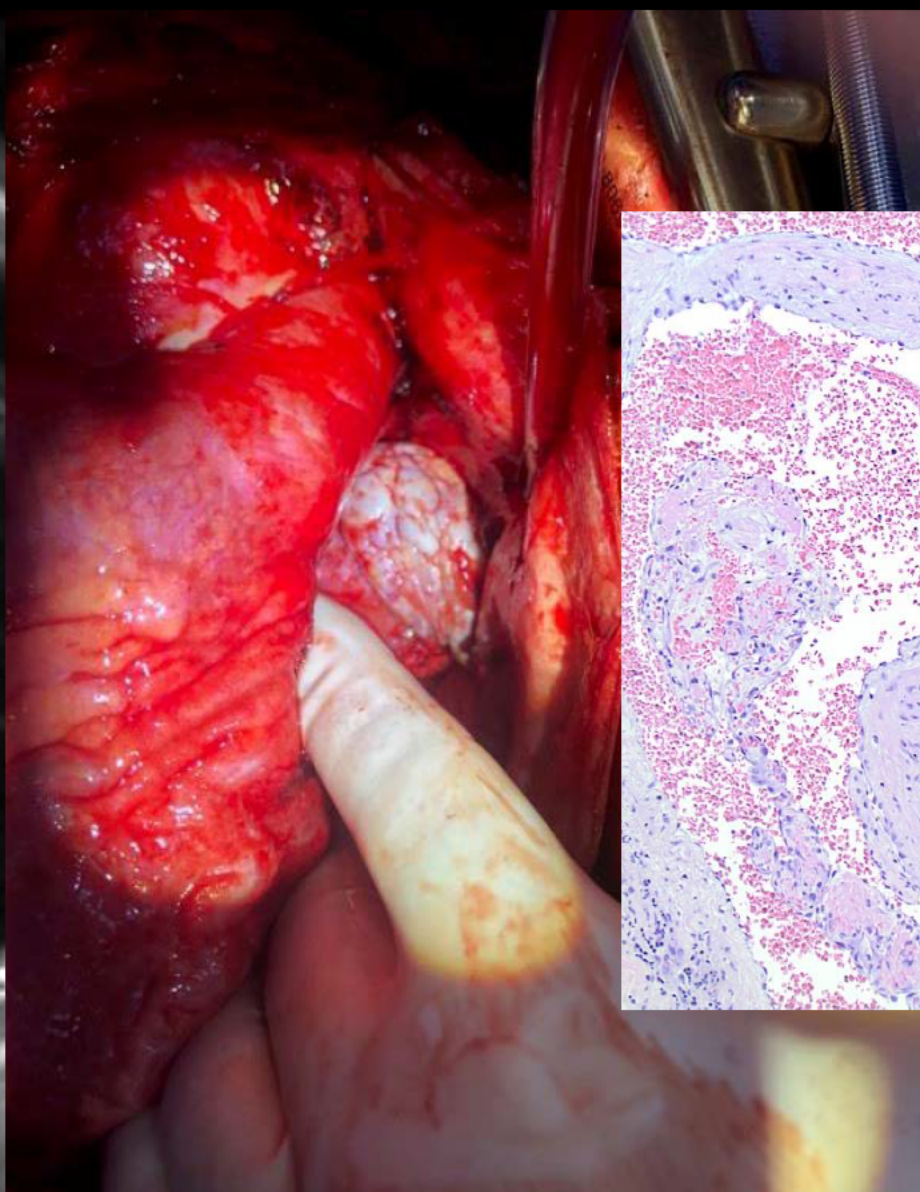
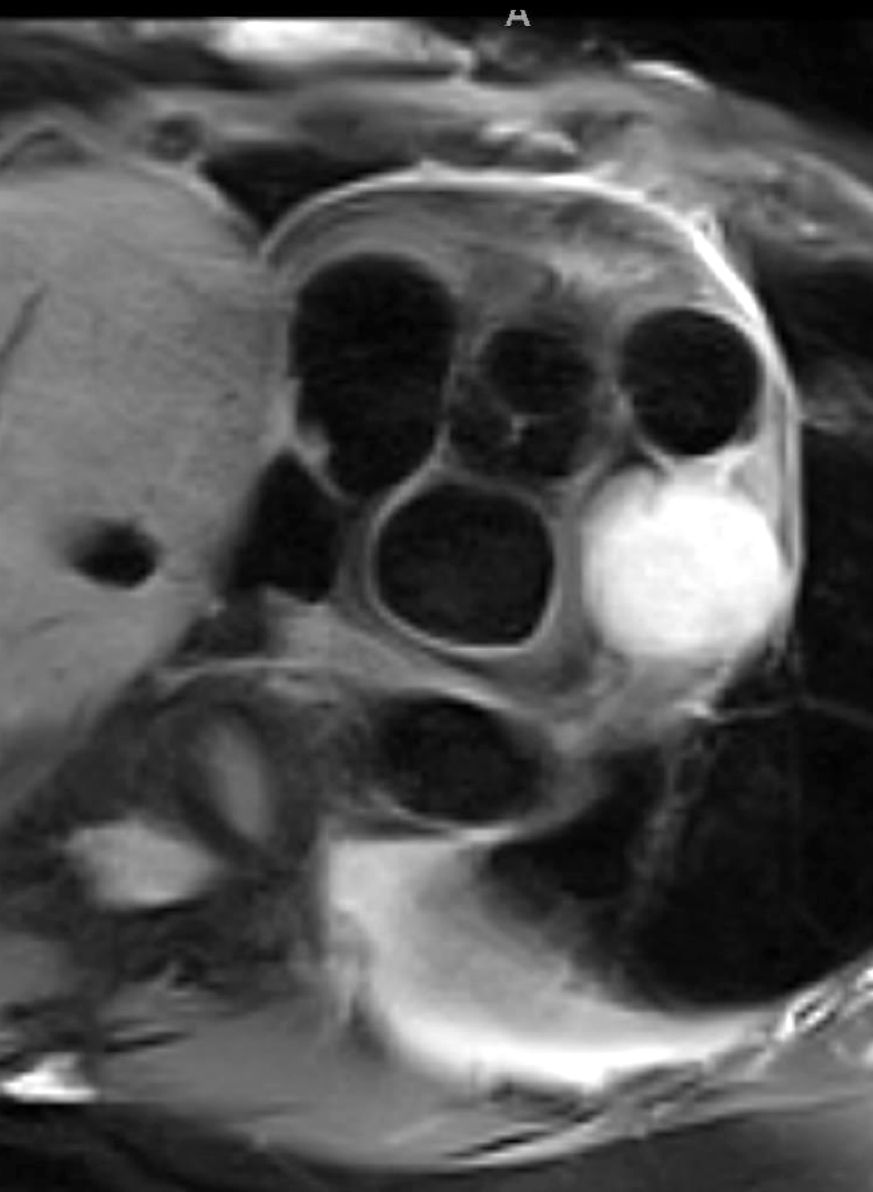
A











Cardiac Hemangioma

Blake Becker

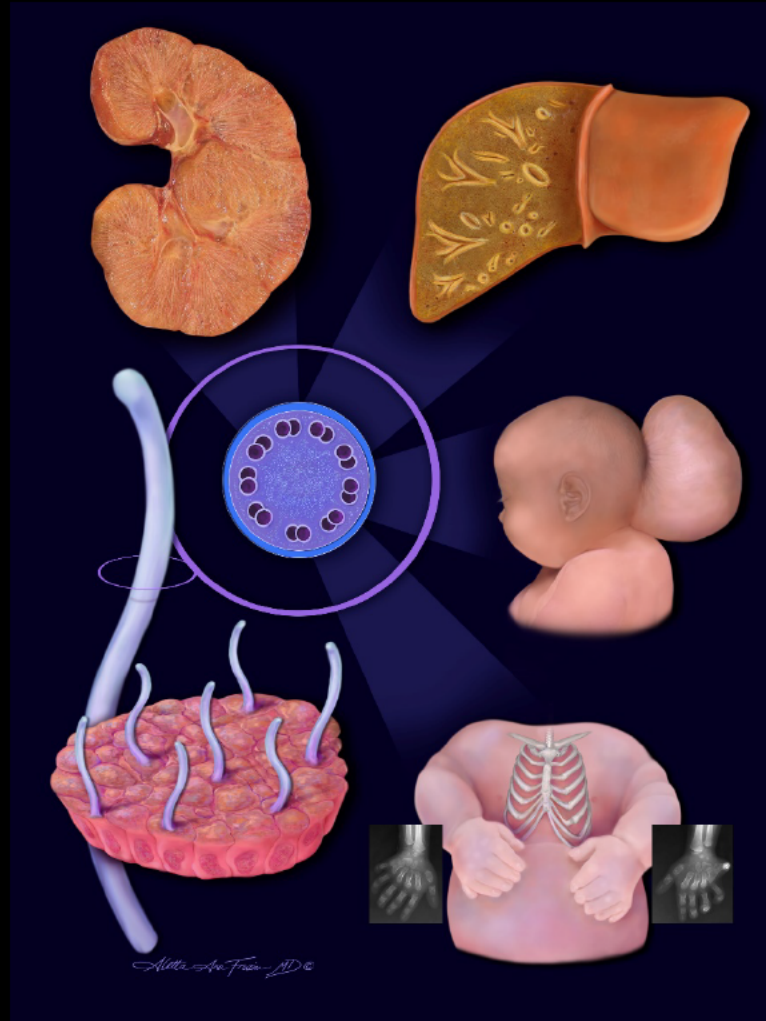
University of Mississippi Medical Center

AIRPTM

AMERICAN INSTITUTE FOR
RADIOLOGIC PATHOLOGY

A PROGRAM OF THE
AMERICAN COLLEGE OF RADIOLOGY

Pediatric Best Case



AIRP™

AMERICAN INSTITUTE FOR
RADIOLOGIC PATHOLOGY

A PROGRAM OF THE
AMERICAN COLLEGE OF RADIOLOGY

Clinical information

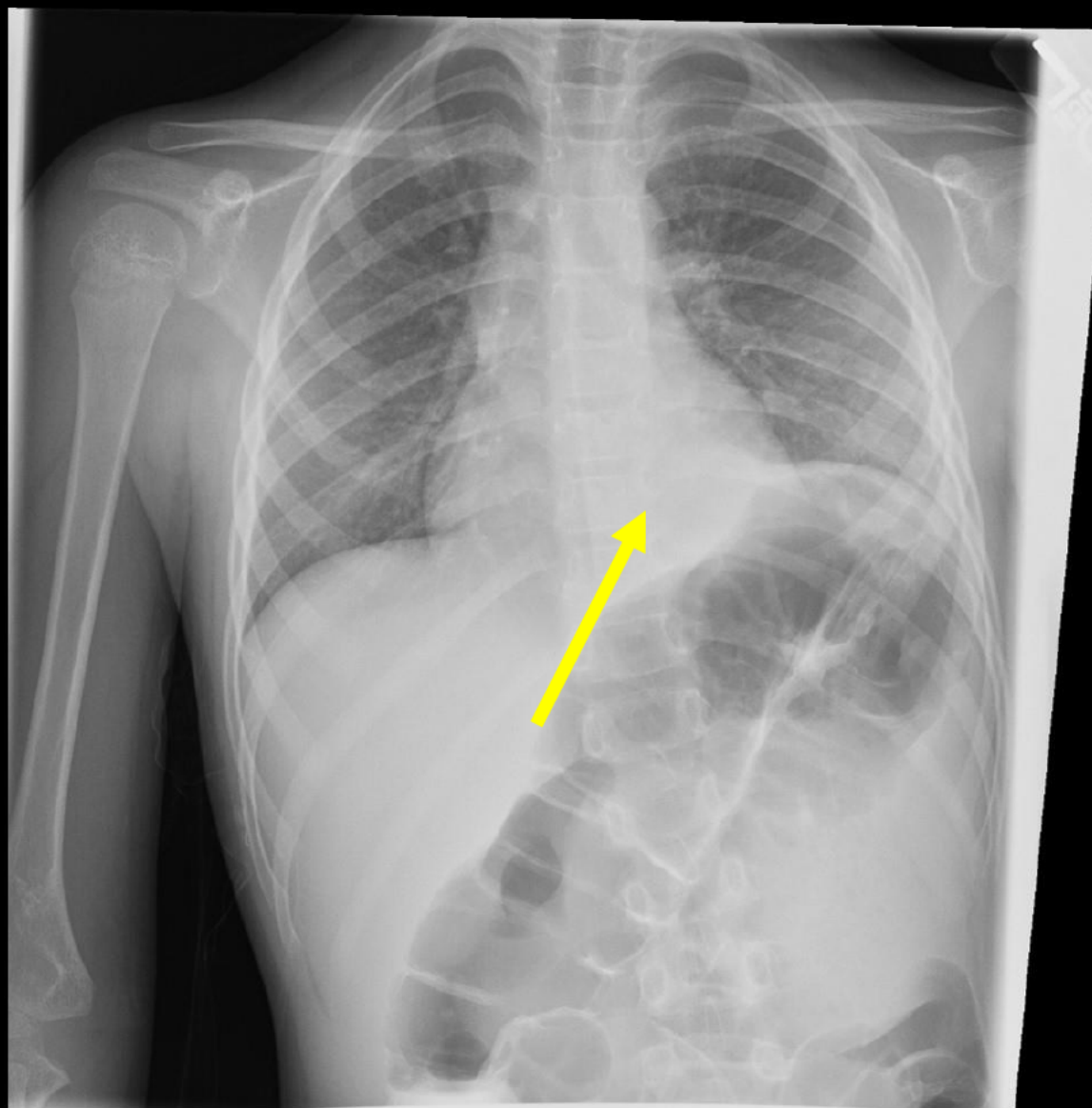
6-year-old boy presented to a community hospital emergency department with one night of increasing abdominal pain and anorexia. Pain developed into left sided chest pain

Frontal chest radiograph was performed.



**AMERICAN INSTITUTE FOR
RADIOLOGIC PATHOLOGY**

**A PROGRAM OF THE
AMERICAN COLLEGE OF RADIOLOGY**



AIRPTM

AMERICAN INSTITUTE FOR
RADIOLOGIC PATHOLOGY

A PROGRAM OF THE
AMERICAN COLLEGE OF RADIOLOGY

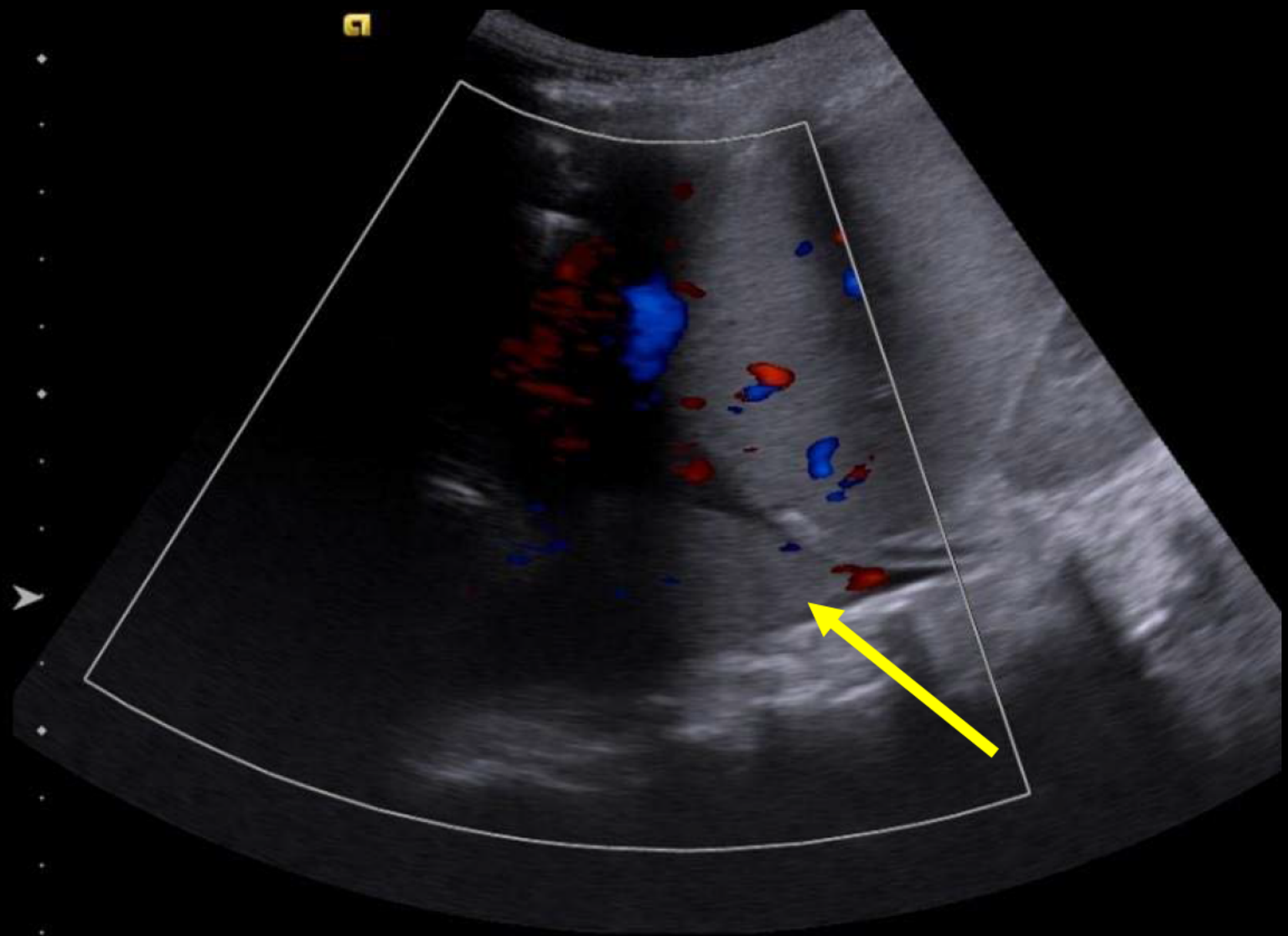
IR

31

31

cm/s

G



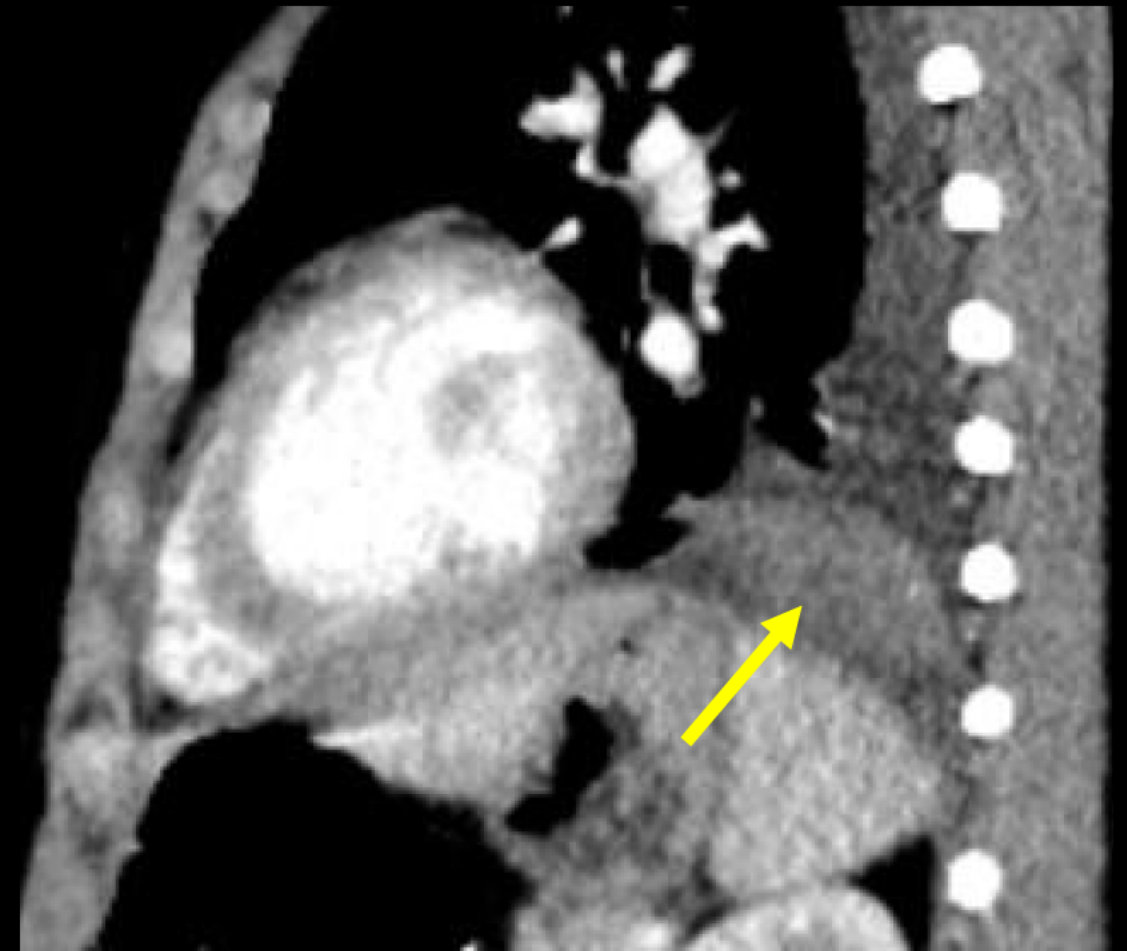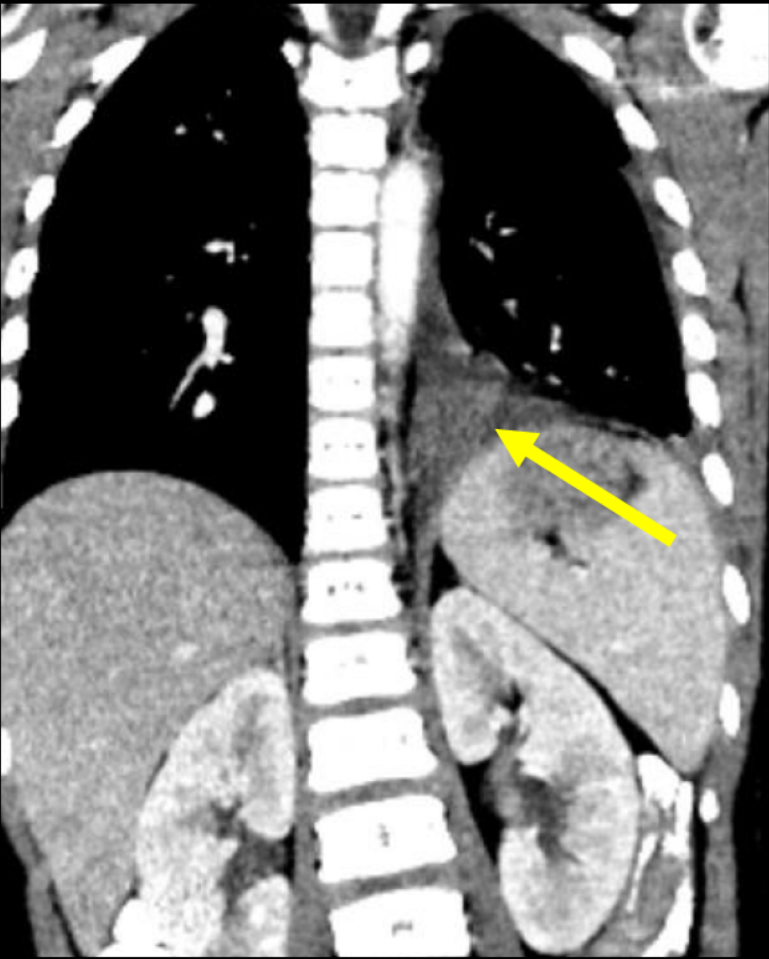
AIRPTM

AMERICAN INSTITUTE FOR
RADIOLOGIC PATHOLOGY

A PROGRAM OF THE
AMERICAN COLLEGE OF RADIOLOGY

LT SAG AXILLARY_

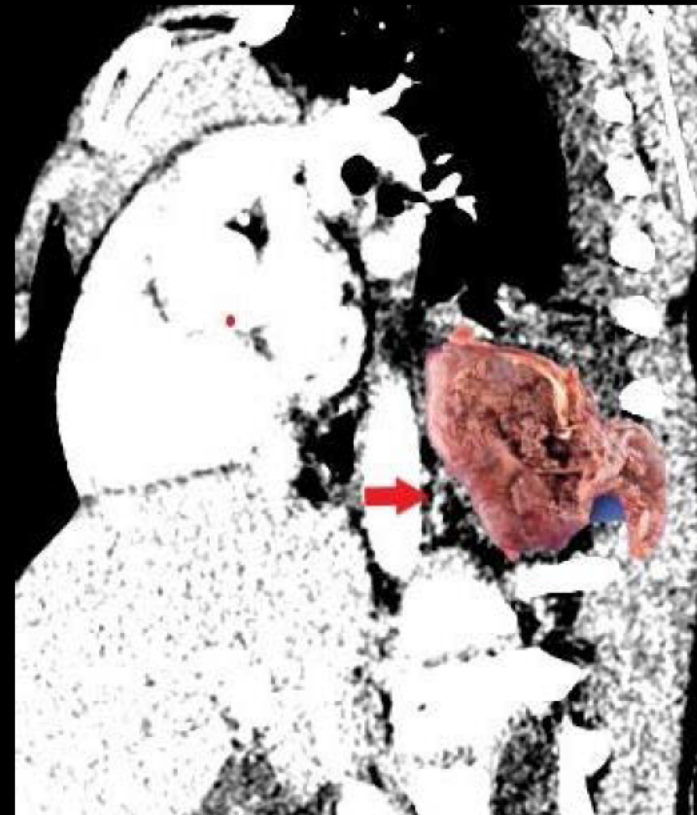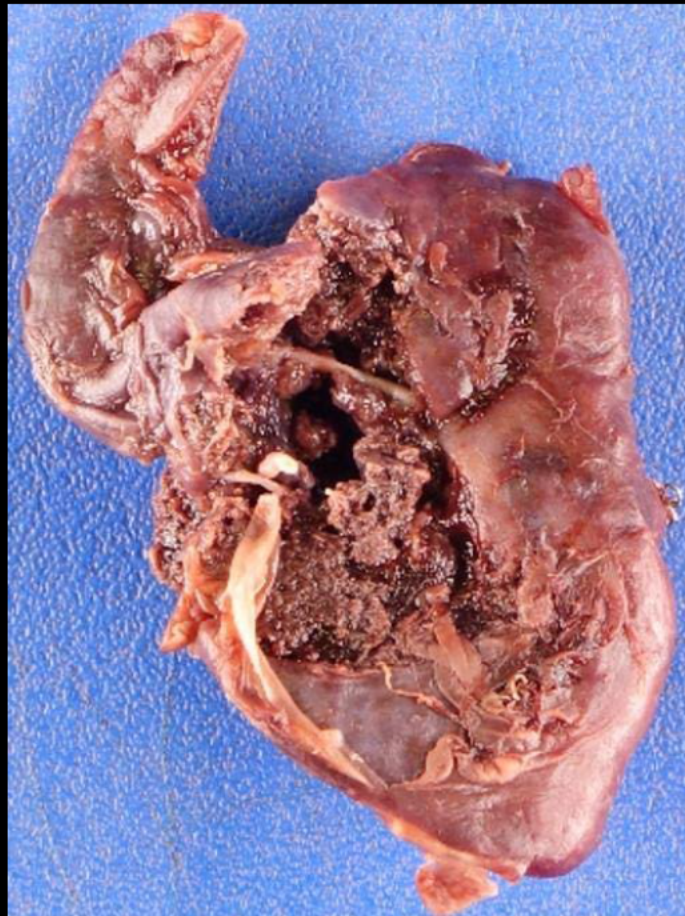
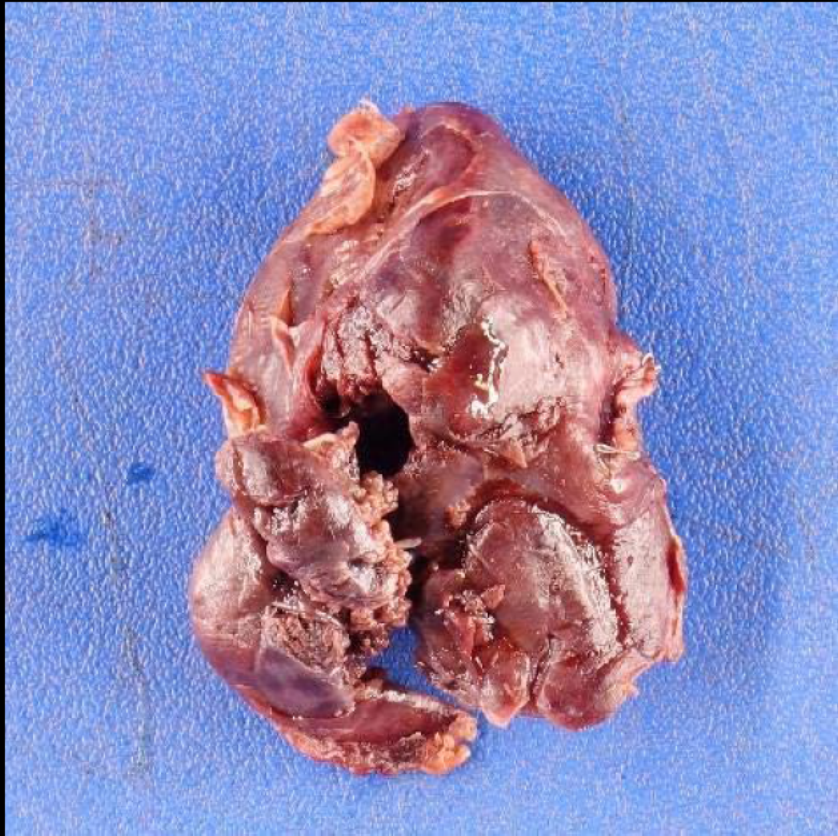13cm



AIRPTM

AMERICAN INSTITUTE FOR
RADIOLOGIC PATHOLOGY

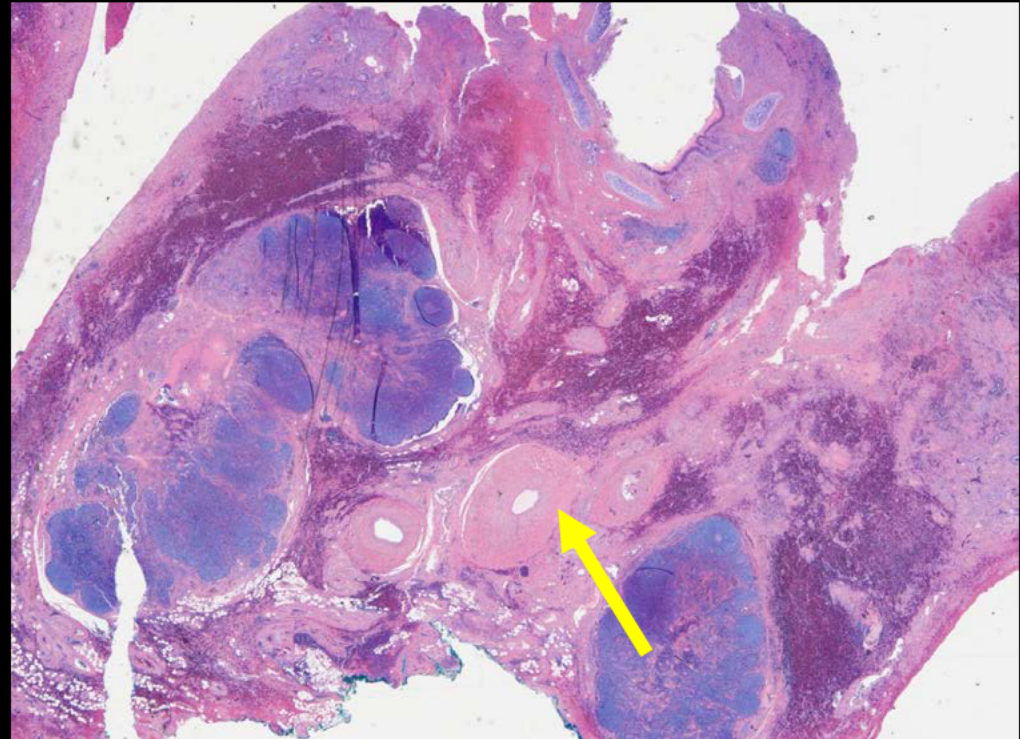
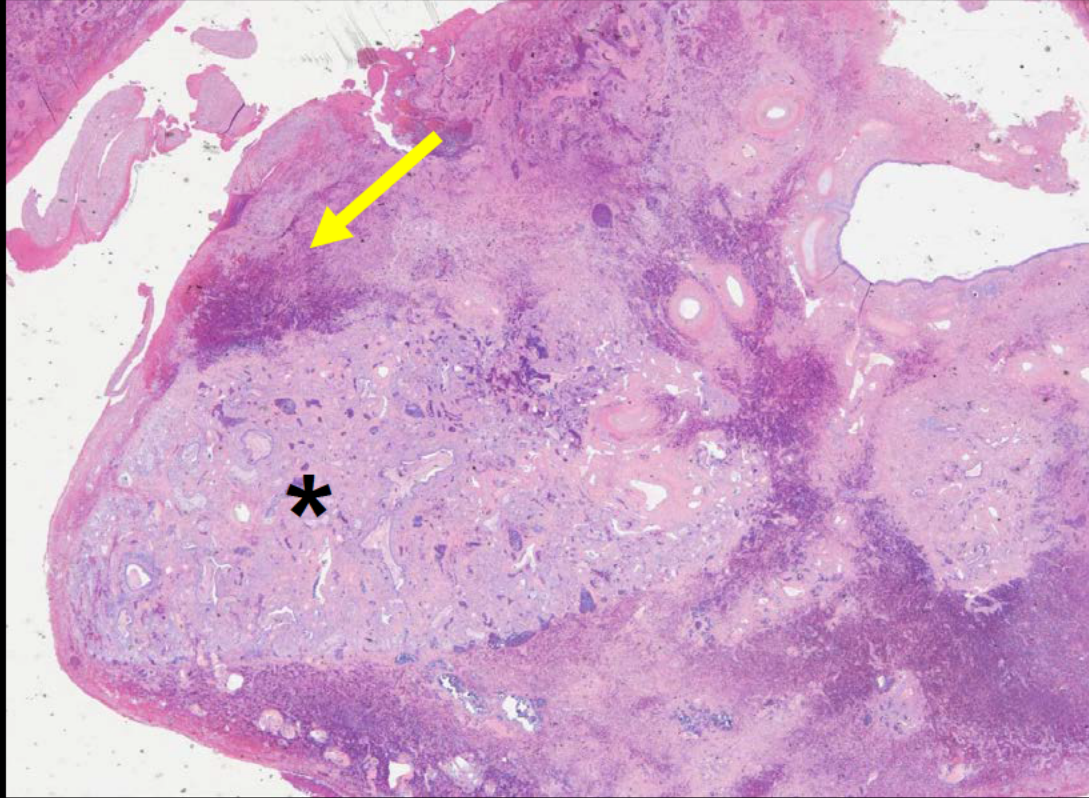
A PROGRAM OF THE
AMERICAN COLLEGE OF RADIOLOGY



AIRPTM

AMERICAN INSTITUTE FOR
RADIOLOGIC PATHOLOGY

A PROGRAM OF THE
AMERICAN COLLEGE OF RADIOLOGY



AIRPTM

AMERICAN INSTITUTE FOR
RADIOLOGIC PATHOLOGY

A PROGRAM OF THE
AMERICAN COLLEGE OF RADIOLOGY

Torsed Extralobar Sequestration

Philip Cheung

Lucile Packard Children's Hospital

Stanford Radiology Residency

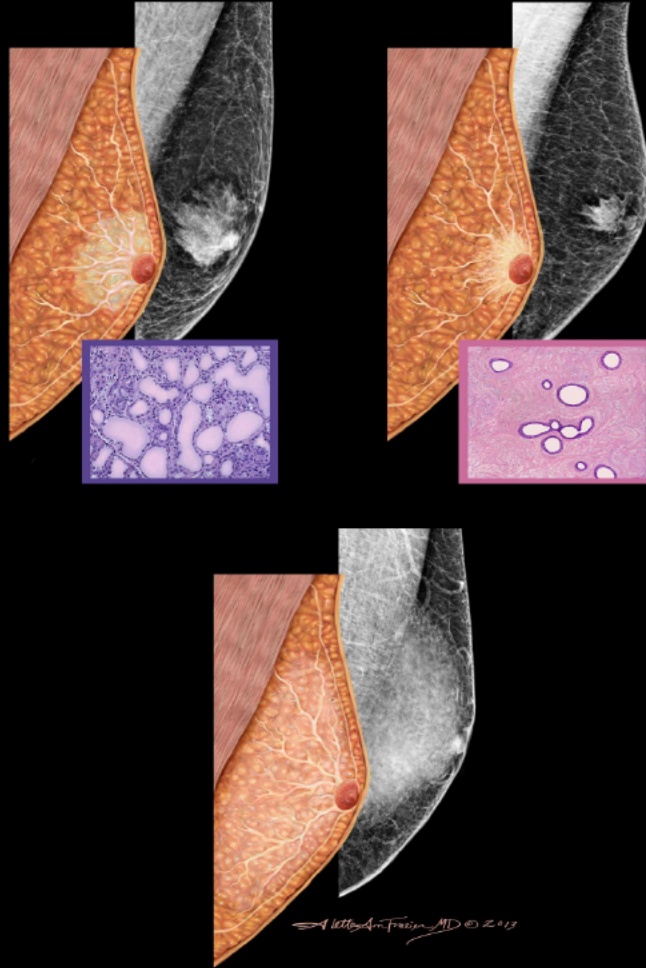
Case ID: 30347



AMERICAN INSTITUTE FOR
RADIOLOGIC PATHOLOGY

A PROGRAM OF THE
AMERICAN COLLEGE OF RADIOLOGY

Breast Best Case



AIRPTM

AMERICAN INSTITUTE FOR
RADIOLOGIC PATHOLOGY

A PROGRAM OF THE
AMERICAN COLLEGE OF RADIOLOGY

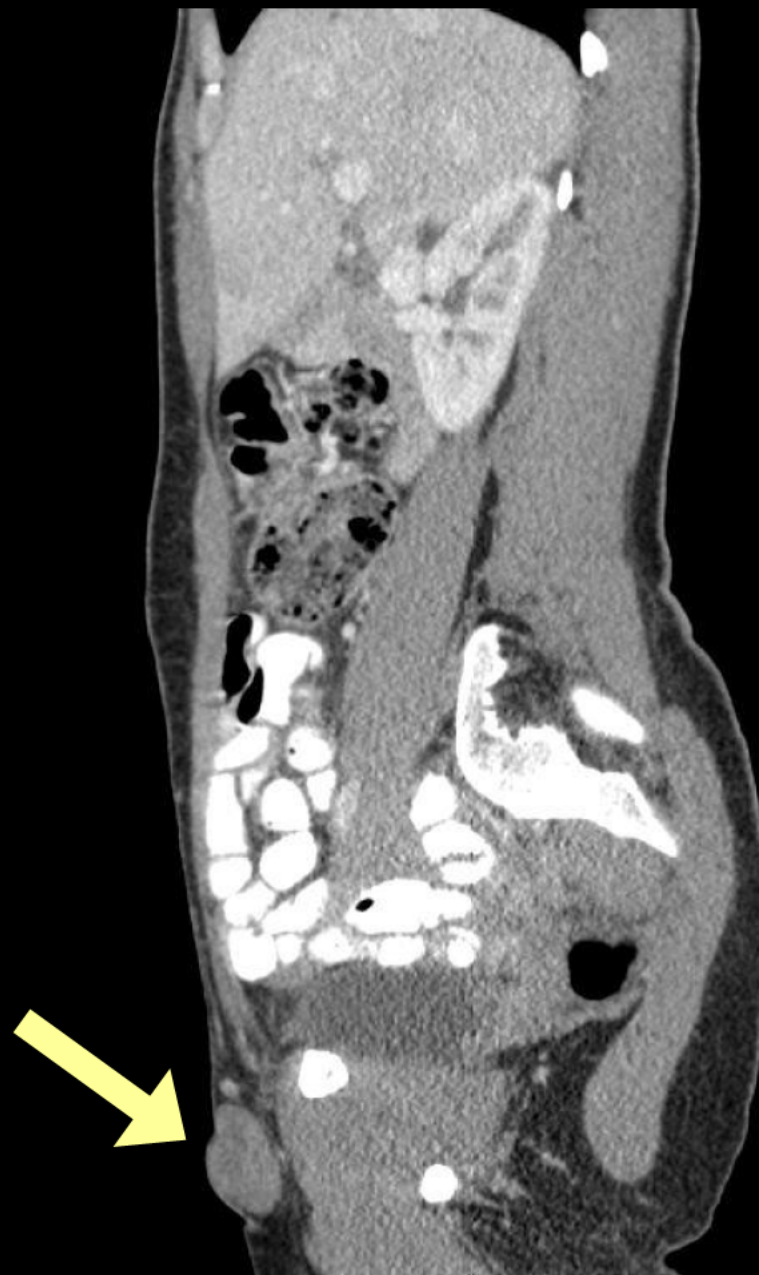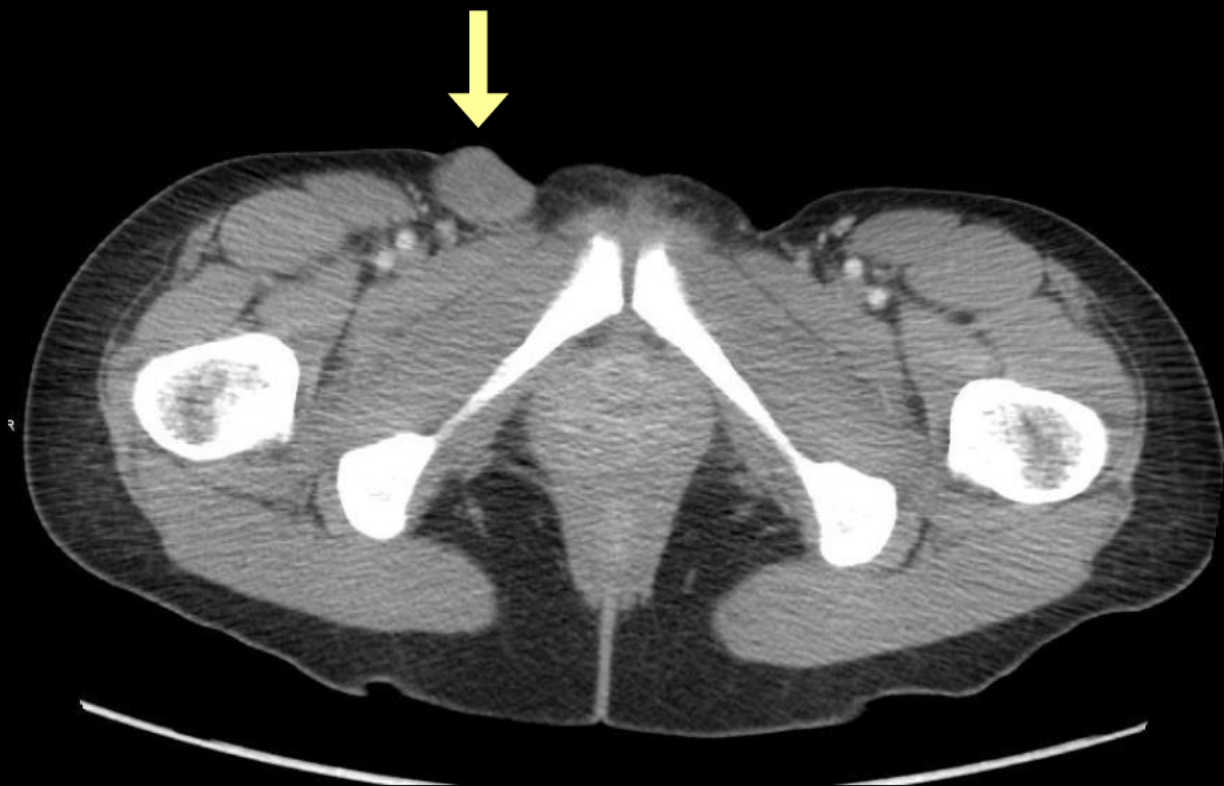
Clinical information

44-year-old woman with painless right groin mass growing over last 10 months.



AMERICAN INSTITUTE FOR
RADIOLOGIC PATHOLOGY

A PROGRAM OF THE
AMERICAN COLLEGE OF RADIOLOGY



AIRPTM

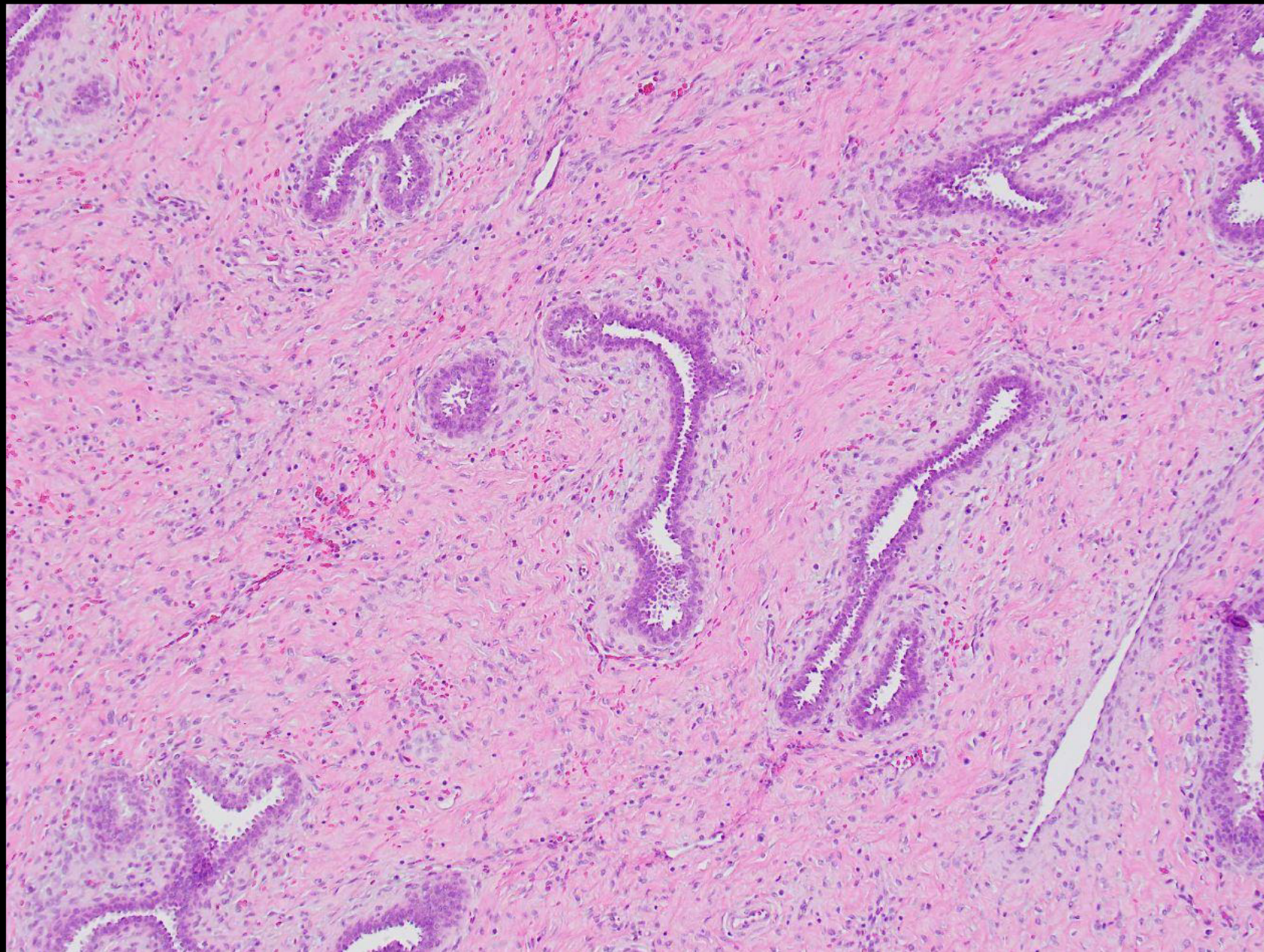
AMERICAN INSTITUTE FOR
RADIOLOGIC PATHOLOGY

A PROGRAM OF THE
AMERICAN COLLEGE OF RADIOLOGY

AIRP™

AMERICAN INSTITUTE FOR
RADIOLOGIC PATHOLOGY

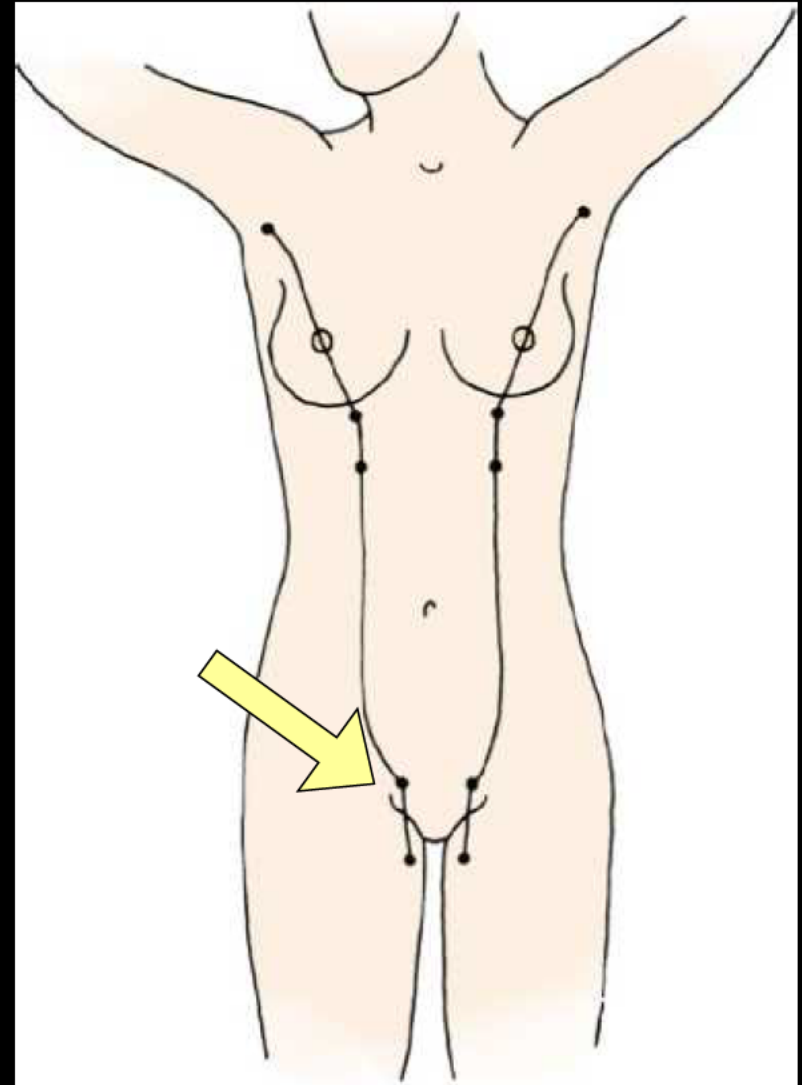
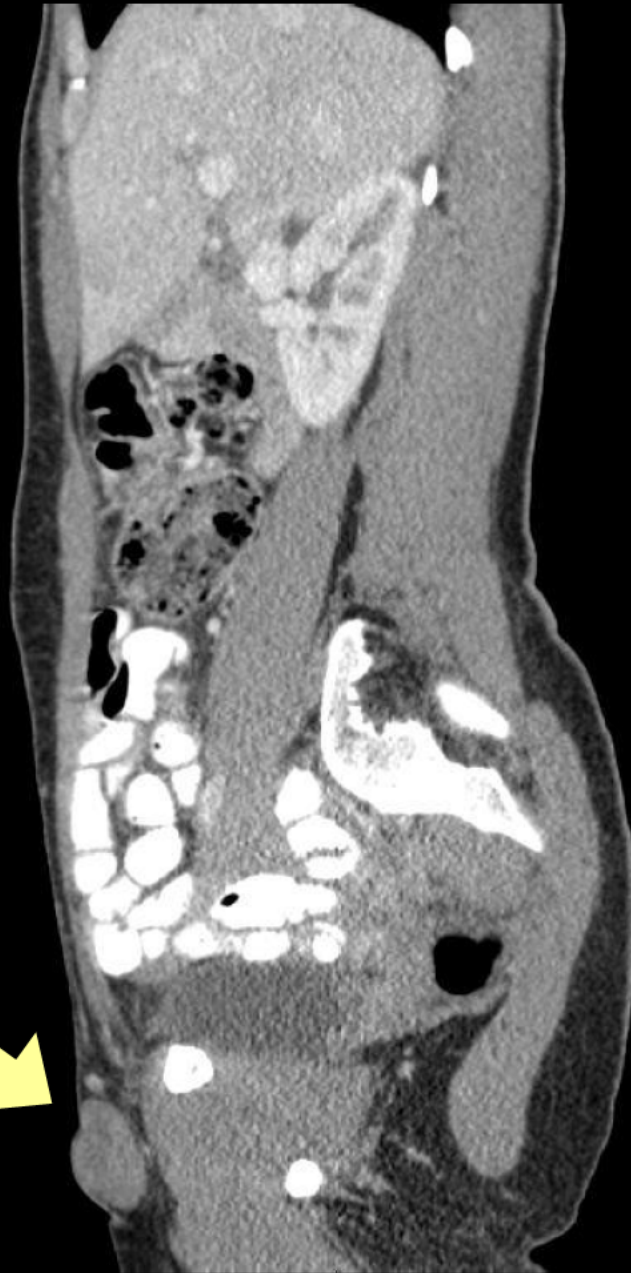A PROGRAM OF THE
AMERICAN COLLEGE OF RADIOLOGY



AIRP

AMERICAN INSTITUTE FOR
RADIOLOGIC PATHOLOGY

A PROGRAM OF THE
AMERICAN COLLEGE OF RADIOLOGY



Fibroadenoma in Ectopic Breast Tissue in the Groin

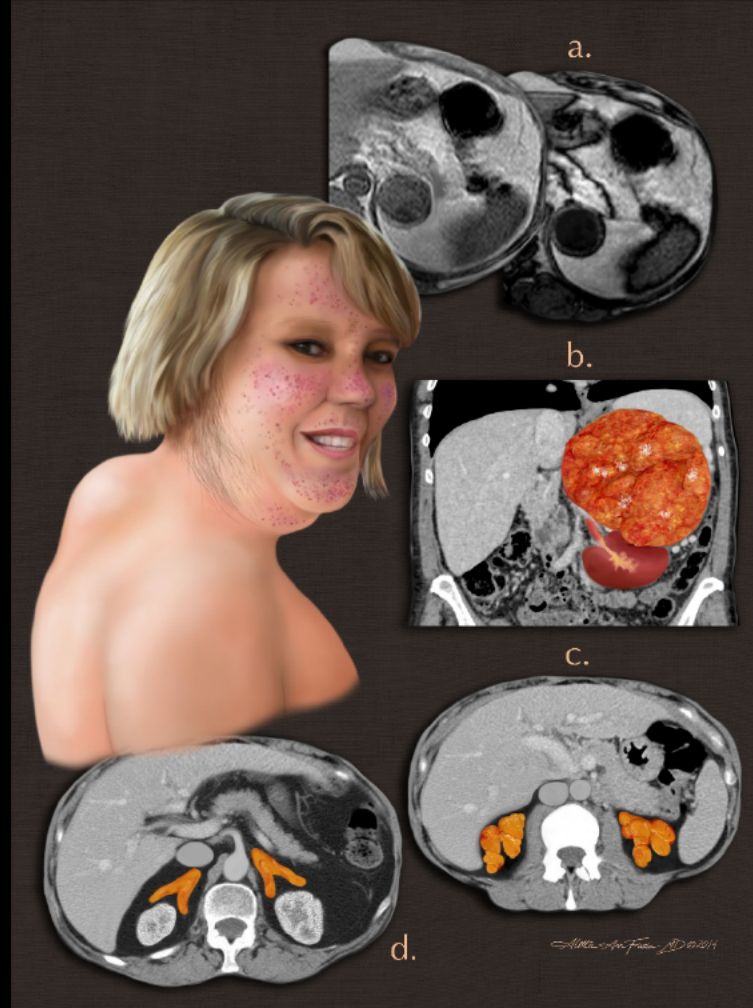Michael Swikehardt, MD
SUNY Downstate
Brooklyn, NY



AMERICAN INSTITUTE FOR
RADIOLOGIC PATHOLOGY

A PROGRAM OF THE
AMERICAN COLLEGE OF RADIOLOGY

Genitourinary Best Case



AIRPTM

AMERICAN INSTITUTE FOR
RADIOLOGIC PATHOLOGY

A PROGRAM OF THE
AMERICAN COLLEGE OF RADIOLOGY

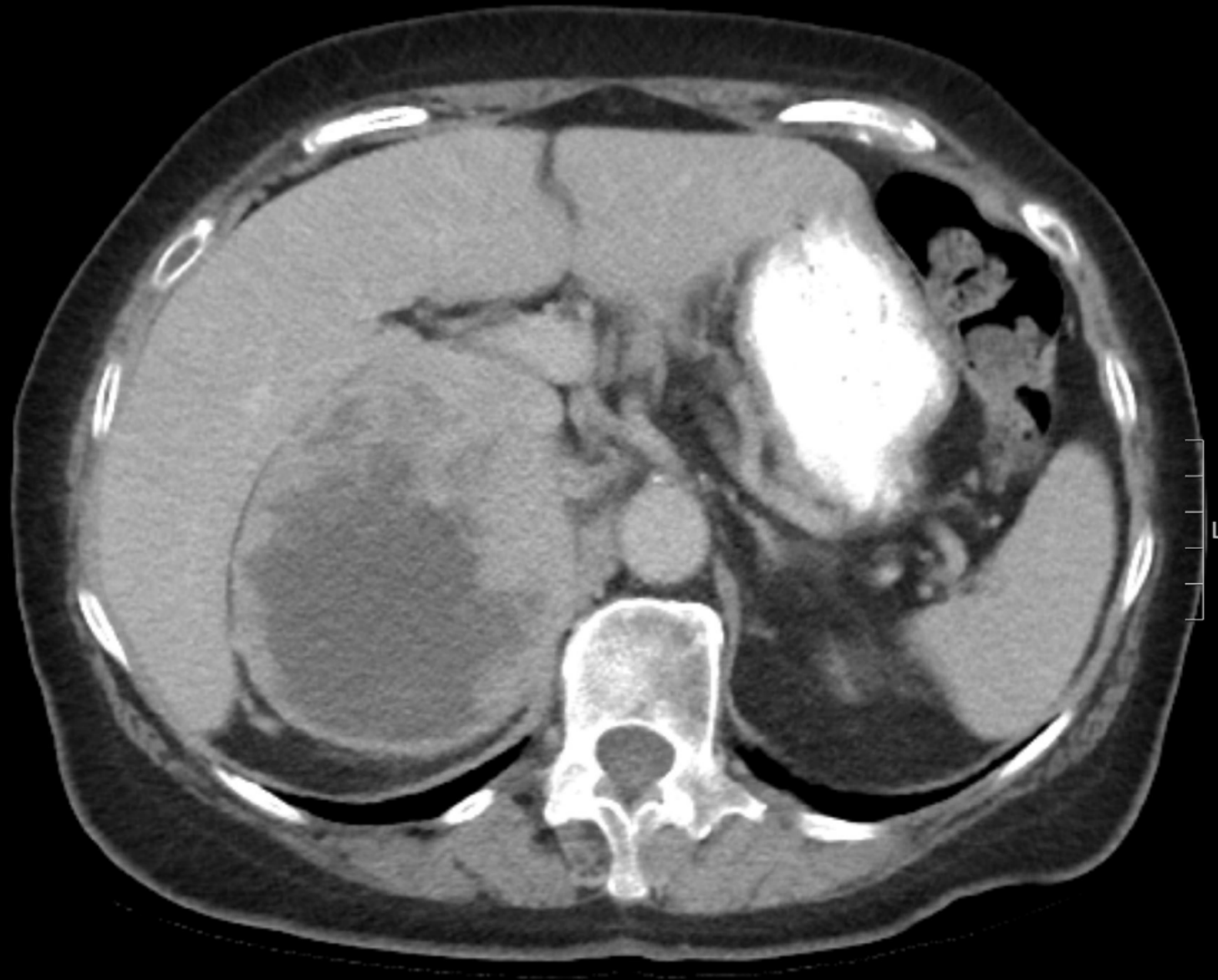Clinical information

80-year-old female with hypertension and malignant melanoma presented with microscopic hematuria.

AIRPTM

AMERICAN INSTITUTE FOR
RADIOLOGIC PATHOLOGY

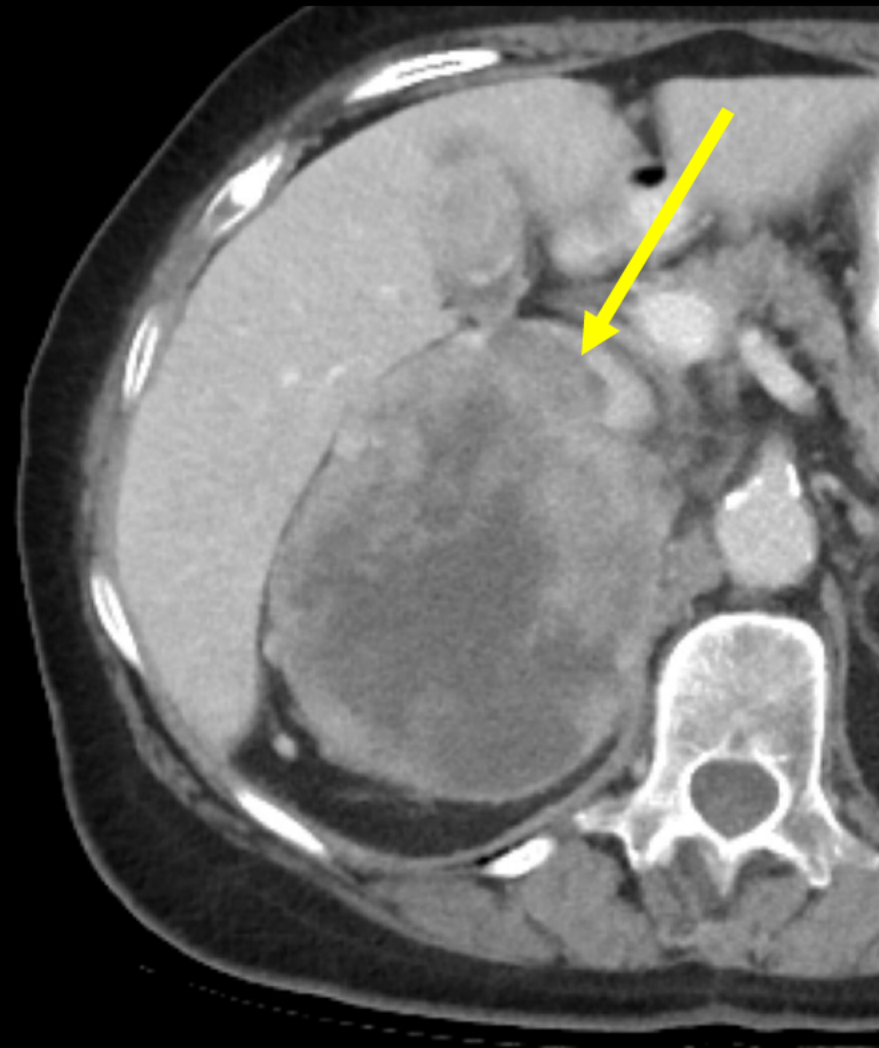
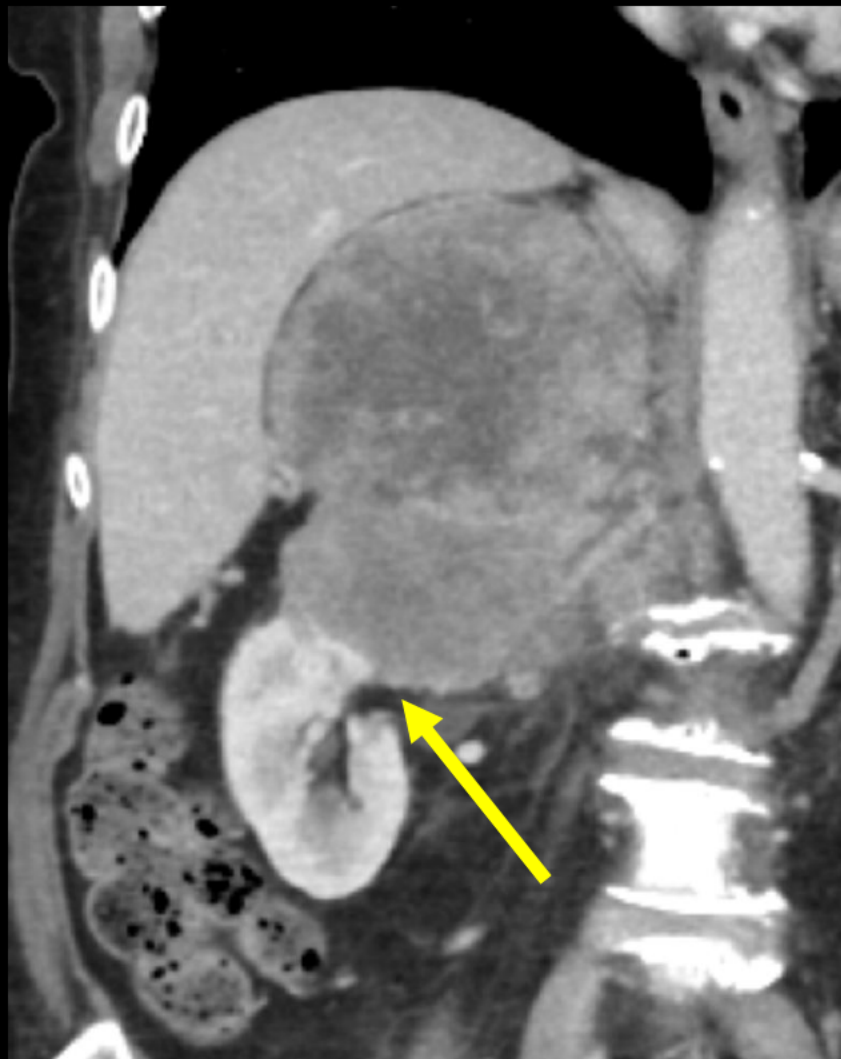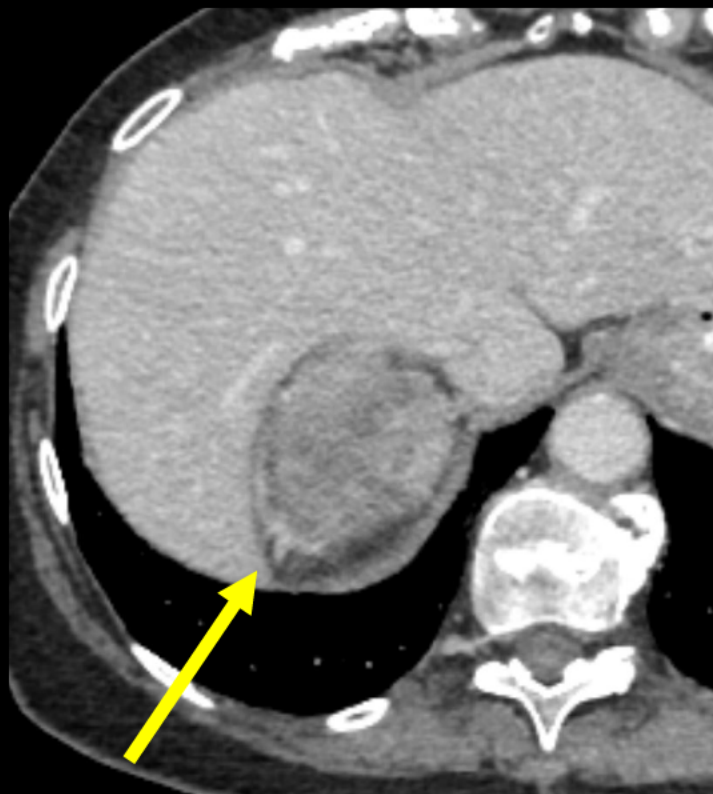
A PROGRAM OF THE
AMERICAN COLLEGE OF RADIOLOGY



AIRPTM

AMERICAN INSTITUTE FOR
RADIOLOGIC PATHOLOGY

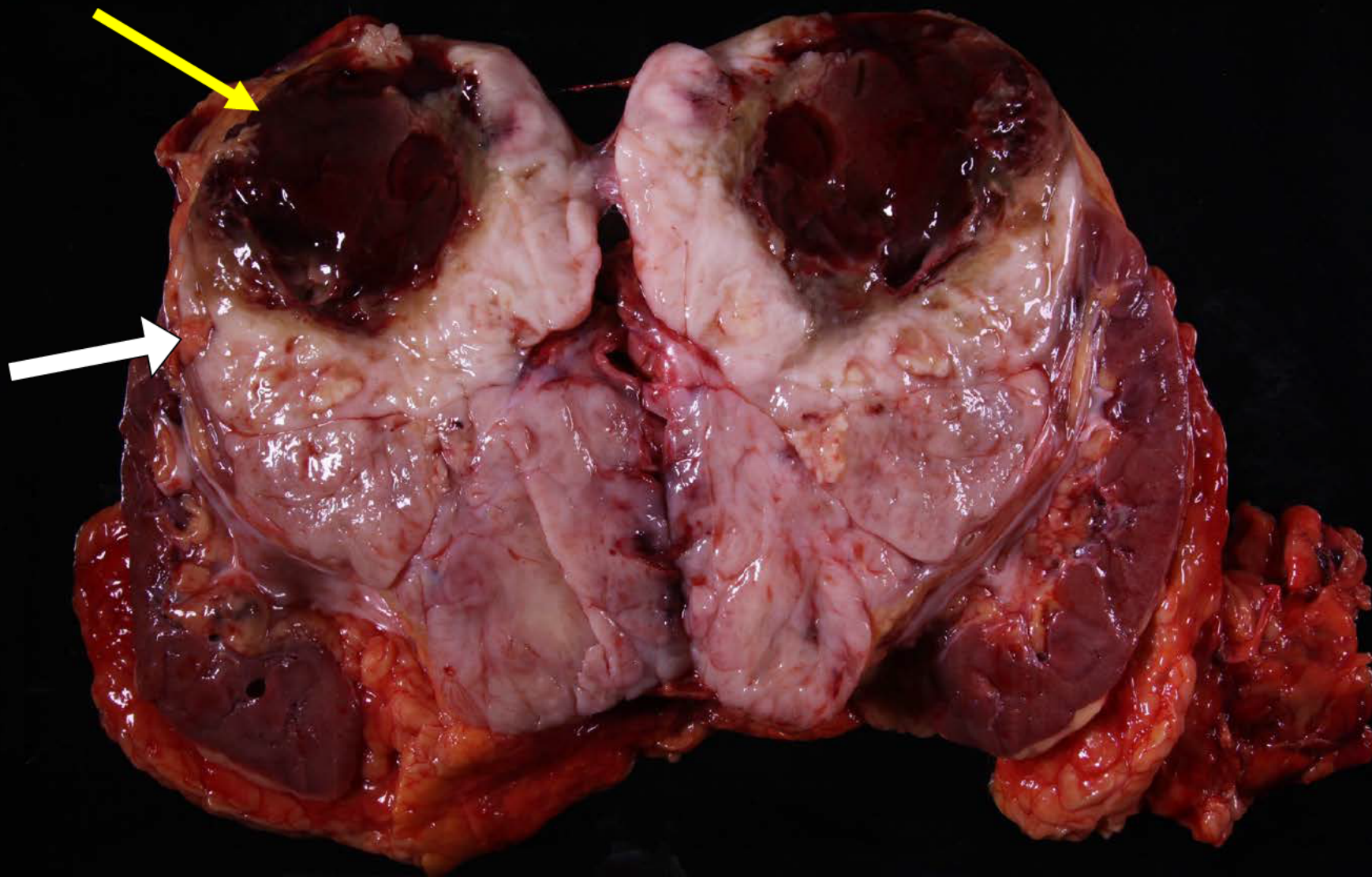
A PROGRAM OF THE
AMERICAN COLLEGE OF RADIOLOGY



AIRPTM

AMERICAN INSTITUTE FOR
RADIOLOGIC PATHOLOGY

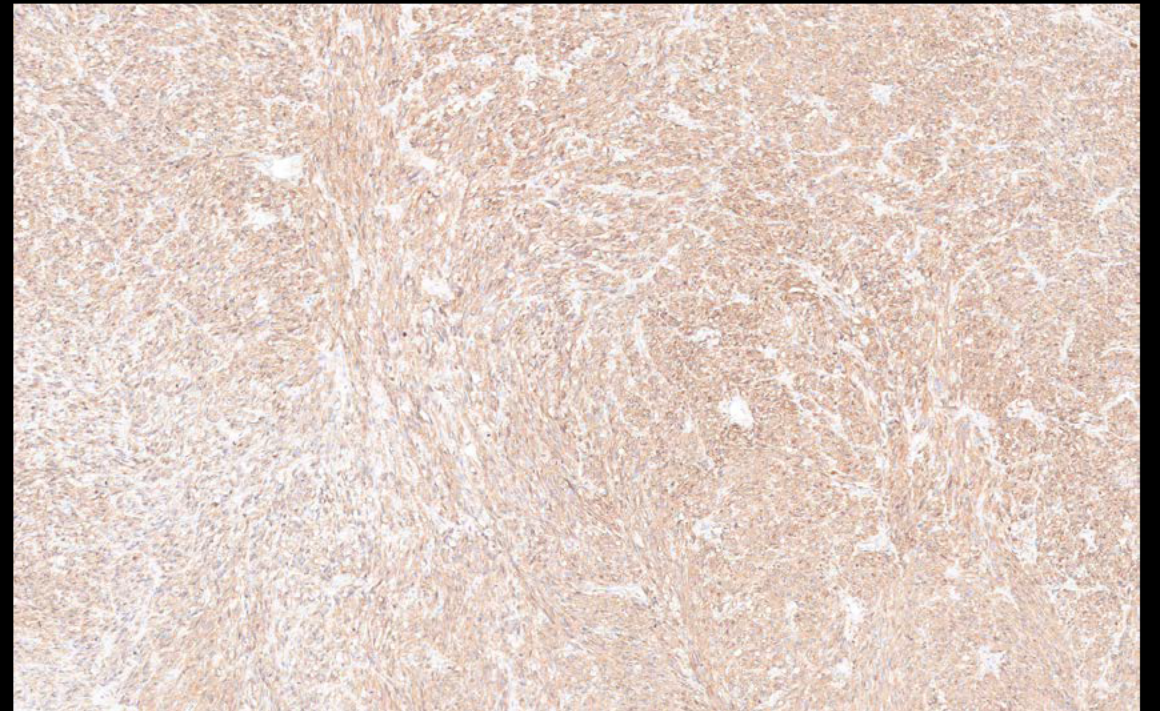
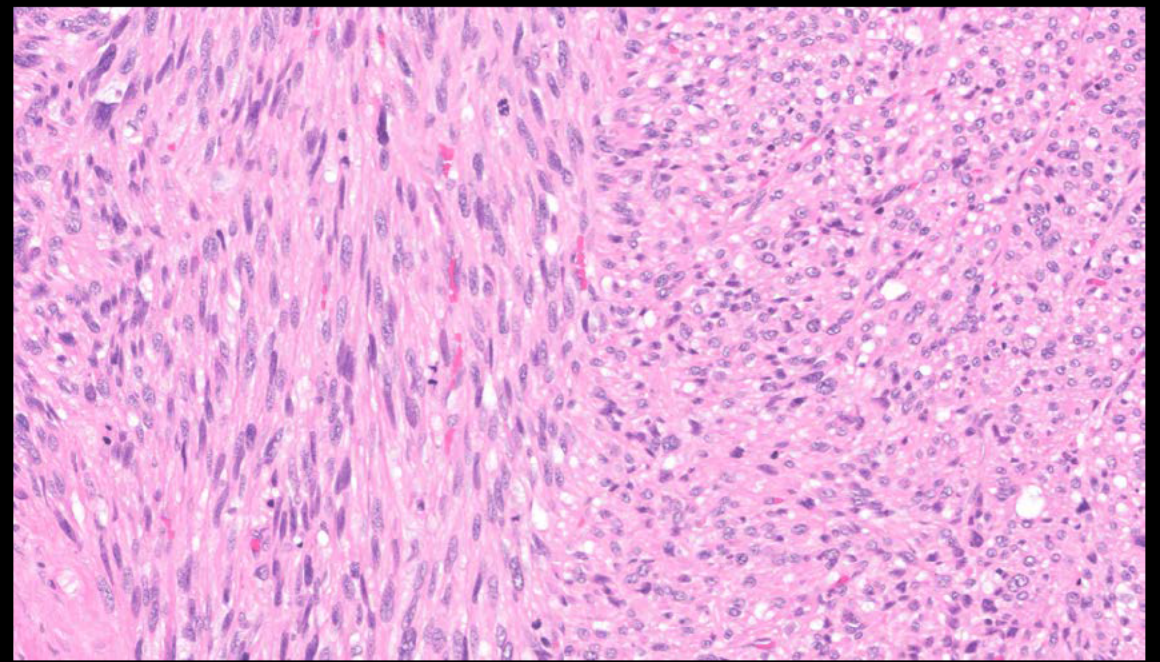
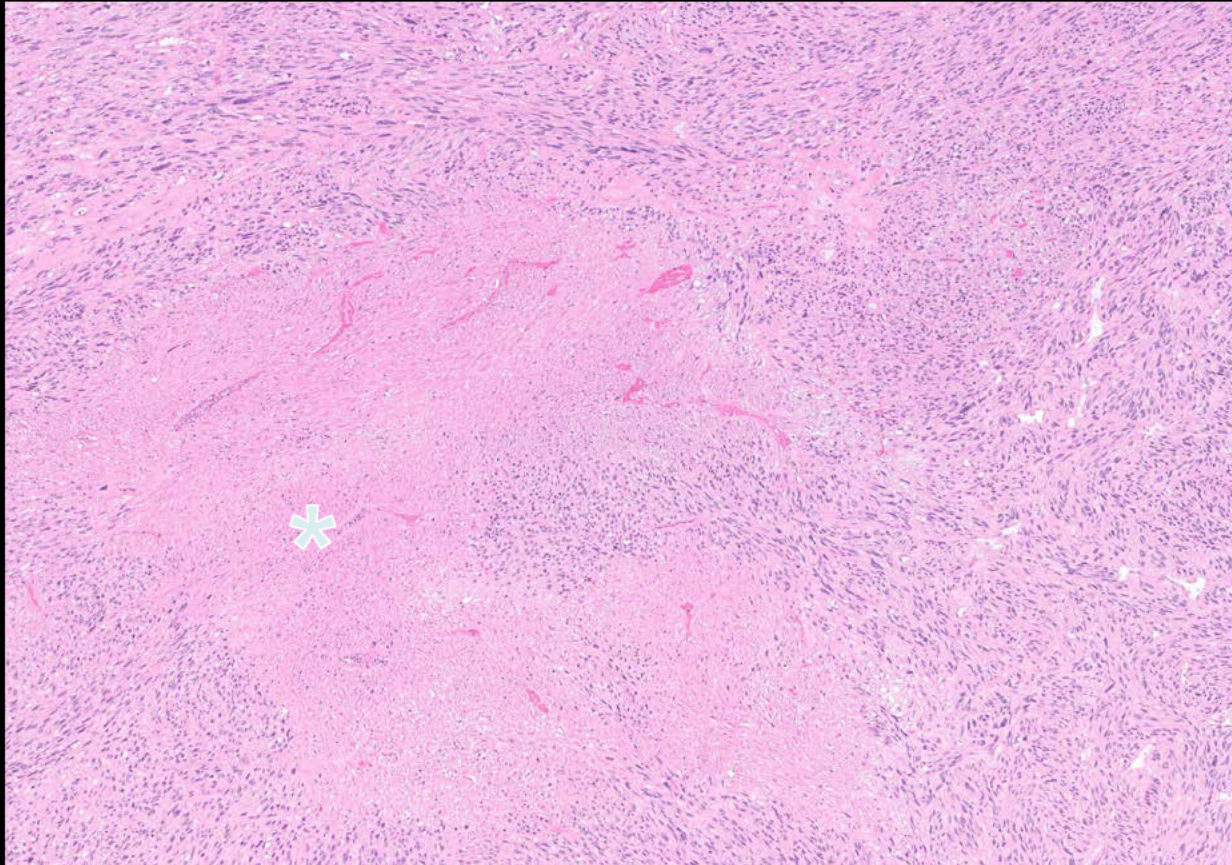
A PROGRAM OF THE
AMERICAN COLLEGE OF RADIOLOGY



AIRP™

AMERICAN INSTITUTE FOR
RADIOLOGIC PATHOLOGY

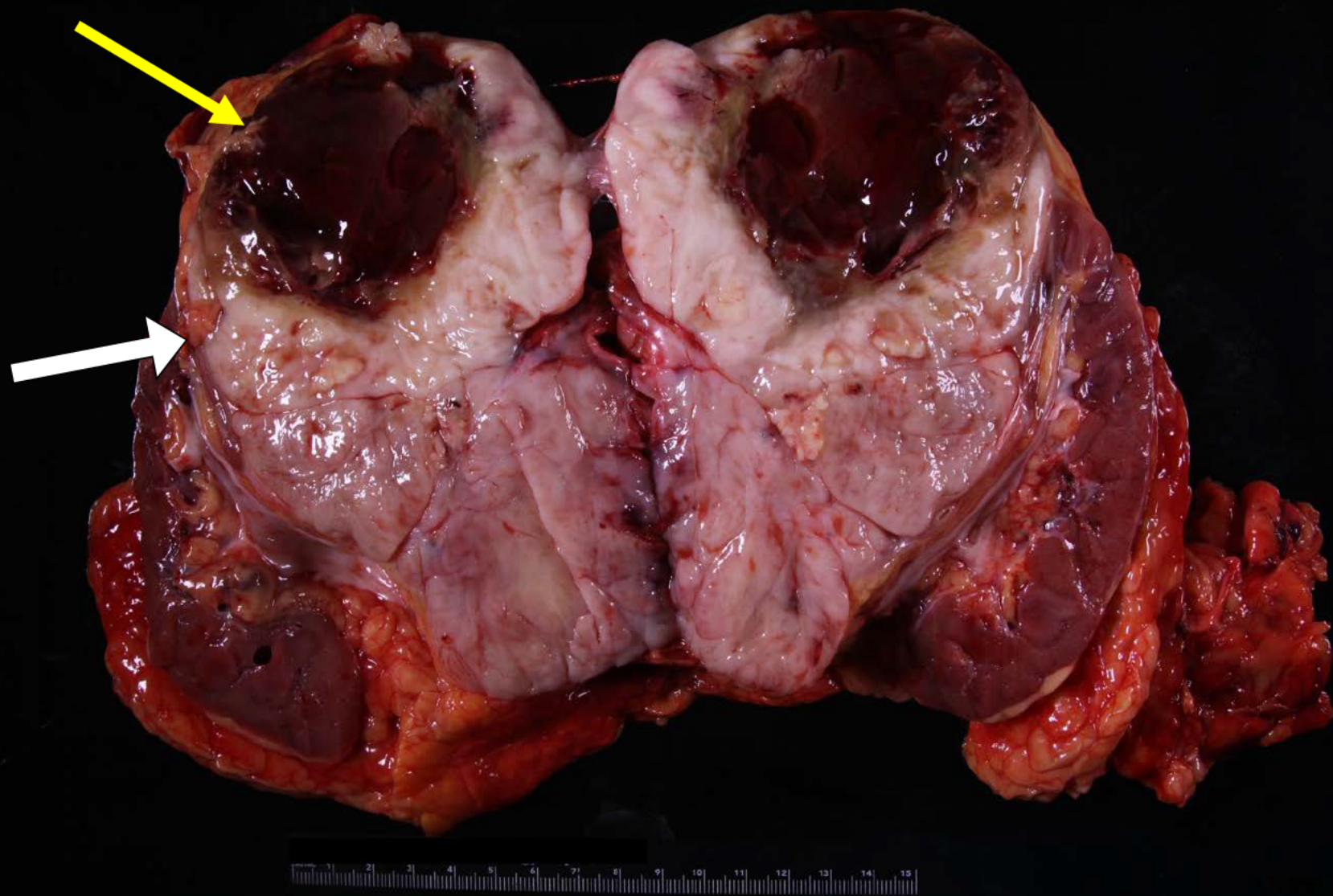
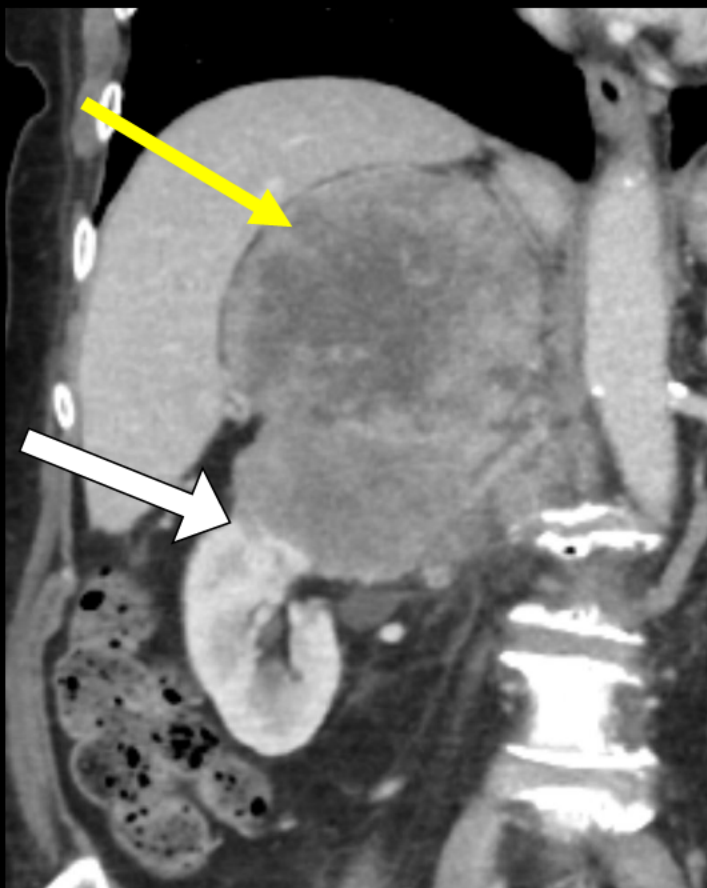A PROGRAM OF THE
AMERICAN COLLEGE OF RADIOLOGY



AIRPTM

AMERICAN INSTITUTE FOR
RADIOLOGIC PATHOLOGY

A PROGRAM OF THE
AMERICAN COLLEGE OF RADIOLOGY



AIRPTM

AMERICAN INSTITUTE FOR
RADIOLOGIC PATHOLOGY

A PROGRAM OF THE
AMERICAN COLLEGE OF RADIOLOGY

Leiomyosarcoma

Thomas An

Massachusetts General Hospital
Boston, Massachusetts



AMERICAN INSTITUTE FOR
RADIOLOGIC PATHOLOGY

A PROGRAM OF THE
AMERICAN COLLEGE OF RADIOLOGY