

# Best Cases of the AIRP

October-November, 2020

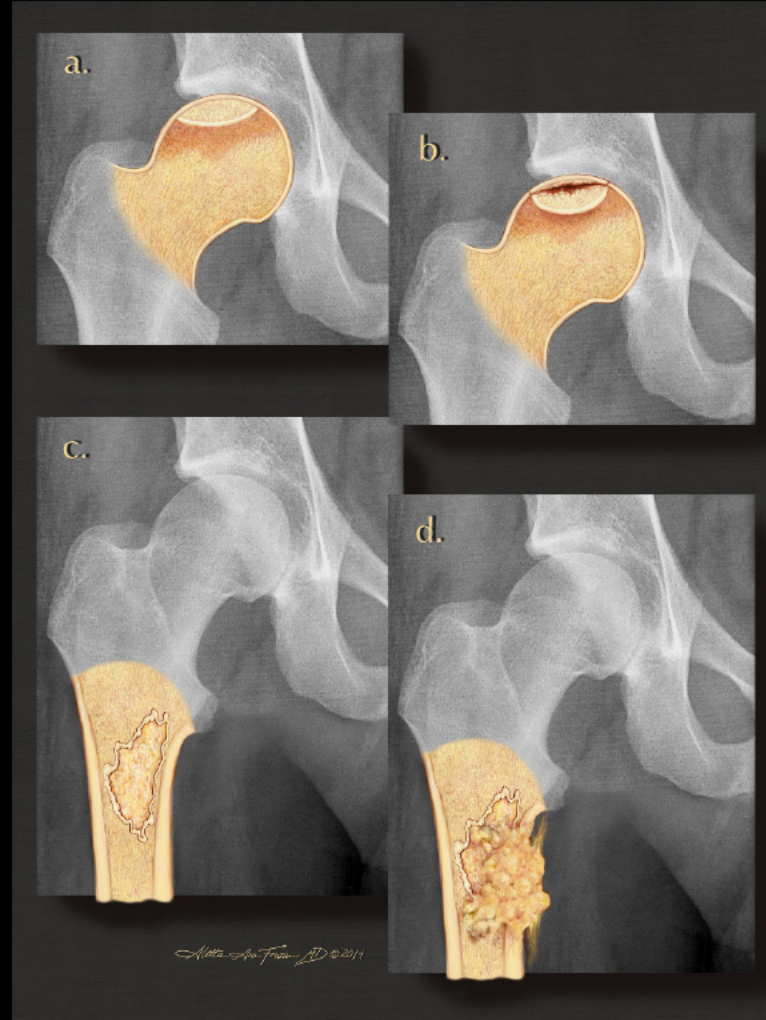
**AIRP**<sup>TM</sup>

AMERICAN INSTITUTE FOR  
RADIOLOGIC PATHOLOGY

---

A PROGRAM OF THE  
AMERICAN COLLEGE OF RADIOLOGY

# Musculoskeletal Best Case



**AIRP**<sup>TM</sup>

AMERICAN INSTITUTE FOR  
RADIOLOGIC PATHOLOGY

A PROGRAM OF THE  
AMERICAN COLLEGE OF RADIOLOGY



# CLINICAL INFORMATION

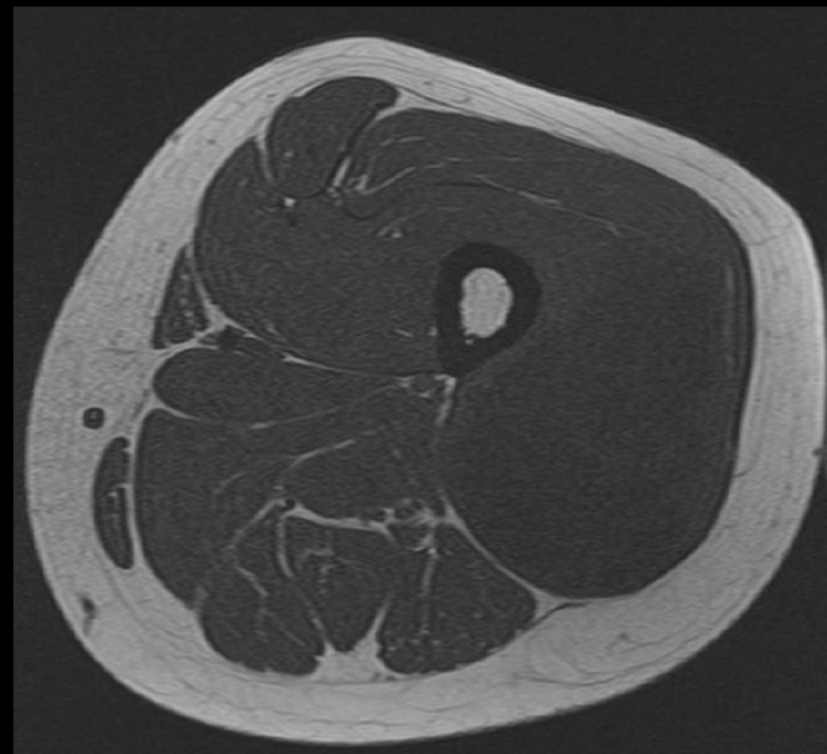
**34-year-old female with persistent left thigh mass**



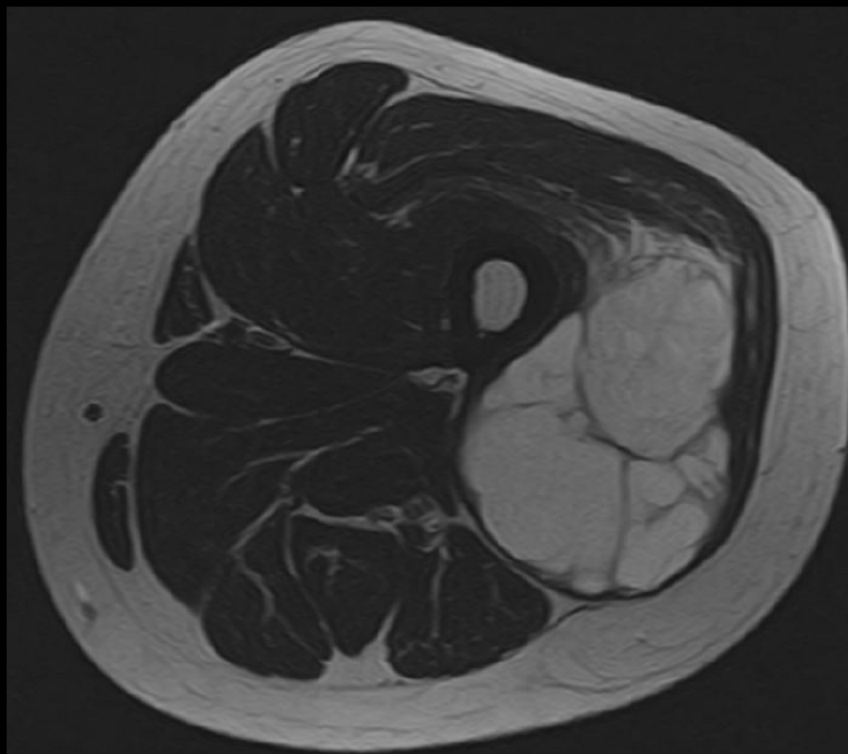
AMERICAN INSTITUTE FOR  
RADIOLOGIC PATHOLOGY

---

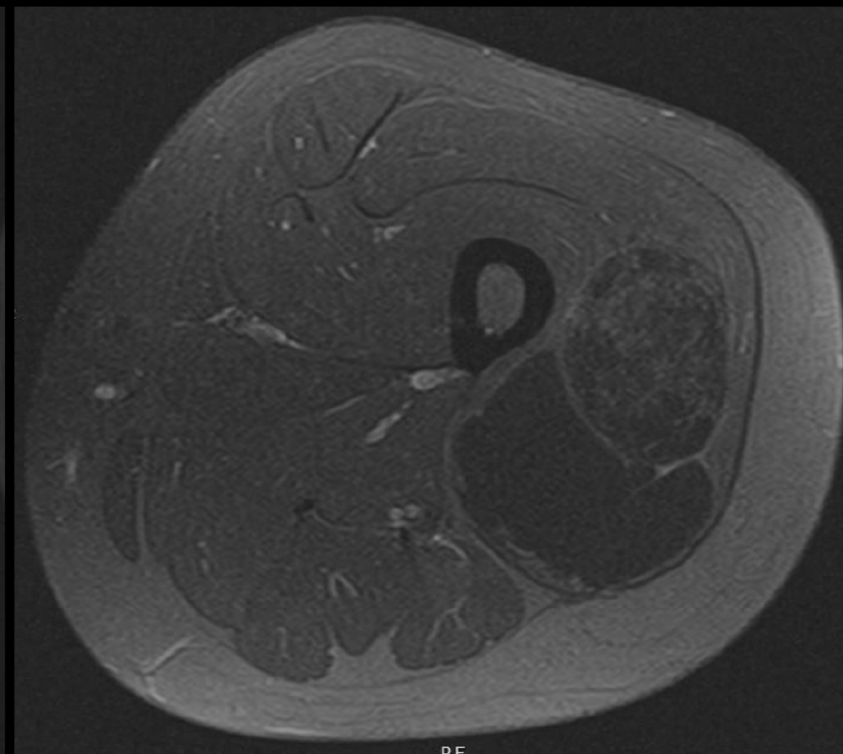
A PROGRAM OF THE  
AMERICAN COLLEGE OF RADIOLOGY



**Axial T1**



**Axial T2**

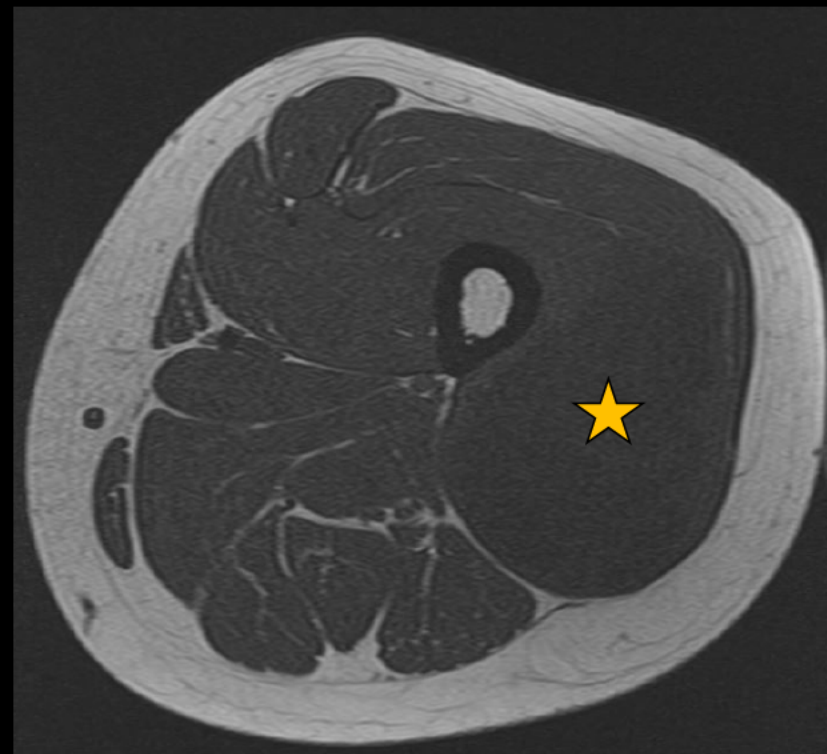


**Axial T1 FS +C**

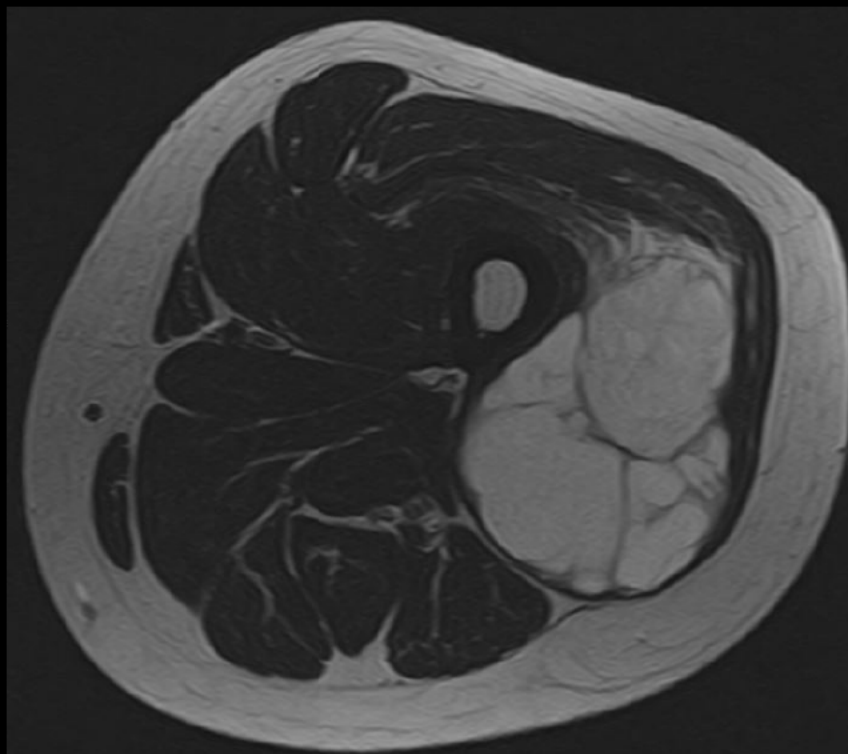
**AIRP**<sup>TM</sup>

AMERICAN INSTITUTE FOR  
RADIOLOGIC PATHOLOGY

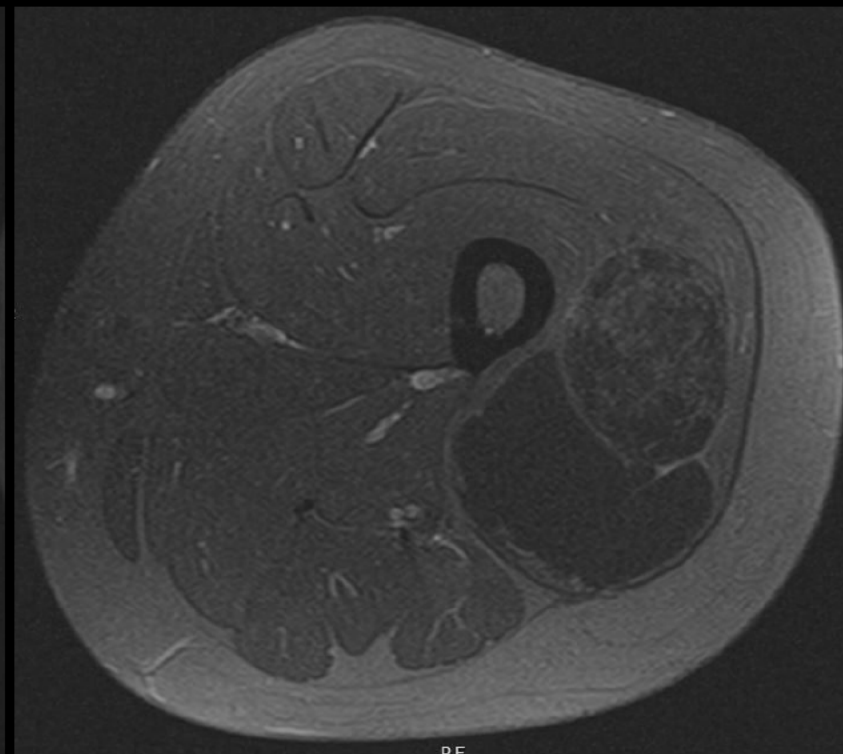
A PROGRAM OF THE  
AMERICAN COLLEGE OF RADIOLOGY



**Axial T1**



**Axial T2**

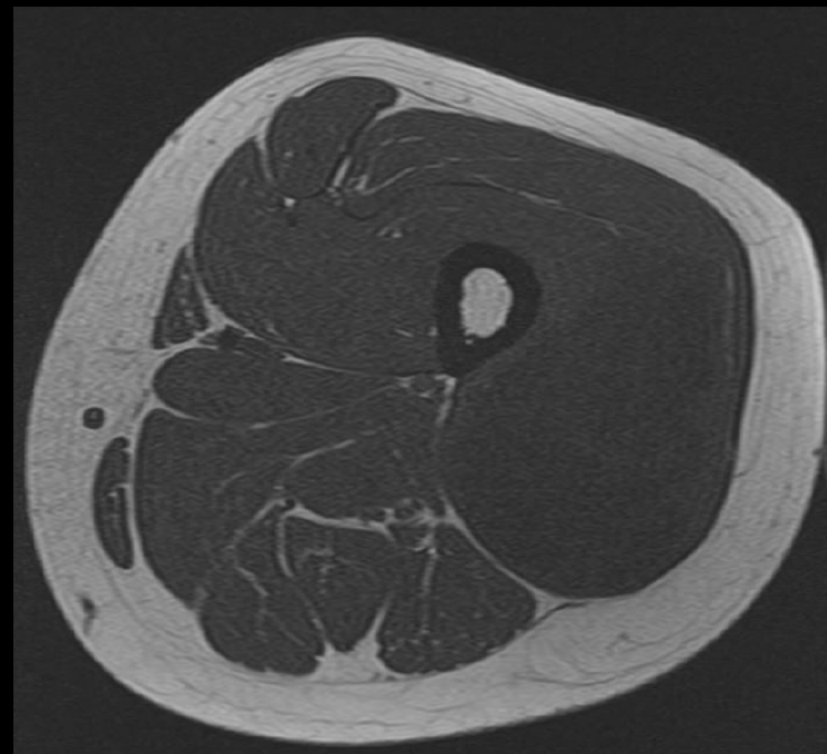


**Axial T1 FS +C**

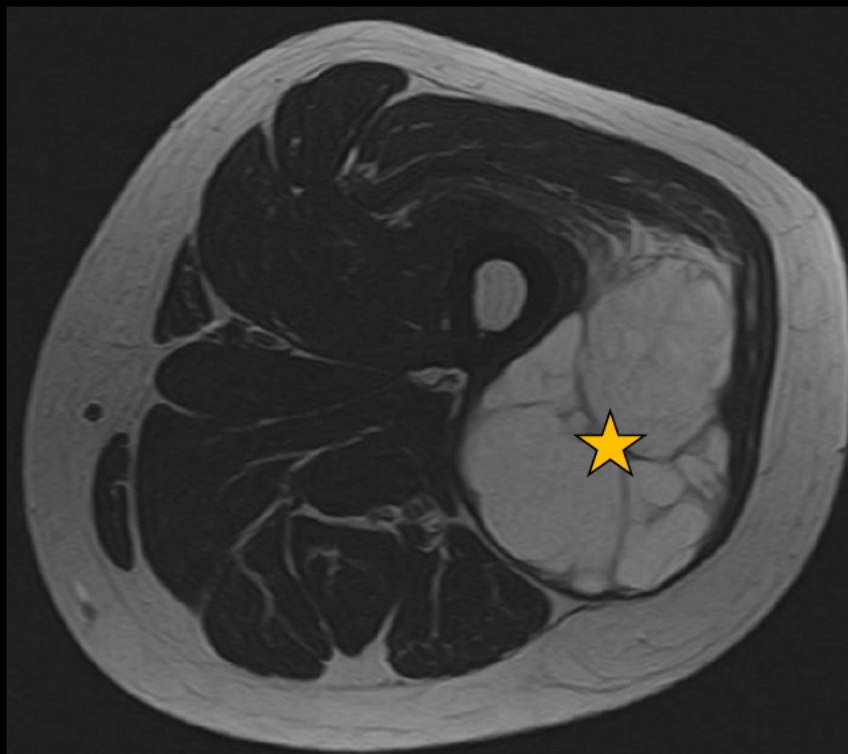
**AIRP**<sup>TM</sup>

AMERICAN INSTITUTE FOR  
RADIOLOGIC PATHOLOGY

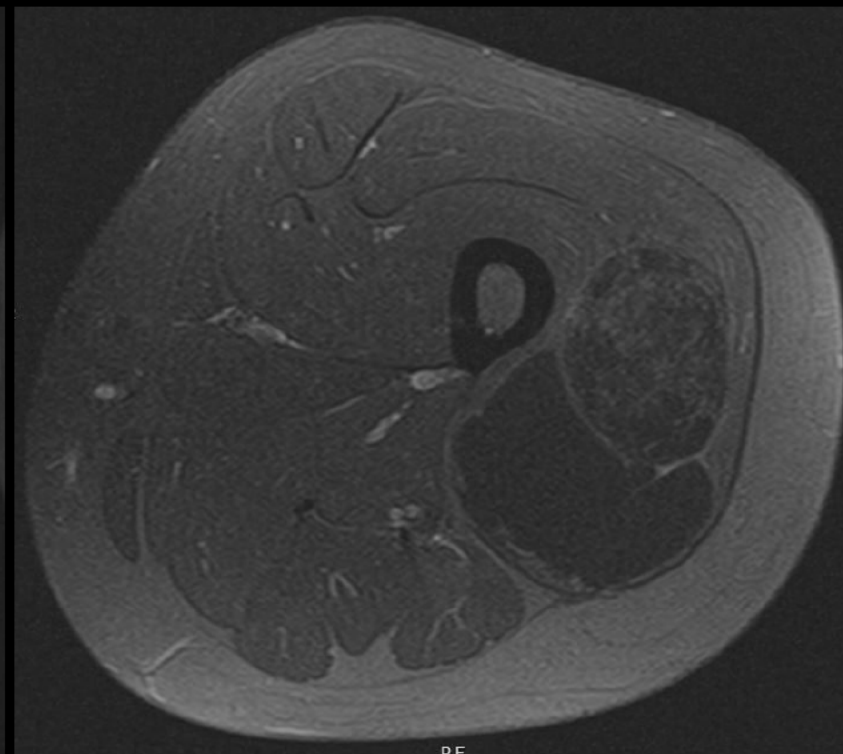
A PROGRAM OF THE  
AMERICAN COLLEGE OF RADIOLOGY



**Axial T1**



**Axial T2**



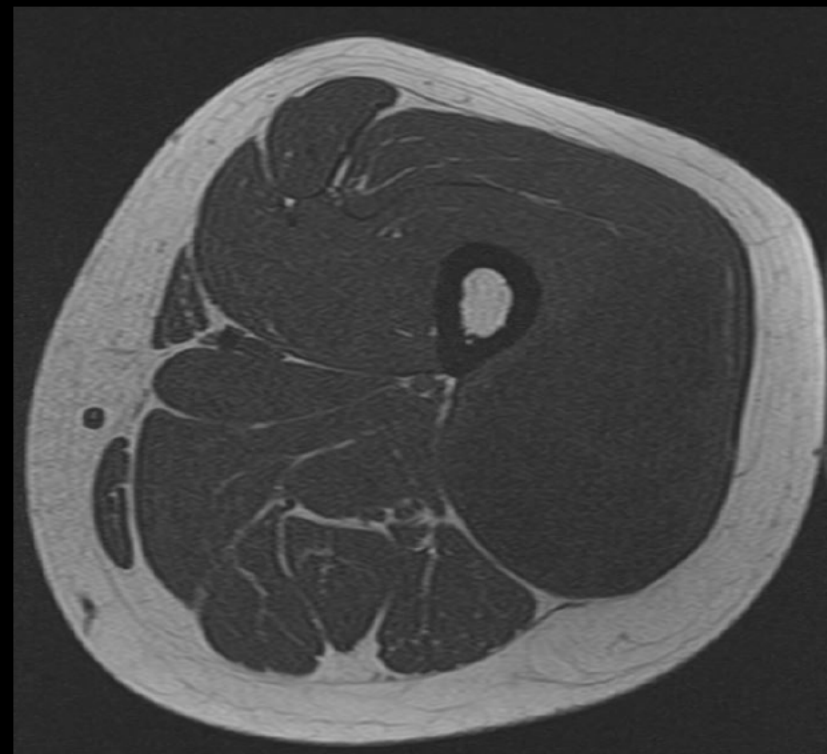
**Axial T1 FS +C**

**AIRP**<sup>TM</sup>

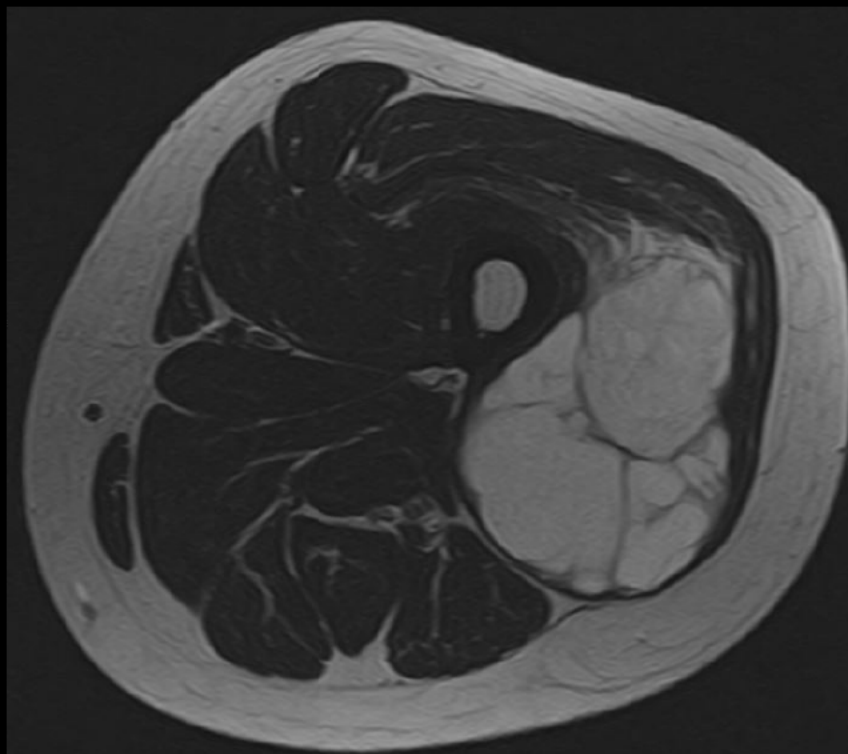
AMERICAN INSTITUTE FOR  
RADIOLOGIC PATHOLOGY

A PROGRAM OF THE  
AMERICAN COLLEGE OF RADIOLOGY

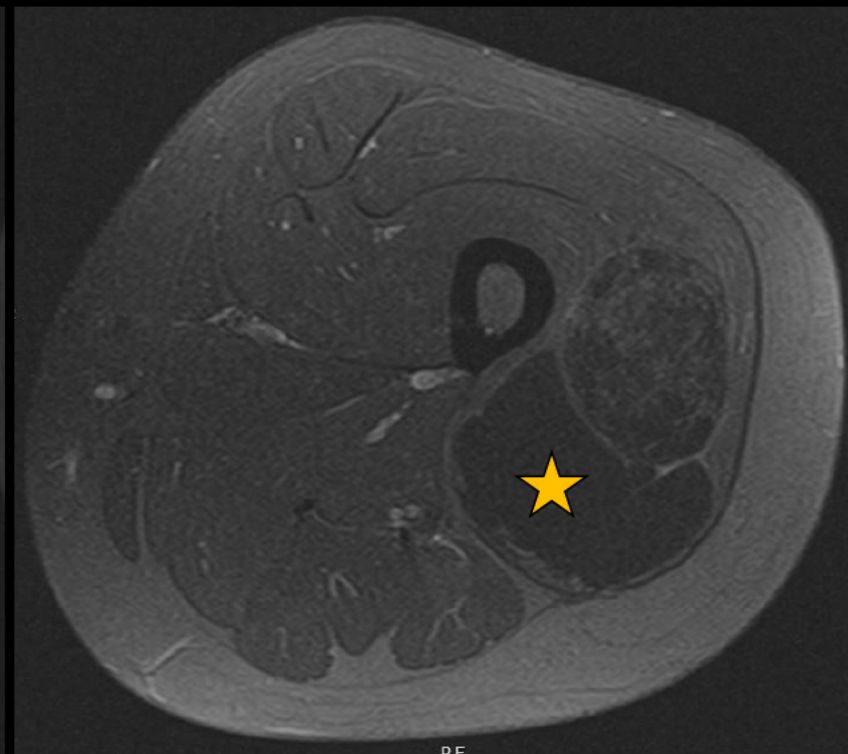




**Axial T1**



**Axial T2**

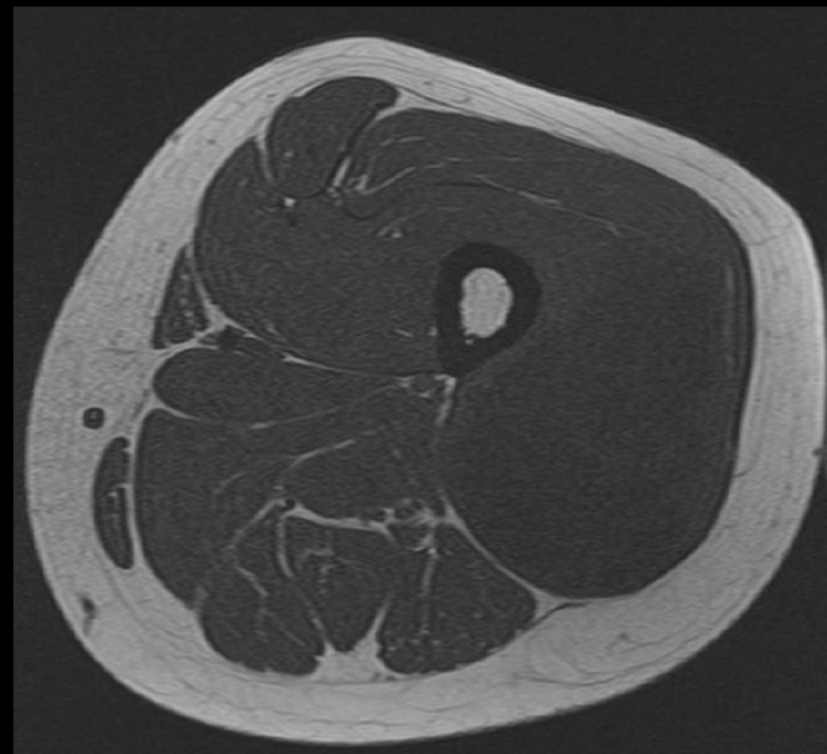


**Axial T1 FS +C**

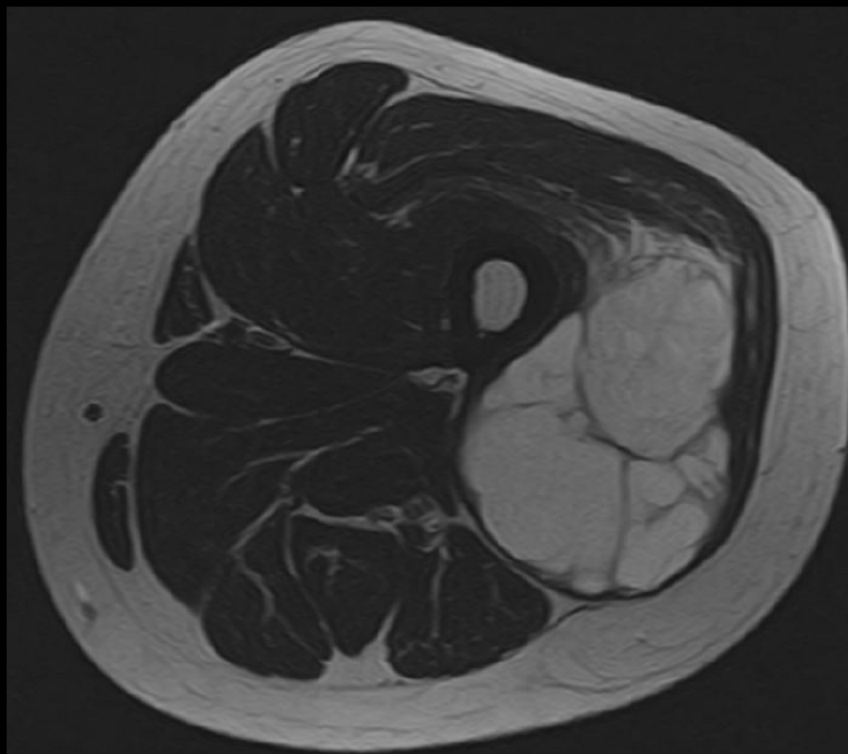
**AIRP**<sup>TM</sup>

AMERICAN INSTITUTE FOR  
RADIOLOGIC PATHOLOGY

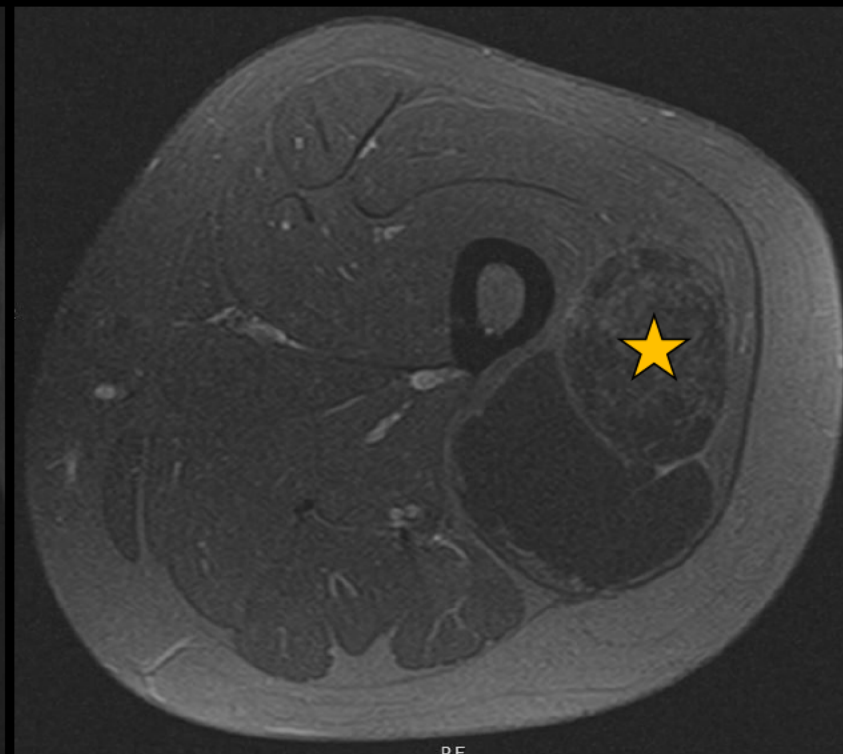
A PROGRAM OF THE  
AMERICAN COLLEGE OF RADIOLOGY



**Axial T1**



**Axial T2**

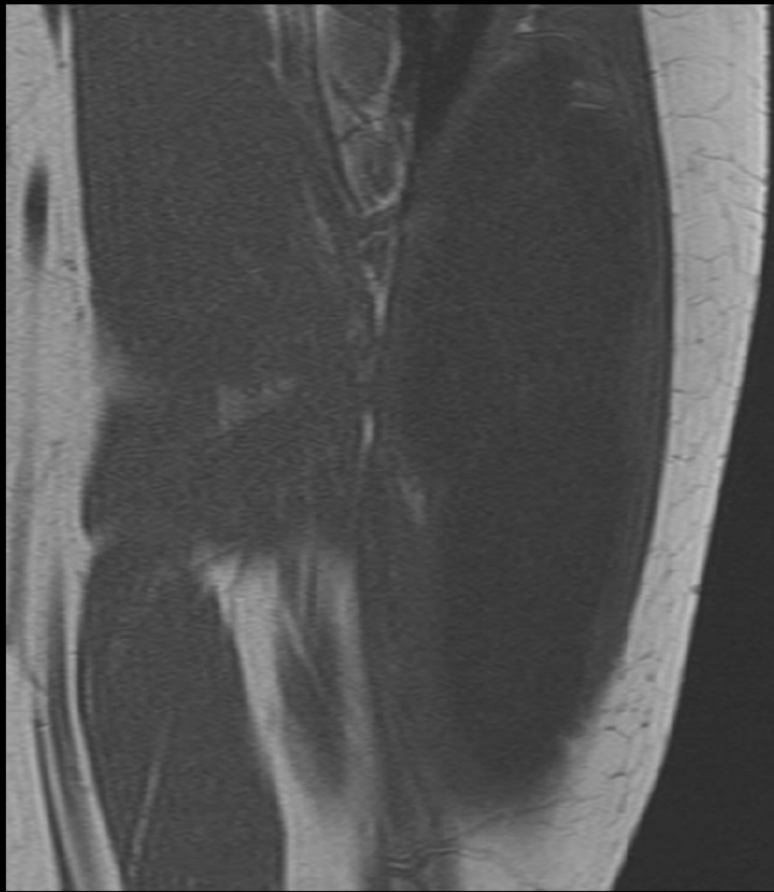

**Axial T1 FS +C**

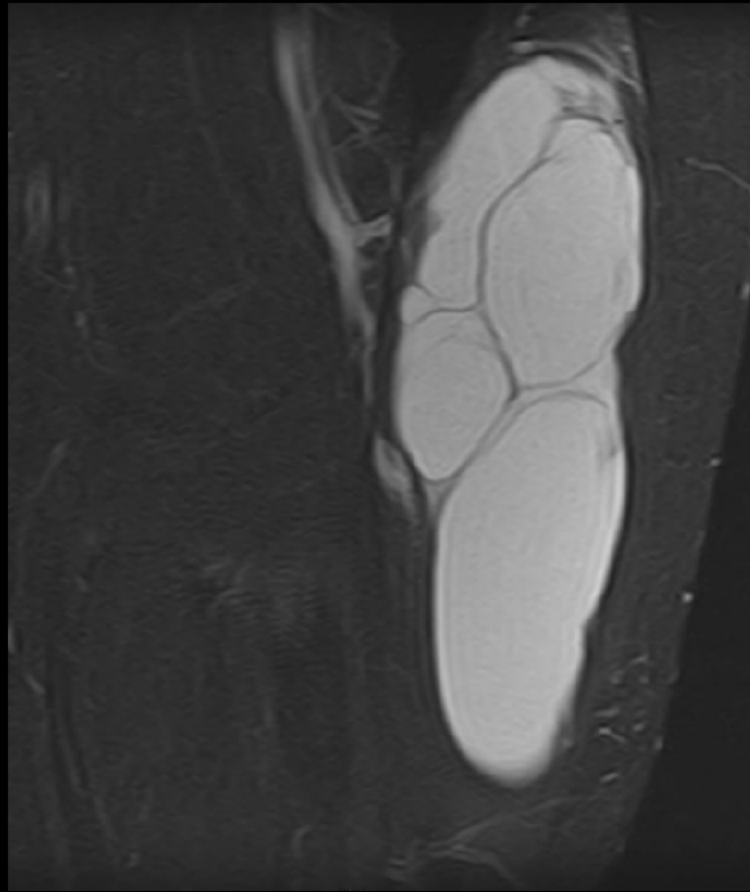
**AIRP**<sup>TM</sup>

AMERICAN INSTITUTE FOR  
RADIOLOGIC PATHOLOGY

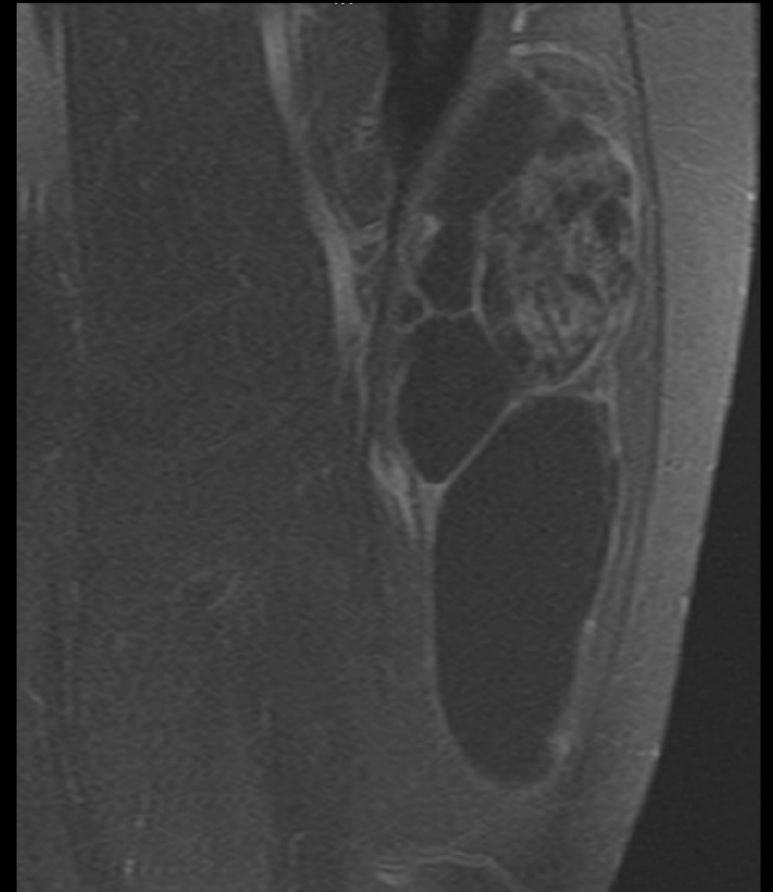
A PROGRAM OF THE  
AMERICAN COLLEGE OF RADIOLOGY



**Coronal T1**



**Coronal STIR**



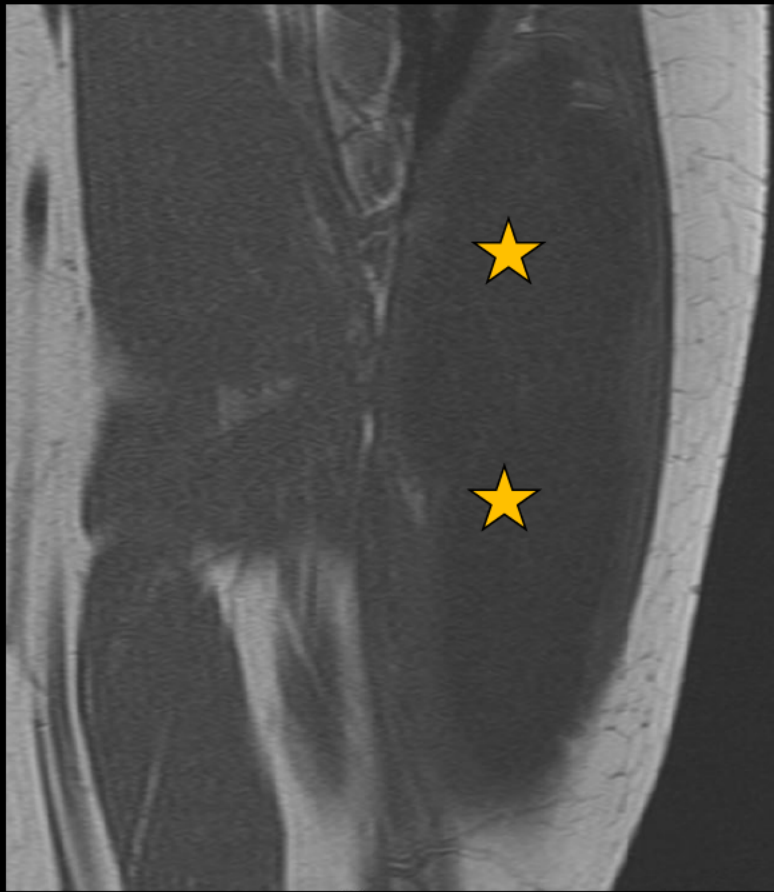
**Coronal T1 FS +C**

**AIRP**<sup>TM</sup>

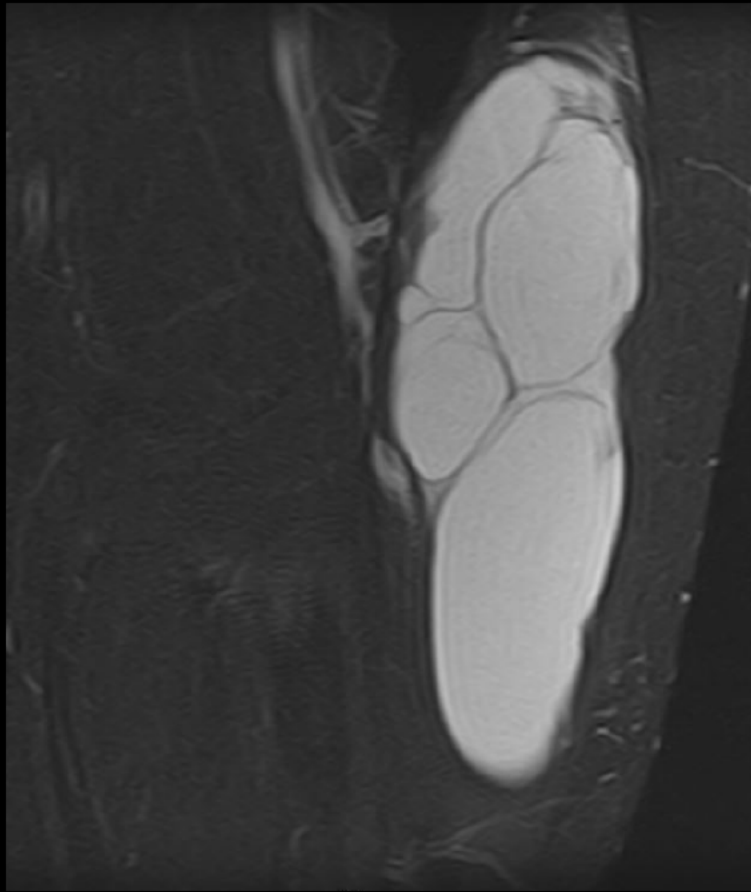
AMERICAN INSTITUTE FOR  
RADIOLOGIC PATHOLOGY

A PROGRAM OF THE  
AMERICAN COLLEGE OF RADIOLOGY

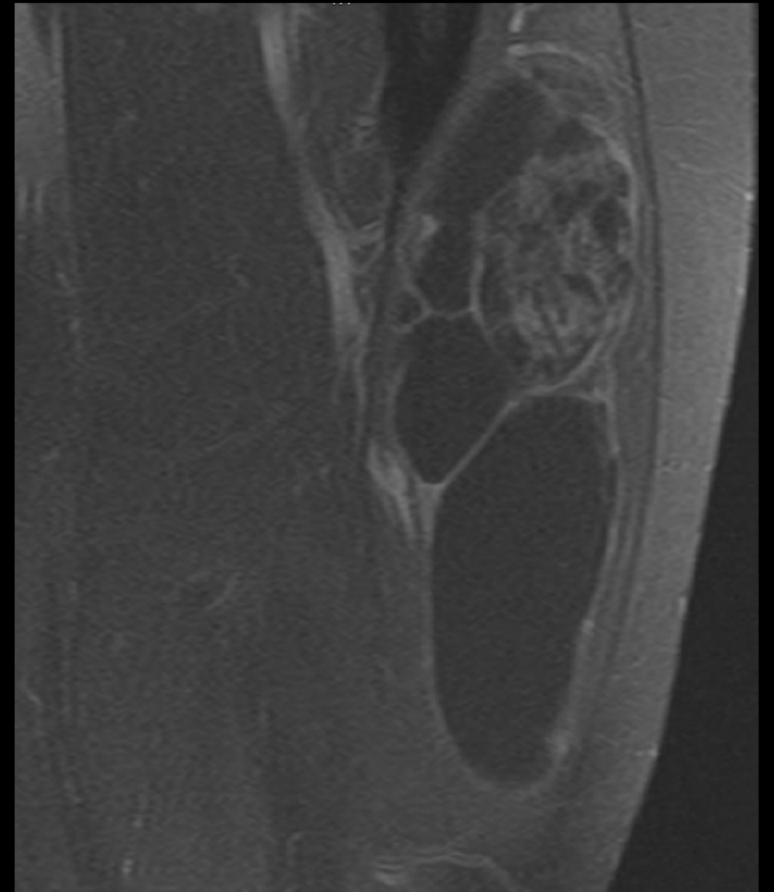




**Coronal T1**



**Coronal STIR**



**Coronal T1 FS +C**

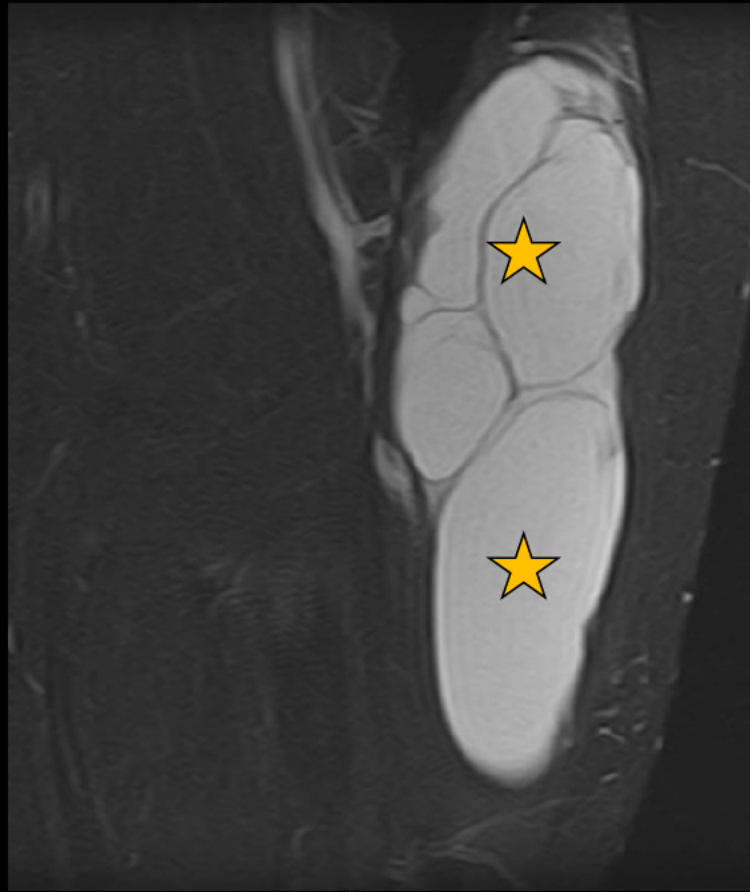**AIRP**<sup>TM</sup>

AMERICAN INSTITUTE FOR  
RADIOLOGIC PATHOLOGY

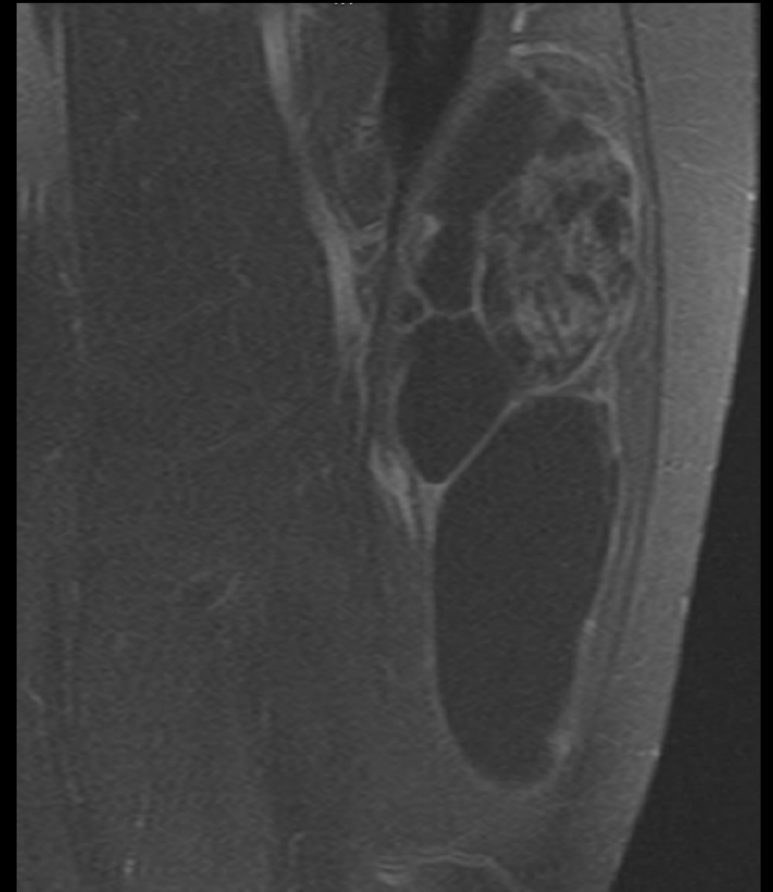
A PROGRAM OF THE  
AMERICAN COLLEGE OF RADIOLOGY



**Coronal T1**



**Coronal STIR**



**Coronal T1 FS +C**

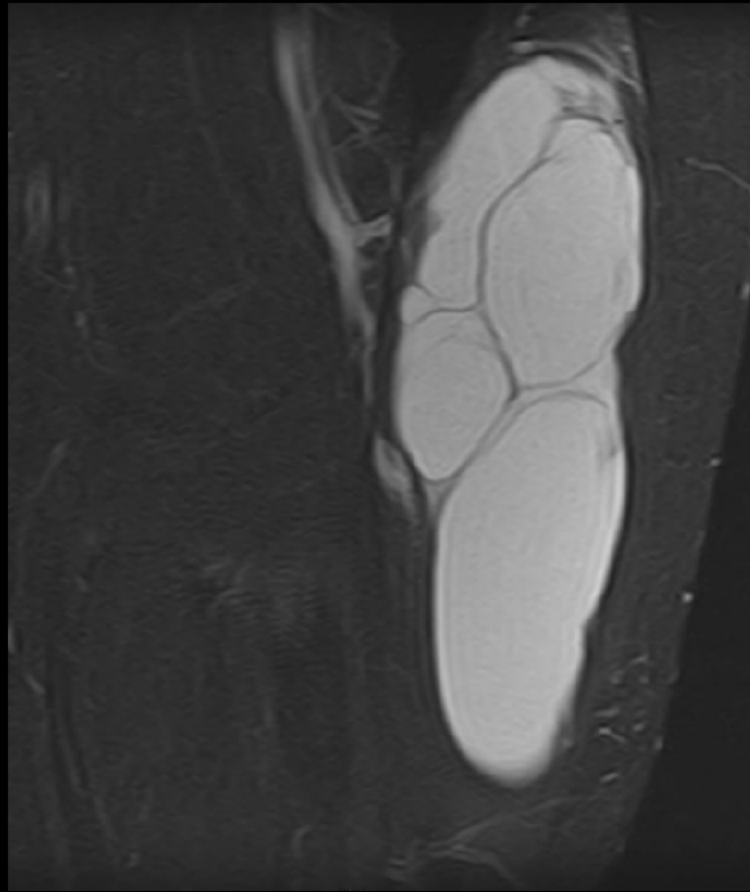
**AIRP**<sup>TM</sup>

AMERICAN INSTITUTE FOR  
RADIOLOGIC PATHOLOGY

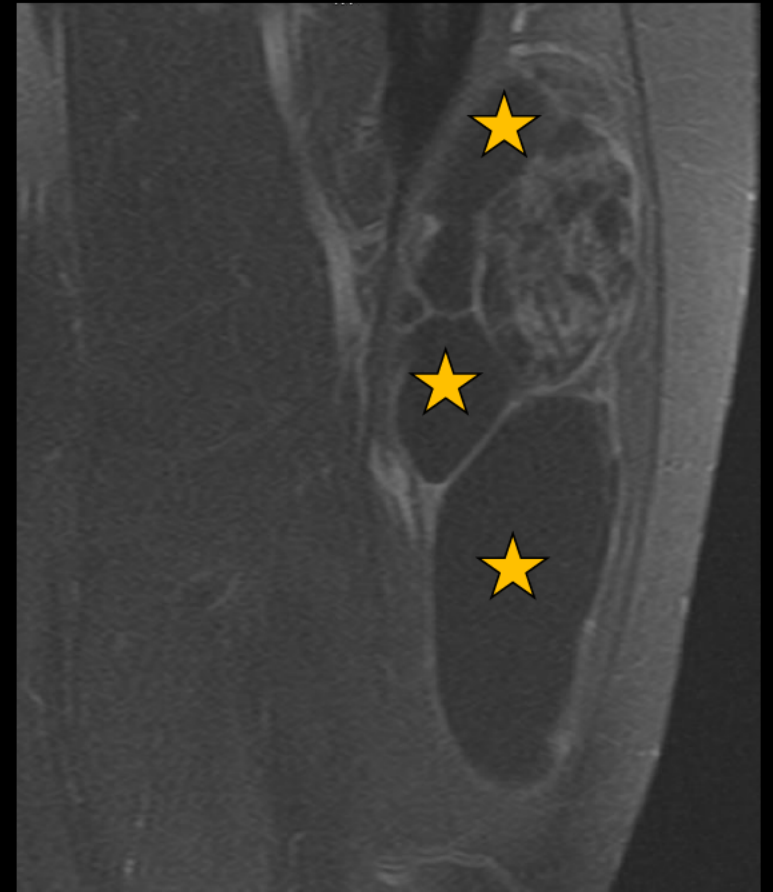
A PROGRAM OF THE  
AMERICAN COLLEGE OF RADIOLOGY



**Coronal T1**



**Coronal STIR**

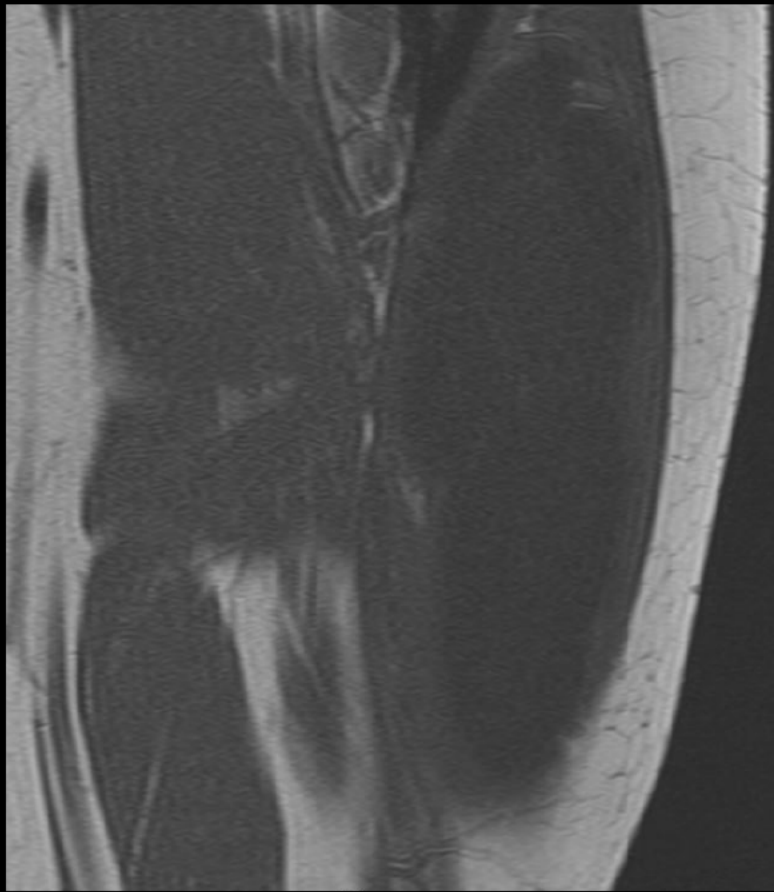


**Coronal T1 FS +C**

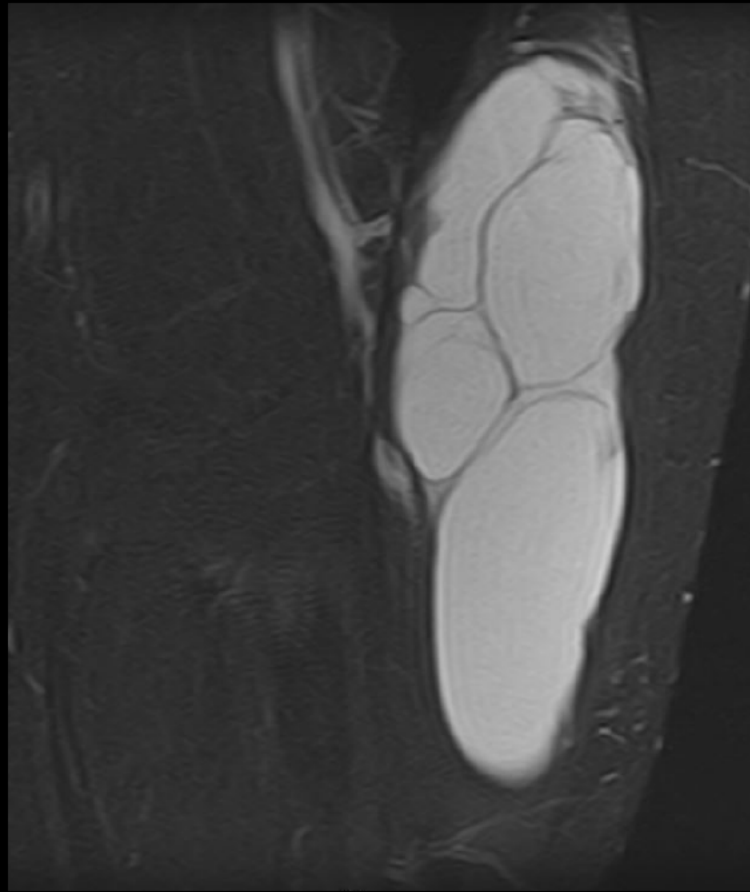
**AIRP**<sup>TM</sup>

AMERICAN INSTITUTE FOR  
RADIOLOGIC PATHOLOGY

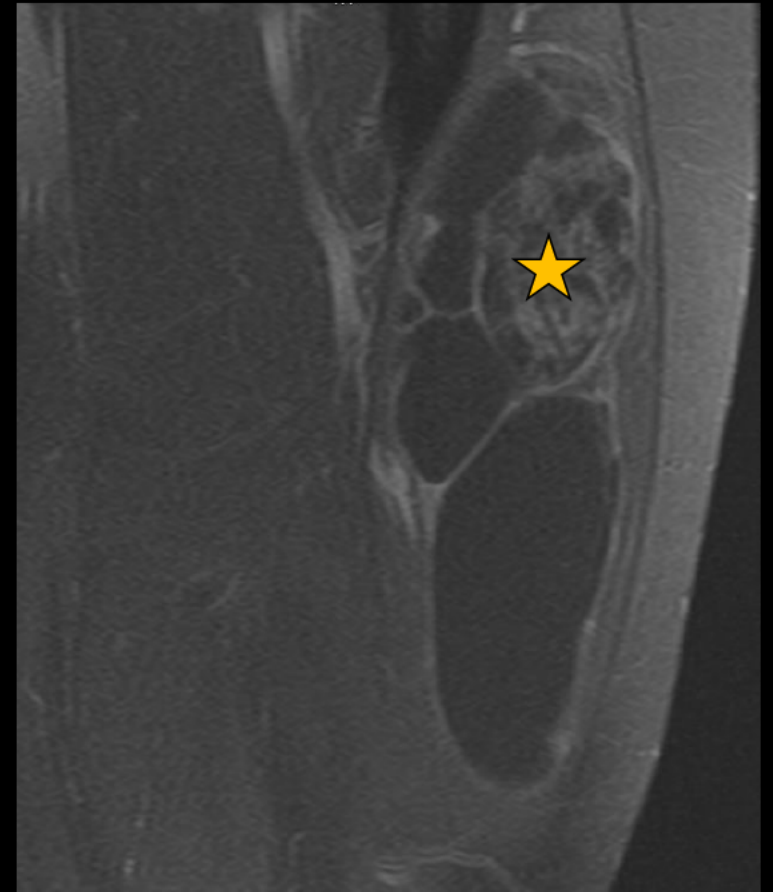
A PROGRAM OF THE  
AMERICAN COLLEGE OF RADIOLOGY



**Coronal T1**



**Coronal STIR**



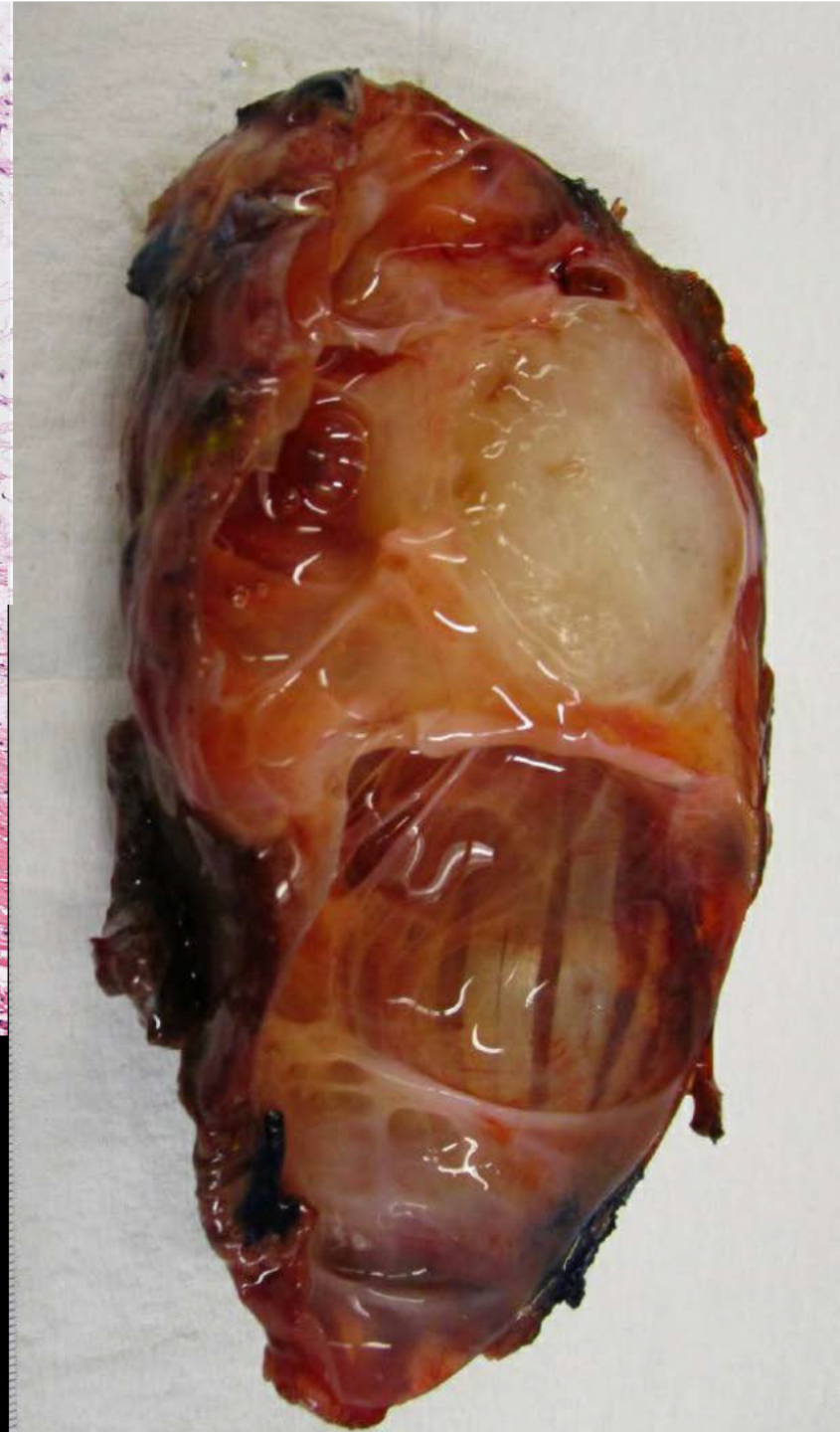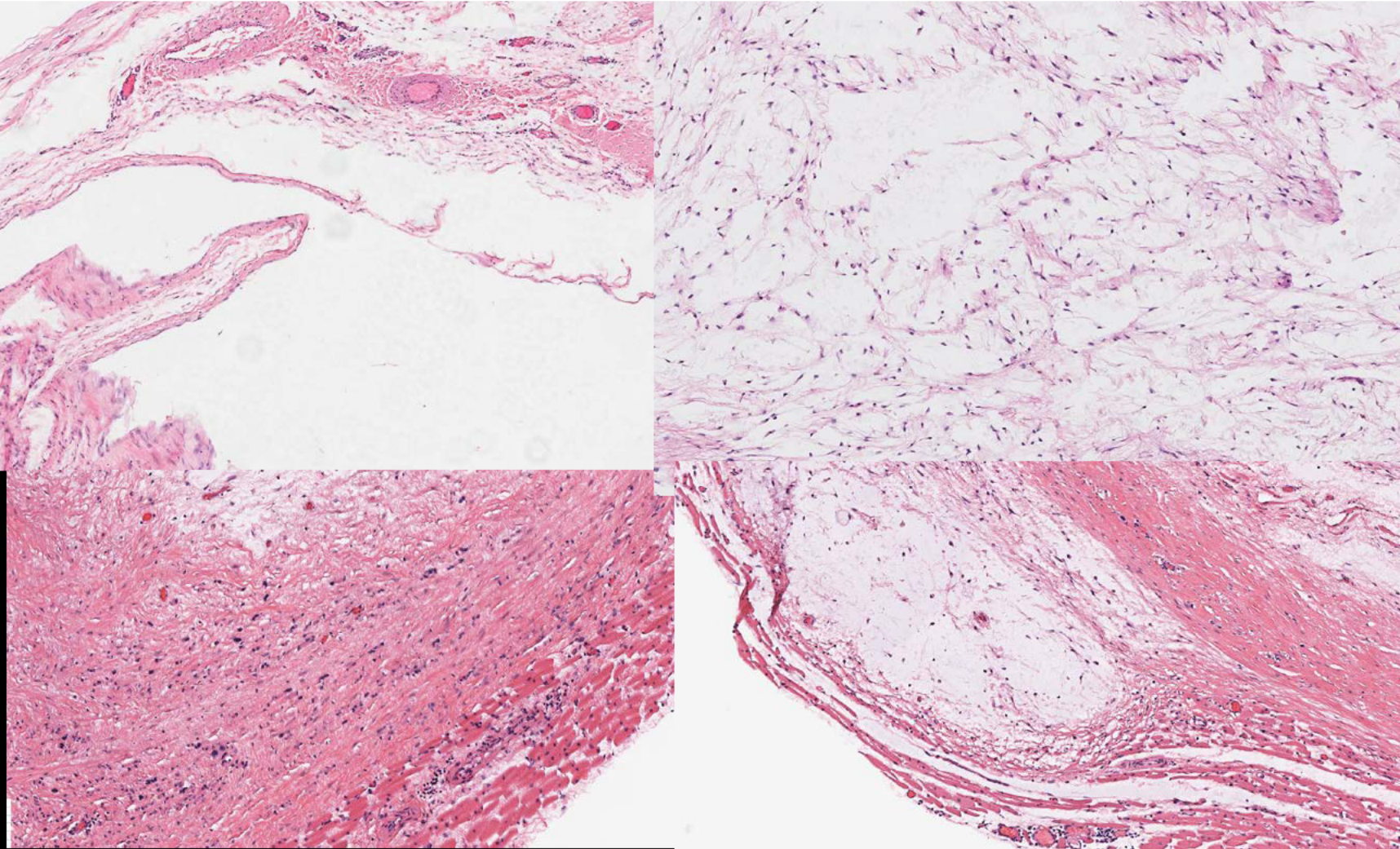
**Coronal T1 FS +C**

**AIRP**<sup>TM</sup>

AMERICAN INSTITUTE FOR  
RADIOLOGIC PATHOLOGY

A PROGRAM OF THE  
AMERICAN COLLEGE OF RADIOLOGY



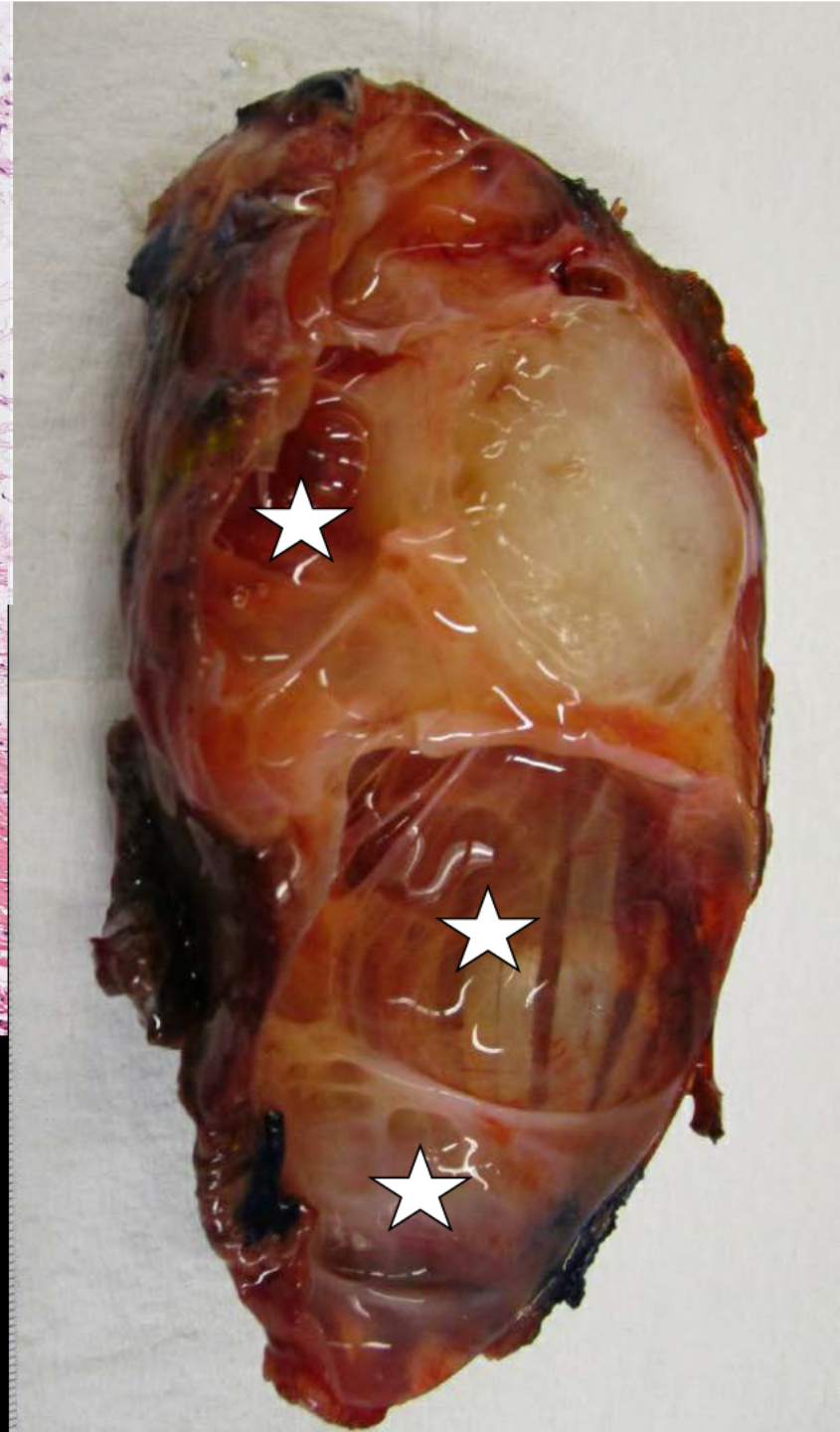
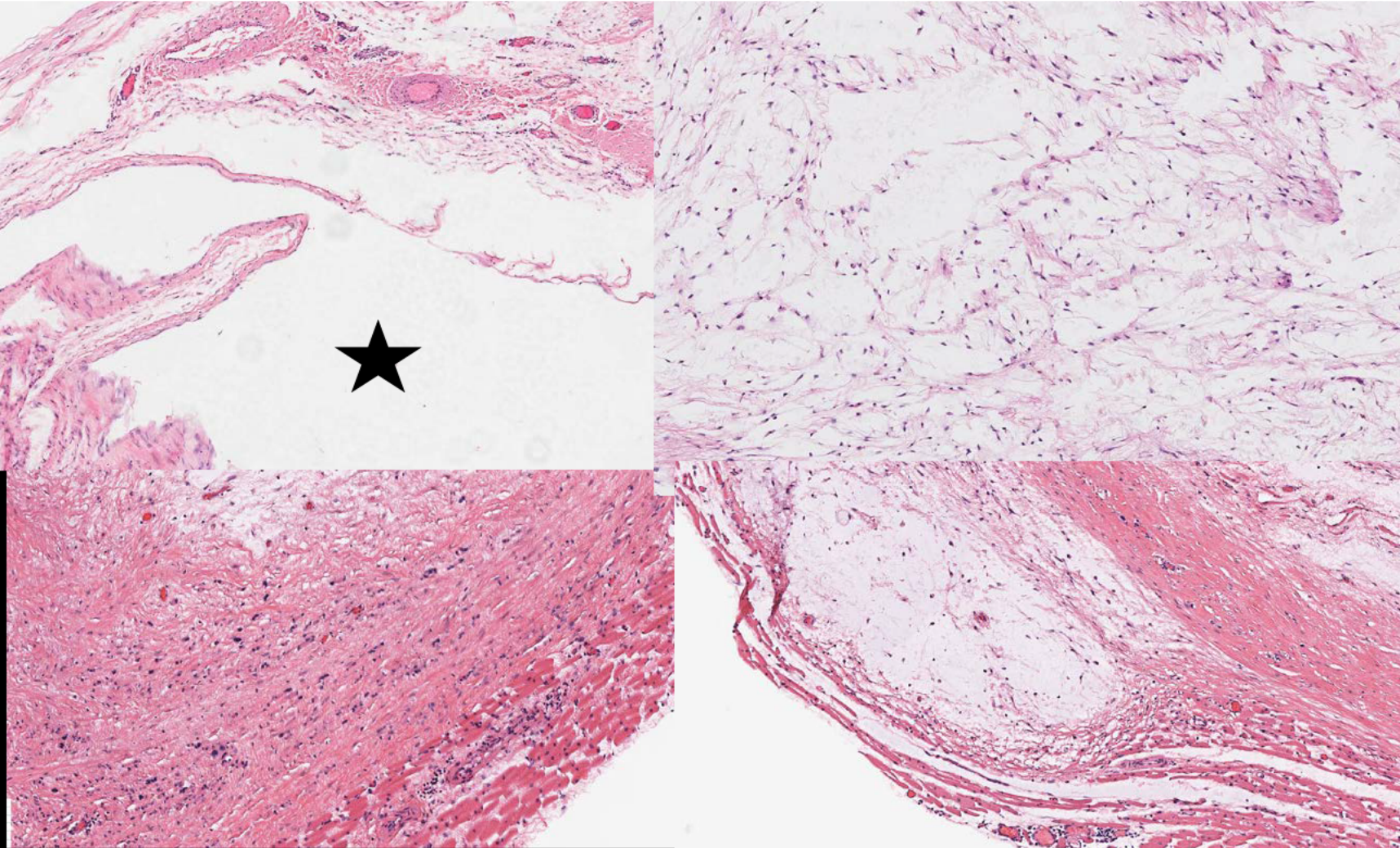


**AIRP**<sup>TM</sup>

AMERICAN INSTITUTE FOR  
RADIOLOGIC PATHOLOGY

A PROGRAM OF THE  
AMERICAN COLLEGE OF RADIOLOGY



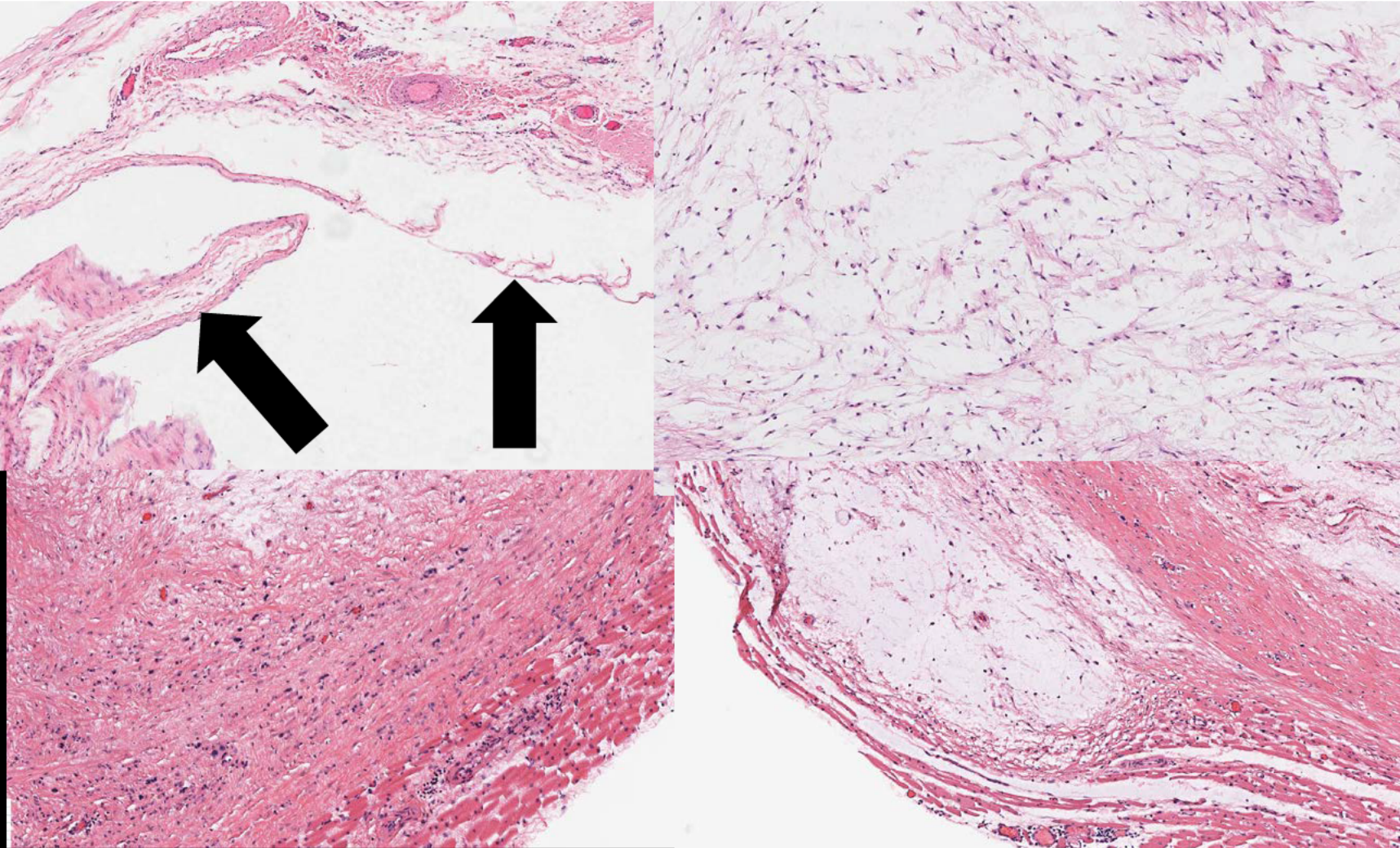


**AIRP**<sup>TM</sup>

AMERICAN INSTITUTE FOR  
RADIOLOGIC PATHOLOGY

A PROGRAM OF THE  
AMERICAN COLLEGE OF RADIOLOGY



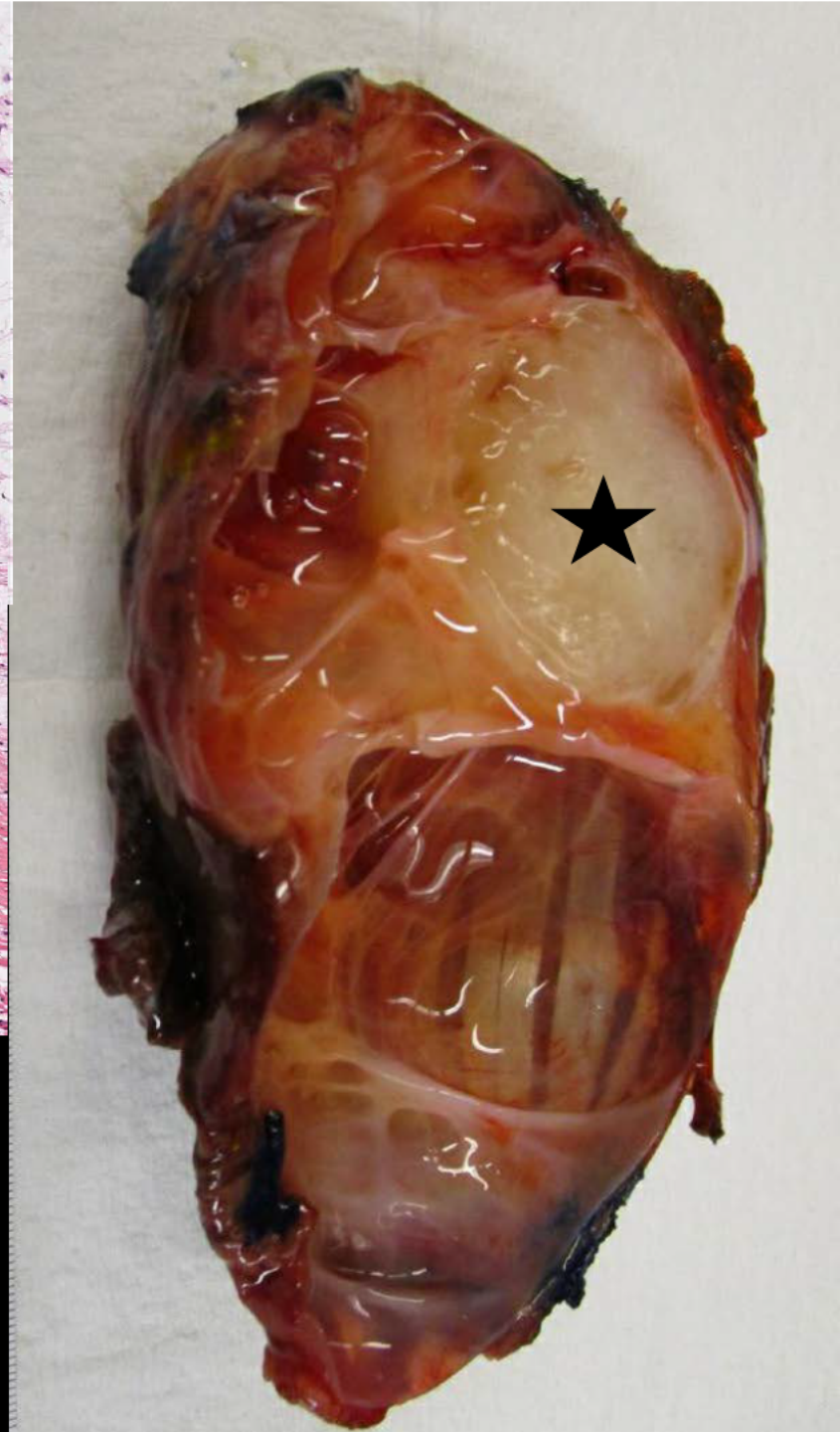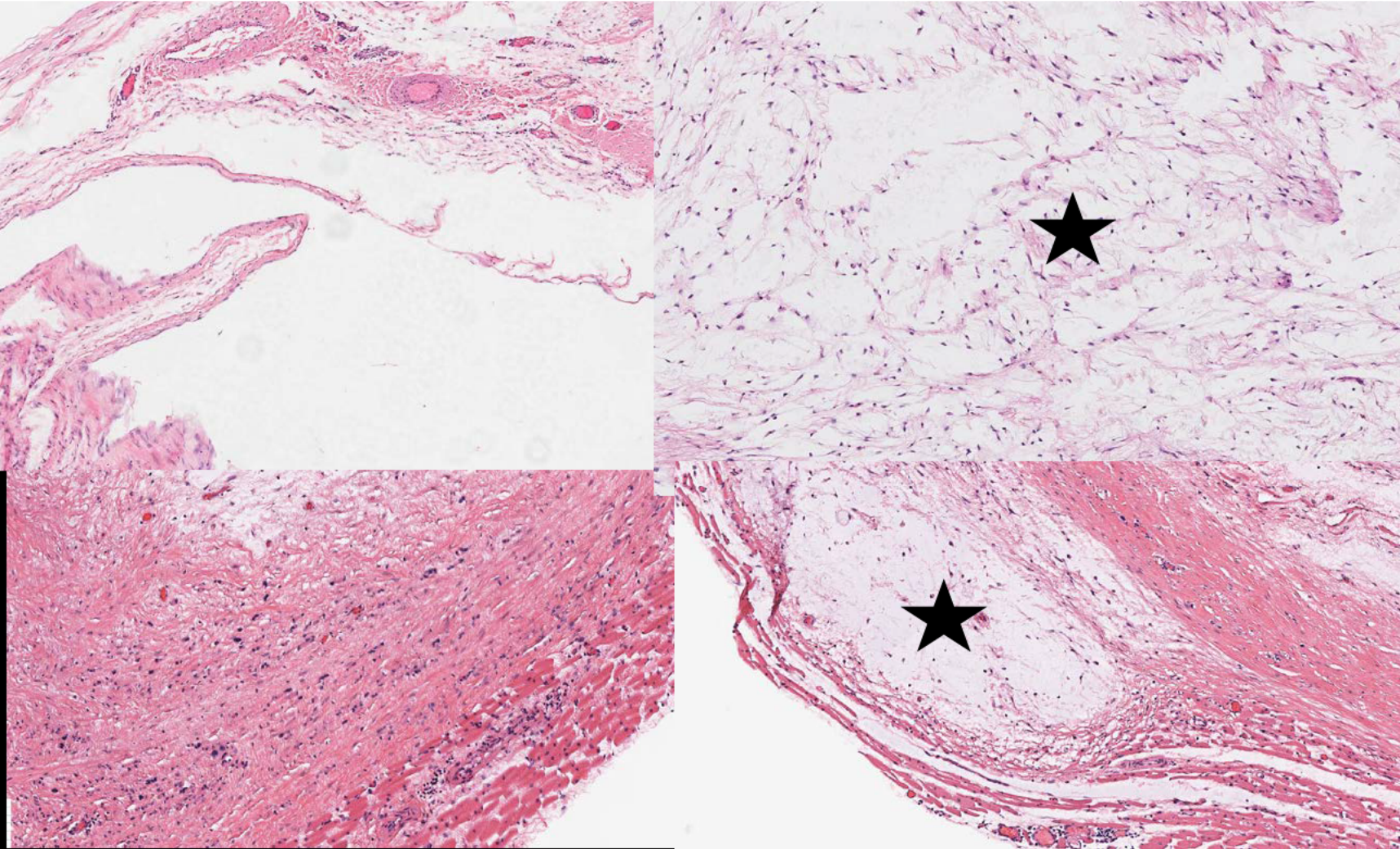


**AIRP**<sup>TM</sup>

AMERICAN INSTITUTE FOR  
RADIOLOGIC PATHOLOGY

A PROGRAM OF THE  
AMERICAN COLLEGE OF RADIOLOGY



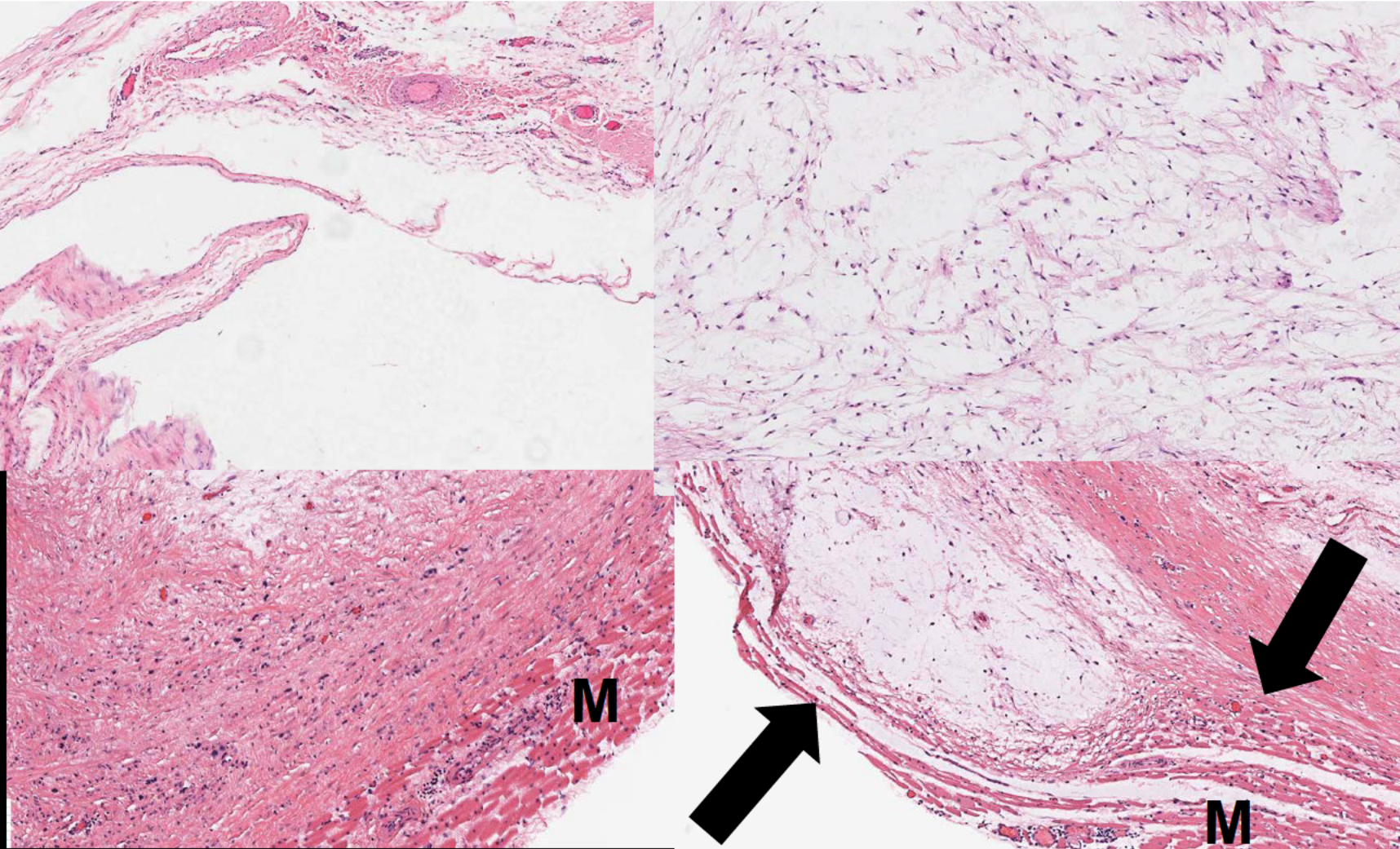


**AIRP**<sup>TM</sup>

AMERICAN INSTITUTE FOR  
RADIOLOGIC PATHOLOGY

A PROGRAM OF THE  
AMERICAN COLLEGE OF RADIOLOGY



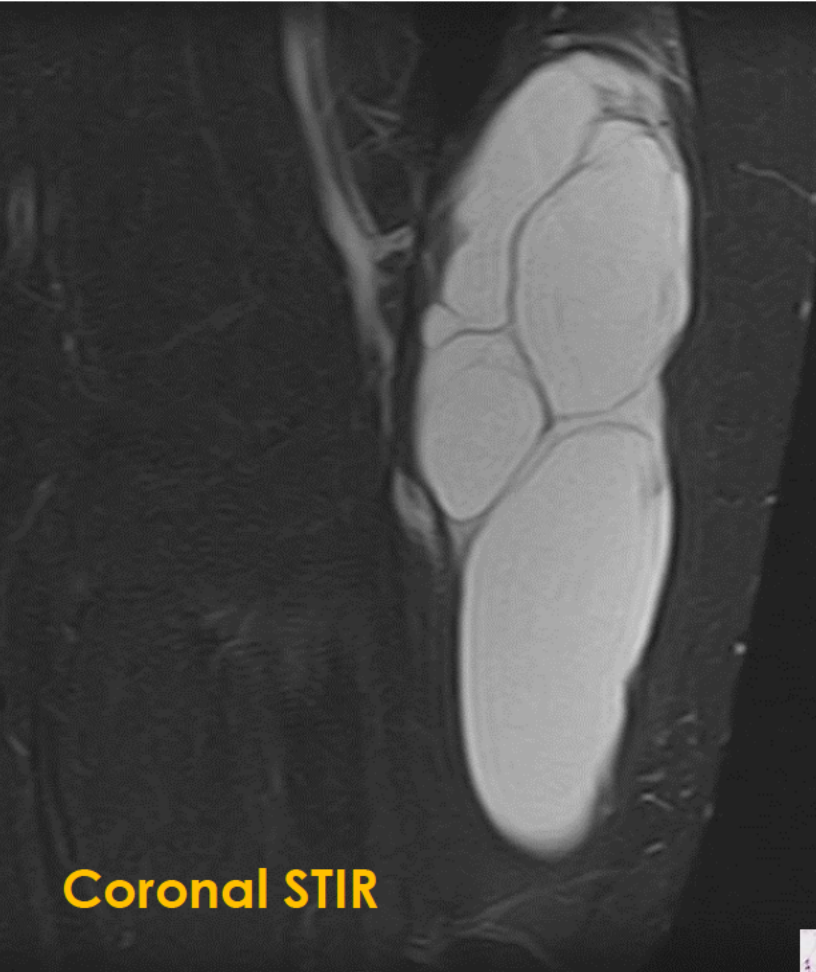

**AIRP**<sup>TM</sup>

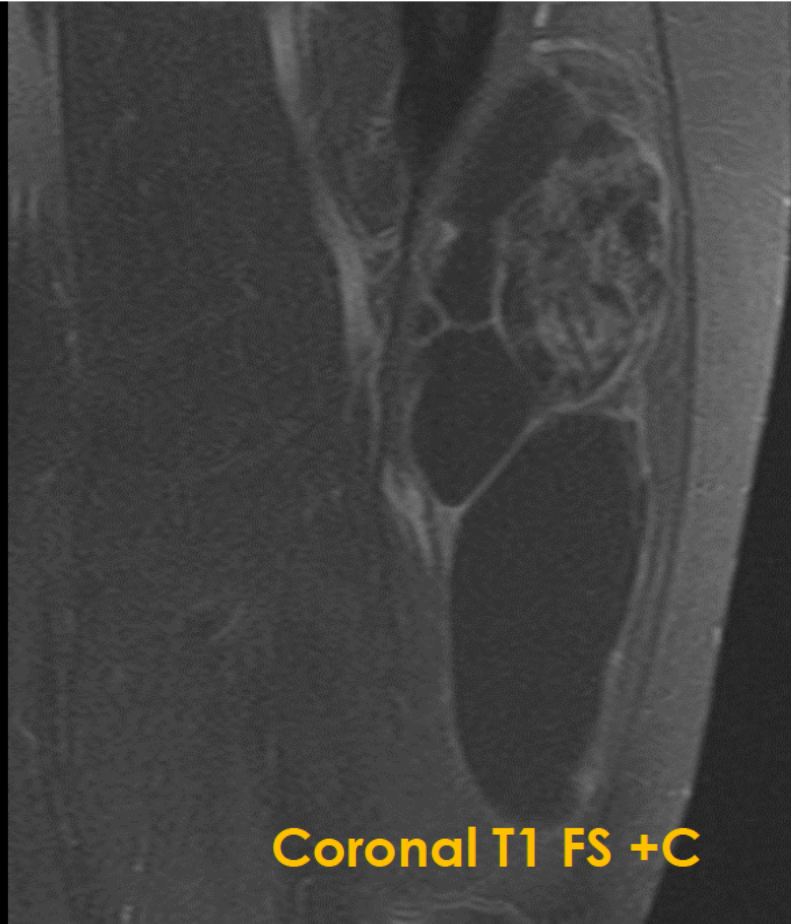AMERICAN INSTITUTE FOR  
RADIOLOGIC PATHOLOGY

A PROGRAM OF THE  
AMERICAN COLLEGE OF RADIOLOGY

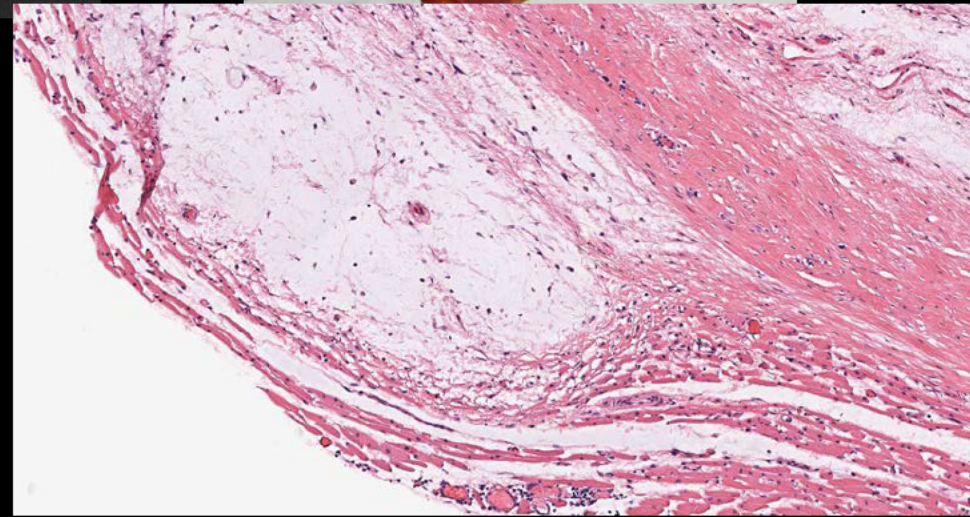
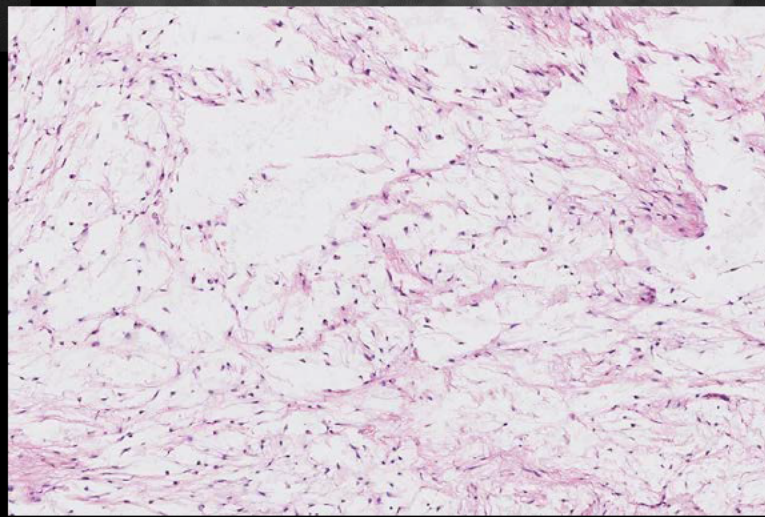
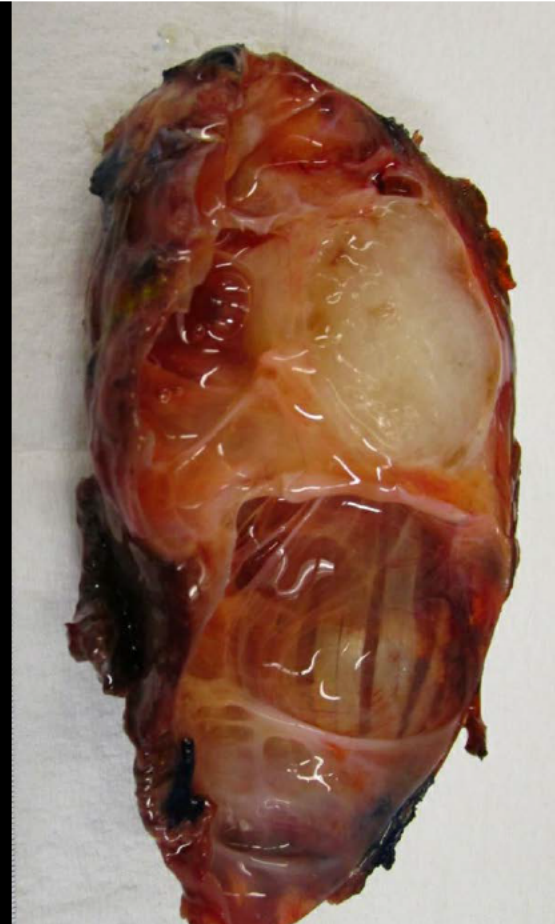



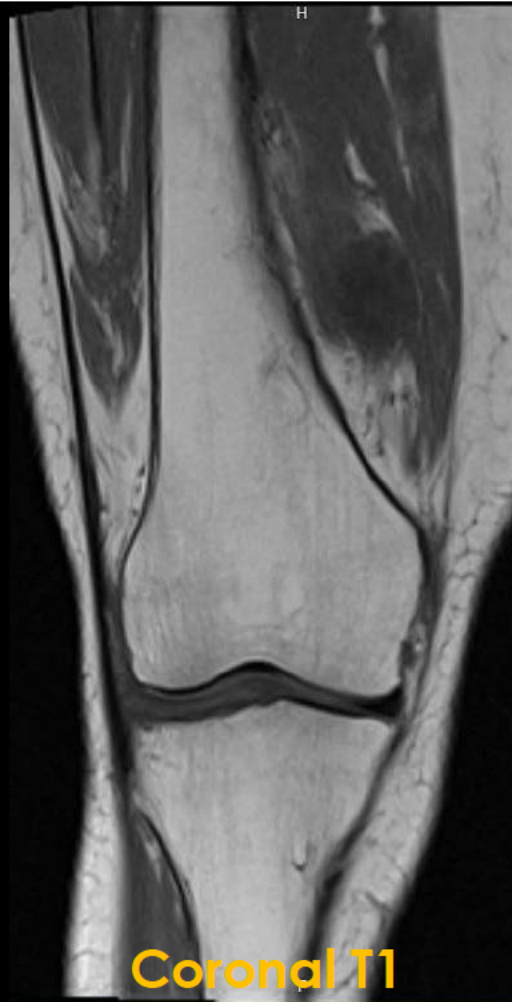Coronal STIR



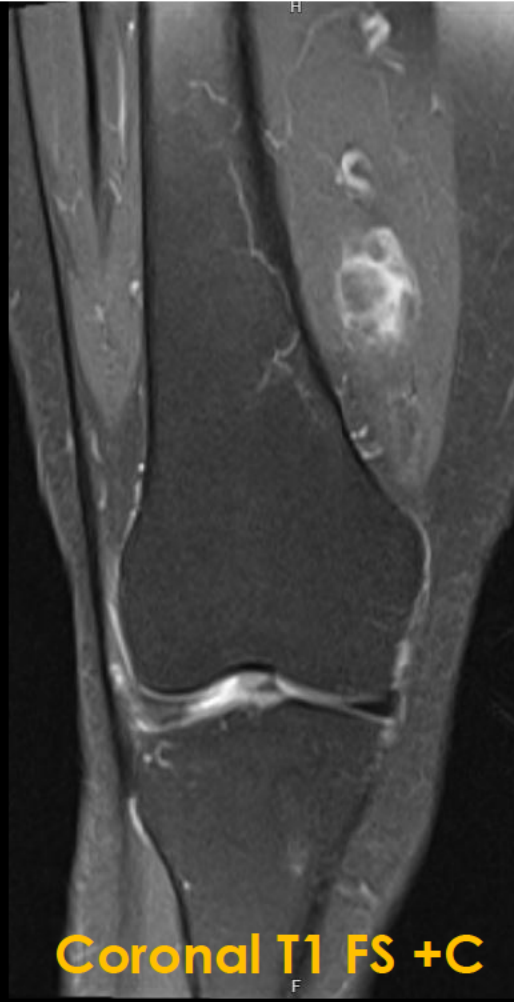
Coronal T1 FS +C



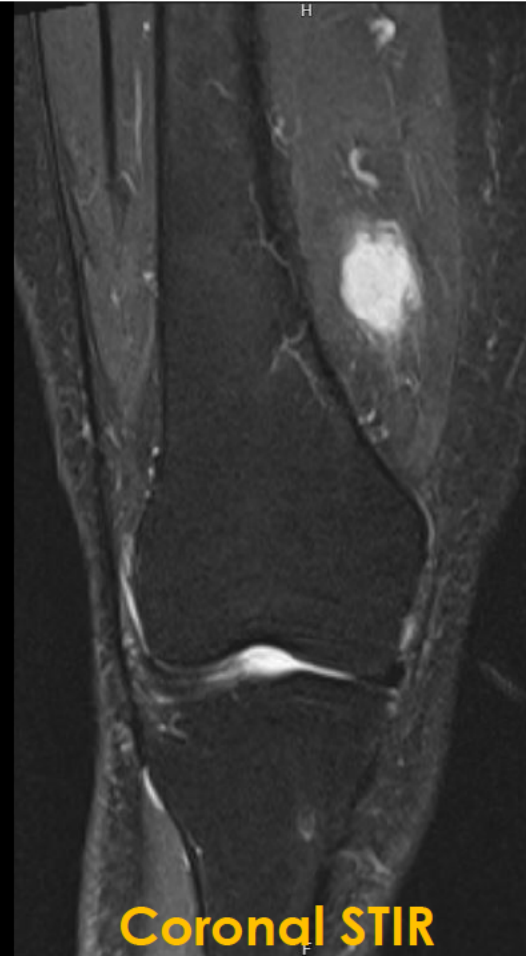



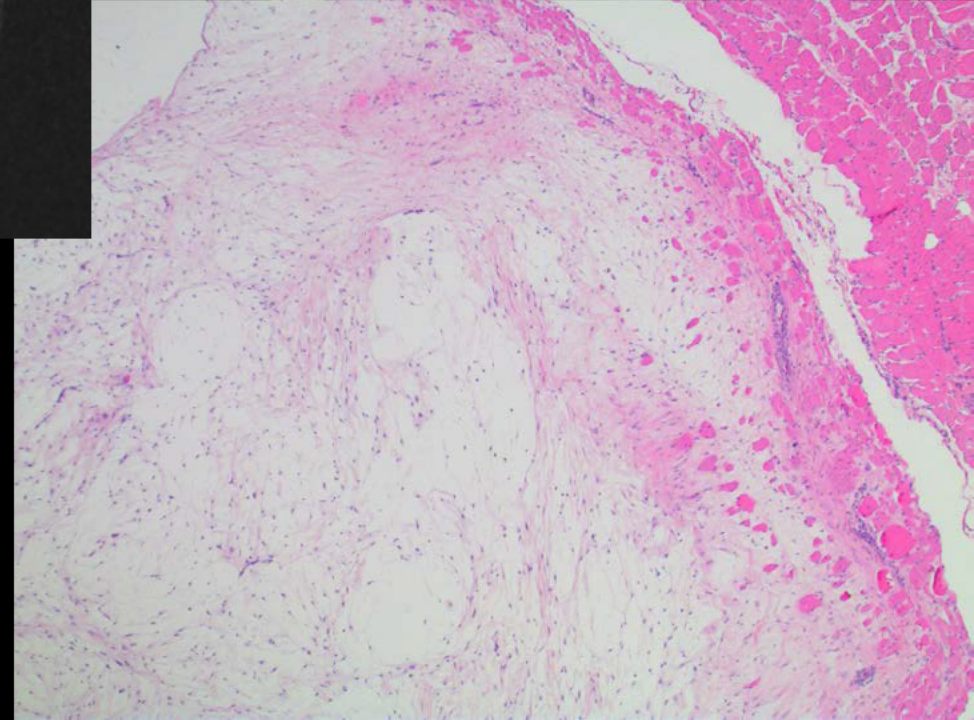
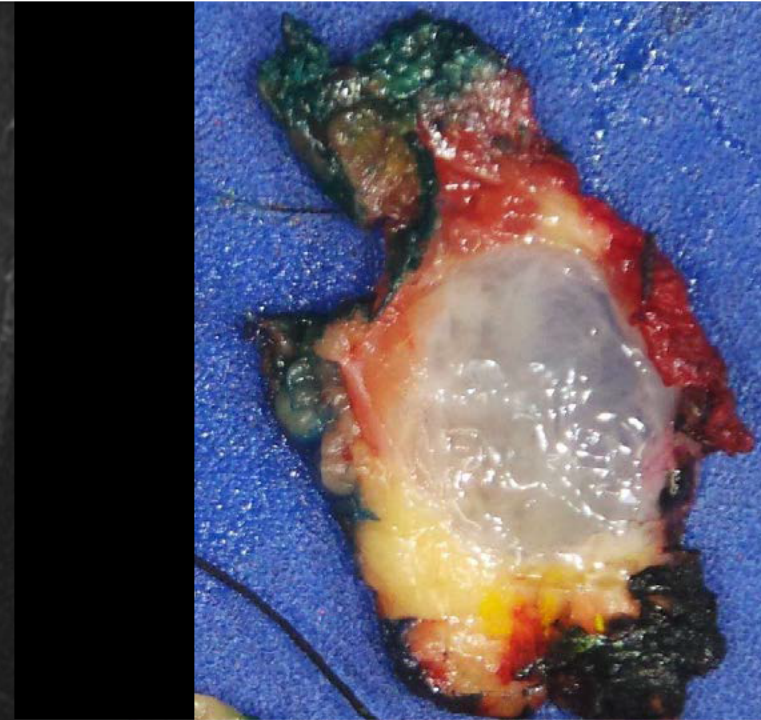
Coronal T1



Coronal T1 FS +C



Coronal STIR

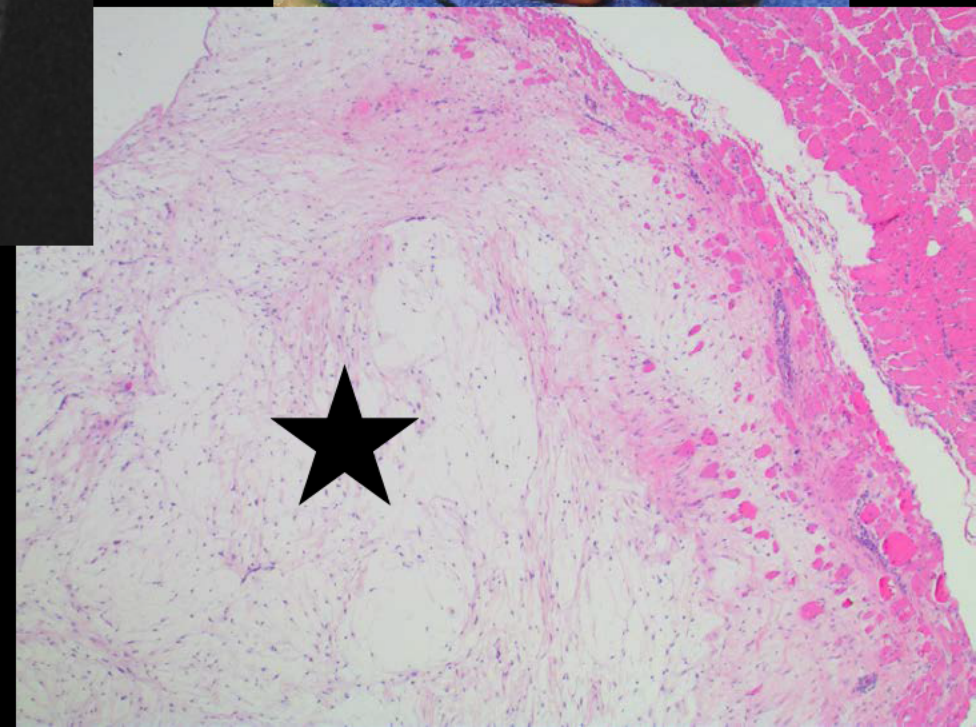
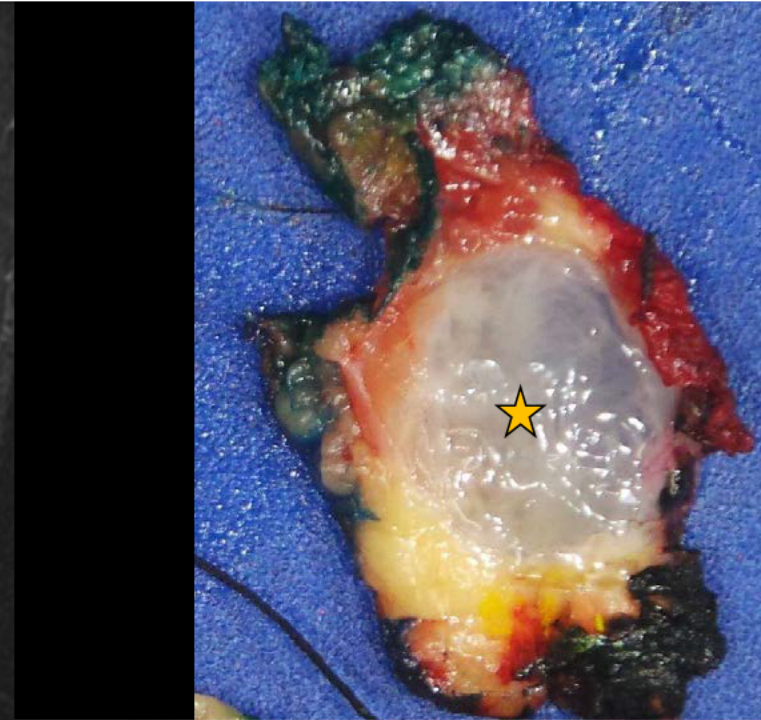
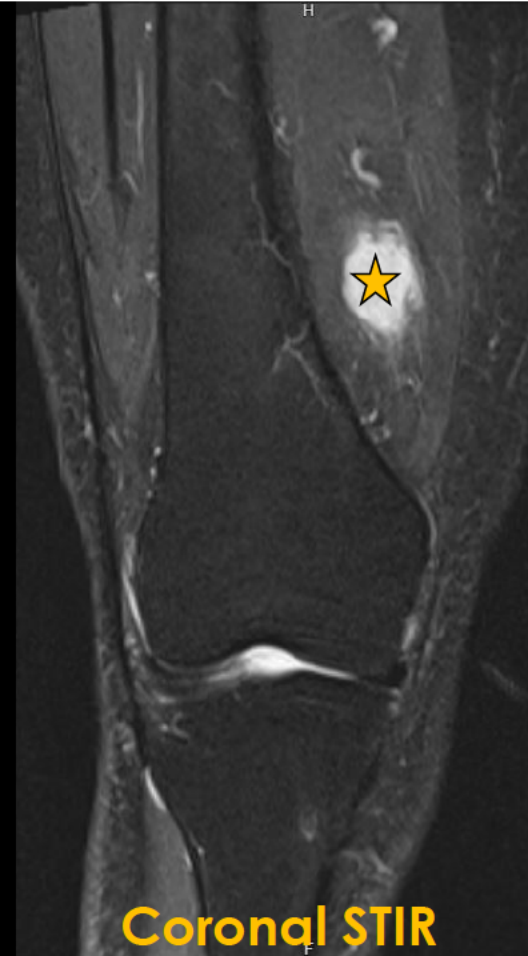
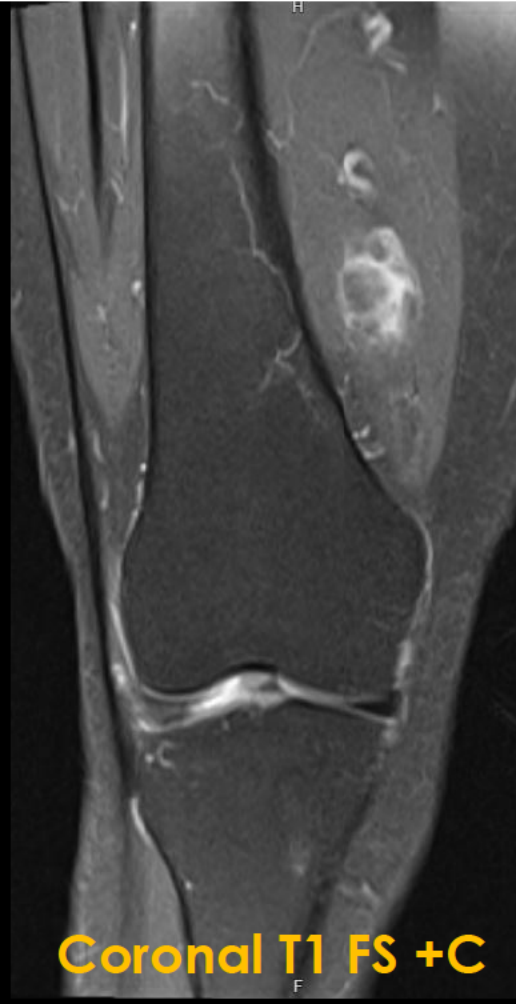
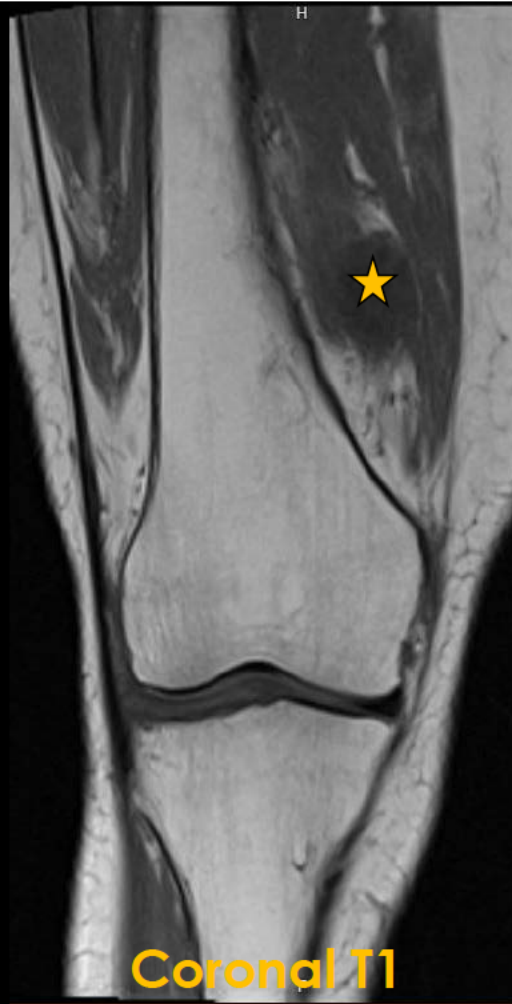

**AIRP**<sup>TM</sup>

AMERICAN INSTITUTE FOR  
RADIOLOGIC PATHOLOGY

A PROGRAM OF THE  
AMERICAN COLLEGE OF RADIOLOGY





**AIRP**<sup>TM</sup>

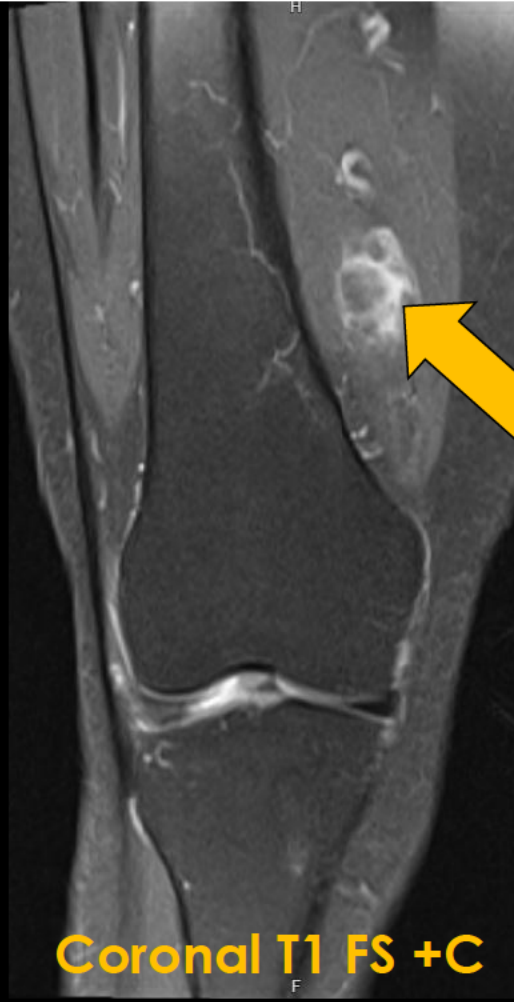
AMERICAN INSTITUTE FOR  
RADIOLOGIC PATHOLOGY

A PROGRAM OF THE  
AMERICAN COLLEGE OF RADIOLOGY





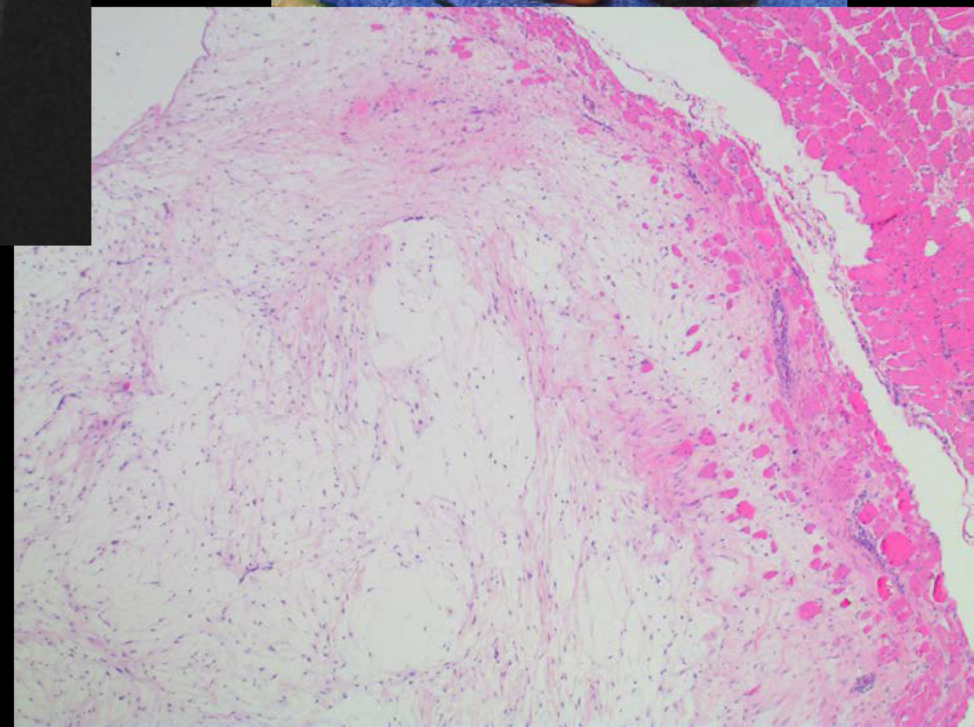
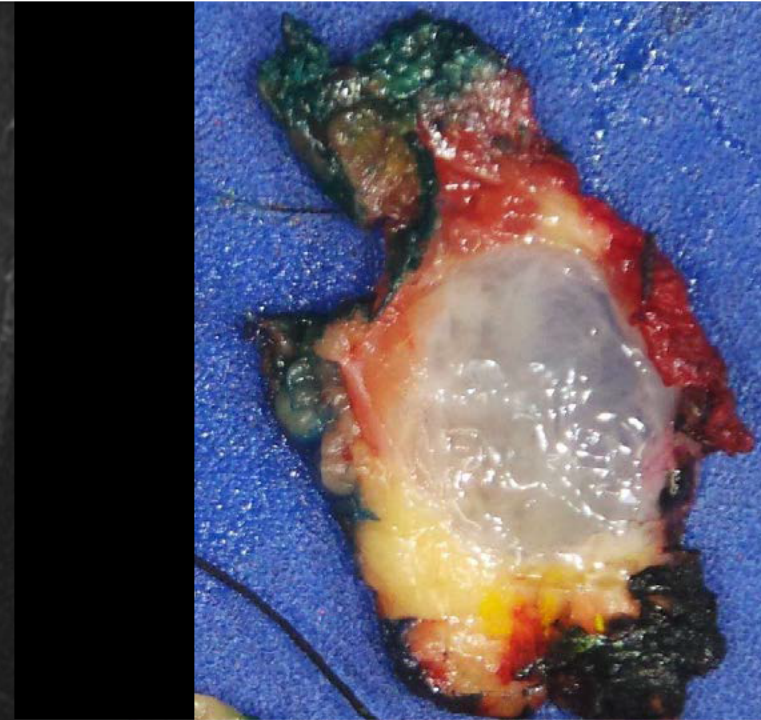
Coronal T1



Coronal T1 FS +C



Coronal STIR

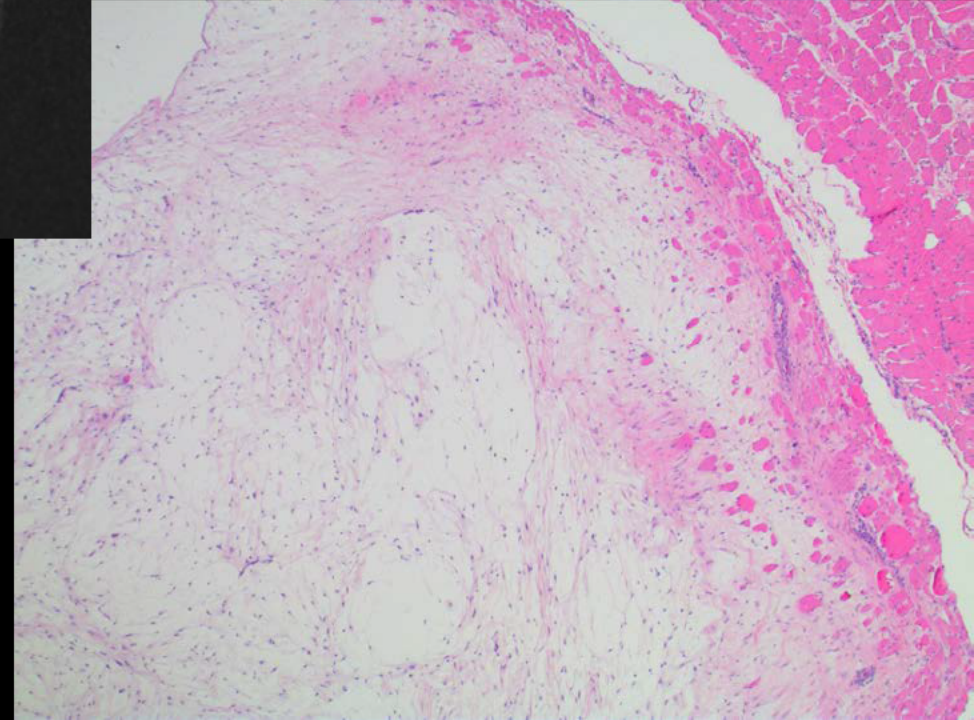
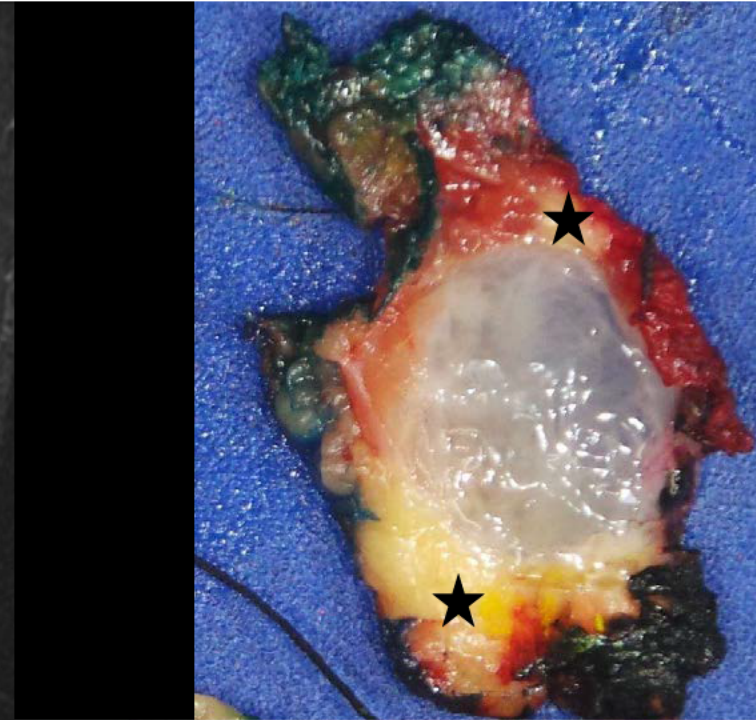
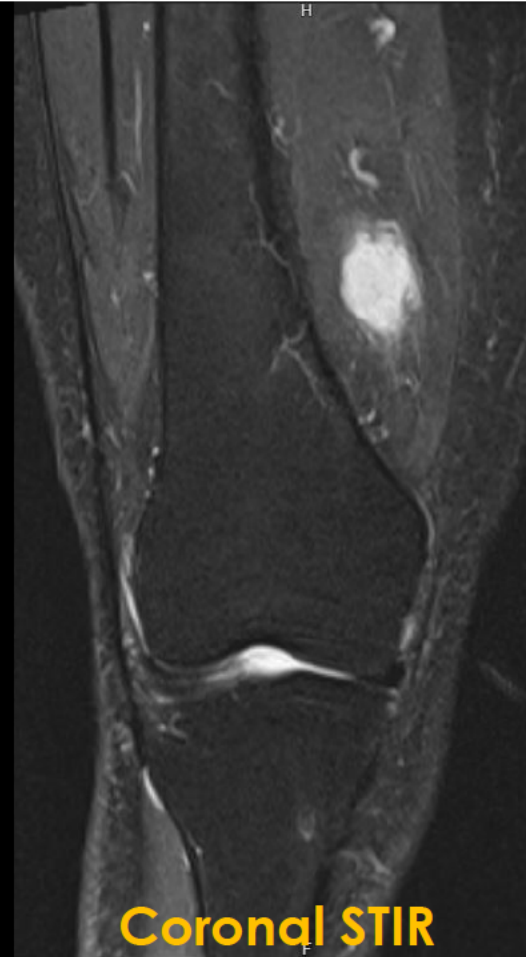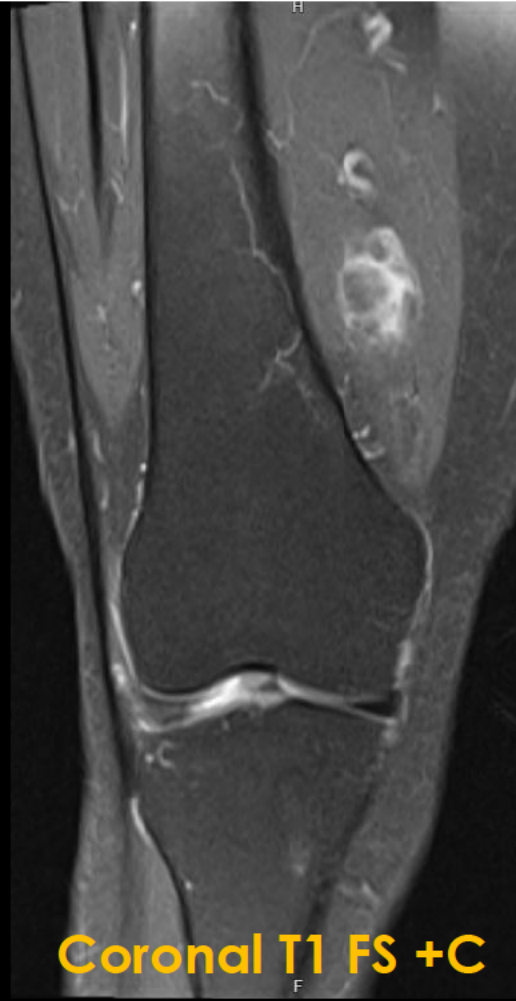

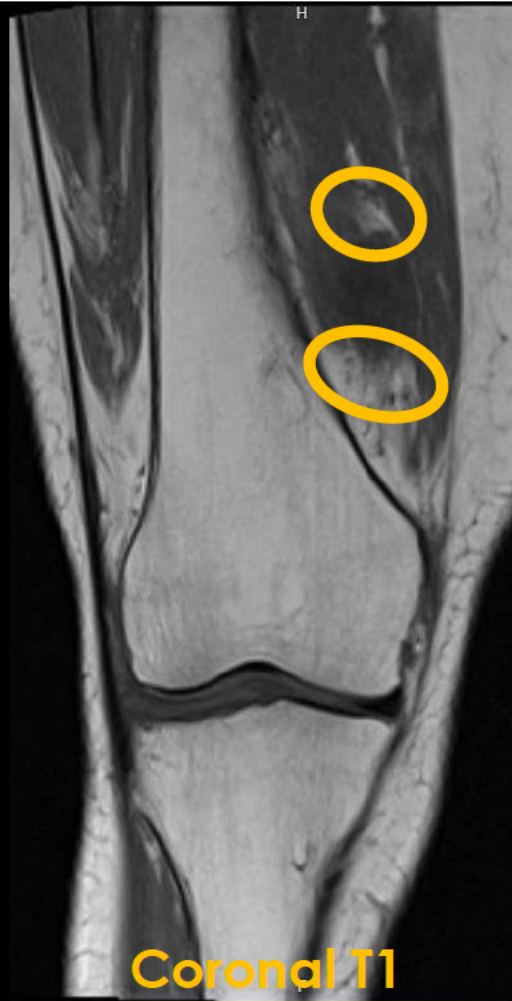
**AIRP**<sup>TM</sup>

AMERICAN INSTITUTE FOR  
RADIOLOGIC PATHOLOGY

A PROGRAM OF THE  
AMERICAN COLLEGE OF RADIOLOGY

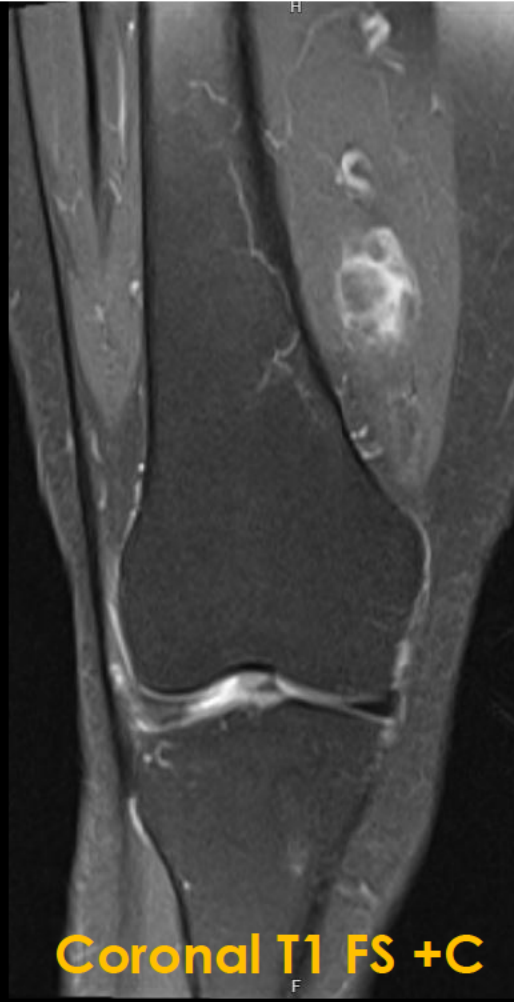




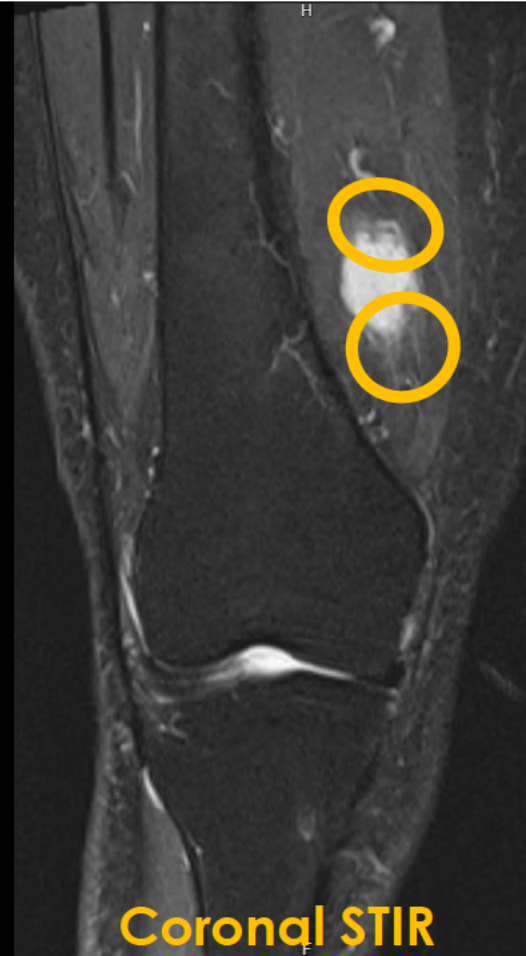




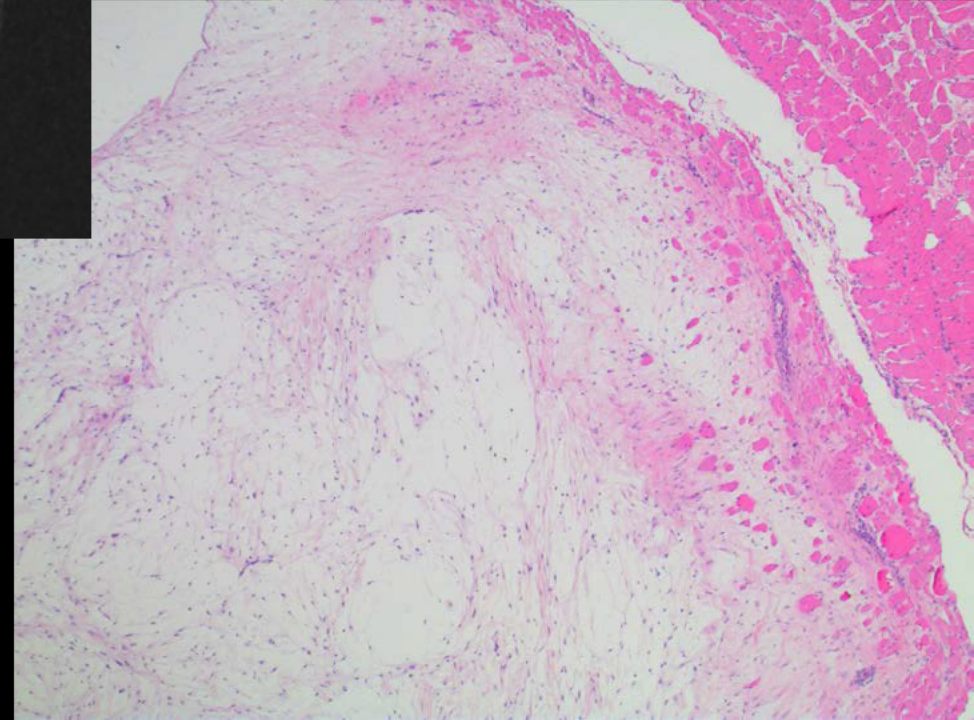
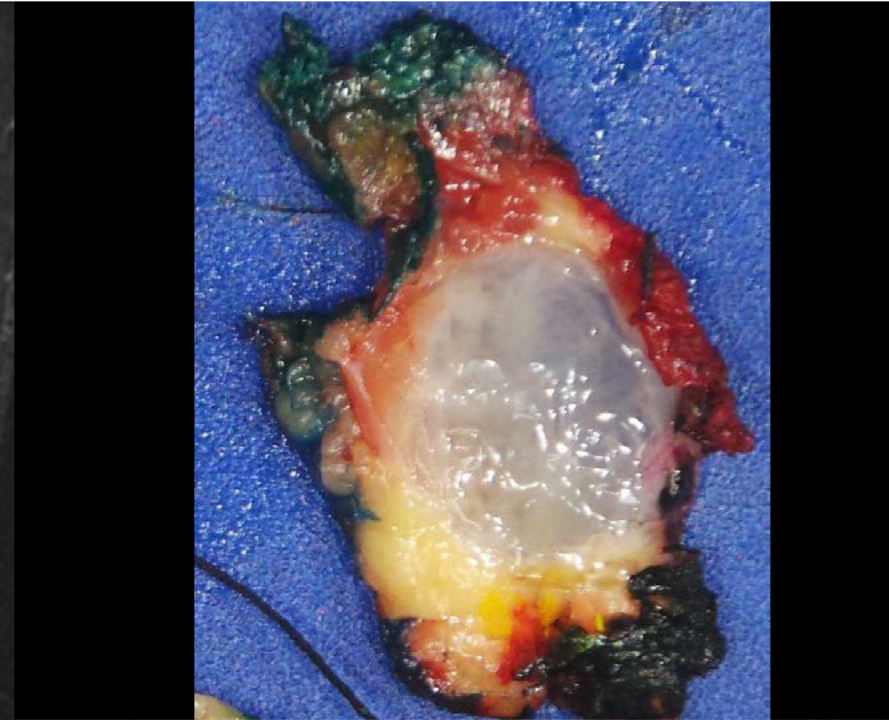
Coronal T1



Coronal T1 FS + C



Coronal STIR

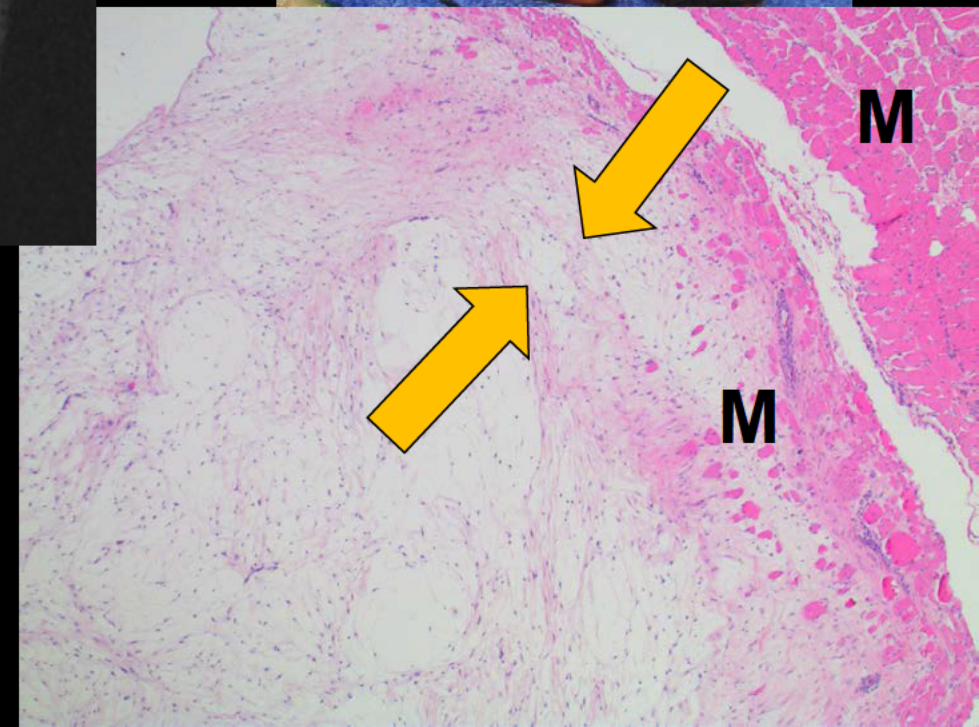
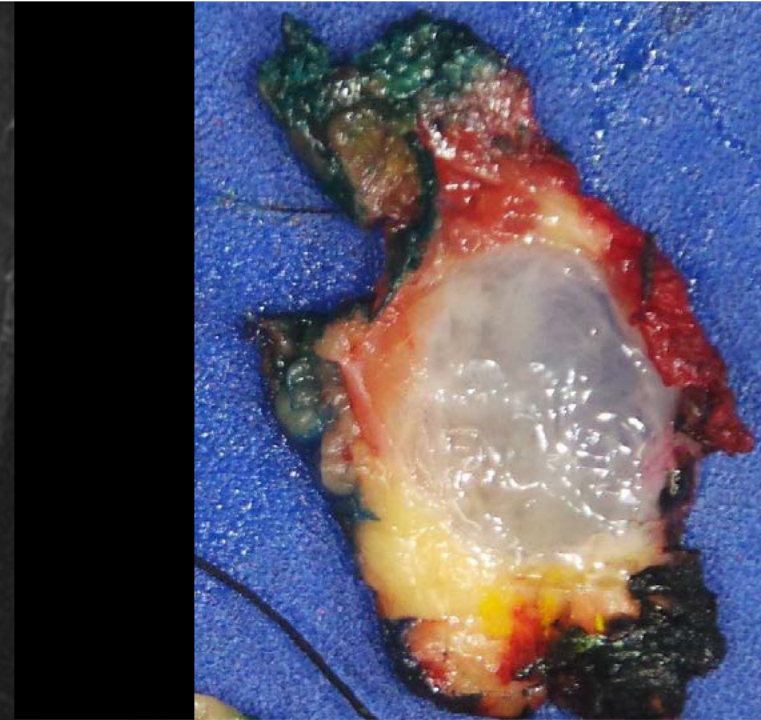
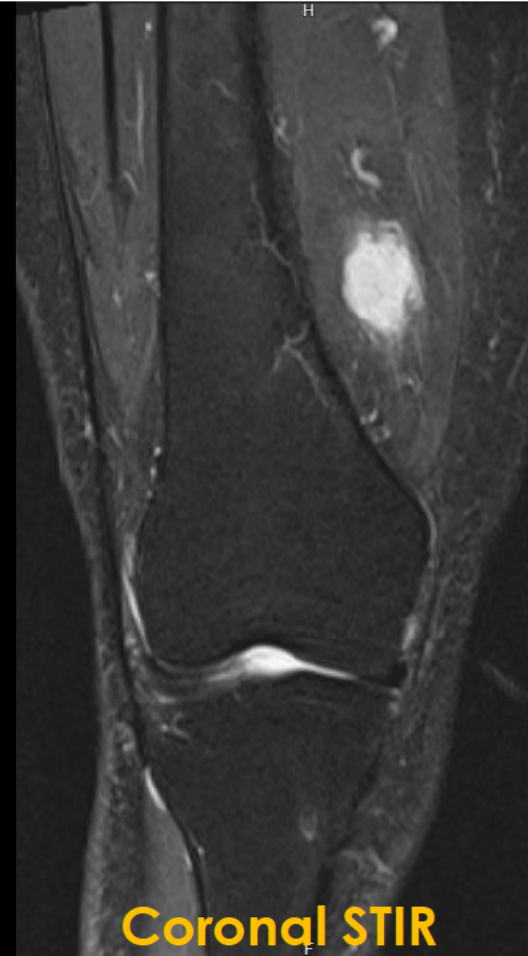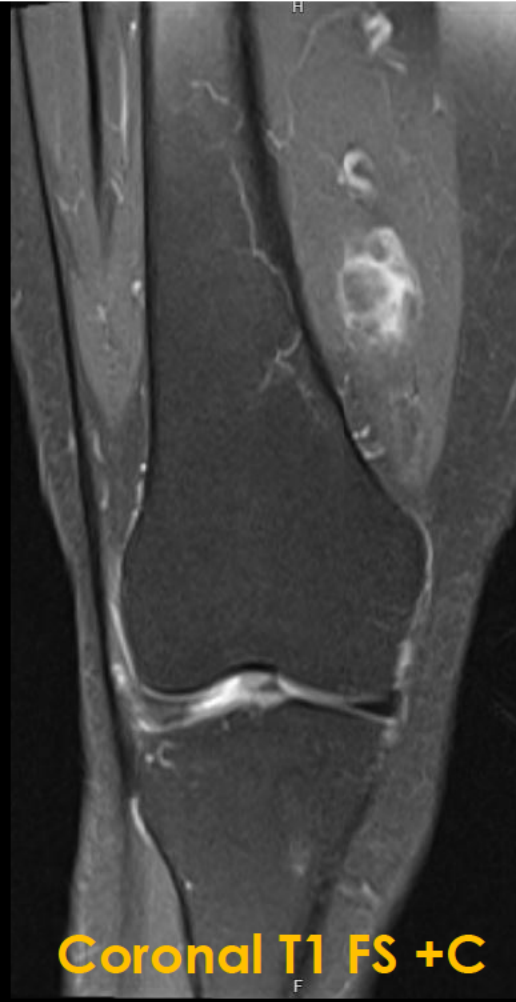


**AIRP**<sup>TM</sup>

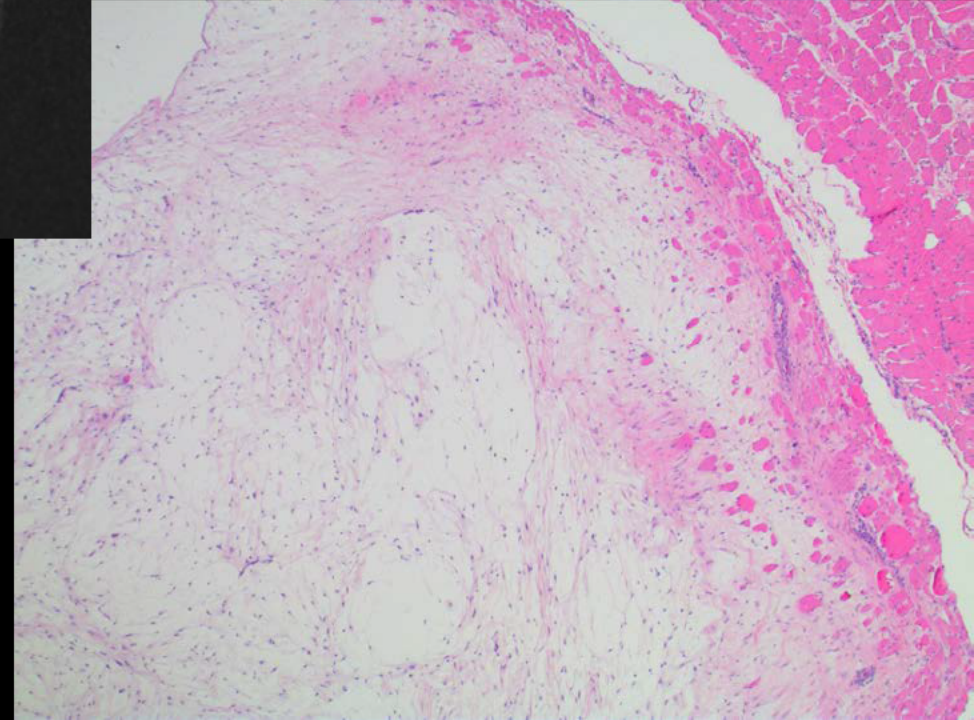
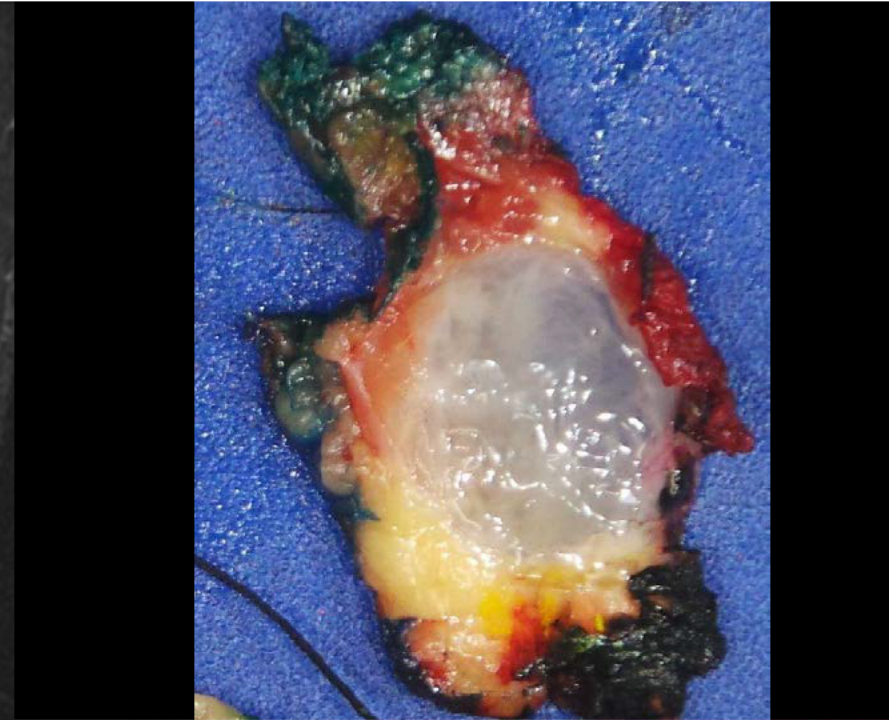
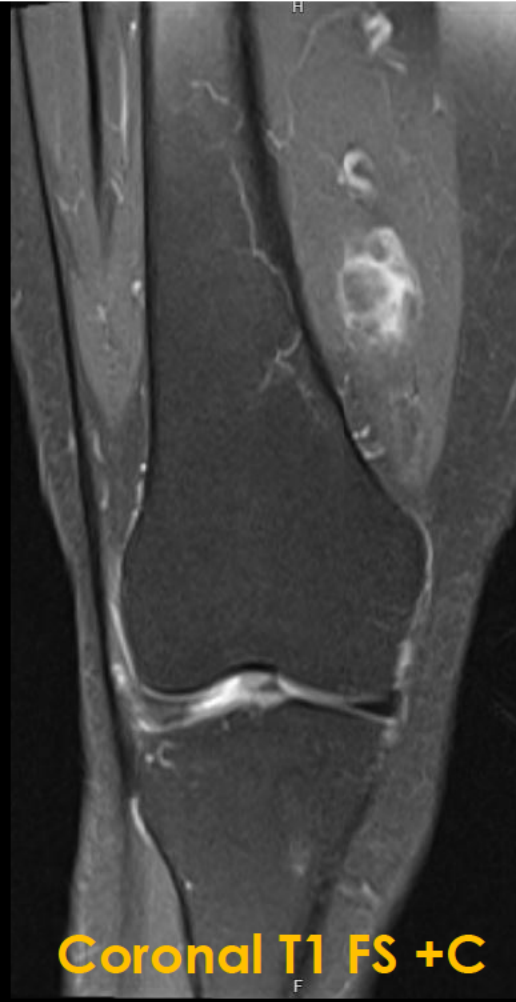
AMERICAN INSTITUTE FOR  
RADIOLOGIC PATHOLOGY

A PROGRAM OF THE  
AMERICAN COLLEGE OF RADIOLOGY









**AIRP**<sup>TM</sup>

AMERICAN INSTITUTE FOR  
RADIOLOGIC PATHOLOGY

A PROGRAM OF THE  
AMERICAN COLLEGE OF RADIOLOGY

# MYXOMA

**Dr. Ashley Hu**  
**UCLA Diagnostic**  
**Radiology Residency**  
**Santa Monica, CA**

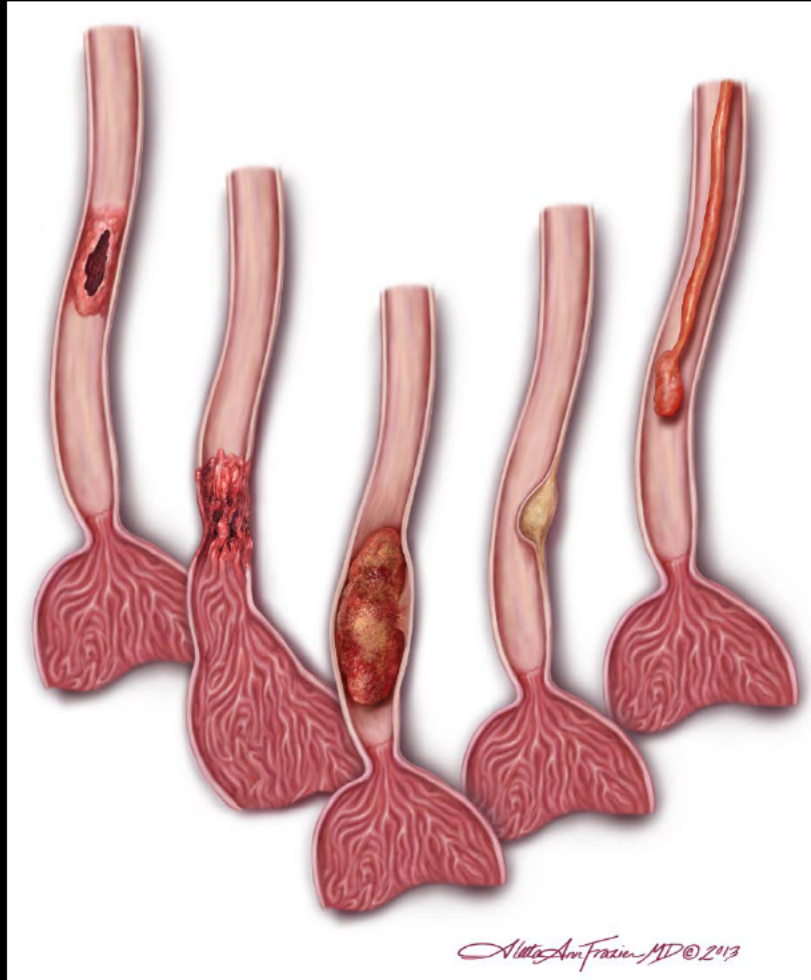
**Dr. Arshan Dehbozorgi**  
**University of Kansas**  
**Medical Center**  
**Kansas City, KS**

**AIRP**<sup>TM</sup>

**AMERICAN INSTITUTE FOR  
RADIOLOGIC PATHOLOGY**

**A PROGRAM OF THE  
AMERICAN COLLEGE OF RADIOLOGY**

# Gastrointestinal Best Case



**AIRP**<sup>TM</sup>

AMERICAN INSTITUTE FOR  
RADIOLOGIC PATHOLOGY

A PROGRAM OF THE  
AMERICAN COLLEGE OF RADIOLOGY

# Clinical information

**34-year-old African American woman with right sided abdominal pain and intermittent fevers.**

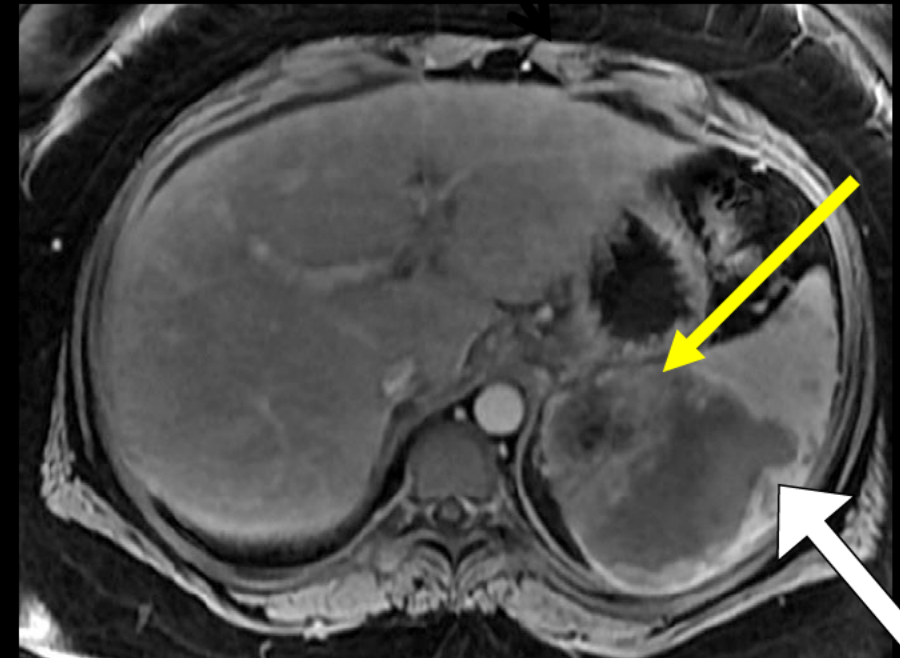
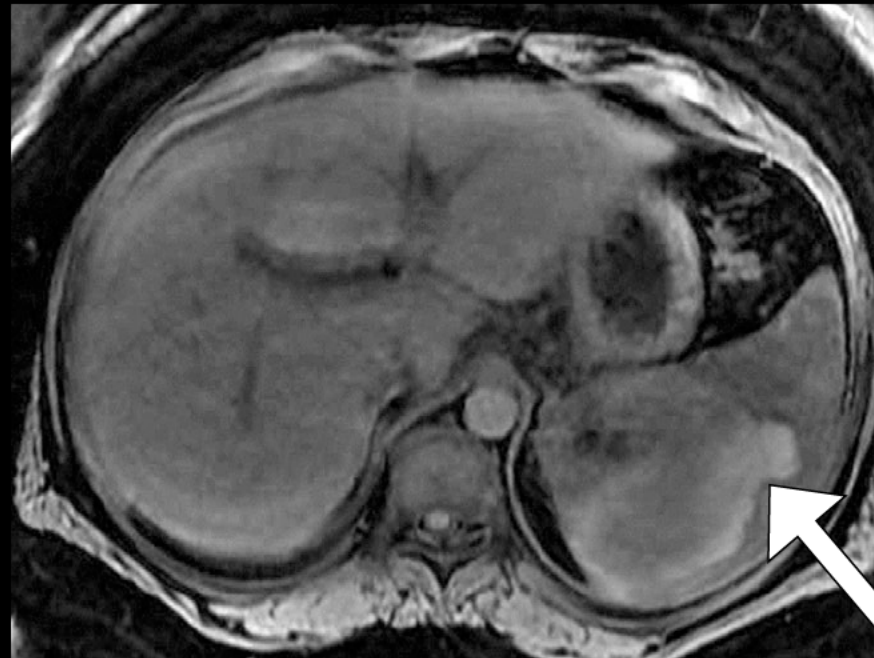
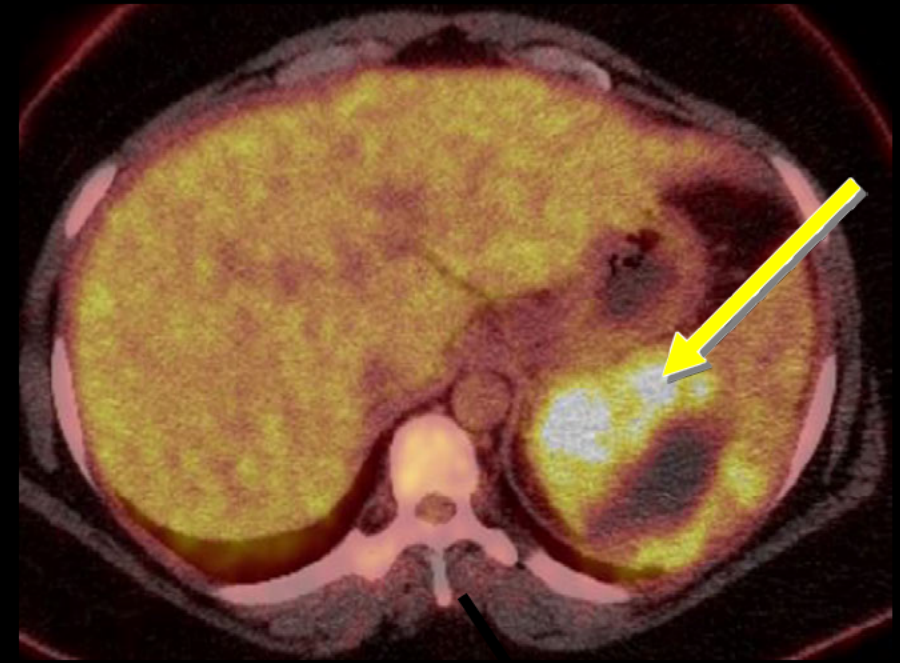
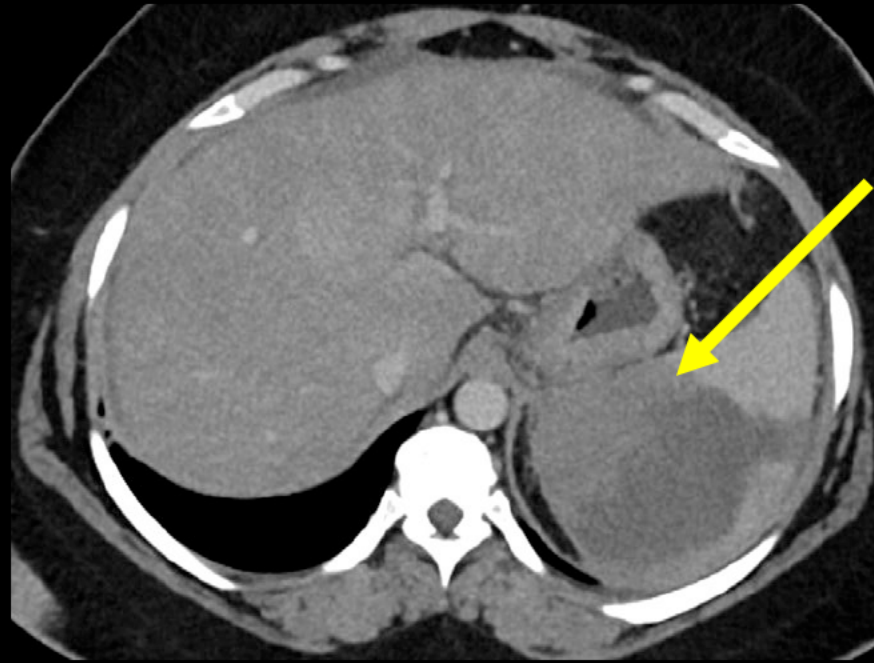


AMERICAN INSTITUTE FOR  
RADIOLOGIC PATHOLOGY

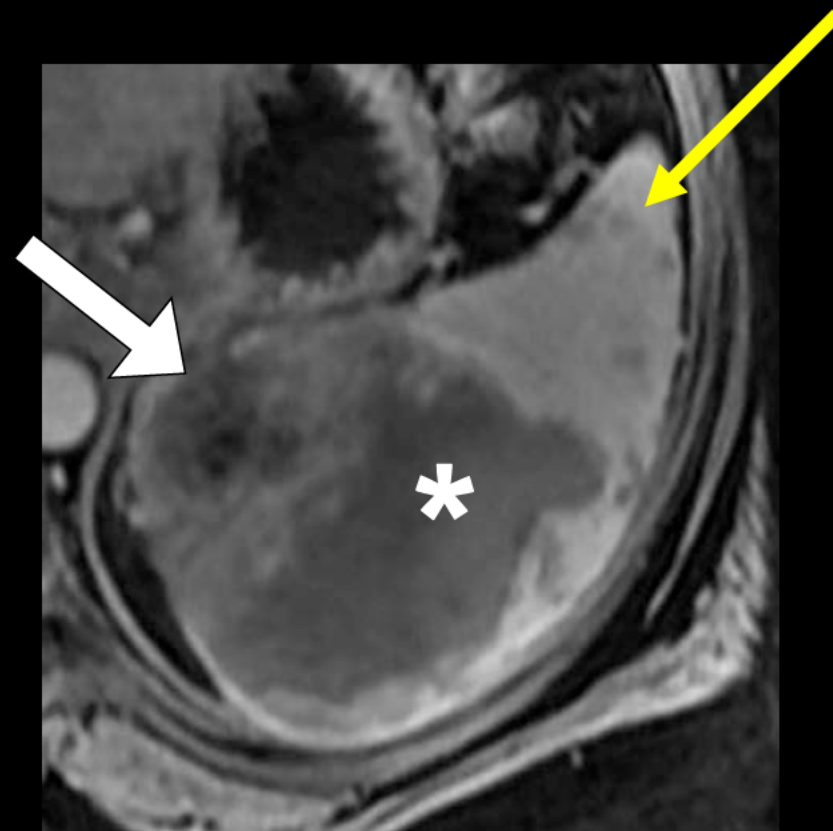
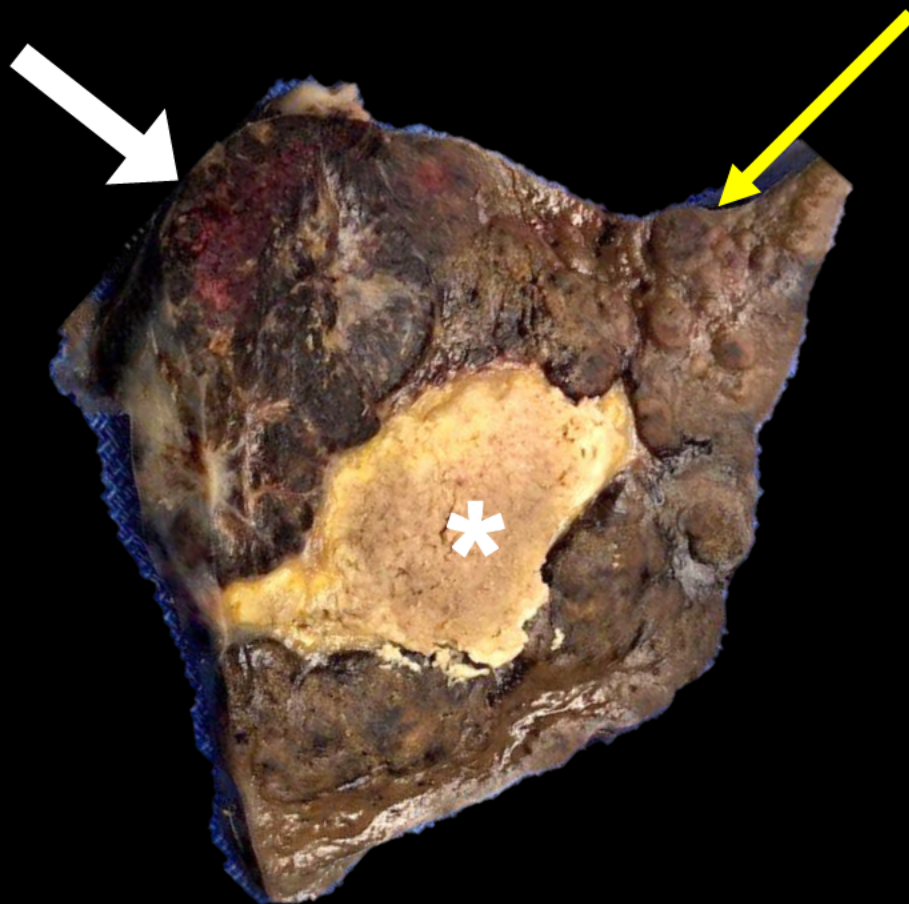
---

A PROGRAM OF THE  
AMERICAN COLLEGE OF RADIOLOGY





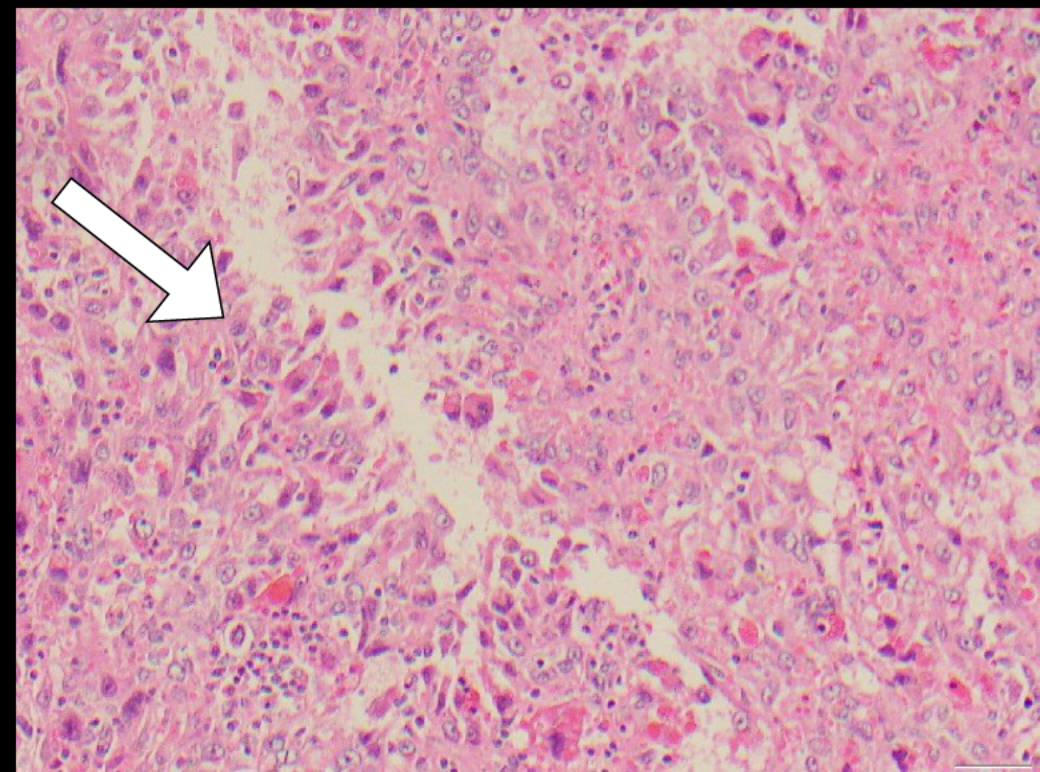
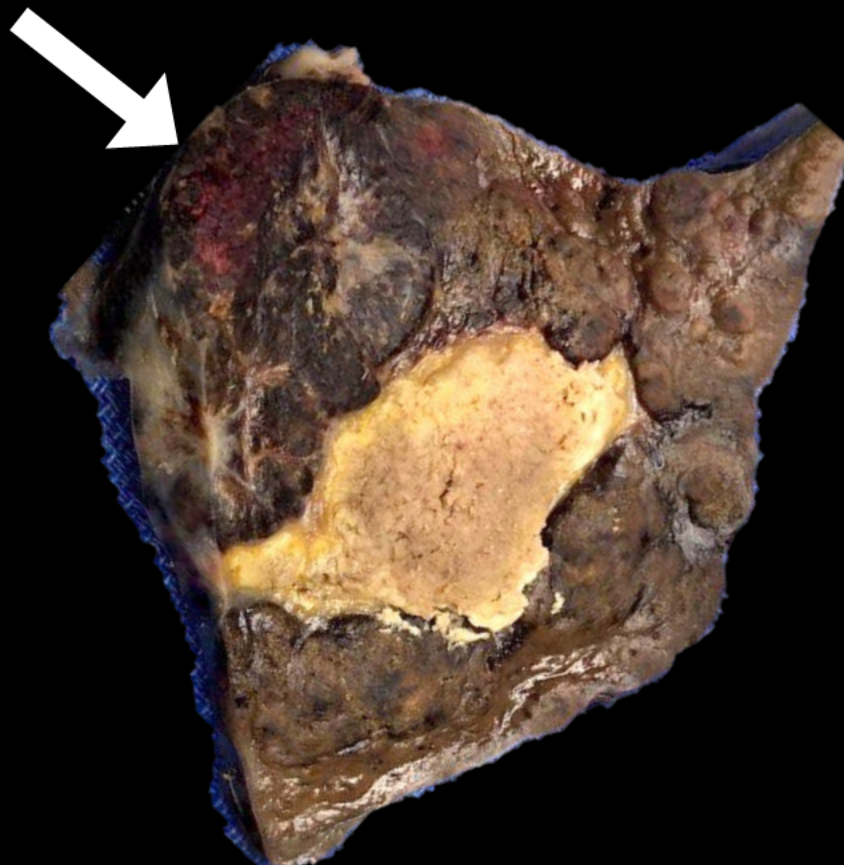




**AIRP**<sup>TM</sup>

AMERICAN INSTITUTE FOR  
RADIOLOGIC PATHOLOGY

A PROGRAM OF THE  
AMERICAN COLLEGE OF RADIOLOGY



**AIRP**<sup>TM</sup>

AMERICAN INSTITUTE FOR  
RADIOLOGIC PATHOLOGY

A PROGRAM OF THE  
AMERICAN COLLEGE OF RADIOLOGY

# Angiosarcoma of the Spleen

**Rebecca Simstein, MD**

**Bryn Mawr Hospital**

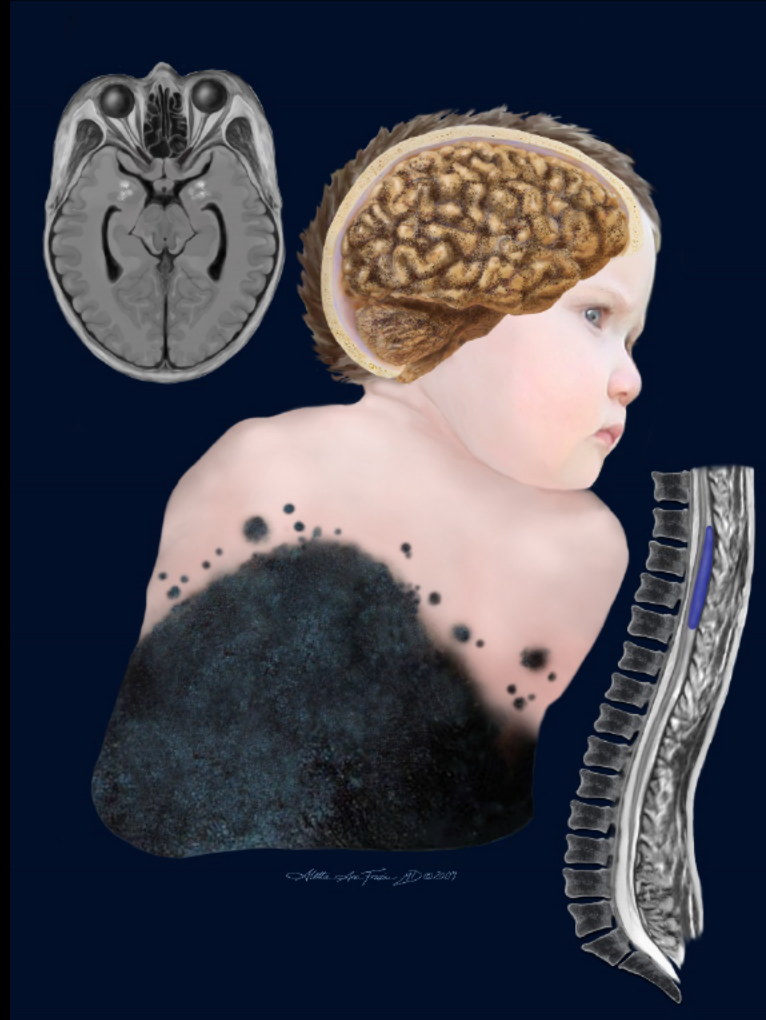**Bryn Mawr, PA**



**AMERICAN INSTITUTE FOR  
RADIOLOGIC PATHOLOGY**

**A PROGRAM OF THE  
AMERICAN COLLEGE OF RADIOLOGY**

# Neuroradiology Best Case



**AIRP**<sup>TM</sup>

AMERICAN INSTITUTE FOR  
RADIOLOGIC PATHOLOGY

A PROGRAM OF THE  
AMERICAN COLLEGE OF RADIOLOGY



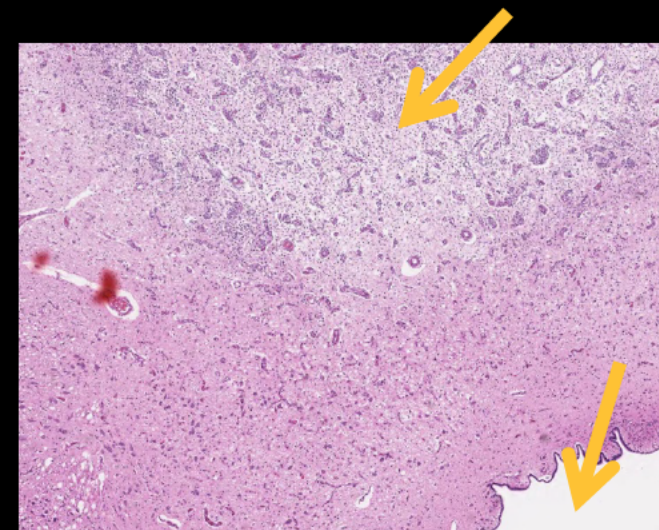
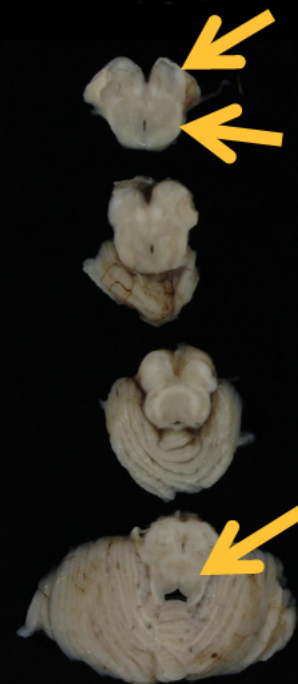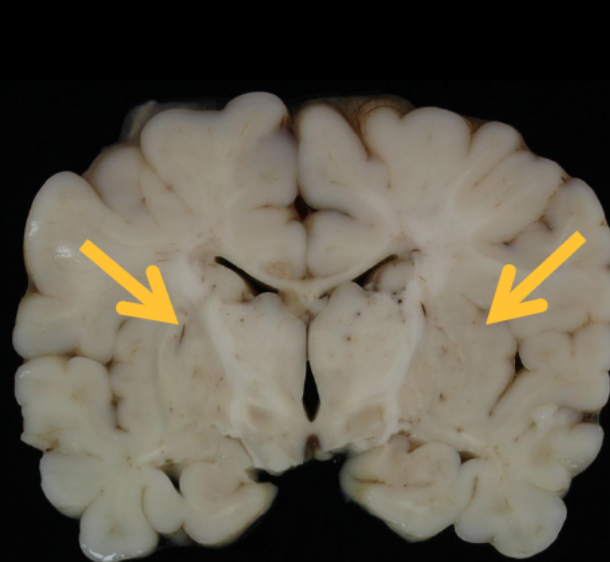
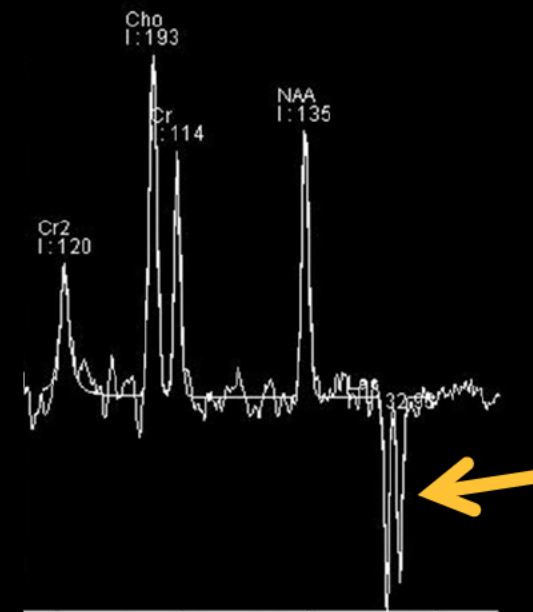
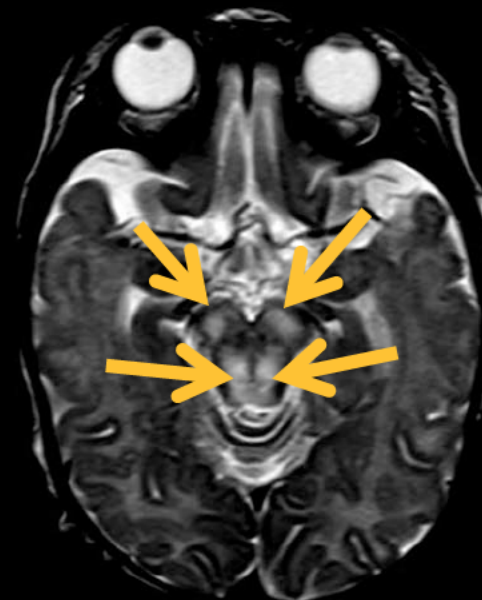
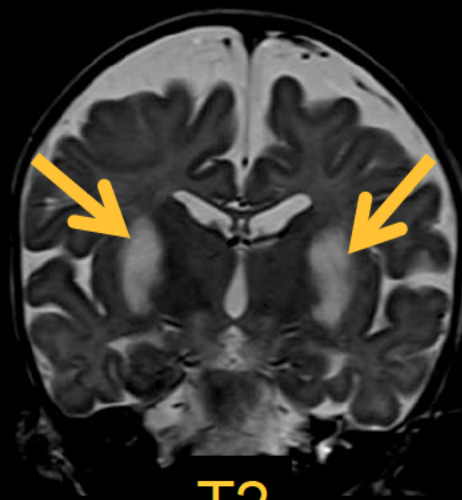
# Clinical Information

**14-week-old female with onset of episodic apnea and staring episodes, progressing to limpness and complete apnea. Elevated serum lactate with blood pH 7.33**



AMERICAN INSTITUTE FOR  
RADIOLOGIC PATHOLOGY

A PROGRAM OF THE  
AMERICAN COLLEGE OF RADIOLOGY



**AIRP**<sup>TM</sup>

AMERICAN INSTITUTE FOR  
RADIOLOGIC PATHOLOGY

A PROGRAM OF THE  
AMERICAN COLLEGE OF RADIOLOGY

# Leigh Disease

**Rhith Bhargavan, M.D.**

**University of British Columbia**

**Vancouver, British Columbia, Canada**

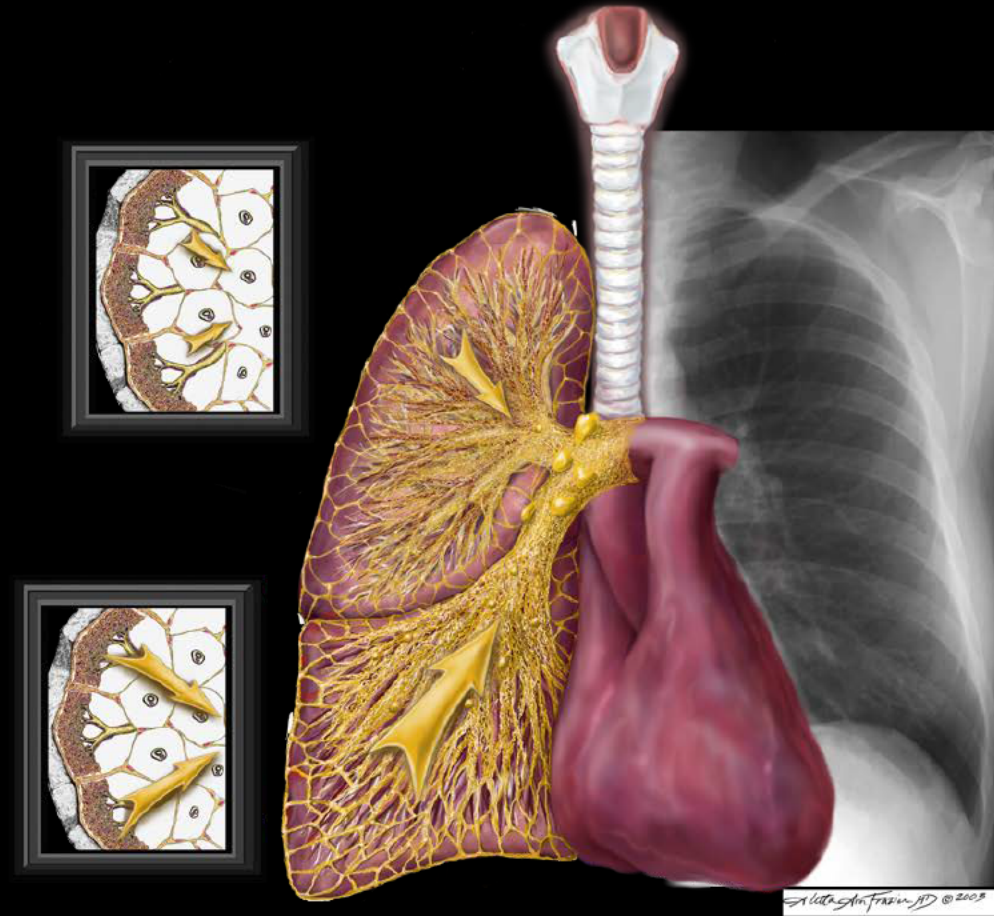
**AIRP**<sup>TM</sup>

AMERICAN INSTITUTE FOR  
RADIOLOGIC PATHOLOGY

A PROGRAM OF THE  
AMERICAN COLLEGE OF RADIOLOGY



# Thoracic Best Case



**AIRP**™

AMERICAN INSTITUTE FOR  
RADIOLOGIC PATHOLOGY

A PROGRAM OF THE  
AMERICAN COLLEGE OF RADIOLOGY

# Clinical information

**78-year-old male with incidental CXR abnormality during workup for gastrointestinal symptoms. Previous smoker (40 pack years, quit 20 years ago).**

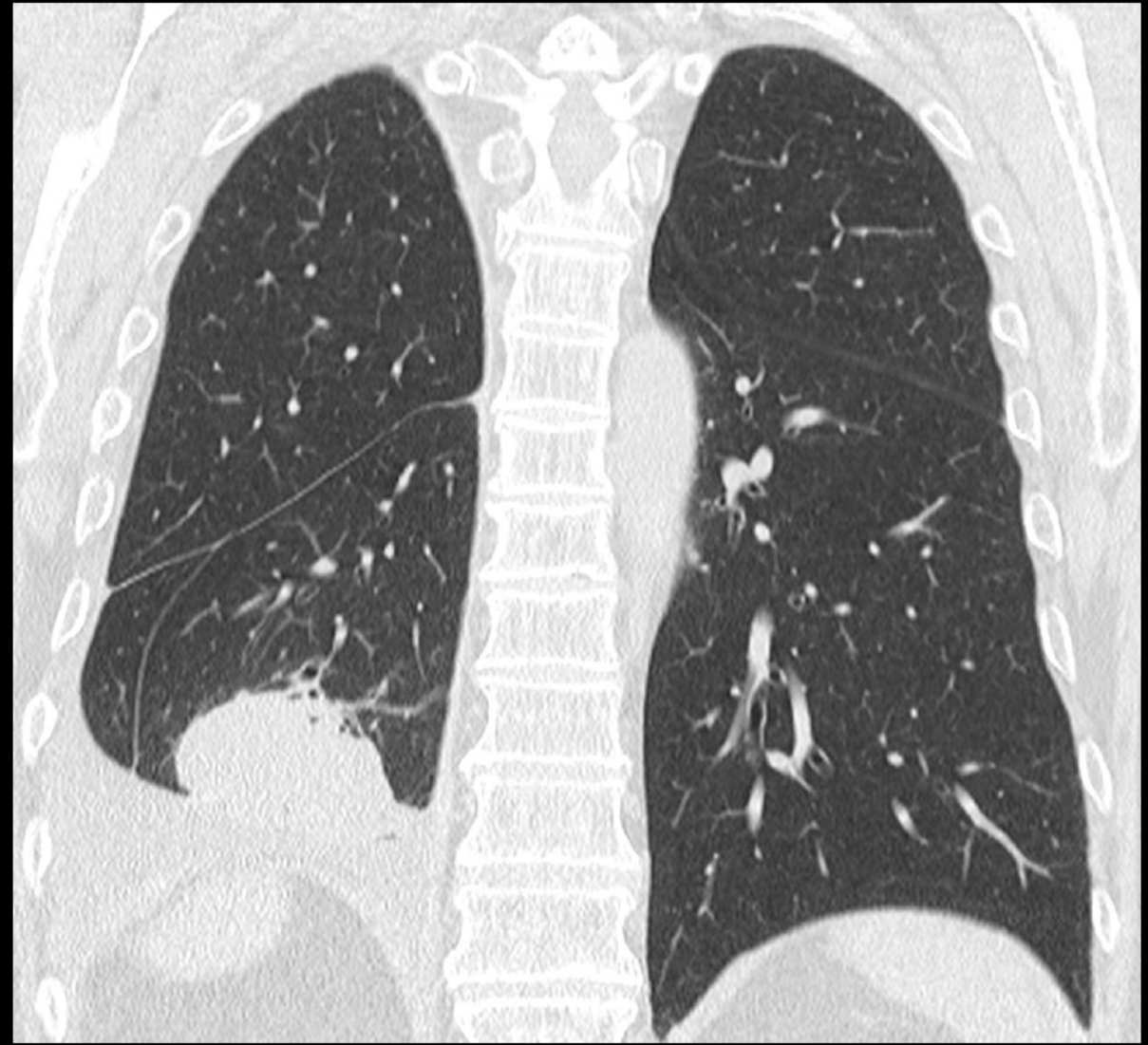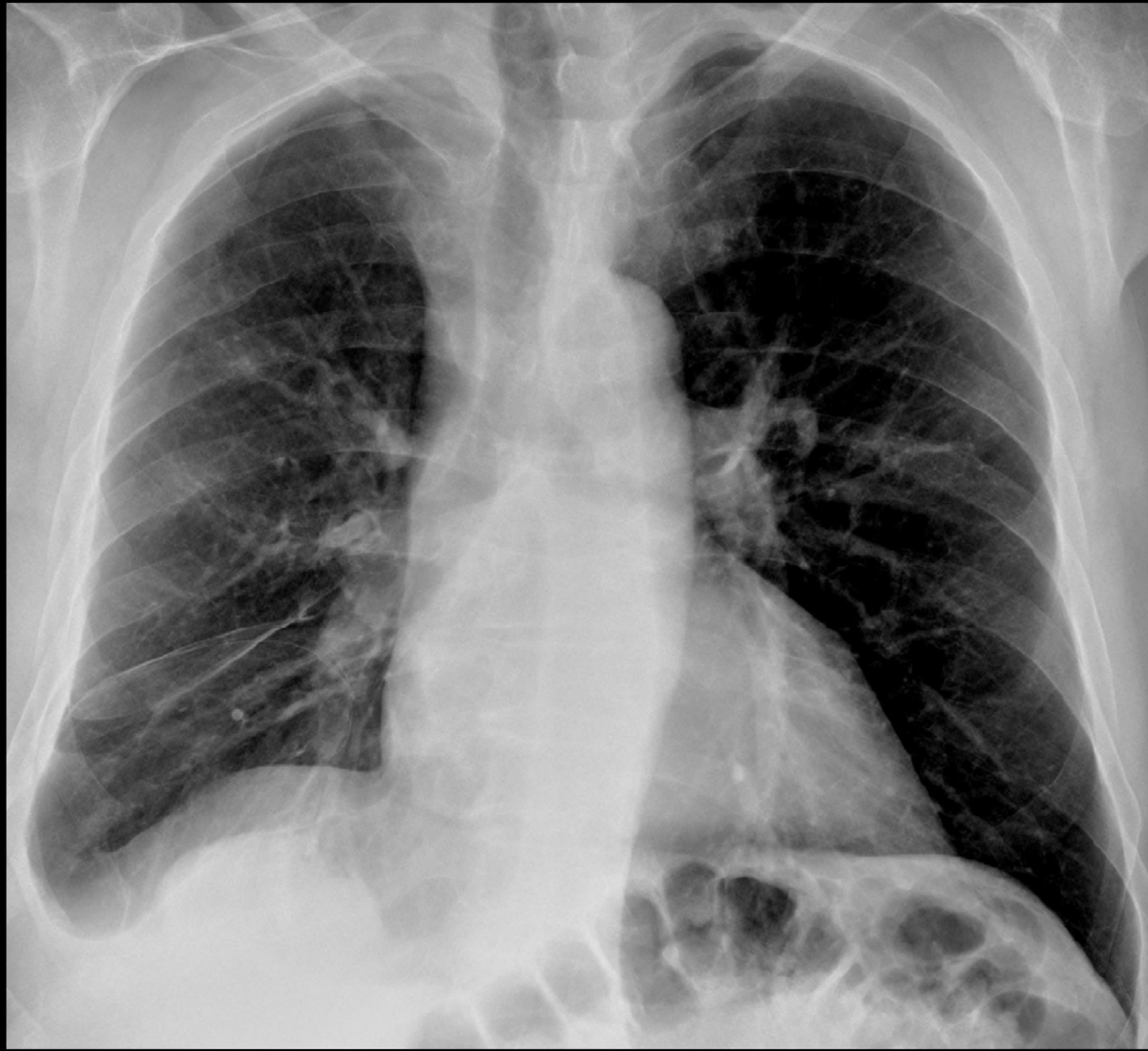


AMERICAN INSTITUTE FOR  
RADIOLOGIC PATHOLOGY

---

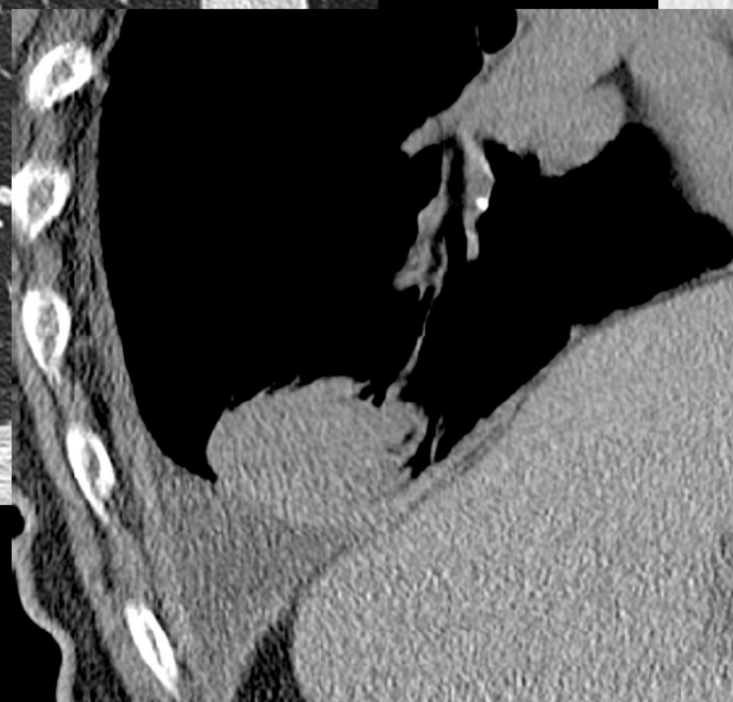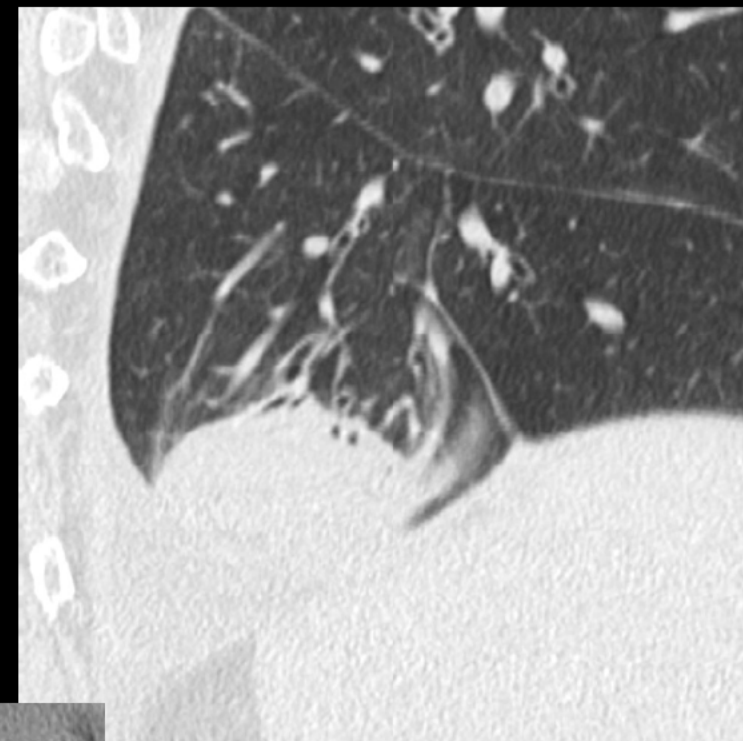
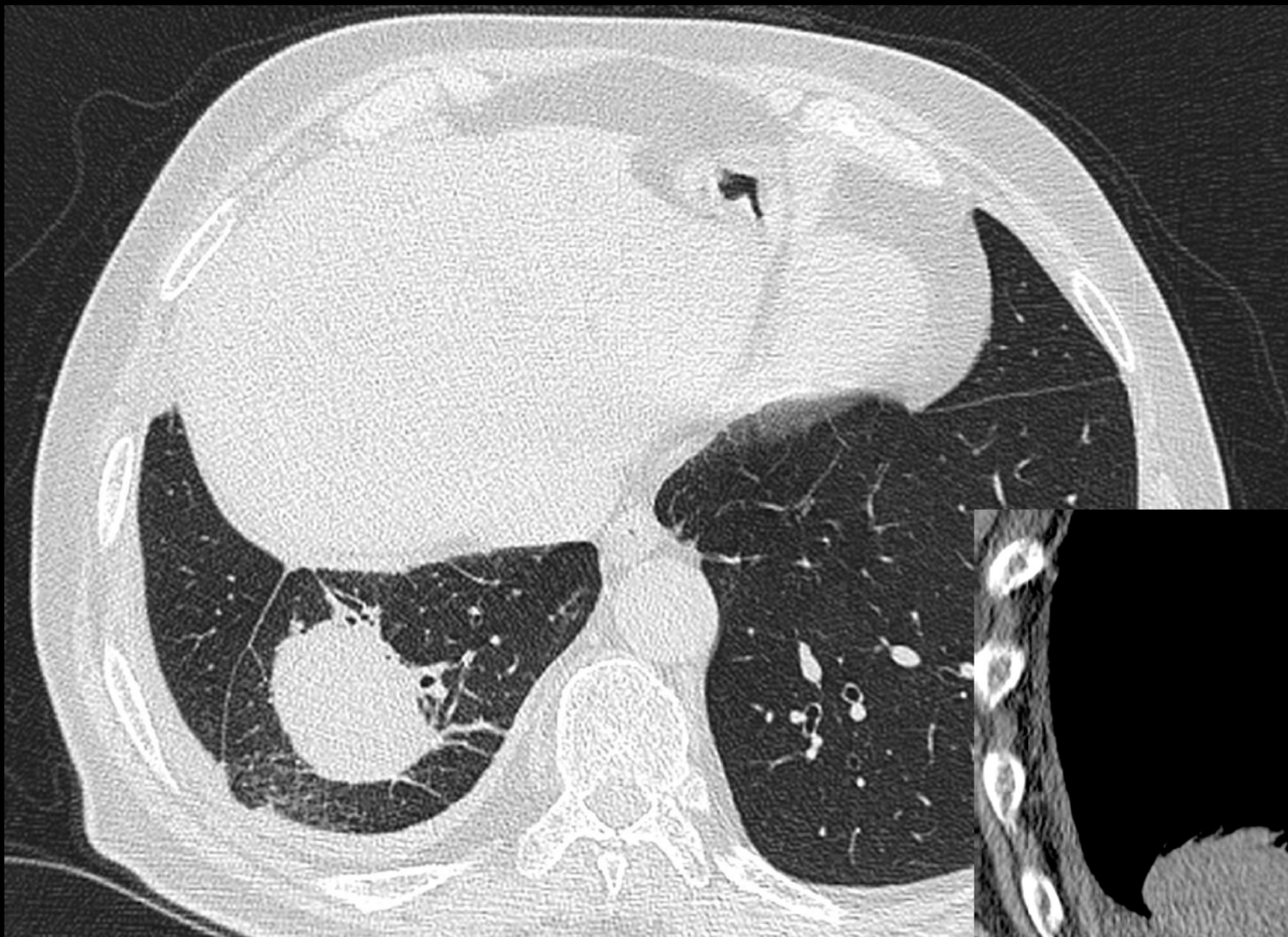
A PROGRAM OF THE  
AMERICAN COLLEGE OF RADIOLOGY





**AMERICAN INSTITUTE FOR  
RADIOLOGIC PATHOLOGY**

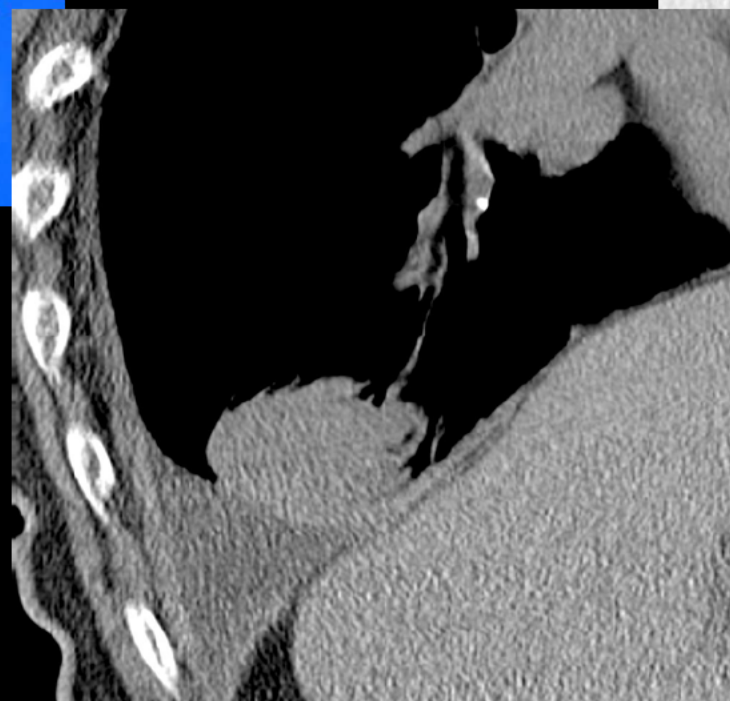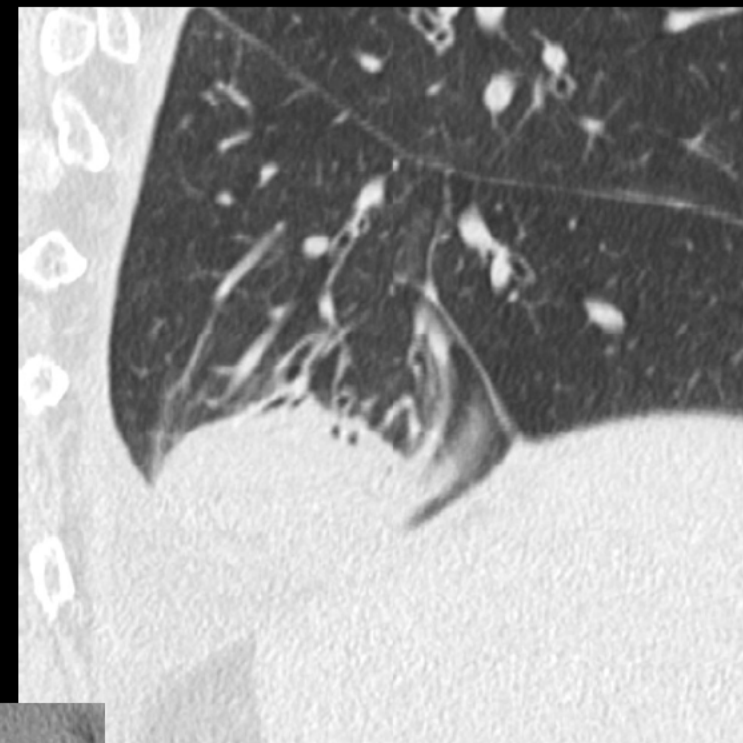
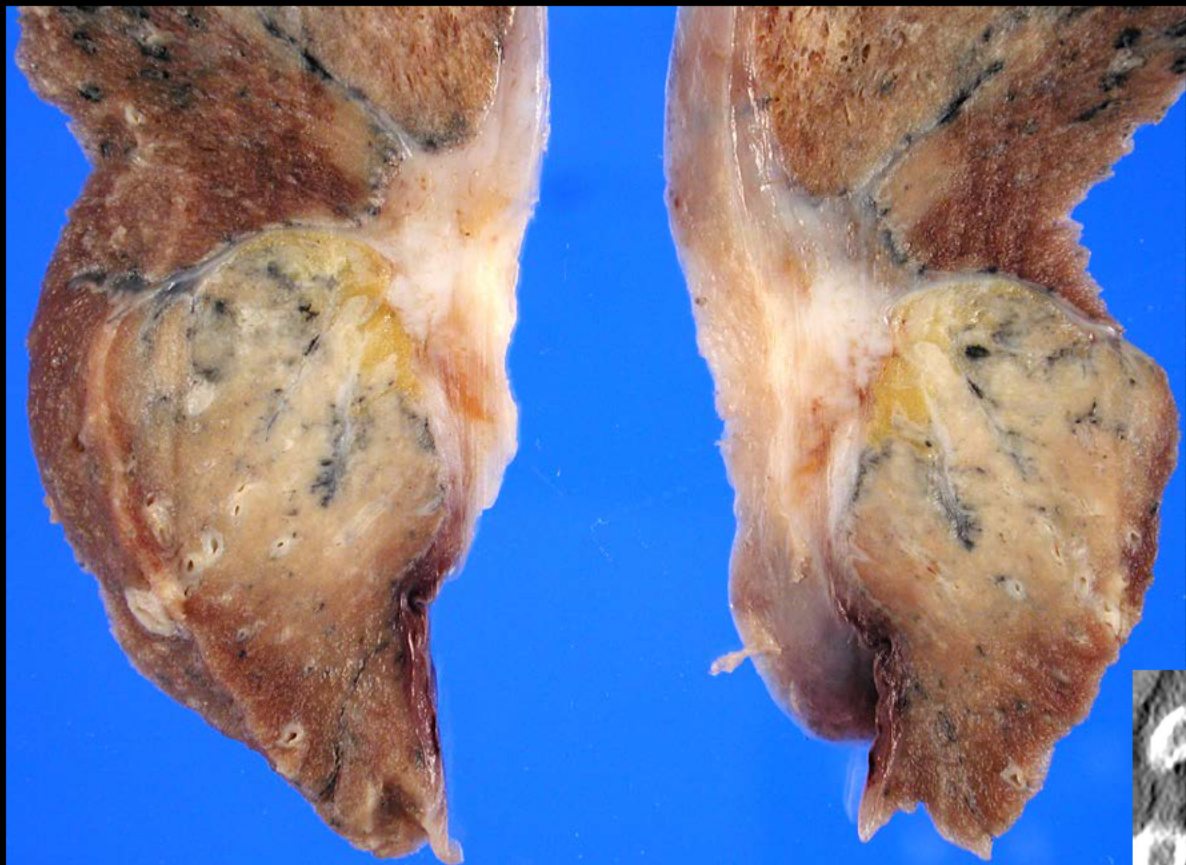A PROGRAM OF THE  
AMERICAN COLLEGE OF RADIOLOGY



**AMERICAN INSTITUTE FOR  
RADIOLOGIC PATHOLOGY**

A PROGRAM OF THE  
AMERICAN COLLEGE OF RADIOLOGY



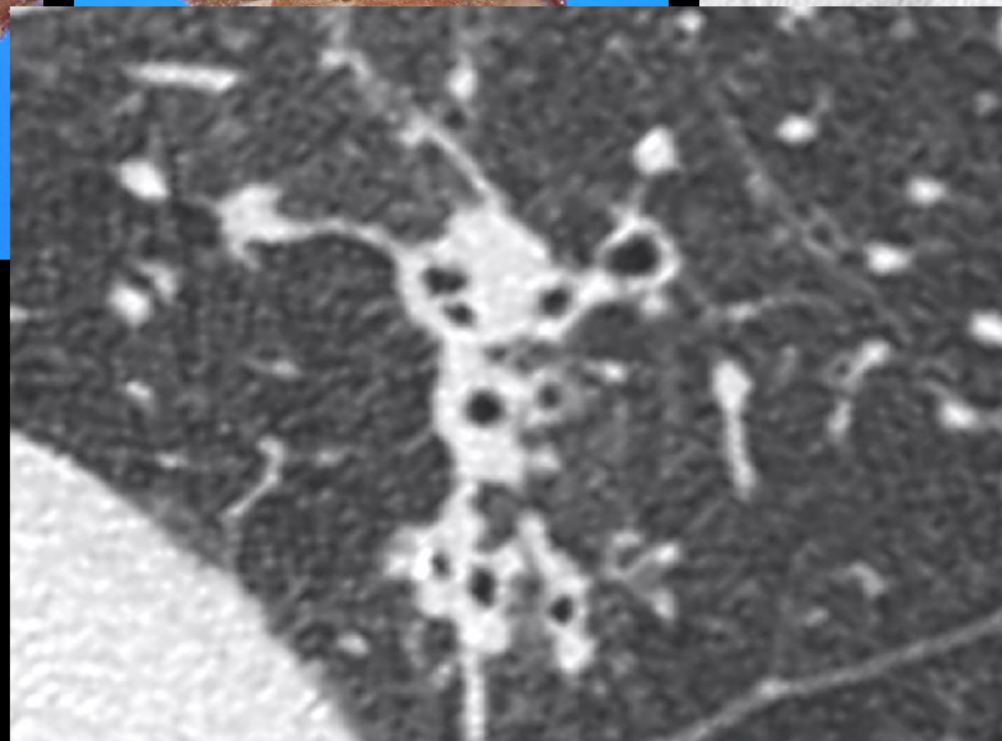
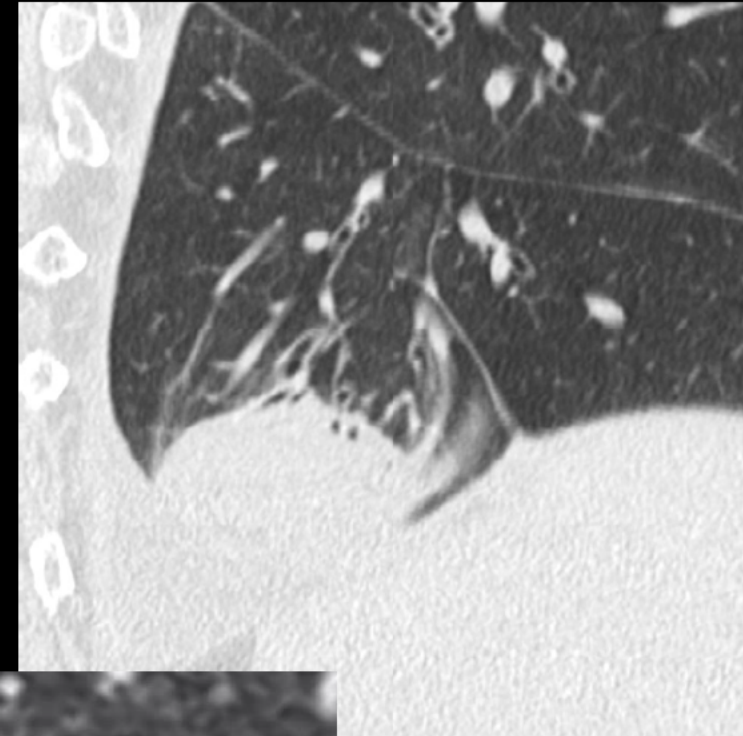
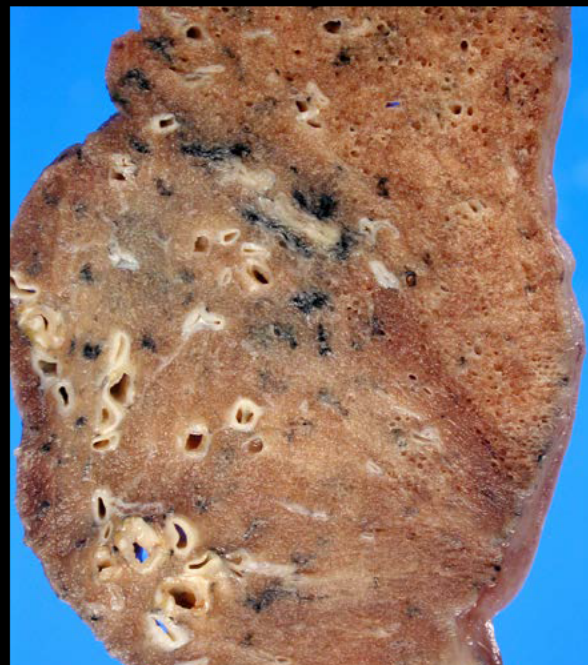
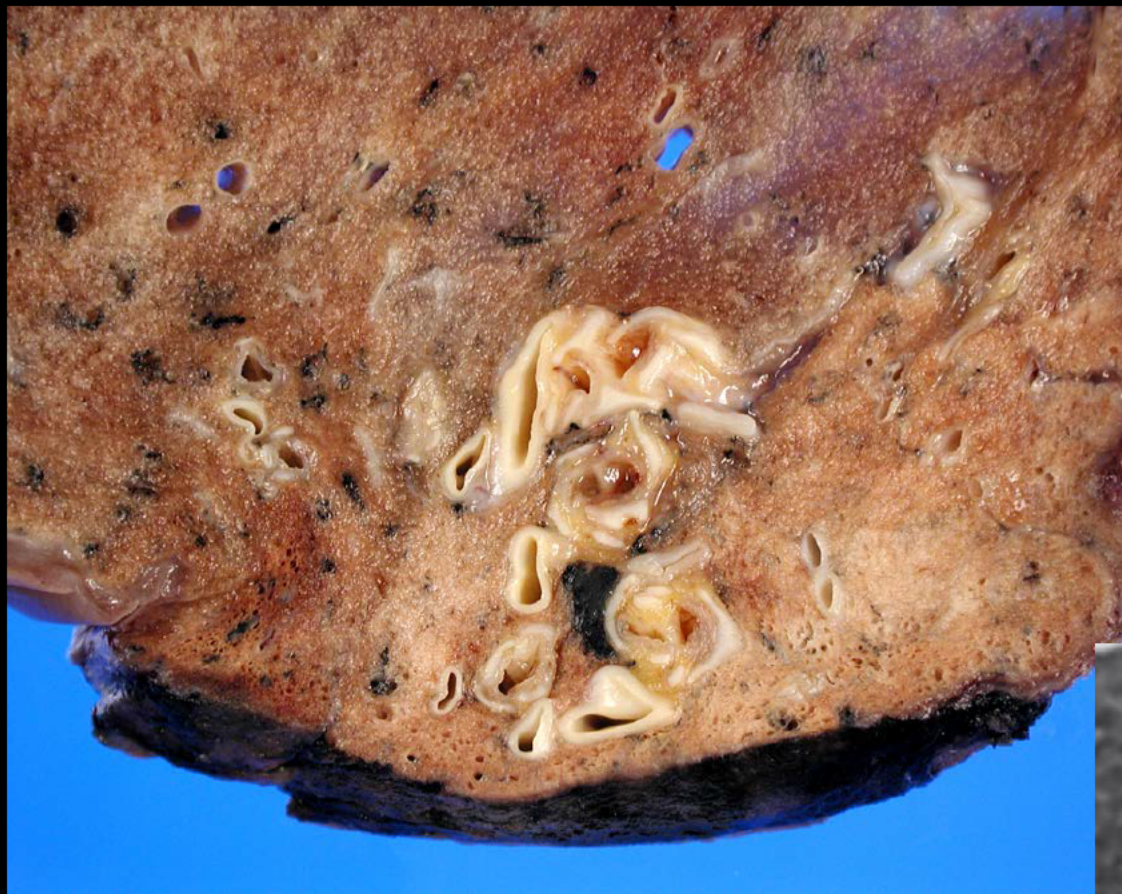
**AIRP**<sup>TM</sup>

AMERICAN INSTITUTE FOR  
RADIOLOGIC PATHOLOGY

A PROGRAM OF THE  
AMERICAN COLLEGE OF RADIOLOGY



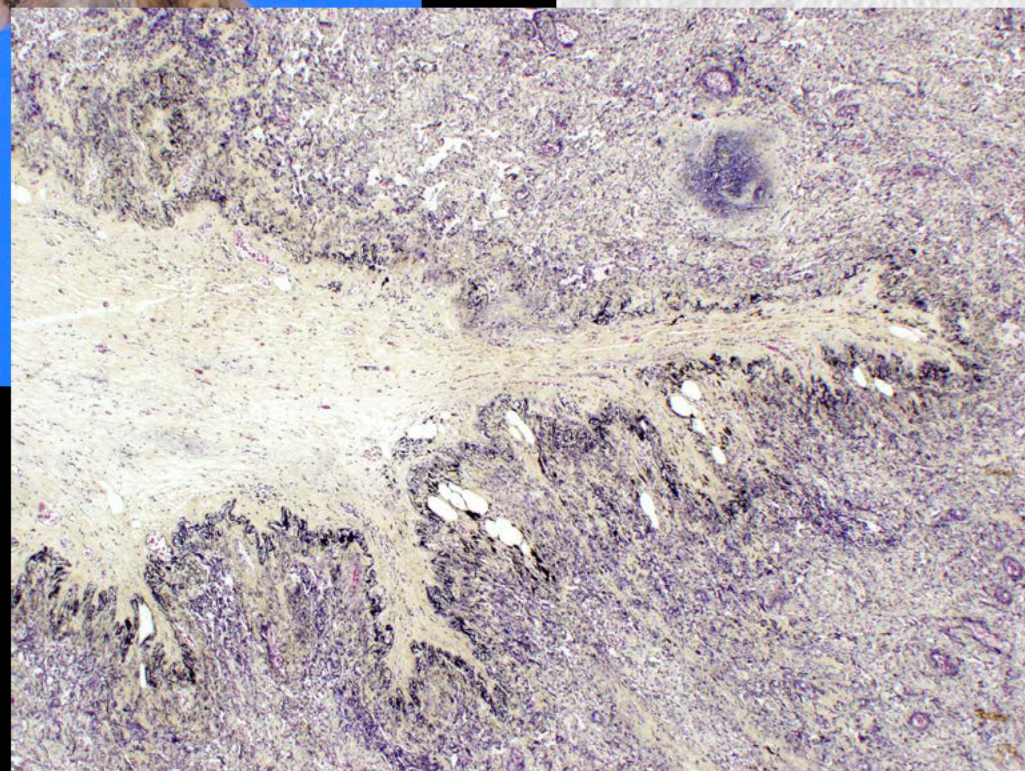
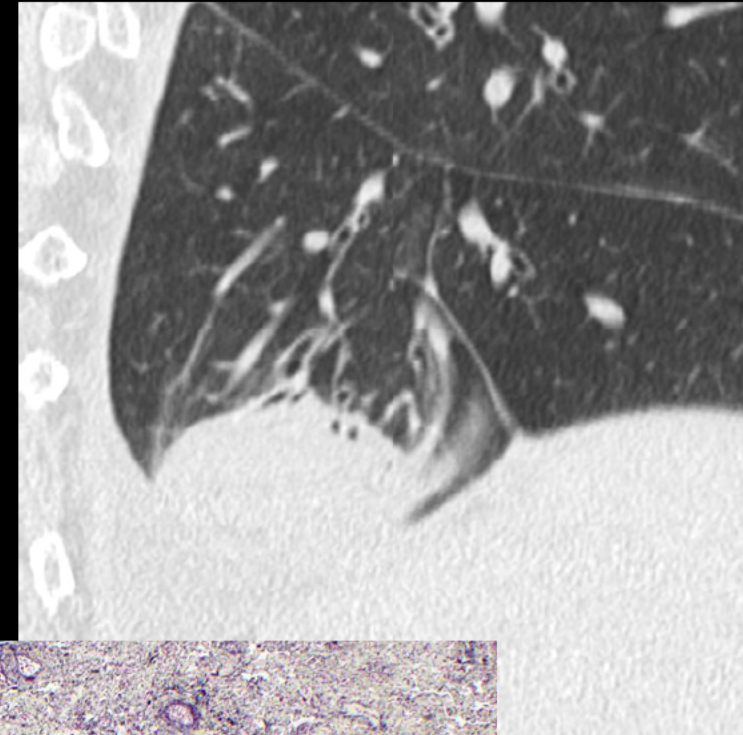
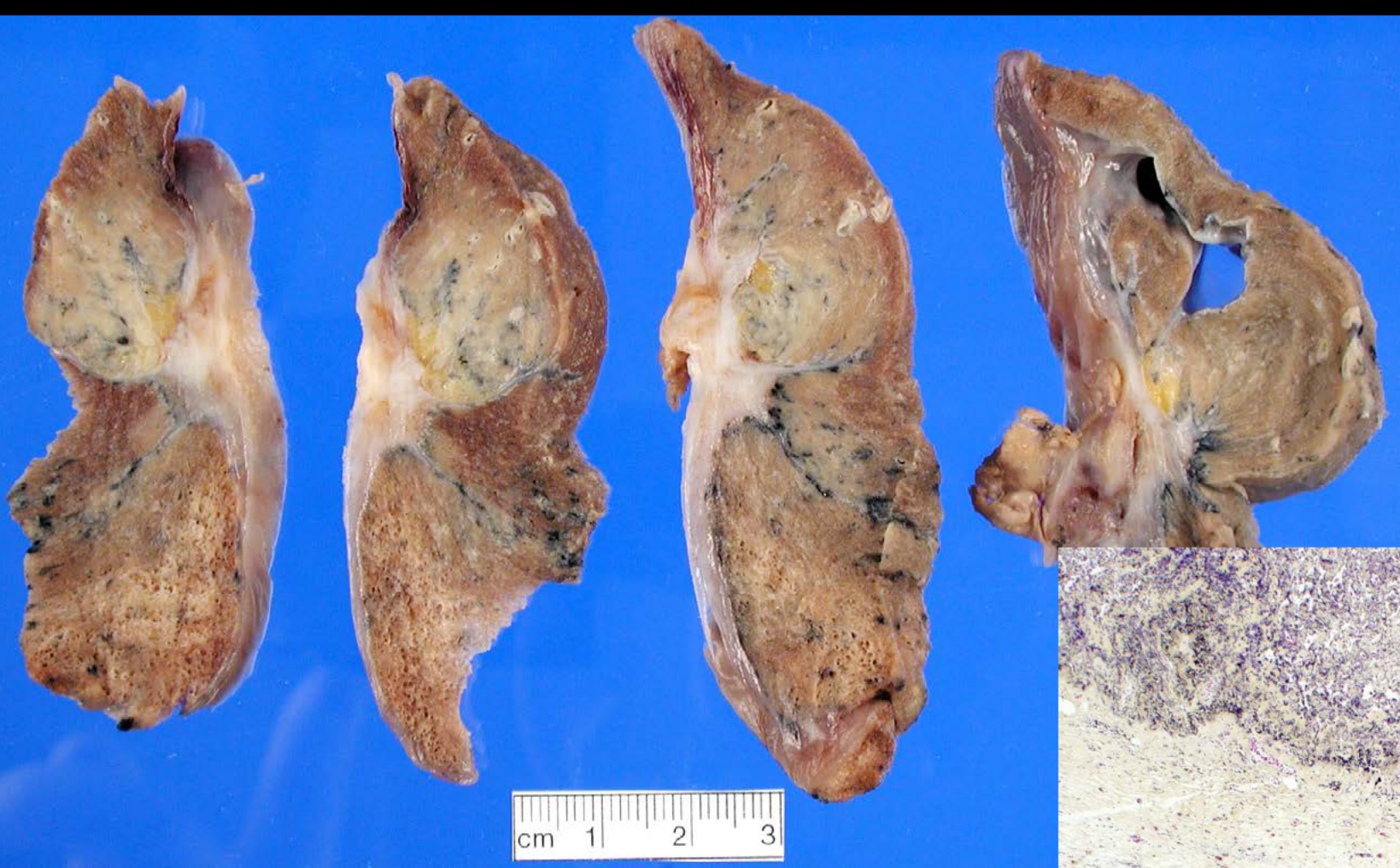

**AIRP**<sup>TM</sup>

AMERICAN INSTITUTE FOR  
RADIOLOGIC PATHOLOGY

A PROGRAM OF THE  
AMERICAN COLLEGE OF RADIOLOGY



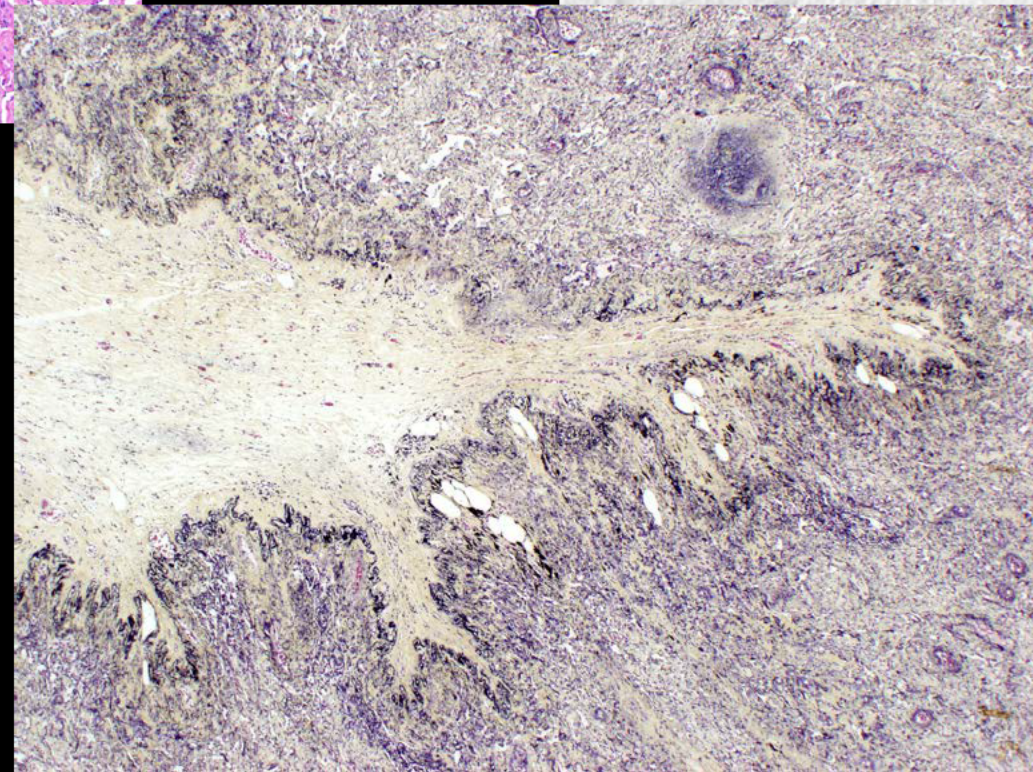
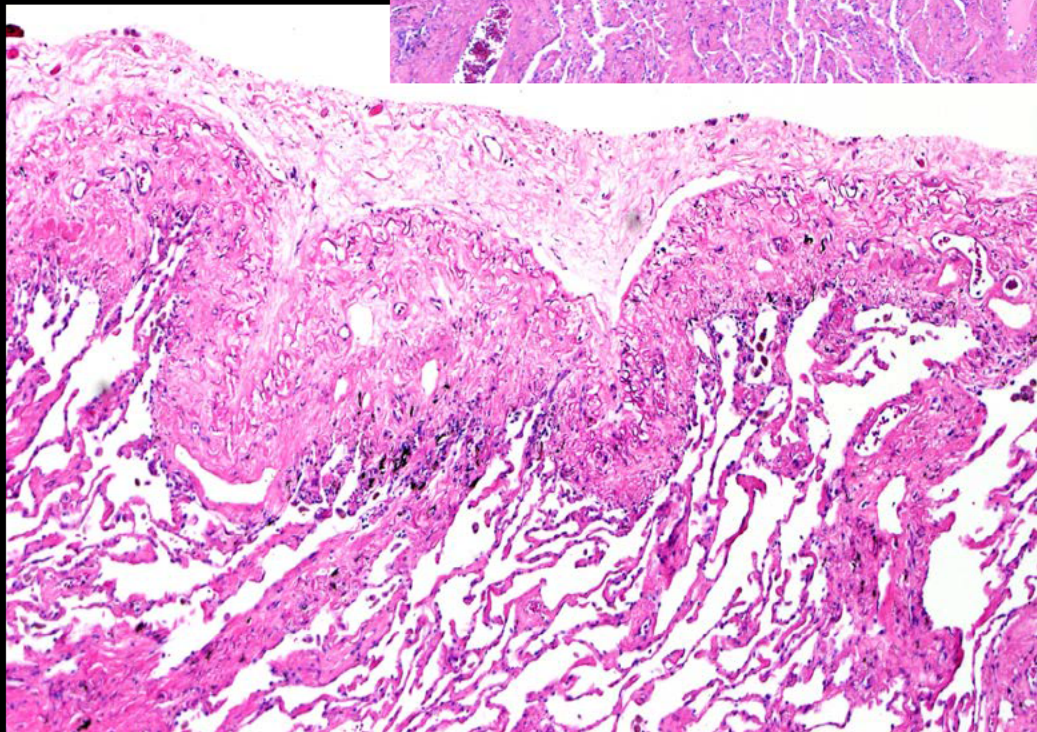
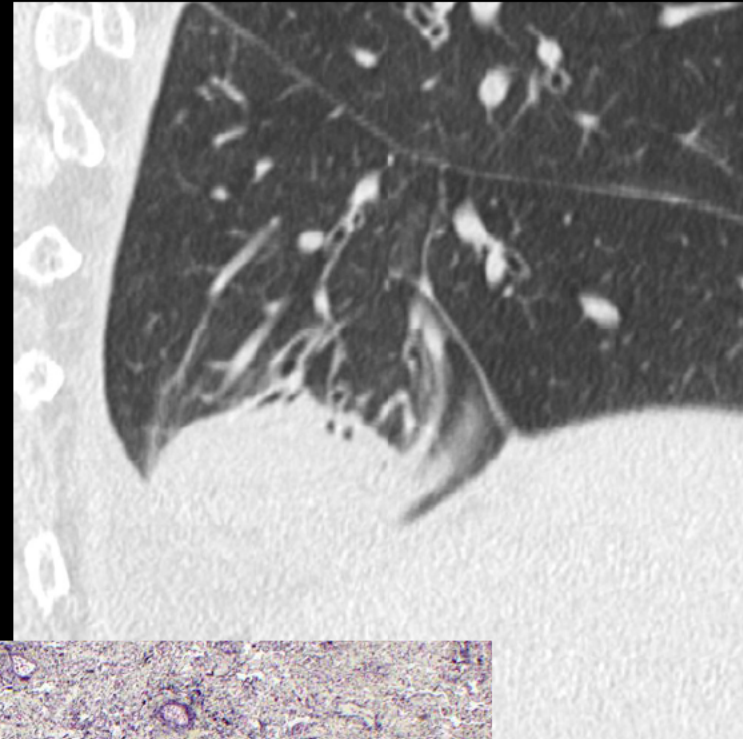
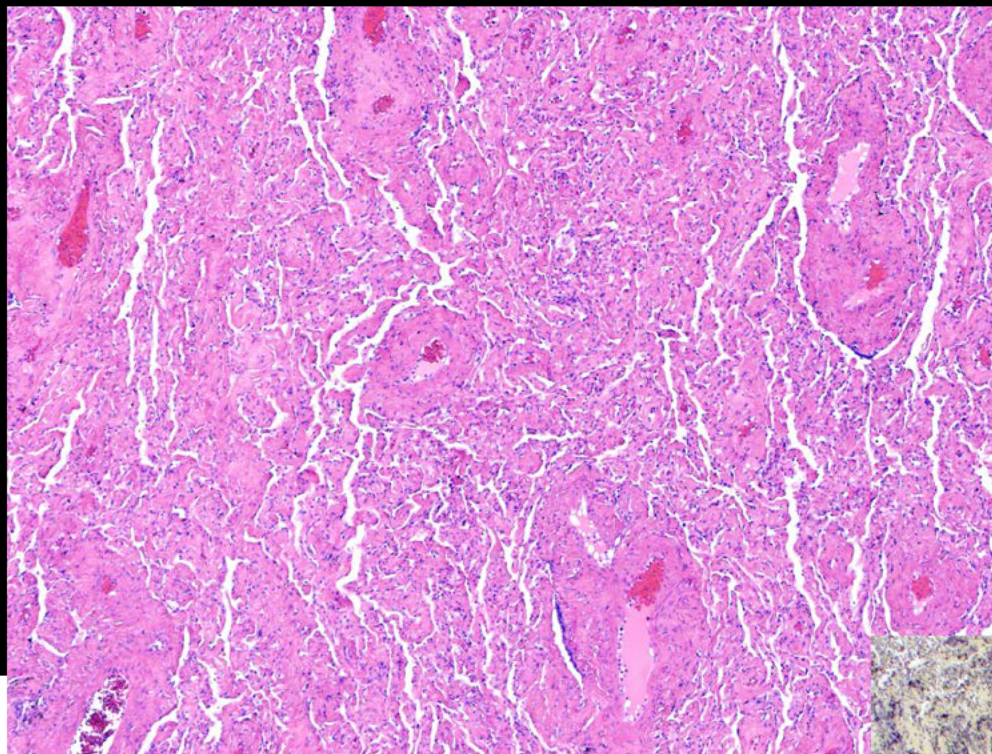


**AIRP**<sup>TM</sup>

AMERICAN INSTITUTE FOR  
RADIOLOGIC PATHOLOGY

A PROGRAM OF THE  
AMERICAN COLLEGE OF RADIOLOGY







# **Rounded Atelectasis Right Lower Lobe**

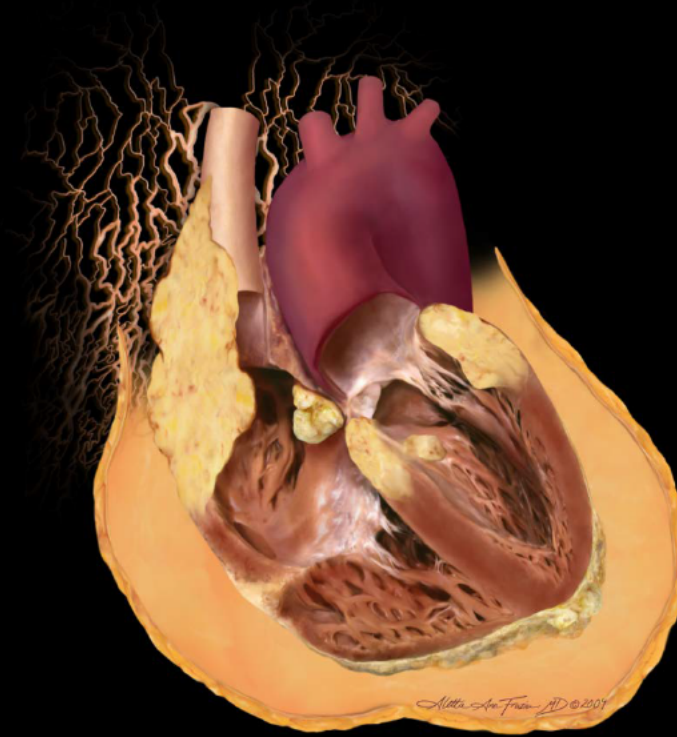
**James Roberts, MD  
Vancouver General Hospital  
Vancouver, Canada**



**AMERICAN INSTITUTE FOR  
RADIOLOGIC PATHOLOGY**

**A PROGRAM OF THE  
AMERICAN COLLEGE OF RADIOLOGY**

# Cardiovascular Best Case



**AIRP**<sup>TM</sup>

AMERICAN INSTITUTE FOR  
RADIOLOGIC PATHOLOGY

A PROGRAM OF THE  
AMERICAN COLLEGE OF RADIOLOGY



# Clinical information

**25-year-old woman worsening shortness of breath on exertion, palpitations, anxiety and fatigue.**

**AIRP**<sup>TM</sup>

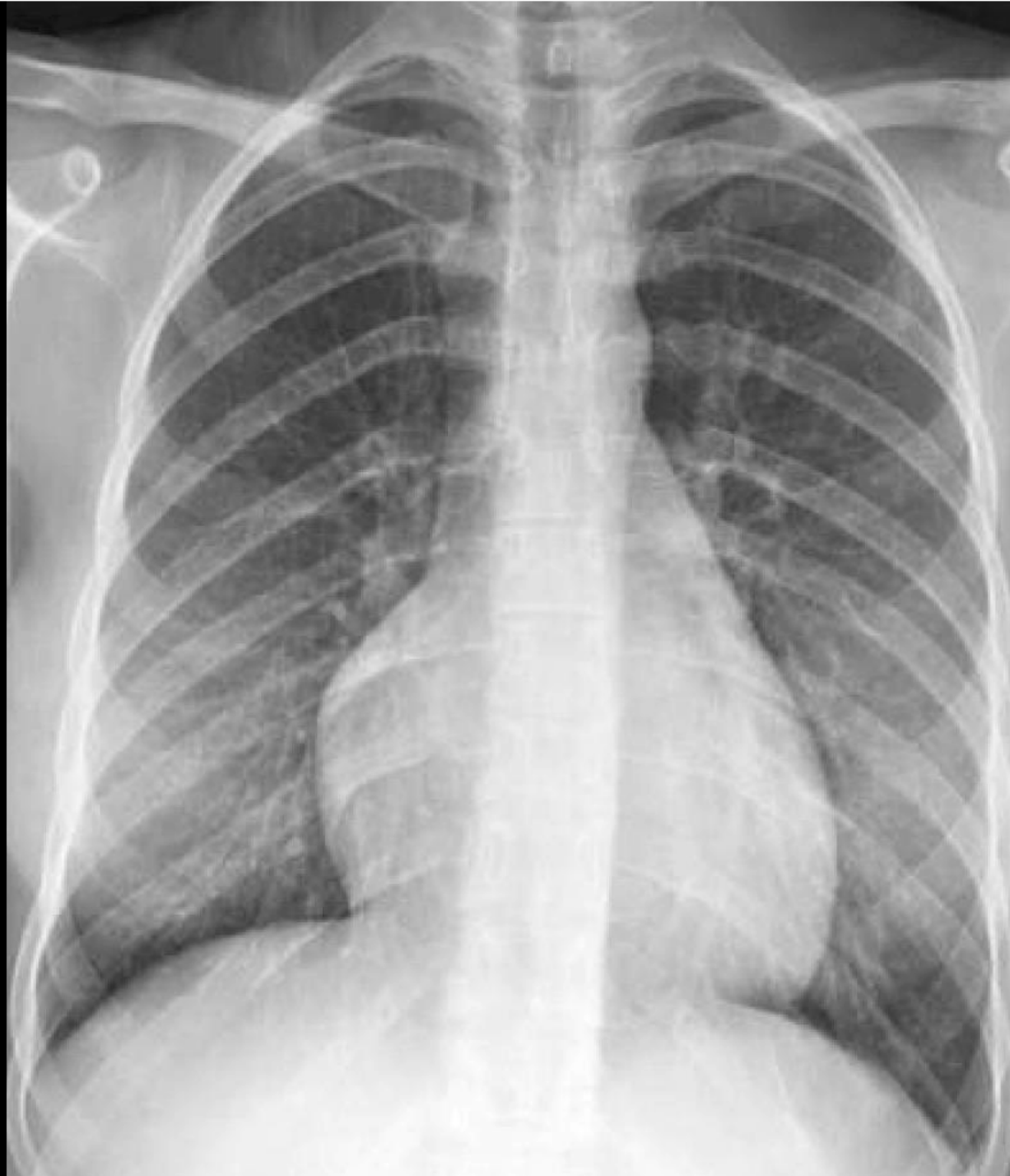AMERICAN INSTITUTE FOR  
RADIOLOGIC PATHOLOGY

A PROGRAM OF THE  
AMERICAN COLLEGE OF RADIOLOGY

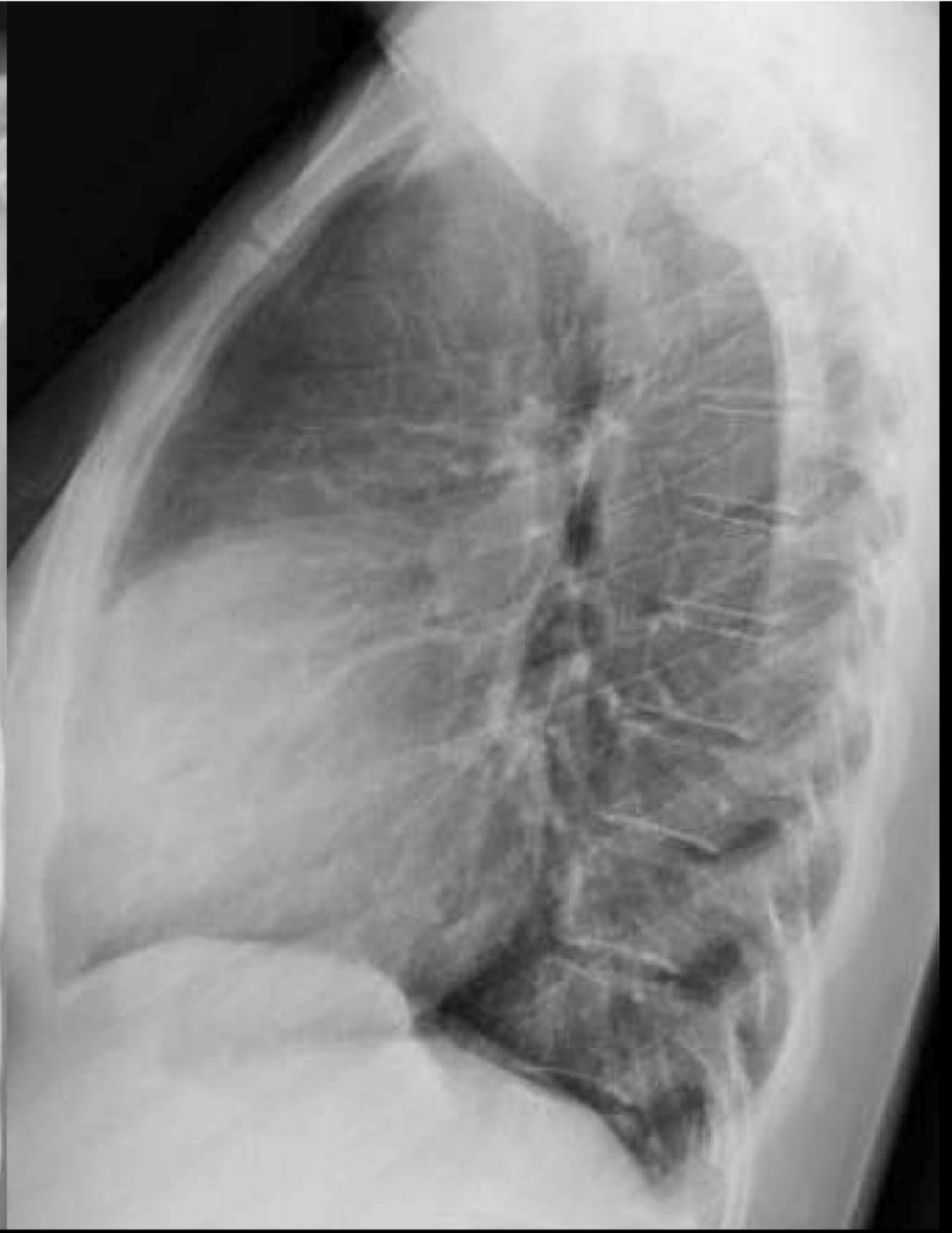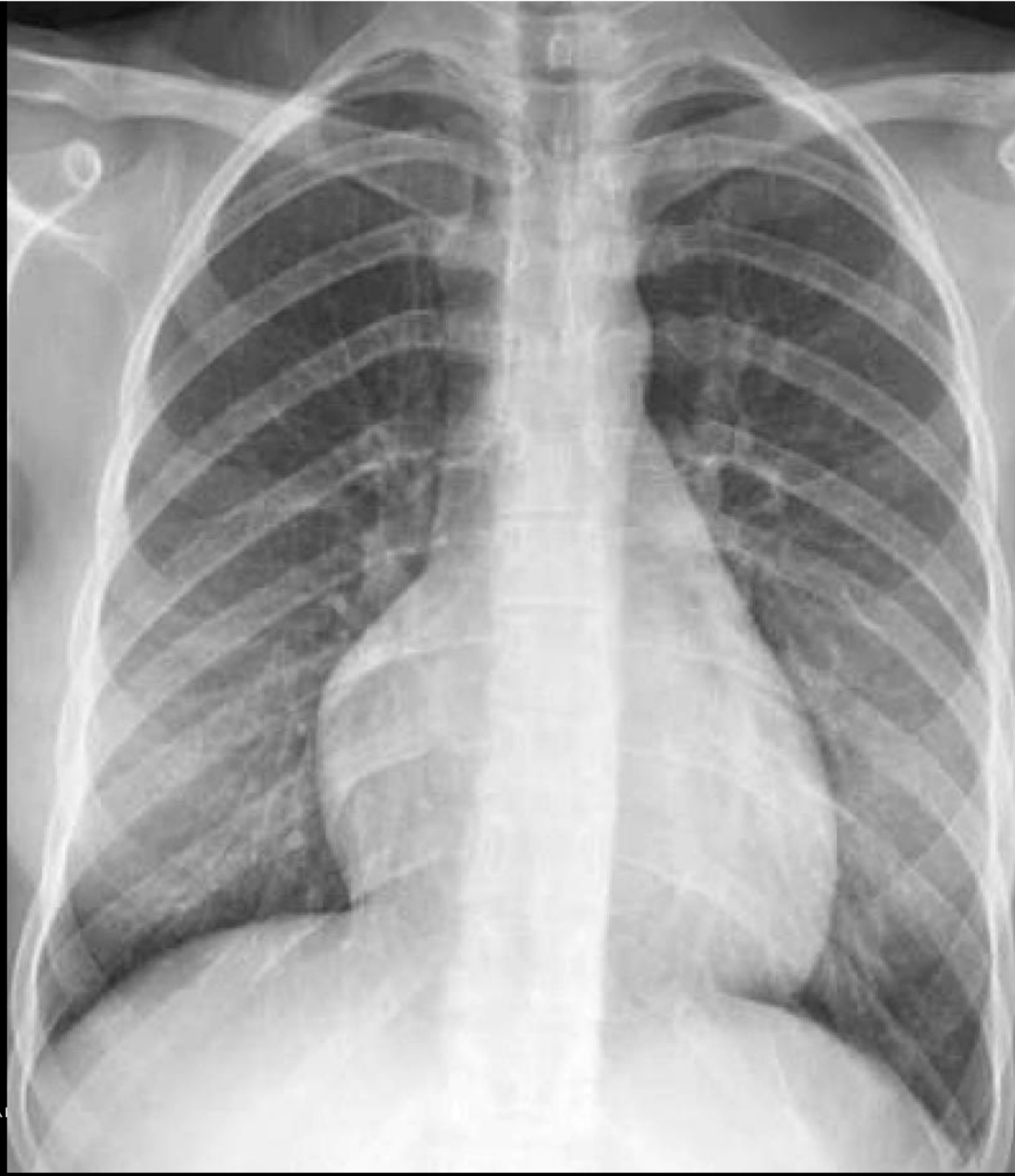**AIRP**<sup>TM</sup>

AMERICAN INSTITUTE FOR  
RADIOLOGIC PATHOLOGY

A PROGRAM OF THE  
AMERICAN COLLEGE OF RADIOLOGY





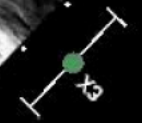


LEE T: 38'3C  
PAT T: 31'0C

b  
g

Gen  
b Off  
C 20  
23%  
SD

13cm  
23Hz  
X1-5f  
Adult Echo



1120'1 MI 0'2

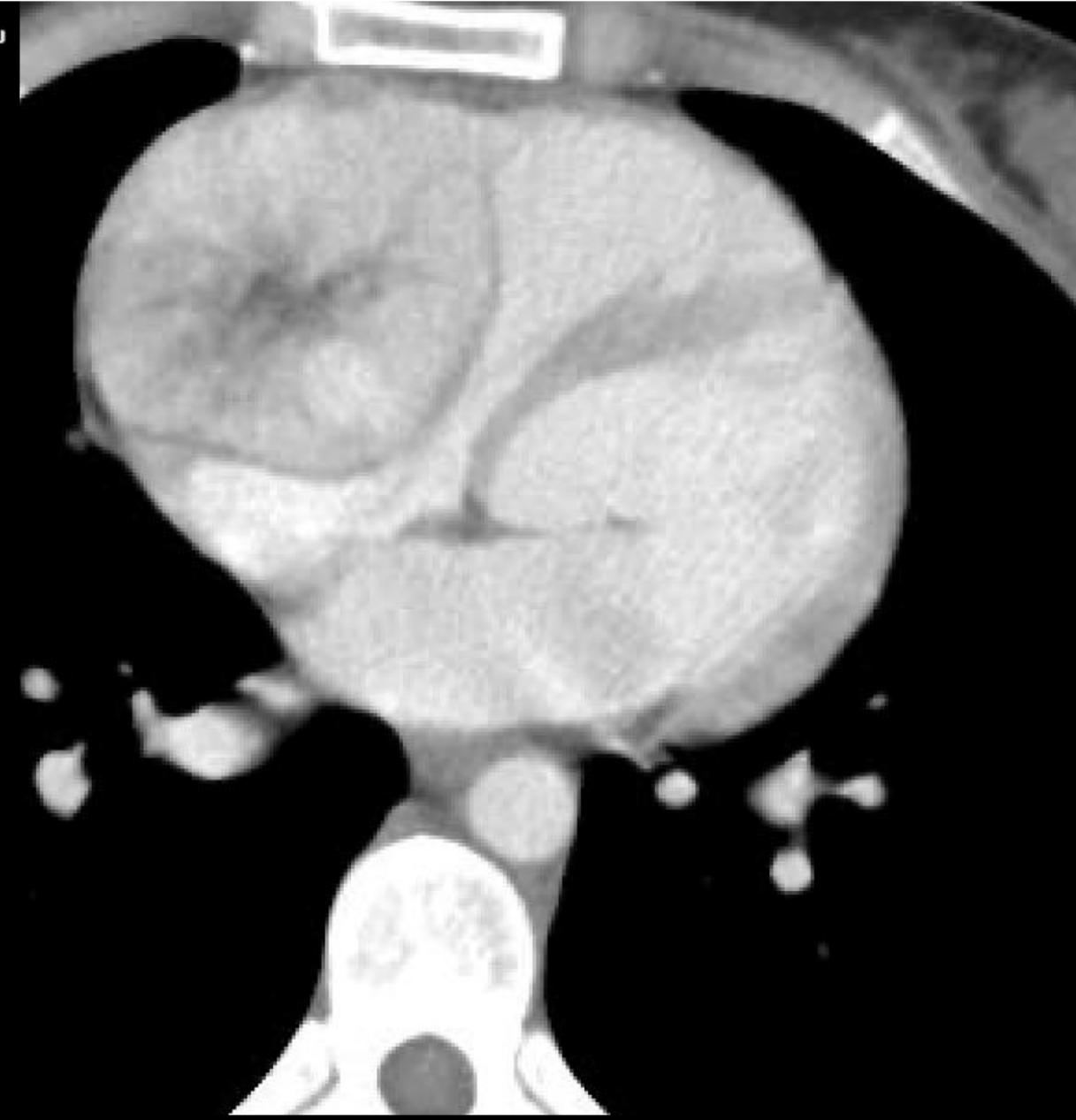15 pbw

W4

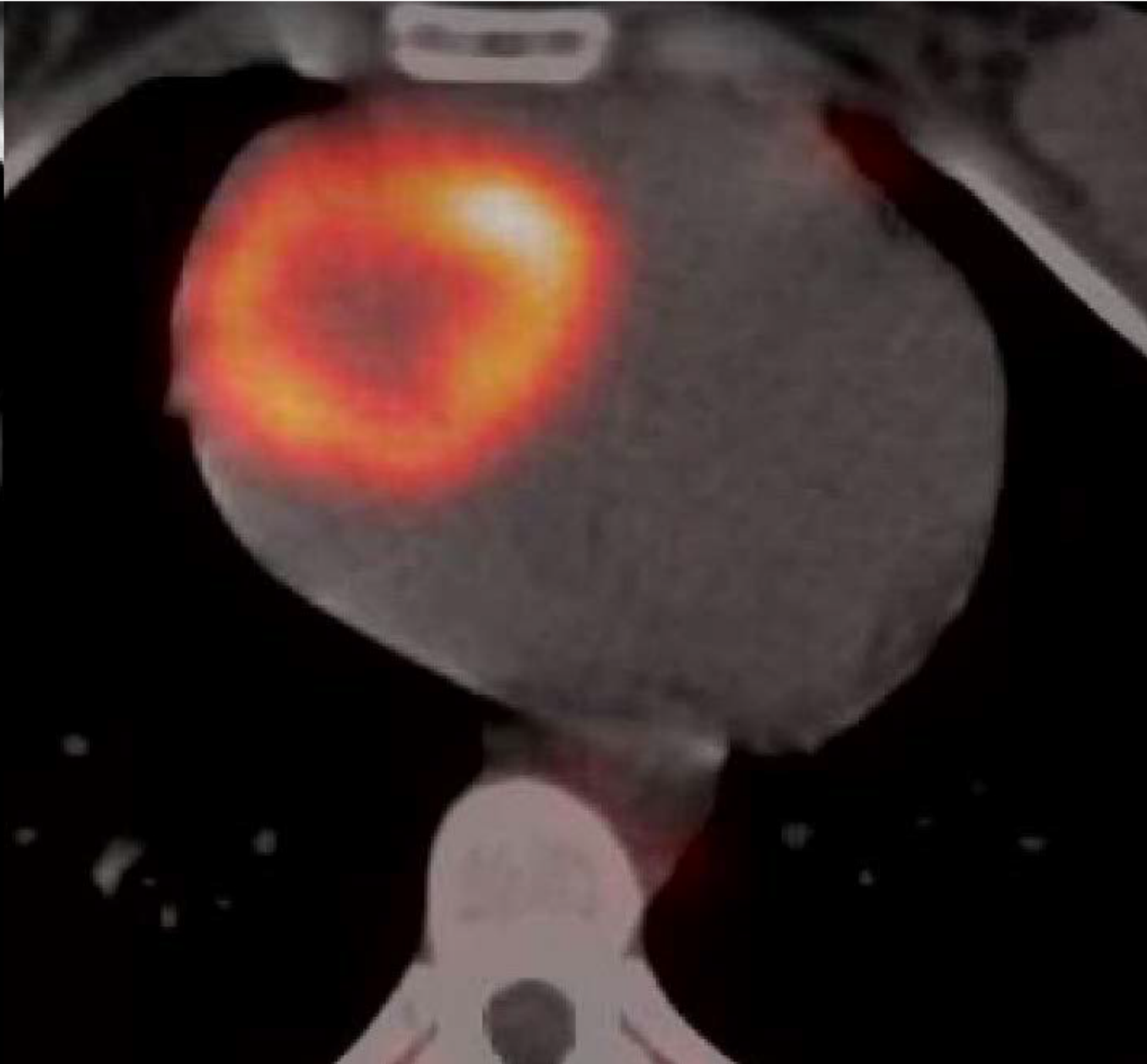
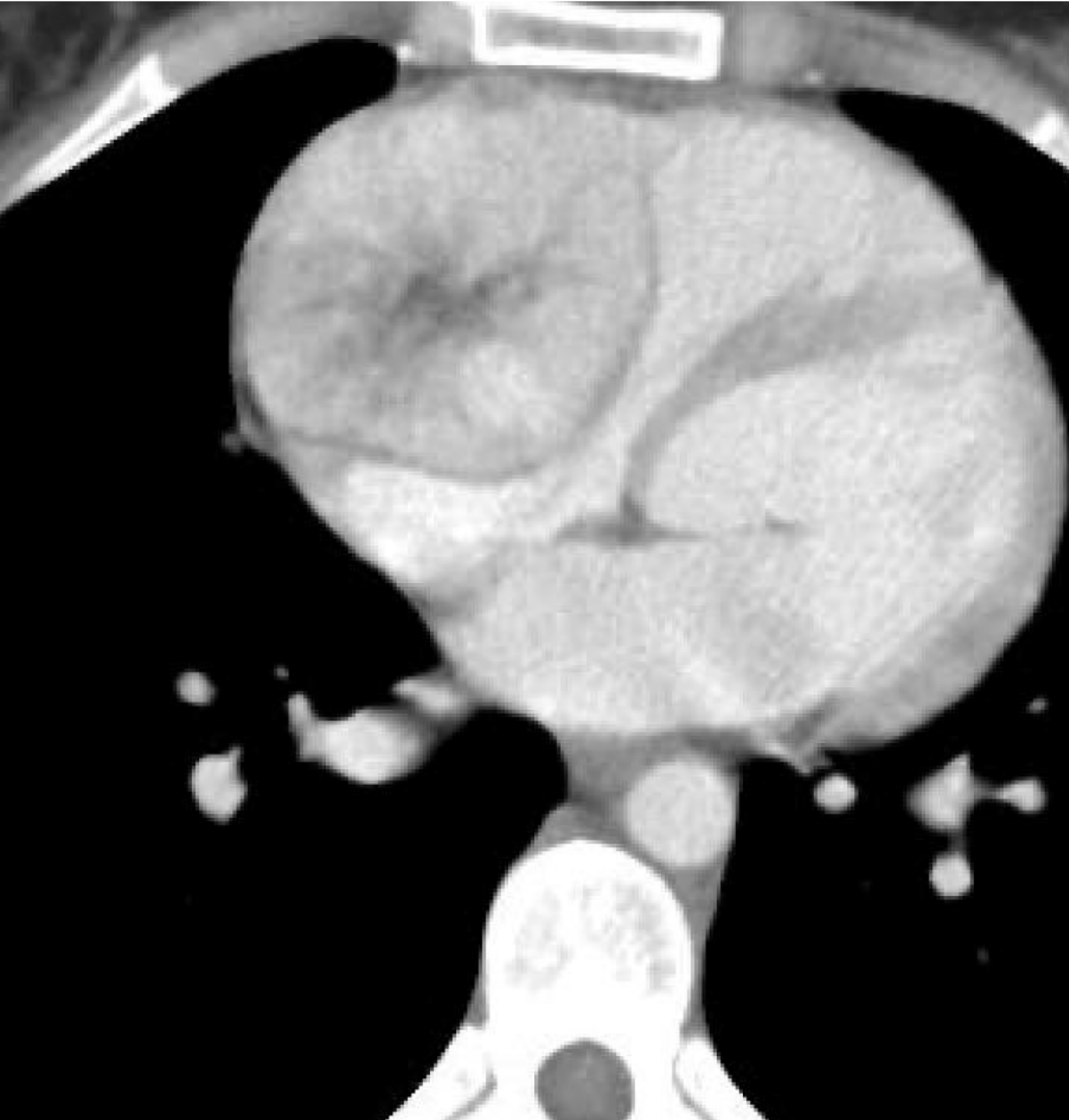# AIRP™

AMERICAN INSTITUTE FOR  
RADIOLOGIC PATHOLOGY

A PROGRAM OF THE  
AMERICAN COLLEGE OF RADIOLOGY

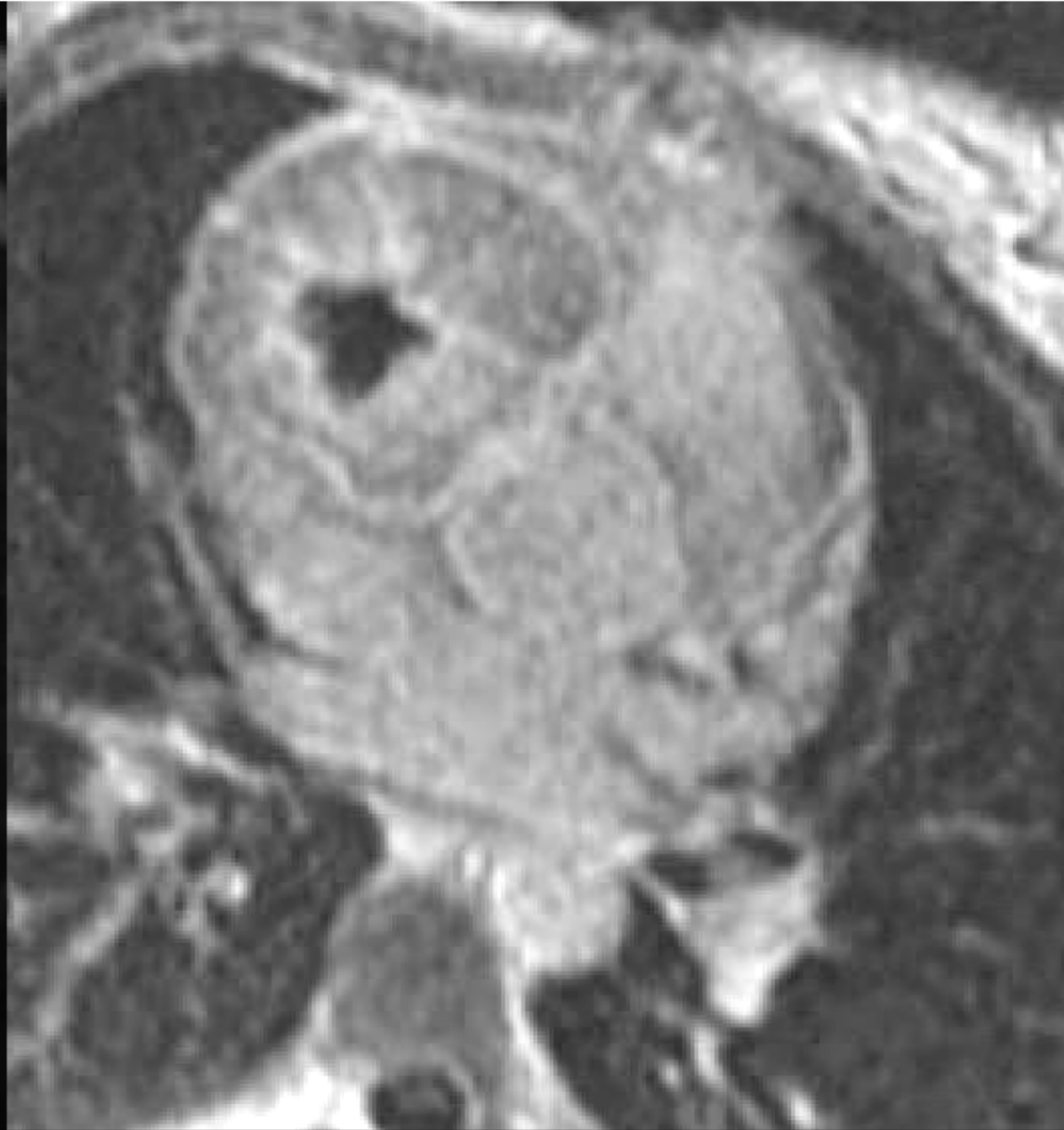
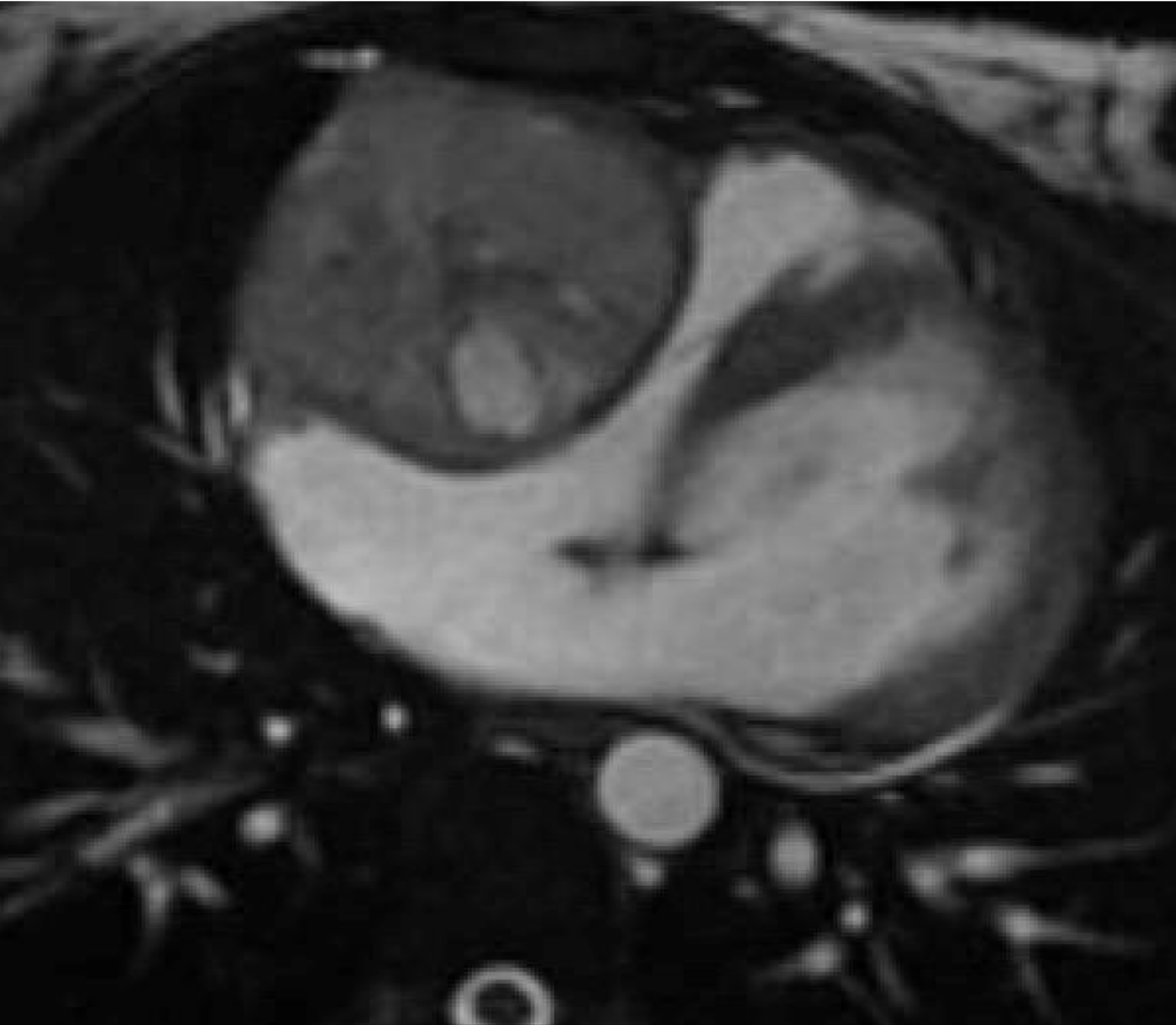






**RADIOLOGIC PATHOLOGY**

A PROGRAM OF THE  
AMERICAN COLLEGE OF RADIOLOGY



AMERICAN INSTITUTE FOR  
RADIOLOGIC PATHOLOGY

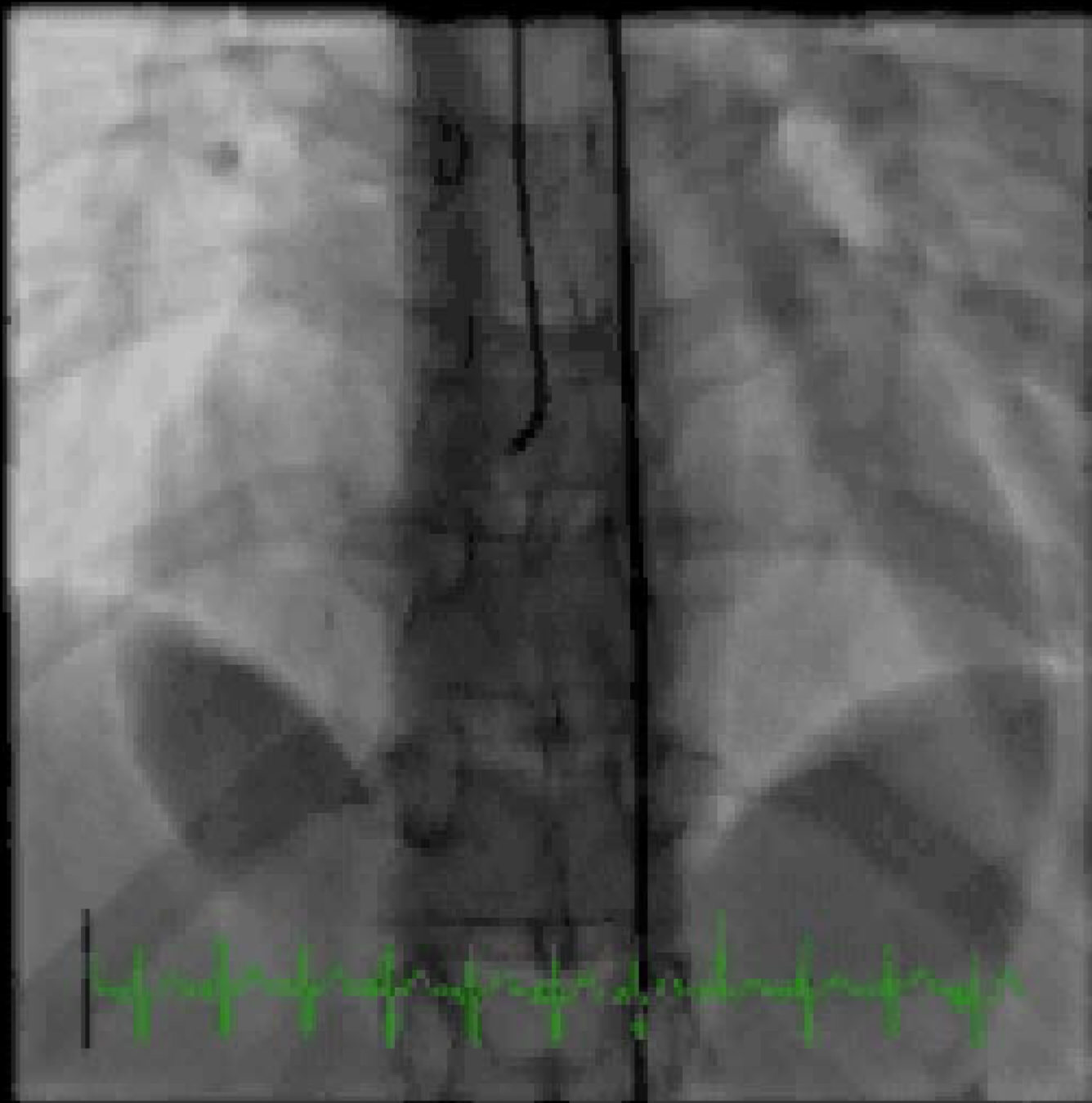
A PROGRAM OF THE  
AMERICAN COLLEGE OF RADIOLOGY



# AIRP™

AMERICAN INSTITUTE FOR  
RADIOLOGIC PATHOLOGY

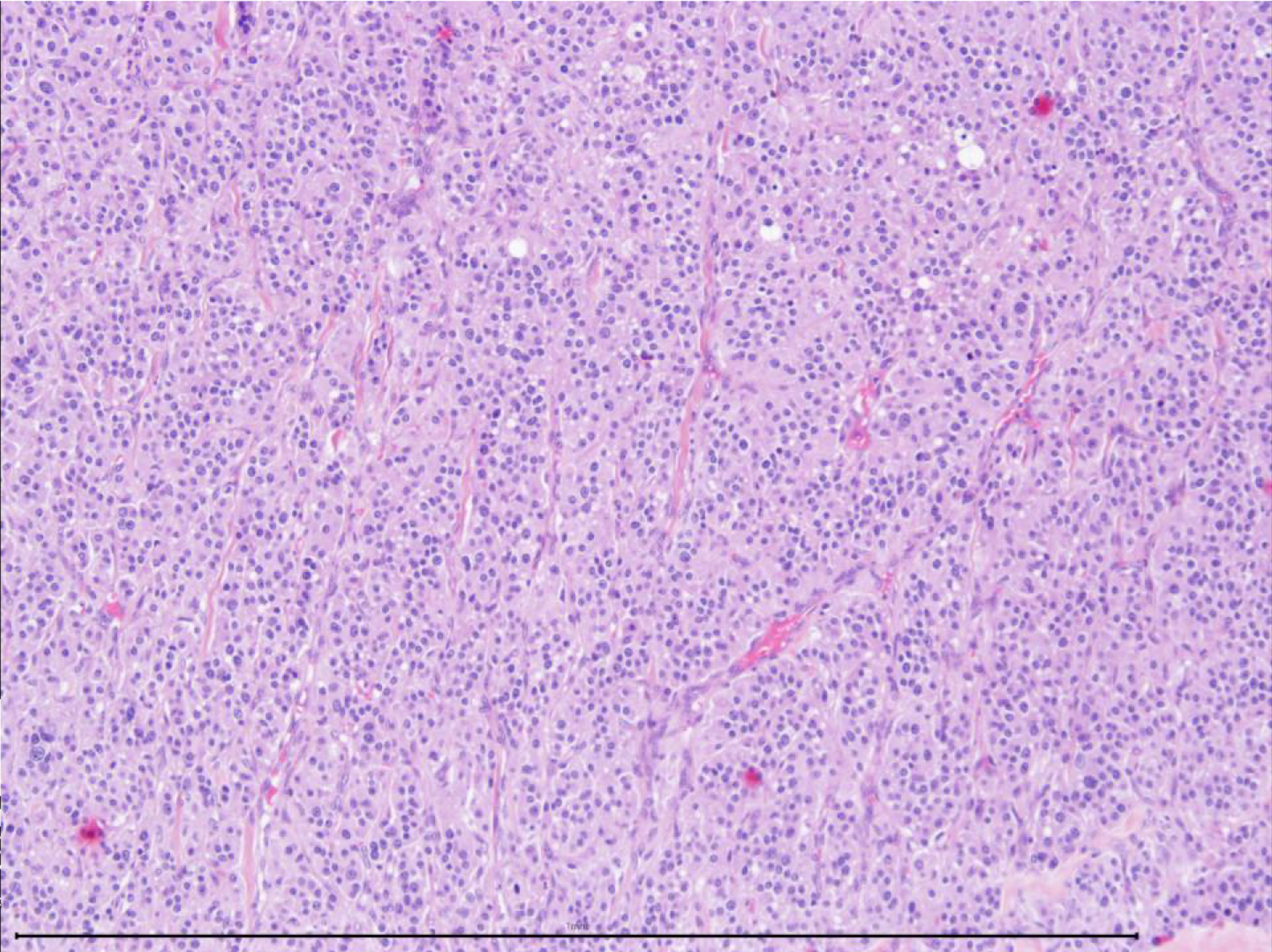
A PROGRAM OF THE  
AMERICAN COLLEGE OF RADIOLOGY



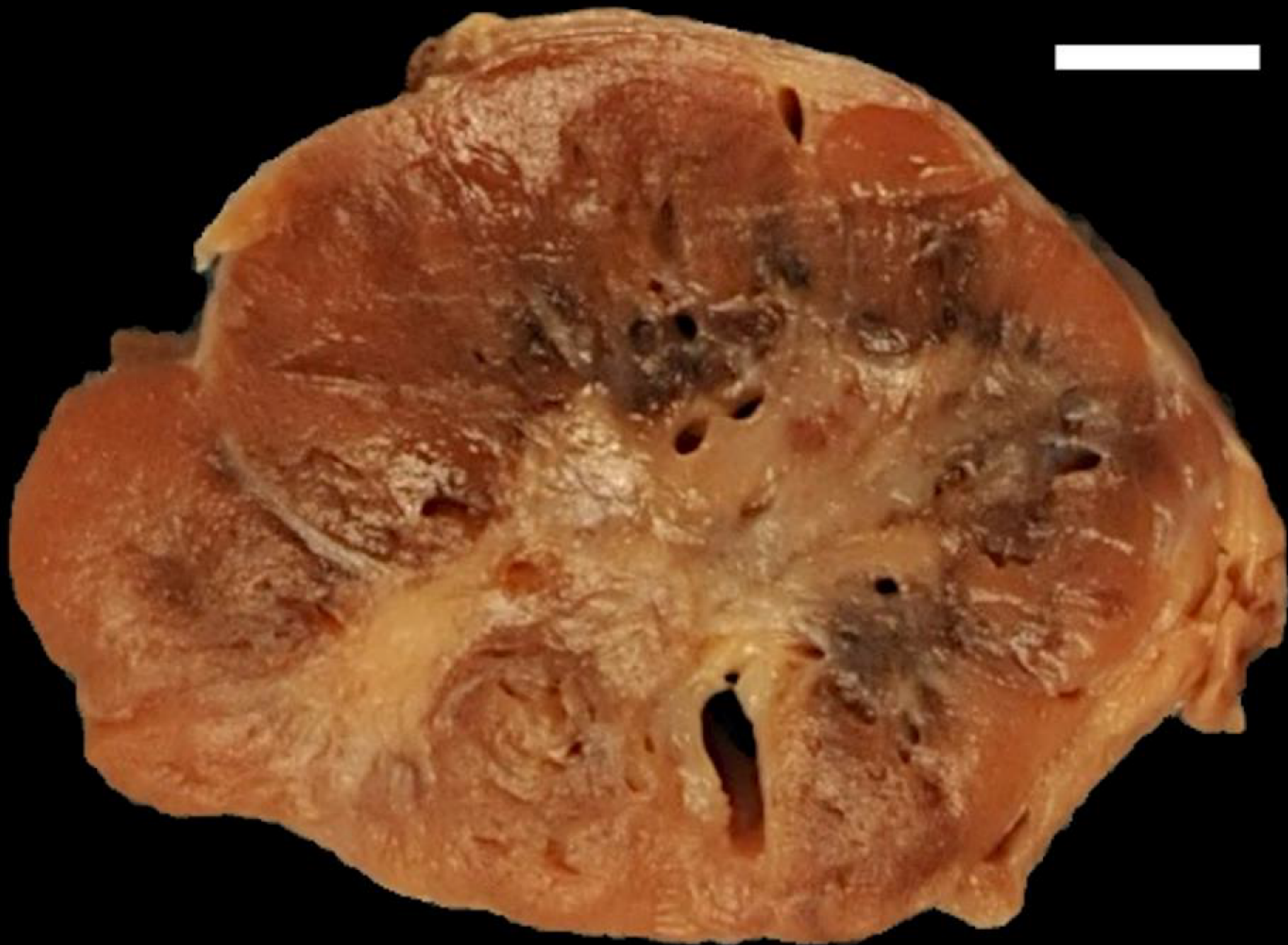**AI**

AMERICAN IN  
RADIOLOGIC

A PROGRA  
AMERICAN COLLEGE



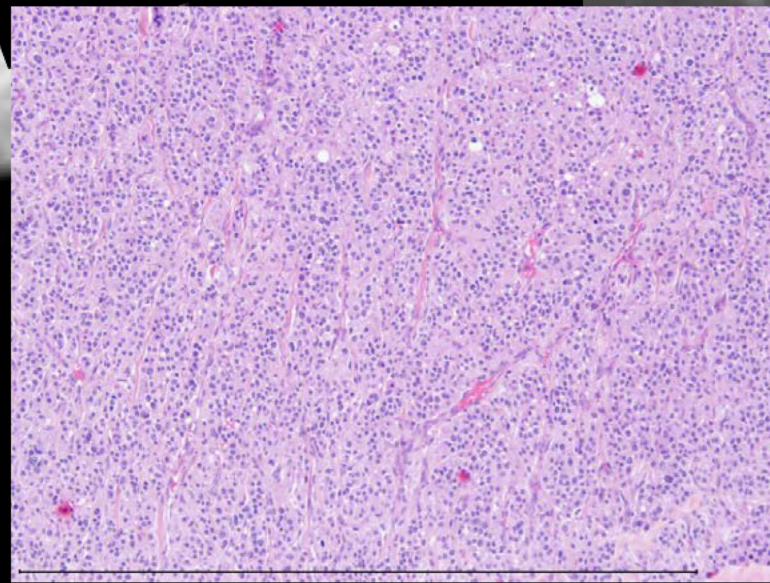
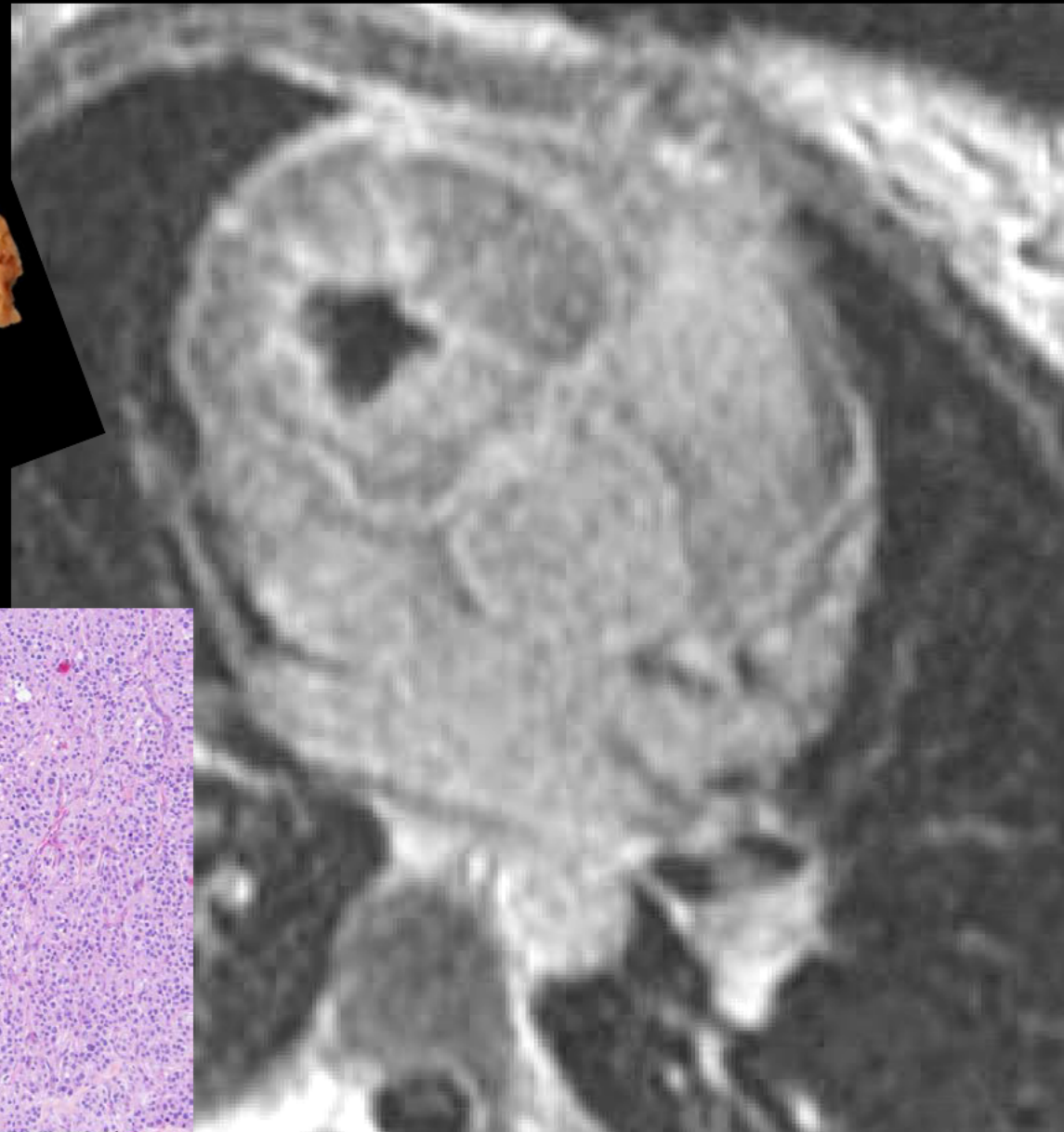
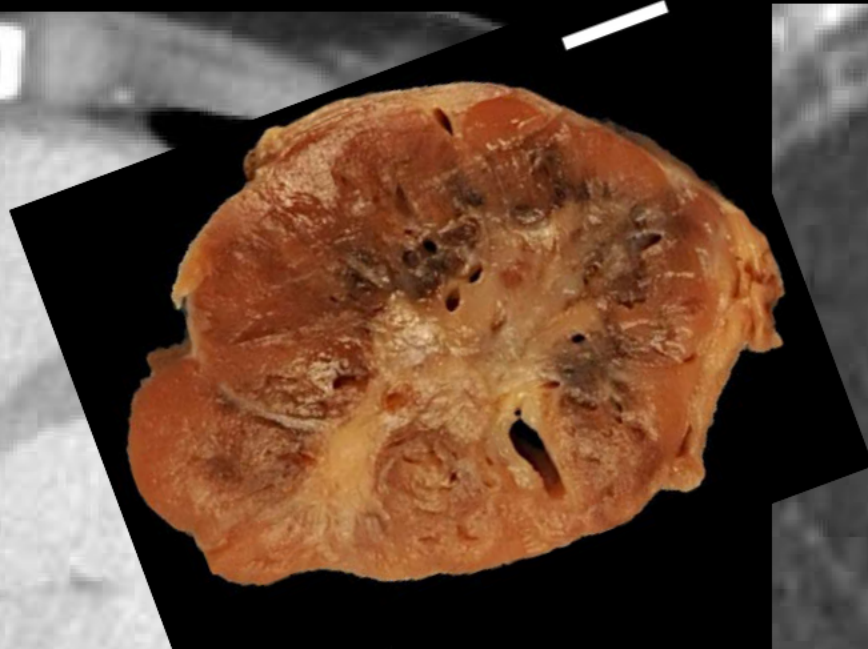
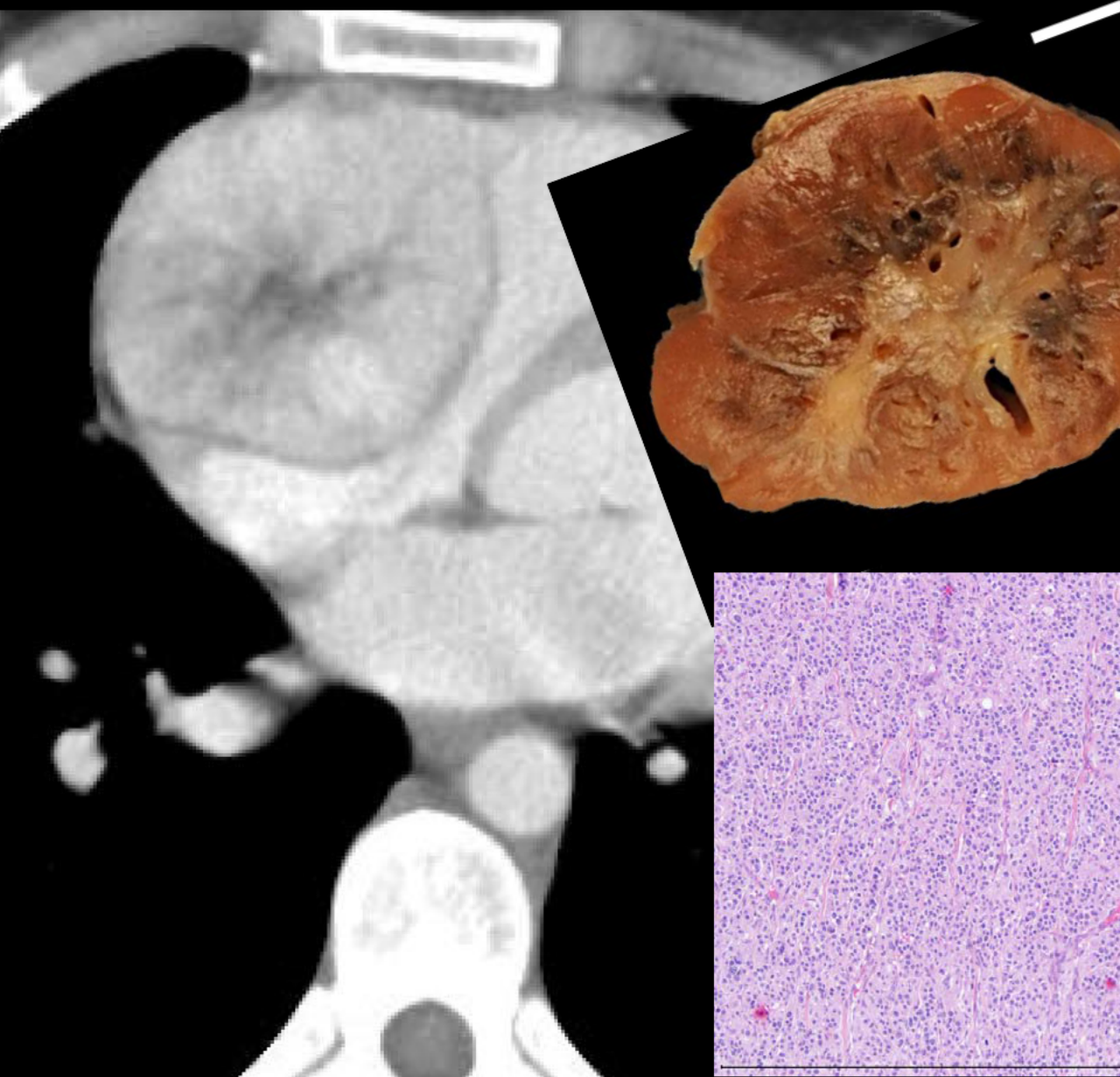




**AI**

AMERICAN IN  
RADIOLOGIC

A PROGRA  
AMERICAN COLLEC





# Cardiac Paraganglioma

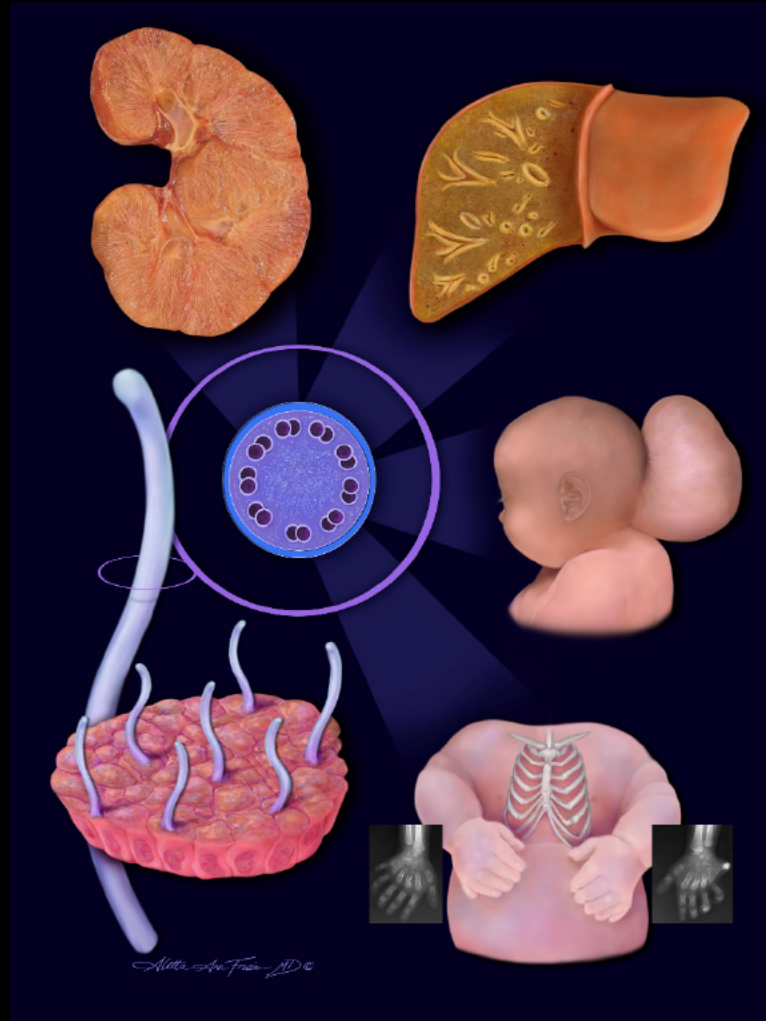
**Will Warnica**  
**University of Toronto**

**AIRP**<sup>TM</sup>

AMERICAN INSTITUTE FOR  
RADIOLOGIC PATHOLOGY

A PROGRAM OF THE  
AMERICAN COLLEGE OF RADIOLOGY

# Pediatric Best Case



**AIRP**™

AMERICAN INSTITUTE FOR  
RADIOLOGIC PATHOLOGY

A PROGRAM OF THE  
AMERICAN COLLEGE OF RADIOLOGY



# Clinical information

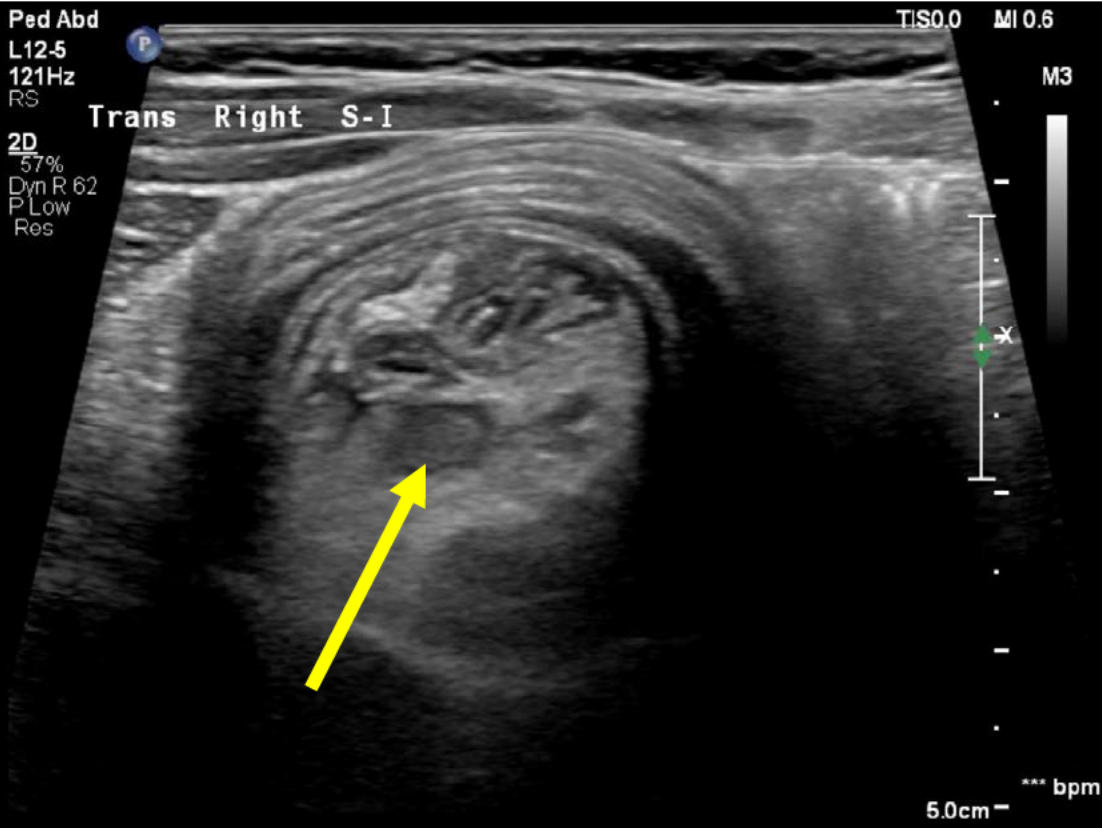
**3 year old healthy girl with recurrent intermittent abdominal pain and emesis occurring 1-2 times per hour.**

**Abdominal ultrasound was performed.**



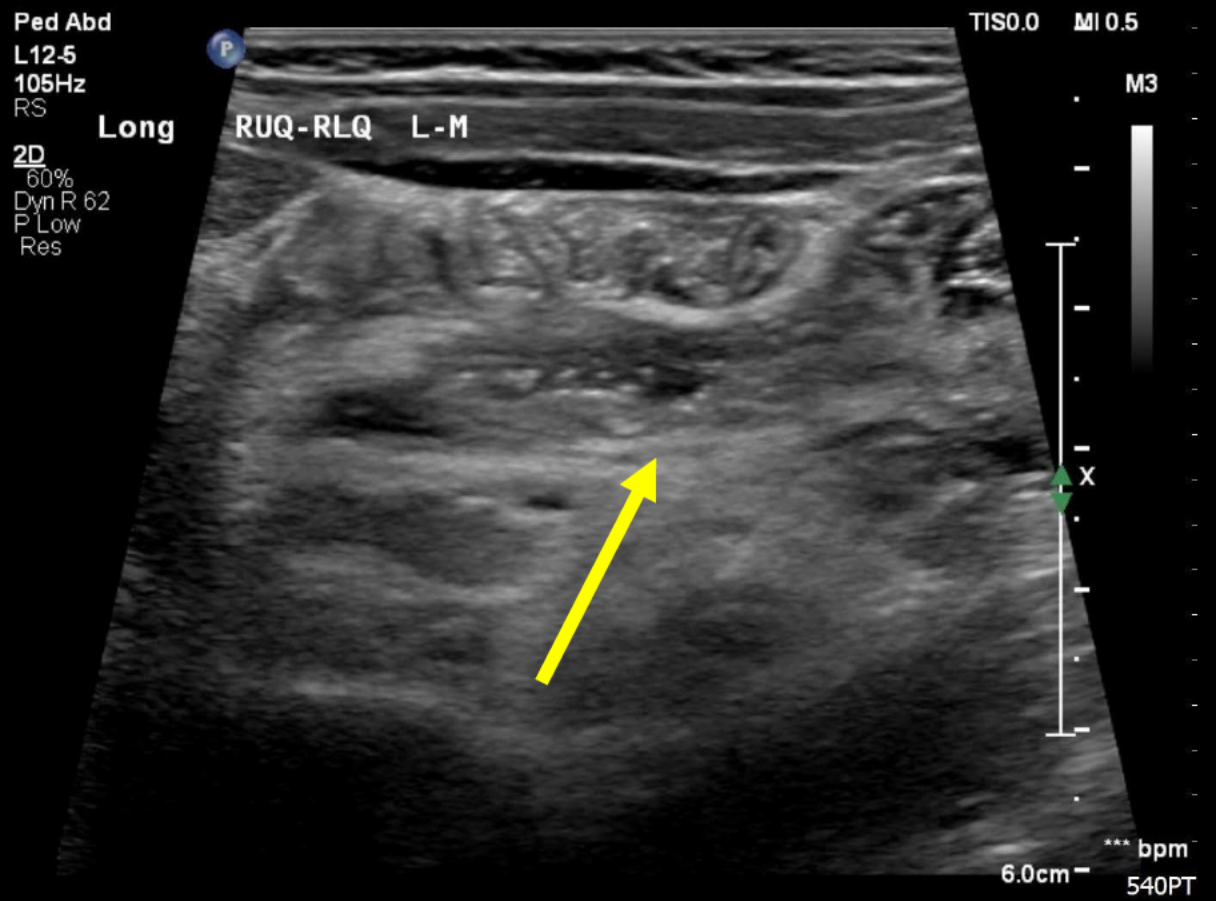
AMERICAN INSTITUTE FOR  
RADIOLOGIC PATHOLOGY

A PROGRAM OF THE  
AMERICAN COLLEGE OF RADIOLOGY

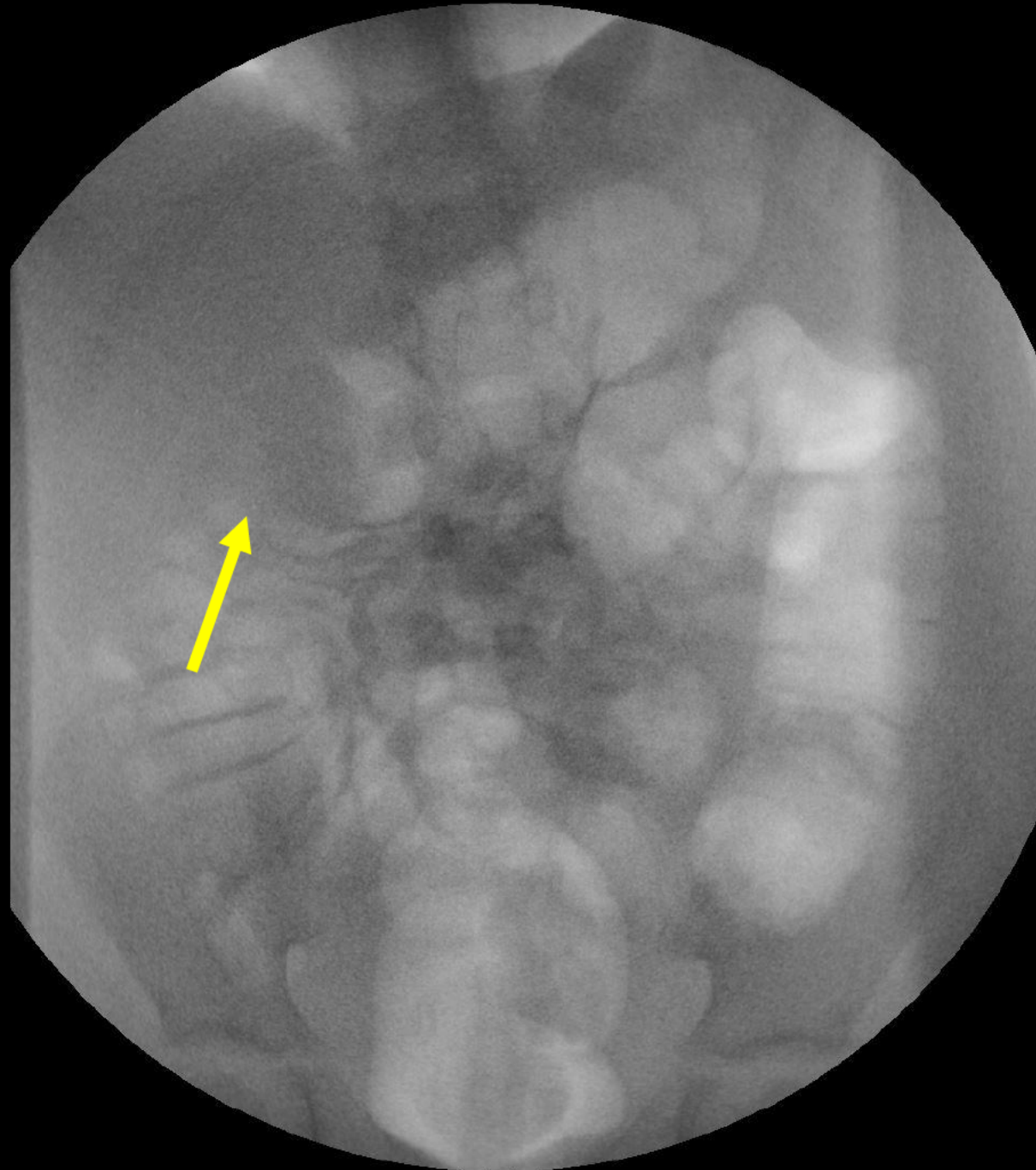


**AIRP**<sup>TM</sup>  
AMERICAN INSTITUTE FOR  
RADIOLOGIC PATHOLOGY

A PROGRAM OF THE  
AMERICAN COLLEGE OF RADIOLOGY







**AIRP**<sup>TM</sup>

AMERICAN INSTITUTE FOR  
RADIOLOGIC PATHOLOGY

A PROGRAM OF THE  
AMERICAN COLLEGE OF RADIOLOGY

Ped Abd

L12-5

6Hz

Z 1.1

2D

68%

Dyn R 60

P Med

Res

CPA

57%

1500Hz

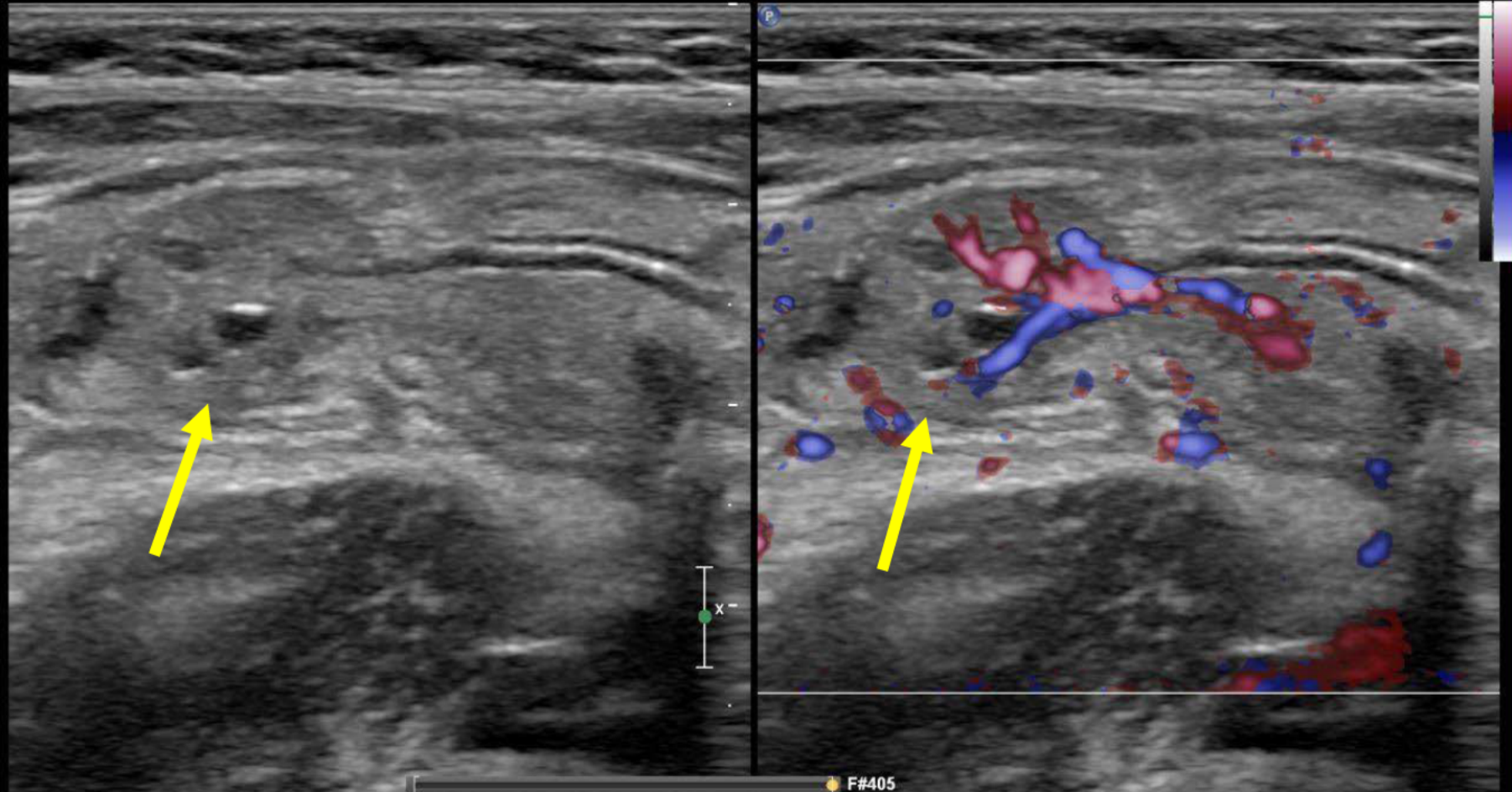
WF 105Hz

6.3MHz

TIS0.1

MI 0.6

RLQ



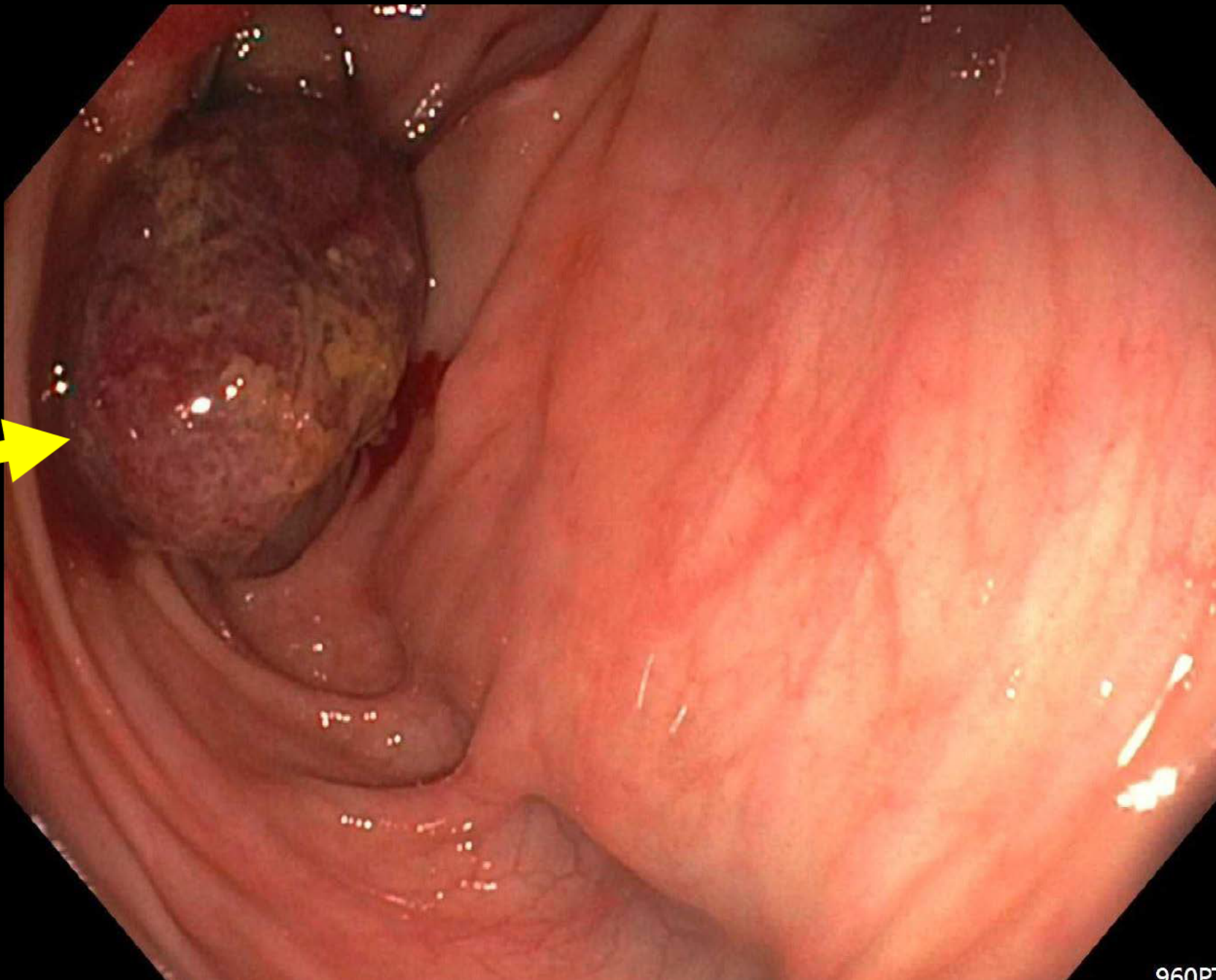
# AIRP<sup>TM</sup>

AMERICAN INSTITUTE FOR  
RADIOLOGIC PATHOLOGY

A PROGRAM OF THE  
AMERICAN COLLEGE OF RADIOLOGY



Colonoscopy  
demonstrated four  
polyps throughout  
the colon



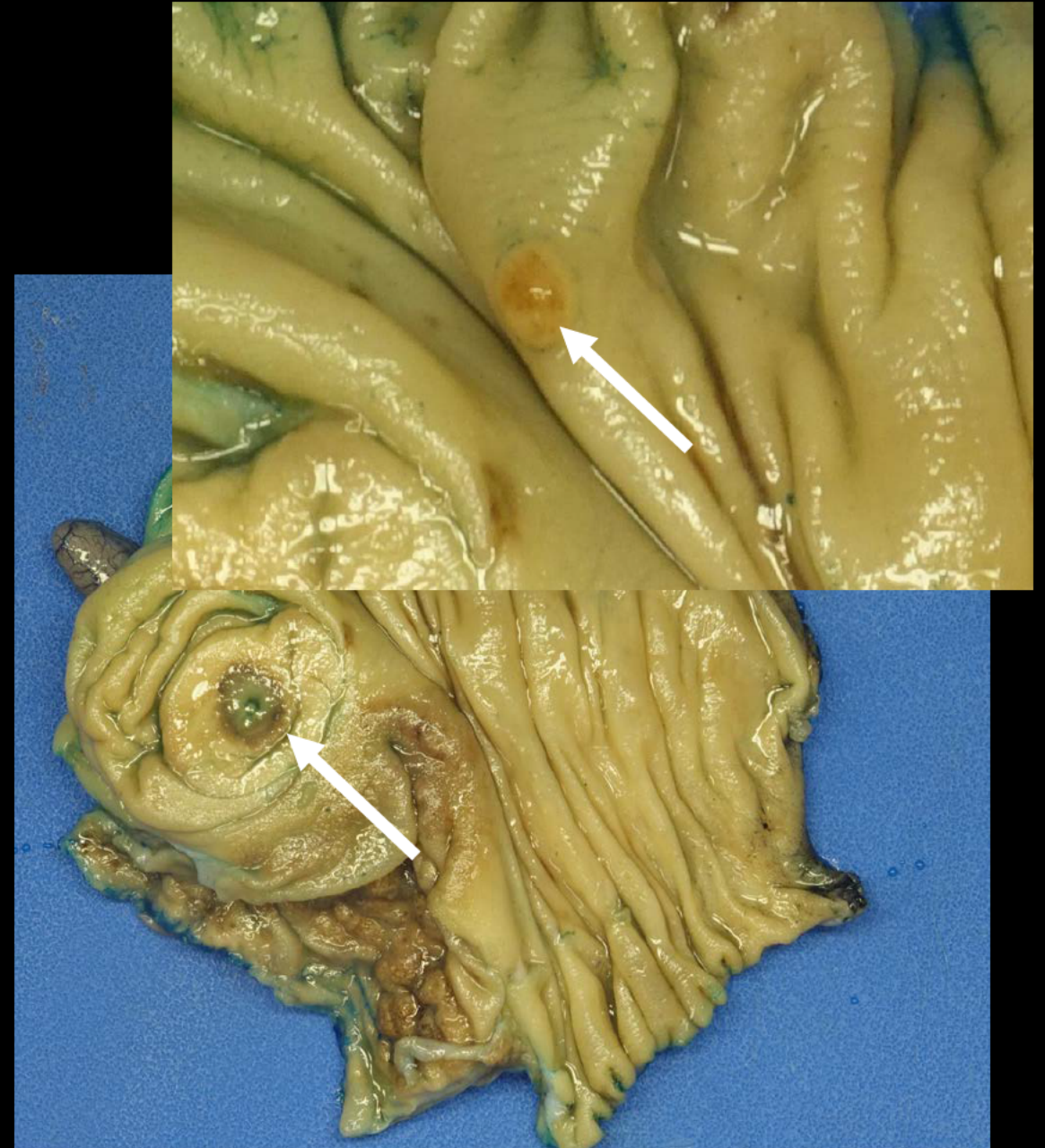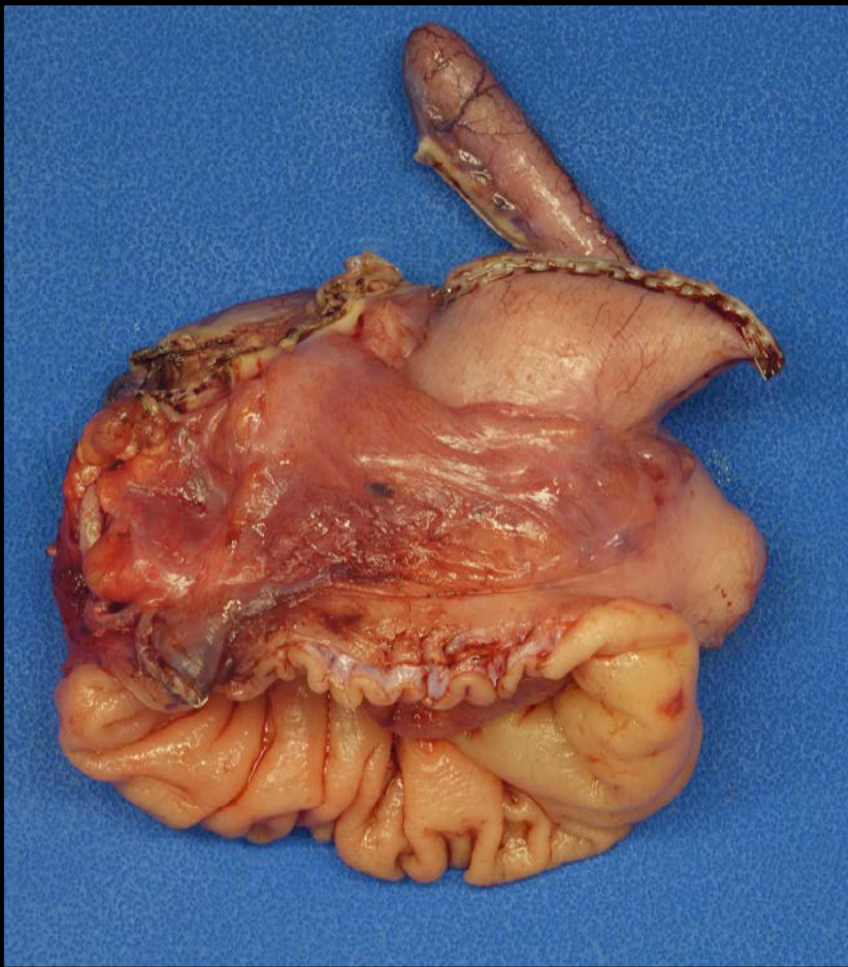
**AIRP**<sup>TM</sup>

AMERICAN INSTITUTE FOR  
RADIOLOGIC PATHOLOGY

A PROGRAM OF THE  
AMERICAN COLLEGE OF RADIOLOGY

960PT



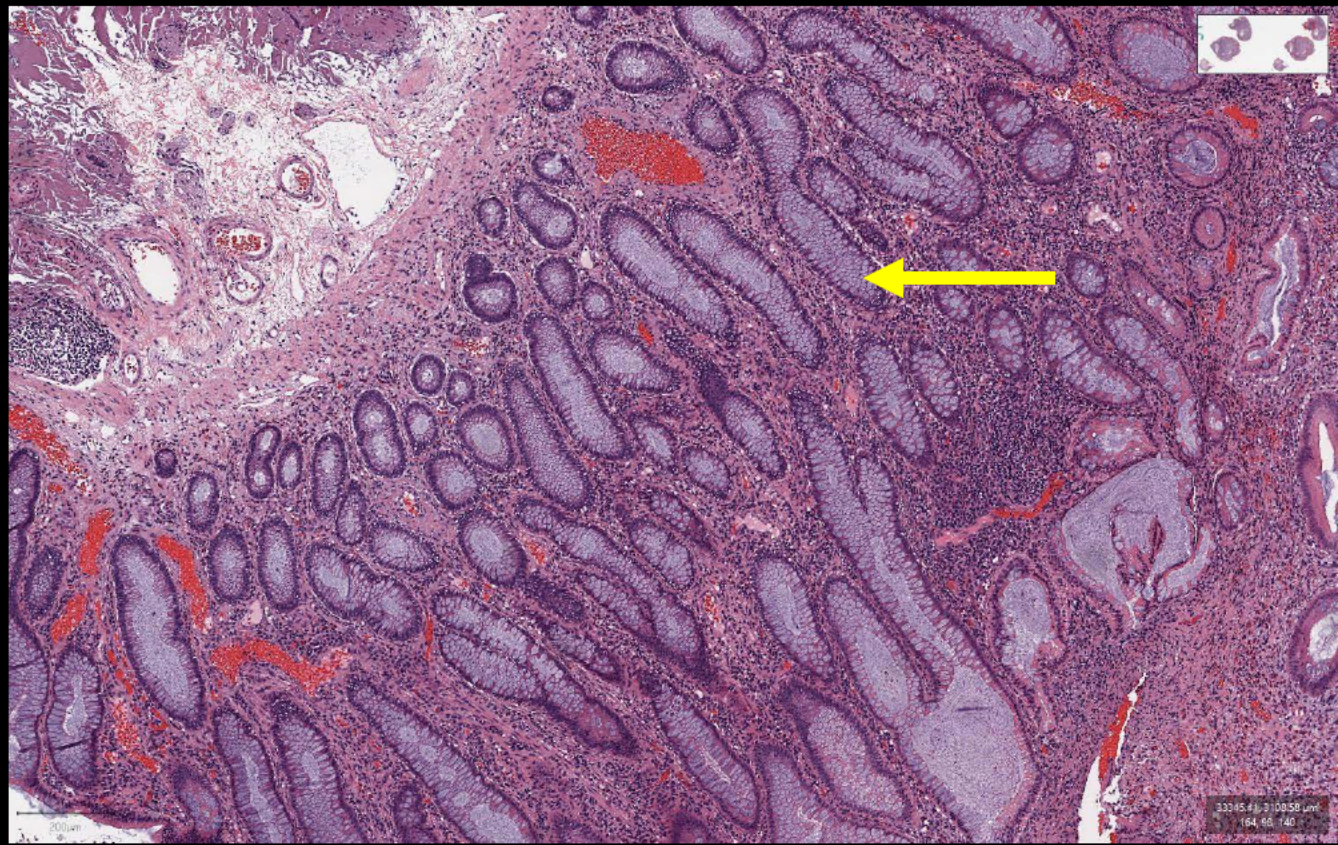
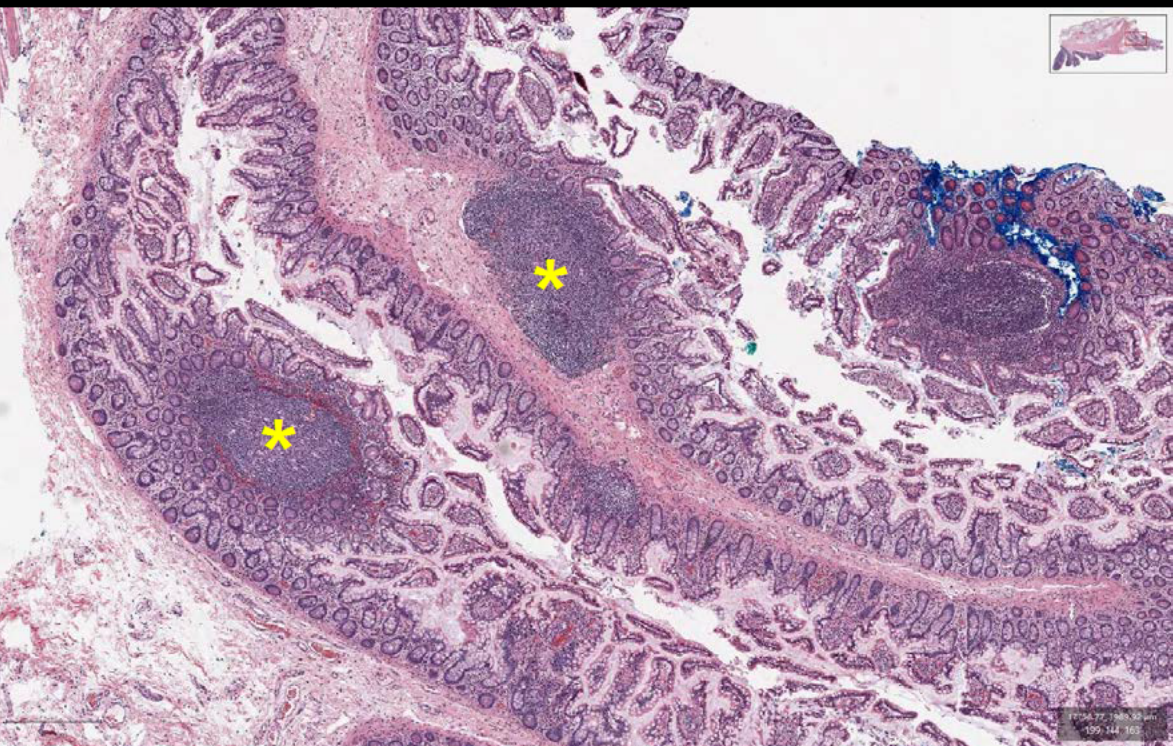


**AIRP**<sup>TM</sup>

AMERICAN INSTITUTE FOR  
RADIOLOGIC PATHOLOGY

A PROGRAM OF THE  
AMERICAN COLLEGE OF RADIOLOGY







# Juvenile Polypsis with Intussusception

Andrew Kim

Seattle Children's Hospital

University of Washington Residency

Case ID: 30661

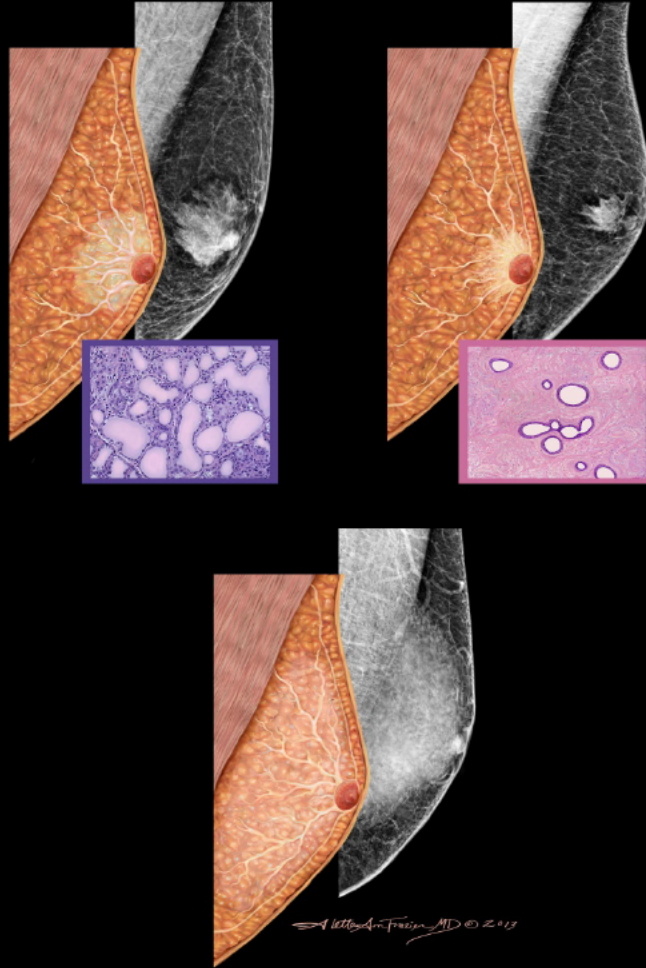
**AIRP**<sup>TM</sup>

AMERICAN INSTITUTE FOR  
RADIOLOGIC PATHOLOGY

A PROGRAM OF THE  
AMERICAN COLLEGE OF RADIOLOGY



# Breast Best Case



**AIRP**<sup>TM</sup>

AMERICAN INSTITUTE FOR  
RADIOLOGIC PATHOLOGY

A PROGRAM OF THE  
AMERICAN COLLEGE OF RADIOLOGY

# Clinical information

**53-year-old woman with enlarging right breast mass.**



AMERICAN INSTITUTE FOR  
RADIOLOGIC PATHOLOGY

---

A PROGRAM OF THE  
AMERICAN COLLEGE OF RADIOLOGY

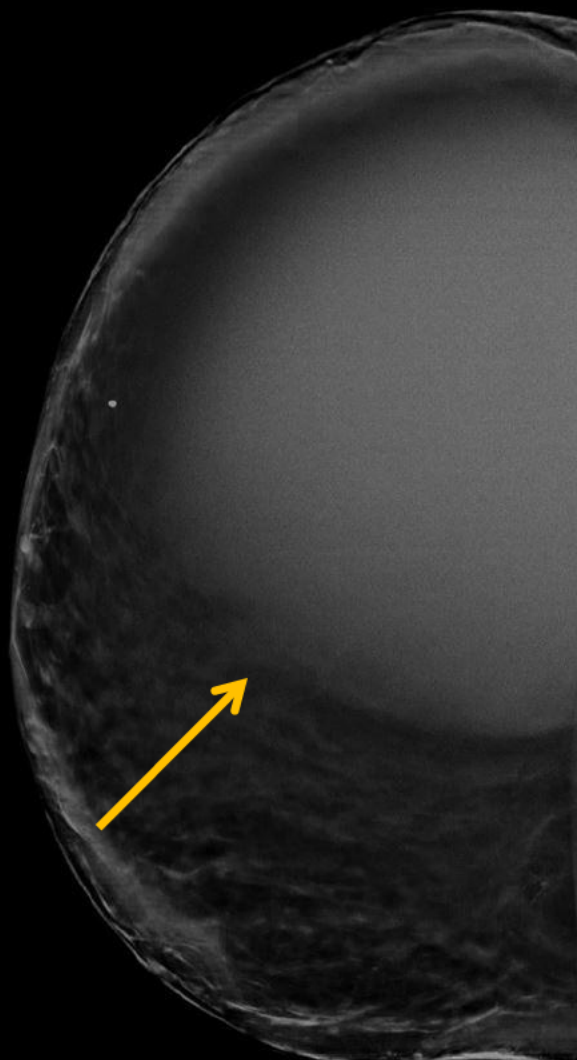


**AIRP**<sup>TM</sup>

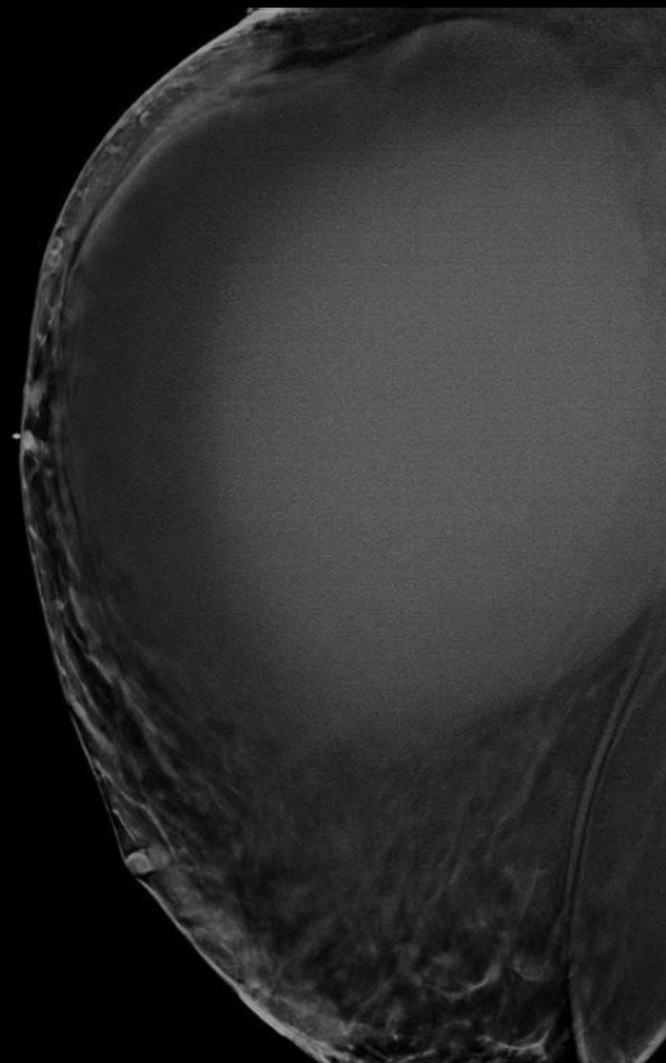
AMERICAN INSTITUTE FOR  
RADIOLOGIC PATHOLOGY

A PROGRAM OF THE  
AMERICAN COLLEGE OF RADIOLOGY

RCC



RCC

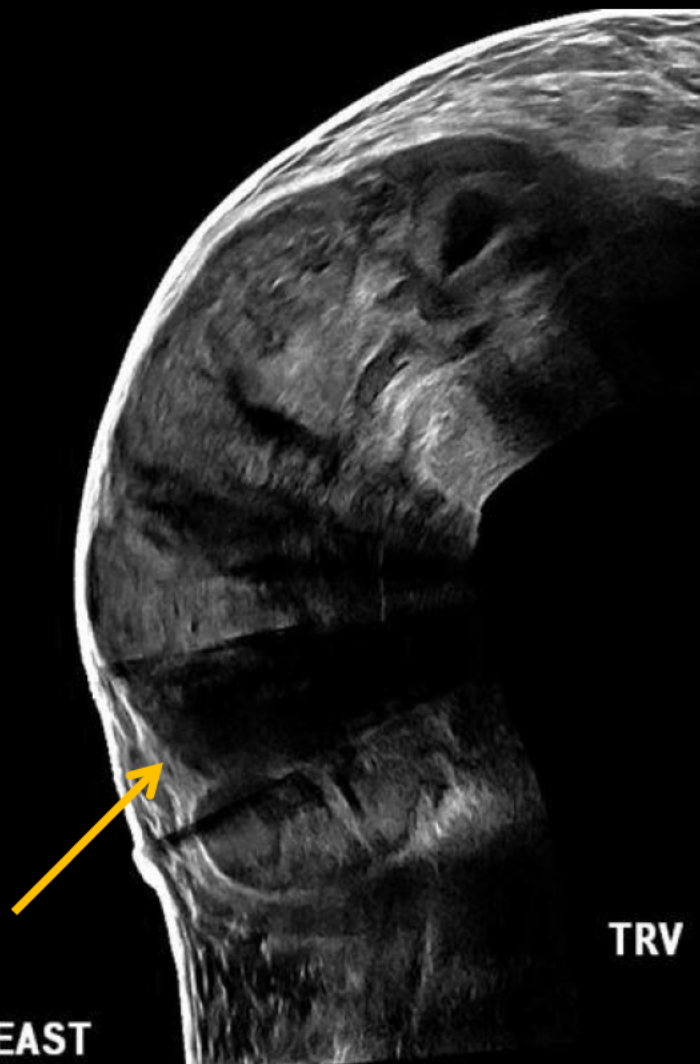


**AIRP**<sup>TM</sup>

AMERICAN INSTITUTE FOR  
RADIOLOGIC PATHOLOGY

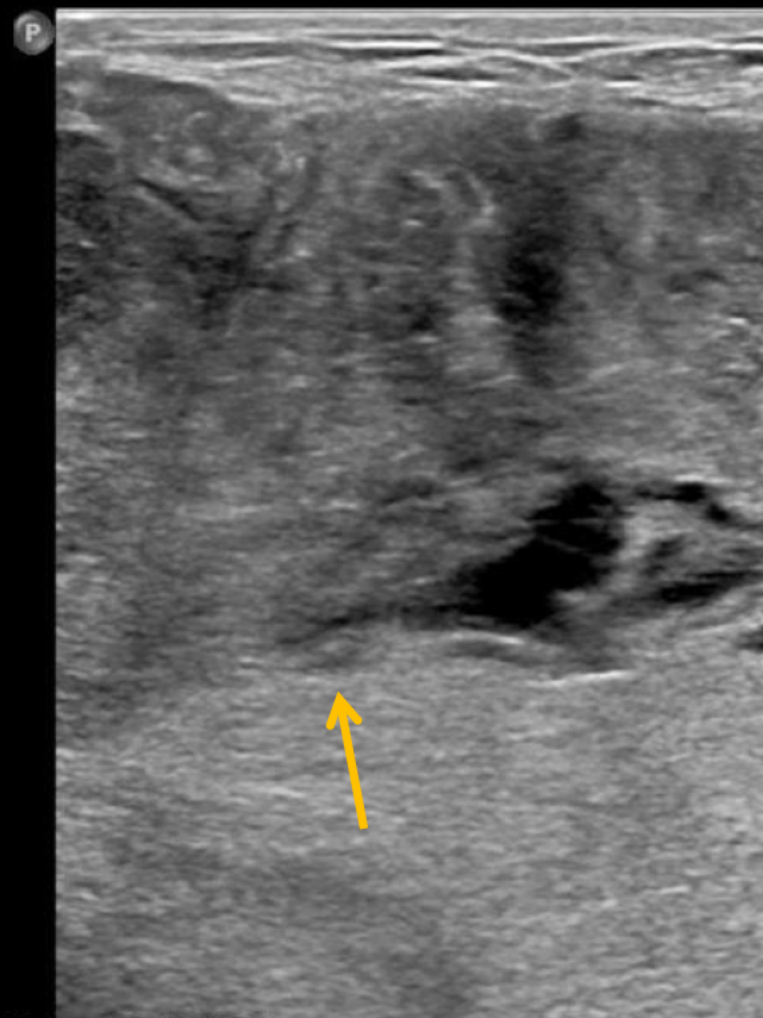
A PROGRAM OF THE  
AMERICAN COLLEGE OF RADIOLOGY

RT BREAST

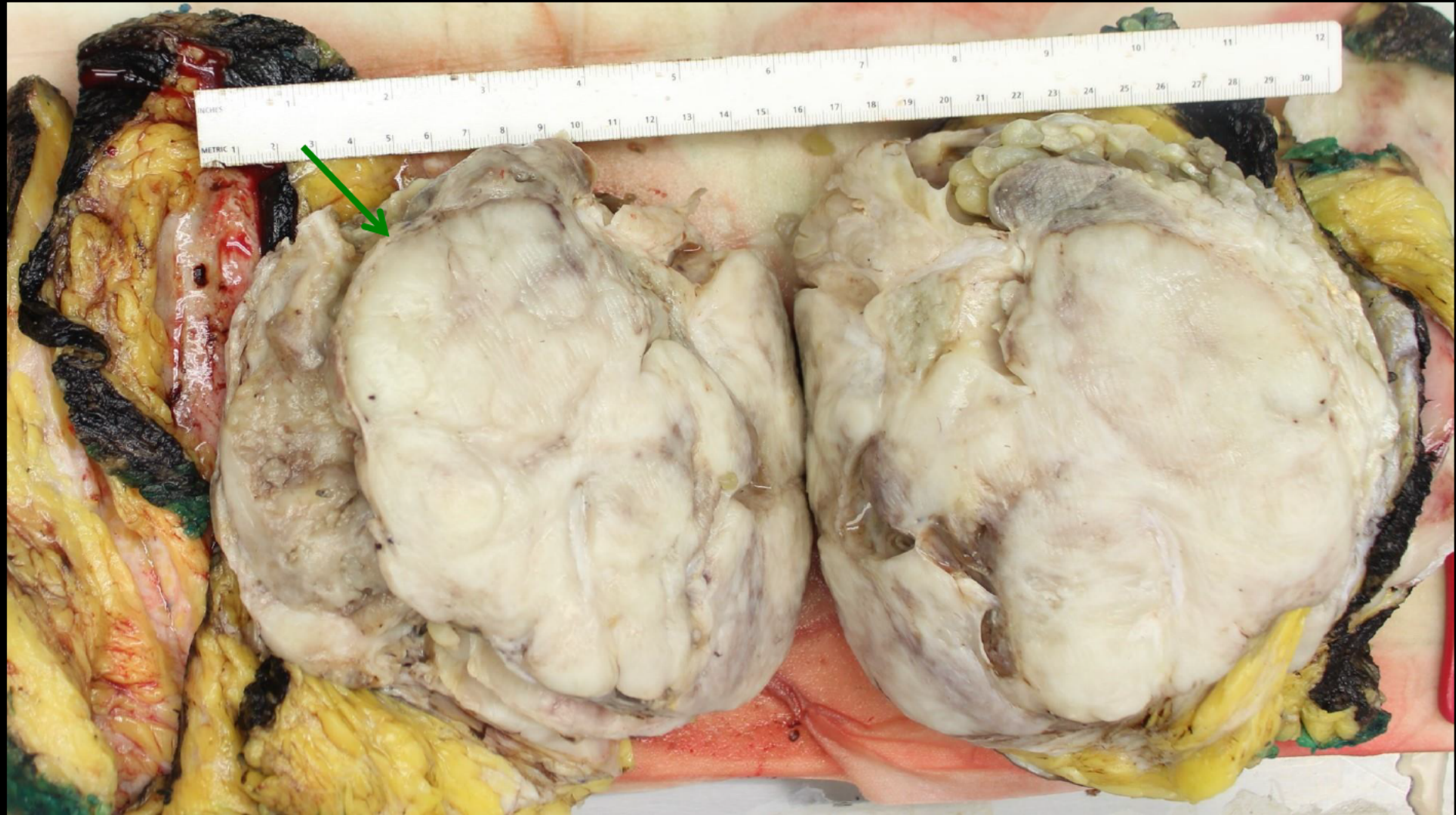

TRV

RT BREAST CENTRAL







**AIRP**<sup>TM</sup>

AMERICAN INSTITUTE FOR  
RADIOLOGIC PATHOLOGY

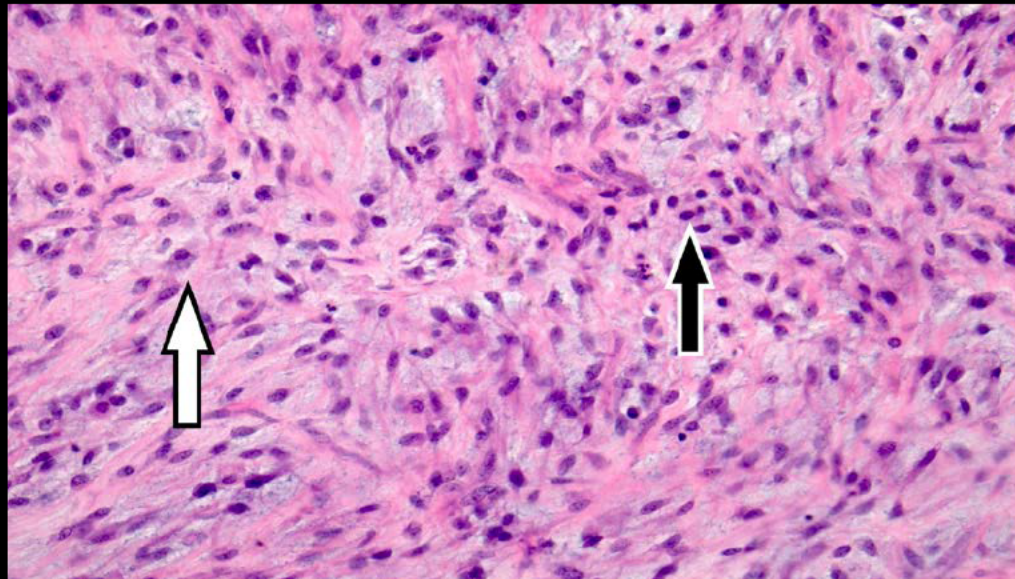
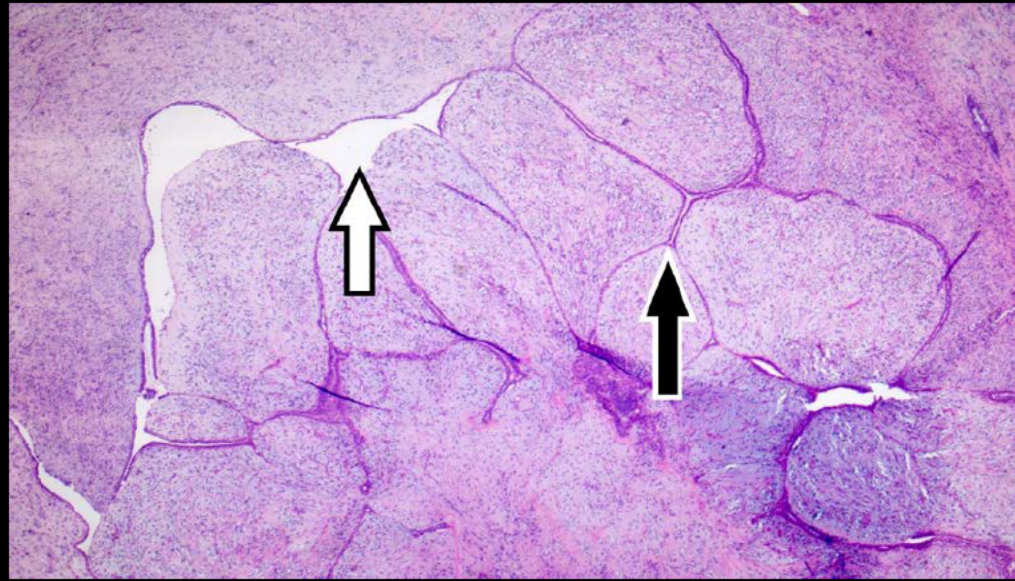
A PROGRAM OF THE  
AMERICAN COLLEGE OF RADIOLOGY



# AIRP™

AMERICAN INSTITUTE FOR  
RADIOLOGIC PATHOLOGY

A PROGRAM OF THE  
AMERICAN COLLEGE OF RADIOLOGY





# Malignant Phyllodes

Nathaniel Linna, MD

University of Pennsylvania

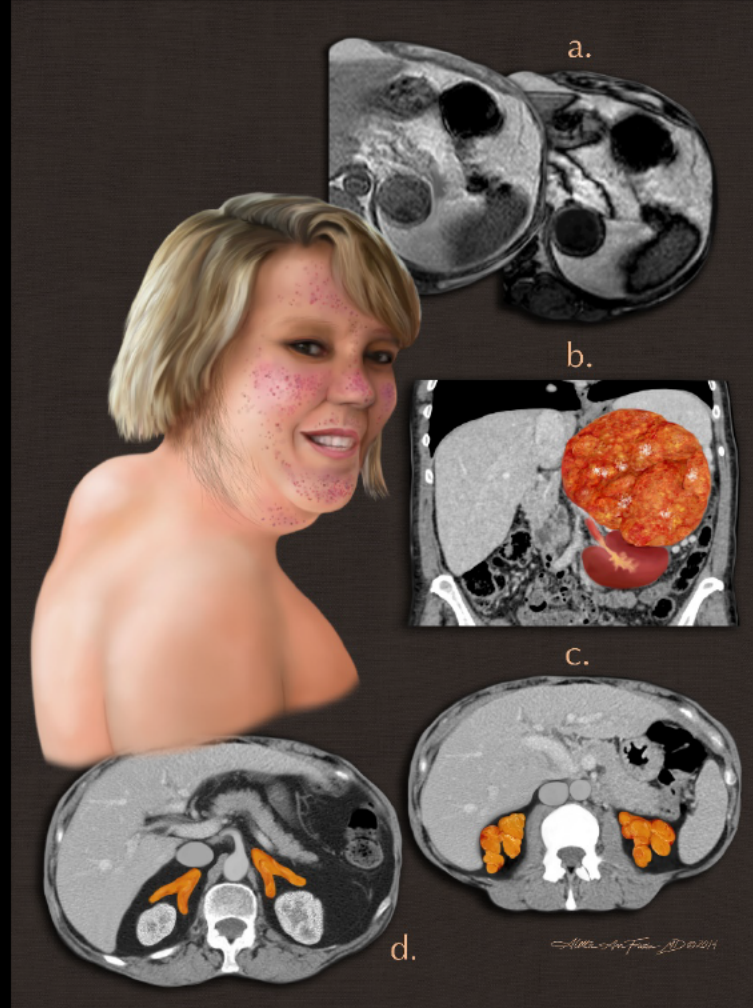Philadelphia, Pennsylvania



AMERICAN INSTITUTE FOR  
RADIOLOGIC PATHOLOGY

A PROGRAM OF THE  
AMERICAN COLLEGE OF RADIOLOGY

# Genitourinary Best Case



**AIRP**<sup>TM</sup>

AMERICAN INSTITUTE FOR  
RADIOLOGIC PATHOLOGY

A PROGRAM OF THE  
AMERICAN COLLEGE OF RADIOLOGY



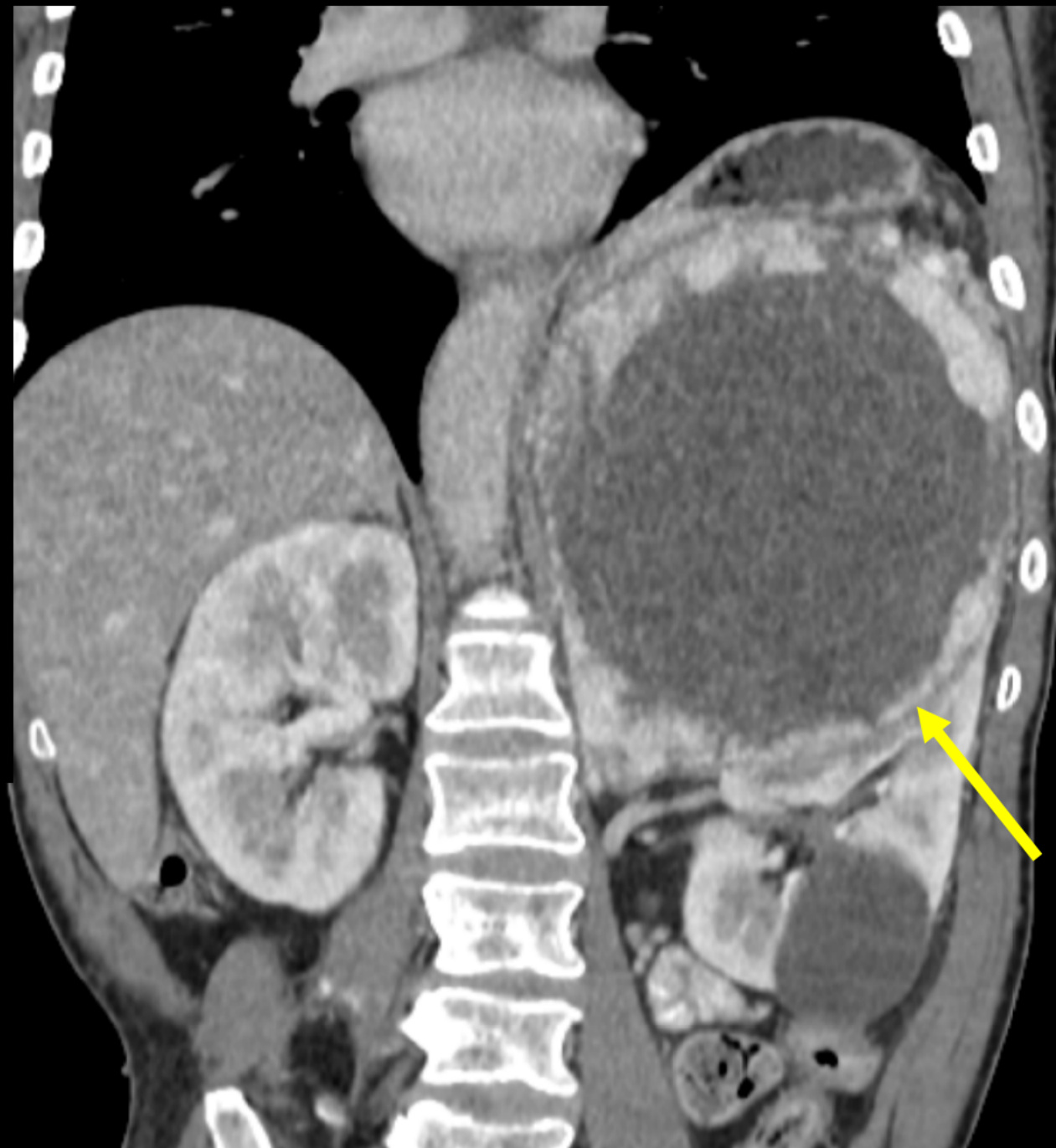
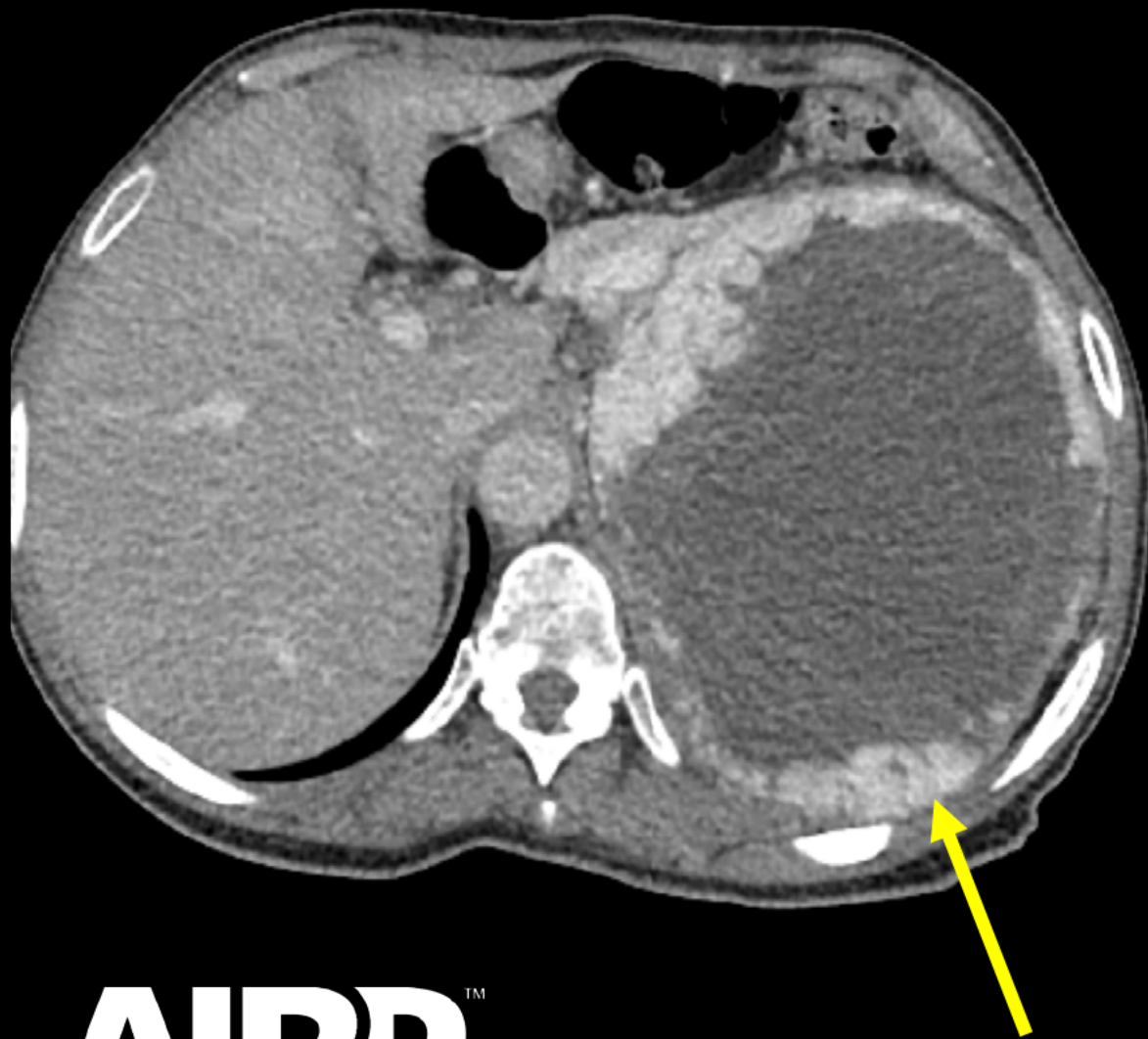# Clinical information

**62-year-old female with diabetes and hypertension who presented to the ED with abdominal pain, nausea, and poor appetite. The patient reported an 80-pound weight loss in the last 1.5 years with 30 pounds lost in the last 3 months.**



AMERICAN INSTITUTE FOR  
RADIOLOGIC PATHOLOGY

A PROGRAM OF THE  
AMERICAN COLLEGE OF RADIOLOGY

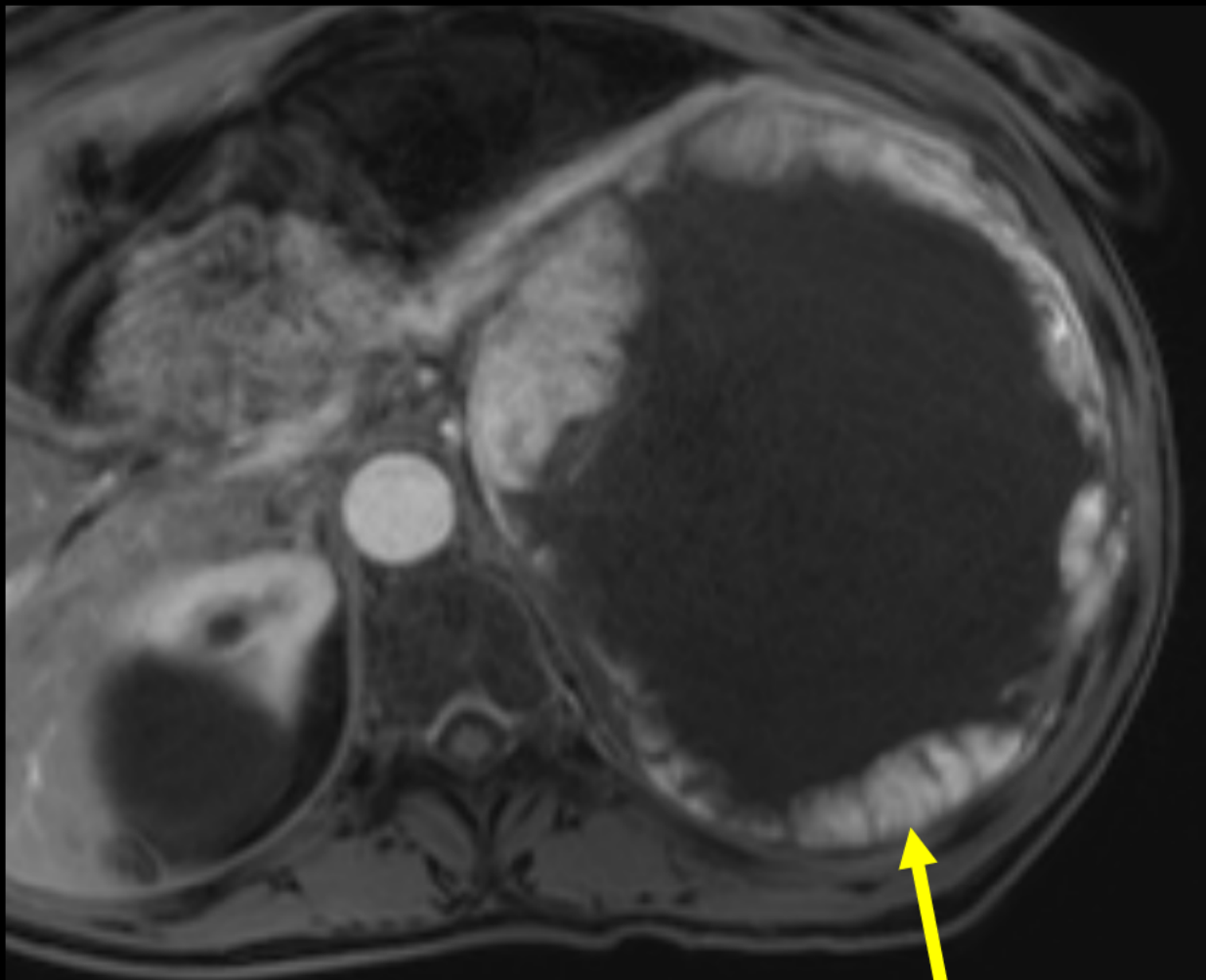


**AIRP**<sup>TM</sup>

AMERICAN INSTITUTE FOR  
RADIOLOGIC PATHOLOGY

A PROGRAM OF THE  
AMERICAN COLLEGE OF RADIOLOGY

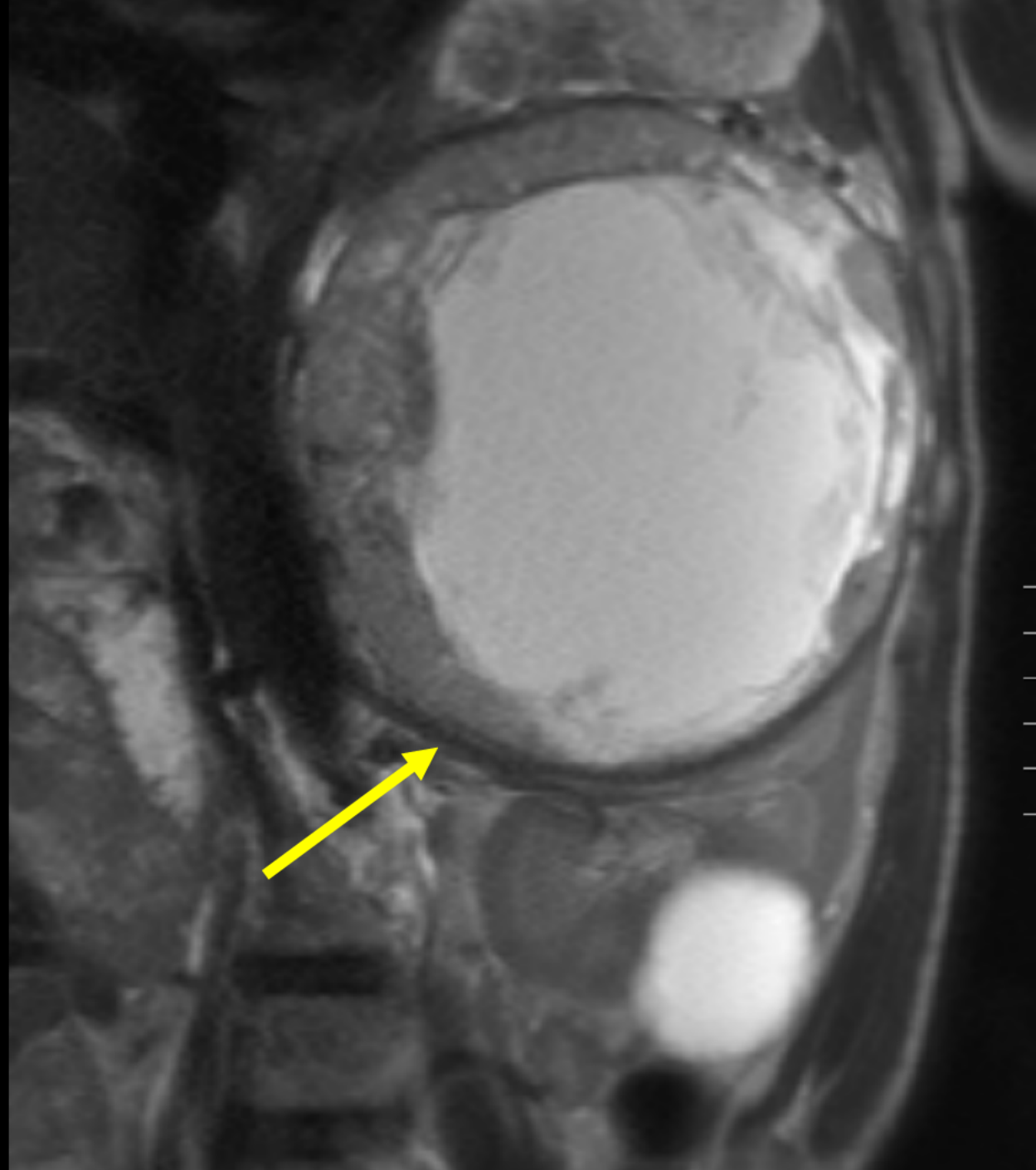


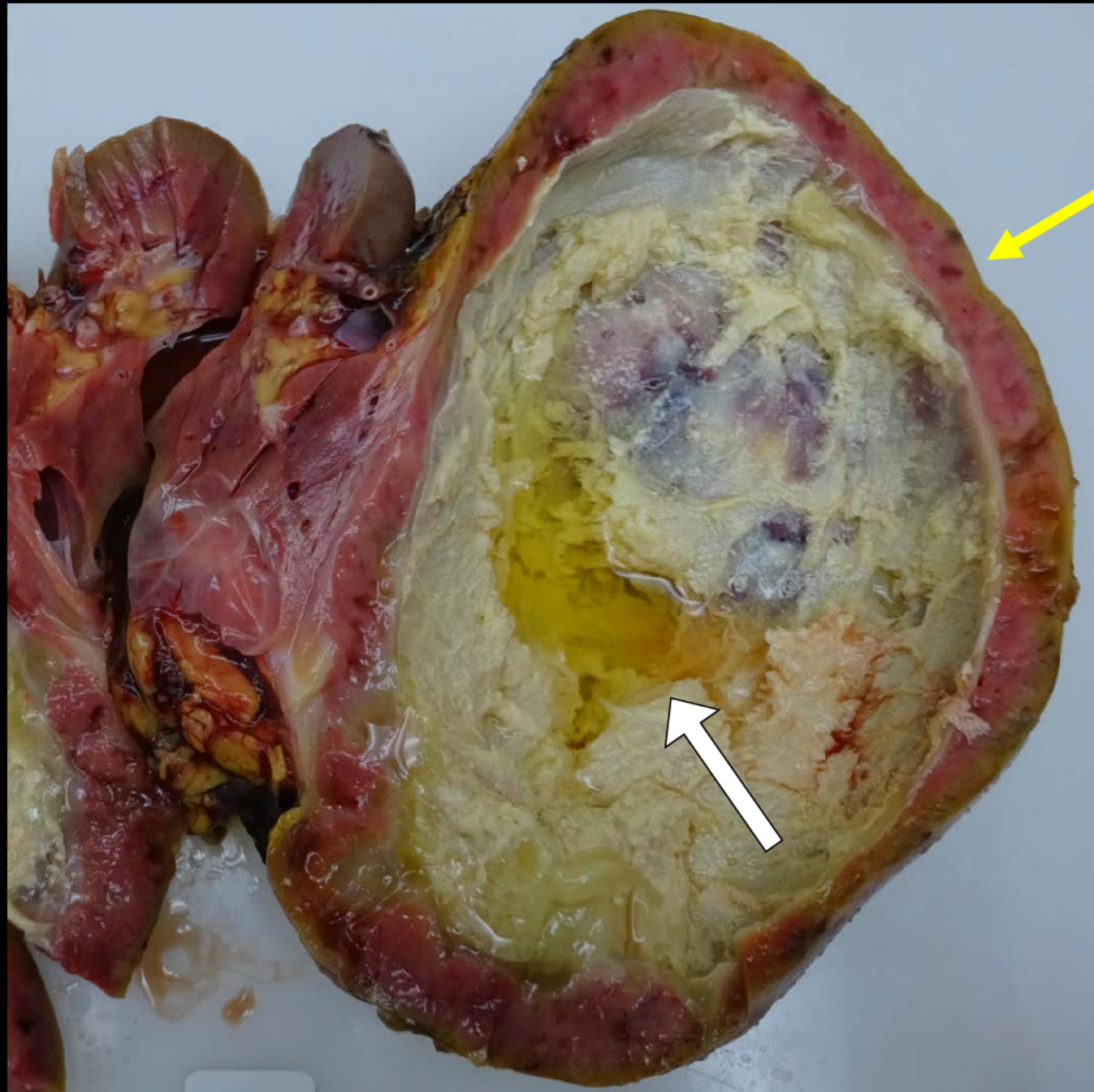


**AIRP**<sup>TM</sup>

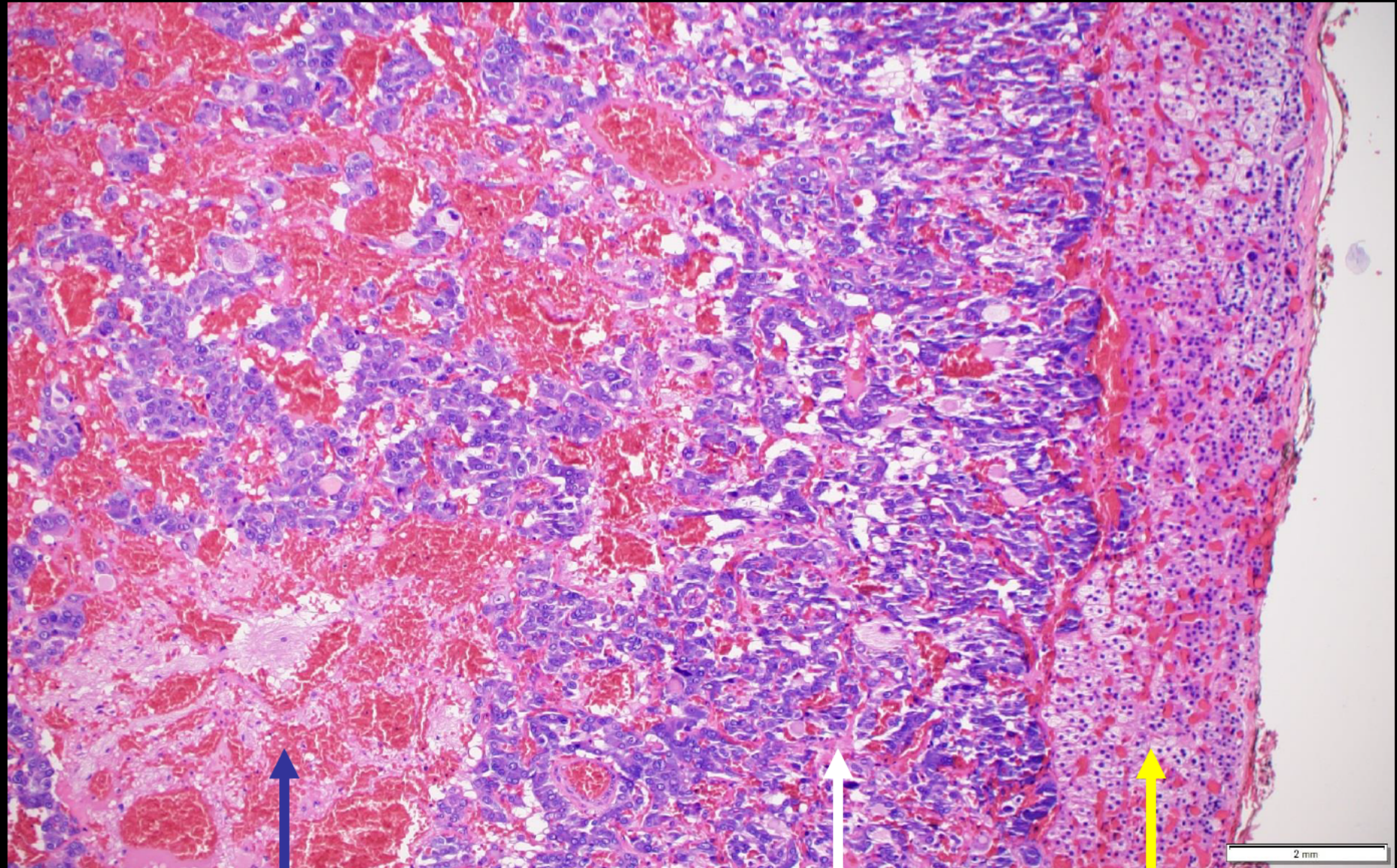
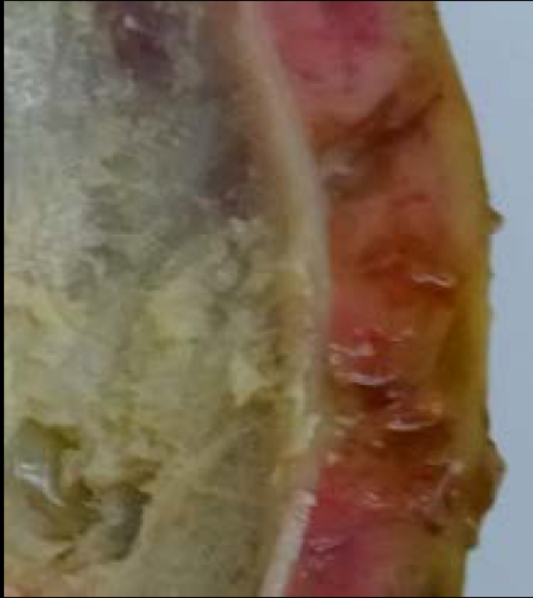AMERICAN INSTITUTE FOR  
RADIOLOGIC PATHOLOGY

A PROGRAM OF THE  
AMERICAN COLLEGE OF RADIOLOGY







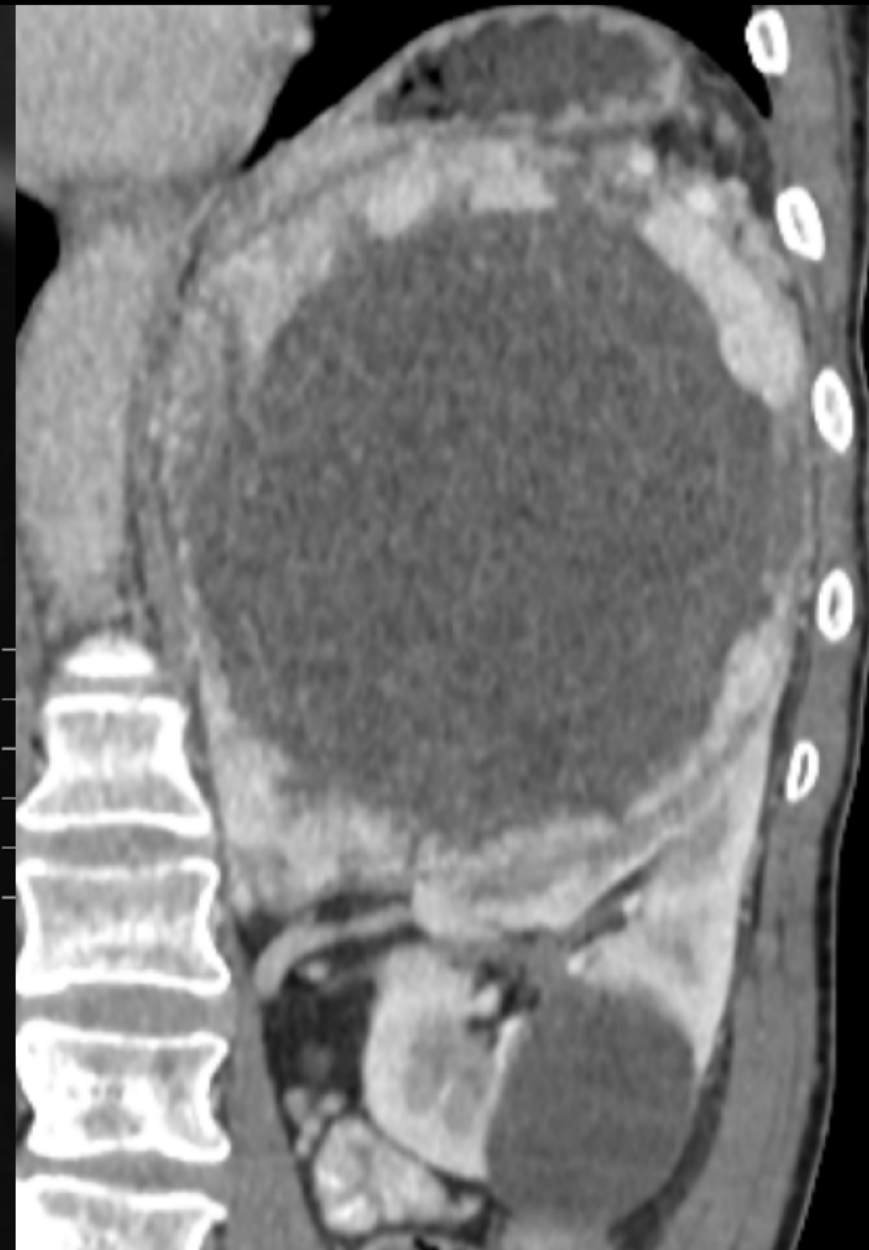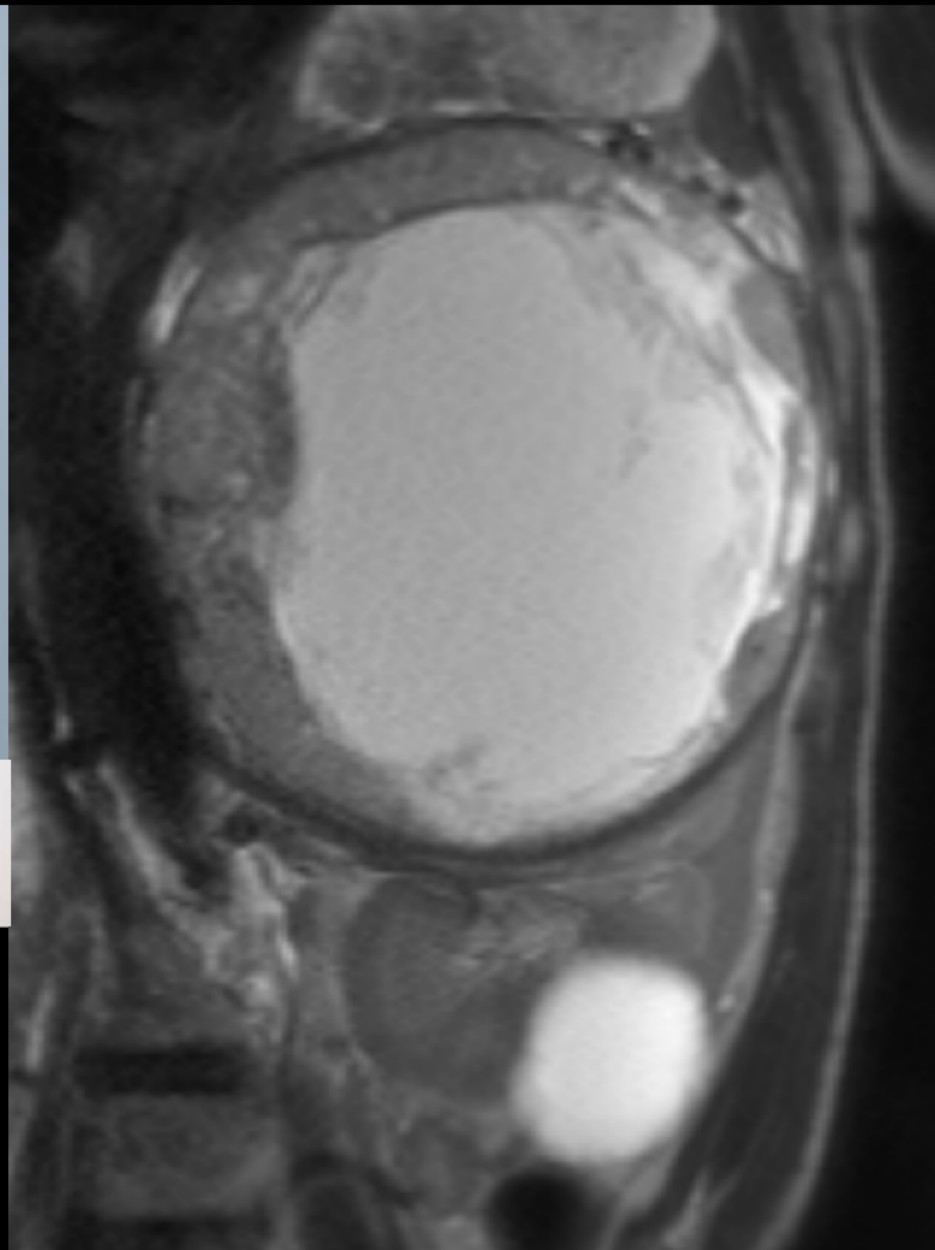
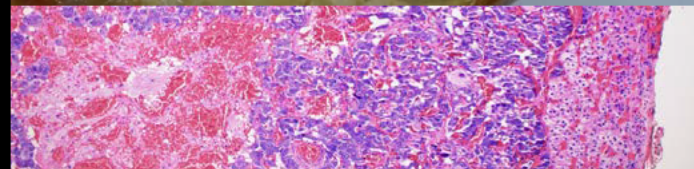

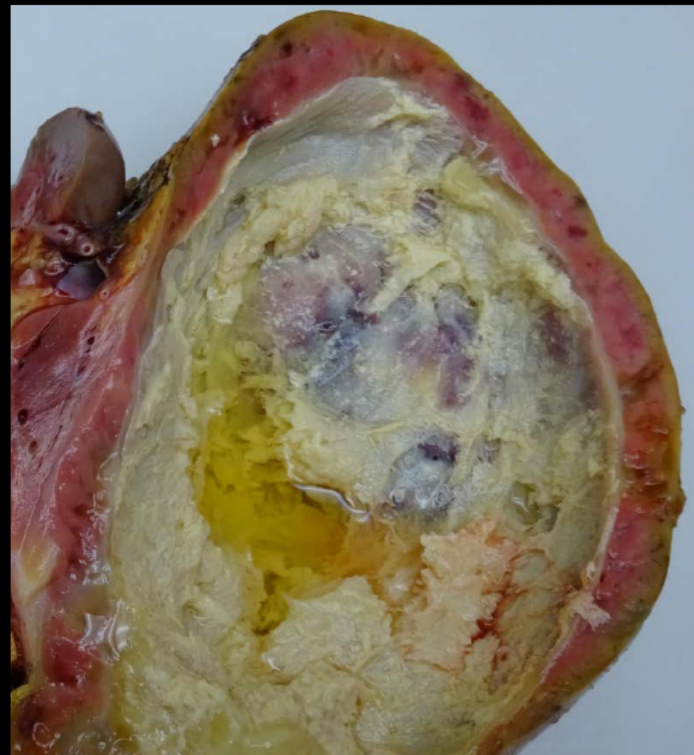
**AIRP**<sup>TM</sup>

AMERICAN INSTITUTE FOR  
RADIOLOGIC PATHOLOGY

A PROGRAM OF THE  
AMERICAN COLLEGE OF RADIOLOGY





**AIRP**<sup>TM</sup>

AMERICAN INSTITUTE FOR  
RADIOLOGIC PATHOLOGY

A PROGRAM OF THE  
AMERICAN COLLEGE OF RADIOLOGY



# Pheochromocytoma

Nicole Sztuk

University of Minnesota

Minneapolis, MN

**AIRP**<sup>TM</sup>

AMERICAN INSTITUTE FOR  
RADIOLOGIC PATHOLOGY

A PROGRAM OF THE  
AMERICAN COLLEGE OF RADIOLOGY