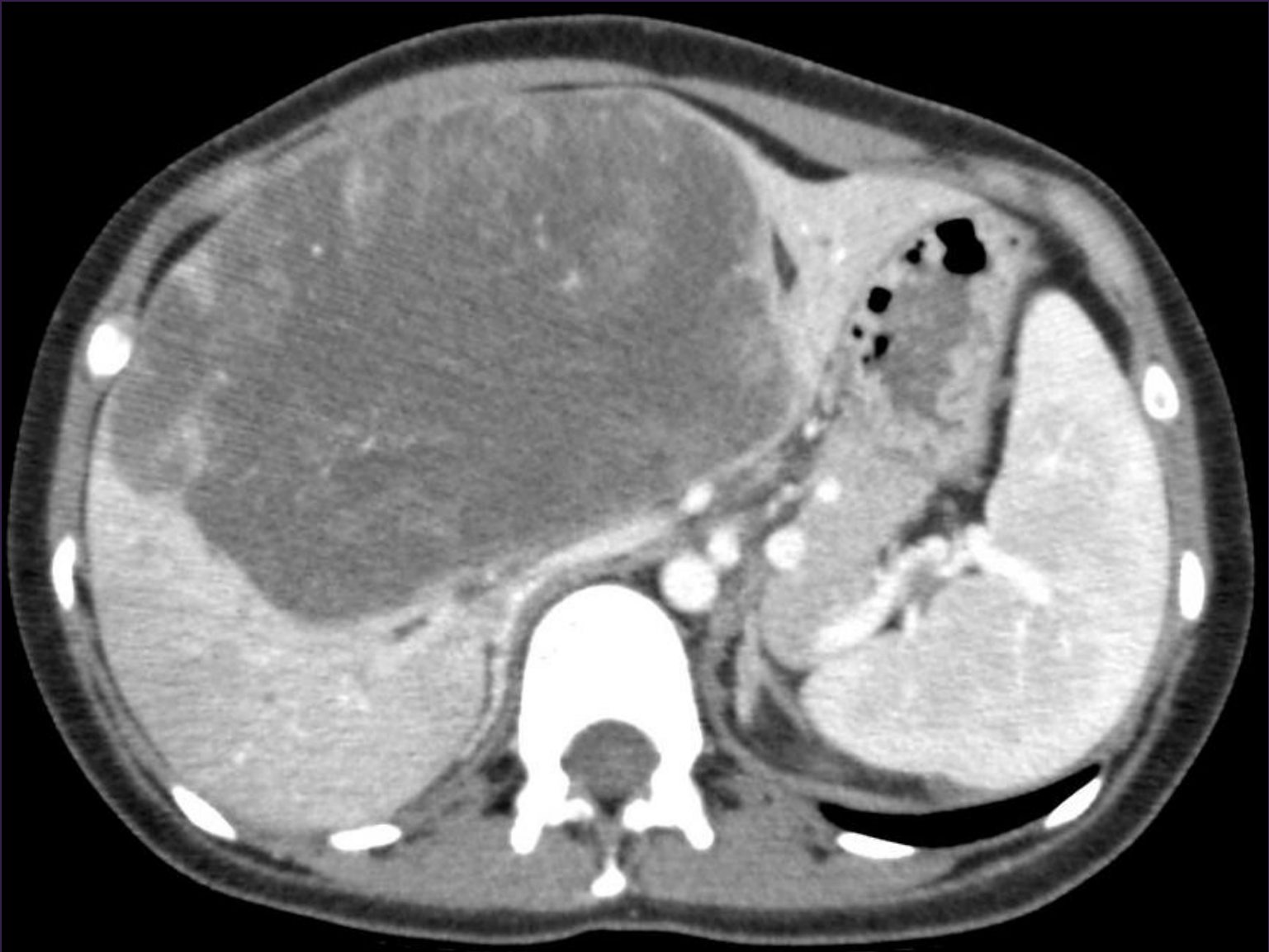

# Best Cases of the AIRP

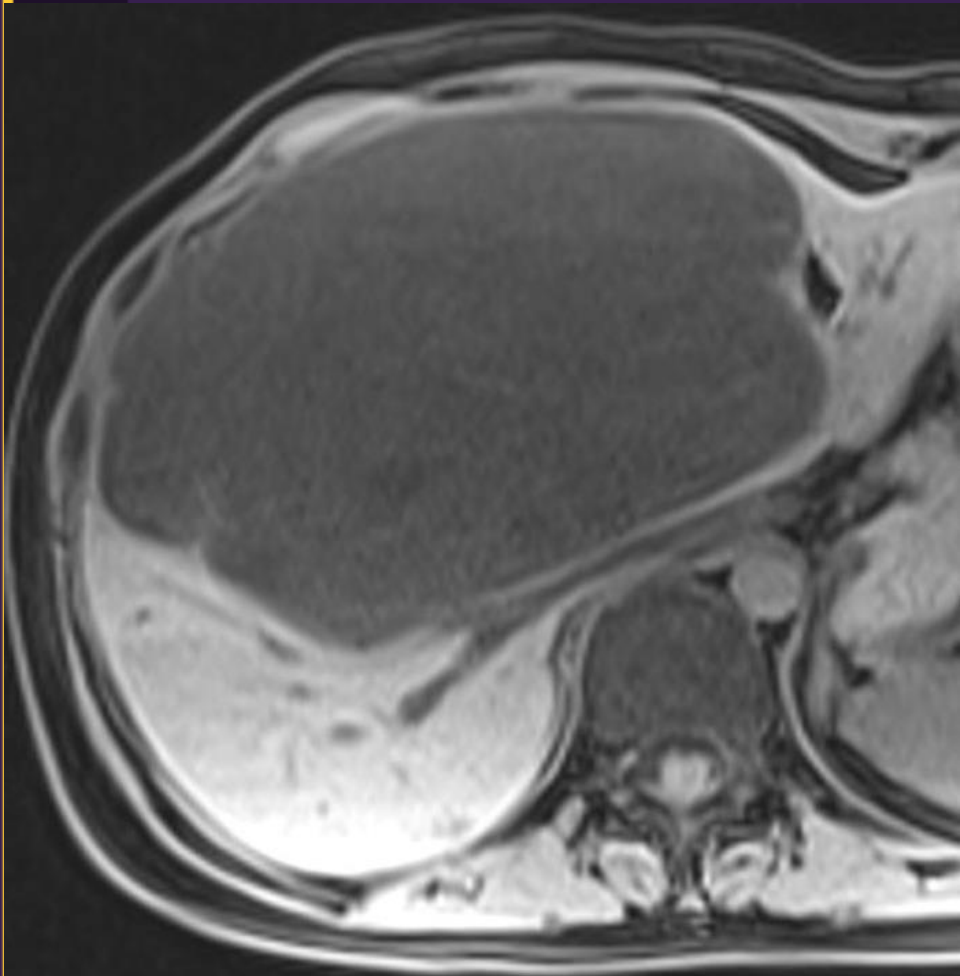
October 14 – November 8, 2013

# Gastrointestinal Best Case

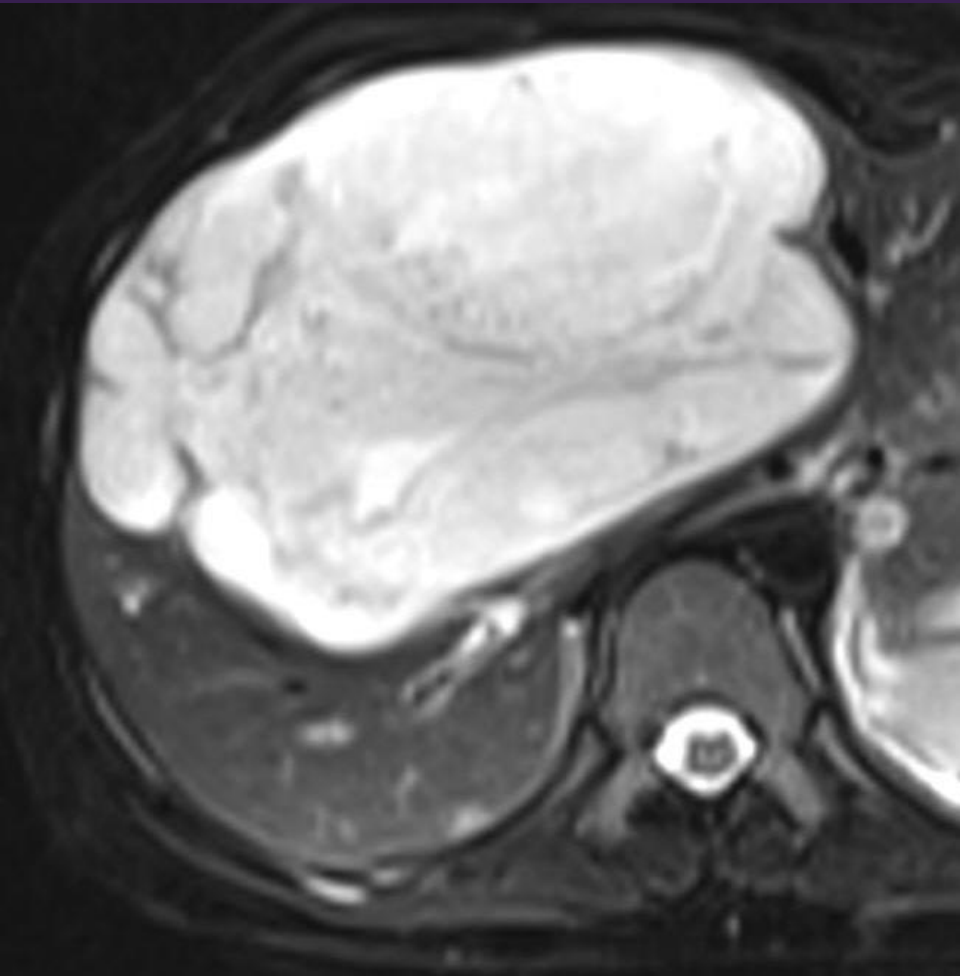
27-year-old woman with right upper quadrant and epigastric pain with fullness in her upper abdomen.

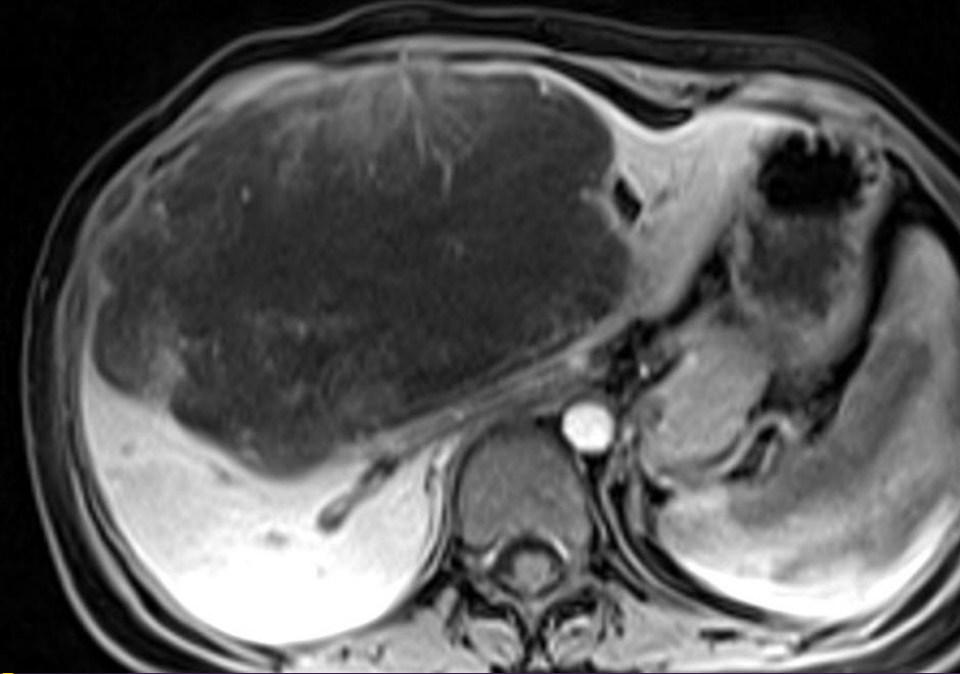


T1W

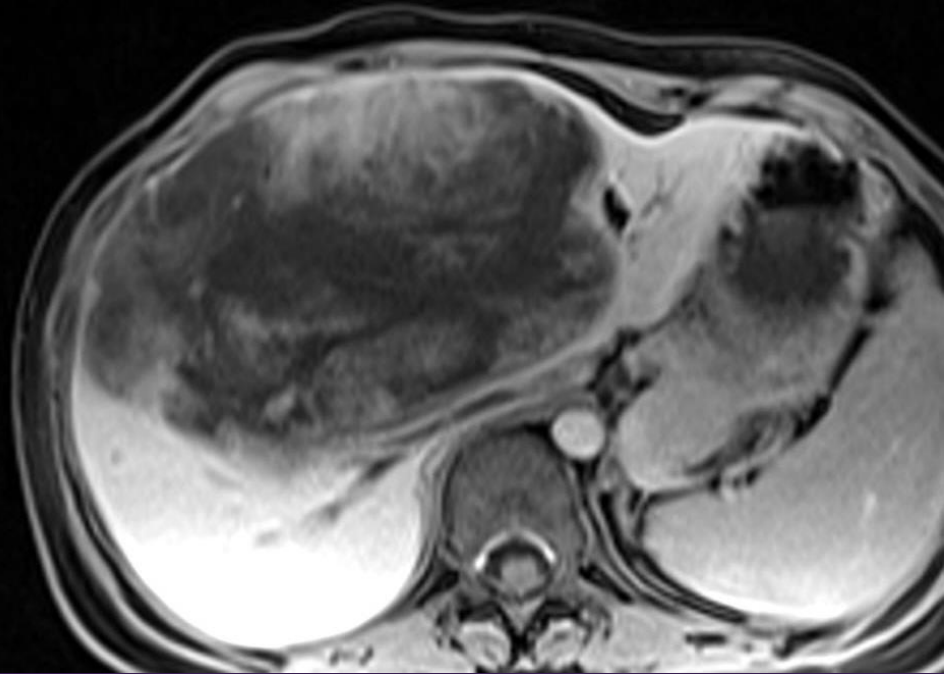


T2W



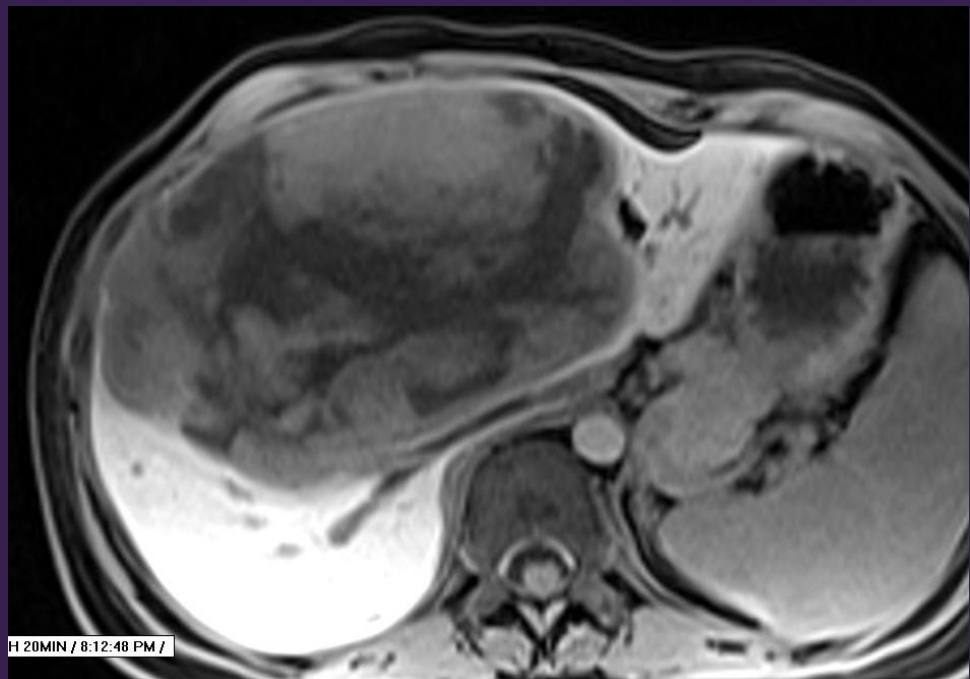


HAP



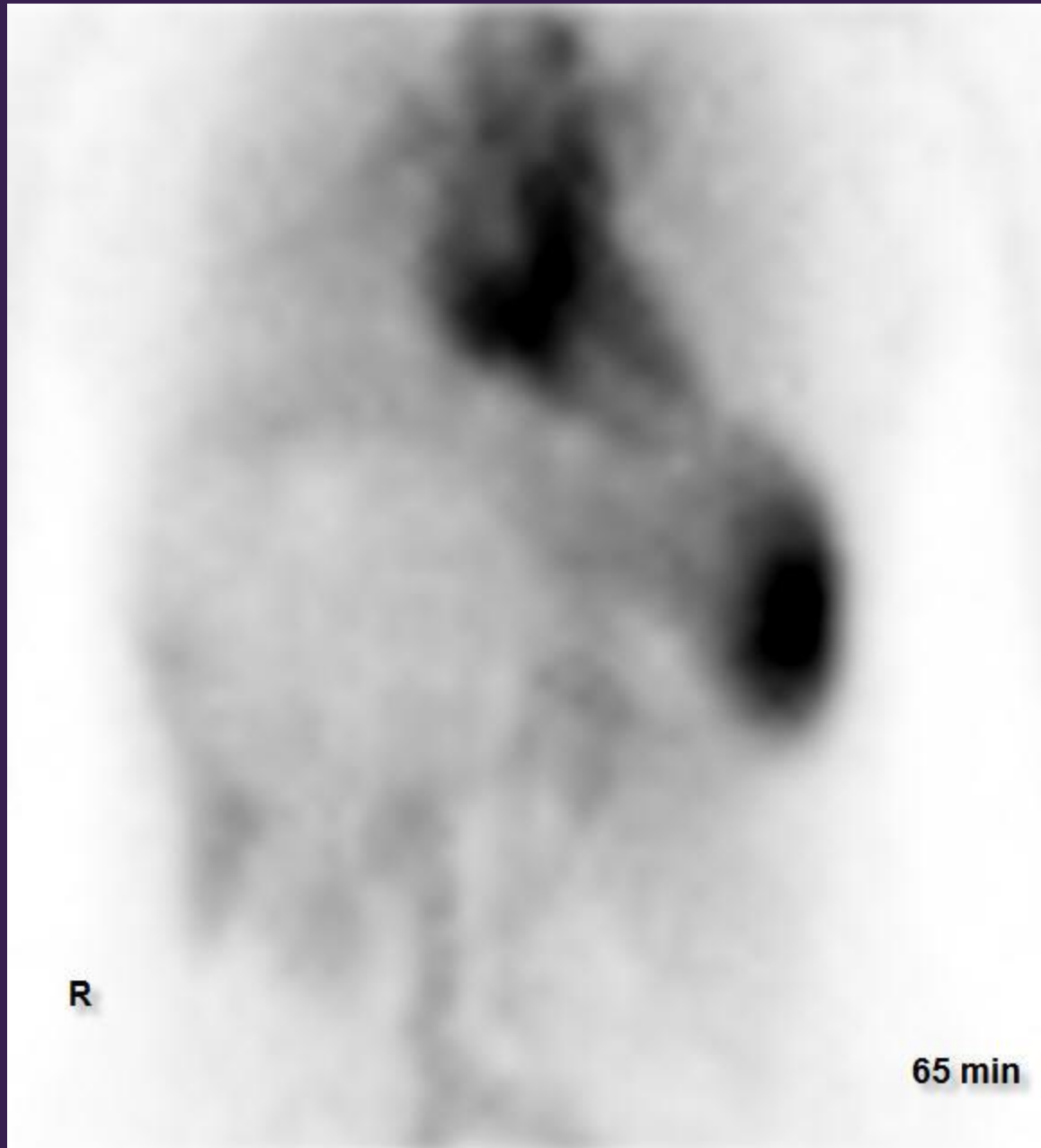
PVP

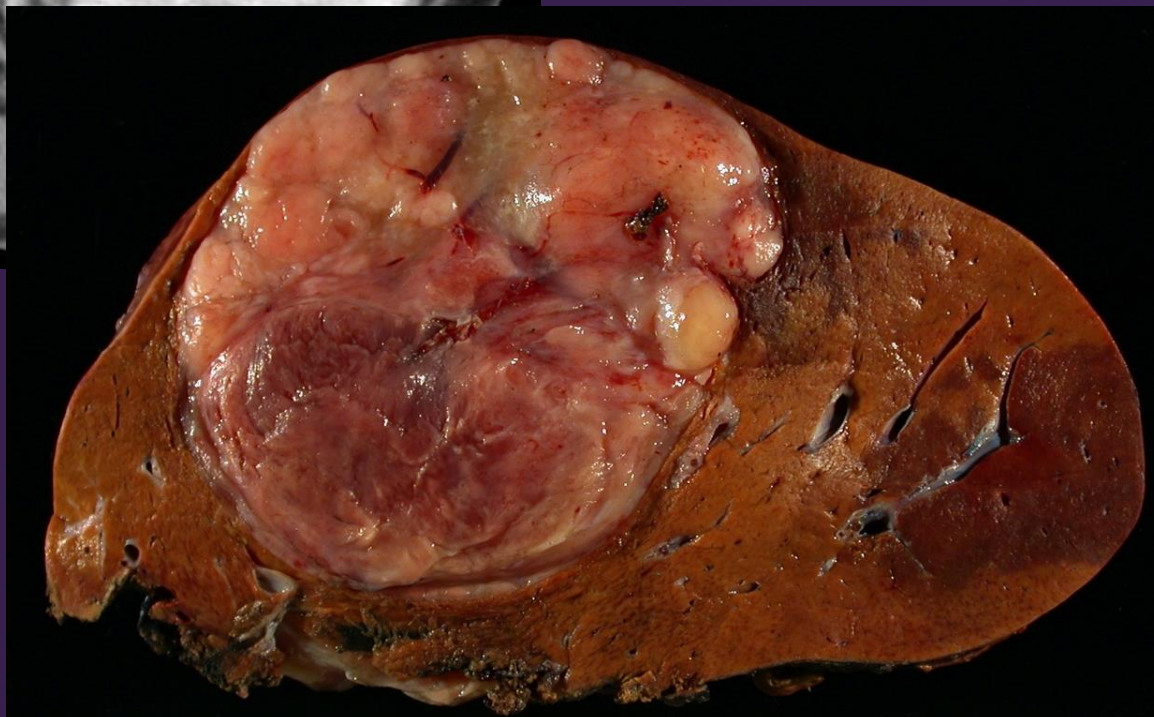
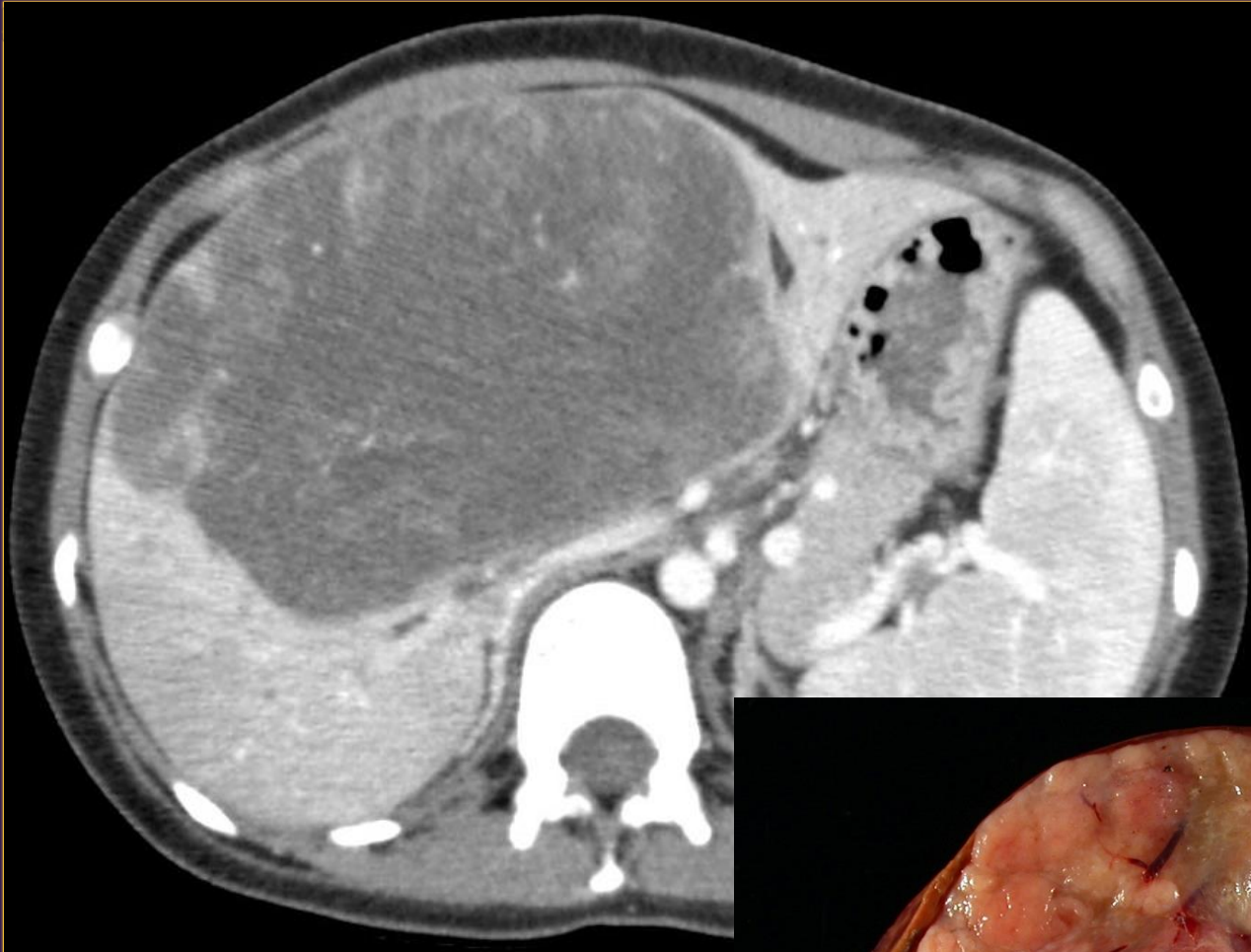HBP



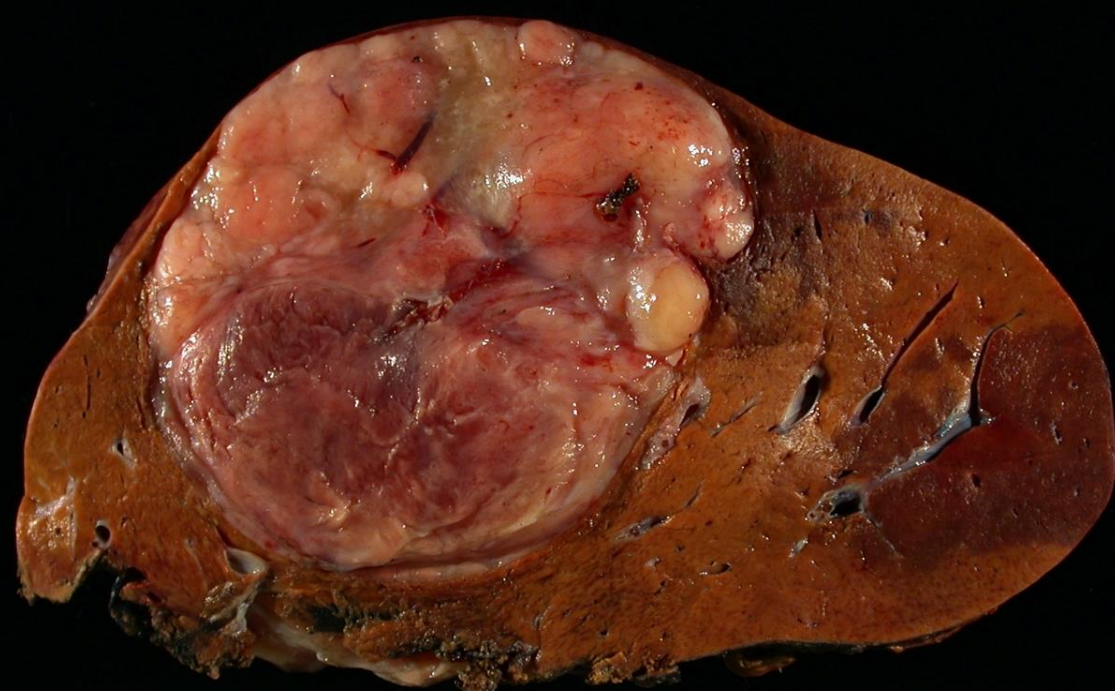
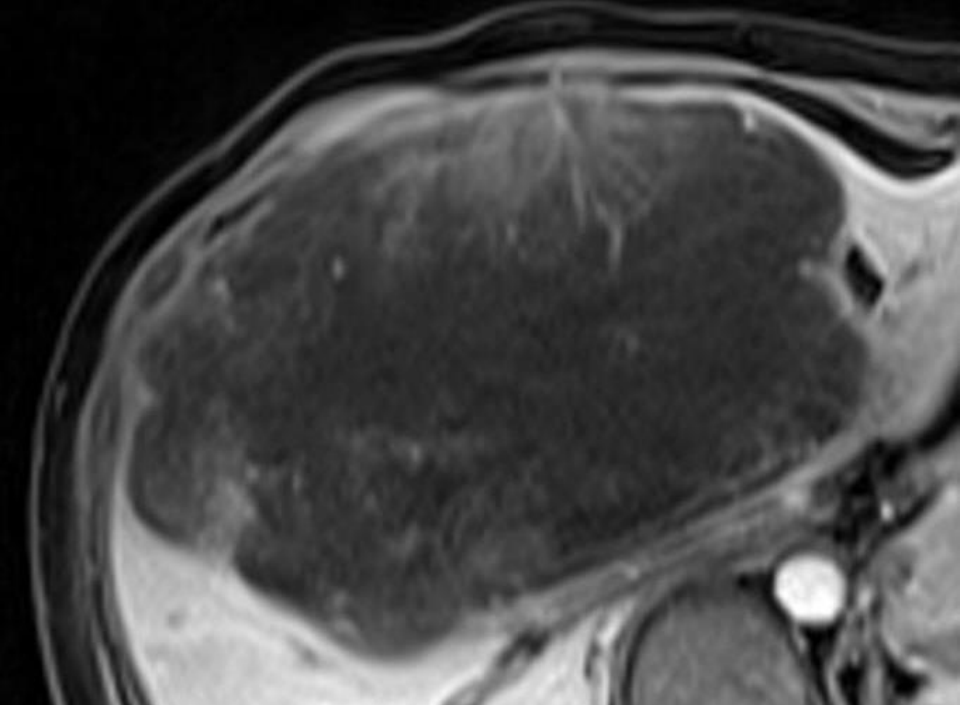
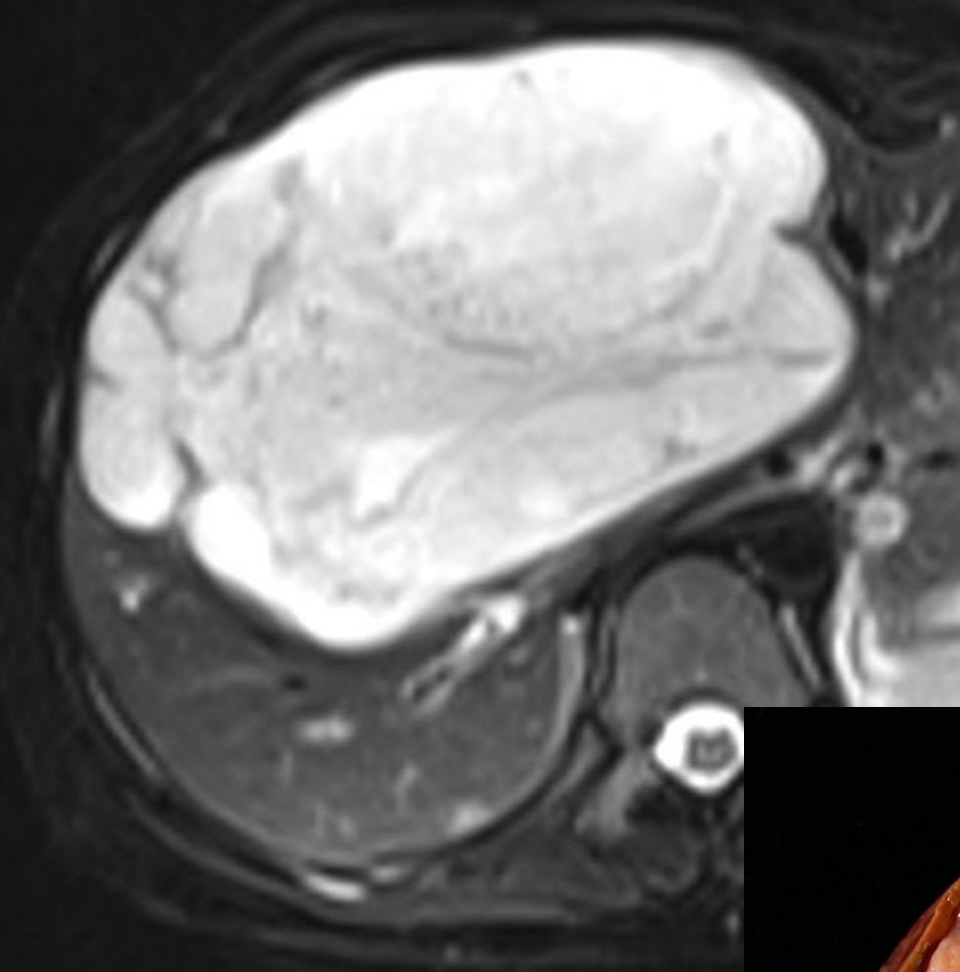
H 20MIN / 8:12:48 PM /

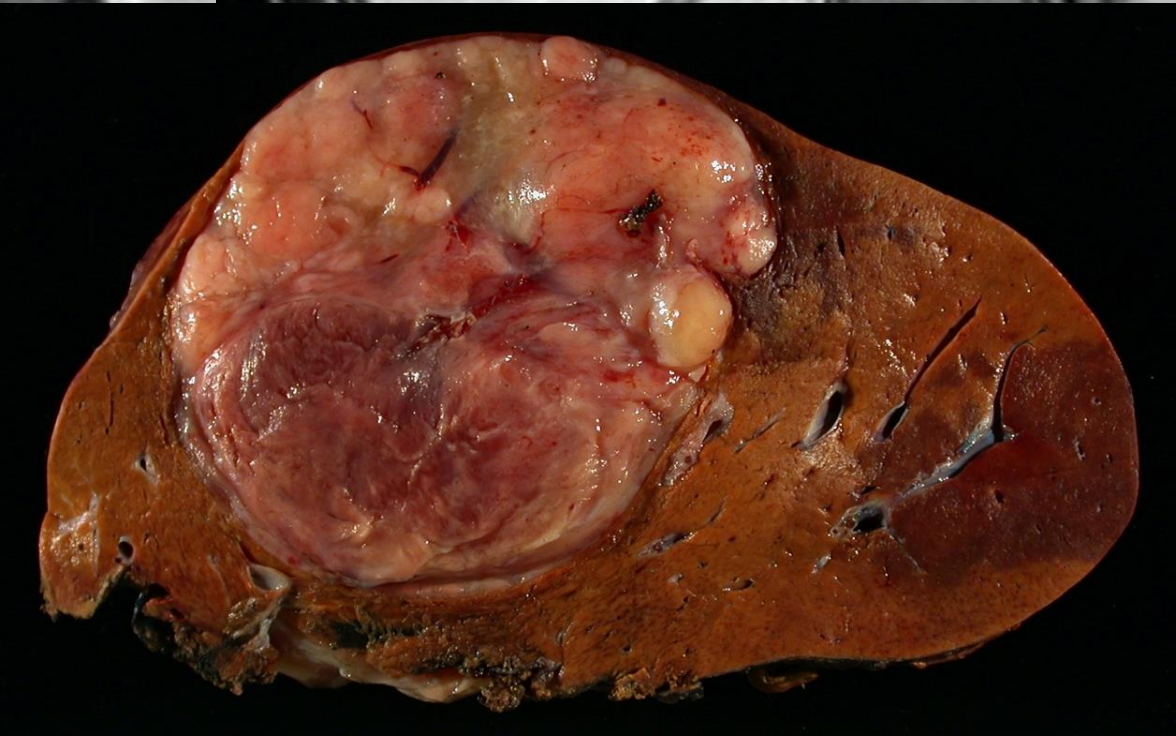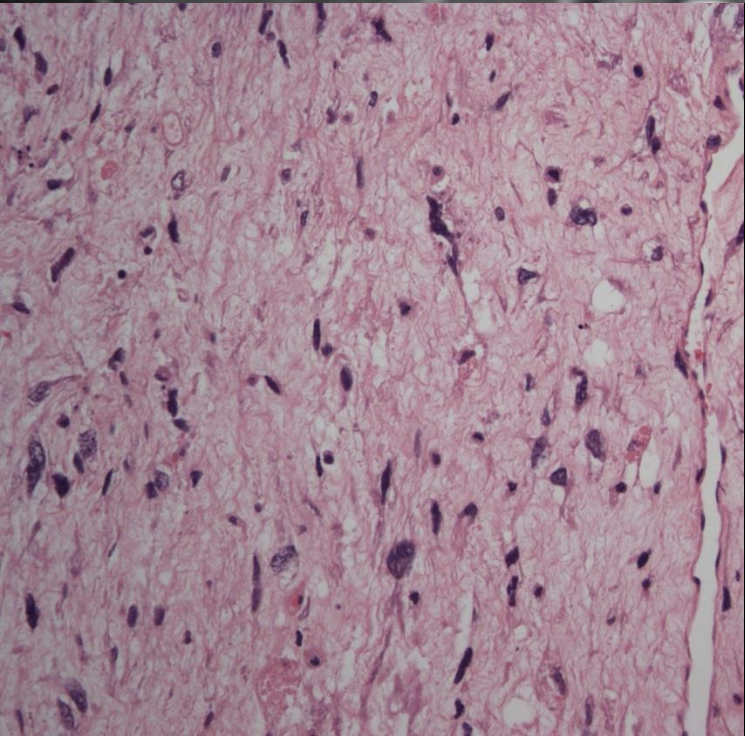
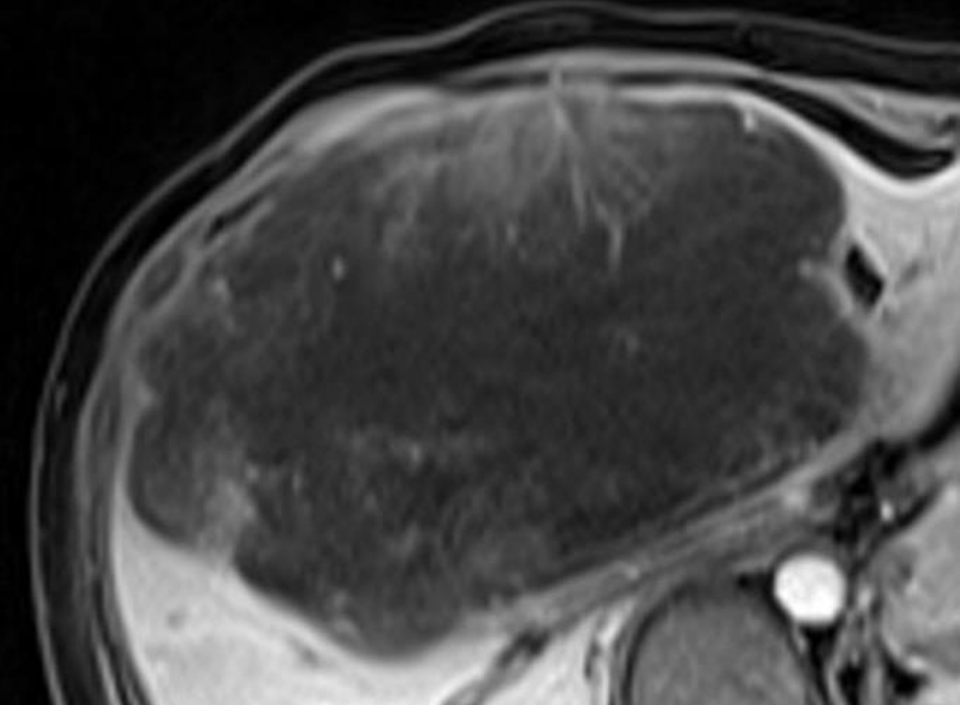
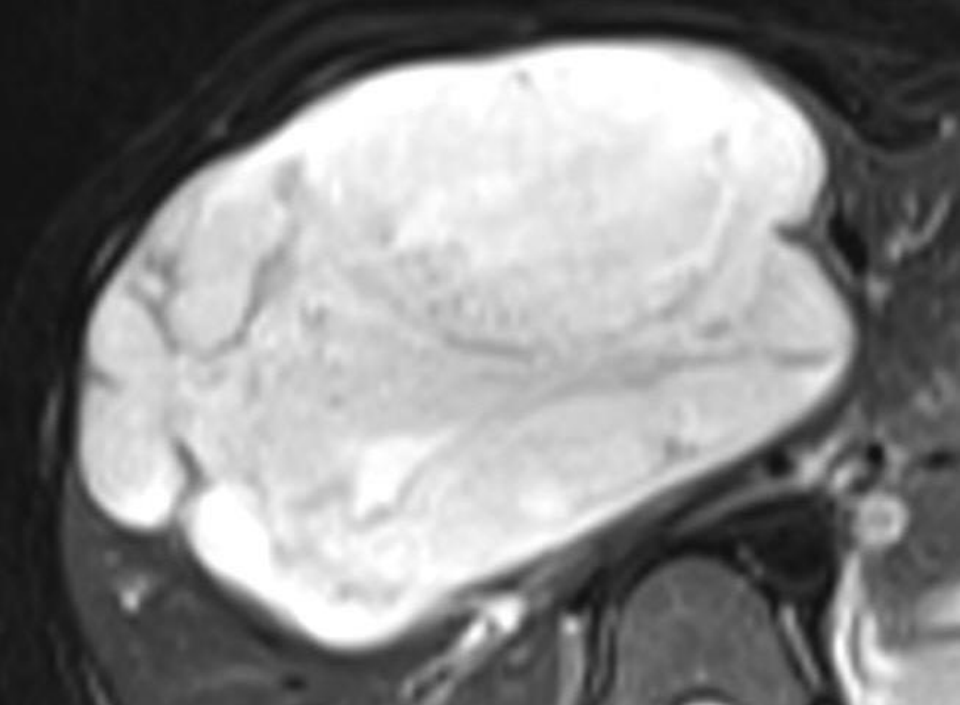
Tc-99m  
Tagged  
RBC Scan











# Undifferentiated Embryonal Sarcoma

Garrett Woodbury, MD  
University of Florida  
Gainesville, Florida

Many thanks to all of you for  
submitting such great cases!  
Have a safe trip home –

From the staff of the  
American Institute for Radiologic Pathology